

We are IntechOpen, the world's leading publisher of Open Access books Built by scientists, for scientists

4,800

Open access books available

122,000

International authors and editors

135M

Downloads

Our authors are among the

154

Countries delivered to

TOP 1%

most cited scientists

12.2%

Contributors from top 500 universities



WEB OF SCIENCE™

Selection of our books indexed in the Book Citation Index
in Web of Science™ Core Collection (BKCI)

Interested in publishing with us?
Contact book.department@intechopen.com

Numbers displayed above are based on latest data collected.
For more information visit www.intechopen.com



Pelvic Endometriosis: A MR Pictorial Review

Rosario Francesco Grasso, Riccardo Del Vescovo,
Roberto Luigi Cazzato and Bruno Beomonte Zobel
*Department of Radiology, Campus Bio-Medico University of Rome,
Italy*

1. Introduction

Endometriosis is one of the most common benign gynaecological conditions. It is defined as the presence of ectopic endometrial glands and stroma outside the uterus. The ectopic endometrium responds to hormonal stimulation with a cyclic hemorrhage, resulting in a complex spectrum of symptoms.

Pain is the cardinal symptom of endometriosis, even though patients may experience several different types of pain, such as dysmenorrhea, deep dyspareunia, discomfort during defecation or while urinating, according to the anatomic location of this disorder. Endometriotic implants, pelvic adhesions and ovarian endometriomas are commonly associated with chronic pelvic pain. Haemorrhage into an endometrioma may result in acute pain. Infertility is another commonly associated complaint.

The exact prevalence of endometriosis is not well defined, as the diagnostic gold standard is represented by laparoscopy or laparotomy. It is estimated about 5-10%, including both symptomatic and asymptomatic women. Nulliparous women and women reporting short and heavy menstrual cycles are at increased risk [1]; these epidemiological findings support the metastatic implantation from retrograde menstruation hypothesis. Other theories include the metaplastic differentiation of serosal surfaces or müllerian remnant tissue, and the induction of undifferentiated mesenchyme to form endometriotic tissue due to released substances from the shed endometrium (induction theory) [2].

The most common locations of endometriosis are the ovaries and the pelvic peritoneum, followed in order of decreasing frequency by deep lesions of the pelvic subperitoneal space, the intestinal system and the urinary system. Deep pelvic endometriosis is a pathologically distinct entity: deep endometriotic lesions penetrate under the surface of peritoneum (infiltration > 5mm) and are typically found in the uterosacral ligaments, rectum, rectovaginal septum, vagina or bladder, and induce a fibromuscular hyperplasia that surrounds endometriosis foci [3].

The diagnosis of endometriosis still remains a challenge for clinicians, resulting from similarities in clinical symptoms to other benign or malignant gynaecological diseases.

Laparoscopy is the standard of reference in the diagnosis of endometriosis; histological analysis of biopsy specimens should confirm the diagnosis, even if it is not necessary.

On the other hand, laparoscopy is also required for staging the disease. The most widely used staging system is the 1985 Revised Classification of Endometriosis published by the

American Fertility Society [4]. The rAFS score takes into account the presence of ovarian and peritoneal implants (subdivided into superficial or deep), the severity of the adhesions and the presence or not of a complete posterior cul-de-sac obliteration (i.e. frozen pelvis). The rAFS staging system has shown poor correlation to the clinical severity of the disease, so requiring further refinement. Meanwhile a new staging system called ENZIAN score has been recently developed [5]; it is focused on the deep pelvic endometriosis that is the most severe form of the disease.

The clinical value of this staging system and its correlation to the reproductive prognosis of endometriosis patients should be assessed.

Therapeutic options are observation, medical treatment, surgery or a combination strategy.

The most widely used medical therapy of endometriosis includes oral contraceptives, androgenic agents, progestins, and gonadotropin releasing hormone (GnRH) analogs. The choice of a surgical option depends upon the severity of the disease. Surgery is the main therapeutic option in patients with deep pelvic endometriosis. Anterior cul-de-sac endometriosis involving the bladder can be treated with laparoscopic surgery. Preoperative staging of disease is necessary because in certain cases surgery should be performed by standard laparotomy (bladder endometriosis associated with bowel involvement). Treatment of posterior cul-de-sac endometriosis can be achieved with laparoscopy, but a vaginal or a laparotomic approach is needed when vaginal or severe bowel disease, respectively are present.

2. Pathologic features of endometriosis

The most common site of involvement is the ovary, but virtually all pelvic organs can be affected by the disease.

Ovarian endometriosis includes a superficial form, which appears as small punctuate foci measuring no more than 5 mm, and a 'deep' one; in the latter case the typical aspect is that of the "chocolate cyst" or "endometrioma". Chocolate cysts typically have thick, fibrotic walls, a dark-brown, viscous content and their diameter rarely exceed 15 cm.

Aspect of endometriotic peritoneal implants ranges from punctuate foci to small stellar patches; according to the age of the lesion and the amount of pigment, they could appear white, yellow, red, blue or brown (**Fig. 1**).

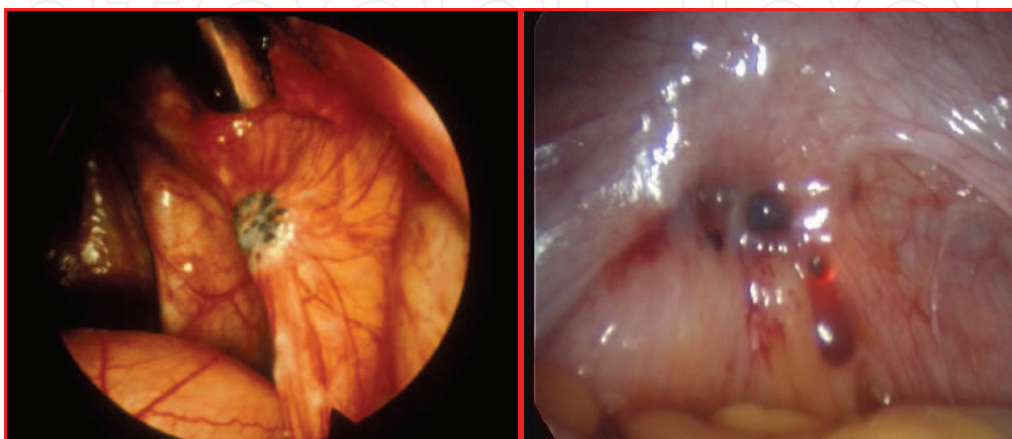


Fig. 1. Endometriotic nodules as they are seen in laparoscopy

When the peritoneal lesion invades the subserosal layers it progressively leads to extensive fibrosis, wall thickening of the pelvic organs, nodule formation and distortion of the normal pelvic anatomy due to a fibrous retraction; the most severe form is the so called "frozen pelvis", that consists of a huge amount of tissue involving the retro-uterine excavation and causing an extensive infiltration of the posterior pelvis (torus uteri, uterosacral ligaments, vaginal and rectal wall).

Microscopic appearance of endometriosis is composed of endometrial glands, stroma and occasionally histiocytes, due to an inflammatory response caused by cyclic hemorrhages within the implant. In rare cases endometriosis may lack glands (stromal endometriosis) [6].

3. Radiologic evaluation of endometriosis

Radiologists are often involved in the diagnosis and pre-operative assessment of the disease: an accurate pre-operative evaluation of the endometrial implants (location, size and depth of penetration) could help the surgeon to perform a radical surgical excision in cases in which severe fibrosis and adhesions hide deep lesions and impede laparoscopic evaluation.

Imaging methods that are used in the daily practice to diagnose endometriosis are ecotomografy, especially Transvaginal Ultrasound (TVUS) and Magnetic Resonance Imaging (MRI).

TVUS provides high resolution images of the pelvic organs, providing reliable information in patients with both acute and chronic pelvic pain [7].

The classic endometrioma on TVUS appears as an area of low and homogenous echoes.

TVUS has been reported to be the best method for discriminating between endometriotic and non-endometriotic cysts, with a sensitivity of 83% and a false positive rate of 7%. The addition of CA-125 evaluation does not improve the diagnostic accuracy of TVUS, thus indicating TVUS alone to be the least expensive instrument for identifying the presence of endometriomas [8,9].

The role of TVUS for the assessment of deep pelvic endometriosis has been recently reported, with conflicting results. TVUS is apparently more accurate than Rectal Endoscopic Ultrasound (RES) for predicting deep pelvic endometriosis in specific locations and should be the first line imaging method in this setting [10]. RES appears to be the best technique for evaluating the depth of bowel infiltration by endometriosis [11].

The role of MRI in the diagnosis of endometriosis has increased after 1987, when Nishimura *et al.* [12] demonstrated the value of this imaging method in the diagnosis of endometriomas. Then the use of MRI for the evaluation of deep endometriosis was proposed by Siegelman *et al.* [13], who studied its role in analysing solid pelvic masses. More recently other investigators [14] showed the promising results of MRI for the specific evaluation of deep endometriosis.

Also dynamic MR imaging has been tested for this purpose, showing a good accuracy in the differential diagnosis of nodular endometriosis from other pathologic conditions of abdominal wall and pelvis [15].

4. MRI technique

In our experience, MRI studies are performed with a 1.5 T magnet (Magnetom Symphony; Siemens Erlangen, Germany) and a surface phased-array coil. Patient preparation requires intravenous injection of an antispasmodic drug prior to study in order to reduce artefacts from bowel motion.

On the basis of the characteristics of our system, the standard imaging protocol includes a coronal T2-weighted HASTE sequence (half-Fourier single shot turbo spin echo: TR 700 ; TE 89; section thickness 6.0 mm; field of view 350x450 mm; matrix 320; time of acquisition 21 s), transverse T1-weighted turbo spin echo sequences from the iliac crest to the pubic sinifisis (TR 771; TE 9.7; section thickness 4.0 mm; field of view 400 x 219 mm; matrix 512x512; time of acquisition 2:46), transverse, sagittal and coronal T2-weighted turbo spin echo sequences. These sequences allow an initial complete analysis of the pelvic region and a preliminary evaluation of endometriotic lesions, which appear as hyperintense lesions in T1-weighted sequences and mildly hypointense or hyperintense in T2 weighted sequences. The FLASH T1-weighted sequences with fat suppression in transverse, coronal and sagittal plane (Fast Low-Angle Shot 2D: TR 357; TE 4.76; FA 70°; section thikness 4.5 mm; field of view 300x300 mm; matrix 256x256; time of acquisition 1:31) (T1 flash 2d fat sat) are performed to evaluate adnexal masses because they allow a distinction between a fatty content lesion (for example a teratoma, which appear hypointense in fat-suppressed T1 weighted sequences) and endometriomal cyst (that exhibits a typical hyperintense signal in such sequences). Fat-suppressed MRI is also useful in enhancing the contrast between hemorrhagic implants and normal tissue.

Contrast-enhanced FLASH T1-weighted sequences (gadolinium Gd-DTPA 0.1 mmol/kg is administrated intravenously) are performed in selected cases, expecially when a mural nodule within a hyperintense endometrioma is observed. Finally, the contrast agent is administrated when the initial images carry the suspicion of ureteral infiltration. In such cases we perform FLASH 3D T1 weighted sequences in the coronal plane with MIP reconstruction of 1 mm (MR Urography) (TR: 2.96; TE 1.21; section thickness 1.40 mm; field of view 350x490 mm; matrix 384; time of acquisition 20 sec).

5. Spectrum of MRI findings

The diagnosis of endometriosis by means of MRI is based on the combination of two aspects: presence abdominal areas with morphologic and signal intensity abnormalities. Endometriotic lesions appear hyperintense on T1-weighted images and mildly hypointense or hyperintense on T2-weighted images (**Fig. 2A, B**). Gradual variation of signal intensity on T2-weighted images has been described as the “shading” sign (**Fig. 2A**) and it is due to chronic bleeding with accumulation of high concentration of iron and protein in the endometrioma.

Fat saturation allows differentiation between hemorrhagic (endometriomas) and fatty (dermoid cyst) content of cystic lesions (**Fig. 3**). Moreover, it increases detection of small implants.

Use of contrast-enhanced imaging is required to identify solid enhancing nodules within endometriotic cysts when malignant transformation is suspected or to define the extent of inflammation associated with endometriosis.

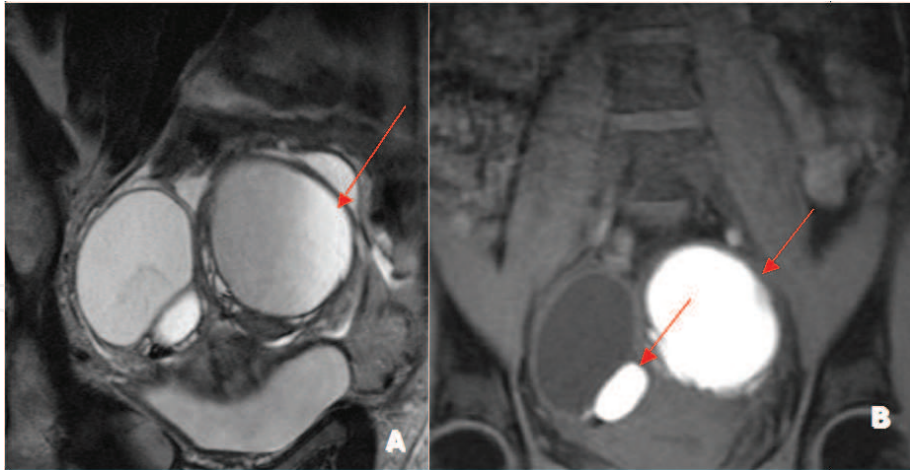


Fig. 2. Endometriotic lesions appear mildly hypointense or hyperintense on T2-weighted images (A) and hyperintense on T1-weighted images (arrows in B). Gradual variation of signal intensity on T2-weighted images has been described as “shading” sign and is due to chronic bleeding with accumulation of high concentration of iron and protein in endometriomas (arrows in A).

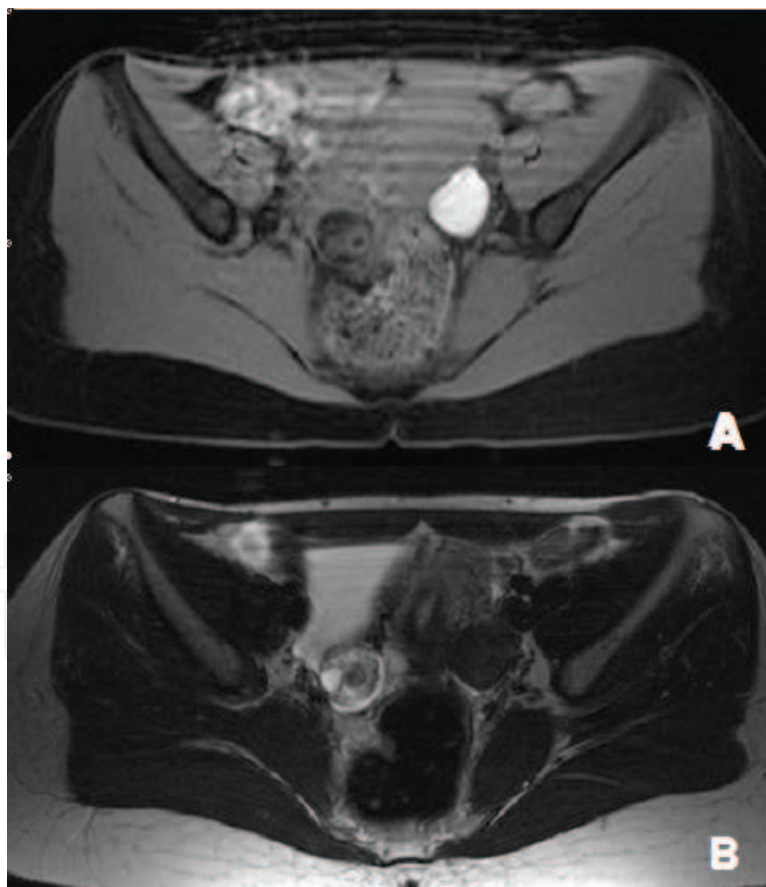


Fig. 3. T1-weighted-fat-suppressed image showing a hyperintense mass on the left ovary and a disomogenous hypointense mass on the right one (A). On T2-weighted sequence (B) the left mass appear hypointense. The left mass proved to be an endometrioma with recent hemorrhage; on the contrary, owing to its appearance on fat-suppressed sequence, the right mass proved to be a dermoid cyst.

5.1 Ovarian endometriosis

Adnexal localization is the most common clinical setting of endometriosis.

TVUS remains the first diagnostic method in the evaluation of the ovary, generally reserving MRI as a tool for resolving cases in which there is some doubt.

At MRI, a large endometrioma (>1 cm in diameter) appears as a homogeneously hyperintense mass on T1 weighted MR images and show a low signal intensity on T2 weighted MR images with areas of high signal intensity. The 'shading' sign is used to differentiate endometriomas from functional hemorrhagic cysts that do not show it, which usually disappears at subsequent MRI examinations.

Another diagnostic criteria for a definitive diagnosis of endometriomas is the presence of multiple T1 hyperintense cysts regardless of their T2 signal intensity [16].

Endometriomas are often bilateral (more than 50% of cases), multilocular or associated with interovarian adhesions; in the last case a typical MRI pattern called "kissing ovaries" could be noted (Fig. 4).

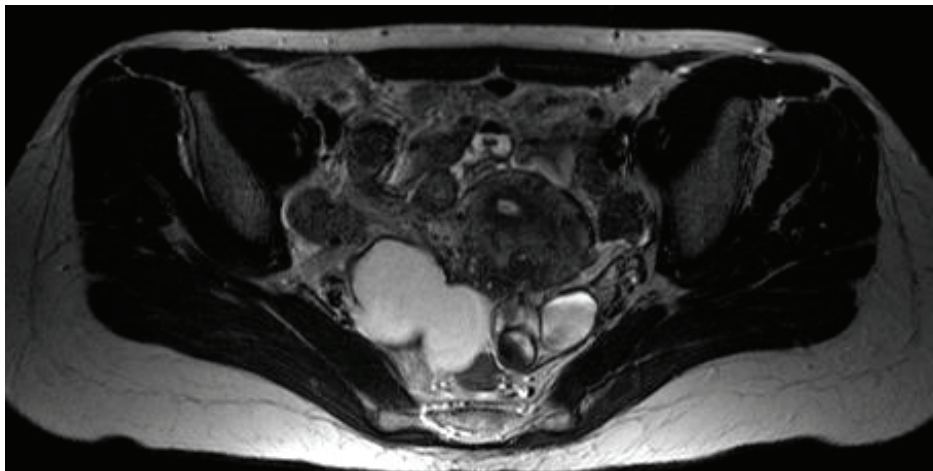


Fig. 4. T2-weighted image acquired on the transverse plane, showing hyperintense bilateral endometrioma masses on the ovaries that are closed up due to interovarian adhesions (Kissing ovaries).

Fat suppression is mandatory to differentiate endometriomas from cystic teratomas.

5.2 'Deep endometriosis'

Deep endometriotic lesions are classified according to the anatomic location in the anterior compartment (bladder) or in the posterior compartment (uterosacral ligament, vagina and bowel).

Multifocality is a major characteristic of deep endometriosis, thus requiring in some cases different surgical procedures (laparoscopy and/or laparotomy) to obtain a complete exeresis and a functional improvement.

5.3 Endometriosis of the bladder

Localization of disease in the bladder is estimated in < 1% of patients.

Uterus is usually anteflexed and the anterior cul-de-sac is obliterated due to extensive adhesions. The patient often complain pain, especially while urinating.

Two types of bladder endometriosis have been recognised. One develops exclusively after cesarean section and is considered to result from iatrogenic implantation of decidua. The other, a primary form, is found in women who have not previously undergone surgery on the uterus. Various hypotheses have been proposed to explain the pathogenesis in the latter case. Microscopically, the typical pattern is a focus of endometriosis scattered in the bladder wall. The main feature is the paucity of endometrial-type stroma [17].

MRI is reliable for the diagnosis of bladder endometriosis. Endocavitary coil MRI is reliable for establishing the depth of the lesions penetrating into the bladder wall [18].

On MRI images, bladder endometriosis can be diagnosed as a localized or diffuse bladder wall thickening, or as focal signal intensity abnormality. T2 and T1 weighted images can show a nodular hypointense mass usually located on the anterior upper or posterior bladder wall (**Fig. 5**).

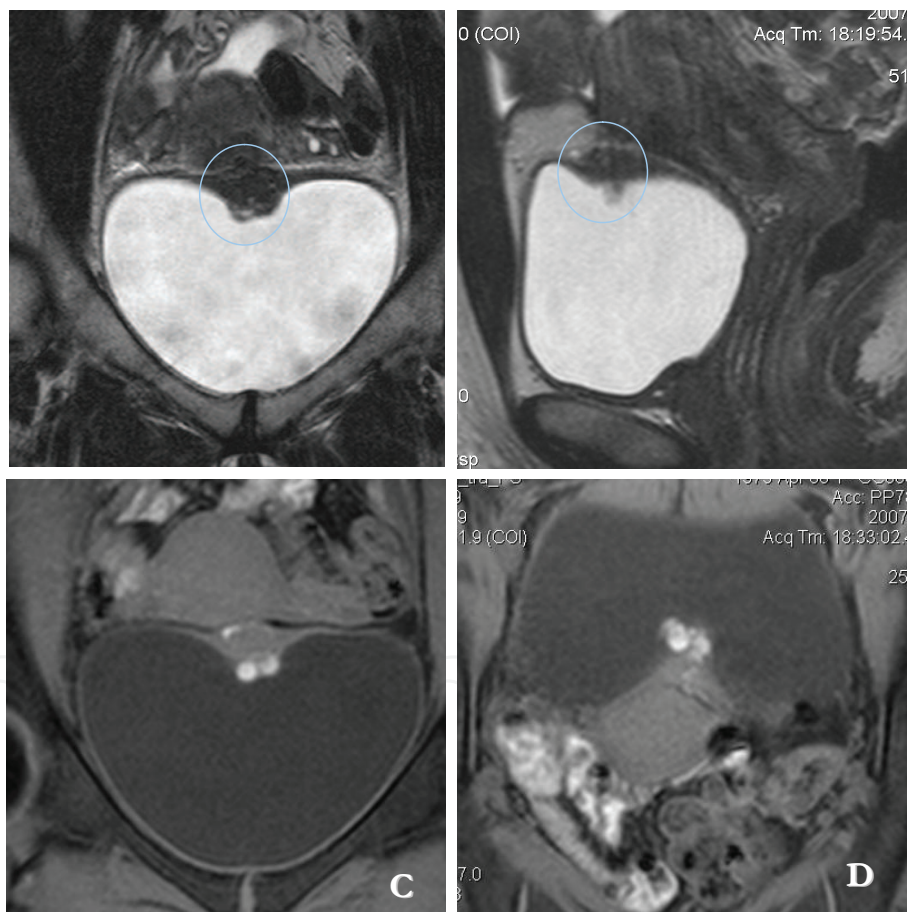


Fig. 5. Coronal (A) and sagittal (B) T2-weighted images showing localized bladder wall thickening in the anterior upper bladder wall (blue circles). On fat suppressed T1-weighted coronal (C) and axial (D) images some high signal intensity intra-lesion spots indicating recent haemorrhage.

On fat suppressed T1-weighted FLASH 2d images, some high signal intensity intralesional spots are present in some cases.

5.4 Endometriosis of the uterosacral ligaments (USLs)

USLs are one of the most common targets of pelvic endometriosis, which is diagnosed more frequently in a clinical than in a surgical setting. USLs extend over a mean cranio-caudal distance of 21 ± 8 mm. Three regions of origin have been found: cervix alone, vagina alone, cervix and vagina. Insertion points are the piriformis muscle, the sciatic foramen and the ischial spine [19].

This affliction often elicits pelvic pain, dyspareunia and painful bowel movement.

Women with endometriosis in this site present thick USLs due to endometriotic nodules and subsequently, fibrosis is responsible for cul-de-sac obliteration.

TVUS may provide quantitative information to manage patients with USLs endometriosis [20].

At MRI, involvement of USLs by endometriosis is diagnosed when the ligament appears thickened or shows irregular margins (**Fig. 6**) compared with the margins of the controlateral ligament. T2-weighted images identify all lesions as iso- or hypointense to myometrium, while T1-weighted images are less sensitive due to lesions isointensity to myometrium. The proximal portion of the ligament typically presents with asymmetric nodular thickening.

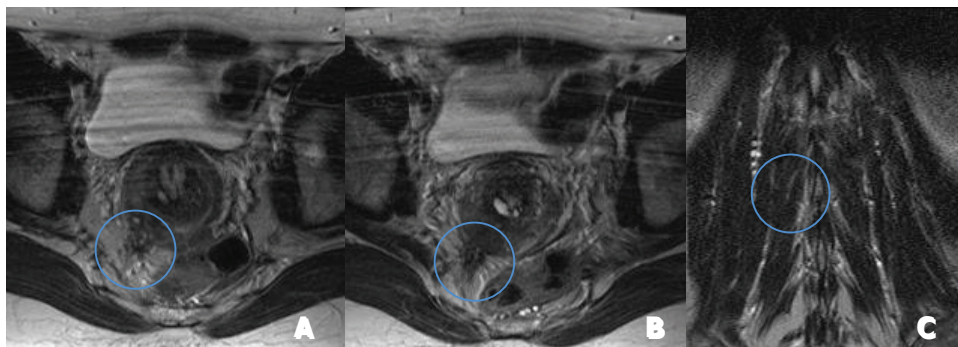


Fig. 6. Axial (A and B) and coronal (C) T2-weighted images showing irregular thickening of the right Utero-Sacral ligaments (blue circles). On the same image there is infiltration of the rectal serosa (blue circle).

Fat-suppressed T1-weighted images sometimes demonstrate hyperintense spots that correlate with hemorrhagic endometrial implants on the ligament (**Fig. 7**).

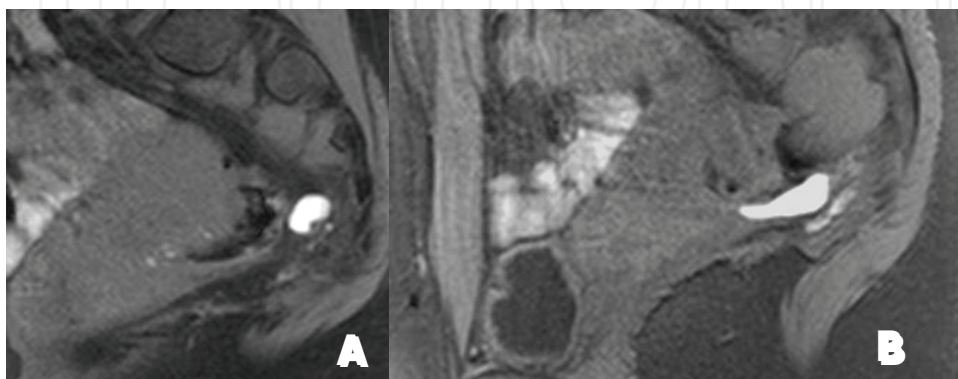


Fig. 7. Fat-suppressed T1-weighted images demonstrate hyperintense spots that correlate with hemorrhagic endometrial implants on the ligament (A, B).

In patients with USLs involvement adhesions could often develop thus, providing posterior displacement of the uterus and ovaries, angulation of bowel loops, elevation of the posterior vaginal fornix, and loculated fluid collections [21]. At MRI, adhesions are detected when low signal intensity is found within the ligaments.

5.5 Endometriosis of the vagina

Endometriosis of the vagina includes lesions infiltrating the anterior rectovaginal pouch, posterior vaginal fornix and retroperitoneal area between the anterior rectovaginal pouch and posterior vaginal fornix.

Patients typically refer dyspareunia.

MRI represents the ideal complement to physical examination and TVUS in order to predict lesion extension upward and posteriorly. Sometimes, the use of a water enema is used to predict the extension of the lesion toward the rectum.

In patients with vaginal endometriosis axial and sagittal T2-weighted Turbo Spin Echo images usually show hypointense nodules. Anterior attraction of the rectum toward the torus uteri and asymmetric thickening of the rectal wall are associated to rectal wall infiltration. Determining the depth of infiltration of the rectal wall allows the gynaecologist to discuss the surgical approach (nodulectomy vs bowel resection) with the colorectal surgeon. The use of the endorectal coil optimizes the finding of MRI [22].

T1-weighted images with fat suppression could demonstrate T1 isointensity of the nodule and some small hyperintense foci, suspected for micro-haemorrhages (Fig. 8 A).

Most patients with vaginal involvement also demonstrate obliteration of the retrouterine excavation (Fig. 8 B, C); in such cases the extension of the pelvic focus may lead to ureteral infiltration and ureterohydronephrosis.

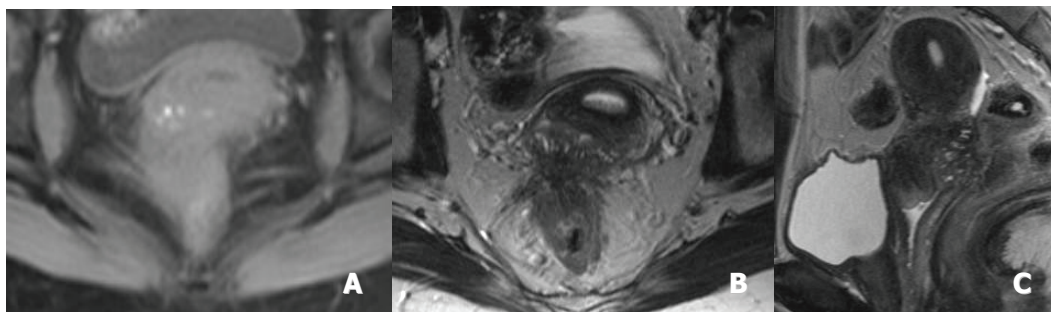


Fig. 8. T1-weighted image with fat suppression demonstrates isointensity of the nodule and some small hyperintense foci, suspected for micro-haemorrhages (A). Axial (B) and sagittal (C) T2-weighted image show obliteration of retrouterine excavation by an hypointense nodule, with anterior attraction of the rectum toward the torus uteri and asymmetric thickening of the rectal wall.

5.6 Endometriosis of the bowel

Rectosigmoid endometriosis represents 70% of cases of intestinal endometriosis.

Clinical symptoms of patients with endometriosis of the recto-sigmoid colon are manifested as crampy pain, flatulence, painful tenesmus, constipation, diarrhoea and bowel obstruction.

Among patients with rectosigmoid endometriosis also dyspareunia is another common symptom. Endometriosis less frequently affects appendix, cecum and distal ileum.

The implants are usually serosal but they can erode through the subserosal layers and cause a fibromuscular hyperplasia of the muscularis propria. Due to the normal appearance of the mucosa in most patients with bowel endometriosis, diagnosis by colonoscopy is often false negative. The appearance of gastrointestinal implants on double-contrast barium enema images is characterized in most cases by a puckering or a crenulated appearance of the affected wall; when the lesion causes a circumferential narrowing of the rectosigmoid colon the differential diagnosis with a primary colon carcinoma is difficult.

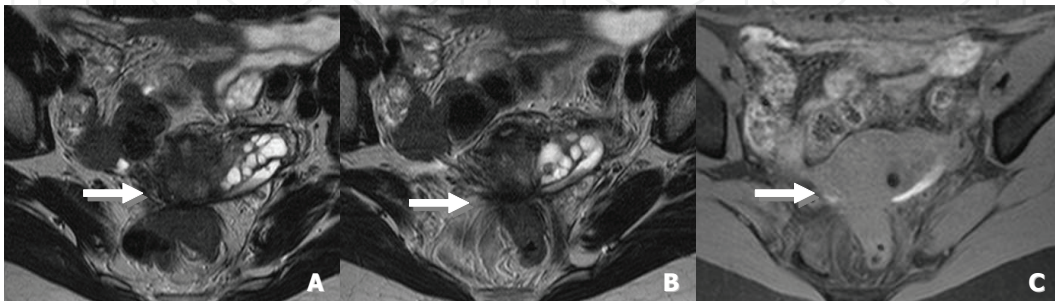


Fig. 9. Diagnostic criteria of bowel invasion at MRI are: colorectal wall thickening with traction of the rectum toward the torus uteri (A, B, C).

At MRI, bowel lesions show a signal intensity similar to fibromuscular tissue (hypointense), with occasional hyperintense foci of T1- and T2- weighted images. An asymmetric thickening of the lower surface of the sigmoid wall or a colorectal wall thickening with attraction of the rectum toward the torus uteri is a common sign (Fig. 9).

According to Roy C *et al* [23], the use of the contrast media helps in reaching the diagnosis of an invasion inside the muscular layer of the intestinal wall. In such cases a thin bright layer on T2-weighted images together with post-contrast enhancement on fat-suppressed T1-weighted images and obliteration of fatty tissue plane between the nodule and the intestinal wall, represents the diagnostic clue of muscular layers involvement. Combined pelvic-phased array and endovaginal coils improve the diagnostic power in the detection of intestinal wall invasion, when compared to phased array alone.

5.7 Malignant transformation

A limited number of endometriosis patients (<5%) will develop ovarian cancer.

Women with endometriosis-associated cancer are typically pre-menopausal, have high incidence of endometrioid and clear cell histologies, and have early stage disease [24].

The association between endometriosis and intra-peritoneal cancer still remains unclear. Probably, women with endometriosis are more susceptible to malignant transformation because of a deficit in their immune system that enables the endometriosis to flourish. Also estrogen may play a role, so endometriosis should be closely monitored in women in the reproductive age [25].

The typical morphologic appearance of an endometriosis-associated carcinoma is that of a unilateral large cystic mass containing hemorrhagic fluid and mural nodules. Signal

intensity is low on T1-weighted images and variable on T2-weighted images. Contrast enhancement of a mural nodule at fat-suppressed T1-weighted sequences is the most important finding for a diagnosis of malignant shift. The “shading” sign within the cystic mass is rarely observed on T2-weighted images because of the dilution of the hemorrhagic fluid caused by tumor secretions. Accordingly, disappearance of the “shading” sign within the mass on T2-weighted images is a diagnostic clue to its malignancy [26].


6. Conclusions

MRI is progressively becoming a widely employed technique in the diagnosis and preoperative staging of endometriosis. It should be performed in selected patients according to the results of TVUS and the severity of symptoms. This imaging method has the advantage to cover the entire pelvis thus, helping the surgeon to achieve a complete resection and prevent post-surgical recurrence.

7. References

- [1] Missmer SA & Cramer DW. The epidemiology of endometriosis. *Obstetrics and Gynecology Clinics of North America* 2003 ; 30 : 1-19
- [2] Olive DL, Schwartz LB. Endometriosis. *N Engl J Med* 1993; 328:1759-1769
- [3] Chapron C, Fauconnier A, Vieira M, Barakat H, Dousset B, Pansini V, Vacher-Lavenu MC, Dubuisson J.B.. Anatomical Distribution of deeply infiltrating endometriosis : surgical implications and proposition for a classification. *Hum Reprod* 2003; 18:157-161.
- [4] Revised American fertility Society classification of endometriosis: 1985. *Fertil Steril* 1985; 43: 351-352.
- [5] Tuttlies F. et al. ENZIAN-Score, eine Klassifikation der tief infiltrierenden Endometriose: *Zentralbl Gynacol* 2005; 127: 275-282.
- [6] Clement PB. Diseases of the peritoneum. In: Kurman RJ, ed. *Blaustein’s pathology of the female genital tract*. 4th ed New York, NY: Springer-Verlag, 1994; 660-680.
- [7] Okaro E, Valentin L. The role of ultrasound in the management of women with acute and chronic pelvic pain. *Best Practice and Research Clinical Obstetrics and Gynaecology* 2004, Vol 18 No 1 1 pp 105-123.
- [8] Mais V, Guerriero S, Ajossa S, Angiolucci M, Paoletti AM, Melis GB. The efficiency of transvaginal ultrasonography in the diagnosis of endometrioma. *Fertil and Steril* 1993, 60:776-780.
- [9] Guerriero S, Mais V, Ajossa S, Paoletti AM, Angiolucci M, Melis GB. Transvaginal ultrasonography combined with CA-125 plasma levels in the diagnosis of endometrioma. *Fertil and Steril* 1996, 65:293-298.
- [10] Bazot M., Malzy P., Cortez A., Roseau G., Amouyal P., Darai E. Accuracy of transvaginale sonography and rectal endoscopic sonography in the diagnosis of deep infiltrating endometriosis. *Ultrasound Obstet Gynecol* 2007; 30:994-1001.
- [11] Chapron C, Vieira M., Chopin N, Balleyguier C, Barakat H, Dumontier I, Roseau G, Fauconnier A, Foulot H, Dousset B. Accuracy of rectal endoscopic ultrasonography and magnetic resonance imaging in the diagnosis of rectal involvement for patients presenting with deeply infiltrating endometriosis. *Ultrasound Obstet Gynecol* 2004; 24:175-179.

- [12] Nishimura K, Togashi K, Itoh K, Fujisawa I, Noma S, Kawamura Y, Nakano Y, Itoh H, Torizuka K, Ozasa H. Endometrial cysts of the ovary: MR imaging. *Radiology*. 1987 Feb;162(2):315-8.
- [13] Siegelman ES, Outwater E, Wang T, Mitchell DG. Solid pelvic masses caused by endometriosis: MR imaging features. *AJR Am J Roentgenol*. 1994 Aug;163(2):357-61.
- [14] Bazot M, Darai E, Hourani R, Thomassin I, Cortez A, Uzan S, Buy JN. Deep pelvic endometriosis: MR imaging for diagnosis and prediction of extension of disease. *Radiology*. 2004 Aug;232(2):379-89
- [15] Onbas O, Kantarci M, Alper F, Kumtepe Y, Durur I, Ingec M, Gursan N, Okur A. Nodular endometriosis: dynamic MR imaging. *Abdominal Imaging* 2007, 32: 451-456.
- [16] Togashi K, Nishimura K, Kimura I et al . Endometrial cysts: diagnosis with MR imaging. *Radiology* 1991. 180: 73-78.
- [17] Fedele L, Piazzola E, Raffaelli R, Bianchi S. Bladder endometriosis: deep infiltrating endometriosis or adenomyosis?. *Fertil and Steril*. 1998; 69: 972-974.
- [18] Halleguier C, Chapron C, Dubuisson J B, Kinkel K, Fauconnier A, Vieira M et al.. Comparison of Magnetic Resonance Imaging and Transvaginal Ultrasonography in diagnosing bladder endometriosis. *The journal of the American Association of Gynecologic Laparoscopy* 2002; 9 (1) 15-23.
- [19] Umek W H, Morgan D M, Ashton-Miller J A, DeLancey J O L. Quantitative analysis of uterosacral ligament origin and insertion points by magnetic resonance imaging. *The American College of Obstetricians and Gynecologists*. 2004; vol 103, no. 3, 447-451.
- [20] Ohba T, Mizutani H, Maeda T, Matsuura K, Okamura H. Evaluation of endometriosis in uterosacral ligaments by transrectal ultrasonography. *Human Reproduction* 1996; vol 11 no.9 2014-17.
- [21] Zawin M, McCarthy S, Scutt L, Comite F. Endometriosis: appearance and detection at MR imaging. *Radiology* 1989; 171:693-696
- [22] Kinkel K, Chapron C, Balleyguier C, Fritel X, Dubuisson JB, Moreau JF. Magnetic resonance imaging characteristics of deep endometriosis. *Hum Reprod*. 1999 Apr;14(4):1080-6.
- [23] Roy C, Balzan C, Thoma V, Sauer B, wattiez A, Leroy J. Efficiency of MR imaging to orientate surgical treatment of posterior deep pelvic endometriosis. *Abdom Imaging* 2008; XX:1-9.
- [24] S. C. Modessitt, G. Tortolero-Luna, J. B. Robinson. D.M. Gerhenson, J.K. Wolf Ovarian and Extraovarian-Associated Cancer *The American College of Obstetricians and Gynecologists* Vol. 100, No. 4, October 2002 788- 794
- [25] Mc Meekin DS, Burger RA, Manetta A, Di Saia P, Barman ML. Endometrioid adenocarcinoma of the ovary and its relationship to endometriosis. *Gynecol Oncol*. 1995; 59:81-86
- [26] M Takeuchi, K Matsuzaki, H. Uehara, H. Nishitani. Malignant transformation of Pelvic Endometriosis: MR Imaging findings and pathologic correlation. *Radiographics* 2006; 26:407-417



Endometriosis - Basic Concepts and Current Research Trends

Edited by Prof. Koel Chaudhury

ISBN 978-953-51-0524-4

Hard cover, 490 pages

Publisher InTech

Published online 09, May, 2012

Published in print edition May, 2012

This book provides an insight into the emerging trends in pathogenesis, diagnosis and management of endometriosis. Key features of the book include overviews of endometriosis; endometrial angiogenesis, stem cells involvement, immunological and hormonal aspects related to the disease pathogenesis; recent research reports on infertility, endometrial receptivity, ovarian cancer and altered gene expression associated with endometriosis; various predictive markers, and imaging modalities including MRI and ultrasound for efficient diagnosis; as well as current non-hormonal and hormonal treatment strategies. This book is expected to be a valuable resource for clinicians, scientists and students who would like to have an improved understanding of endometriosis and also appreciate recent research trends associated with this disease.

How to reference

In order to correctly reference this scholarly work, feel free to copy and paste the following:

Rosario Francesco Grasso, Riccardo Del Vescovo, Roberto Luigi Cazzato and Bruno Beomonte Zobel (2012). Pelvic Endometriosis: A MR Pictorial Review, *Endometriosis - Basic Concepts and Current Research Trends*, Prof. Koel Chaudhury (Ed.), ISBN: 978-953-51-0524-4, InTech, Available from: <http://www.intechopen.com/books/endometriosis-basic-concepts-and-current-research-trends/pelvic-endometriosis-a-mr-pictorial-review>

INTECH
open science | open minds

InTech Europe

University Campus STeP Ri
Slavka Krautzeka 83/A
51000 Rijeka, Croatia
Phone: +385 (51) 770 447
Fax: +385 (51) 686 166
www.intechopen.com

InTech China

Unit 405, Office Block, Hotel Equatorial Shanghai
No.65, Yan An Road (West), Shanghai, 200040, China
中国上海市延安西路65号上海国际贵都大饭店办公楼405单元
Phone: +86-21-62489820
Fax: +86-21-62489821

© 2012 The Author(s). Licensee IntechOpen. This is an open access article distributed under the terms of the [Creative Commons Attribution 3.0 License](#), which permits unrestricted use, distribution, and reproduction in any medium, provided the original work is properly cited.

IntechOpen

IntechOpen