

# We are IntechOpen, the world's leading publisher of Open Access books Built by scientists, for scientists

**4,800**

Open access books available

**122,000**

International authors and editors

**135M**

Downloads

Our authors are among the

**154**

Countries delivered to

**TOP 1%**

most cited scientists

**12.2%**

Contributors from top 500 universities



**WEB OF SCIENCE™**

Selection of our books indexed in the Book Citation Index  
in Web of Science™ Core Collection (BKCI)

Interested in publishing with us?  
Contact [book.department@intechopen.com](mailto:book.department@intechopen.com)

Numbers displayed above are based on latest data collected.

For more information visit [www.intechopen.com](http://www.intechopen.com)



## Posttransplantation Encephalopathies

Daniela Anghel<sup>1,2</sup>, Laura Dumitrescu<sup>3</sup>, Catalina Coclitu<sup>4</sup>,  
Amalia Ene<sup>4</sup>, Ovidiu Bajenaru<sup>1,4</sup> and Radu Tanasescu<sup>1,3</sup>

<sup>1</sup>University of Medicine and Pharmacy "Carol Davila" Bucharest,

<sup>2</sup>Department of Neurology, Fundeni Clinical Institute,

<sup>3</sup>Department of Neurology, Colentina Hospital,

<sup>4</sup>Department of Neurology, University Emergency Hospital,  
Romania

### 1. Introduction

Neurological complications may occur in 30 to 60% of the patients undergoing organ transplantation, especially liver and bone marrow (Padovan et al. 2000). Because of the constantly changing protocols regarding the transplantation procedure and the subsequent immunosuppression required for the prevention of graft rejection and graft versus host disease, the nature of the neurologic complications has changed over time.

Recipients of solid organ or bone marrow cell transplants are at risk of life-threatening neurological complications including encephalopathies, seizures, brain infections and malignancies, stroke, central pontine myelinolysis and neuromuscular disorders. Many of these disorders are linked directly or indirectly to the immunosuppressive therapy. However, they may also result from graft versus host disease, from pretransplantation radiation or chemotherapy, and from injuries induced during surgery and intensive care unit (ICU) stay. In rare cases neuroinfectious pathogens may be transmitted with the transplanted tissue. Though most of the neurological complications occur disrespectful of the transplanted organ, transplant-specific complications also exist. Heart and pulmonary transplants are frequently associated to cerebral hypoxia, ischemia and bleeding. Bone marrow transplant is commonly associated with prolonged thrombocytopenia that may lead to catastrophic cerebral haemorrhage (Bashir 2001).

In spite of the advances that have been made in the management of transplanted patients, the so-called posttransplantation encephalopathy (PTE), a complex syndrome with various etiologies characterized especially by disturbance of consciousness, is still frequently observed. The spectrum of PTE is vast and changes along in relationship with the time that has passed since transplantation (see Table 1). Metabolic disturbances (secondary to the underlying or associated systemic disease or iatrogenic), drug neurotoxicity (caused by immunosuppressant, but also by antibiotics or other drugs), disimmunity and opportunistic central nervous system infections are frequent PTE etiologies. Though commonly the encephalopathies with these etiologies are well circumscribed clinical entities, highlighting the diagnostic and therapeutic particularities arising from their occurrence in the posttransplantation setting is of great utility for the current clinical practice. Moreover,

encephalopathies of different etiologies may overlap in the same transplanted patient (Mathew and Rosenfeld 2007).

The etiological diagnosis of PTE is challenging because the clinical presentation and the neuroimaging findings lack specificity and the unique circumstances related to the underlying disease, the transplant procedure and the subsequent management may give rise to less typical presentations. Most clinical signs of PTE are nonspecific and do not reliably identify a particular etiology. Humoral or tissue samples are often required for definite diagnosis.

The major clinical feature is impaired attention, but the clinical findings can range from subtle cognitive difficulties to delirium or coma. A characteristic abnormality is marked fluctuation in the level of consciousness. The motor signs are variable and include tremor, asterix and multifocal myoclonus, the latter particularly involving the face and the proximal muscles. In the severely affected subjects decorticate and decerebrate posturing may occur. Computed tomography (CT) or magnetic resonance imaging (MRI) of the brain is mandatory when signs suggestive for diffuse or focal brain injury are present. If clinical examination shows no focal signs and brain MRI is normal, the most probable causes of the encephalopathy are systemic metabolic abnormalities or drug toxicity (commonly related to cyclosporine, tacrolimus or amphotericin-B). In posttransplantation encephalopathic patients with normal MRI cytomegalovirus (CMV) infection should also be considered. In the setting of CNS signs and symptoms the electroencephalogram (EEG) is a useful investigation since it can identify diffuse non-specific slowing of the normal activity translating diffuse brain injury, and it can confirm the presence of non-convulsive seizures which may be difficult to differentiate from confusion or other mental status changes on clinical grounds only. The required laboratory investigations include complete blood count, coagulation studies, electrolyte panel, glucose, renal and liver function parameters and arterial blood gases. Assessment of the blood immunosuppressive drug levels should be performed when overdose may have occurred and blood and CSF cultures should be obtained when infection is suspected.

Early posttransplantation period (first 30 days)	Subacute posttransplantation period (1-6 months)	Chronic posttransplantation period (>6 months)
METABOLIC DISTURBANCES	OPPORTUNISTIC INFECTION (SOLID ORGAN ALLOGRAFTS)	OPPORTUNISTIC INFECTION (SOLID ORGAN ALLOGRAFTS)
HYPOXIC-ISCHEMIC ENCEPHALOPATHY	METABOLIC DISTURBANCES	METABOLIC DISTURBANCES
IMMUNOSUPPRESSIVE DRUG TOXICITY	IMMUNOSUPPRESSIVE DRUG TOXICITY	IMMUNOSUPPRESSIVE DRUG TOXICITY
OPPORTUNISTIC INFECTION (BONE MARROW TRANSPLANTATION)		

Table 1. The time relationship with the transplant procedure of the common causes of PTE

The patient's management should be centered on preventing further neurological injury, administering etiology-targeted therapy, and balancing the benefits and toxicities of the specific immunosuppressive agents used. Knowledge regarding the etiologies of PTE and their incidence in relationship with the posttransplantation period in which they occur is essential for the adequate medical approach (Mathew and Rosenfeld 2007). Without the objective of being exhaustive, the present chapter offers an updated overview on the subject.

## 2. Encephalopathy related to the underlying disease

In a significant number of cases the disease that imposed transplantation also predisposes to brain injury, some patients having a certain degree of encephalopathy when the transplant procedure takes place. Moreover, hyperacute, acute or chronic graft rejection may also lead to encephalopathy secondary to organ failure (but also, see 'Rejection Encephalopathy' below).

Patients with end-stage cardiomyopathy may develop encephalopathy secondary to global cerebral hypoperfusion.

Patients with chronic renal failure may develop pretransplant uremic encephalopathy and acute renal rejection encephalopathy (Brouns et De Deyn 2004).

The patients undergoing liver transplant may continue to experience hepatic encephalopathy if the graft fails acutely and/or may suffer hypoxic ischemic brain injury. In the majority of cases the clinical picture is the expression of the intracranial hypertension caused by brain edema, i.e. the net increase in brain water that may occur in the cellular (cytotoxic edema) or interstitial (vasogenic edema) compartments of the brain. Toxic, metabolic, inflammatory and infectious humoral factors may play a pathogenic role in the development of brain edema. Therefore, measurement of arterial ammonia levels is important for estimating the risk for the development of intracranial hypertension. It has been reported that worsening of hepatic encephalopathy may precede the detection of bacterial infection by an average of 24 hours, so, is recommended that patients experiencing worsening of hepatic encephalopathy should be treated with empiric wide-spectrum antibiotics. In those with hepatic insufficiency the translocation of bacteria from the intestine to regional lymph nodes may be an important pathogenic pathway, but endovenous catheters are also important routes of infection. Acute hyponatremia can induce brain edema by itself, therefore electrolytes levels should be routinely checked (Londono et al. 2006).

Brain edema leads to impaired consciousness ranging from sleepiness to stupor and coma and correlates with severe encephalopathy. The presence of long tract signs, decerebrate posturing, alterations in pupillary reactivity, or abnormalities in oculovestibular reflexes are specific though not sensitive indicators of the presence of an increased intracranial pressure. Radiological detection of brain edema can provide useful information, but the sensitivity is low. For identifying the presence of intracranial hypertension, intracranial pressure monitoring is the most accurate tool.

The therapeutic measures include treatment of the underlying disease and correction of the metabolic disturbances. Ammonia can be removed by dialytic methods. N-acetylcysteine administered over 3-days infusion may lead to a significant improvement in the survival of those with mild hepatic encephalopathy. The management of elevated intracranial pressure

includes correcting the patient's position, temperature, ventilation and hemodynamics and when present removal of the excessive fluid. Osmotic therapy (e.g. mannitol 0.25 to 2 g/kg as 20% solution IV over at least 30 minutes, administered not more frequently than every 6 to 8 hours) is commonly administered. In selected cases forced hyperventilation (aiming a  $\text{paCO}_2$  lower than 25 mmHg), barbiturate coma, high dose indomethacin administration and bilateral decompressive craniectomy should be taken into consideration (Jantzen 2007).

### **3. Cranial irradiation encephalopathy**

Cranial irradiation is commonly used before bone marrow transplantation. Encephalopathy related to cranial irradiation has been reported. The clinical picture is that of an acute encephalopathy characterized by fever, headache, nausea, somnolence and seizures. The cause is diffuse cerebral edema. The treatment comprises of corticosteroids administration. In those with hematologic malignancies, pretransplant cranial irradiation and intrathecal chemotherapy may also cause a delayed leukoencephalopathy, which may occur even several years after these procedures.

### **4. PTE due to transplantation procedures**

Hypoxic-ischemic encephalopathy is a potential posttransplantation complication common to most of the transplant procedures.

Hypoxia describes a reduction in oxygen supply or tissue utilisation, which leads to an increase in cerebral blood flow that aims at providing glucose to the brain and clearing toxic metabolites.

Ischemia refers to a reduction in blood supply, which leads to decreased oxygen delivery, impaired clearance of the accumulating toxic cellular metabolites (lactate,  $\text{H}^+$ , glutamate) and subsequent exacerbation of the pre-existent brain injury. Global cerebral ischemia is usually due to: cardiac arrest, profound hypotension associated with surgery, shock, sepsis, metabolic encephalopathy, prolonged hypoxia or hypoglycemia and severe anemia (Liang 2000). Precaution should be taken to avoid the occurrence of these precipitating factors. Elevated cerebral metabolic rate may also play a role in the etiology of hypoxic-ischemic encephalopathy. Global cerebral ischemia quickly leads to impaired synaptic transmission and axonal conduction. The degree of neuronal susceptibility to the hypoxic/ischemic injury is not uniform within the brain, particularly vulnerable regions being the hippocampus, the neocortex, the reticular nucleus of the thalamus, the amygdala, the cerebellar vermis and some neurons in the caudate nucleus and pars reticulata of the substantia nigra. This different topographic susceptibility to ischemic injury seems to be caused by the specific properties of the neurons in those brain regions, and not by uneven circulation. An impaired cerebral oxygen supply may lead to transient or irreversible neurologic changes, depending on the severity of the initial insult and on the post-resuscitation management.

The clinical picture of hypoxic ischemic encephalopathy consists of impaired consciousness ranging from coma to vegetative state or minimally conscious state and epileptic seizures. Generalised tonic-clonic seizures may be masked in the first days, due to sedation. Focal seizures may be restricted to blinking, eye deviations or small repetitive facial or limb movements, which can be easily overlooked. Multifocal generalised myoclonus (posthypoxic myoclonic status) may start immediately after injury, responds unsatisfactory

to medication and translates a poor prognosis. Focal myoclonus, action or startle sensitive (Lance-Adams syndrome), may appear in the first 24-48 hours after the injury, responds well to antiepileptic drugs (valproate, levetiracetam, clonazepam) and carries a favourable prognosis (Chabolla et al. 2003).

The investigations required when facing hypoxic-ischemic encephalopathy include:

Neurophysiological tests (EEG, somatosensory evoked potentials), which are valuable in assessing the diagnosis and prognosis.

Imaging studies, which in the first days commonly show brain edema (hypodensity on CT or hyperintensity on MRI - DWI, FLAIR- localised in the cortical grey matter, basal ganglia and subcortical white matter). In the subacute phase there is progressive resolution of brain edema, normalisation of DWI, but persistence of cortical, basal ganglia and white matter hyperintensity on T2 and FLAIR images. Cortical laminar necrosis and boundary zone infarctions may also appear.

The treatment should be adapted for each particular situation, but several approaches are commonly required. As mentioned above, if raised intracranial pressure is clinically suspected, several measures should be taken: adequate positioning of the head, osmotherapy (mannitol, hypertonic saline), controlled hyperventilation and metabolic control (fever, seizures, hypoglycaemia, hypokalemia). Systemic coagulopathy can occur, due to an increase in cytokines, so antithrombotic therapy should be given. For the patients in coma, hypothermia should be tried, as it increases the chances for a good outcome, if the possible complications are avoided (i.e. cardiac arrhythmias, sepsis, hypotension during rewarming, renal failure, hypokalemia).

The outcomes of hypoxic-ischemic brain injury include death, coma, vegetative state (VS), minimally conscious state (MCS), severe neurological or cognitive deficits, with chronic dependence on nursing care or, in some cases, recovery. The factors that correlate with worse prognosis are: duration of coma over 6 hours, absence of spontaneous limb movements or localisation to painful stimuli in the first hours, prolonged loss of pupillary responses, ocular abnormalities (e.g. sustained conjugate eye deviation, up- or downbeat nystagmus, ping-pong gaze, periodic alternating nystagmus), myoclonic seizures, absent reflexes of lower cranial nerves (cough and gag reflexes). Biomarkers that may predict outcome have been searched. So far, the only one that appears to be related to a poor prognosis seems to be neuron specific enolase (NSE), if it rises over 80ng/ml in the first days.

Among the types of transplant, lung transplantation is associated with increased risk of hypoxic-ischemic encephalopathy. A particular situation is that of heart transplantation which has similar neurological complications as other open-heart procedures, including encephalopathy. The manifestations of the perioperative cerebral injury include ischemic (or, less commonly, hemorrhagic) stroke, encephalopathy and neurocognitive dysfunction occurring in the first month after surgery. Brain injury secondary to cardiac surgery is primarily ischemic. The etiology of ischemic brain injury secondary to cardiac transplant includes:

1. Cerebral embolism: cerebral macroembolism arising from the ascending aorta causes stroke, while cerebral microembolism causes encephalopathy and neurocognitive dysfunction; microemboli are either gaseous or particulate.

2. Cerebral hypoperfusion: induces injury caused by the combination of systemic hypotension and cerebral venous hypertension (traction on the superior vena cava), occurring during off-pump surgery.
3. Atherosclerosis of the aorta: atherosclerotic lesions injury during surgery can result in emboli and may expose lipidic prothrombotic material, which promotes thrombus formation postoperatively. On the other hand, atherosclerosis of the ascending aorta is a marker for severe atherosclerosis of the cerebral arteries, which prones to cerebral injury during hypoperfusion.
4. Perioperative anemia reduces cerebral oxygen delivery and/or causes increased cerebral blood flow, increasing the number of potential emboli.

### **5. PTE related to the immunosuppressive medication**

Immunosuppressive therapy is required in all transplanted patients for the prevention of graft rejection and graft versus host disease. Commonly used drugs include calcineurin inhibitors, corticosteroids and biological agents. It is widely recognized that the immunosuppressive therapy is associated with an increased incidence of sepsis (and thus of sepsis encephalopathy) and of central nervous system opportunistic infections, both of which are briefly discussed in separate sub-chapters. The literature is abundant in case reports of encephalopathy occurring in the absence of sepsis or neuroinfections. As detailed further on, these encephalopathies appear to be specifically related to several drugs. Their evolution is typically favourable, providing the offending drug is stopped. It is important to note that even if metabolic disturbances or other causes that may explain the encephalopathy are identified, the blood levels of the potential neurotoxic drugs that the patient is receiving should be assessed.

Certain particularities in respect with the organ being transplanted have been reported.

The patients undergoing liver transplantation commonly have an advanced stage of the disease resulting in immunodepression and coagulopathy (Watt et al. 2010). Disrespectful of the technique used, the surgical procedure required by liver transplantation is very complex and has high risk of blood loss or massive fluid shifts. In the days following the transplant, the engrafted liver releases immunologically active cells (T-cells, macrophages, stem cells), which can react with the host immune system, already affected by the preexistent liver failure and by the immunosuppressive medication. Liver transplanted patients commonly develop PRES related to calcineurin inhibitors administration early after transplantation and usually have associated favouring factors such as serious bacterial infection, organ rejection or CMV infection (reactivation or new infection). The arterial blood pressure is normal in most cases.

Because the possibility of adequately substituting the impaired renal function via periodic dialysis, the patients requiring kidney transplantation are usually "healthier" than those with liver failure. At the same time, the transplant procedure is less laborious than in the case of liver transplantation. These patients may develop late PRES related to calcineurin inhibitors administration and usually have high blood pressure, episodes of severe systemic infection or rejection. Probably the chronic exposure to the graft endothelium promotes a minimal inflammatory response (increased leukocyte trafficking and activation of endothelial adhesion molecules). These changes can receive a boost when the immune system is stimulated by an infection or an episode of rejection.

Patients with allogenic bone marrow transplantation have the highest risk for infection and neurotoxicity, because of the aggressive chemotherapy and total body irradiation (both can cause endothelial injury) and because of the potential development of graft versus host disease, requiring high doses of neurotoxic immunosuppressants.

### 5.1 Calcineurin inhibitors

Calcineurin inhibitors (i.e. cyclosporine and tacrolimus) are drugs with immunosuppressive effects, frequently administered in transplant receivers. They act as blockers of calcineurin, which is a T lymphocyte calmodulin-dependent protein. The principal role of calcineurin consists of increasing the quantity of interleukin 2 (IL-2) released by the activated T lymphocyte. The blockage of this signal stops the clonal expansion of the T lymphocytes, thus decreasing the amplitude of the immune response (Gerald 2001). Cyclosporine and tacrolimus are frequently administered in transplant recipients, especially in those with allogeneic hematopoietic stem cell transplant for the prophylaxis of graft versus host disease. Cyclosporine and tacrolimus are absorbed in jejunum, metabolised by P450 cytochrome and excreted mostly through bile. Their plasma levels are increased by certain drugs which are metabolised by the same pathways (e.g. calcium channel blockers, macrolides, conasoles, amiodarone, metoclopramide, colchicine, allopurinolum). The drugs that are enzyme inducers (e.g. phenytoin, phenobarbital, rifampicin, carbamazepine, sulfonyleureas) lower the plasma level of cyclosporine and tacrolimus. The optimum blood level of cyclosporine is between 250-350 ng/ml in the first 3 months after transplantation, with progressive reduction to 100-150 ng/ml after one year, required for minimizing the adverse effects. Its potential adverse effects include arterial hypertension, nephrotoxicity and neurotoxicity. For tacrolimus, the optimum blood level is 10ng/ml in the first 3 months after transplantation, with progressive reduction to 5ng/ml at one year for the same rationale as above. Its potential adverse effects are arterial hypertension, nephrotoxicity, neurotoxicity and diabetes mellitus. Both drugs cause similar neurotoxicity, which particularly occurs in the first months after transplant when the administered doses are higher.

Cyclosporine and tacrolimus are lipophilic molecules which pass the blood-brain barrier, sometimes reaching higher concentrations in the corticospinal fluid (CSF) than those present in the blood. That is why neurotoxicity can appear early and may not correlate with the presence of high blood concentrations. It is commonly accepted that early calcineurin inhibitor-induced neurotoxicity occurs within the first 4 weeks since treatment initiation (and since transplantation). Their neurotoxicity occurs through various mechanisms, one of which is the release of endothelin, which causes intense cerebral vasospasm, sympathetic activation and local coagulation disturbances, finally determining vasogenic edema affecting predominantly (but not exclusively) the subcortical white matter of the posterior regions of the brain. Both cyclosporine and tacrolimus decrease endothelial cell viability (Illsinger et al. 2010) and increase endothelial permeability (i.e. endotheliotoxic dysfunction), with secondary failure of the cerebral vascular autoregulation and impaired function of the blood-brain barrier. Both drugs inhibit P-glycoprotein, which could result in the enhancement of the brain distribution of these drugs and thus increased neurotoxicity. Factors favouring these alterations induced by cyclosporine and tacrolimus include arterial hypertension, concomitant treatment with corticosteroids, hypocholesterolemia, hypomagnesemia, concomitant graft versus host disease (as it needs high doses of



immunosuppressant therapy) and high aluminium blood levels- occurring especially in the patients from developing countries where contaminated dialysis water is still used or in those taking over-the-counter aluminium-containing phosphate binders(Bechstein 2000).

The neurotoxicity induced by calcineurin inhibitors occurs more frequently in liver transplanted patients. The neurotoxic effects of cyclosporine and tacrolimus may be divided in minor symptoms (mild postural and action tremor of the extremities, distal burning paresthesia, somnolence or insomnia, headache, dysarthria, agitation, depression) and major symptoms (auditive or visual hallucinations, cortical blindness, akinetic mutism, speech apraxia, psychosis, seizures, coma, polyneuropathy, myopathy). The exclusion of other potential causes (stroke, central nervous system infection, central pontine myelinolysis) is mandatory. Following dose modification or switching to another calcineurin inhibitor there is an obvious clinical improvement. Tremor and paresthesias are the most common side effects of calcineurin inhibitors, occurring in up to 30% and respectively 11% of the patients. These commonly subside when the dose is decreased. Isolated seizures are reported in up to 5% of patients and may sometimes be associated with hypomagnesemia (nota bene: imipenem, cefepime and levofloxacin administration is also associated with seizures). Although more severe neurological complications are rare, two CNS syndromes have been reported: posterior reversible encephalopathy syndrome (PRES) and a syndrome predominantly characterized by motor features of parkinsonism or ataxia. A similar syndrome consisting of confusion, tremor and parkinsonism may be caused by amphotericin-B.

PRES is caused by potentially reversible, predominantly vasogenic edema of the white matter, with a predilection to the brain regions supplied by the posterior arteries(Wijdicks 2001).

PRES can manifest with seizures, disturbed vision, headache and altered mental status. Severe hypertension is sometimes present, but usually the mean arterial pressure is normal. Because acutely raised blood pressure is found in many PRES patients, it is sometimes considered to be an important causal factor. On the other hand, patients with normal blood pressure may also develop PRES. Perhaps, therefore, the raised blood pressure is required to sustain cerebral blood flow and is reactive rather than a cause. The symptoms usually develop quite quickly over a few hours, reaching their worst in 12 to 48 hours since onset. Confusion and altered mental status are very frequent findings and may hide other symptoms such as disturbed vision and nausea. Patients can be confused, lethargic with slowed motor responses or deeply stuporous. As mentioned, seizures, including non-convulsive status epilepticus, may occur in those with PRES. Differentiating altered mental status from non-convulsive status epilepticus on clinical grounds only may be difficult. Using EEG monitoring in all patients with altered mental status can help detecting non-convulsive electroencephalographic seizures. PRES patients with status epilepticus show rhythmic delta and sharp waves, mostly in the parieto-occipital and temporal regions. The EEG abnormalities resolve along with clinical improvement(Cruz-Martinez et Gilmore 2002). Visual disturbances occur frequently due to the involvement of the occipital lobe. PRES patients may experience not only cortical blindness or homonymous hemianopsia, but also blurred vision, visual neglect and visual hallucinations. Headache, usually bilateral and dull in nature, commonly occurs in PRES. Tremor of the extremities is a minor but very important sign, because most of the patients with altered consciousness due to calcineurin

inhibitor neurotoxicity have this sign, which is not so often present when other causes are involved. Other clinical features of PRES include nausea and vomiting. These occur less frequently. The tendon reflexes are often brisk but symmetrical. Hemiparesis, Babinski's sign and brainstem features may occur occasionally.

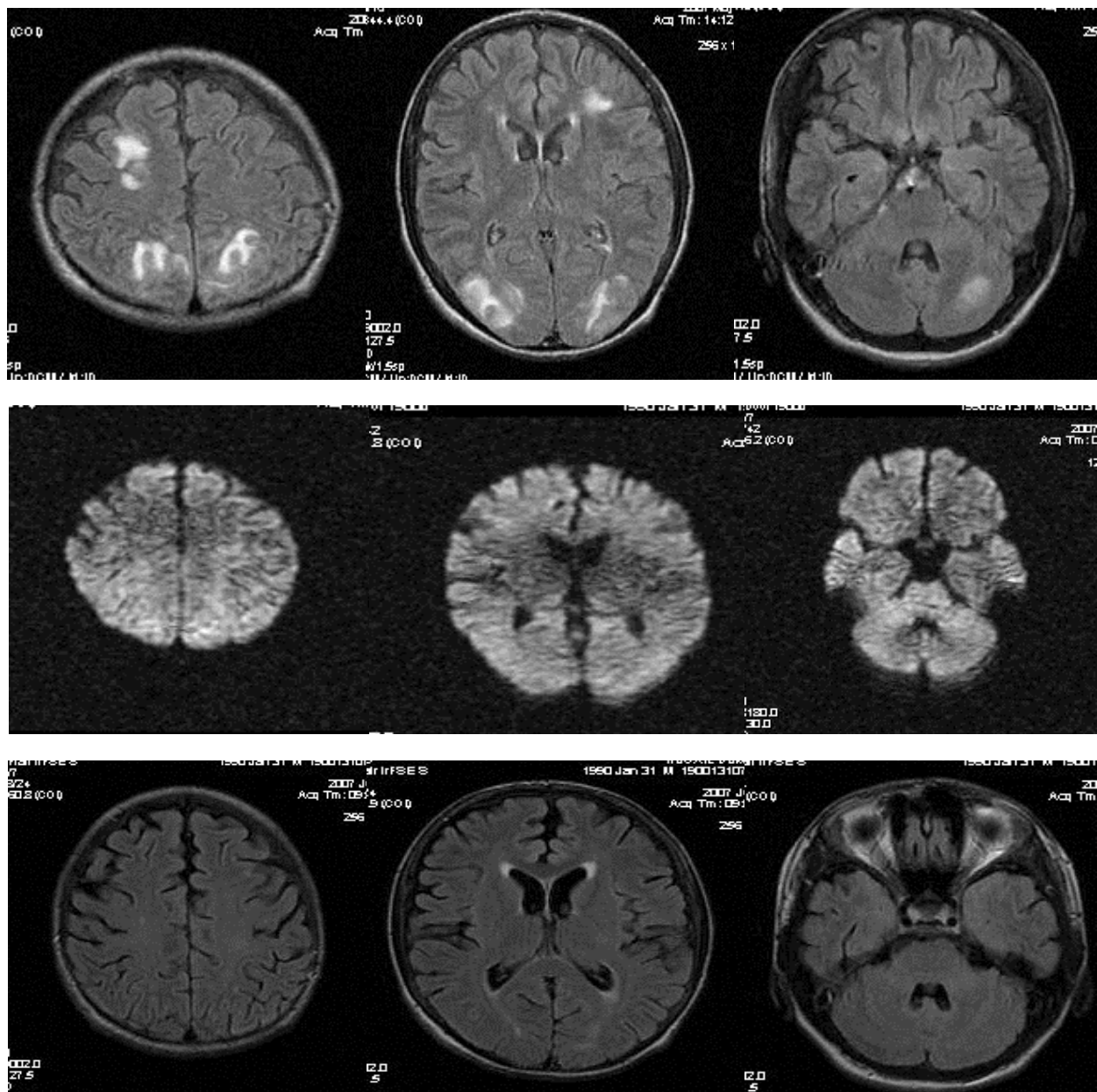


Fig. 1. PRES in a 17-year-old male who developed headache, seizures, visual disturbances and altered mental status 14 days after cadaveric renal transplant for glomerulonephritis-related chronic renal failure. He was treated for pneumonia just before toxicity occurred. The MR imaging was obtained 4 days after the onset of PRES. (A) FLAIR sequences showing bilateral frontal and occipital hyperintensity, translating vasogenic edema. (B) Diffusion weighted imaging showing isointensity of the affected areas (i.e. no cytotoxic edema). (C) Follow-up FLAIR sequences obtained one month later show resolution of the vasogenic edema.

The CSF may be normal or show slightly raised protein level.

Brain imagistic studies (CT or preferably MRI) are required. The common neuroradiological abnormalities comprise of the subcortical white matter hyperintensities typically bilaterally, nonenhanced and involving mainly the posterior lobes-parietal and/or occipital (Bartynsky et al. 2008). Involvement of the anterior brain (frontal lobes, along the superior frontal sulcus), cerebellum, and brain stem may also be observed. A typical PRES pattern mostly spares the paramedian occipital structures below the sulcus calcarinus. Although PRES is often thought to be a leukoencephalopathy, the cortex and deep gray mater can often be involved.

SYNDROME	PARTICULAR CHARACTERISTICS
Posterior circulation stroke - "top of the basilar syndrome"	MRI: hyperintensity on DWI images and low signal on ADC map; involvement of calcarine and paramedian areas
Primary CNS vasculitis	Insidious onset Abnormal CSF, with inflammatory changes MRI: multiple infarcts, of different ages
Reversible cerebral vasoconstriction syndrome	Severe headache (thunderclap headache) Progression of symptoms in days, not hours Angiography: multiple segmental stenoses, reversible after few weeks
Viral Encephalitis- (herpetic)	Systemic inflammation signs: fever, blood tests, inflammatory CSF changes

Table 2. The differential diagnosis of PRES

Although the blood levels of cyclosporine and tacrolimus tend not to correlate with PRES and normal serum levels do not rule out drug-related neurotoxicity, both clinical and radiologic findings can resolve as the blood levels of the offending drug are reduced (Singh et al. 2000). Therefore the specific therapeutic approach comprises of lowering of the dose or discontinuation of the offending drug, which interestingly can be switched with the other calcineurin inhibitor without PRES reoccurring. The encephalopathy is almost always reversible but it may not resolve until several weeks after the drug has been stopped. There are reports of a potential protective effect of soya bean oil administration (Kentaro et al. 2007). The lipids contained by this oil may impair the passage of the calcineurin inhibitors through the blood-brain barrier, and therefore diminish their accumulation in the central nervous system. Symptomatic treatment is also required and should be adapted to each case. The minor symptoms related to calcineurin inhibitors neurotoxicity are usually self-limited and responsive to symptomatic drugs. However, refractory headache leading to change of the immunosuppressive drug has been reported. When facing major symptoms the usual therapeutic approach is changing the immunosuppressive treatment: either substituting calcineurin inhibitor with a non-calcineurin inhibitor (e.g. sirolimus, mycophenolate mofetil) or changing the calcineurin inhibitors between each other - cyclosporine with tacrolimus or tacrolimus with cyclosporine (Guarino et al. 2006). Syndrome-specific treatments are mandatory. These include administration of cerebral depletive drugs and administration of antiepileptic drugs adapted to the type of seizures according to the local guidelines but also adapted to the patient (i.e. lacking either

hepatotoxicity or nephrotoxicity and not interfering with the patient's immunosuppressant drugs). Since it does not induce hepatic metabolism of cyclosporine or tacrolimus and can be given either orally or intravenously in the absence of liver dysfunction valproic acid may be optimal for treatment of seizures. The antiepileptic treatment may be stopped after about 6 months, unless the seizures reappear. Administration of anxiolytics (for agitation) or neuroleptics (for psychotic episodes) may sometimes be required.

## 5.2 Corticosteroids

Corticosteroids prevent interleukin IL-1 and IL-6 production by macrophages and inhibit all stages of T-cell activation. In transplanted patients, they are commonly used for the induction and maintenance of immunosuppression and for the treatment of acute rejection. Corticosteroid administration may cause insomnia, irritability, impaired concentration, and mood changes, and sometimes they may even cause psychotic episodes. The treatment of corticosteroid-related neurological side effects consists of lowering the dose and administering antipsychotic agents.

## 5.3 Biologic agents

The biologic agents include polyclonal and monoclonal antibodies with immunomodulatory/immunosuppressive effects. They are used for the induction of immunosuppression and for the treatment of graft rejection.

The polyclonal antibodies (e.g. antithymocyte globulins) are produced by injecting animals with human lymphoid cells, then harvesting and purifying the resultant antibody. Polyclonal antibodies induce lysis of lymphocytes and mask the lymphoid cell-surface receptors. The available pharmaceutical preparations include horse antithymocyte globulin (ATGAM) and rabbit antithymocyte globulin (Thymoglobulin). These agents are used for immunosuppression induction and treatment of acute graft rejection. Adverse effects include fever, chills, thrombocytopenia, leukopenia, hemolysis, respiratory distress, serum sickness, and anaphylaxis. Some adverse effects are ameliorated with steroids, acetaminophen, and diphenhydramine.

The monoclonal antibodies used in transplanted patients include monoclonal anti-CD3 antibody (i.e. muromonab-CD3), monoclonal anti-CD25 antibody (i.e. basiliximab and daclizumab), monoclonal anti-CD20 antibody (i.e. rituximab). Except for muromonab their administration in transplanted patients is associated with a very low prevalence of neurologic adverse effects.

Muromonab-CD3 (Orthoklone OKT3) is a murine monoclonal antibody directed to the CD3 portion of the T-cell receptor. It blocks T-cell function and has limited reactions with other tissues or cells. This agent is used for induction and acute rejection (primary treatment or steroid-resistant). Its adverse effects include cytokine release syndrome (fever, dyspnea, wheezing, headache, hypotension, diarrhea, vomiting, nausea, tremor, generalized weakness) and pulmonary edema, usually following the first few doses. Sometimes patients experience "shock-like" reactions, which may include cardiovascular and central nervous system manifestations. All patients must be carefully evaluated for excessive fluid retention and hypertension before the initiation of Muromonab therapy. Close monitoring for neuro-psychiatric symptoms must be observed during the first 24 hours following the first

injection. Patients who may be at greater risk for CNS adverse events include those with history of seizures, with cerebrovascular disease, head trauma, uraemia, or who are receiving a medication concomitantly that may affect the central nervous system. Premedication with steroids (first 2 doses only), acetaminophen, and diphenhydramine avoids cytokine release syndrome. The possible neuro-psychiatric events include headache, seizures, aseptic meningitis, encephalopathy and cerebral edema/herniation. Seizures, which have been occasionally accompanied by cardiorespiratory arrest, have occurred independently or in conjunction with any of the neurologic syndromes described below. Patients predisposed to seizures are those with the following conditions: uraemia, fever, infection, fluid overload, hypertension, hypoglycaemia, history of seizures, and electrolyte imbalances. Symptoms of aseptic meningitis include fever, headache, stiff neck and photophobia. The cerebrospinal fluid shows leucocytosis, elevated protein and normal or decreased glucose, with negative viral, bacterial and fungal cultures. Most patients with aseptic meningitis have a benign course, but infectious meningitis must be taken into account in the differential diagnosis of an immunosuppressed transplant patient with any signs or symptoms of meningitis. Manifestations of encephalopathy may include impaired cognition, confusion, altered mental status, auditory/visual hallucinations, psychosis (delirium, paranoia), mood changes (mania, agitation), hyperreflexia, myoclonus, tremor, asterixis, involuntary movements, major motor seizures, lethargy/stupor/coma and diffuse weakness. All these side effects are usually reversible.

## 6. Rejection encephalopathy

Rejection Encephalopathy is a pathogenic entity seen in patients with systemic features of acute graft rejection. Commonly the symptoms appear in the first 3 months post transplantation. The presumed pathology is cytokine production secondary to the rejection process. The clinical picture includes headache, confusion, seizures, and papilledema. The lumbar puncture reveals increased CSF opening pressure and the cerebral CT/MRI reveals diffuse cerebral edema. The EEG shows diffuse or focal rhythm slowing. The overall prognosis is good, with rapid and complete recovery after the immunosuppressive treatment of the rejection episode.

## 7. Graft versus host disease

Graft versus host disease is a complex complication of allogenic hematopoietic stem cell transplantation. It occurs in 40 to 75% of the patients undergoing this procedure. The underlying mechanism comprises of donor T cells reaction against host antigens. Neurological complications associated with graft versus host disease occur several months after the transplantation, in chronic phase of the disease, and typically involve the peripheral nervous system, causing polymyositis, myasthenia gravis and peripheral neuropathies compatible with acute Guillain-Barre syndrome or chronic idiopathic demyelinating polyneuropathy (Echaniz-Laguna et al. 2004). Brain MRI abnormalities comprising mainly of atrophy and white matter lesions are not uncommon in patients with chronic graft versus host disease, but their etiopathogeny is difficult to establish since these patients associate several factors that may result in brain injury. According to the current knowledge, the brain does not express major histocompatibility complex antigens, and therefore is expected to be protected from the potential damage induced by autoreactive T

cells. However, a few cases of possible central nervous system involvement related to graft versus host disease have been reported. These patients presented with subacute encephalopathy developing in the setting of systemic involvement. The neuropathological examination revealed widespread T-cell infiltrates in the absence of conclusive evidence for viral infection. Imagistic features compatible with CNS vasculitis (one case with pathological confirmation) were reported to occur in several patients with chronic graft versus host disease. The authors that reported the latter series of cases proposed that an angitis-like syndrome involving the CNS may occur as a complication of chronic graft versus host disease and may be responsible for the clinical and brain MRI findings encountered in some of these patients (Padovan et al. 1999).

## 8. Septic encephalopathy

Sepsis is defined as a known or suspected infection leading to the systemic inflammatory response syndrome. Due to the associated immunodepression sepsis has higher incidence in transplanted patients. It frequently presents with delirium and represents perhaps the most common causal factor for intensive care unit delirium. Encephalopathy occurring in the setting of sepsis may have several causes, being either a direct consequence of sepsis, or secondary to various of its associated complications, such as liver or renal failure (resulting in metabolic disturbances), or induced by the pharmacologic agents required for its treatment. The evolution is usually acute. Though commonly diffuse brain involvement is observed, focal brain lesions may also occur.

The physiopathology of sepsis-associated encephalopathy is complex and involves inflammatory and non-inflammatory processes that affect endothelial cells, glial cells and neurons and that induce blood-brain barrier breakdown, dysfunction of intracellular metabolism, and cell death. The ongoing inflammatory cascade may impair capillary blood flow and therefore decrease the brain's supply of oxygen and essential nutrients and the clearance of toxic by-products. Elevated levels of tumour necrosis factor- $\alpha$ , interleukin-1, and other cytokines and chemokines that are released in response to the presence of bacterial lipopolysaccharides promote leukocyte-vascular endothelium adhesion and induce endothelial damage, sometimes resulting in disseminated intravascular coagulation. The endothelial dysfunction may lead to blood-brain barrier disruption with its subsequent consequences on brain parenchyma. Peri-microvessel edema impairs the transfer of oxygen, nutrients, and metabolites, while increased blood-brain barrier permeability facilitates the passage of various neurotoxic factors. The sepsis-related damage of the blood-brain barrier is attenuated by glial cells, dexamethasone or nitric oxid synthetase inhibition. Mitochondrial dysfunction, oxidative stress, and apoptosis also occur. The formation of reactive oxygen species compromises cell function and survival. A major consequence of oxidative stress is apoptosis. Neuronal apoptosis can also be secondary to glial cell dysfunction. Neurons are also vulnerable to other disturbances that frequently accompany sepsis, such as hypoxemia, hyperglycemia, hypoglycemia and consequences of organ dysfunction. Liver dysfunction increases plasma levels of ammonium, which interferes with neurotransmission. Exposure to lipopolysaccharide causes accumulation of calcium in brain cells, impairs synaptic transmission and depresses neuronal excitability.

Patients with sepsis-associated encephalopathy have altered state of consciousness; they can be disoriented, agitated, confused, or delirious but also somnolent, stuporous or comatose.

Agitation and somnolence occur alternatively. Confusion and agitation are associated with hypoxia; despite hypoxia correction the state of consciousness remains altered, usually correlated with septic hypotension. Neurological examination should assess neck stiffness, motor responses, muscular strength, plantar and deep tendon reflexes and cranial nerves to disclose a focal neurologic sign. Seizures should be considered in the presence of abnormal movements or eyelid twitching. In heavily sedated patients, detection of brain dysfunction is challenging. Interruption of sedation is necessary for the evaluation of mental status, but it is very difficult to discriminate between a sepsis associated encephalopathy and an effect of sedative accumulation or withdrawal. In patients who cannot tolerate sedative interruption, the diagnosis of brain dysfunction relies on electrophysiology (somatosensory evoked potentials, electroencephalogram), serum brain biomarkers (neuron-specific enolase, S-100b protein) or brain imaging. Routine biochemical tests are mandatory to rule out a metabolic disturbance. An EEG may be helpful to detect non-convulsive status epilepticus. In sepsis-associated encephalopathy, the electroencephalogram may be normal or show excessive theta, predominantly delta, triphasic waves, or burst suppression (the two latter patterns are associated with increased mortality). Lumbar puncture should be performed if meningitis or encephalitis is suspected. In septic encephalopathy, cerebrospinal fluid is usually normal. Brain imaging is indicated in the presence of a focal neurologic sign or seizure. In comparison with the CT scan, the MRI allows an accurate exploration of the brain, especially of the white matter and blood-brain barrier. MRI can reveal ischemic or hemorrhagic lesions, white matter lesions including PRES or leukoencephalopathy related to blood-brain barrier breakdown affecting predominately the areas around the Virchow-Robin spaces, as well as grey matter lesions involving the basal ganglia and thalami.

Treatment consists of controlling the underlying infection and general supportive measures, management of organ failure and metabolic disturbances and avoidance of neurotoxic drugs.

## 9. Wernicke's encephalopathy

Wernicke's Encephalopathy is caused by the impairment of thiamine-dependent enzymatic activity in the susceptible brain cells. The classical clinical picture comprises of mental status changes, ocular motility signs and axial and/or gait ataxia developing acutely or subacutely in individuals prone to thiamine (vitamin B1) deficiency (e.g. alcoholics). Atypical clinical presentations ranging from unexplained hypothermia to coma may occur, especially in non-alcoholics. In the majority of cases the clinical picture is completely reversible providing adequate parenteral thiamine is promptly supplied (Galvin et al. 2010; Tanasescu 2009; Thorarinsson et al. 2011; Thomson et al. 2002). Due to factors related to the underlying disease (including increased metabolic requirements, impaired intestinal absorption and persistent vomiting) and sometimes to the inadequate diet, transplanted patients have increased risk of developing thiamine deficiency and therefore Wernicke's Encephalopathy (Bleggi-Torres et al. 2000; Thomson and Marshall 2006). Moreover, several drugs that may be required for the transplanted patients (e.g. 5-fluorouracil, cisplatin, erbulozole, ifosfamide metronidazole, antacids, phenytoin, cephalosporins, diuretics and tetracycline) may impair thiamine's absorption or utilization or may increase its elimination, thus increasing the risk of developing Wernicke's Encephalopathy (Kondo et al. 1996; Imtiaz and Muzaffar 2010; Hamadani and Awan 2006; Van Belle et al. 1993; Cho et al. 2009). Special attention should be paid that those on total parenteral nutrition receive adequate amounts of

thiamine. In marginally thiamine deficient patients, the administration of high doses of intravenous glucose solution may precipitate the development of Wernicke's Encephalopathy. Iatrogenic hyperalimentation without adequate thiamine supplementation may also precipitate it (Serra et al. 2007; Watson et al. 1981; Sechi and Serra 2007). The diagnosis is supported by the presence of characteristic imagistic findings (i.e. symmetrical periaqueductal and periventricular gray matter signal changes on brain MRI translating cytotoxic and subsequently vasogenic edema and blood brain barrier disruption) and by the identification of low thiamine blood levels. However, since parenteral thiamine administration is cheap, has virtually no contraindications (except for prior allergic reactions) and might be a life saving intervention, its administration should be started on clinical grounds only. The presence of concomitant hypomagnesaemia should be searched for and corrected. The 2010 EFNS guideline recommends that 200 milligrams of thiamine hydrochloride diluted in 100 millilitres of normal saline or glucose solution should be administered intravenously, thrice a day, until there is no further clinical improvement and advocates the maintenance of a low threshold for thiamine administration and a high index of suspicion for Wernicke's Encephalopathy (Galvin et al. 2010; Tanasescu 2009; Thorarinnsson et al. 2011; Thomson et al. 2002).

## 10. Posttransplantation opportunistic infection involving the CNS

The incidence of bacterial, fungal, viral and parasitic opportunistic infections is high in transplant recipients, especially in those with persistent neutropenia. The prophylactic use of broad spectrum antibiotics increases the risk of fungal infections (e.g. various *Candida* or *Aspergillus* species). Considering the poor prognosis of these infections prophylactic approaches are justified. The identification of the pathogen may sometimes be difficult and the treatment should be empirically started prior to the identification of the causative organism. Though the detailed discussion of the opportunistic infections involving the CNS is above the objective of the present chapter, several important aspects are detailed bellow.

Encephalitis caused by *Listeria*, *Toxoplasma*, *Varicella Zoster virus*, *Cytomegalovirus* and *Cryptococcus* may present with clinical and paraclinical findings similar to that of posttransplantation encephalopathies of other causes. In the chronic posttransplant period JC virus activation resulting in progressive multifocal leucoencephalopathy (PML) may also occur. Viral CNS opportunistic infections are most likely caused by herpes group viruses. Adenoviruses are also frequently involved. Routine prophylaxis with acyclovir has been reported to significantly reduce the incidence of herpes simplex type I, *Varicella Zoster virus* and *Cytomegalovirus* infections in transplanted patients (Shanahan et al. 2009). Human herpesvirus-6 has been reported to cause limbic encephalitis, commonly responsive to gancyclovir or foscarnet, in several transplant recipients. Septic *Aspergillus* brain embolism may be encountered, being reported to account for 15% of the neurological complications observed at necropsy in hematopoietic stem cells transplanted patients.

The brain MRI reveals multiple lesions preferentially involving the cerebral hemispheres, basal ganglia and corpus callosum. The microbiological isolation of the organism is especially difficult, the prognosis is poor and treatment (e.g. voriconazole and surgical management) should be started as soon as possible (Schwartz et al. 2005). CNS



toxoplasmosis (i.e. infection with *Toxoplasma gondii*) is the most frequent parasitic CNS infection occurring in transplanted patients. The clinical picture comprises of various degrees of mental status changes associated or not with the presence of focal signs. The brain MRI reveals multiple mass lesions, with different characteristics than those seen in AIDS-related toxoplasmosis, because in transplant patients contrast enhancement and haemorrhage are only rarely encountered (Portegies et al. 2004). *Toxoplasma gondii* DNA may be identified in the CSF of these patients by various techniques of polymerase chain reaction. Though it does not completely eliminate the risk of developing CNS toxoplasmosis, the prophylactic administration of trimethoprim/sulfamethoxazole should be considered in transplanted patients. Rarely *Listeria monocytogenes*, *Mycobacterium tuberculosis* and *Cryptococcus neoformans* may cause meningitis in transplanted patients. Brain abscesses caused by *Nocardia asteroides*, *Mucorales* or *Candida* species have been reported to occur in transplanted patients (Singh and Husain 2000).

## 11. Conclusions

Transplantation medicine is a constantly changing field. PTE is a common neurologic complication with a broad spectrum of causes and presentations. Knowledge of all the potential etiologies and of the particularities of transplanted patients are a sine qua non condition for the optimal management of these patients.

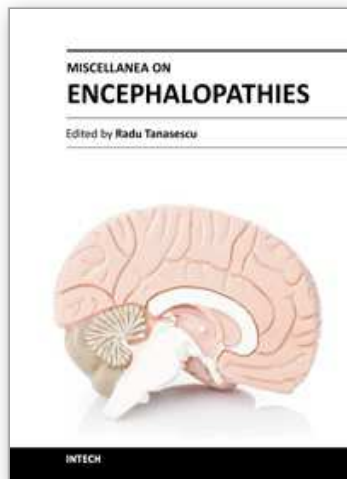
## 12. References

- Bartynski WS, Tan HP, Boardman JF, Shapiro R, Marsh JW (2008) Posterior reversible encephalopathy syndrome after solid organ transplantation. *American Journal of Neuroradiology*; 29:924-930
- Bashir RM (2001) Neurologic Complications of Organ Transplantation. *Current treatment options in neurology* 3 (6):543-554
- Bechstein WO (2000) Neurotoxicity of calcineurin inhibitors: impact and clinical management. *Transplant International*; 5:313-326.
- Bleggi-Torres LF, de Medeiros BC, Werner B, Neto JZ, Loddo G, Pasquini R, de Medeiros CR (2000) Neuropathological findings after bone marrow transplantation: an autopsy study of 180 cases. *Bone marrow transplantation* 25 (3):301-307.
- Brouns R, De Deyn PP (2004) Neurological complications in renal failure: a review. *Clinical Neurology and Neurosurgery* ; 107: 1-16
- Chabolla DR, Harnois DM, Meschia JF (2003) Levetiracetam monotherapy for liver transplant patients with seizures. *Transplant Proc*; 35: 1480-1481
- Cho IJ, Chang HJ, Lee KE, Won HS, Choi MY, Nam EM, Mun YC, Lee SN, Seong CM (2009) A case of Wernicke's encephalopathy following fluorouracil-based chemotherapy. *Journal of Korean medical science* 24 (4):747-750.
- Cruz-Martinez E, Gilmore RL (2002). Transplantation and seizures. In: Ettinger AB and Devinsky O, eds. *Managing epilepsy and co-existing disorders*. Boston: Butterworth-Heinemann; 75-82.
- Echaniz-Laguna A, Battaglia F, Ellero B, Mohr M, Jaek D (2004) Chronic inflammatory demyelinating polyradiculoneuropathy in patients with liver transplantation. *Muscle and Nerve*; 30: 501-504.

- Galvin R, Brathen G, Ivashynka A, Hillbom M, Tanasescu R, Leone MA (2010) EFNS guidelines for diagnosis, therapy and prevention of Wernicke encephalopathy. *European journal of neurology : the official journal of the European Federation of Neurological Societies* 17 (12):1408-1418.
- Gerald R. Crabtree (2001). Calcium, Calcineurin and the Control of Transcription. *Journal of Biological Chemistry*; 276(4): 2313-2316.
- Guarino M, J. Benito-Leon, J. Decruyenaere, E. Schmutzhard, K. Weissenborn, A. Stracciari(2006) EFNS guidelines on management of neurological problems in liver transplantation. *European Journal of Neurology*; 13: 2-9
- Hamadani M, Awan F (2006) Role of thiamine in managing ifosfamide-induced encephalopathy. *Journal of oncology pharmacy practice : official publication of the International Society of Oncology Pharmacy Practitioners* 12 (4):237-239.
- Illsinger S, Janzen N, LÄ¼cke T, Bednarczyk J, Schmidt K-H, Hoy L, Sander J, Das nAM(2010). Cyclosporine A: impact on mitochondrial function in endothelial cells. *Clinical Transplantation*; 25(4)
- Intiaz S, Muzaffar N (2010) Ifosfamide neurotoxicity in a young female with a remarkable response to thiamine. *JPMA The Journal of the Pakistan Medical Association* 60 (10):867-869
- Jantzen JP (2007) Prevention and treatment of intracranial hypertension. *Best Pract Res Clin Anaesthesiol* 21 (4):517-538
- Kentaro I, Hideki O, Hiroyuki T, Kohei I, Masayuki S, Toshimitsu I, Masahiro O, HirotakaT(2007) Possible therapeutic effect of lipid supplementation on neurological complications in liver transplant recipients. *Transplant International*; 20 (7): 632-635.
- Kondo K, Fujiwara M, Murase M, Kodera Y, Akiyama S, Ito K, Takagi H (1996) Severe acute metabolic acidosis and Wernicke's encephalopathy following chemotherapy with 5-fluorouracil and cisplatin: case report and review of the literature. *Japanese journal of clinical oncology* 26 (4):234-236
- Liang BC(2000) Neurologic complications of orthotopic liver transplantation. *Hospital Physician*: 43-46
- Londono MC, Guevara M, Rimola A, Navasa M, Taura P, Mas A, Garcia-Valdecasas JC, Arroyo V, Gines P(2006) Hyponatremia Impairs Early Posttransplantation Outcome in Patients With Cirrhosis Undergoing Liver Transplantation. *Gastroenterology*;130 :1135-1143
- Mathew RM, Rosenfeld MR (2007) Neurologic Complications of Bone Marrow and Stem-cell Transplantation in Patients with Cancer. *Current treatment options in neurology* 9 (4):308-314
- Padovan CS, Bise K, Hahn J, Sostak P, Holler E, Kolb HJ, Straube A (1999) Angiitis of the central nervous system after allogeneic bone marrow transplantation? *Stroke; a journal of cerebral circulation* 30 (8):1651-1656
- Padovan CS, Sostak P, Straube A (2000) [Neurological complications after organ transplantation]. *Der Nervenarzt* 71 (4):249-258
- Portegies P, Solod L, Cinque P, et al(2004) Guidelines for the diagnosis and management of neurological complications of HIV infection. *European Journal of Neurology* 11:297-304

- Sechi G, Serra A (2007) Wernicke's encephalopathy: new clinical settings and recent advances in diagnosis and management. *Lancet neurology* 6 (5):442-455. Serra A, Sechi G, Singh S, Kumar A (2007) Wernicke encephalopathy after obesity surgery: a systematic review. *Neurology* 69 (6):615; author reply 615-616.
- Singh N, Bonham A, Fukui M(2000) Immunosuppressive-associated leukoencephalopathy in organ transplant recipients. *Transplantation*;69:467
- Singh N, Husain S (2000) Infections of the central nervous system in transplant recipients. *Transpl Infect Dis* 2 (3):101-111.
- Shanahan A, Malani PN, Kaul DR(2009) Relapsing cytomegalovirus infection in solid organ transplant recipients. *Transplant Infectious Disease*;11(6)
- Tanasescu R (2009) Wernicke's Encephalopathy In General Neurological Practice: Short Considerations On The Need For Revision (I). *Romanian Journal of Neurology* VIII (3):3
- Thomson AD, Cook CC, Touquet R, Henry JA (2002) The Royal College of Physicians report on alcohol: guidelines for managing Wernicke's encephalopathy in the accident and Emergency Department. *Alcohol* 37 (6):513-521
- Thomson AD, Marshall EJ (2006) The treatment of patients at risk of developing Wernicke's encephalopathy in the community. *Alcohol* 41 (2):159-167.
- Thorarinnsson BL, Olafsson E, Kjartansson O, Blondal H (2011) [Wernicke's encephalopathy in chronic alcoholics]. *Laeknabladid* 97 (1):21-29
- Van Belle SJ, Distelmans W, Vandebroek J, Bruynseels J, Van Ginckel R, Storme GA (1993) Phase I trial of erbulozole (R55104). *Anticancer research* 13 (6B):2389-2391
- Watson AJ, Walker JF, Tomkin GH, Finn MM, Keogh JA (1981) Acute Wernicke's encephalopathy precipitated by glucose loading. *Irish journal of medical science* 150 (10):301-303
- Watt KD, Pedersen RA, Kremers WK, Heimbach JK, Charlton MR(2010). Evolution of Causes and Risk Factors for Mortality Post-Liver Transplant: Results of the NIDDK Long-Term Follow-Up Study. *American Journal of Transplantation*; 10(6):1420-1427
- Wijdicks EF (2001) Neurotoxicity of immunosuppressive drugs. *Liver Transplantation*; 7: 937-942

IntechOpen



## **Miscellanea on Encephalopathies**

Edited by Dr. Radu Tanasescu

ISBN 978-953-51-0499-5

Hard cover, 202 pages

**Publisher** InTech

**Published online** 18, April, 2012

**Published in print edition** April, 2012

The book project “Miscellanea on Encephalopathies” aims to cover some of the important aspects of infectious-related encephalopathies, post-transplantation and drug-induced encephalopathies, by transmitting valuable information filtered through the real life clinical and research experience of the authors.

### **How to reference**

In order to correctly reference this scholarly work, feel free to copy and paste the following:

Daniela Anghel, Laura Dumitrescu, Catalina Coclitu, Amalia Ene, Ovidiu Bajenaru and Radu Tanasescu (2012). Posttransplantation Encephalopathies, Miscellanea on Encephalopathies, Dr. Radu Tanasescu (Ed.), ISBN: 978-953-51-0499-5, InTech, Available from: <http://www.intechopen.com/books/miscellanea-on-encephalopathies/posttransplantation-encephalopathies>

**INTECH**  
open science | open minds

### **InTech Europe**

University Campus STeP Ri  
Slavka Krautzeka 83/A  
51000 Rijeka, Croatia  
Phone: +385 (51) 770 447  
Fax: +385 (51) 686 166  
[www.intechopen.com](http://www.intechopen.com)

### **InTech China**

Unit 405, Office Block, Hotel Equatorial Shanghai  
No.65, Yan An Road (West), Shanghai, 200040, China  
中国上海市延安西路65号上海国际贵都大饭店办公楼405单元  
Phone: +86-21-62489820  
Fax: +86-21-62489821

© 2012 The Author(s). Licensee IntechOpen. This is an open access article distributed under the terms of the [Creative Commons Attribution 3.0 License](#), which permits unrestricted use, distribution, and reproduction in any medium, provided the original work is properly cited.

IntechOpen

IntechOpen