

# We are IntechOpen, the world's leading publisher of Open Access books Built by scientists, for scientists

4,800

Open access books available

122,000

International authors and editors

135M

Downloads

Our authors are among the

154

Countries delivered to

TOP 1%

most cited scientists

12.2%

Contributors from top 500 universities



WEB OF SCIENCE™

Selection of our books indexed in the Book Citation Index  
in Web of Science™ Core Collection (BKCI)

Interested in publishing with us?  
Contact [book.department@intechopen.com](mailto:book.department@intechopen.com)

Numbers displayed above are based on latest data collected.

For more information visit [www.intechopen.com](http://www.intechopen.com)



# Detection of Intracardiac and Intrapulmonary Shunts at Rest and During Exercise Using Saline Contrast Echocardiography

Andrew T. Lovering and Randall D. Goodman  
*University of Oregon, Oregon Heart & Vascular Institute,  
USA*

## 1. Introduction

Ultrasound has become a valuable tool for making non-invasive physiological measurements that are clinically important, one of which is detection of anatomic shunts using saline contrast echocardiography. Right-to-left intrapulmonary and intracardiac shunts are clinically relevant for two reasons. First, they allow deoxygenated blood to mix with oxygenated blood, thereby reducing the overall efficiency of pulmonary gas exchange. Thus, the opening of either intrapulmonary or intracardiac shunts at rest and/or during exercise may play a role in determining pulmonary gas exchange efficiency (Sun *et al.*, 2002; Stickland & Lovering, 2006; Lovering *et al.*, 2011). The opening of these shunts may also explain why some people with pulmonary diseases such as chronic obstructive pulmonary disease (COPD) desaturate so profoundly during even mild exercise (Miller *et al.*, 1984; Dansky *et al.*, 1992). The second reason that these pathways are clinically relevant is that anatomic right-to-left shunts may allow for thrombi to bypass the pulmonary capillary filter. Indeed, a patent foramen ovale and pulmonary arteriovenous malformations are associated with increased risk for neurological sequelae such as migraines, transient ischemic attacks and stroke (Movsowitz *et al.*, 1992; Petty *et al.*, 1997; De Castro *et al.*, 2000; Lamy *et al.*, 2002).

Where there is a right-to-left shunt it is likely that there may also be a left-to-right shunt following the same path but during a different phase of the cardiac and/or respiratory cycle. Left-to-right shunts are clinically relevant because they can result in right heart volume overload and irreversible pulmonary hypertension (Mulder, 2010). Thus, evidence of right heart chamber enlargement or right-to-left shunt by saline contrast echocardiography is sufficient reason for further investigation to rule out significant left-to-right shunting.

This chapter will focus on the ultrasound measurements used for detecting anatomic right-to-left shunts at rest, during exercise and during pharmacological-induced stress in both clinical and research settings. We also include a section on recent findings from our lab and others using saline contrast to detect right-to-left shunts in healthy human subjects and subjects with COPD.

## 2. Right-to-left intrapulmonary and intracardiac shunt

Intracardiac shunts include patent foramen ovale (PFO), atrial septal defects (ASD) and ventricular septal defects (VSD). It is generally accepted that 25 to 30% of the general population has a probe-patent foramen ovale (Hagen *et al.*, 1984). Interestingly, recent estimates of the prevalence of PFO using saline contrast echocardiography suggest a slightly higher prevalence of approximately 40% (Woods *et al.*, 2010; Elliott *et al.*, 2011b). The association of PFO with neurological sequelae such as migraine, transient ischemic attack and stroke make these pathways highly clinically relevant (Homma *et al.*, 1997; Petty *et al.*, 1997; De Castro *et al.*, 2000; Lamy *et al.*, 2002; Carpenter *et al.*, 2010).

It has been documented for over 70 years that anatomic right-to-left intrapulmonary shunts exist in normal human lungs. The studies that established the existence of these pathways used solid, large diameter microspheres to prove that there are large diameter pathways that bypass pulmonary capillaries (von Hayek, 1940; Tobin & Zariquiey, 1950; Tobin, 1966). More recent studies by our group have used microspheres to demonstrate the existence of large diameter (>25 to 50  $\mu\text{m}$ ) intrapulmonary arteriovenous anastomoses in isolated, ventilated and perfused healthy human and baboon lungs under physiologic conditions (Lovering *et al.*, 2007).

Intrapulmonary right-to-left pathways can be pulmonary arteriovenous malformations (PAVMs), grossly distended capillaries or arteriovenous anastomoses. The prevalence of PAVMs and grossly distended capillaries that result from rare diseases such as hepatopulmonary syndrome and hemorrhagic hereditary telangiectasia is considered to be very small, on the order of 1 in 50,000 (Khurshid & Downie, 2002; Liu *et al.*, 2010). However, we have found that greater than 95% of healthy humans have intrapulmonary arteriovenous anastomoses that are closed at rest but open up during exercise (Stickland & Lovering, 2006; Lovering *et al.*, 2010). Furthermore, the existence of these pathways in baboon lungs suggests that they may not be evolutionary disadvantageous since humans, gorillas and chimpanzees diverged from the old world monkeys (baboons, macaques, etc.) approximately 25 to 30 million years ago (Purvis, 1995; Goodman *et al.*, 1998; Stewart & Disotell, 1998). Although there is a high prevalence of these pathways in healthy humans, a significant impact on physiologic processes has not yet been proven.

## 3. Echocardiography for the detection of anatomic right-to-left shunt at rest

Saline contrast echocardiography is a proven non-invasive technique for the detection of right-to-left shunts at rest. This technique is used in both clinical and research settings, although certified ultrasonographers are typically required to obtain images of diagnostic quality. We strongly suggest that all recommendations by the American Society for Echocardiography for performance, interpretation and application of saline contrast echocardiography be followed accordingly (Waggoner *et al.*, 2001; Mulvagh *et al.*, 2008).

### 3.1 Theory

Echocardiography used as a technique for the detection of right-to-left shunts assumes that intravenously-infused saline contrast bubbles are filtered out by the pulmonary capillaries or collapse before reaching the left side of the heart (Yang, 1971; Yang *et al.*, 1971a, b; Meltzer

*et al.*, 1980a; Meltzer *et al.*, 1980b; Meltzer *et al.*, 1981; Bommer *et al.*, 1984; Woods & Patel, 2006). Thus, large diameter bubbles do not reach the left side of the heart unless they travel through large diameter pathways such as pulmonary arteriovenous malformations (PAVMs) or a PFO. Saline contrast echocardiography is therefore considered to be the most sensitive test for detection of intracardiac shunts (Belkin *et al.*, 1994). With a prevalence of 30 to 40%, it is difficult to argue the existence of a PFO if intravenously injected saline contrast bubbles appear in the left heart. Alternatively, saline contrast echocardiography as a technique for intrapulmonary right-to-left shunts remains less well established, despite the fact that it is more sensitive than pulmonary angiography for detection of even the smallest right-to-left intrapulmonary shunts (Cottin *et al.*, 2004; van Gent *et al.*, 2009).

### 3.2 Equipment, instrumentation & technique

Subjects are instrumented with an intravenous catheter (i.v.) in a peripheral vein for the introduction of the contrast agent, which is normally air and sterile saline. Typically, 0.5-1 ml of air and 4-10 ml of saline are used to manually agitate between two syringes connected by stopcocks for a total injection volume of 10 ml (Otto, 2004; Feigenbaum, 2005; Woods *et al.*, 2010). In a research setting, equal success has been achieved in detecting right-to-left shunts via intrapulmonary arteriovenous anastomoses using 0.5-1 ml of air and 3-5 ml of saline, for a total injection volume of 5 ml (Stickland & Lovering, 2006; Laurie *et al.*, 2010; Lovering *et al.*, 2010; Elliott *et al.*, 2011a). The agitated saline mix solution should be injected as a bolus, forcibly by hand. Simultaneously, a well-trained sonographer should be acquiring a four chamber apical view of the heart. For superior image quality, the resting subject should be positioned in the left lateral decubitus position so that the heart moves anteriorly and laterally within the chest cavity. If necessary, the left arm should be folded upwards behind the head to expand the ribcage. A mattress cutout/drop-down is beneficial when the subject must be rolled steeply onto their left side to reduce lung artifact during inspiration. The echocardiograph should be preset to digitally acquire a 20-beat loop and the sonographer should employ settings that achieve high resolution without compromising penetration. The focal zone should be set near the base of the heart.

Technique and timing are important for a successful agitated saline contrast echocardiogram with a Valsalva maneuver. The subject should be instructed in the Valsalva maneuver and it is often helpful if they practice it a few times prior to contrast injection. The sonographer should position the patient and locate the best apical imaging window. The patient is asked to inhale a small breath, stop breathing, tighten the stomach muscles and sustain this effort for a minimum of ten seconds. The sonographer should move the imaging plane (typically inferiorly and medially) with the heart during the maneuver and then follow the heart back to the original window upon release of the maneuver. During the maneuver, a second caregiver forcibly agitates the saline mixture by plunging it back and forth between two syringes. When the 10 second maneuver is nearly completed, the contrast is quickly injected. Image acquisition should commence the moment contrast is injected. Immediately following injection, the subject is instructed to release the Valsalva maneuver and take small breaths. Upon release of Valsalva a rush of contrast will quickly opacify the right heart. Additional injections are performed if initial findings are equivocal.

Transesophageal echocardiography (TEE) provides image resolution that is superior to transthoracic echocardiography (TTE). Saline contrast injections are a routine element of

every TEE and intracardiac shunt pathways are often easily identified as contrast passes through them. Patient sedation can prevent adequate Valsalva maneuvers during TEE so right-to-left shunts across a patent foramen ovale may go undetected (Fisher *et al.*, 1995).

### 3.3 Differentiating between intrapulmonary and intracardiac shunt

Once the agitated saline contrast mix is injected as a bolus, forcibly by hand, timing becomes critical in differentiating between intrapulmonary and intracardiac right-to-left shunts. After the appearance of saline contrast on the right side of the heart, timing of the appearance of saline contrast bubbles on the left heart will determine whether an intrapulmonary or intracardiac shunt is suspected. In general, if bubbles appear on the left side of the heart in  $\leq 3$  heart beats, then an intracardiac shunt is suspected, e.g. patent foramen ovale, atrial septal defect (Meltzer *et al.*, 1980a; Woods & Patel, 2006). If an intracardiac shunt is suspected, then a second contrast injection should be performed upon the subject's release of a Valsalva maneuver (Woods & Patel, 2006). Performing and releasing the Valsalva maneuver transiently elevates right heart pressure, which reverses the pressure gradient between the atria, creating conditions favorable for right-sided contrast to move to the left side of the heart across the intracardiac shunt. The second injection should confirm the presence of an intracardiac shunt if there is increased contrast and/or if the contrast bubbles continue to appear in the left heart in  $\leq 3$  heartbeats. Alternatively, if saline contrast bubbles appear in the left heart in  $> 3$  heartbeats after their appearance in the right heart, then an intrapulmonary shunt is suspected, e.g., pulmonary arteriovenous malformation, pulmonary arteriovenous anastomoses (Nanthakumar *et al.*, 2001; Lee *et al.*, 2003; van Gent *et al.*, 2009; Elliott *et al.*, 2011a). The different types of intracardiac and intrapulmonary shunts are outlined in detail below.

#### 3.3.1 Intracardiac shunts

The most common intracardiac shunt pathway is the PFO. Unlike ASDs, a PFO is a feature of normal cardiac development. Although the foramen is no longer patent in the majority of adults, a PFO is detectible in 25 to 40% of the general population (Hagen *et al.*, 1984; Woods *et al.*, 2010; Elliott *et al.*, 2011b). A PFO typically has the echocardiographic appearance of a valve-like flap of tissue covering the foramen ovale in the middle portion of the interatrial septum. This flap can be seen opening intermittently into the left atrium whenever right atrial pressure exceeds left atrial pressure. If fusion of the flap provides a nearly complete seal, the remaining orifice is shaped more like a narrow slit or tunnel. Standard TTE views for visualizing a PFO include the parasternal short-axis view at the level of the aortic valve, the right parasternal bicaval view and the subcostal bicaval view. The atrial septum is best imaged by TEE and a small PFO may only be visualized using this technique. However, saline contrast TTE during the release of a Valsalva maneuver has been found to be even more sensitive than TEE for revealing a PFO (Lam *et al.*, 2010; Gonzalez-Alujas *et al.*, 2011). To achieve the highest sensitivity for intracardiac right-to-left shunting, one should always coordinate contrast injection with the release of a Valsalva maneuver.

Right-to-left shunting may also occur through an ASD. The most common type is a secundum ASD. Unlike a PFO, a secundum ASD typically has the appearance of a hole with defined edges. Similar to a PFO, a secundum defect is located in the middle of the interatrial



septum and may be quite small and difficult to visualize. It is best viewed using the same imaging planes one would use to view a PFO, and might only be detected by a saline contrast injection. Three-dimensional imaging, either TTE or TEE, is a useful method of examining the true shape and area of the defect. It is important to differentiate between a PFO and an ASD because an ASD is less likely to restrict left-to-right shunting and therefore may present a greater risk of right heart volume overload and associated sequelae.

An ostium primum ASD results from the incomplete fusion of the inferior and superior endocardial cushions and therefore is located in the inferior portion of the interatrial septum. An ostium primum ASD may exist in isolation and may be referred to as a partial AV canal. Commonly it is paired with an inlet ventricular septal defect, in which case it bears the name atrioventricular septal defect (AVSD) or complete AV canal. A distinguishing feature of AVSD is that both atrioventricular valves share the same annulus and valve plane. This valvular alignment is visible by TTE in the apical four-chamber view. This is easily distinguishable from normal heart alignment because the normal tricuspid valve plane is displaced towards the apex relative to the mitral valve plane.

A defect adjoining the atria near the junction of the superior or inferior vena cava with the right atrium is a sinus venosus ASD. It most often involves the superior and posterior portion of the interatrial septum and is commonly associated with partial anomalous pulmonary venous return. It can be difficult to detect using standard TTE views but is readily visible by TEE in the bicaval view. An effort should be made to rule out sinus venosus ASD if a substantial and early right-to-left shunt is detected by saline contrast injection without evidence of defects in the secundum or primum septum.

The absence of separation between the roof of the coronary sinus and the floor of the left atrium (coronary sinus defect) has often been categorized as an atrial septal defect because it effectively provides a shunt pathway between the atria via the coronary sinus. This defect is sometimes associated with a common thoracic venous abnormality known as persistent left superior vena cava (PLSVC). A PLSVC provides venous return from the left upper extremity (or both if the right SVC is absent) into the right atrium via the coronary sinus resulting in coronary sinus dilatation. For direct visualization of a coronary sinus defect, TEE is superior to TTE. However, a customized saline contrast TTE can uncover both PLSVC and coronary sinus defect with one injection. Whenever a dilated coronary sinus is detected (usually an incidental finding), a PLSVC and/or coronary sinus defect should be suspected as the cause and a saline contrast injection should be performed (Goyal *et al.*, 2008). The sonographer images the heart using an inferiorly tilted apical four-chamber view to reveal coronary sinus drainage into the right atrium. Once contrast appears within the coronary sinus, the sonographer quickly tilts the scanhead anteriorly to the standard apical four-chamber view. If a PLSVC is present, contrast will be seen in the coronary sinus before it reaches the right atrium. If both a PLSVC and a coronary sinus defect are present, contrast will appear within the left atrium and right atrium simultaneously. If contrast appears within the left atrium shortly following opacification of the right atrium, a PFO is likely but a coronary sinus defect is effectively ruled-out.

Saline contrast echocardiography should not be used to rule out suspected small ventricular septal defects (VSD). Shunting through a small VSD is primarily systolic, left-to-right, and because of the high-pressure gradient they are readily apparent by color flow Doppler on

the right ventricular side of the septum. If a small VSD is suspected by 2D imaging, but there is no high-velocity systolic color jet on the right side of the septum and right ventricular systolic pressure is normal, VSD has been effectively ruled out.

### 3.3.2 Intrapulmonary shunts

As listed above, the interrogator should count the number of cardiac cycles between right atrial opacification and the arrival of contrast in the left atrium. If the delay is  $> 3$  cardiac cycles, the passage of microbubbles followed a transpulmonary pathway. Intrapulmonary pathways include pulmonary arteriovenous malformations (PAVMs) and intrapulmonary arteriovenous anastomoses. Although PAVMs are considered to be rare, and associated with diseases states, more recent work suggests a prevalence of  $\sim 20\%$  in the general population (Woods *et al.*, 2010; Elliott *et al.*, 2011b). Whether or not these pathways detected by Woods and colleagues are truly PAVMs or intrapulmonary arteriovenous anastomoses is unknown. Preliminary findings from our lab suggest that they are the latter (Elliott *et al.*, 2011b), however further research into this area is needed.

Clinically, subjects lay in the supine position for ultrasound imaging. In a research setting, subjects can be in a supine, upright or reclined position, however interpretation of the echocardiograms should take into account body positioning during ultrasound imaging. Specifically, there are data suggesting that intrapulmonary arteriovenous anastomoses are patent in the supine position, but not in the upright position (Stickland *et al.*, 2004; Elliott *et al.*, 2011b). Also, Tobin & Zariquiey demonstrated that intrapulmonary arteriovenous anastomoses 20 to 500  $\mu\text{m}$  in functional diameter are located in the apex of the human lung (Tobin & Zariquiey, 1950). Together, these data support the idea that perfusion of the apices of the lung may open these vessels. Thus, if the goal is to identify the presence of intrapulmonary right-to-left shunts, then subjects should be screened in the supine position. When subjects are in the reclined position, it is recommended that they be rotated 45 degrees on their left side to allow for optimal imaging conditions.

In summary, the chance to detect either an intracardiac or an intrapulmonary right-to-left shunt in healthy human subjects at rest is approximately 60% (40% PFO + 20% intrapulmonary). In subjects with a PFO, it is not possible to unequivocally detect intrapulmonary right-to-left shunts. The reason for this is that bubbles may cross over the inter-atrial septum at any time during echocardiographic imaging. Thus, if bubbles appear in the left ventricle after 10 heartbeats in subjects with a PFO, there is no way to determine if those bubbles crossed the atrium via an intracardiac or intrapulmonary shunt pathway.

### 3.4 Semi-quantification of right-to-left shunt

There are numerous scoring methods used in both clinical and research settings for *semi-quantification* of right-to-left shunt with saline contrast bubbles (Barzilai *et al.*, 1991; Lovering *et al.*, 2008b; La Gerche *et al.*, 2010; Laurie *et al.*, 2010). These scoring methods take into account the density and spatial distribution of saline contrast bubbles in the left heart. As such, a score of 0 typically represents no saline contrast bubbles, while increasing numbers indicate increasing amounts of saline contrast (Figure 1). Better anatomic approaches to quantification of right-to-left shunts use radiolabeled albumin macroaggregates in

conjunction with nuclear medicine imaging (Whyte *et al.*, 1992; Lovering *et al.*, 2009b), but this topic is beyond the scope of the current chapter.

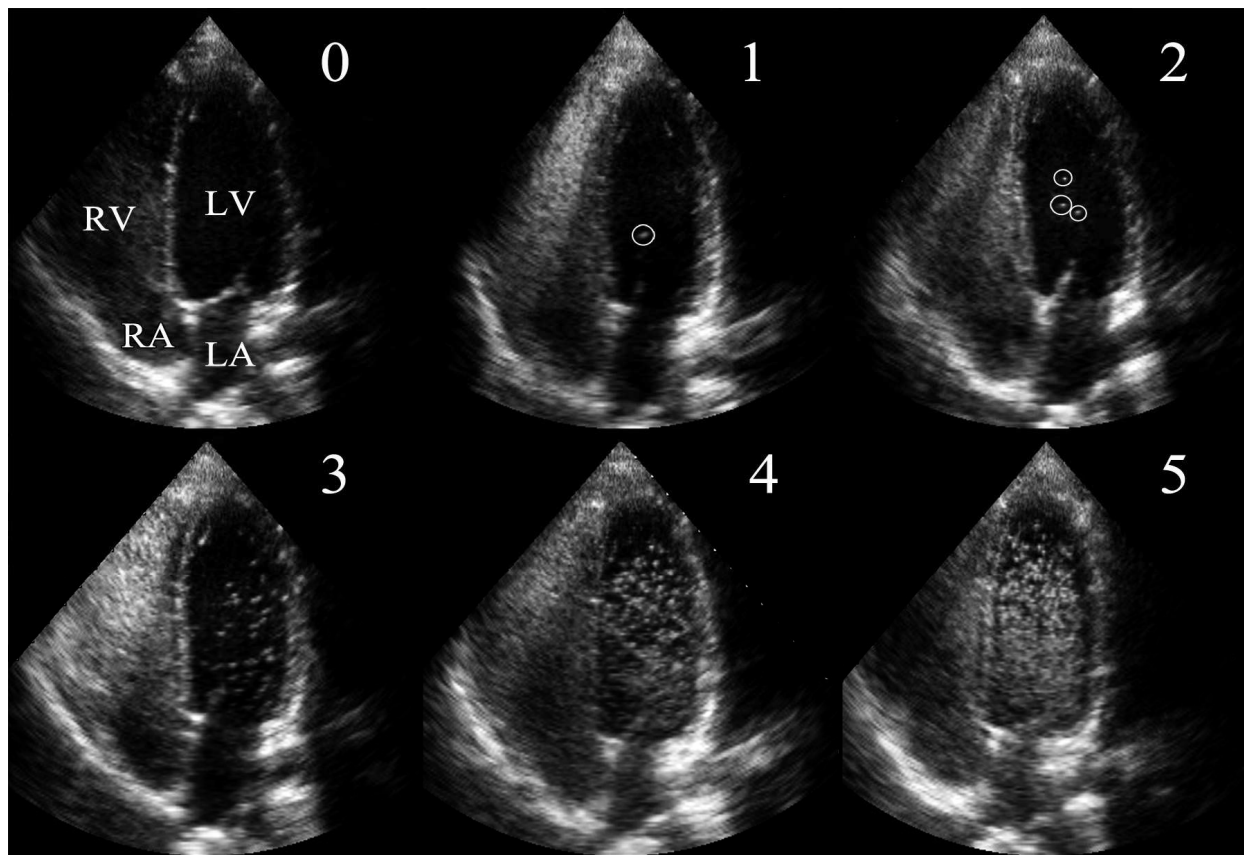


Fig. 1. Representative echocardiograms of bubble scores. Scores are assigned based on both the density and spatial distribution of microbubbles in the left ventricle from the frame with the largest amount of contrast. A score of 0 = 0 microbubbles; 1 = 1 - 3 microbubbles; 2 = 4 - 12 microbubbles; 3 = more than 12 microbubbles in a bolus; 4 = more than 12 microbubbles heterogeneously distributed throughout the left ventricle; 5 = more than 12 microbubbles homogeneously distributed throughout the left ventricle. Scores 1 and 2 have bubbles circled for clarity. RA, LA = right & left atrium; RV, LV = right & left ventricle.

#### 4. Echocardiography for the detection of anatomic right-to-left shunt during exercise & stress

Stress echocardiography is a proven non-invasive technique frequently used to test for flow-limiting coronary artery disease in patients with symptoms of angina. Less commonly, it is used in combination with Doppler techniques to evaluate the effect of stress on valvular lesions and outflow tract obstruction. Saline contrast is also useful during exercise to enhance the Doppler signal or to assess the effect of exercise on right-to-left shunting. Performing echocardiography on an individual during exercise is a challenge to the skill of the sonographer. Obtaining images of diagnostic quality is made more difficult by respiratory artifact, motion of the patient, exaggerated cardiac motion, and tachycardia. It is recommended that only experienced sonographers be selected for the performance of these tests. Furthermore, we strongly suggest that all recommendations by the American Society



for Echocardiography for performance, interpretation and application of stress echocardiography be followed accordingly (Pellicka *et al.*, 2007).

#### 4.1 Technical considerations for echocardiographic measurements during exercise

The ultrasound equipment required for saline contrast echocardiography during exercise are the same as those listed above for resting imaging. Continuous 12-lead electrocardiography is often performed during exercise testing. Depending upon the locations of the imaging windows in an individual during rest and exercise, some of the precordial EKG leads may need to be relocated to allow for echocardiographic imaging. This varies significantly between individuals, but the leads most likely to be affected are V2, V4 and V5. If they must be moved, V2 can be moved to a higher rib space and V4 and V5 can be moved to a lower rib space to accommodate echocardiographic imaging (Figure 2).

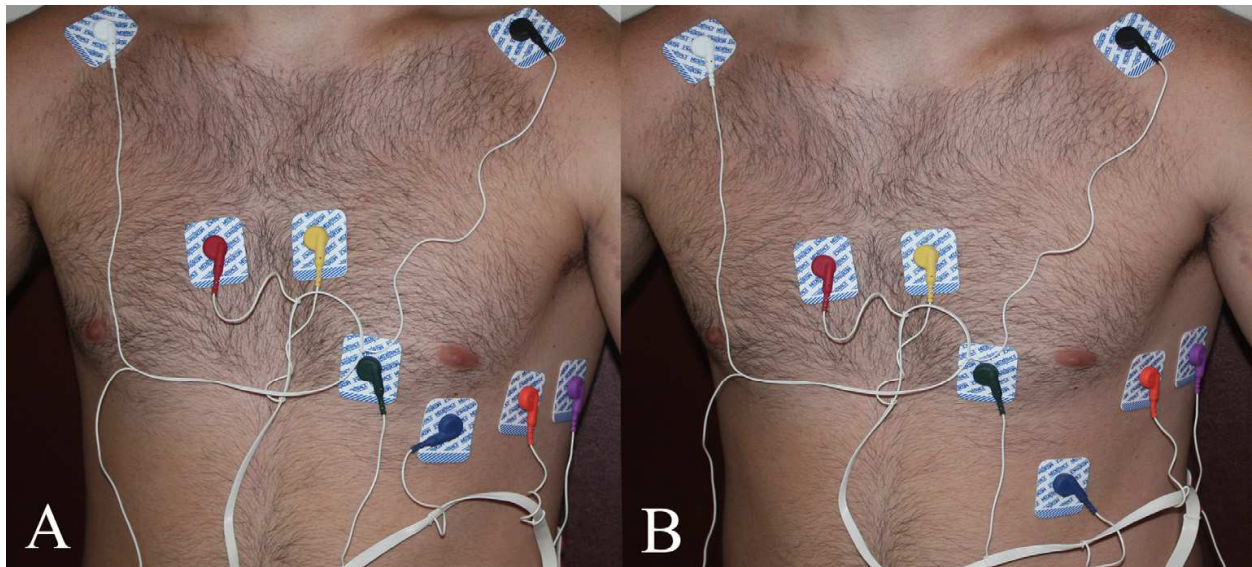


Fig. 2. Placement of 12 lead electrodes for use with ultrasound imaging during exercise. A) normal configuration, B) adaptive configuration example.

#### 4.2 Treadmill versus cycle ergometer exercise:

Most stress echocardiograms are performed using a treadmill and three minute stages of increasing workload. Treadmill exercise has the advantage in that it allows most patients to achieve their target heart rate (85% of the age-predicted maximum) on a treadmill. However, it bears the significant disadvantage that echocardiographic images cannot be acquired during exercise. Images must be acquired immediately following exercise during the recovery phase on an exam table, and for this reason, transient exercise-induced cardiac abnormalities, and right-to-left shunting, can be missed.

Supine and/or recumbent cycle ergometers are popular in many clinical settings because echocardiographic imaging can be performed during exercise (Stickland *et al.*, 2004). The cycling apparatus is built into an exam table so that an individual is able to exercise while lying in the supine or recumbent position. These tables normally include the capacity to be tilted sideward and are equipped with a drop-down section to expose the apical imaging

window. These features permit high quality imaging during various levels of exercise. The primary disadvantage of supine cycle stress is that some patients find it difficult to exercise well in that position and are consequently unable to achieve the target heart rate.

We have considerable experience successfully performing diagnostic contrast-enhanced spectral Doppler studies during exercise and evaluations of right-to-left shunting during exercise on subjects in the forward-leaning upright bike arrangement, or “Aerobar” position (Lovering *et al.*, 2008b; Elliott *et al.*, 2011a) (Figure 3). The “Aerobar” position has several advantages: One, subjects are able to lean forward resting their forearms on bars that allow them to maintain a relatively still upper body during exercise. Two, the apex of the heart falls forward in this position allowing for superior image quality during exercise. Three, this is a more comfortable and more natural position for exercise than the supine bike, so the likelihood of achieving the target heart rate is greater than in supine exercise. Four, evaluation of global and regional left and right ventricular wall motion may also be successfully performed during exercise in this position. A disadvantage is that it can be difficult to image a patient during exercise in this position if they have abdominal obesity. To date, similar results have been found when comparing right-to-left shunt during recumbent and upright exercise (Stickland *et al.*, 2004; La Gerche *et al.*, 2010; Elliott *et al.*, 2011a). There are no published data examining intrapulmonary shunting during supine exercise. We would suggest that body positioning be taken into consideration when making these measurements in the supine position during exercise given the fact that previous work has shown differences in patency of intrapulmonary arteriovenous anastomoses at rest (see **3.3.2 Intrapulmonary Shunts** above). Thus it seems appropriate to use the cycle ergometer-testing paradigm that best suits the investigator needs.

#### **4.3 Non-exercise stress modalities**

In addition to cycle ergometer exercise, pharmacologic-induced stress can be used in lieu of “true exercise.” Pharmacological stress echocardiography allows for better image quality than any of the competing exercise modalities because the patient is lying still in a position best suited for imaging while the heart is stressed chemically. The most common protocol calls for continuous infusion of dobutamine that increases in three to five minute stages with atropine injections performed during the later stages if necessary to reach the target heart rate (Pellikka *et al.*, 2007). Pharmacological stress echocardiography is the preferred method when a patient is physically unable to exercise or when valvular lesions or outflow tract obstructions need to be assessed. The disadvantage of pharmacological stress is that it is not true exercise. Additionally, many patients do not tolerate the drugs well.

### **5. Recent research advancements using echocardiography in healthy humans & patient populations**

#### **5.1 Research using echocardiography in healthy humans during exercise**

Work by our group and others have focused on detection of intrapulmonary and intracardiac shunting at rest and during exercise using saline contrast echocardiography. Succinylated gelatin has been used to detect patent intrapulmonary arteriovenous anastomoses (La Gerche *et al.*, 2010) but there are no data suggesting that this contrast agent is superior to using air and saline alone. Given the fact that additives may increase the risk

of adverse reactions in research subjects, the use of saline and air seems to be the best choice (Bommer *et al.*, 1984; Mulvagh *et al.*, 2008). Commercially available contrast agents contain microbubbles small enough to transit pulmonary capillaries and opacify the left ventricle. By design these agents opacify all four cardiac chambers preventing the viewer from detecting an intracardiac shunt. They are also specifically contraindicated for use when there is a known or suspected intracardiac shunt (Mulvagh *et al.*, 2008).

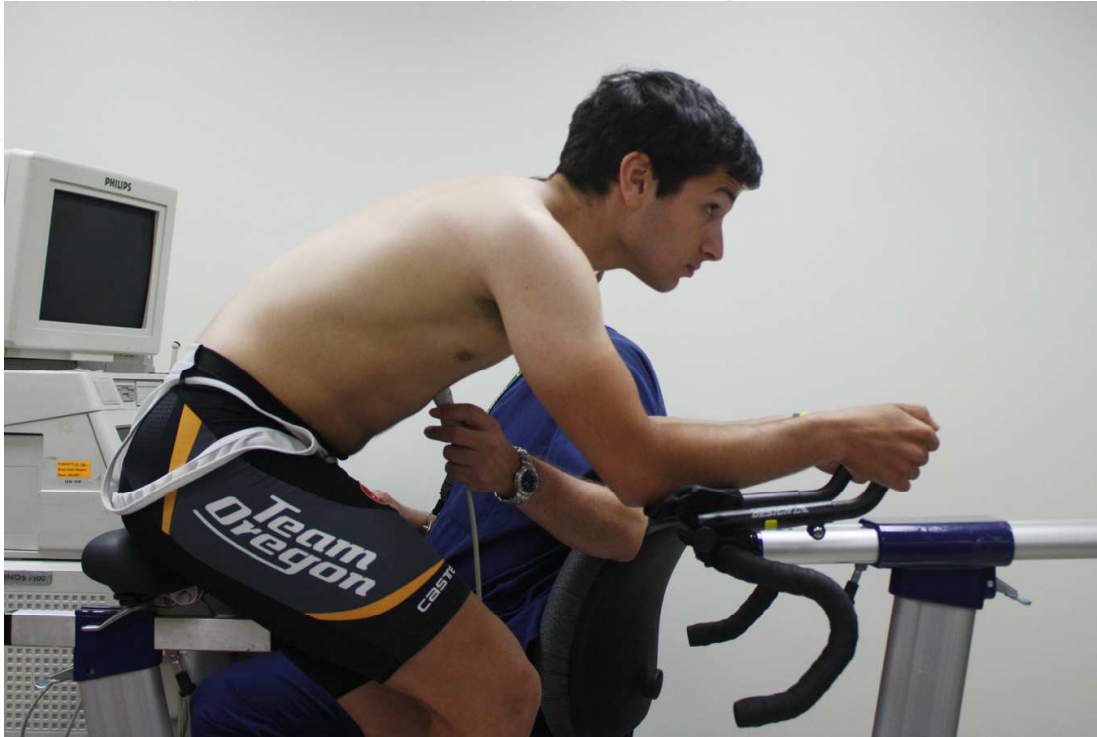

Fig. 3. Subject in the “aerobar” position. Note aerobars on the cycle ergometer with subject in the forward leaning position.

It has been demonstrated that exercise opens intrapulmonary arteriovenous anastomoses that were closed at rest in healthy humans (Eldridge *et al.*, 2004; Stickland *et al.*, 2004; La Gerche *et al.*, 2010; Elliott *et al.*, 2011a). Furthermore, increasing exercise intensity increases the amount of saline contrast that is detected in the left ventricle, which is indicative of increased intrapulmonary shunting (Stickland *et al.*, 2004). It has been suggested that blood flowing through intrapulmonary arteriovenous anastomoses is acting as a “true” shunt (Stickland & Lovering, 2006; Lovering *et al.*, 2009a), however the physiologic role of these vessels remains highly controversial and as of yet, unproven (Hopkins *et al.*, 2009).

The effect of inspired oxygen concentration is another intervention that has been shown to have a modulatory effect on the patency of intrapulmonary arteriovenous anastomoses. We have demonstrated that breathing hyperoxic gas closes intrapulmonary arteriovenous anastomoses at rest and during exercise (Elliott *et al.*, 2011a). This may play a role in detecting intrapulmonary arteriovenous anastomoses at rest in patients with lung disease or healthy human subjects (Elliott *et al.*, 2011b). Conversely, we have also demonstrated that breathing hypoxic gas mixtures will open intrapulmonary arteriovenous anastomoses in healthy humans at rest and will increase the degree of shunting during exercise compared to



exercise in normoxia (Lovering *et al.*, 2008a; Elliott *et al.*, 2011a) (Figure 4). Since arterial hypoxemia is associated with patent intrapulmonary arteriovenous anastomoses in healthy humans, this may have an effect on patient populations with arterial hypoxemia (see below).

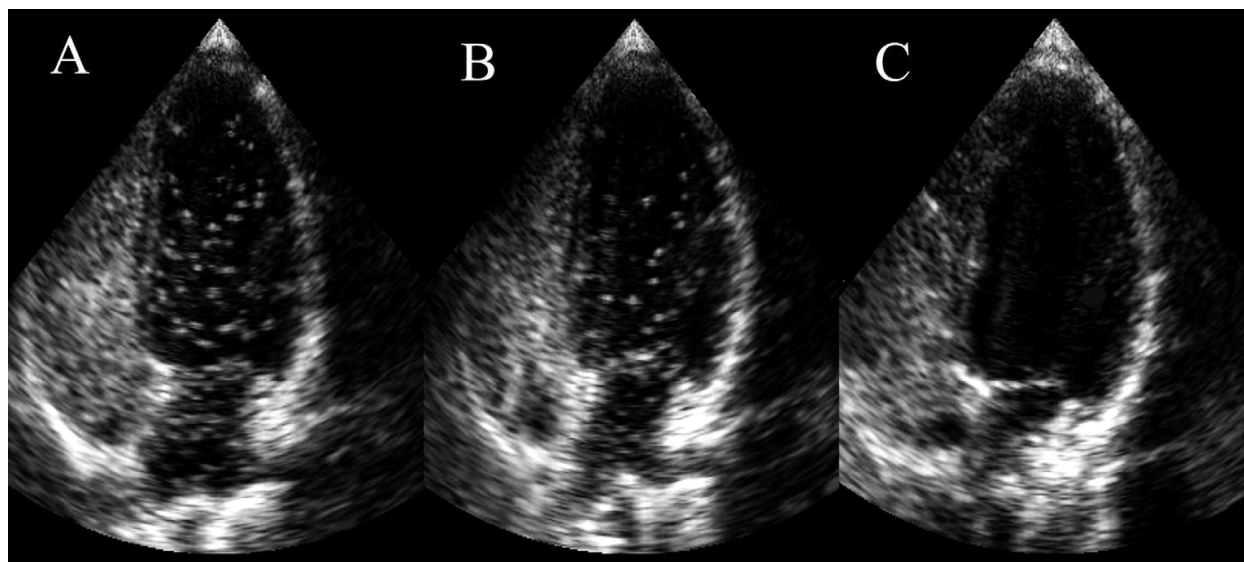


Fig. 4. Echocardiograms during exercise in hypoxia (A), normoxia (B) and hyperoxia (C). Note left side contrast is greatest in hypoxia (A) but is absent during in hyperoxia (C).

Of note, it has been argued that changing inspired oxygen tension may affect the external partial pressure environment (i.e.  $PO_2$  of the blood) such that breathing hyperoxia may shorten the lifespan of saline contrast bubbles whereas hypoxia may lengthen the life span of saline contrast bubbles (Van Liew & Vann, 2010). Although this argument follows mathematical modeling and theoretical calculations, when this question was directly addressed *in vivo* using various inspired gases and saline contrast bubbles made of 100% carbon dioxide, 100% nitrogen, 100% helium, 100% room air or 100% oxygen, it was found that there was no effect on either the bubble score or the sensitivity of the technique (Elliott *et al.*, 2011a). Thus, any effect on inspired oxygen tension is likely a direct effect on the pulmonary vasculature rather than an effect on *in vivo* gas bubble dynamics. These data are further supported by the fact that ventilating dogs with low and high oxygen mixtures results in increased and decreased intrapulmonary shunt fractions, respectively (Niden & Aviado, 1956). In these studies the authors detected right-to-left shunting using solid microspheres (60 to 420  $\mu\text{m}$  in diameter), which clearly would not be affected by altered *in vivo* external partial pressure environments.

## 5.2 Research using echocardiography in patients with lung disease at rest

Special considerations are suggested when examining certain patient populations. For example, patients with chronic obstructive pulmonary disease (COPD) who also have arterial hypoxemia are likely to have patent intrapulmonary right-to-left shunts at rest (Miller *et al.*, 1984; Dansky *et al.*, 1992). Preliminary work in our lab using saline contrast echocardiography has detected these pathways in subjects with COPD who do not have a PFO (Figure 5). Interestingly, administration of supplemental oxygen to these subjects with COPD closes intrapulmonary pathways suggesting that they are actively regulated.

Other diseases associated with arterial hypoxemia such as hepatopulmonary syndrome and hereditary hemorrhagic telangiectasia are known to have arteriovenous malformations that will allow for the transpulmonary passage of saline contrast bubbles under resting conditions (Woods & Patel, 2006). Thus, patients with underlying lung diseases and arterial hypoxemia, may desaturate further as a result of the opening of hypoxia-induced intrapulmonary arteriovenous anastomoses. It is unknown whether or not hyperoxia would close intrapulmonary arteriovenous anastomoses in these patients, but data from healthy humans suggests that it would be possible (Lovering *et al.*, 2008b; Elliott *et al.*, 2011a).

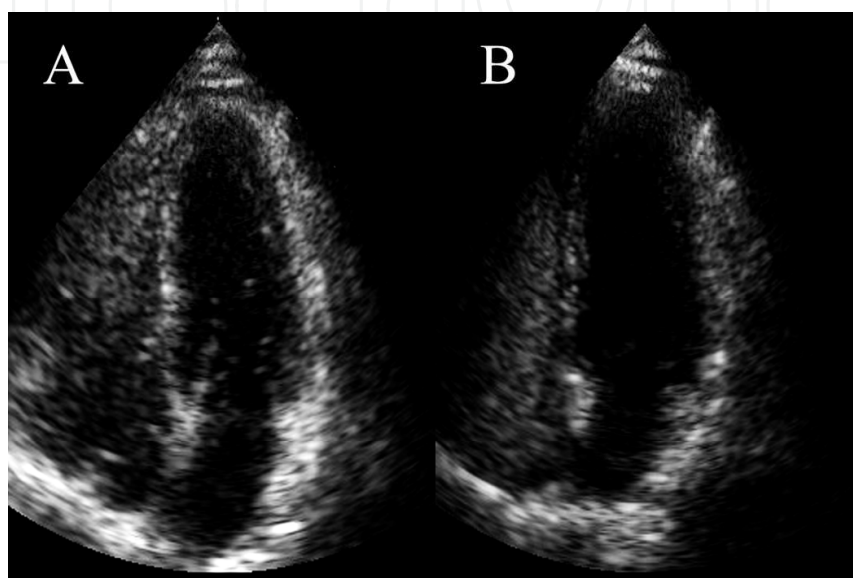


Fig. 5. Intrapulmonary arteriovenous anastomoses in COPD subjects. A) left side contrast in subject at rest with arterial saturation of 94%, B) absence of left side contrast in the same subject breathing 100% O<sub>2</sub> with a saturation of 100%.

## 6. Conclusion

In conclusion, saline contrast echocardiography is a non-invasive technique that can be used to detect right-to-left shunts in healthy humans and in various patient populations. Timing of the appearance of saline contrast bubbles in the left heart can be used to differentiate intracardiac shunts (e.g. PFOs) from intrapulmonary shunts (e.g. PAVMs) in subjects who do not have both. Special considerations should be taken with the interpretation of the echocardiograms depending on the subject's body positioning, the fraction of inspired oxygen the subject is breathing and the disease status of the patient.

## 7. Acknowledgement

We thank Kara M. Beasley, BS for assistance with preparation of figures. Andrew Lovering thanks John Hokanson, MD for introducing him to saline contrast echocardiography. Financial support: Oregon Health & Science University Medical Research Foundation Grant, American Lung Association in Oregon Research Grant, University of Oregon/Peace Health Oregon Region Translational Research Award, American Physiological Society's Giles F. Filley Memorial Award for Excellence in Respiratory Physiology & Medicine.



## 8. References


- Barzilai B, Waggoner AD, Spessert C, Picus D & Goodenberger D. (1991). Two-dimensional contrast echocardiography in the detection and follow-up of congenital pulmonary arteriovenous malformations. *Am J Cardiol* 68, 1507-1510.
- Belkin RN, Pollack BD, Ruggiero ML, Alas LL & Tatini U. (1994). Comparison of transesophageal and transthoracic echocardiography with contrast and color flow Doppler in the detection of patent foramen ovale. *American heart journal* 128, 520-525.
- Bommer WJ, Shah PM, Allen H, Meltzer R & Kisslo J. (1984). The safety of contrast echocardiography: report of the Committee on Contrast Echocardiography for the American Society of Echocardiography. *J Am CollCardiol* 3, 6-13.
- Carpenter DA, Ford AL & Lee JM. (2010). Patent foramen ovale and stroke: Should PFOs be closed in otherwise cryptogenic stroke? *Curr Atheroscler Rep* 12, 251-258.
- Cottin V, Plauchu H, Bayle JY, Barthelet M, Revel D & Cordier JF. (2004). Pulmonary arteriovenous malformations in patients with hereditary hemorrhagic telangiectasia. *American journal of respiratory and critical care medicine* 169, 994-1000.
- Dansky HM, Schwinger ME & Cohen MV. (1992). Using contrast material-enhanced echocardiography to identify abnormal pulmonary arteriovenous connections in patients with hypoxemia. *Chest* 102, 1690-1692.
- De Castro S, Cartoni D, Fiorelli M, Rasura M, Anzini A, Zanette EM, Beccia M, Colonnese C, Fedele F, Fieschi C & Pandian NG. (2000). Morphological and functional characteristics of patent foramen ovale and their embolic implications. *Stroke; a journal of cerebral circulation* 31, 2407-2413.
- Eldridge MW, Dempsey JA, Haverkamp HC, Lovering AT & Hokanson JS. (2004). Exercise-induced intrapulmonary arteriovenous shunting in healthy humans. *J Appl Physiol* 97, 797-805.
- Elliott JE, Choi Y, Laurie SS, Yang X, Gladstone IM & Lovering AT. (2011a). Effect of initial gas bubble composition on detection of inducible intrapulmonary arteriovenous shunt during exercise in normoxia, hypoxia, or hyperoxia. *Journal of Appl Physiol* 110, 35-45.
- Elliott JE, Nigam SM, Laurie SS, Yang X, Beasley KM, Goodman RD, Gladstone IM & Lovering AT. (2011b). Pulmonary arteriovenous malformations or intrapulmonary arteriovenous anastomoses in healthy humans at rest. Unpublished Observations.
- Feigenbaum H. (2005). *Feigenbaum's Echocardiography*. Lippincott Williams & Wilkins, Philadelphia.
- Fisher DC, Fisher EA, Budd JH, Rosen SE & Goldman ME. (1995). The incidence of patent foramen ovale in 1,000 consecutive patients. A contrast transesophageal echocardiography study. *Chest* 107, 1504-1509.
- Gonzalez-Alujas T, Evangelista A, Santamarina E, Rubiera M, Gomez-Bosch Z, Rodriguez-Palomares JF, Avegliano G, Molina C, Alvarez-Sabin J & Garcia-Dorado D. (2011). Diagnosis and quantification of patent foramen ovale. Which is the reference technique? Simultaneous study with transcranial Doppler, transthoracic and transesophageal echocardiography. *Rev Esp Cardiol* 64, 133-139.
- Goodman M, Porter CA, Czelusniak J, Page SL, Schneider H, Shoshani J, Gunnell G & Groves CP. (1998). Toward a phylogenetic classification of Primates based on DNA evidence complemented by fossil evidence. *MolPhylogenetEvol* 9, 585-598.

- Goyal SK, Punnam SR, Verma G & Ruberg FL. (2008). Persistent left superior vena cava: a case report and review of literature. *Cardiovasc Ultrasound* 6, 50.
- Hagen PT, Scholz DG & Edwards WD. (1984). Incidence and size of patent foramen ovale during the first 10 decades of life: an autopsy study of 965 normal hearts. *Mayo ClinProc* 59, 17-20.
- Homma S, Di Tullio MR, Sacco RL, Sciacca RR, Smith C & Mohr JP. (1997). Surgical closure of patent foramen ovale in cryptogenic stroke patients. *Stroke* 28, 2376-2381.
- Hopkins SR, Olfert IM & Wagner PD. (2009). Last Word on Point:Counterpoint: Exercise-induced intrapulmonary shunting is imaginary vs. real. *J Appl Physiol* 107, 1002.
- Khurshid I & Downie GH. (2002). Pulmonary arteriovenous malformation. *Postgrad Med J* 78, 191-197.
- La Gerche A, Macisaac AI, Burns AT, Mooney DJ, Inder WJ, Voigt JU, Heidebuchel H & Prior DL. (2010). Pulmonary transit of agitated contrast is associated with enhanced pulmonary vascular reserve and right ventricular function during exercise. *J Appl Physiol*.
- Lam YY, Yu CM, Zhang Q, Yan BP & Yip GW. (2010). Enhanced detection of patent foramen ovale by systematic transthoracic saline contrast echocardiography. *International journal of cardiology*.
- Lamy C, Giannesini C, Zuber M, Arquizan C, Meder JF, Trystram D, Coste J & Mas JL. (2002). Clinical and imaging findings in cryptogenic stroke patients with and without patent foramen ovale: the PFO-ASA Study. Atrial Septal Aneurysm. *Stroke* 33, 706-711.
- Laurie SS, Yang X, Elliott JE, Beasley KM & Lovering AT. (2010). Hypoxia-induced intrapulmonary arteriovenous shunting at rest in healthy humans. *J Appl Physiol* 109, 1072-1079.
- Lee WL, Graham AF, Pugash RA, Hutchison SJ, Grande P, Hyland RH & Faughnan ME. (2003). Contrast echocardiography remains positive after treatment of pulmonary arteriovenous malformations. *Chest* 123, 351-358.
- Liu FY, Wang MQ, Fan QS, Duan F, Wang ZJ & Song P. (2010). Endovascular embolization of pulmonary arteriovenous malformations. *Chin Med J (Engl)* 123, 23-28.
- Lovering AT, Eldridge MW & Stickland MK. (2009a). Counterpoint: Exercise-induced intrapulmonary shunting is real. *J Appl Physiol* 107, 994-997.
- Lovering AT, Elliott JE, Beasley KM & Laurie SS. (2010). Pulmonary pathways and mechanisms regulating transpulmonary shunting into the general circulation: An update. *Injury* 41S2, S16-S23.
- Lovering AT, Haverkamp HC, Romer LM, Hokanson JS & Eldridge MW. (2009b). Transpulmonary passage of 99mTc macroaggregated albumin in healthy humans at rest and during maximal exercise. *J Appl Physiol* 106, 1986-1992.
- Lovering AT, Romer LM, Haverkamp HC, Pegelow DE, Hokanson JS & Eldridge MW. (2008a). Intrapulmonary shunting and pulmonary gas exchange during normoxic and hypoxic exercise in healthy humans. *J ApplPhysiol* 104, 1418-1425.
- Lovering AT, Stickland MK, Amann M, Murphy JC, O'Brien MJ, Hokanson JS & Eldridge MW. (2008b). Hyperoxia prevents exercise-induced intrapulmonary arteriovenous shunt in healthy humans. *J Physiol* 586, 4559-4565.

- Lovering AT, Stickland MK, Amann M, O'Brien MJ, Hokanson JS & Eldridge MW. (2011). Effect of a patent foramen ovale on pulmonary gas exchange efficiency at rest and during exercise. *Journal of applied physiology* 110, 1354-1361.
- Lovering AT, Stickland MK, Kelso AJ & Eldridge MW. (2007). Direct demonstration of 25- and 50-  $\mu$ m arteriovenous pathways in healthy human and baboon lungs. *Am J Physiol Heart CircPhysiol* 292, H1777-H1781.
- Meltzer RS, Sartorius OE, Lancee CT, Serruys PW, Verdouw PD, Essed CE & Roelandt J. (1981). Transmission of ultrasonic contrast through the lungs. *Ultrasound MedBiol* 7, 377-384.
- Meltzer RS, Tickner EG & Popp RL. (1980a). Why do the lungs clear ultrasonic contrast? *Ultrasound Med Biol* 6, 263-269.
- Meltzer RS, Tickner EG, Sahines TP & Popp RL. (1980b). The source of ultrasound contrast effect. *J ClinUltrasound* 8, 121-127.
- Miller WC, Heard JG & Unger KM. (1984). Enlarged pulmonary arteriovenous vessels in COPD. Another possible mechanism of hypoxemia. *Chest* 86, 704-706.
- Movsowitz C, Podolsky LA, Meyerowitz CB, Jacobs LE & Kotler MN. (1992). Patent foramen ovale: a nonfunctional embryological remnant or a potential cause of significant pathology? *J Am Soc Echocardiogr* 5, 259-270.
- Mulder BJ. (2010). Changing demographics of pulmonary arterial hypertension in congenital heart disease. *Eur Respir Rev* 19, 308-313.
- Mulvagh SL, Rakowski H, Vannan MA, Abdelmoneim SS, Becher H, Bierig SM, Burns PN, Castello R, Coon PD, Hagen ME, Jollis JG, Kimball TR, Kitzman DW, Kronzon I, Labovitz AJ, Lang RM, Mathew J, Moir WS, Nagueh SF, Pearlman AS, Perez JE, Porter TR, Rosenbloom J, Strachan GM, Thanigaraj S, Wei K, Woo A, Yu EH & Zoghbi WA. (2008). American Society of Echocardiography Consensus Statement on the Clinical Applications of Ultrasonic Contrast Agents in Echocardiography. *Journal of the American Society of Echocardiography : official publication of the American Society of Echocardiography* 21, 1179-1201; quiz 1281.
- Nanthakumar K, Graham AT, Robinson TI, Grande P, Pugash RA, Clarke JA, Hutchison SJ, Mandzia JL, Hyland RH & Faughnan ME. (2001). Contrast echocardiography for detection of pulmonary arteriovenous malformations. *Am Heart J* 141, 243-246.
- Niden AH & Aviado DM, Jr. (1956). Effects of pulmonary embolism on the pulmonary circulation with special reference to arteriovenous shunts in the lung. *CircRes* 4, 67-73.
- Otto C. (2004). *Textbook of Clinical Echocardiography*. Saunders, Philadelphia.
- Pellikka PA, Nagueh SF, Elhendy AA, Kuehl CA & Sawada SG. (2007). American Society of Echocardiography recommendations for performance, interpretation, and application of stress echocardiography. *Journal of the American Society of Echocardiography : official publication of the American Society of Echocardiography* 20, 1021-1041.
- Petty GW, Khandheria BK, Chu CP, Sicks JD & Whisnant JP. (1997). Patent foramen ovale in patients with cerebral infarction. A transesophageal echocardiographic study. *Arch Neurol* 54, 819-822.
- Purvis A. (1995). A composite estimate of primate phylogeny. *PhilosTransRSocLond B BiolSci* 348, 405-421.

- Stewart CB & Disotell TR. (1998). Primate evolution - in and out of Africa. *CurrBiol* 8, R582-R588.
- Stickland MK & Lovering AT. (2006). Exercise-induced intrapulmonary arteriovenous shunting and pulmonary gas exchange. *ExercSport SciRev* 34, 99-106.
- Stickland MK, Welsh RC, Haykowsky MJ, Petersen SR, Anderson WD, Taylor DA, Bouffard M & Jones RL. (2004). Intra-pulmonary shunt and pulmonary gas exchange during exercise in humans. *J Physiol* 561, 321-329.
- Sun XG, Hansen JE, Oudiz RJ & Wasserman K. (2002). Gas exchange detection of exercise-induced right-to-left shunt in patients with primary pulmonary hypertension. *Circulation* 105, 54-60.
- Tobin CE. (1966). Arteriovenous shunts in the peripheral pulmonary circulation in the human lung. *Thorax* 21, 197-204.
- Tobin CE & Zariquiey MO. (1950). Arteriovenous shunts in the human lung. *Proc Soc Exp Biol Med* 75, 827-829.
- van Gent MW, Post MC, Luermans JG, Snijder RJ, Westermann CJ, Plokker HW, Overtoom TT & Mager JJ. (2009). Screening for pulmonary arteriovenous malformations using transthoracic contrast echocardiography: a prospective study. *Eur Respir J* 33, 85-91.
- Van Liew HD & Vann RD. (2010). Sonic echocardiography: what does it mean when there are no bubbles in the left ventricle? *J Appl Physiol* 110, 295; author reply 296-7.
- von Hayek H. (1940). über einen Kurzschlusskreislauf (arterio-venöse Anastomosen) in der menschlichen Lunge. *ZtschrftAnatuEntwklsg* 110, 412-422.
- Waggoner AD, Ehler D, Adams D, Moos S, Rosenbloom J, Gresser C, Perez JE & Douglas PS. (2001). Guidelines for the cardiac sonographer in the performance of contrast echocardiography: recommendations of the American Society of Echocardiography Council on Cardiac Sonography. *Journal of the American Society of Echocardiography : official publication of the American Society of Echocardiography* 14, 417-420.
- Whyte MK, Peters AM, Hughes JM, Henderson BL, Bellingan GJ, Jackson JE & Chilvers ER. (1992). Quantification of right to left shunt at rest and during exercise in patients with pulmonary arteriovenous malformations. *Thorax* 47, 790-796.
- Woods TD, Harmann L, Purath T, Ramamurthy S, Subramanian S, Jackson S & Tarima S. (2010). Small and Moderate Size Right-to-Left Shunts Identified By Saline Contrast Echocardiography Are Normal and Unrelated To Migraine Headache. *Chest*.
- Woods TD & Patel A. (2006). A critical review of patent foramen ovale detection using saline contrast echocardiography: when bubbles lie. *J Am SocEchocardiogr* 19, 215-222.
- Yang WJ. (1971). Dynamics of gas bubbles in whole blood and plasma. *J Biomech* 4, 119-125.
- Yang WJ, Echigo R, Wotton DR & Hwang JB. (1971a). Experimental studies of the dissolution of gas bubbles in whole blood and plasma. I. Stationary bubbles. *J Biomech* 4, 275-281.
- Yang WJ, Echigo R, Wotton DR & Hwang JB. (1971b). Experimental studies of the dissolution of gas bubbles in whole blood and plasma. II. Moving bubbles or liquids. *J Biomech* 4, 283-288.





## **Applied Aspects of Ultrasonography in Humans**

Edited by Prof. Philip Ainslie

ISBN 978-953-51-0522-0

Hard cover, 190 pages

**Publisher** InTech

**Published online** 25, April, 2012

**Published in print edition** April, 2012

Written by international experts, this publication provides the reader with the present knowledge and future research directions of diagnostic and therapeutic ultrasound and spectroscopy. Focused topics include Duplex ultrasound, transcranial color Duplex, MRA guided Doppler ultrasonography and near-infrared spectroscopy. New directions in the use and application of transcranial and color Duplex ultrasound are provided, as well as the use of ultrasound and arterial stiffness for measuring human vascular health and circulatory control. Novel use of ultrasound for the detection of intra-cardiac and intra-pulmonary shunts is also described along with its utility for the assessment of gastric regulation and emptying.

### **How to reference**

In order to correctly reference this scholarly work, feel free to copy and paste the following:

Andrew T. Lovering and Randall D. Goodman (2012). Detection of Intracardiac and Intrapulmonary Shunts at Rest and During Exercise Using Saline Contrast Echocardiography, Applied Aspects of Ultrasonography in Humans, Prof. Philip Ainslie (Ed.), ISBN: 978-953-51-0522-0, InTech, Available from: <http://www.intechopen.com/books/applied-aspects-of-ultrasonography-in-humans/detection-of-intracardiac-and-intrapulmonary-shunts-at-rest-and-during-exercise-and-stress-using-ech>

**INTECH**  
open science | open minds

### **InTech Europe**

University Campus STeP Ri  
Slavka Krautzeka 83/A  
51000 Rijeka, Croatia  
Phone: +385 (51) 770 447  
Fax: +385 (51) 686 166  
[www.intechopen.com](http://www.intechopen.com)

### **InTech China**

Unit 405, Office Block, Hotel Equatorial Shanghai  
No.65, Yan An Road (West), Shanghai, 200040, China  
中国上海市延安西路65号上海国际贵都大饭店办公楼405单元  
Phone: +86-21-62489820  
Fax: +86-21-62489821



© 2012 The Author(s). Licensee IntechOpen. This is an open access article distributed under the terms of the [Creative Commons Attribution 3.0 License](#), which permits unrestricted use, distribution, and reproduction in any medium, provided the original work is properly cited.

IntechOpen

IntechOpen