

We are IntechOpen, the world's leading publisher of Open Access books Built by scientists, for scientists

4,800

Open access books available

122,000

International authors and editors

135M

Downloads

Our authors are among the

154

Countries delivered to

TOP 1%

most cited scientists

12.2%

Contributors from top 500 universities

**WEB OF SCIENCE™**Selection of our books indexed in the Book Citation Index
in Web of Science™ Core Collection (BKCI)

Interested in publishing with us?
Contact book.department@intechopen.com

Numbers displayed above are based on latest data collected.
For more information visit www.intechopen.com



Why, When and How Should Atrial Septal Defects Be Closed in Adults

P. Syamasundar Rao

*University of Texas at Houston Medical School, Houston, TX,
USA*

1. Introduction

The most common defects in the atrial septum are ostium secundum, ostium primum and sinus venosus atrial septal defects (ASDs) and patent foramen ovale. The management of ostium primum and sinus venosus defects is by surgery because of associated abnormalities, namely, cleft in the mitral valve causing mitral regurgitation in ostium primum defects and partial anomalous pulmonary venous connection in sinus venosus defects and is addressed in Chapter 1. Patent foramen ovale (PFO) in relation to presumed paradoxical embolism, platypnea-orthodeoxia syndrome, migraine, decompression illness and others may also require closure and the considerations for closure of such PFOs are different than those of closure of ostium secundum ASDs and some of these are discussed in other chapters in this book and will not be addressed in this chapter. In this chapter only ostium secundum ASDs in adult subjects will be discussed; I will address issues related to why, when and how should atrial septal defects be closed in these subjects. The methods of transcatheter closure in adults will also be reviewed as are the approaches to occlude complex forms of ASD.

2. Why should atrial septal defects be closed in adults?

In the past it was generally thought that closure ASDs in adult subjects is not necessary if they are not symptomatic. Some early studies (Ward 1994, Gatzoulis et al 1996, Webb 2001) suggested that there is no major benefit if surgical closure is performed in adulthood. Based on more recent analysis however, it would appear that the ASDs should be closed as and when they are identified. The purpose of this section of this chapter is to present evidence that the ASDs in adults should be closed.

2.1 Evidence in favor of closing ASDs in adults

In this section I will review some of the published evidence supporting closure of ASDs in all adults

2.1.1 Complications in unrepaired ASD patients

In a follow-up study (Rosas et al 2004) of 200 patients older than 40 years (49 ± 9 years) with unrepaired ASD for 2 to 22 years, it was found that 37 (18.5%) had major events, namely

heart failure in seven, sudden death in five, severe pulmonary infection in 13, embolism in five, stroke in four and miscellaneous complications in three. In addition, more than half of the patients had dyspnea at follow-up evaluation. Predictors of complications were analyzed and age at presentation, elevated pulmonary artery pressures and O₂ saturation less than 80% were found to be associated with complications. These data suggest that major cardiovascular events are likely to occur in older adult patients with unrepaired ASD.

2.1.2 Safety and efficacy of surgical closure

Horvath et al (1991) examined safety and efficacy of surgical closure of ASDs. In this study, surgical closure was performed in 166 patients with a mean age of 44 years who had an average pulmonary to systemic flow ratio (Q_p:Q_s) of 3.0:1.0. The operative mortality was 1.2% (two deaths). The remaining patients were followed for a mean of 7.5 years. The overall survival and event-free survival rates were 98% and 97% at five years, respectively. Similarly, ten-year overall (94%) and event-free (92%) survival rates were high. Their (Horvath et al 1991) conclusion was that surgical closure is safe and effective with high event-free survival rates.

Konstantinides et al (1995) made a comparison of surgical closure with medical follow-up without surgery. One hundred-seventy-nine patients older than 40 years were examined; 84 of these had surgical closure while 95 had no surgery. The follow-up duration for both groups was 10 years. The actuarial 10-Year survival rate was 95% for the surgery group and 84% for no surgery group. In addition surgery also appears to have prevented deterioration of NYHA functional class. Based on these data the authors (Konstantinides et al 1995) conclude that surgical repair of ASD in adult subjects increases long-term survival and decreases functional deterioration when compared to medical therapy (no surgery).

2.1.3 Effect of ASD closure on cardiac function

Myocardial performance index (MPI), a Doppler-derived non-geometric measure of ventricular function, has been used to for quantitative assessment of ventricular function in patients with congenital heart disease both in adults and children; this measure appears to be relatively independent of changes in preload and afterload (Eidem 2000). Right ventricular (RV) MPI did not improve following surgical closure of ASD despite relief of RV volume overload (Eidem 2000). This was attributed to adverse effect of cardiopulmonary bypass on ventricular function. Salehian et al (2005) evaluated twenty-five patients at a mean age 46 years prior to and 3 months (mean) after device closure of ASD. Right ventricular MPI improved from 0.35 ± 0.14 to 0.28 ± 0.09 ($p = 0.004$) while left ventricular MPI enhanced from 0.37 ± 0.12 to 0.31 ± 0.11 ($p = 0.04$) (Figure 1). These authors (Salehian et al 2005) conclude that ASD closure improves cardiac function.

2.1.4 Effect of ASD closure on functional capacity

Improvement in functional capacity following ASD closure was studied by Brochu et al (2002). Thirty-seven patients with a mean age of 49 years whose mean Q_p:Q_s was 2:1 were evaluated. The VO₂ max was measured and NYHA classification assessed prior to and 6 months after ASD closure. They found that VO₂ max improved from 23 ± 6 to 27 ± 7 ($p < 0.0001$) following ASD closure. Fifteen out of 37 patients were in NYHA Class I prior to

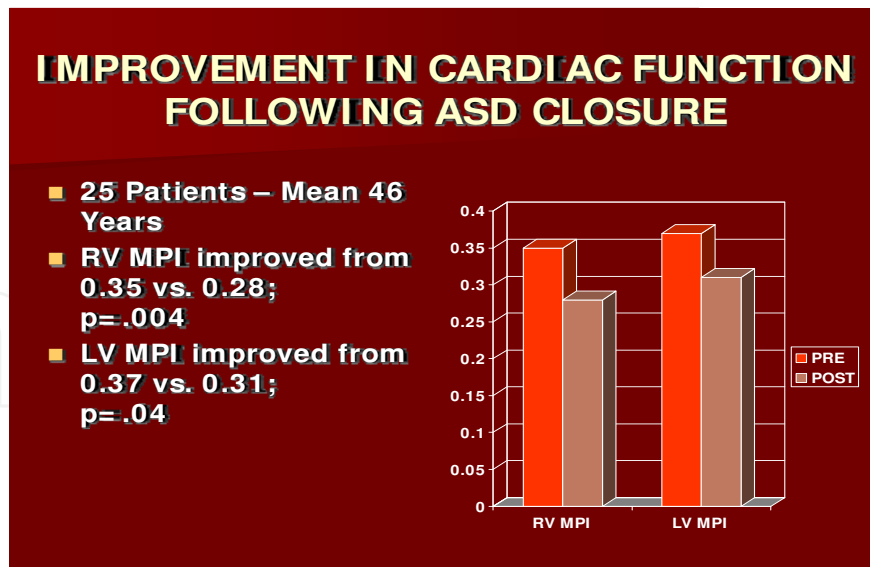


Fig. 1. Bar diagram demonstrating improvement in right ventricular (RV) and left ventricular (LV) myocardial performance index (MPI) following closure of atrial septal defect (ASD). PRE, before atrial septal defect closure; POST, three months after closure (constructed from the data of Salehian et al 2005).

surgery whereas 35 out of 37 patients were in NYHA Class I ($p < 0.0001$) six months after surgical closure. Thus, these authors' data demonstrated improvement in functional capacity following ASD closure (Brochu et al 2002).

2.2 Summary of why should atrial septal defects should be closed in adults

Based on review of the above and other reports, I conclude that untreated ASD patients tend to have decreased event-free survival rates when compared to normal population and surgical closure is safe and effective with high event-free survival rates. ASD closure also prevents functional deterioration, improves cardiac function and increases functional capacity. Consequently all adult patients with ASD should undergo closure of ASD.

3. When should atrial septal defects be closed in adults?

Murphy et al (1990) examined the effect of age at surgical closure of ASD. Patients who had surgical closure of ASD, performed between 1956 and 1960 at Mayo Clinic, were studied; they followed 123 patients and compared their actuarial survival rates with those of normal population. In the groups of patients who had surgery after 24 years of age, the actuarial survival rates are lower (Figure 2). When surgery is performed prior to 24 years of age, there was no significant difference in survival rates. The earlier the surgery was performed the better were the 27-year survival rates (Figure 2).

Based on these data Murphy concludes that early intervention may be beneficial; earlier the closure, the better is the long-term outlook. Consequently, it is prudent to close hemodynamically significant ASDs in all adults. Since there is no advantage in waiting beyond 24 years of age, the closure should be performed at the time of identification of the case.

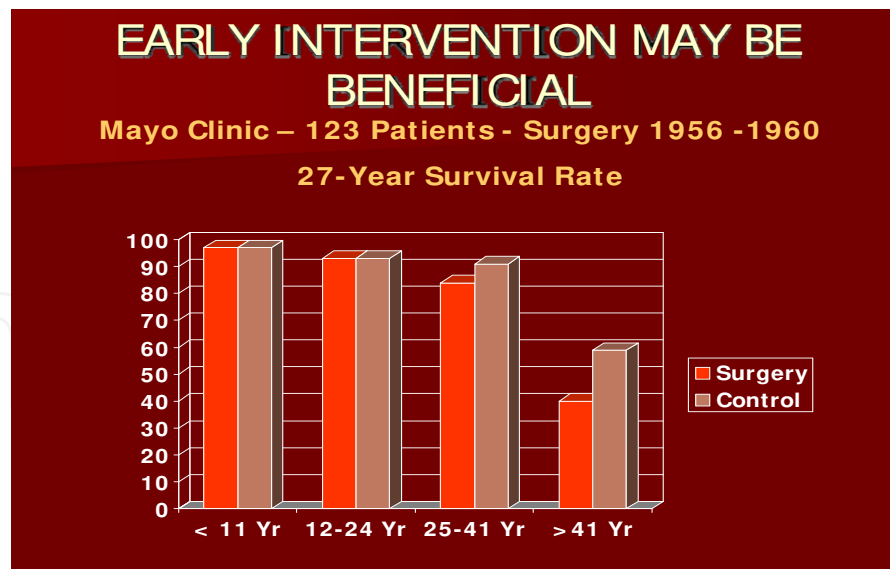


Fig. 2. Bar diagram (constructed from the data of Murphy et al 1990) depicting 27-year survival rates following closure of atrial septal defect by surgery; these data were compared with those of normal population. If surgery is performed prior to 24 years of age, there was no significant difference in survival rates. However, the survival rates are lower when surgical closure is performed later.

4. How should atrial septal defects be closed in adults

Following the introduction of cardiopulmonary bypass techniques for open heart surgery and the description of surgical closure of atrial septal defect (ASD) by Gibbon, Lillehei and Kirklin in 1950s, it rapidly became a standard form of treatment for atrial defects. The conventional treatment of choice of moderate and large defects until recently is surgical correction. Although surgical closure of ASDs is safe and effective with low mortality (Galal et al 1994, Pastorek et al 1994), the morbidity associated with sternotomy/thoracotomy is unavoidable. Consequently, substantial efforts have been made by the cardiology community to develop a non-surgical, catheter-based method of ASD occlusion. Since the initial description in mid 1970s by King & Mills and their associates (King and Mills 1974, Mills and King 1976, King et al 1976) of an atrial septal defect occluding device, a number of other devices, reviewed elsewhere (Chopra and Rao 2001, Rao 2003c) and in Chapter 1 of this book, were developed. However, Amplatzer Septal Occluder and HELEX are the only two devices approved for general clinical use by the US Food and Drug Administration (FDA) at the present time. Consequently, two methods of ASD closure, namely, surgical and transcatheter are now available.

4.1 Surgical vs. transcatheter closure

Studies, though limited in number, comparing surgical with device closure suggest similar effectiveness (Berger et al 1999, Du et al 2002, Durongpisitkul 2002, Bialkowski 2004). However, the device closure is less invasive, requires no cardio-pulmonary bypass. The device closure also appears to have less number of complications (10% vs. 31%), require less hospital stay (1 day vs. 4.3 days), and is less expensive (US \$ 11,000 vs. \$ 21,000) (Kim and Hijazi, 2002). The device closure techniques proved to be safe, cost-effective and favorably

compare with surgical closure (Berger et al 1999, Du et al 2002, Kim and Hijazi 2002, Durongpisitkul 2002, Bettencourt et al 2003, Bialkowski 2004). Transcatheter occlusion of ASDs using various devices (Rao 2003a) is now an established practice in most centers providing state of the art care to patients with heart disease.

4.2 Surgical closure

When surgical closure is contemplated, a median sternotomy or a right sub mammary incision is made under general anesthesia. The aorta and vena cavae are cannulated and the patient is placed on cardiopulmonary bypass and right atriotomy is performed. The defect is exposed and closed either by approximating the defect margins with suture material or by using a pericardial patch, depending upon the size of the defect.

However, at the present time, surgical repair is largely reserved for ASDs with poor septal rims in which the interventional cardiologist opines that defect is difficult to close with trans-catheter methodology or was unsuccessful in closing the defect. If intra-cardiac repair of other defects is contemplated, surgical closure of ASD could also be performed at the same time.

4.3 Transcatheter closure

A number of devices are available to the interventional cardiologist for closure of ASD, but selection of an appropriate device is difficult because of lack of randomized clinical trials. Some studies (Formigari et al 1998, Walsh et al 1999, Sievert et al 1999, Keppeir 1999, Godart et al 2000, Butera et al 2004) compared the results of two or more devices, as and when the new devices became available. But, these studies are neither randomized nor blinded in their design and are unlikely to shed any more light than feasibility, safety and effectiveness studies of single devices. Given the current economical, ethical and medical considerations, a prospective randomized clinical trial utilizing all the eligible devices may not be possible. Therefore, selection of the device has largely been based on results of clinical trials conducted separately by the inventor or manufacturer of the device. I have carefully compared (Rao 1998a, Rao 1998b, Rao 2000, Rao 2003c) the implantation feasibility (ratio of implantations vs. patients taken to the catheterization laboratory with the intent to occlude), percentage of device dislodgements/miss-placements/embolizations, percent of patients with effective occlusion and re-intervention-free rates during follow-up; these results were tabulated elsewhere (Rao 2000, Rao 2003c). These comparisons revealed that these parameters are similar and comparable for most, if not all devices that I had the opportunity to evaluate. While the feasibility, safety and effectiveness are most important, availability, cost, size of the delivery sheath and other factors should also be considered in the process of device selection.

Of the devices tabulated in the prior publications (Rao 2000, Rao 2003c) and others that entered clinical trials since those reviews (see chapter 1), some devices were discontinued, shelved or withdrawn because of different reasons and some others continue to be in clinical trials either within or outside the US. Amplatzer (AGA Medical Corp., Golden Valley, MN) and HELEX (W.L. Gore, Flagstaff, AZ) devices are the only devices approved by the FDA at the present time, for general clinical use for closure of the ASDs.

The Amplatzer septal occluder is the most commonly used ASD closure device worldwide at the present time. The feasibility, safety and efficacy of device occlusion are based on self-

expandable, retrievable and re-positionable design of the device (Hamdan et al 2003). Even very large defects can be closed successfully with Amplatzer device using a variety of techniques (Nagm and Rao 2004, Rao 2007).

4.3.1 Protocol for ASD closure

4.3.1.1 Diagnosis and indications

After a clinical and echocardiographic diagnosis of moderate to large ostium secundum ASD is made, consideration for transcatheter closure should be given. Because of poor echo windows, most adult subjects require transesophageal echocardiography (TEE) to confirm the diagnosis, to quantify its size and define the septal rims. The indications for closure in adults are similar to those used in children (see Chapter 1) and are echocardiographic finding of right ventricular volume overloading and/or catheterization findings of Qp:Qs greater than 1.5:1.0. The reasons for closure of ASDs in children are prevention of pulmonary vascular obstructive disease in adulthood, to prevent arrhythmias and to prevent symptoms later in life. Additional reasons in adult subjects are to prevent heart failure, prevent functional deterioration, improve myocardial function and prevent paradoxical embolism.

4.3.1.2 Consent, catheterization and transesophageal or intracardiac echocardiography

Informed consent is obtained and cardiac catheterization is performed preparatory to transcatheter occlusion, at the same sitting. Right heart catheterization is undertaken percutaneously to confirm the clinical and echocardiographic diagnosis with particular attention to exclude partial anomalous pulmonary venous return. Some interventionalists perform left atrial cineangiogram in a left axial oblique view (30° LAO and 30° Cranial) with the catheter positioned in the right upper pulmonary vein at its junction with the left atrium while others do not routinely perform this angiogram. Transesophageal (TEE) or intracardiac (ICE) (Hijazi et al 2001) echocardiography to measure the size of the ASD, to visualize entry of all pulmonary veins into the left atrium and to examine the atrial septal rims is then undertaken.

4.3.1.3 Device description and implantation

Detailed descriptions of Amplatzer Septal Occluder and HELEX devices and their implantation were included in Chapter 1 of this book. Device placement protocol in adults is similar to that described for children and will not be detailed here except to state that the procedure is performed more often under ICE guidance in adults than in children and Clopidogrel 75 mg/day for the first 2 to 3 months after device implantation in addition to Aspirin 185 or 325 mg/Kg/day by mouth for six months is given in adults. However, discussion of some issues germane to adult subjects and device closure of complex ASDs will be included hereunder.

4.3.1.4 Precautions in elderly subjects prior to ASD closure

Reduced diastolic elasticity of the left ventricle is particularly seen in the elderly, causing restrictive filling of the left ventricle (Holzer et al 2005, Al-Hindi et al 2009). The ASD decompresses the left atrium and prevents high left ventricular end-diastolic pressure. The pop-off mechanism no longer exists after the ASD is closed. Consequently, the patients may

develop pulmonary edema and may require prolonged mechanical ventilation and inotropic support (Al-Hindi et al 2009). If the left atrial pressure is higher than 15 mmHg, temporary balloon occlusion of the defect for 10 to 15 minutes and re-measuring the left atrial pressure (or pulmonary artery wedge pressure) is recommended. If the pressure increases by more than 5 mmHg, the defect should not be closed at that sitting. But the patient should be treated with afterload reducing agents and diuretics for one to two weeks. The patient should be restudied following afore-mentioned treatment, measuring the left atrial pressures during balloon occlusion of the ASD. If the pressure does not increase by more than 5 mmHg, device occlusion of ASD may be undertaken. If the pressure continues to be high, a fenestrated device may have to be used (Peters et al 2006, Kretschmar et al 2010, MacDonald et al 2011, Kenny 2011).

4.3.1.5 Precautions in subjects with pulmonary hypertension

In some adult ASD patients pulmonary hypertension may be present. In these patients, a particular attention should be paid to calculate pulmonary vascular resistance. Pulmonary vascular resistance (PVR) may be calculated:

$$\text{PVR} = (\text{Mean PA pressure} - \text{Mean LA pressure}) / \text{Pulmonary blood flow index}$$

Where, PA and LA are pulmonary artery and left atrium respectively.

The calculated resistance is normally between 1 and 2 units and a resistance higher than 3.0 units is considered elevated. Marked elevation of the resistance (>8.0 units) contraindicates closure of the ASD. When the resistance is elevated, oxygen and other vasodilating agents, particularly Nitric oxide (NO) should be administered to demonstrate the reversibility. In addition, pulmonary arterial wedge angiography and sometimes, even lung biopsy may be necessary to determine the suitability for closure. Patients with calculated pulmonary vascular resistance less than 8 wood units with a Qp:Qs >1.5 are generally considered suitable candidates for ASD occlusion. In patients with increased pulmonary vascular resistance, if the calculated resistance drops to levels below 8 units after administering oxygen or other vasodilator agents (NO), the patient becomes a candidate for closure of ASD.

If the results of the testing of pulmonary vascular reactivity are marginal or the pulmonary vascular resistance remains elevated (>8.0 units) following vasodilator testing, a fenestrated Amplatzer device may be implanted across the ASD (Lammerset al 2007, Kretschmar et al 2010). The device will reduce the left-to-right shunt, thus removing the effect of continued increase in pulmonary blood flow and may result in improvement. Should the pulmonary vascular resistance continue to increase despite the fenestrated device closure, the fenestrations in the device will serve as a pop-off escape mechanism and maintain near normal cardiac index, though at the expense of arterial oxygen desaturation.

4.3.2 Approaches for closure of complex ASDs

Secundum ASDs located centrally in the atrial septum are found in only 24% of cases (Podnar et al 2001). These authors reviewed the characteristic of ASDs in 190 patients who had transcatheter or surgical repair and found deficient superior anterior rim in 42%, deficient inferior posterior rim in 10%, perforated aneurysm of the atrial septum in 8%, multiple defects in 7%, deficient inferior anterior and superior anterior rims in 3%, deficient

inferior posterior and posterior rims in 2% and deficient inferior anterior, superior posterior and coronary sinus rims in 1 % each. In another study complex ASDs were present in 40 (28%) of 143 patients (Pedra et al 2004). These authors arbitrarily defined complex anatomy as ASDs with stretched diameters larger than 26 mm with a deficient (<4 mm) rim in 23 (16%), two separate defects with a distance greater than 7 mm in 8 (5.6%), fenestrated atrial septum in 5 (3.5%) or redundant and hyper mobile (>10 mm) atrial septum in 4 (2.8%). In the ensuing paragraphs I will address how the complex ASDs can be closed by transcatheter methodology.

4.3.2.1 Large defects with deficient anterior-superior rim

Pedra et al (2004) defined large ASD as a defect with a stretched diameter > 26 mm. Similar definitions were used by most other cardiologists. While it goes without saying that large defects need large devices to close, the interventionalist needs to consider whether the left atrium could accommodate a large device and whether such a large device would interfere with atrio-ventricular valve function or obstruct vena caval or pulmonary venous blood return. Deficient anterosuperior rim is frequently encountered with large ASDs and indeed, in my own personal experience most patients I attempted to occlude with various devices were found to have deficient anterior superior rim. Other cardiologists (Podnar et al 2001, Berger et al 2001, Chessa et al 2002, Mathewson et al 2004) had similar experiences. With deficient anterosuperior rim, the disks of the Amplatzer straddle the ascending aorta. With other double disk devices the left atrial disk sits on the back of aorta.

4.3.2.1.1 Amplatzer device

While deploying the Amplatzer device in ASDs with deficient anterior superior rim, the left atrial disk tends to become perpendicular to the atrial septum leading to prolapse of the left disk into the right atrium. Several techniques have been proposed to overcome such difficulties; these were reviewed elsewhere (Nagm and Rao 2004, Rao 2007). The left atrial disk of the device is deployed in the right upper or left upper pulmonary vein and the waist and the right atrial disk are released while simultaneously withdrawing the deployed left atrial disk against the atrial septum; this technique has been successfully used by several investigators (Berger et al 2001, Du et al 2002, Chessa et al 2002, Harper et al 2002, Varma et al 2004, Fu et al 2007). While the device placement may be successful with these techniques, there is some concern regarding the risk of injury to the pulmonary vein. Heat-bending the distal portion of the delivery sheath 360 degrees along with cutting off the tip of the sheath ≥ 45 degrees toward its inner circumference is another technique used to help overcome the prolapse of the left disk into the right atrium (Cooke et al 2001, Mathewson et al 2004, Varma et al 2004). Hausdorf sheath (Cook, Bloomington, IN), a specially designed sheath with two curves at the end may help align the left atrial disk parallel to the septum and this delivery catheter has successfully been used by some workers (Staniloae et al 2003, Pedra et al 2004, Varma et al 2004). Holding the left atrial disk with the tip of a reinforced dilator (Abdul Wahab 2003), sizing balloon catheter (Dalvi et al 2005, Flores et al 2008) or a steerable guide catheter (Nounou et al 2008) to prevent its prolapse into the right atrium has also been employed successfully. Kutty et al (2007) cut the sheath to create a straight catheter with a side-hole, the so called SSH modification and were successful in positioning the device in 120 of 122 (98.4%) patients; this is in contradistinction to the successful deployment of the device in 14 of 18 (78%) patients with the use of standard Amplatzer

delivery sheath. The cardiologists should consider all options reviewed above and select the method that is most likely to result in successful implantation of the device in their patient.

4.3.2.1.2 HELEX device

Since the HELEX device is not suitable for large defects, it should not be used to occlude large ASDs.

4.3.2.2 Large defects with deficient postero-inferior rim

Some of the large ASDs are associated with deficient posterior-inferior (PI) rim (Pedra et al 2004) making the device implantation difficult. Varma et al (2004) studied reasons for unsuccessful Amplatzer implantations and found deficient inferior rim as an explanation for unsuccessful deployments. Closure of a large ASD with deficient or absent PI rim is a real challenge. Insufficient number of cases with deficient PI rim reported in most series makes it even more difficult to have a consensus. Du et al (2002) reported 23 patients with deficient rims; of these 3 patients had deficient inferior or posterior rims. Two patients had 2 mm of posterior rim and the third had a 4 mm posterior rim. These 3 patients' ASDs were successfully closed. Mathewson et al (2004) defined absent PI rim as a rim < 3 mm. As the difference in radius length between right and left atrial disks of the Amplatzer device is 2-3 mm, a rim < 3 mm will not allow both disks to hang on both sides of the rim. They found that defects with absent PI rim tend to be larger in diameter. They concluded that, although a stable Amplatzer device deployment is possible, these defects are more liable for complications such as pulmonary vein or inferior vena caval obstruction, encroachment onto the anterior mitral leaflet or frank embolization (Mathewson et al 2004). The number of cases reported is too small to make a generalized conclusion as to what is the best approach to address these ASDs.

4.3.2.3 Multiple or fenestrated defects

Multiple or fenestrated ASDs may be successfully occluded by different techniques or devices. One method used for addressing fenestrated defects was to perform balloon atrial septostomy to create a single large defect which was then closed with a single large Amplatzer device (Carano et al 2001). While these authors were successful in occluding the defect, I am not in favor of using such a technique. A large single Amplatzer device may be deployed in the larger defect to occlude two or more smaller defects as used by Szkutnik et al (2004) and others (Roman et al 2002). While examining this technique, Szkutnik et al (2004) found that a smaller defect less than 7 mm distance from the larger defect had a 100% closure rate at 1 month follow-up. The device in the larger defect decreases the distance between the two defects or even compress the smaller defect (Szkutnik et al 2004). However, if the distance between the two defects is >7 mm, a residual left to right shunt persisted (Szkutnik et al 2004). Several investigators (Pedra et al 1998, Bandel et al 2002, Roman et al 2002, Pinto and Dalvi 2005, Awad et al 2007, Tillman et al 2008, Butera et al 2010, Duygu et al 2010, Cho et al 2011) used two Amplatzer devices to close two ASDs concurrently. Extremely rarely three devices (Lander et al 2004, Arcidiacono et al 2008) may be required to completely close all the defects. Multiple defects may also be closed with a large single device such as CardioSeal device (Pedra et al 2000, Evert et al 2001) or Cribiform Amplatzer device (Hijazi et al 2003, Numan et al 2008).

While the conventional method of imaging the atrial septum and monitoring device deployment is two-dimensional TEE or ICE, more recently three-dimensional transthoracic (Arcidiacono et al 2008) or transesophageal (Kuo et al 2011) echocardiography has been used. However, it is not clear whether three dimensional imaging techniques are superior to two dimensional techniques.

Based on these observations and other reports as well as our personal experience, the following recommendations may be made. If the smaller defect is hemodynamically significant, but is far (>7 mm) from the larger defect, two devices should be used. After verifying good position of both devices, release of smaller device should precede the release of larger device. Extremely rarely three devices (Lander et al 2004, Arcidiacono et al 2008) may be needed to completely close all the defects. If the defects are close to each other (<7mm) Cribriform Amplatzer device (Hijazi et al 2003, Zanchetta et al 2005, Numan et al 2008), large enough to cover all the defects may be used. We used both these techniques with good success.

4.3.2.4 Anuerysmal atrial septum

Single or multiple defects with septal aneurysm represent a different type of complex ASD. Such defects may be better dealt with devices that don't rely on stenting the defect (for example Amplatzer device) in order to achieve stabilization in the septum. Devices with two discs such as the hybrid buttoned device (Rao 2003d), the HELEX, the CardioSeal or the Cribriform Amplatzer (Musto et al 2009) are more appropriate choices to close such defects. Closing two small but distant defects within an aneurysmal atrial septum may effectively close both defects but carry a higher risk of later development of thrombus formation (Krumdorf et al 2004). We have successfully closed defects associated with atrial septal aneurysms with hybrid buttoned devices (Figure 3) by compressing the aneurysm between the occluder and the square shaped counter-occluder (Rao 2003d).

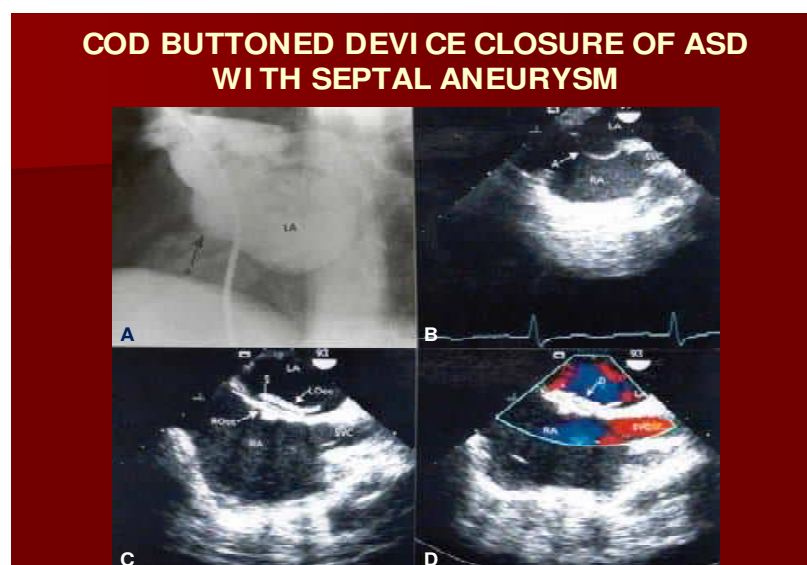


Fig. 3. Selected left atrial (LA) cineangiographic (A) and transesophageal echocardiographic (B) frames showing atrial septal aneurysm (A, arrow). After closure of the atrial septal defect with a hybrid buttoned device (C), the aneurysm is sandwiched between the left atrial (LA) component of the device (LOcc) and right atrial (RA) component of the device (ROcc). No residual shunt is seen (D). The superior vena cava (SVC) is unobstructed.

4.3.3 Conclusions – Approaches for closure of complex ASDs

It may be concluded that most complex ASDs can be closed successfully either by using traditional or special devices or techniques. Defects with deficient or absent PI rim continue to be challenging for most interventionalists and may require surgical closure.

4.3.4 Long-term complications of transcatheter closure

Reports of erosion of the aortic wall by the Amplatzer device with development of aorta-to-right atrium (Chun 2003) or aorta-to-left atrium (Aggoun et al 2002) fistulae led to the suggestion of over-sizing the device (4 mm larger than the measured stretched diameter) in large defects with deficient anterior superior rim. This is meant to ensure that the device disks straddle and remain flared around the ascending aorta to prevent discrete areas of pressure where erosion may occur. Of course, when over-sizing the device, care must be taken not to interfere with atrio-ventricular valve function and venous return. Device migration and erosion of aorta (Amin et al 2004, AGA 2006) was observed during follow-up in 37 out of 35,000 (0.11% or 1 in 1,000) Amplatzer device implants world-wide. This complication was also similar in the US study population: 18 out of 15,900 implants (0.12% or 1 in 1,000). Review of data by the Review Board and AGA Medical (AGA 2006) suggested that the device erosion is related to over-sizing of the device (Figure 4) and recommended that device size >1.5 times the TEE/ICE diameter of ASD should not be used.

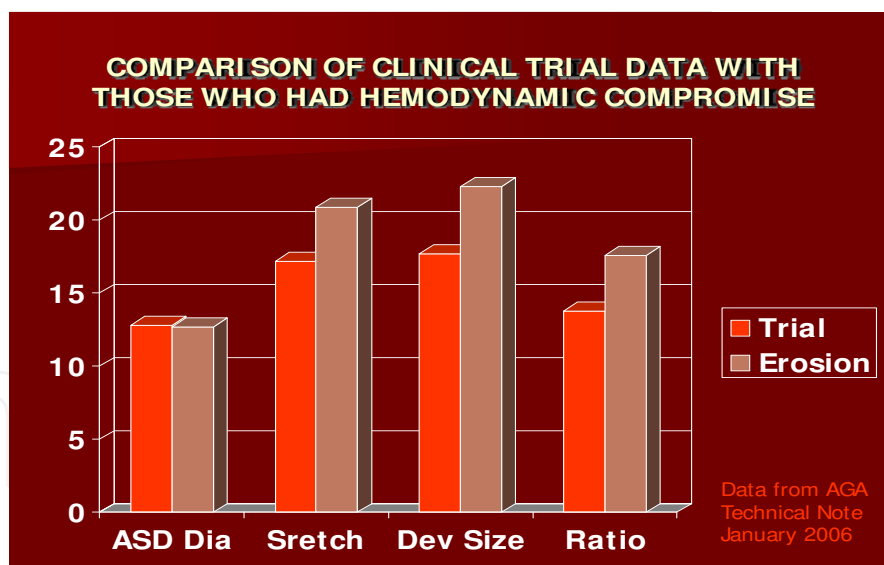


Fig. 4. Bar diagram demonstrating relationship of atrial septal defect (ASD) and device size data between the group of patients without perforation (Trial) and those that had perforation (Erosion). The diameter (Dia) of the ASD was similar in both groups whereas the stretched diameter (Stretch), device size (Dev size) and ratio of device to ASD (Ratio) were larger in the patients who had perforation than those who did not. Based on these data a recommendation made not to use devices larger 1.5 X ASD size (Constructed from the data of AGA 2006).

5. Summary and conclusions

ASDs in adult subjects should be closed at presentation, electively, irrespective of their age. Evidence was presented to indicate that hemodynamically significant (right ventricular volume overload) ASDs in adults should be transcatheter occluded irrespective of symptomatology. While surgical closure is safe and effective, device closure carries less morbidity. Multiple devices have been investigated over the last few decades, but only Amplatzer and HELEX devices received FDA approval as of this time. The Amplatzer is useful in most ASDs while the HELEX device is useful in small and medium-sized defects. Some procedural details were mentioned with particular emphasis on the need for test occlusion of ASD in the elderly. Approaches taken to occlude ASDs with complex anatomy were also reviewed. Amplatzer device appears to be best available option at the present time. Careful attention to the details of the technique are mandatory to achieve a successful outcome

6. References

- [1] Abdul Wahab, H.; Bairam, AR.; Cao, Q.; Hijazi, ZM. (2003) Novel technique to prevent prolapse of the Amplatzer septal occluder through large atrial septal defect. *Cathet Cardiovascu Intervent*, Vol. 60, No. 4, pp. 543-545.
- [2] AGA Medical Technical Note, January 2006:1-4.
- [3] Aggoun, Y.; Gallet, B.; Acar, P.; et al. (2002) Perforation of the aorta after percutaneous closure of an atrial septal defect with an Amplatzer prosthesis with acute severe hemolysis. *Arch Mal Coeur Vaiss*, Vol. 95, No. 5, pp. 479-482.
- [4] Al-Hindi, A.; Cao, QL.; Hijazi, ZM. (2009) Transcatheter closure of secundum atrial septal defect in the elderly. *J Invasive Cardiol*, Vol. 21, No. 2, pp. 70-75.
- [5] Amin, Z.; Hijazi, ZM.; Bass, JL.; et al. (2004) Erosion of Amplatzer septal occluder device after closure of secundum atrial septal defect: Review of registry of complications and recommendations to minimize future risk. *Cathet Cardiovascu Intervent*, Vol. 63, No. 4, pp. 491-502.
- [6] Arcidiacon, C.; Gaio, G.; Butera, G.; Carminati, M. (2008) Percutaneous closure of multiple secundum atrial septal defects using 3 Amplatzer atrial septal occluder devices: evaluation by live transthoracic 3-dimensional echocardiography. *Circ Cardiovasc Imaging*, Vol. 1, No. 2, pp. c15-16.
- [7] Awad, SM.; Garay, FF.; Cao, QL.; Hijazi, ZM. (2007) Multiple Amplatzer septal occluder devices for multiple atrial communications: immediate and long-term follow-up results. *Catheter Cardiovasc Interv*, Vol. 70, No. 2, pp. 265-273.
- [8] Bandel, JW.; Collet, HC.; Patiño, J. (2002) The versatility of the Amplatzer Septal Occluder for the management of multiple atrial septal defects in a patient with dextrocardia and situs inversus. *J Invasive Cardiol*, Vol. 14, No. 6, pp. 340-342.
- [9] Berger, F.; Ewert, P.; Abdul-Khalid, H.; et al. (2001) Percutaneous closure of large atrial septal defects with the Amplatzer septal occluder: technical overkill or recommendable alternative treatment. *J Intervent Cardiol*, Vol. 14, No. 1, pp. 63-67.

- [10] Berger, F.; Vogel, M.; Alexi-Meskishvili, V.; Lange, PE. (1999) Comparison of results and complications of surgical and Amplatzer device closure of atrial septal defects. *J Thorac Cardiovasc Surg*, Vol. 118, No. 4, pp. 674-678.
- [11] Bettencourt, N.; Salome, N.; Carneiro, F.; et al. (2003) Atrial septal closure in adults : surgery versus Amplatzer – comparison of results. *Rev Port Cardiol*, Vol. 22, No. 10, pp. 1203-1211.
- [12] Bialkowski, J.; Karwot, B.; Szkutnik, M.; et al. (2004) Closure of atrial septal defects in children: surgery versus Amplatzer device implantation. *Tex Heart Inst J*, Vol. 31, No. 3, pp. 220-223.
- [13] Brochu, MC.; Baril, JF.; Dore, A.; et al. (2002) Improvement in exercise capacity in asymptomatic and mildly symptomatic adults after atrial septal defect percutaneous closure. *Circulation*, Vol. 106, No. 14, pp. 1821-1826.
- [14] Butera, G.; Carminati, M.; Chessa, M.; et al. (2004) CardioSEAL/STARflex versus Amplatzer devices for percutaneous closure of small to moderate (up to 18 mm) atrial septal defects. *Am Heart J*, Vol. 148, No. 3, pp. 507-510.
- [15] Butera, G.; Romagnoli, E.; Saliba, Z.; et al. (2010) Percutaneous closure of multiple defects of the atrial septum: procedural results and long-term follow-up. *Catheter Cardiovasc Interv*, Vol. 76, No. 1, pp. 121-128.
- [16] Carano, N.; Hagler, DJ.; Agnetti, A.; Squarcia, U. (2001) Device closure of fenestrated atrial septal defect: use of a single Amplatzer atrial occluder after balloon atrial septostomy to create a single defect. *Catheter Cardiovasc Interv*, Vol. 53, No. 2, pp. 203-207.
- [17] Chessa, M.; Carminati, M.; Buetera, G.; et al. (2002) Early and late complications associated with transcatheter occlusion of secundum atrial septal defect. *J Am Coll Cardiol*, Vol. 39, No. 2, pp. 1061-1065.
- [18] Cho, MJ.; Song, J.; Kim, SJ.; et al. (2011) Transcatheter closure of multiple atrial septal defects with the Amplatzer device. *Korean Circ J*, Vol. 41, No. 9, pp. 549-551. Epub 2011 Sep 29.
- [19] Chopra, PS.; Rao, PS. (2000) History of the Development of Atrial Septal Occlusion Devices. *Current Intervent Cardiol Reports*, Vol. 2, No. 1, 63-69.
- [20] Chun, DS.; Turrentine, MW.; Moustapha, A.; Hoyer MH. (2003) Development of aorta-to-right atrial fistula following closure of secundum atrial septal defect using the Amplatzer septal occluder. *Catheter Cardiovasc Interv*, Vol. 58, No. 2, pp. 246-251.
- [21] Cooke, JC.; Gelman, JS.; Harper, RW. (2001) Echocardiographic role in the deployment of the Amplatzer septal occluder device in adults. *J Am Society of Echocardiogr*, Vol. 14, No. 6, pp. 588-594.
- [22] Dalvi, BV.; Pinto, RJ.; Gupta, A. (2005) New technique for device closure of large atrial septal defects. *Cathet Cardiovascu Interv*, Vol. 64, No. 1, 102-107.
- [23] Du, ZD.; Hijazi, ZM.; Kleinman, CS.; et al. (2002) Comparison between transcatheter and surgical closure of secundum atrial septal defect in children and adults: results of multicenter nonrandomized trial. *J Am Coll Cardiol*, Vol. 39, No. 11, pp. 1836-1844.

- [24] Durongpisitkul, K.; Soongswang, J.; Laohaprasitiporn, D.; et al. (2002) Comparison of atrial septal defect closure using amplatzer septal occluder with surgery. *Pediatr Cardiol*, Vol. 23, No. 1, pp. 36-40.
- [25] Duygu, H.; Acet, H.; Kocabas, U.; et al. (2010) Percutaneous successful closure of dual atrial septal defect with two Amplatzer septal occluder devices. *Clin Res Cardiol*, Vol. 99, No. 5, pp. 29-31.
- [26] Eidem, BW.; O'Leary, PW.; Tei, C.; Seward, JB. (2000) Usefulness of the myocardial performance index for assessing right ventricular function in congenital heart disease. *Am J Cardiol*, Vol. 86, No. 6, pp. 654-658.
- [27] Ewert, P.; Berger, F.; Kretschmar O, et al. (2001) Feasibility of transcatheter closure of multiple defects within the oval fossa. *Cardiol Young*, Vol. 11, No. 3, pp. 314 -319.
- [28] Flores, RA.; Salgado, A.; Antúnez, SP.; et al. (2008) Correction of the perpendicular positioning of the Amplatzer device during closure of an ostium secundum atrial septal defect. *Rev Esp Cardiol*, Vol. 61, No. 7, pp. 714-718.
- [29] Formigari, R.; Santoro, G.; Rosetti, L.; et al. (1998) Comparison of three different atrial septal defect occluding devices. *Am J Cardiol*, Vol. 82, No. 5, pp. 690-692.
- [30] Fu, YC.; Cao, QL.; Hijazi, ZM. (2007) Device closure of large atrial septal defects: technical considerations. *J Cardiovasc Med (Hagerstown)*, Vol. 8, No. 1, pp. 30-33.
- [31] Galal, MO.; Wobst, A.; Halees, Z.; et al. (1994) Perioperative complications following surgical closure of atrial septal defect type II in 232 patients - a baseline study. *Europ Heart J*, Vol. 15, No. 10, pp. 1381-1384.
- [32] Gatzoulis, MA.; Redington, AN.; Somerville, J.; et al. (1996) Should atrial septal defects in adults be closed? *Ann Thorac Surg*, Vol. 61, No. 2, pp. 657-659.
- [33] Godart, F.; Rey, C.; Francart, C.; et al. (2000) Experience in one centre using the buttoned device for occlusion of atrial septal defect: comparison with the Amplatzer septal occluder. *Cardiol Young*, Vol. 10, No. 5, pp. 527-533.
- [34] Hamdan, MA.; Cao, Q.; Hijazi, ZM. (2003) Amplatzer septal occluder. In: *Catheter Based Devices for Treatment of Noncoronary Cardiovascular Disease in Adults and Children*, P.S. Rao, M.J. Kern. (Eds.): 51-59, Lippincott, Williams & Wilkins, Philadelphia, PA, USA.
- [35] Harper, RW.; Mottram, PM.; McGaw, DJ. (2002) Closure of secundum atrial septal defects with the Amplatzer septal occluder device: techniques and problems. *Catheter Cardiovasc Intervent*, Vol. 57, No. 4, pp. 508-524.
- [36] Hijazi, ZM.; and Cao, Q-L. (2003) Transcatheter closure of multi-fenestrated atrial septal defects using the new Amplatzer cribriform device. *Congenital Cardiology Today*, Vol. 1, No. pp. 1-4.
- [37] Hijazi, ZM., Wang, Z.; Cao, QL.; et al. (2001) Transcatheter closure of atrial septal defects and patent foramen ovale under intracardiac echocardiographic guidance: feasibility and comparison with transesophageal echocardiography. *Cath Cardiovasc Intervent*, Vol. 52, No. 2, pp. 194-199.
- [38] Holzer, R.; Cao, QL.; Hijazi, ZM. (2005) Closure of a moderately large atrial septal defect with a self-fabricated fenestrated Amplatzer septal occluder in an 85-year-old patient with reduced diastolic elasticity of the left ventricle. *Catheter Cardiovasc Intervent*, Vol. 64, No. 4, pp. 513-518

- [39] Horvath, KA.; Burke, RP.; Collins, JJ. Jr.; Cohn, LH. (1991) Surgical treatment of adult atrial septal defect: early and long-term results. *J Am Coll Cardiol*, Vol. 20, No. 5, pp. 1156-1159.
- [40] Kenny, D.; Cao, QL.; Hijazi, ZM. (2011) Fenestration of a Gore Helex Septal Occluder device in a patient with diastolic dysfunction of the left ventricle. *Catheter Cardiovasc Interv*, Vol. 78, No. 4, pp. 594-598
- [41] Keppeir, P.; Rux, S.; Dirko, J.; et al. (1999) Transcatheter closure of 100 patent foramina ovalia in patients with unexplained stroke and suspected paradoxical embolism: a comparison of five different devices [abstract]. *Europ Heart J*, Vol. 20, No. 2, pp. 196.
- [42] Kim, JJ.; Hijazi, ZM. (2002) Clinical outcomes and costs of Amplatzer transcatheter closure as compared with surgical closure of ostium secundum atrial septal defects. *Med Science Monitor*, Vol. 8, No. 12, pp. CR787-791.
- [43] King, TD.; Mills NL. (1974) Nonoperative closure of atrial septal defects. *Surgery*, Vol. 75, No. 3, pp. 383-388.
- [44] King, TD.; Thompson, SL.; Steiner, C.; et al. (1976) Secundum atrial septal defect: nonoperative closure during cardiac catheterization. *J Am Med Assoc*, Vol. 235, No. 23, pp. 2506-2509.
- [45] Konstantinides, S.; Geibel, A.; Olschewski, M.; et al. (1995) A comparison of surgical and medical therapy for atrial septal defects in adults. *New Engl J Med*, Vol. 333, No. 8, pp. 469-473.
- [46] Kretschmar, O.; Sglimbea, A.; Corti, R.; Knirsch, W. (2010) Shunt reduction with a fenestrated Amplatzer device. *Catheter Cardiovasc Interv*, Vol. 76, No. 4, pp. 564-571.
- [47] Krumdorf, U.; Ostermayer, S.; Ballinger, K.; et al. (2004) Incidence and clinical course of thrombus formation on atrial septal defect and patent foramen ovale closure devices in 1000 consecutive patients. *J Am Coll Cardiol*, Vol. 43, No. 2, 302-309.
- [48] Kuo, BT.; Whitbeck, MG.; Gurley, JC.; Smith, MD. (2011) Double atrial septal defect: diagnosis and closure guidance with 3D transesophageal echocardiography. *Echocardiography*, Vol. 28, No. 6, pp. E115-117.
- [49] Kutty, S.; Asnes, JD.; Srinath, G.; et al. (2007) Use of a straight, side-hole delivery sheath for improved delivery of Amplatzer ASD occluder. *Cathet Cardiovascular Interv*, Vol. 69, No. 1, pp. 15-20.
- [50] Lammers, AE.; Derrick, G.; Haworth, SG.; et al. (2007) Efficacy and long-term patency of fenestrated Amplatzer devices in children. *Catheter Cardiovasc Interv*, Vol. 70, No. 4, pp. 578-584.
- [51] Lander, SR.; Phillips, S.; Vallabhan, RC.; (2004) et al. Percutaneous closure of multiple atrial septal defects with three Amplatzer septal occluder devices. *Catheter Cardiovasc Interv*, Vol. 62, No. 4, pp. 526-529.
- [52] Mathewson, JW.; Bichell, D.; Rothman, A.; Ing, FF. (2004) Absent posteroinferior and anterosuperior atrial septal defect rims: Factors affecting nonsurgical closure of large secundum defects using the Amplatzer occluder. *J Am Soc Echocardiogr*, Vol. 17, No. 1, pp. 62-69.
- [53] MacDonald, ST.; Arcidiacono, C.; Butera, G. (2011) Fenestrated Amplatzer atrial septal defect occluder in an elderly patient with restrictive left ventricular physiology. *Heart*, Vol. 97, No.5, p. 438.

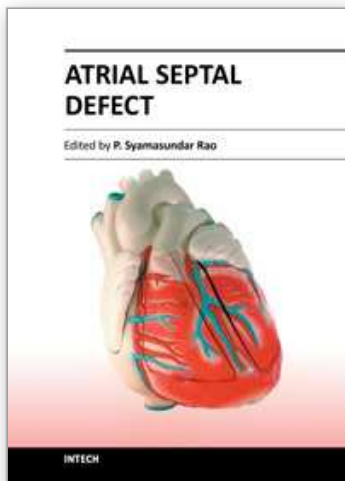
- [54] Mills, NL.; King, TD. (1976) Nonoperative closure of left-to-right shunts. *J Thorac Cardiovasc Surg*, Vol. 72, No. 3, pp. 371-378.
- [55] Murphy, JG.; Gersh, BJ.; McGoon, MD.; et al. (1990) Long-term outcome after surgical repair of isolated atrial septal defect. *New Engl J Med*, Vol. 323, No. 24, pp. 1645-1650.
- [56] Musto, C.; Cifarelli, A.; Pandolfi, C.; et al. (2009) Transcatheter closure of patent foramen ovale associated with atrial septal aneurysm with Amplatzer Cribriform septal occluder. *J Invasive Cardiol*, Vol. 21, No. 6, pp. 290-293.
- [57] Nagm, AM.; Rao, PS. (2004) Percutaneous occlusion of complex atrial septal defects (Editorial). *J Invasive Cardiol*, Vol. 16, No. 3, pp. 123-125.
- [58] Nounou, M.; Harrison, A.; Kern, M. (2008) A novel technique using a steerable guide catheter to successfully deliver an Amplatzer septal occluder to close an atrial septal defect. *Catheter Cardiovasc Interv*, Vol. 72, No. 7, pp. 994-997.
- [59] Numan, M.; El Sisi, A.; Tofeig, M.; et al. (2008) Cribriform amplatzer device closure of fenestrated atrial septal defects: feasibility and technical aspects. *Pediatr Cardiol*, Vol. 29, No. 3, pp. 530-535. Epub 2007 Nov 13.
- [60] Pastorek, JS.; Allen, HD.; Davis, JT. (1994) Current outcomes of surgical closure of secundum atrial septal defect. *Am J Cardiol*, Vol. 74, No. 1, pp. 75-77.
- [61] Pedra, CA.; Fontes-Pedra, SR.; Esteves, CA.; et al. (1998) Multiple atrial septal defects and patent ductus arteriosus: successful outcome using two Amplatzer septal occluders and Gianturco coils. *Cathet Cardiovasc Diagn*, Vol. 45, No. 3, pp. 257-259.
- [62] Pedra, CA.; Pedra, SRF.; Esteves, CSA.; et al. (2004) Transcatheter closure of secundum atrial septal defects with complex anatomy. *J Invasive Cardiol*, Vol. 16, No. 3, pp. 117-122
- [63] Pedra, CA.; Pihkala, J.; Lee, K-J.; et al. (2000) Transcatheter closure of atrial septal defects using the CardioSeal implant. *Heart*, Vol. 84, No. 3, pp. 320-326.
- [64] Peters, B.; Ewert, P.; Schubert, S.; et al. (2006) Self-fabricated fenestrated Amplatzer occluders for transcatheter closure of atrial septal defect in patients with left ventricular restriction: midterm results. *Clin Res Cardiol*, Vol. 95, No. 2, pp. 88-92. Epub 2006 Jan 16.
- [65] Pinto, RJ.; Dalvi, B. (2005) Closure of two atrial septal defects using two separate Amplatzer ASD devices. *Indian Heart J*. Vol. 57, No. 3, pp. 251-254.
- [66] Podnar, T.; Martanovič, P.; Gavora, P.; Masura, J. (2001) Morphological variations of secundum - type atrial septal defects: Feasibility for percutaneous closure using Amplatzer septal occluders. *Catheter Cardiovasc Intervent*, Vol. 53, No. 3, pp. 386-391.
- [67] Rao, PS. (1998a) Closure devices for atrial septal defect: which one to chose? (editorial). *Indian Heart J*, Vol. 50, No. 4, pp. 379-383.
- [68] Rao, PS. (1998b) Transcatheter closure of atrial septal defects: Are we there yet? (editorial). *J Am Coll Cardiol*, Vol. 31, No. 5, pp. 1117-1119.
- [69] Rao, PS. (2000) Summary and Comparison of Atrial Septal Defect Closure Devices. *Current Intervent Cardiol Reports*, Vol. 2, No. 4, pp. 367-376.
- [70] Rao, PS. (2003a) Catheter Closure of Atrial Septal Defects (Editorial). *J Invasive Cardiol*, Vol. 15, No. pp. 398-400.

- [71] Rao, PS. (2003b) History of atrial septal occlusion devices, In: *Catheter Based Devices for Treatment of Noncoronary Cardiovascular Disease in Adults and Children*, P.S. Rao, M.J. Kern. (Eds.): 1-9, Lippincott, Williams & Wilkins, Philadelphia, PA, USA.
- [72] Rao, PS. (2003c) Comparative summary of atrial septal defect occlusion devices, In: *Catheter Based Devices for Treatment of Noncoronary Cardiovascular Disease in Adults and Children*, P.S. Rao, M.J. Kern. (Eds.): 91-101, Lippincott, Williams & Wilkins, Philadelphia, PA, USA.
- [73] Rao, PS. (2003d) The buttoned device. In: *Catheter Based Devices for Treatment of Noncoronary Cardiovascular Disease in Adults and Children*, P.S. Rao, M.J. Kern. (Eds.): 17-34, Lippincott, Williams & Wilkins, Philadelphia, PA, USA.
- [74] Rao, PS. (2007) Techniques for closure of large atrial septal defects. *Cath Cardiovasc Intervent*, Vol. 70, No. 2, pp. 329-330.
- [75] Roman, KS.; Jones, A.; Keeton, BR.; Salmon, AP. (2002) Different techniques for closure of multiple interatrial communications with the Amplatzer septal occluder. *J Interv Cardiol*, Vol. 15, No. 5, pp. 393-397.
- [76] Rosas, M.; Attie, F.; Sandoval, J.; et al. (2004) Atrial septal defect in adults ≥ 40 years old: negative impact of low arterial oxygen saturation. *Int J Cardiol*, Vol. 93, No. 2-3, pp. 145-155.
- [77] Salehian, O.; Horlik, E.; Schwermann, M.; et al. (2005) Improvement in cardiac form and function after transcatheter closure of secundum atrial septal defects. *J Am Coll Cardiol*, Vol. 45, No. 4, pp. 499-504.
- [78] Sievert, H.; Koppeler, P.; Rux, S.; et al. (1999) Percutaneous closure of 176 interatrial defects in adults with different occlusion devices - 6 years experience [abstract]. *J Am Coll Cardiol*, Vol. 33, No. pp. 519A.
- [79] Staniloae, CS.; El-Khally, Z.; Ibrahim, R.; et al. (2003) Percutaneous closure of secundum atrial septal defects in adults - A single center experience with Amplatzer septal occluder. *J Invasive Cardiol*, Vol. 15, No. 7, pp. 393-397.
- [80] Szkutnik, M.; Masura, J.; Bialkowski, J.; et al. (2004) Transcatheter Closure of double atrial septal defects with a single Amplatzer device. *Catheter Cardiovasc Intervent*, Vol. 61, No. 2, pp. 237-241.
- [81] Tillman, T.; Mulingtapang, R.; Sullebarger, JT. (2008) Approach to percutaneous closure in patients with multiple atrial septal defects. *J Invasive Cardiol*, Vol. 20, No. 5, pp. E167-170.
- [82] Varma, C.; Benson, LN.; Silversides, C.; et al. (2004) Outcome and alternative techniques for device closure of large secundum atrial septal defect. *Cath Cardiovasc Intervent*, Vol. 61, No. 1, pp. 131-139.
- [83] Walsh, KP.; Tofeig, M.; Kitchiner, DJ.; et al. (1999) Comparison of the Sideris and Amplatzer septal occlusion devices. *Am J Cardiol*, Vol. 83, No. 6, pp. 933-936.
- [84] Ward, C. (1994) Secundum atrial septal defect: routine surgical treatment is not of proven benefit. *Br Heart J*, Vol. 71, No. 3, pp. 219-223.
- [85] Webb, G. (2001) Do patients over 40 years of age benefit from closure of an atrial septal defect? *Heart*, Vol. 85, No. 3, pp. 249-250.

- [86] Zanchetta, M.; Rigatelli, G.; Pedon, L.; et al. (2005) Catheter closure of perforated secundum atrial septal defect under intracardiac echocardiographic guidance using a single Amplatzer device: feasibility of a new method. *J Invasive Cardiol*, Vol. 17, No. 5, pp. 262-265.

IntechOpen

IntechOpen



Atrial Septal Defect

Edited by Dr. P. Syamasundar Rao

ISBN 978-953-51-0531-2

Hard cover, 184 pages

Publisher InTech

Published online 25, April, 2012

Published in print edition April, 2012

Atrial Septal Defects (ASDs) are relatively common both in children and adults. Recent reports of increase in the prevalence of ASD may be related use of color Doppler echocardiography. The etiology of the ASD is largely unknown. While the majority of the book addresses closure of ASDs, one chapter in particular focuses on creating atrial defects in the fetus with hypoplastic left heart syndrome. This book, I hope, will give the needed knowledge to the physician caring for infants, children, adults and elderly with ASD which may help them provide best possible care for their patients.

How to reference

In order to correctly reference this scholarly work, feel free to copy and paste the following:

P. Syamasundar Rao (2012). Why, When and How Should Atrial Septal Defects Be Closed in Adults, Atrial Septal Defect, Dr. P. Syamasundar Rao (Ed.), ISBN: 978-953-51-0531-2, InTech, Available from: <http://www.intechopen.com/books/atrial-septal-defect/why-when-and-how-should-atrial-septal-defects-be-closed-in-adults>

INTECH
open science | open minds

InTech Europe

University Campus STeP Ri
Slavka Krautzeka 83/A
51000 Rijeka, Croatia
Phone: +385 (51) 770 447
Fax: +385 (51) 686 166
www.intechopen.com

InTech China

Unit 405, Office Block, Hotel Equatorial Shanghai
No.65, Yan An Road (West), Shanghai, 200040, China
中国上海市延安西路65号上海国际贵都大饭店办公楼405单元
Phone: +86-21-62489820
Fax: +86-21-62489821

© 2012 The Author(s). Licensee IntechOpen. This is an open access article distributed under the terms of the [Creative Commons Attribution 3.0 License](#), which permits unrestricted use, distribution, and reproduction in any medium, provided the original work is properly cited.

IntechOpen

IntechOpen