

We are IntechOpen, the world's leading publisher of Open Access books Built by scientists, for scientists

4,800

Open access books available

122,000

International authors and editors

135M

Downloads

Our authors are among the

154

Countries delivered to

TOP 1%

most cited scientists

12.2%

Contributors from top 500 universities



WEB OF SCIENCE™

Selection of our books indexed in the Book Citation Index
in Web of Science™ Core Collection (BKCI)

Interested in publishing with us?
Contact book.department@intechopen.com

Numbers displayed above are based on latest data collected.
For more information visit www.intechopen.com



Historical Aspects of Transcatheter Occlusion of Atrial Septal Defects

Srilatha Alapati and P. Syamasundar Rao

*University of Texas at Houston Medical School, Houston, TX,
USA*

1. Introduction

Following the description of surgical closure of atrial septal defect (ASD) in early 1950s (Bigelow et al., 1950; Lewis et al., 1953; Gibbon, 1953), it rapidly became a standard therapy of ASDs. Surgical closure of ostium secundum ASDs is safe and effective with negligible mortality (Murphy et al., 1990; Galal et al., 1994; Pastorek et al., 1994), but the morbidity associated with sternotomy/thoracotomy, cardiopulmonary bypass and potential for postoperative complications cannot be avoided. Other disadvantages of surgical therapy are the expense associated with surgical correction, residual surgical scar and psychological trauma to the patients and/or the parents. Presumably because of these reasons, several groups of cardiologists embarked upon developing transcatheter methods of closure of the ASD. The studies of King (King & Mills, 1974; Mills & King, 1976; King et al., 1976), Rashkind (Rashkind, 1975; Rashkind & Cuaso, 1977; Rashkind, 1983) and their associates paved the way for the future development of transcatheter ASD device occlusion methodology. In this chapter, history of development of ASD closure devices will be reviewed. Historical development for occlusion of patent foramen ovale (PFO) will be briefed at the end of the chapter.

2. Closure of atrial septal defects

Historical aspects of closure of atrial septal defect will be reviewed in this section.

2.1 King and Mill's device

King and his associates were successful in occluding the ASD via a transcatheter delivered occluding device and were the first in doing so and reported their studies in mid 70s (King & Mills, 1974; Mills & King, 1976; King et al., 1976). This device is composed of paired, Dacron-covered stainless steel umbrellas (Figure 1A) collapsed into a capsule at the tip of a catheter. A number of sizes of the umbrella were manufactured. King & Mills (1974) initially attempted this technique in experimental animal models. ASDs were created by a punch biopsy technique in adult dogs. Successful device deployment was achieved in five of nine dogs in whom the procedure was attempted. Complete closure of the ASD and endothelialization of the implanted umbrellas was observed during the follow-up.

Following this experience in the dog model, the technique was extended to human subjects (Mills & King, 1976; King et al., 1976). Stretched ASD diameter was measured by balloon sizing (King et al., 1978) and a device 10 mm larger than the stretched ASD diameter is selected for deployment. The device delivery catheter is inserted through the saphenous vein at the sapheno-femoral venous junction by cut-down. The catheter tip is positioned into the left atrium through the ASD. The distal umbrella is extruded in the body of the left atrium and the catheter withdrawn into the right atrium. Then, the distal (left atrial) umbrella is fixed against the left side of the atrial septum and the proximal (right atrial) umbrella is opened in the right atrium. The umbrellas are locked to each other with a special locking mechanism. After the device is in place, the obturator wire is unscrewed and withdrawn, thus releasing the device.

Eighteen patients were taken to the catheterization laboratory and ten (56%) of these were considered suitable candidates for device closure. Successful implantation of the device was accomplished in five (50%) patients. Their ages were 17 to 75 years with a median of 24. The stretched ASD diameter was 18 to 26 mm by balloon sizing. Ostium secundum ASD with left-to-right shunt was present in four patients. The fifth patient had an atrial defect with presumed paradoxical embolism and a stroke. Symptoms improved and the heart size decreased during observed follow-up. Repeat cardiac catheterization data did not show shunts by oximetry. However, trivial shunts were observed by hydrogen curves. In a 27 year follow up study, 4 patients remain alive with closed defects and there had been no adverse events related to the device. The deceased patient died from Hodgkin's disease and a cerebral vascular accident 9 years after device closure (King & Mills, 2010).

Although these results were encouraging, King and his associates did not continue their use nor did any other investigator, to our knowledge, pursued the technique. It may be presumed that this may be related to the need for a large delivery sheath and complicated maneuvering required for implantation of the device.

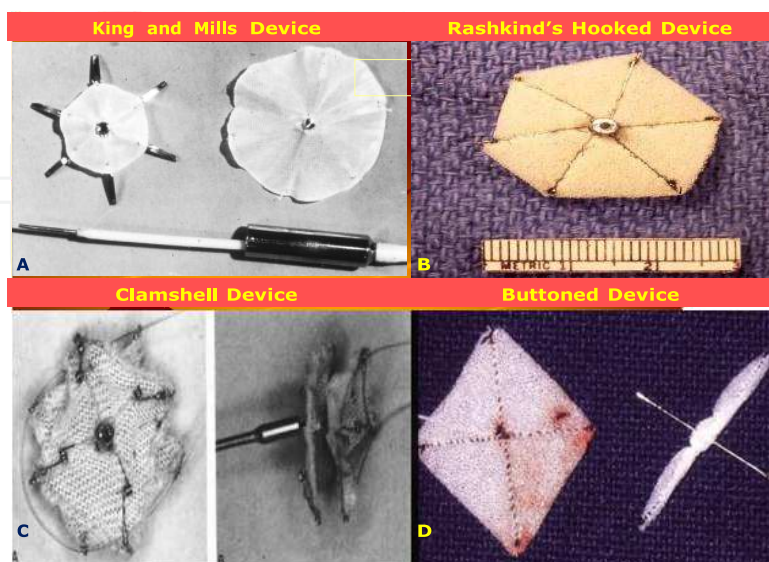


Fig. 1. Photographs of King's device (A), Rashkind's hooked device (B), on-face and side views of the clamshell device (C) and buttoned device (D); see the text for detailed description of the devices.

2.2 Rashkind's devices

Rashkind developed a slightly different type of ASD closure device. Rashkind's investigations appear to be parallel to those of King and Mills (Rashkind et al., 1985). The first Rashkind umbrella consisted of three stainless-steel arms covered with medical grade foam (Rashkind & Cuaso, 1977). The central ends of the stainless-steel arms are attached to miniature springs, which in turn are welded to a small central hub. The outer end of the stainless steel arm ended in a miniature "fish" hook. Rashkind subsequently modified this umbrella such that there are six stainless steel arms with the alternate arms carrying the hook (Figure 1B). He also designed an elaborate centering mechanism, which consisted of five arms bent to produce a gentle outward curve. The umbrella delivery mechanism is built on a 6 F catheter with locking tip, which interlocks with the central hub of the device. The entire system is threaded over a guide wire. Withdrawal of the guide wire after implantation of the device will unlock the mechanism, thereby disconnecting the umbrella from the delivery system. The umbrella collapsed into a pod, the centering mechanism folded and the delivery system can all be loaded into a 14 or 16 F long sheath. The umbrellas were manufactured in three sizes: 25, 30 and 35 mm. An umbrella that is approximately twice the stretched size of the ASD is chosen for implantation. First, the tip of the pod containing the umbrella is advanced into the left-atrium through the ASD (Figure 2 a). Then, the umbrella and centering mechanism delivered into the mid left atrium by retracting the tip of the sheath or pod (Figure 2 b). The entire system is then slowly withdrawn. The centering mechanism keeps the umbrella centered over the ASD. Further withdrawal results in embedding the hooks of the umbrella onto the left atrial side of the atrial septum (Figure 2 c). After the umbrella is fixed to the atrial septum, the umbrella delivery system is disconnected and removed. Experimental studies in closing surgically created ASDs in dogs and calves have indicated the feasibility of the method with excellent endothelialization of the umbrella components (Rashkind, 1975).

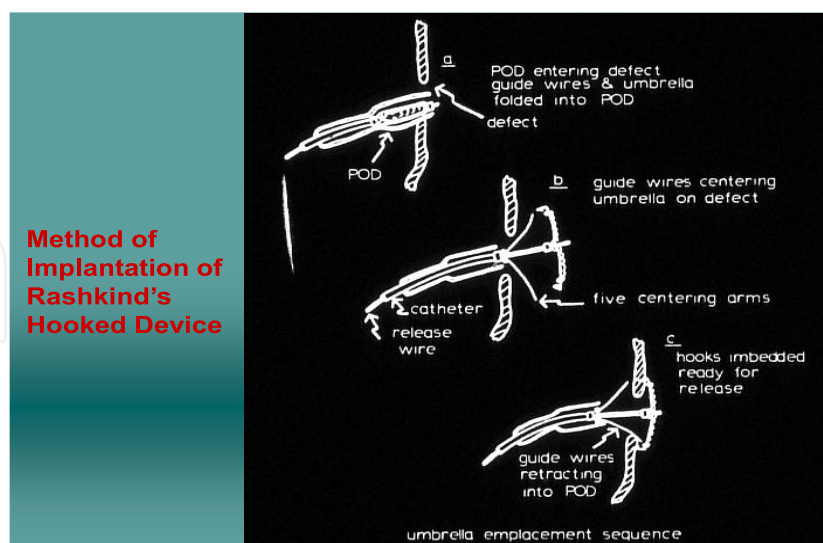


Fig. 2. Sequence of hooked prosthesis implantation (see text for details).

The senior author had the privilege of spending a month-long mini-sabbatical with Dr. William Rashkind in mid-1979 and during that period, had the opportunity in performing ASD device closures with the hooked device, both in calf model and in patients under the

direction of Rashkind. Rashkind's enthusiasm and dedication in developing transcatheter closure methodology is laudable and the diligence with which he pursued the project is admirable. Subsequently, Rashkind obtained investigational device exemption from the FDA and began organizing multi-institutional clinical trials in the US in early 1980s. This is probably the first clinical trial for device implantation in pediatric cardiac practice. Unfortunately, Rashkind did not live to witness the conclusion of these trials or to see the monumental effect that his work had on the evolution of transcatheter occlusion technology.

Following experimental studies in animal models, Rashkind studied ASD closure in human subjects (Rashkind, 1983; Rashkind & Cuaso, 1977). A total of 33 patients were recruited for the clinical trial. Device implantation was not attempted in 10 patients because the defect was too large (N=6) to safely implant the device or too small (N=4) to warrant the potential risk of device placement. In the remaining 23 patients, 14 (61%) had adequate ASD closure and in nine (39%) the results were considered unsatisfactory. The initial six device implantations were three-rib umbrellas and the remaining were six-rib prostheses. Urgent surgical intervention was required in some patients to address the unsatisfactory implantations and others underwent elective surgery. However, uneventful surgical closure of the ASD and removal of the device were undertaken in all subjects. Clinical application in a limited number of patients by Beekman et al (1989) showed similar results.

Although good results were achieved in >50% patients, a number of problems were identified: requirement of a large sheath for implantation, uncertainty of whether the tissue will bind to the entire rim of the single disc device and difficulty in disengaging and repositioning the device if the hooks of the umbrella accidentally engage onto the left atrial wall or mitral valve. Because of these reasons, Rashkind modified this device into a double disc prosthesis which he had successfully employed to close an ASD in a cow (Rashkind, 1983). This modification was patterned after a concurrently developed Rashkind's patent ductus arteriosus occluding device (Rashkind, 1983; Rashkind et al., 1987).

2.3 Transformation from Rashkind to clamshell

The double-umbrella Rashkind device was subsequently utilized in closing ASDs by other workers (Lock et al., 1987, 1989; Rome et al., 1990). Whilst the results appeared good, difficulty in delivering umbrellas on either side of the defect, centering the device because of the angle of the delivery catheter (Lock et al., 1987) and inability of the umbrellas to fold back against each other, the device was modified by introducing a second spring in center of the arms (Lock et al., 1989) and was named Lock Clamshell Occluder. The clamshell device was initially used to occlude experimentally created ASDs in lambs: successful implantation was accomplished in six of the eight lambs. Embolization occurred in the remaining two. Complete occlusion of the ASD was noted in four lambs. Endothelialization of the device components was demonstrated in two lambs followed for 1 and 2 months after device deployment.

The clamshell device is composed of two opposing umbrellas made of 4 steel arms covered with woven Dacron material (Figure 1C). The steel arms are hinged together in the center of the device and the springs in the middle of the arm were introduced to facilitate folding back of the umbrellas against each other, thereby creating a clamshell configuration. The device is delivered through an 11 F sheath, a definitive improvement compared to the

sheath size required to implant King's and hooked Rashkind's devices. Several device sizes were manufactured: 17 mm, 23 mm, 28 mm and 33 mm. Balloon stretched diameter of the ASD was measured as in the previous device implantation reports and a device at least 1.6 times larger than stretched ASD diameter was recommended for device placement. The delivery catheter is advanced into the left atrium across the ASD, and its tip positioned in mid-left atrium. The distal arms of the device are opened and the device is withdrawn against the atrial septum until the arms are seen to bend. The sheath is pulled back while keeping the device in position with resultant opening of the proximal arms in the right atrium. After ensuring the stability of the device across the atrial septum by fluoroscopic and echocardiographic imaging, the device is released by activating pin-to-pin mechanism.

The preliminary clinical experience included 17 clamshell device implantations (Rome et al., 1990). This report (Rome et al., 1990) combines the results of implantation of Rashkind double umbrella, prototype clamshell and clamshell devices and therefore the exact clamshell results are difficult to discern. Forty patients were taken to catheterization laboratory with intent to close, and of these, 34 (85%) had implantation of the device. With the exception of one major complication (death secondary to cerebral embolus, presumably related to dislodgment of iliac vein thrombus during placement of device delivery sheath), the procedures were successful. Embolization of the device into the descending aorta at iliac bifurcation occurred in two (6%) patients. The embolized devices were transcatheter retrieved and the patients sent to elective closure of their ASDs. At short-term follow-up, 12 (63%) of 19 who had adequate echocardiographic study had no residual shunts.

Hellenbrand et al reported use of this device; device implantation was attempted in eleven patients aged 13 months to 46 years (Hellenbrand et al., 1990). The device was implanted successfully in ten patients; the single failure was in their youngest patient weighing 11 kg. The procedures were performed under general anesthesia with endotracheal intubation and transesophageal echo-Doppler (TEE) monitoring; they advocated TEE monitoring during the procedure. Residual shunt was present in one (10%) patient. In the study by Boutin et al (1993), residual shunt was present in 91% immediately following device placement. The residual shunts decreased to 53% at a mean follow-up of 10 months. Actuarial analysis indicated progressive reduction of shunt with time (Boutin et al., 1993). Clinical trials by these and other investigators continued (Boutin et al., 1993; Latson, 1993; Perry et al., 1993). However, fractures of the arms of the device were reported in 40 to 84% of implanted devices with occasional embolization (Justo et al., 1996; Perry et al., 1993; Prieto et al., 1996), which were of concern. Consequently, further clinical trials with the device were suspended in 1991 by the investigators and the FDA. Subsequently the device was modified which will be reviewed later in this chapter.

2.4 Buttoned device

Sideris et al described "buttoned device" at about the time of transformation of Rashkind double disk device to clamshell device (Sideris et al., 1990 a & b). The device consisted of three components: occluder, counter-occluder and delivery system. The occluder consisted of an x-shaped, Teflon-coated wire skeleton covered with 1/8-in polyurethane foam (Figure 1 D, left component). The wire skeleton of the occluder can be folded, making the wires parallel, which can then be introduced into an 8-French sheath. When delivered to site of implantation, the occluder springs opens into its original square-shaped structure. A 2-mm

string loop made of silk thread is attached to the center of the occluder; the loop is closed with a 1-mm knot (button). The counter-occluder is composed of a single strand, Teflon-coated wire skeleton covered with rhomboid shaped polyurethane foam (Figure 1 D, right component). A rubber piece is sutured in its center and becomes a buttonhole. The delivery system consisted of a) Teflon-coated 0.035-in guide wire (loading wire), b) a folded 0.008-in nylon thread passing through the guide wire, after having its core removed. The loop of this thread passes through the loop in the center of the occluder, c) an 8-French or 9-French long sheath for device delivery and implantation and d) an 8-French pusher catheter to advance the occluder and counter occluder within the sheath. This may be considered first generation buttoned device. The device was manufactured in 5-mm increments beginning with 25-mm size. The device size was measured by the diagonal length of the occluder and is same as the length of the counter-occluder.

Atrial septal defects were produced in piglets. The buttoned device was successfully implanted in 17 (85%) of 20 attempts. The failures were in the first three animals; presumably related inexperience of the operator and design imperfections (Sideris et al., 1990a). Full occlusion of the ASD and endothelialization of the device was demonstrated in all the 17 successful implantations.

During the preliminary clinical experience with this device (Rao et al., 1992a), minutes after implantation of the device, it spontaneously dislodged from the ASD site in one child. Inspection of the surgically explanted device revealed that the tie binding the occluder with the counter-occluder was torn. It seemed that excessive force was used while buttoning the components of the device across the atrial septum, to ensure adequate buttoning. Based on this undesirable experience, the device was modified by a) strengthening the button-loop by replacing the silk tie with 4-lb proof nylon, b) introducing a radio-opaque marker on the button, so that passage of the buttonhole of the counter-occluder over the button can be visualized by fluoroscopy. Consequently, there will be no need to use excessive force and c) the 1/8-in polyurethane foam covering the wire skeleton was replaced with thinner 1/16-in foam. This is considered second-generation of the buttoned device (Figure 3, left).

While incorporation of radio-opacity in the button made easy visualization of the button (Figure 4), it produced eccentricity of the button (Figure 3, left). This created additional difficulty in buttoning. Therefore, an additional loop of nylon thread was added immediately below the button (Figure 3, middle). This transformed the eccentric button of the second-generation device to be aligned straight, thus making it easier to button the occluder and counter-occluder across the atrial septum; this became third-generation device. Although the prevalence of unbuttoning decreased with the introduction of the additional loop (Rao et al., 1994), buttoning across a thick atrial septum, especially when closing patent foramen ovale for prevention of presumed paradoxical embolism (Ende et al., 1996), became difficult with the radio-opaque wire of the counter-occluder swayed away from radio-opaque button despite "adequate buttoning." This, along with our experience with buttoned device for patent ductus arteriosus (Rao et al., 1993) in which we used two knots (buttons), the device was further modified such that an 8-mm string loop is attached to the occluder with two knots (buttons) on it, 4-mm and 8-mm from the occluder (Figure 3, right). Radio-opaque spring buttons were incorporated into both the knots. A sketch with details of the button loop and photographs of the fourth generation device are shown in figures 5 and 6, respectively.

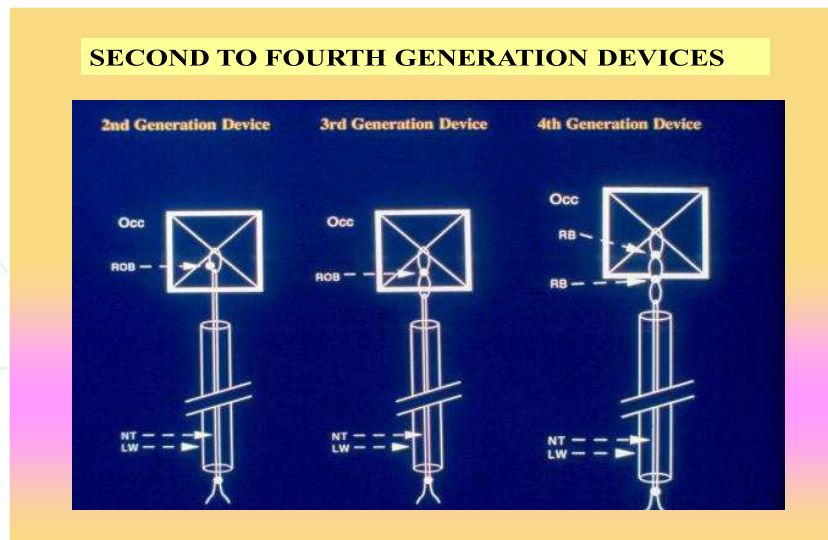


Fig. 3. Second, third and fourth generation buttoned devices; see the text for details. Occ, occluder; ROB, Radio-opaque button, NT, nylon thread; LW, loading wire.




Fig. 4. Selected cinefluorograms in AP view demonstration the buttoning: the occluder (O) and the counter-occluder (CO) are past the radio-opaque button (B). LW, loading wire.

During the initial period of the clinical trials the device delivery required cutting the valve component of the delivery sheath which was then re-attached after loading the device into the sheath (Sideris et al., 1990b; Rao et al., 1991; Rao et al., 1992 a & b). This step was subsequently eliminated by directly loading the device into a short sheath which was then introduced thru' the valve of the delivery sheath (Rao, 2003). During this period the device was directly delivered across the defect. In cases with misplacement or slippage of the occluder into the right atrium, it was difficult to reposition the occluder and it had to be retrieved out of the patient, damaging the device. Therefore, over-the-wire delivery technique was developed. The implantation of the device is similar to direct delivery except the central foam part (close to middle of the X) is pierced with the end of 025" Amplatz wire and the wire is removed at the end of the procedure. The majority of devices were delivered

by the over-the-wire technique in the later part of fourth generation device trials (Rao & Sideris, 1998; Rao et al., 2000; Rao, 2003).

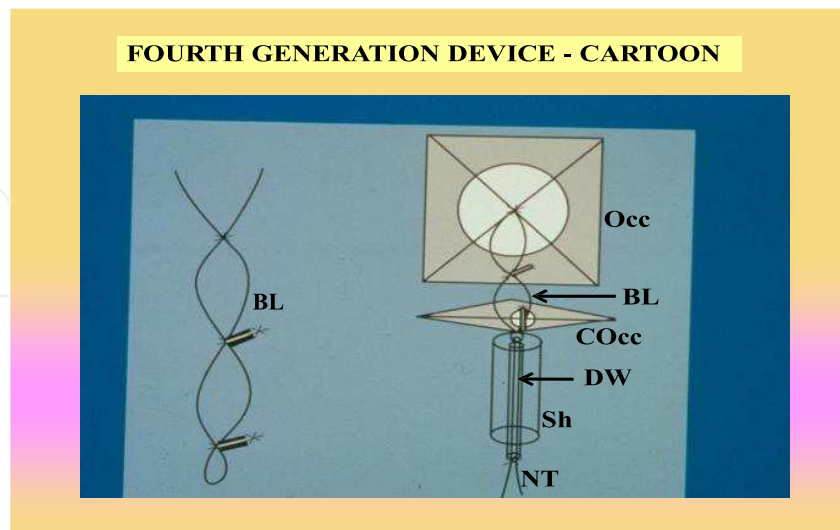


Fig. 5. Cartoon of the fourth generation buttoned device (right) with details of the buttoned loop (BL) (left). The buttoned loop (BL) includes two “spring” buttons positioned 4-mm apart. During buttoning, the spring button becomes straightened in line with the button loop. After buttoning the radio-opaque spring button becomes perpendicular, preventing unbuttoning. COcc, counter-occluder; DW, delivery wire; NT, nylon thread; Occ, occluder; Sh, sheath.




Fig. 6. Photographs of fourth generation buttoned device in multiple views.

Concomitantly a number of other modifications of the device were introduced which include, centering device (Sideris et al., 1996) to center the device over the defect (Figure 7), inverted device (Rao et al. 1997;) to address closure of right to left shunts (Figure 8), centering on demand device (Sideris et al., 1997; Rao & Sideris 2001) to center the device when necessary (Figure 9) and hybrid device (Rao, 2003) to address closure of defects with associated with atrial septal aneurysm (Figure 10).




Fig. 7. Photographs of centering buttoned device with the centering mechanism open (left panel) and closed (right panel).




Fig. 8. Photograph of inverted buttoned device. COc, counter occluder; OCC, Occluder.



Fig. 9. Photographs of centering on demand buttoned device with the centering mechanism open (left panel) and closed (right panel).



Fig. 10. Photograph of a hybrid device with square-shaped counter occluder on the aright atrial side, particular usefully with ASDs with atrial septal aneurysms.

A comprehensive review and comparison from international and US trials of the first four generations of buttoned device and the COD device was presented in 2001 (Rao and Sideris, 2001). The first three generation devices were used during a 3.5-year period ending in February 1993 in 180 patients at 16 institutions around the world (Rao et al., 1994). The ASD size varied between 5 and 25 mm. The device size varied between 25 and 50 mm. Successful implantation rate was 92% (166/180). Effective closure, defined as no (92 patients) or trivial (62 patients) shunt by echocardiography within 24 hours was achieved in 154 patients (92%). Unbuttoning occurred in 13 patients (7.2%) and of these, 10 (5.5%) had surgical retrieval and closure of their ASD. In a 7 -year follow-up study (Rao at al. 2000), residual shunts were closed surgically in 13 and by catheter methodology in 1 patient. In the remaining patients, the shunt either disappeared or decreased. The fourth generation device was implanted during a 4-year period ending in September 1997 in 423 patients at 40 institutions worldwide (Rao et al., 2000). The ASD size varied between 5 and 30 mm (median 17 mm). The device size varied between 25 and 60 mm and the successful implantation rate was 99.8% (422/423). Unbuttoning diminished to 0.9% and device embolization occurred in only one patient. Four patients had device retrieval and subsequent surgical repair and one patient required urgent surgical retrieval and ASD repair. Effective closure, as previously defined, was 90% (377 /417). Follow-up data were available up to a 5-year period in 333 of 417 patients (80%). During this period re-intervention occurred in 21 patients (5%) mainly due to residual shunts. This included 11 patients requiring surgical closure and 9 patients receiving a second device. In the remaining patients, there was a gradual reduction in residual shunt. The COD device was implanted in 65 of 68 patients (95.6%) during an 18 month period ending in July 2000 (Rao and Sideris, 2001). In the remaining 3 patients, the device was not implanted either because of a large defect with deficient rims (n = 1) or because the device was unstable (n = 2). In the latter two patients, the device was transcatheter retrieved, and all three patients underwent successful surgical closure electively. Based on echo-Doppler studies performed within 24 hours of device implantation, effective occlusion defined as no (n = 45; 69%) or trivial (n = 17; 26%) shunt was seen in 62 (95.4%) of 65 patients. In the remaining three, residual shunts were small and were followed-up clinically. One pediatric patient had a suspected thrombus on the

occluder disc, which was treated with tissue plasminogen activator (tPA). The clot resolved without complications. At the time of that report (Rao and Sideris, 2001), short-term follow-up indicated that no further interventions had been required. An updated experience in 80 patients (Rao, 2003) indicated similar results.

The device has also been successfully used to close atrial defects presumed to be responsible for paradoxical embolism and cerebrovascular accidents (Ende et al., 1996), patent foramen ovale causing hypoxemia in platypnea-orthodeoxia syndrome in the elderly (Rao et al., 2001) and persistent right to left shunt associated with previously operated complex congenital cardiac anomalies, including Fontan fenestrations (Rao et al., 1997).

A number of single institutional (Sideris et al., 1990; Rao et al., 1991; Rao et al., 1992a; Rao et al., 1992b; Rao et al., 1995; Arora et al., 1996; Haddad et al., 1996; Worms et al., 1996) and multi-institutional (Rao et al., 1994; Lloyd et al., 1994; Zamora et al., 1998; Rao et al., 1998; Rao & Sideris et al., 1998; Rao et al., 2000; Rao and Sideris, 2001) clinical trials were undertaken which demonstrated feasibility, safety and effectiveness of this device. However, pre-market-approval (PMA) application was not made and consequently the device is not approved by the FDA and is not available for general clinical use.

2.5 Monodisk device

Pavcnik et al (Pavcnik et al., 1993) designed a monodisk device. The device consists of a stainless steel ring constructed with wire coil covered with two layers of nylon mesh. Three hollow pieces of braided stainless steel wires were sutured onto the right atrial side of the device (Figure 11). Three strands of monofilament nylon pass through, one in each of the hollow wires. The nylon thread also passes through the delivery catheter. The entire system

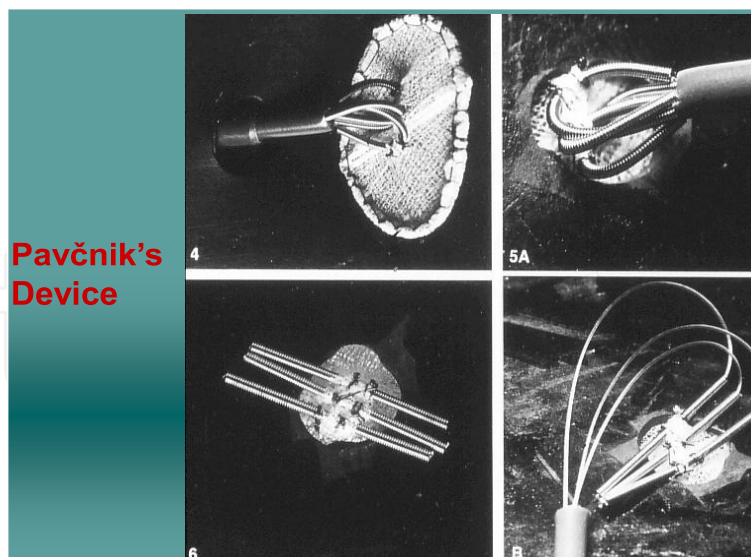


Fig. 11. Photographs of the monodisk device showing tilted side profile of the device after having opened it following passage through a model atrial septal defect (left top). Right atrial views of the device after having the device pulled against the model atrial septal defect prior to (right upper) and after (right lower) releasing flexible wires against the atrial septum are shown. Final position of the device (left lower) after disconnecting device by cutting monofilament nylon.

can be loaded and the device delivered through a 9 F sheath. Once the device is opened in the left atrium, it is withdrawn against the atrial septum so that the hollow wires are positioned onto the right atrial side of the septum (Figure 11, right upper panel). The nylon filaments are cut, which allow the wires to spring back and detach the device from the delivery catheter (Figure 11, right lower and left lower).

Device implantation to occlude five experimentally created ASDs in dogs was undertaken. The position of the device was good in all dogs and there was no residual shunt. In four dogs, postmortem studies were performed six months later, which showed the device to be in place with incorporation into the atrial septum and excellent endothelialization. The device was used successfully in two patients with secundum ASD (personal communication: D. Pavčnik, December 2000). More recently, a biodisk device was developed and animal experimentation suggested that device deployment is feasible, safe and effective (Pavčnik et al., 2010). The authors recommended long-term studies were to evaluate its long-term effectiveness.

2.6 Modified Rashkind PDA umbrella device

The Rashkind PDA umbrella (Rashkind et al., 1987) device was modified by bending the arms of the device such that there is a better apposition of the umbrellas against each other and the atrial septum (Redington & Rigby, 1994). The device was used to occlude four ASDs with left-to-right shunt. In two (50%) patients, the ASD was successfully closed. The remaining two (50%) patients required surgical removal of the device along with closure of the ASD. The device was also used to occlude 11 fenestrated Fontans. In nine patients, there was improvement in oxygen saturation. In the remaining two (18%), the procedure failed. To my knowledge, there are no other reports on the use of this modification by this or other workers. In addition, a similar bend placed in the clamshell device has resulted in breakage of the arms, forcing its removal from use. Therefore, advisability of introducing such a bend in the Rashkind PDA device was questioned (Rao & Sideris, 1995).

2.7 Atrial Septal Defect Occluding System (ASDOS)

Babic and his associates (Babic et al., 1991) described a double umbrella device implanted via arterio-venous guide wire loop in 1991. They named it ASDOS (atrial septal defect occluding system) (Sievert et al., 1995; 1998). In the initial prototype, once the device was locked in place, it required surgical removal for suboptimal positioning. The device underwent further modifications and the updated prototype was released in 1994. This version consists of two major components: (1) a prosthesis consisting of two self-opening umbrellas made of Nitinol wire frame and a thin membrane of polyurethane (Figure 12A) and (2) a delivery system. Each umbrella has five arms, which assume a round shape in the open position. When joined together, the umbrellas assume a discoid shape in profile and a "flower" shape in the frontal view. Umbrella sizes from 25 mm to 50 mm; with 5mm increments were manufactured. This system uses 11-F long sheath for device deployment.

Inter-atrial communications were created with dilatation balloons in 20 pigs and their defects closed with ASDOS device. Examination 3, 4 and 6 months after device closure revealed that devices were completely covered with smooth, scar-like tissue after three months of the procedure (Schneider et al., 1995; Thomsen-Bloch, 1995).




Fig. 12. Photographs of ASDOS (A), Das Angel Wing (B), CardioSEAL (C) and STARFlex (D) devices; see the text for detailed description of the devices.

Initial clinical trials in adult subjects (Babic et al., 1991; Sievert et al., 1995) and children (Hausdorf et al., 1996) demonstrated feasibility of the method and a multi-institutional clinical trial in 20 European institutions began (Sievert et al., 1998). Babic (Babic, 2000; Babic et al., 2003) reviewed the experience with the ASDOS system, including the European multi-institutional study. Between 1995 and 1998, closure was attempted in 350 patients (ASDOS registry, December 1998); 261 had ASDs and 89 had PFOs. It should be noted that 800 patients with ASD were screened and 261 (33%) of these were selected for device closure. Three hundred and eighteen patients (91%) had successful implantation. There were 32 (9%) failures; 26 devices were retrieved via catheter (7%) and 6 devices retrieved by surgery (2%). Early embolization was noted in 3 (0.9%), thromboemboli in 3 (0.9%), perforations in 6 (1.6%) and suspected infections in 2 (0.6%). Embolizations were to the right ventricular outflow tract, the abdominal aorta and the pulmonary artery. There were no late dislodgments or embolizations. Residual shunts were noted in 25% to 30% of patients and in some patients the shunt closed over time. A medium-to-large shunt remained in 8% and the defects were surgically repaired because of no shunt reduction with time. During follow-up, surgical extraction was performed in 11 (3%) patients. The complications include frame fractures in 20% of patients, thrombus formation in 25% patients and atrial wall perforation in 1.5% patients. Presumably because of these complications, the device was renounced by the inventor (Babic et al., 2003) and is not currently used. A modified version with a stent between the umbrellas to provide optimal centering along with other changes was conceived, but not available for clinical use (Babic et al. 2003).

2.8 Das Angel Wing Device

In 1993, Das and his colleagues (Das et al., 1993) designed a self-centering device, delivered transvenously via an 11 F sheath and named it Das Angel Wing Device (Figure 12B). This device had two polyester fabric-covered square frames and a Nitinol frame with midpoint torsion spring eyelets. A circular hole with a diameter equal to one-half of the size of the disk was punched from the right disk with the margins sewn to the left-sided disk forming a

conjoined ring, the centering mechanism (Rickers et al., 1998). Device sizes ranging from 12 to 40 mm were manufactured. The length of the square of the device determines device size.

ASDs were produced surgically in 20 adult canines. Percutaneous closure was attempted in all and was successful in 19 (95%). Following closure, angiography revealed no shunts in 17 and trivial shunts in 2. Six dogs were followed for 2 to 8 months; trivial shunt present in 1 animal immediately after closure had closed by the time of the repeat study. Device embolization was not seen either at the time of device deployment or during follow-up. Microscopy at 8 weeks in 3 dogs showed the devices to be covered by smooth endocardium, enmeshed in mature collagen tissue. The authors conclude that this self-centering device, with effective and safe ASD closure in a canine model, supports its use in human clinical trials (Das et al., 1993).

Clinical trials were undertaken in US and abroad (Rickers et al., 1998; Banerjee et al., 1999). Phase I clinical trial included 90 patients; 50 of these were ostium secundum ASDs (Banerjee et al., 1999; Das et al., 2003). The ASD size varied between 2 and 20 mm. The device size varied between 18 and 35 mm. The device was successfully implanted in 46 (92%) patients; in the remaining four patients surgical retrieval of the mal-positioned device along with surgical closure of ASD was accomplished without additional complications. Significant procedure related complications were seen in three patients. Follow-up echo studies were available in 34 and in 31 of these, there was no residual shunt. A phase II trial involving 47 patients followed with essentially similar results as those of phase I trials (Das et al., 2003). Prior to the conclusion of phase II trial, the investigation was halted in attempts to reconfigure the device. The new device modification, Guardian Angel wing (Angel wing II) included rounded right and left atrial disks, to be easily retrievable, to be easily repositioned and to maintain the self-centering mechanism. Although it was stated that the re-made device will enter clinical trials in the near future (Das et al., 2003), to our knowledge, there has been no further activity reported of either the Angel Wing or Guardian Angel devices; it would appear that the device was shelved.

2.9 CardioSEAL and STARFlex devices

As mentioned in the previous section of this paper, following withdrawal of clamshell device because of breakage of arms (stress fractures), the device was redesigned by replacing stainless steel of the umbrella arms with MP35N, a nonferrous alloy and by introducing an additional bend in the arms of the device; the device was named CardioSEAL (Figure 12 C) in 1996 (Ryan et al., 1998). Subsequently the device was modified to introduce self-centering mechanism by attaching micro springs between the umbrellas, and is named STARFlex (Figure 12 D) in 1998 (Hausdorf et al., 1999).

Both CardioSEAL and STARFlex devices were used in the European multicenter trial (Carminati et al., 2000; Bennhagen et al., 2003) conducted from October 1996 to April 1999; device implantation was attempted in 334 patients with success in 325 (97.3%) patients. Device to balloon stretched ASD diameter ratio was 2.16 (mean). Embolization of the device occurred shortly after the procedure in 13 patients (4%); 12 embolized to the pulmonary artery and one to the left ventricle. In ten patients, surgical retrieval and ASD closure was performed while the remaining three had catheter retrieval with successful re-implantation of another device. One patient had hemiplegia four hours after the procedure. A residual shunt was present in

41% immediately following the procedure, which decreased to 31% at time of discharge and to 21% six and 12 months later. During follow-up surgery was required in two more patients and wire frame fractures were observed in 6.1% patients. The authors concludes that these devices are useful to close small to moderate ASDs and when used to close large defects, complications or less than optimal results are likely. Similar results were reported in the Canadian experience with CardioSEAL device in 50 patients (Pedra et al., 2000).

STARFlex was further modified by replacing Dacron with bio-absorbable materials: BioSTAR and BioTREK; these devices will be discussed in a latter section of this paper.

2.10 Amplatzer septal occluder

In 1997, a new self-expanding Nitinol prosthesis was developed by Dr. Kurt Amplatz, which consists of two self-expandable round disks connected to each other with a short connecting waist (Sharafuddin et al., 1997) and is commonly referred to as Amplatzer septal occluder (Figure 13 A). Nitinol is a nickel-titanium compound consisting of 55% nickel and 45% titanium and has a property of resuming the original shape (shape memory) when deployed. The device size is determined by the waist diameter and ranges from 4 to 40 mm. The disk diameters increase with increasing waist diameters.




Fig. 13. Photographs of Amplatzer septal occluder (A), PFO Occluder (B), fenestrated Amplatzer device (C) and cribriform Amplatzer device (D).

ASDs were created surgically in 15 mini-pigs; the ASD diameter ranged between 10 and 16 mm. Amplatzer septal occluder was used to percutaneously close the ASDs (Sharafuddin et al., 1997). Successful implantation of the device was accomplished in 12 (80%) animals. Angiography revealed complete closure of ASD in 7 of 12 animals immediately after device placement and in 11 of 12 one week later. Fibrous incorporation of the device with neoendothelialization was seen within 3 months. The authors concluded that occlusion of secundum ASDs is feasible with this new device.

The device has been used widely in PFOs, ASDs, and Fontan fenestrations. The results of first clinical trial were reported by Masura in 1997 (Masura et al., 1997). The device was approved by FDA in December 2001 and has since been used extensively worldwide.

Detailed description of the device, implantation procedure and results were described in Chapter 1 and several other chapters in this book and will not be further discussed. Several modifications of the Amplatzer device were introduced: 1. PFO Occluder (Figure 13 B) to close patent foramen ovale (Han et al., 1999), 2. fenestrated Amplatzer device (Figure 13 C) to keep atrial septal defects or Fontan fenestration open to maintain cardiac output (Amin et al., 2002), restrict the size of defect to reduce the atrial shunt (Holtzer et al., 2005) or to serve as pop-off mechanism in severe pulmonary hypertension (Lammers et al., 2007), 3. cribriform device (Figure 13 D) to occlude multiple or fenestrated ASDs (Hijazi et al 2003) and 4. nanoplatinum coating to prevent nickel release from Amplatzer devices (Lertsapcharoen, 2008), thus preventing Kounis syndrome.

2.11 HELEX septal occluder

The HELEX septal occluder is made up of a single length of 0.012-in diameter Nitinol wire covered by an ultra thin membrane of ePTFE. The configuration, once delivered to the site of implantation, was two round and flexible disks (Figure 14 A), one on either side of the ASD. During delivery, the flexible frame is elongated around a central mandrel and fits through a 9F sheath. The wire mandrel except for the central locking mechanism is covered with ePTFE membrane so that only a small portion of Nitinol wire is exposed in the vascular system. Several sizes from 15 to 35 mm, in 5 mm increments were manufactured.

Device closure was performed in 24 dogs with surgically created ASDs with 100% successful implantation. Initial occlusion rate of 88% was found by transesophageal echocardiography which improved to 100% at 2-week follow-up (Zahn et al., 1999; 2001). These animal studies also demonstrated coverage of the defect components with fibrous connective tissue followed by neo-endothelialization, usually within three months.

The first clinical implant was performed by in 1999 (Latson et al., 2000), and the Food and Drug Administration phase I feasibility trial began in 2000. Feasibility study involving 63 patients, multicenter pivotal study including 143 subjects and continued access study that enrolled 156 patients (Feldman, 2010) demonstrated feasibility, safety and effectiveness of the device. The HELEX occluder was approved by FDA in 2006 and from then on it has been used extensively worldwide for closing small to medium sized ASDs and PFOs.

2.12 Sideris' Wire-less devices including transcatheter patch

Majority of ASD-occluding devices are double disc devices with wire components and have limitations. The major disadvantages are requirement of sufficient septal rims to hold the device in place and complications related to wire components (wire fractures and perforations) of the device. To address these problems, Sideris and colleagues developed wireless, transcatheter-implantable devices to occlude large ASDs (Sideris et al., 1999 a & b; Zamora et al., 2000; Sideris, 2003). Two devices were developed (Sideris, 2003): detachable balloon device and the transcatheter patch (Figure 14 B).

The detachable balloon device (DBD) consisted of balloon occluder, made from Latex in different sizes and a floppy disk, similar to the counter occluder described in the buttoned device section above. The DBDs were used to occlude of experimentally created ASDs in 20 piglets (Sideris et al., 2000a); in three experiments detachable double balloon devices were

used. One device embolized into the descending aorta and complete occlusion was noticed in remaining pigs. Follow-up studies revealed that the detachable balloons lost their content and became flat in approximately two months and the device was covered by endothelial tissue in 3 to 4 weeks. Human feasibility study (Sideris et al., 1999a) involved six ostium secundum ASDs (among others); one device embolized, one patient had residual shunt which increased over time and four had good occlusion.

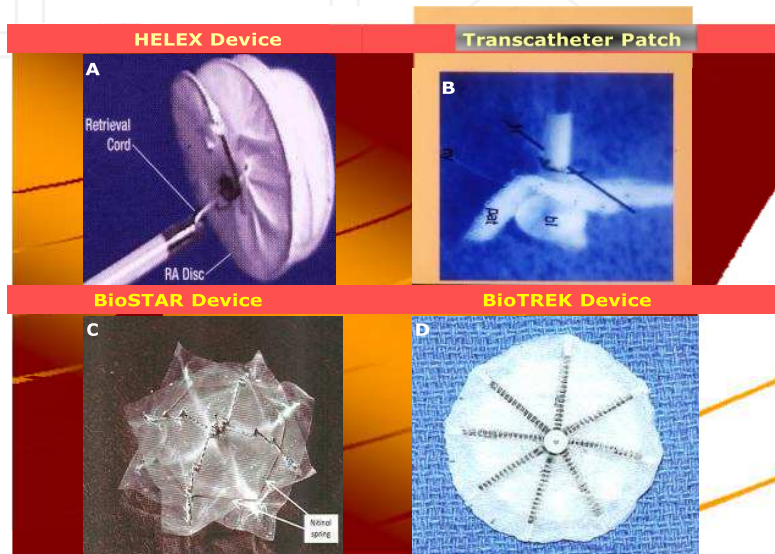


Fig. 14. Photographs of HELEX device (A), transcatheter patch (B), BioSTAR device (C) and BioTREK device (D).

The transcatheter patch device consisted of a flat or sleeve patch, a balloon support catheter and a safety thread; the patch, made up of polyurethane foam, covers the distal balloon. The occluding distal balloon (balloon/patch) is inflated at volumes 2 mm larger than the test-occluding diameter of the defect and held in place. The balloons were deflated and removed 48 hours later. This device was also tried in 20 experimentally created ASDs (Sideris et al., 2000b); ten were flat patches and ten sleeve patches. The patches were supported by balloon catheters from one to six days. Good occlusion of ASDs was seen if the supporting catheter was withdrawn 48 hours or later. Histological studies revealed formation fibrin and inflammatory cells. The sleeve patch appeared to be better centered over the defect than a flat patch. Initial clinical trials were performed in a limited number of patients (Sideris, 2003). Subsequently (Sideris et al., 2010), a larger number (N=74) of patients participated in the clinical trial. The age of the subjects varied from 1.5 to 67 years and their defect sizes were from 13 to 35 mm (mean=25) in diameter; 88% had effective occlusion immediately after deployment of the patch which increased to 96% at follow-up (Sideris et al., 2010).

Initially, this device required keeping the balloon in place up to 48 hours to allow the patch to adhere to the septal wall, an obvious disadvantage of this technique (King & Mills, 2010). To address this problem, Sideris et al (2010) developed accelerated release technique by applying polyethylene glycol-based surgical adhesive to the surface of the patch immediately prior to its implantation. This method was used in 9 patients with ASD diameters ranging from six and 25 mm. Effective occlusion immediately after implantation occurred in 78% which improved to 100% a follow-up. An immediate release patch (IRP)

was developed which uses a single latex balloon, a safety bioabsorbable thread (Vicryl, Ethicon, a Johnson & Johnson company, Somerville, NJ) and polyurethane patch with surgical adhesive that was used in accelerated release technique. The addition of the adhesive makes the device release immediate and attachment to the septum (mediated by fibrin formation) takes place in approximately 48 hours (Sideris et al., 2010). The IRP was used in 10 subjects with defects ranging from 12 to 26 mm; 100% full occlusion both at implantation and at follow-up was reported (Sideris et al., 2010). Further clinical trials are planned.

2.13 New devices

Subsequent to the development of the devices reviewed in the preceding sections additional devices were designed and tested. None of these are approved by the FDA for routine clinical use and will be reviewed briefly.

These devices, to the best of our knowledge, are bio-absorbable NMT devices (Bio-STAR and Bio-TREK), Occlutech device, Cardia devices (INTRASEPT, ATRIASEPT I/II-ASD and ULTRASEPT), Solysafe Septal Occluder, pfm ASD-R device, Heart R Septal Occluder (manufactured in China) and others.

2.13.1 BioSTAR and BioTREK

When occluding devices are implanted to close ASDs, the left atrium is essentially inaccessible, should trans-septal intervention becomes necessary later in life such as mapping and ablation of left-sided accessory pathways, mitral valve interventions, left atrial appendage occlusion and others. To address this concern, NMT Medical Inc. (Boston, MA) modified the STARFlex device by replacing Dacron with heparin-coated, acellular, tissue engineered, porcine intestinal collagen matrix that allows absorption and replacement of the membrane with human tissue, and was named BioSTAR (Figure 14C). Studies in sheep model (Jux et al., 2003; 2006) demonstrated rapid endothelialization of the device and resorption of intestinal collagen matrix over a period of 2 years. Feasibility, safety, and effectiveness of closure of ASDs with BioSTAR both in adults (Mullen et al., 2006) and children (Hoehn et al., 2010) were demonstrated.

The supporting arms (ribs) of the BioSTAR device however, continue to be metallic and are not bio-absorbable. BioTREK device (Figure 14 D) was developed and designed to be 100% reabsorbable. The covering discs as well as support ribs are made up of poly-4-hydroxybutyrate. Over time, the patches and the connecting ribs disappear, leaving the fibrous septum. The device was reported in preclinical testing (Kramer, 2010). Other workers are developing additional biodegradable devices (Duong-Hong et al., 2010).

2.13.2 Occlutech

Occlutech septal occluder, initially designed to close PFOs (Krizanic et al. 2008) has been modified to close ASDs. The device is similar to Amplatzer in design (double-disc device composed of self-expanding Nitinol mesh wire), but with use of unique braiding technology; the amount of metal is reduced by 50%. In addition, the left atrial hub is removed. The devices were implanted in 29 patients with PFO and in 12 patients with ASD.

TEE studies showed a residual shunt in 11.2% after 60 days in patients with PFO and a left-to-right shunt in 9.1% of the remaining patients with ASD. After 180 days only 1 patient (3.7%) with PFO had a right-to-left shunt. No residual shunts were observed in the patients with ASD (Krizanic et al., 2010).

2.13.3 Cardia devices (INTRASEPT, ATRIASEPT I/II-ASD and ULTRASEPT)

PFO-Star device, consisting of Ivalon foam double umbrella was developed in late 1990s by Cardia Inc. (Eagan, MN) for percutaneous closure of PFOs (Braun et al., 2002; Schraeder et al., 2003). This device may be considered Generation I and was modified several times, addressing its deficiencies with resultant development of Generation II, Generation III, Generation IV (INTRASEPT), Generation V (ATRIASEPT I-ASD and ATRIASEPT II-ASD) and Generation VI (ULTRASEPT) devices (Turner & Forbes, 2010). Generation V and VI devices were designed to deal with ostium secundum ASDs. Clinical trials with ATRIASEPT I-ASD device (Stolt et al., 2010; Turner & Forbes, 2010) showed favorable early results. Clinical trials with ATRIASEPT II-ASD and ULTRASEPT devices are planned (Turner & Forbes, 2010).

2.13.4 Solysafe septal occluder

The Solysafe Septal Occluder device (Swissimplant AG, Solothurn, Switzerland), designed by Dr. Lazlo Solymar of Gothenburg, consists of two foldable polyester patches attached to eight cobalt-based alloy (Phynox) wires. The course of the wires through the patches enables the device to center itself within the defect. The maximum diameter is given by the distance of the wires that are fixed in the patches. Several sizes, 25 mm thru' 44 mm are manufactured (Ewert, 2010). Two clinical trials with 44 and 32 patients (Ewert et al., 2008, Kretschmar et al., 2010) respectively were reported with implantation rates of 87% and closure rate of 100% at six month follow-up. The worldwide experience with this device was said to approximate 1,400 patients (Ewert, 2010).

2.13.5 The pfm ASD-R device

The pfm ASD-R devices were made up of tightly woven single piece of Nitinol wire mesh without welding or hubs and in their final form have a double-disc configuration. Animal experimentation in pigs revealed complete endothelialization in three weeks without significant inflammatory reaction (Granja & Freudenthal, 2010). The initial clinical application in 23 patients demonstrated good results and a multi-institutional phase II clinical trial in Argentina is planned (Granja & Freudenthal, 2010).

2.13.6 Other devices

Other devices such as Cardi-O-Fix Septal Occluder, Heart R Septal Occluder, cocoon, Lifetech device (also called sears device), some manufactured in China and others that may have escaped detection by our literature search may be in development.

3. Closure of patent foramen ovale

Some cerebrovascular accidents and other systemic arterial emboli, especially in young subjects are presumed to be due to paradoxical embolism through an atrial defect, most

frequently a patent foramen ovale (PFO). Closure of such atrial defects is an alternative option to life-long anticoagulation. Non-surgical transcatheter occlusion of such a defect was first reported with King's device in 1976 (Mills & King, 1976). Mills and King effectively occluded an atrial defect with a 25 mm device in a 17-year-old male who had a hemiparetic stroke secondary to paradoxical embolism. Subsequently, clamshell (Bridges et al., 1992) and buttoned (Rao et al., 1992 a & b; Chandar et al., 1996; Ende et al., 1996) devices have been used to successfully occlude PFOs presumed to be the site of paradoxical embolism.

In addition, some PFOs are considered to be the seat of right to left shunt causing hypoxemia as seen in platypnea-orthodeoxia syndrome. Right to left shunt thru' PFO can also occur in patients who were previously treated for complex congenital cardiac anomalies including Fontan fenestrations as well as in patients who had right ventricular infarction. Decompression (Caisson's) illness and migraine have also been attributed to right to left shunt across PFO.

Majority of the ASD devices described in the preceding sections, as and when they became available, have also been used to close PFOs to address the above listed conditions. Moreover, either the existing devices were modified to address the anatomic features of the foramen ovale or new devices were designed to specifically address the PFOs and these include, Amplatzer PFO occluder, Cardia devices (PFO-Star and several of its subsequent generations), Premere occluder, Coherex Flat stent, PFX Closure System (not a device but employs monopolar radio frequency energy to effect closure of a PFO by welding the tissues of the septum primum with the septum secundum), pfm PFO-R, Solysafe PFO occluder and others. Because of limitation in space and the intent to mainly address history of ASD device closure, no further discussion of PFOs will be included.

4. Summary and conclusion

In this chapter, historical aspects of transcatheter atrial septal occluding devices are reviewed. Since the initial description of an ASD closing devices by King, Rashkind and their associates, a large number of single disc and double disc devices have been designed

and tested in animal models followed by clinical trials in human subjects. Feasibility, safety and effectiveness have been demonstrated with most devices. However, design, redesign, testing and re-testing have been the typical path with most devices. Currently, only two devices are approved by the FDA in the US and these are: Amplatzer septal occluder and HELEX septal occluder. Several other devices are in development, some at the stage of animal experimentation and some in clinical trials in Europe or US. We will await for additional devices to be approved for general clinical use so that the practicing interventional cardiologist will have several devices at his/her disposal so that an appropriate device that suits best for a given patient and his/her defect. A brief review of historical aspects of PFO closure was also included.

5. References

- [1] Amin, Z.; Danford, D. A.; Pedra, C. A. (2002). A new Amplatzer device to maintain patency of Fontan fenestrations and atrial septal defects. *Catheter Cardiovasc Interv*, Vol. 57, No. 2, pp. 246-251

- [2] Arora, R.; Trehan, V. K.; Karla, G. S.; et al. (1996). Transcatheter closure of atrial septal defect using buttoned device: Indian experience. *Indian Heart J*, Vol. 48, No.2, pp. 145-149
- [3] Babic, U. (2000). Experience with ASDOS for transcatheter closure of atrial septal defect and patent foramen ovale. *Curr Intervent Cardiol Rep*, Vol. 2, No. 2, pp. 177-183
- [4] Babic, U. U.; Grujicic, S.; Popvic, Z.; et al. (1991). Double-umbrella device for transvenous closure of patent ductus arteriosus and atrial septal defect: first clinical experience. *J Intervent Cardiol*, Vol. 4, No. 4, pp. 283-294
- [5] Babic, U.; Sievert, H.; Schneider, M.; Babic, M. (2003). ASDOS-Atrial Septal Defect Occluder System, In: *Catheter Based Devices for Treatment of Noncoronary Cardiovascular Disease in Adults and Children*, P. S. Rao, M. J. Kern (Eds.): 35-43, Lippincott, Williams & Wilkins, Philadelphia, PA, USA.
- [6] Banerjee, A.; Bengur, A. R.; Li, J. S.; et al. (1999). Echocardiographic characteristics of successful deployment of the Das Angel Wings atrial septal defect closure device: initial multicenter experience in the United States. *Am J Cardiol*, Vol. 83, No. 8, pp. 1236-1241
- [7] Beekman, R. H.; Rocchini, A. P.; Snider, A. R.; et al. (1989). Transcatheter atrial septal defect closure: preliminary experience with the Rashkind occluder device. *J Intervent Cardiol*, Vol. 2, No. 1, pp. 35-41
- [8] Bennhagen, R. G.; McLaughlin, P., Benson, L. N. (2003). CARDIOSEAL AND STARFLEX DEVICES, In: *Catheter Based Devices for Treatment of Noncoronary Cardiovascular Disease in Adults and Children*, P. S. Rao & M. J. Kern (Eds.): 61-69, Lippincott, Williams & Wilkins, Philadelphia, PA, USA.
- [9] Bigelow, W. G.; Lindsey, W. E. & Greenwood, W. F. (1950). Hypothermia, it's possible role in cardiac surgery. *Ann Surg*, Vol. 132, No. 5, pp. 849-866
- [10] Boutin, C.; Musewe, N. N.; Smallhorn, J. F.; et al. (1993). Echocardiographic follow-up of atrial septal defect after catheter closure by double-umbrella device. *Circulation*, Vol. 88, No. 2, pp. 621-627
- [11] Braun, M. U.; Fassbender, D.; Schoen, S. P.; et al. (2002). Transcatheter closure of patent foramen ovale in patients with cerebral ischemia. *J Am Coll Cardiol*, Vol. 39, No. 12, pp. 2019-2025
- [12] Bridges, N. D.; Hellenbrand, W.; Latson, L.; et al. (1992). Transcatheter closure of patent foramen ovale after presumed paradoxical embolism. *Circulation*, Vol. 86, No. 6, pp. 1902-1908
- [13] Carminati, M.; Giusti, S.; Hausdorf, G.; et al. (2000). A European multicentre experience using the CardioSEAL® and Starflex double umbrella devices to close interatrial communications holes within the oval fossa. *Cardiol Young*, Vol. 10, No. 5, pp. 519-526
- [14] Chandar, J. S. ; Rao, P. S. ; Lloyd, T. R. ; et al. (1999). Atrial septal defect closure with 4th generation buttoned device: results of US multicenter FDA Phase II clinical trial (Abstract). *Circulation*, Vol. 100, Suppl - I-708
- [15] Das, G. S.; Harrison, J. K. & O'Laughlin, M. P. (2003). The Angel Wings Das device. In: *Catheter based devices for the treatment of non-coronary cardiovascular disease in adults and children*. P. S. Rao & M. J. Kern (Eds): 45-49, Lippincott Williams & Wilkins, Philadelphia, PA, USA

- [16] Das, G. S.; Voss, G.; Jarvis, G.; et al. (1993). Experimental atrial septal defect closure with a new, transcatheter, self-centering device. *Circulation*, Vol. 88, No. 4, pp. 1754-1764
- [17] Duong-Hong, D.; Tang, Y. D. & Wu, W. (2010). Fully biodegradable septal defect occluder-a double umbrella design. *Catheter Cardiovasc Interv*, Vol. 76, No. 5, pp. 711-718
- [18] Ende, D. J.; Chopra, P. S. & Rao, P. S. (1996). Prevention of recurrence of paradoxical embolism: mid-term follow-up after transcatheter closure of atrial defects with buttoned device. *Am J Cardiol*, Vol. 78, No. 2, pp. 233-236
- [19] Ewert, P. (2010). The Solysafe septal occluder for the closure of ASDs and PFOs. In: *Transcatheter closure of ASDs and PFOs: A comprehensive assessment*, Z. M. Hijazi, T. Feldman, M. H. Abdullah A Al-Qbandi, & H. Sievert (Eds): 417-422, Cardiotext, Minneapolis, MN, USA
- [20] Ewert, P.; Soderberg, B.; Dahnert, I.; et al. (2008). ASD and PFO closure with the Solysafe septal occluder-Results of a prospective multicenter pilot study. *Cathet Cardiovasc Intervent*, Vol. 71, No. 3, pp. 398-402
- [21] Feldman, T. (2010). The GORE HELEX septal occluder. In: *Transcatheter closure of ASDs and PFOs: A comprehensive assessment*, Z. M. Hijazi, T. Feldman, M. H. Abdullah A Al-Qbandi, & H. Sievert (Eds): 355-368, Cardiotext, Minneapolis, MN, USA
- [22] Galal, M. O.; Wobst, A.; Halees, Z.; et al. (1994). Perioperative complications following surgical closure of atrial septal defect type II in 232 patients - a baseline study. *Europ Heart J*, Vol. 15, No. 10, pp. 1381-1384
- [23] Gibbon, J. H., Jr. (1953) Application of a mechanical heart and lung apparatus to cardiac surgery. In: *Recent Advances in Cardiovascular Physiology and Surgery*, J. H. Gibbon, Jr (ed): 107-113, University of Minnesota, Minneapolis, MN, USA
- [24] Granja, M. & Freudenthal, F. (2010). The pfm device for ASD closure. In: *Transcatheter closure of ASDs and PFOs: A comprehensive assessment*. Z. M Hijazi, T. Feldman, M. H. Abdullah A Al-Qbandi, & H. Sievert (Eds): 423-429, Cardiotext, Minneapolis, MN, USA
- [25] Haddad, J.; Secches, A.; Finzi, L.; et al. (1996). Atrial septal defect: percutaneous transvenous occlusion with the buttoned device. *Arq Bras Cardiol*, Vol. 67, No. 1, pp. 17-22
- [26] Han, Y. ; Gu, X. ; Titus, J. L. ; et al. (1999). New self-expanding patent foramen ovale occlusion device. *Cathet Cardiovasc Intervent*, Vol. 47, No. 3, pp. 370-376
- [27] Holzer, R.; Cao, Q. L. & Hijazi, Z. M. (2005). Closure of a moderately large atrial septal defect with a self-fabricated fenestrated Amplatzer septal occluder in an 85- year-old patient with reduced diastolic elasticity of the left ventricle. *Catheter Cardiovasc Interv*, Vol. 64, No. 4, pp. 513-518
- [28] Hausdorf, G.; Kaulitz. R. & Paul T. (1999). Transcatheter closure of atrial septal defect with a new flexible, self-centering device, The Starflex Occluder. *Am Heart J*, Vol. 84, No. 9, pp. 1113-1116
- [29] Hausdorf, G.; Schneider, M.; Franzbach, B.; et al. (1996). Transcatheter closure of secundum atrial septal defects with the atrial septal defect occlusion system (ASDOS): initial experience in children. *Heart*, Vol. 75, No. 1, pp. 83-88
- [30] Hellenbrand, W. E.; Fahey, J. T.; McGowan, F. X.; et al. (1990). Transesophageal echocardiographic guidance of transcatheter closure of atrial septal defect. *Am J Cardiol*, Vol. 66, No. 2, pp. 207-213

- [31] Hijazi, Z. M. & Cao, Q-L. (2003). Transcatheter closure of multi-fenestrated atrial septal defects using the new Amplatzer cribriform device. *Congenital Cardiology Today*, Vol. 1, No. 1, pp. 1-4
- [32] Hoehn, R.; Hesse, C.; Ince, H. & Peuster, M. (2010). First experience with the BioSTAR-device for various applications in pediatric patients with congenital heart disease. *Catheter Cardiovasc Interv*, Vol. 75, No. 1, pp. 72-77
- [33] Justo, R. N.; Nykanen, D. G.; Boutin, C.; et al. (1996). Clinical impact of transcatheter closure of secundum atrial septal defects with double umbrella device. *Am J Cardiol*, Vol. 77, No. 10, pp. 889-892
- [34] Jux, C.; Bertram, H.; Wohlsein, P.; et al. (2006). Interventional atrial septal defect closure using a totally bioresorbable occluder matrix: development and preclinical evaluation of the BioSTAR device. *J Amer Coll Cardiol*, Vol. 48, No. 1, pp. 161-169
- [35] Jux, C.; Wohlsein, P.; Bruegmann, M.; et al. (2003). A new biological matrix for septal occlusion. *J Interv Cardiol*, Vol. 16, No. 2, pp. 149-52
- [36] King, T. D. & Mills, N. L. (1974). Nonoperative closure of atrial septal defects. *Surgery*, Vol. 75, No. 3, pp. 383-388
- [37] King, T. D.; Thompson, S. L.; Steiner, C.; et al. (1976). Secundum atrial septal defect: nonoperative closure during cardiac catheterization. *J Am Med Assoc*, Vol. 235, No. 25, pp. 2506-2509
- [38] King, T. D.; Thompson, S. L.; Steiner, C.; et al. (1978). Measurement of atrial septal defect during cardiac catheterization: experimental and clinical trials. *Am J Cardiol*, Vol. 41, No. 3, pp. 537-542
- [39] King, T. D & Mills, N. L. (2010). Historical perspectives on ASD device closure. In: *Transcatheter closure of ASDs and PFOs: A comprehensive assessment*, Z. M. Hijazi, T. Feldman, M. H. Abdullah A Al-Qbandi, & H. Sievert (Eds): 423-429, Cardiotext, Minneapolis, MN, USA
- [40] Kramer, P. (2010). The CardioSEAL/STARFlex family of devices for closure of atrial level defects. In: *Transcatheter closure of ASDs and PFOs: A comprehensive assessment*, Z. M. Hijazi, T. Feldman, M. H. Abdullah A Al-Qbandi, & H. Sievert (Eds): 483-399, Cardiotext, Minneapolis, MN, USA
- [41] Kretschmar, O.; Sglimbea, A.; Daehnert, I.; et al. (2010). Interventional closure of atrial septal defects with the Solysafe Septal Occluder--preliminary results in children. *Int J Cardiol*, Vol. 143, No. 3, pp. 373-377
- [42] Krizanic, F.; Krizanic, F.; Sievert, H.; et al. (2010). The Occlutech Figulla PFO and ASD Occluder: A New Nitinol Wire Mesh Device for Closure of Atrial Septal Defects. *J Invasive Cardiol*, Vol. 22, No. 4, pp. 182-187
- [43] Krizanic, F.; Sievert, H.; Pfeiffer, D.; et al. (2008). Clinical evaluation of a novel occluder device (Occlutech) for percutaneous transcatheter closure of patent foramen ovale (PFO). *Clin Res Cardiol*, Vol. 97, No. 12, pp. 872- 877
- [44] Krizanic, F.; Sievert, H.; Pfeiffer, D.; et al. (2010). The Occlutech Figulla PFO and ASD occluder: a new nitinol wiremesh device for closure of atrial septal defects. *J Invasive Cardiol*, Vol. 22, No. 4, pp. 182-187
- [45] 45. Lammers, A. E.; Derrick, G.; Haworth, S. G.; et al. (2007). Efficacy and long-term patency of fenestrated Amplatzer devices in children. *Catheter Cardiovasc Interv*, Vol. 70, No. 4, pp. 578-584

- [46] Latson, L. A. (1993). Transcatheter closure of atrial septal defects. In: *Transcatheter Therapy in Pediatric Cardiology*, P. S. Rao (ed): 335-348, Wiley-Liss, New York, NY, USA
- [47] Latson, L.; Zahn, E. & Wilson N. (2000). HELEX septal occluder for closure of atrial septal defects. *Curr Intervent Cardiol Rep*, Vol. 2, No. 3, pp. 268-273
- [48] Lertsapcharoen, P.; Khongphatthanayothin, A.; Srimahachota, S. & Leelanukrom, R. (2008). Self-expanding platinum-coated nitinol devices for transcatheter closure of atrial septal defect: prevention of nickel release. *J Invasive Cardiol*, Vol. 20, No. 6, pp. 279-283
- [49] Lewis, F. J. & Tauffic, M. (1953). Closure of atrial septal defects with the aid of hypothermia: experimental accomplishments and the report of one successful case. *Surg*, Vol. 33, No. 1, pp. 52-59
- [50] Lloyd, T. R.; Rao, P. S.; Beekman, R. H., III.; et al. (1994). Atrial septal defect occlusion with the buttoned device: a multi-institutional U.S. trial. *Am J Cardiol*, Vol. 73, No. 4, pp. 286-291
- [51] Lock, J. E. ; Cockerham J. T.; Keane, J. F.; et al. (1987). Transcatheter umbrella closure of congenital heart defects. *Circulation*, Vol. 75, No. 3, pp. 593-599
- [52] Lock, J. E. ; Rome, J. J.; Davis, R.; et al. (1989). Transcatheter closure of atrial septal defects: experimental studies. *Circulation*, Vol. 79, No. 5, pp. 1091-1099
- [53] Masura, J.; Gavora, P.; Formanek, A. & Hijazi, Z. M. (1997). Transcatheter closure of secundum atrial septal defects using the new self-centering Amplatzer septal occluder: initial human experience. *Cathet Cardiovasc Diagn*, Vol. 42, No. 4, pp. 388-393
- [54] Mills, N. L. & King, T. D. (1976). Nonoperative closure of left-to-right shunts. *J Thorac Cardiovasc Surg*, Vol. 72, No. 3, pp. 371-378
- [55] Mullen, M. J.; Hildick-Smith, D.; De Giovanni, J. V.; et al. (2006). BioSTAR Evaluation Study (BEST): a prospective, multicenter, phase I clinical trial to evaluate the feasibility, efficacy, and safety of the BioSTAR bioabsorbable septal repair implant for the closure of atrial-level shunts. *Circulation*, Vol. 114, No. 18, pp. 1962-1967
- [56] Murphy, J. G.; Gersh, B. J.; McGoon, M. D.; et al. (1990). Long-term outcome after surgical repair of isolated atrial septal defect. *New Engl J Med*, Vol. 323, No. 24, pp. 1645-1650
- [57] Pastorek, J. S.; Allen, H. D. & Davis, J. T. (1994). Current outcomes of surgical closure of secundum atrial septal defect. *Am J Cardiol*, Vol. 74, No. 2, pp. 175-179
- [58] Pavcnik, D.; Takulve, K.; Uchida, B. T.; et al. (2010). Biodisk: a new device for closure of patent foramen ovale: a feasibility study in swine. *Catheter Cardiovasc Interv*, Vol. 75, No. 6, pp. 861-867
- [59] Pavcnik, D.; Wright, K. C. & Wallace, S. (1993). Monodisk: device for percutaneous transcatheter closure of cardiac septal defects. *Cardiovasc Intervent Radiol*, Vol. 16, No. 5, pp. 308-312
- [60] Pedra, C. A. C.; Pihkala, J.; Lee, K-J.; et al. (2000). Transcatheter closure of the atrial septal defects using the CardioSeal implant. *Heart*, Vol. 84, No. 3, pp. 320-326
- [61] Perry, S. B.; Van der Velde, M. E.; Bridges, N. D.; et al. (1993). Transcatheter closure of atrial and ventricular septal defects. *Herz*, Vol. 18, No. 2, pp. 135-142

- [62] Prieto, L. R.; Foreman, C. K.; Cheatham, J. P.; et al. (1996). Intermediate-term outcome of transcatheter secundum atrial septal defect closure using Bard clamshell septal umbrella. *Am J Cardiol*, Vol. 78, No. 11, pp. 1310-1312
- [63] Rao, P. S. Buttoned Device. (2003) In: *Catheter based devices for the treatment of non-coronary cardiovascular disease in adults and children*, P. S. Rao & M. J. Kern (Eds): 17-34, Lippincott Williams & Wilkins, Philadelphia, PA, USA
- [64] Rao, P. S.; Berger, F.; Rey, C.; et al. (2000). Transvenous occlusion of secundum atrial septal defects with 4th generation buttoned device: comparison with 1st, 2nd and 3rd generation devices. *J Am Coll Cardiol*, Vol. 36, No. 2, pp. 583-592
- [65] Rao, P. S.; Chander, J. S. & Sideris, E. B. (1997). Role of inverted buttoned device in transcatheter occlusion of atrial septal defects or patent foramen ovale with right-to-left shunting associated with previously operated complex congenital cardiac anomalies. *Am J Cardiol*, Vol. 80, No. 7, pp. 914-921
- [66] Rao, P. S. Ende, D. J.; Wilson, A. D.; et al. (1995). Follow-up results of transcatheter occlusion of atrial septal defects with buttoned device. *Cand J Cardiol*, Vol. 11, No. 8, pp. 695-701
- [67] Rao, P. S.; Palacios, I. F.; Bach, R. G.; et al. (2001). Platypnea- Orthodeoxia Syndrome: Management by Transcatheter Buttoned Device Implantation. *Cathet Cardiovasc Intervent*, Vol. 54, No. 1, pp. 77-82
- [68] Rao, P. S. & Sideris, E. B. (1995). Transcatheter occlusion of cardiac defects [letter]. *Br Heart J*, Vol. 73, No. 6, pp. 585-586
- [69] Rao, P. S. & Sideris, E. B. (1998). Buttoned device closure of the atrial septal defect. *J Interventional Cardiol*, Vol. 11, No. 5, pp. 467-484
- [70] Rao, P. S. & Sideris, E. B. (2001). Centering-on-demand buttoned device: Its role in transcatheter occlusion of atrial septal defects. *J Intervent Cardiol*, Vol. 14, No. 1, pp. 81-89
- [71] Rao, P. S.; Sideris, E. B. & Chopra, P. S. (1991). Catheter closure of atrial septal defect: successful use in a 3.6 kg infant. *Am Heart J*, Vol. 121, No. 6, pp. 1826-1829
- [72] Rao, P. S.; Sideris, E. B.; Haddad, J.; et al. (1993). Transcatheter occlusion of patent ductus arteriosus with adjustable buttoned device: initial clinical experience. *Circulation*, Vol. 88, No. 3, pp. 1119-1126
- [73] Rao, P. S.; Sideris, E. B.; Hausdorf, G.; et al. (1994). International experience with secundum atrial septal defect occlusion by the buttoned device. *Am Heart J*, Vol. 128, No. 5, pp. 1022-1035
- [74] Rao, P. S.; Sideris, E. B.; Rey, C.; et al. (1998). Echo-Doppler follow-up evaluation after transcatheter occlusion of atrial septal defects with the buttoned device. In: *Proceedings of the Second World Congress of Pediatric Cardiology and Cardiac Surgery*, Y. Imai & K. Momma (Eds): 197-200, Futura Publishing Co, Armonk, NY, USA
- [75] Rao, P. S.; Wilson, A. D.; Levy, J. M.; et al. (1992a). Role of "buttoned" double-disc device in the management of atrial septal defects. *Am Heart J*, Vol. 123, No. 1, pp. 191-200
- [76] Rao, P. S, Wilson, A. D.; Chopra, P. S. (1992b). Transcatheter closure of atrial septal defects by "buttoned" devices. *Am J Cardiol*, Vol. 69, No. 12, pp. 1056-1061
- [77] Rashkind, W. J. (1975). Experimental transvenous closure of atrial and ventricular septal defects. *Circulation*, Vol. 52, Suppl-II-8

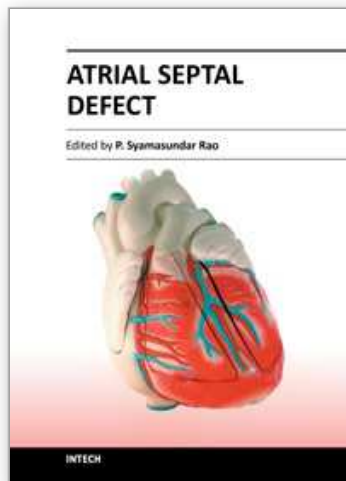
- [78] Rashkind, W. J. (1983). Transcatheter treatment of congenital heart disease. *Circulation*, Vol. 67, No. 4, pp. 711-716
- [79] Rashkind, W. J. & Cuaso, C. E. (1977). Transcatheter closure of atrial septal defects in children. *Eur J Cardiol*, Vol. 8, No. pp. 119-120
- [80] Rashkind, W. J.; Mullins, C. E.; Hellenbrand, W. E.; et al. (1987). Non-surgical closure of patent ductus arteriosus: clinical applications of the Rashkind PDA occluder system. *Circulation*, Vol. 75, No. 3, pp. 583-592
- [81] Rashkind, W. J.; Tait, M. A. & Gibson, R. J., Jr. (1985). Interventional cardiac catheterization in congenital heart disease. *Internat J Cardiol*, Vol. 7, No. 1, pp. 1-11
- [82] Redington, A. N. & Rigby, M. L. (1994). Transcatheter closure of interatrial communication with a modified umbrella device. *Br Heart J*, Vol. 72, No. 4, pp. 372-377
- [83] Rickers, C.; Hamm, C.; Stern, H.; et al. (1998). Percutaneous closure of secundum atrial septal defect with a new self centering device ("angel wings"). *Heart*, Vol. 80, No. 5, pp. 517-521
- [84] Rome, J. J.; Keane, J. F.; Perry, S. B.; et al. (1990). Double-umbrella closure of atrial defects: initial clinical applications. *Circulation*, Vol. 82, No. 3, pp. 751-758
- [85] Ryan, C.; Opolski, S.; Wright, J.; et al. (1998). Structural considerations in the development of the CardioSeal septal occluder. In: *Proceedings of the Second World Congress of Pediatric Cardiology and Cardiac Surgery*, Y. Imai & K. Momma (Eds): 191-193, Futura Publishing Co, Armonk, NY, USA
- [86] Sharafuddin, M. J. A.; Gu, X.; Titus, J. L.; et al. (1997). Transvenous closure of secundum atrial septal defects: preliminary results with a new self-expanding Nitinol prosthesis in a swine model. *Circulation*, Vol. 95, No. 8, pp. 2162-2168
- [87] Schneider, M.; Babic, U.; Thomsen, B. A.; et al., (1995). Das ASDOS-Implantat: Tierexperimentelle Erprobung. *Z Kardiologie*, Vol. 84: (Suppl.) pp. 751
- [88] Schraeder, R.; Fassbender, D. & Strasser, R. H. (2003). PFO-star for closure of patent foramen ovale in patients with presumed paradoxical embolism. In: *Catheter based devices for the treatment of non-coronary cardiovascular disease in adults and children*, P. S. Rao & M. J Kern (Eds): 103-109, Lippincott Williams & Wilkins, Philadelphia, PA, USA
- [89] Sideris, E. B. (2003). Wireless devices. In: *Catheter based devices for the treatment of non-coronary cardiovascular disease in adults and children*, P. S. Rao, & M. J Kern (Eds): 79-84, Lippincott Williams & Wilkins, Philadelphia, PA, USA
- [90] Sideris, E. B.; Chiang, C. W.; Zhang, J. C. & Wang, W. S. (1999a). Transcatheter correction of heart defects by detachable balloon buttoned devices: A feasibility study. *J Am Coll Cardiol*, Vol. 33 No. 2, Suppl A, p. 528
- [91] Sideris, B. E.; Coulson, J. D. & Sideris, E. B. (2010). Transcatheter patch device. In: *Transcatheter closure of ASDs and PFOs: A comprehensive assessment*, Z. M. Hijazi, T. Feldman, M. H. Abdullah A Al-Qbandi, & H. Sievert (Eds): 373-384, Cardiotext, Minneapolis, MN, USA
- [92] Sideris, E.; Kaneva, A.; Sideris, S. & Moulopoulos, S. (2000a). Transcatheter atrial septal defect occlusion in piglets by balloon detachable devices. *Catheter Cardiovasc Interventions*, Vol. 51, No. 4, pp. 529-534

- [93] Sideris, E. B.; Leung, M.; Yoon, J. H.; et al. (1996). Occlusion of large atrial septal defects with a centering device: early clinical experience. *Am Heart J*, Vol. 131, No. 2, pp. 356-359
- [94] Sideris, E. B.; Sideris, S. E.; Fowlkes, J. P.; et al. (1990a). Transvenous atrial septal occlusion in piglets using a "buttoned" double-disc device. *Circulation*, Vol. 81, No. 1, pp. 312-318
- [95] Sideris, E. B.; Sideris, E. E.; Kaneva, A.; et al. (1999b). Transcatheter occlusion of experimental atrial septal defects by wireless occluders and patches (abstract). *Cardiol Young*, Vol. 9, Suppl, p. 92
- [96] Sideris, E. B.; Sideris, S. E.; Thanopoulos, B. D.; et al. (1990b). Transvenous atrial septal defect occlusion by the "buttoned" device. *Am J Cardiol*, Vol. 66, No. 20, pp. 1524-1526
- [97] Sideris, E. B.; Rey, C.; Schrader, R.; et al. (1997). Occlusion of large atrial septal defects by buttoned devices; comparison of centering and the fourth generation devices [abstract]. *Circulation*, Vol. 96, No. 8S, p. I-99
- [98] Sideris, E.; Toumanides, S.; Alekian, B.; et al. (2000b). Transcatheter patch correction of atrial septal defects: Experimental validation and early clinical experience. *Circulation*, Vol. 102: (Suppl) II, p. 588
- [99] Sievert, H.; Babic, U. U.; Ensslen, R.; et al. (1995). Transcatheter closure of large atrial septal defects with the Babic system. *Cathet Cardiovasc Diagn*, Vol. 36: No. 3, pp. 232-240
- [100] Sievert, H.; Babic, U. U.; Hausdorf, G.; et al. (1998). Transcatheter closure of atrial septal defect and patent foramen ovale with ASDOS device, a multi-institutional European trial. *Am J Cardiol*, Vol. 82, No. 11, pp. 1405-1413
- [101] Stolt, V. S.; Chessa, M.; Aubry, P.; et al. (2010). Closure of ostium secundum atrial septum defect with the Atriosept occluder: early European experience. *Catheter Cardiovasc Interv*, Vol. 75, No. 7, pp. 1091-1095
- [102] Thomsen-Bloch, A. (1995). Closure of Atrial Septal Defects with Catheter Technique: An animal experimental study. Diploma Thesis, Aarhus University Hospital, Denmark
- [103] Turner, D. R. & Forbes, T. J. (2010). Cardia devices. In: *Transcatheter closure of ASDs and PFOs: A comprehensive assessment*, Z. M. Hijazi, T. Feldman, M. H. Abdullah A Al-Qbandi, & H. Sievert (Eds): 407-416, Cardiotext, Minneapolis, MN, USA
- [104] Worms, A. M.; Rey, C.; Bourlan, F.; et al. (1996). French experience in the closure of atrial septal defects of the ostium secundum type with Sideris buttoned occluder. *Arch Mal Coeur Vaiss*, Vol. 89, No. 5, pp. 509-515
- [105] Zahn, E.; Cheatham, J.; Latson, L. & Wilson, N. (1999). Results of in vivo testing of a new Nitinol ePTTEF septal occlusion device. *Cathet Cardiovasc Intervent*, Vol. 47, No. 1, pp. 124
- [106] Zahn, E.; Wilson, N.; Cutright, W. & Latson, L. (2001). Development and testing of the HELEX septal occluder, a new expanded polytetrafluoroethylene atrial septal defect occlusion system. *Circulation*, Vol. 104, No. 6, pp. 711-716
- [107] Zamora, R.; Rao, P. S.; Lloyd, T.R.; et al. (1998). Intermediate-term results of Phase I FDA trials of buttoned device occlusion of secundum atrial septal defects. *J Am Coll Cardiol*, Vol. 31, No. 3, pp. 674-678

- [108] Zamora, R.; Rao, P. S. & Sideris, E. B. (2000). Buttoned device for atrial septal defect occlusion. *Current Intervent Cardiol Reports*, Vol. 2, No. 2, pp. 167-176

IntechOpen

IntechOpen



Atrial Septal Defect

Edited by Dr. P. Syamasundar Rao

ISBN 978-953-51-0531-2

Hard cover, 184 pages

Publisher InTech

Published online 25, April, 2012

Published in print edition April, 2012

Atrial Septal Defects (ASDs) are relatively common both in children and adults. Recent reports of increase in the prevalence of ASD may be related use of color Doppler echocardiography. The etiology of the ASD is largely unknown. While the majority of the book addresses closure of ASDs, one chapter in particular focuses on creating atrial defects in the fetus with hypoplastic left heart syndrome. This book, I hope, will give the needed knowledge to the physician caring for infants, children, adults and elderly with ASD which may help them provide best possible care for their patients.

How to reference

In order to correctly reference this scholarly work, feel free to copy and paste the following:

Srilatha Alapati and P. Syamasundar Rao (2012). Historical Aspects of Transcatheter Occlusion of Atrial Septal Defects, Atrial Septal Defect, Dr. P. Syamasundar Rao (Ed.), ISBN: 978-953-51-0531-2, InTech, Available from: <http://www.intechopen.com/books/atrial-septal-defect/historical-aspects-of-transcatheter-occlusion-of-atrial-septal-defects>

INTECH
open science | open minds

InTech Europe

University Campus STeP Ri
Slavka Krautzeka 83/A
51000 Rijeka, Croatia
Phone: +385 (51) 770 447
Fax: +385 (51) 686 166
www.intechopen.com

InTech China

Unit 405, Office Block, Hotel Equatorial Shanghai
No.65, Yan An Road (West), Shanghai, 200040, China
中国上海市延安西路65号上海国际贵都大饭店办公楼405单元
Phone: +86-21-62489820
Fax: +86-21-62489821

© 2012 The Author(s). Licensee IntechOpen. This is an open access article distributed under the terms of the [Creative Commons Attribution 3.0 License](#), which permits unrestricted use, distribution, and reproduction in any medium, provided the original work is properly cited.

IntechOpen

IntechOpen