

We are IntechOpen, the world's leading publisher of Open Access books Built by scientists, for scientists

4,800

Open access books available

122,000

International authors and editors

135M

Downloads

Our authors are among the

154

Countries delivered to

TOP 1%

most cited scientists

12.2%

Contributors from top 500 universities



WEB OF SCIENCE™

Selection of our books indexed in the Book Citation Index
in Web of Science™ Core Collection (BKCI)

Interested in publishing with us?
Contact book.department@intechopen.com

Numbers displayed above are based on latest data collected.
For more information visit www.intechopen.com



Pancreato-Biliary Cancers – Diagnosis and Management

Nam Q. Nguyen

*Department of Gastroenterology, Royal Adelaide Hospital,
North Terrace, Adelaide, SA
Australia*

1. Introduction

Pancreato-biliary cancers are relatively uncommon and in general, including cancers arise from the pancreas, bile duct and major ampullae. These tumours are uniformly carried a poor prognosis due to late presentation and surgical resection is only possible in less than 20% patients (David et al., 2009; Luke et al., 2009). Despite many medical advances in the imaging diagnosis, chemo-radio-therapy, surgical technique and post-operative care over the last 2 decades, the overall survival of patients with pancreato-biliary neoplasm has not improved significantly (Luke et al., 2009). The aim of the current chapter is to review and discuss current techniques and approaches to the diagnosis and management of pancreato-biliary neoplasm.

2. Clinico-pathology of pancreato-biliary tumours

2.1 Pancreatic carcinoma

In the Western world, pancreatic cancer is the fourth leading cause of cancer related mortality with the approximate incidence of 11 per 100 000, and ranks second after colorectal cancer among all gastrointestinal malignancies (Shaib et al., 2006). Men are more frequently affected than women and over 80% patients are diagnosed at the age older than 60 years. Almost 50% patients have distant metastases at the time of presentation with poor 5-year survival of 5% (Shaib et al., 2006). Recent data suggest that although the mortality rate for males has decreased by 0.4% from 1990 to 2005, the mortality rate for females has increased by 4.4% (Shaib et al., 2006; Jemal et al., 2009). The reason for this gender difference in mortality is unknown. Risk factors for pancreatic cancer include smoking, alcohol, diabetes mellitus, chronic pancreatitis, family history of pancreatic cancer. Patients with hereditary pancreatitis, Puetz-Jeghers syndrome, familial atypical multiple mole melanoma, familial breast and ovarian cancer, Li-Fraumeni syndrome, Fanconi anaemia, ataxia-telangiectasia, familial adenomatous polyposis, cystic fibrosis and possible hereditary non-polyposis colon cancer syndrome are also at higher risk of having pancreatic cancer (Shaib et al., 2006; Klapman and Malafa, 2008).

Ductal infiltrating adenocarcinoma is the most common type of pancreatic cancer with 78% located in the head, 11% in the body and 11% in the tail (Lillemoe et al., 2000; Ghaneh et al.,

2008). Less than 15% of pancreatic cancers are intraductal mucinous papillary neoplasm (IPMN), solid pseudopapillary neoplasm, pancreatoblastoma, mucinous cystadenocarcinoma, adenosquamous carcinoma and acinar cell carcinoma (Ghaneh et al., 2008). Given the preponderance pancreatic head location of the tumours, painless cholestatic symptoms are the most common presentation (Ghaneh et al., 2008). Anorexia, abdominal pain or mass and weight loss often indicate the presence of advanced disease.

2.2 Cholangiocarcinoma

This is rare malignant disease of the epithelial cells in the intra- and extrahepatic bile ducts and the incidence is increasing, especially the intra-hepatic subtype (Patel, 2001). In addition to liver flukes infestation, hepatitis B and C infections have recently been associated with rise of cholangiocarcinoma in the developing countries, and are thought to be responsible for the increasing incidence of intra-hepatic cholangiocarcinomas. In the western countries, primary sclerosing cholangitis and congenital anomalies such as Caroli's syndrome and choledochal cysts are the main predisposing risk factors for cholangiocarcinoma (Patel, 2006).

As with pancreatic cancer, most of the cholangiocarcinomas are unresectable at presentation and the prognosis for these patients is dismal. Clinical presentations of cholangiocarcinoma are dependent on tumour location (Patel, 2006). Extrahepatic tumours, including those involving the bifurcation usually show signs of biliary obstruction with jaundice and pale stools. In contrast, intra-hepatic cholangiocarcinomas more often present with late symptoms of malignancy such as weight loss, loss of appetite, and abdominal pain or mass.

2.3 Ampullary tumours

Compared to pancreatic carcinoma and cholangiocarcinoma, ampullary neoplasm is the least common and aggressive tumour. In general, ampullary tumour has better clinical outcomes even when the tumour is not resectable (Heinrich and Clavien 2010). Whilst ampullary tumours can occur sporadically, they are often seen in the context of genetic syndromes such as familial adenomatous polyposis and hereditary non-polyposis colorectal cancer, in whom the risk is 100 times more than the general population (Offerhaus et al., 1992). As endoscopic screening and surveillance program is adopted for these at-risk individuals, most tumours are adenomas at detection, though the potential of malignant transformation to carcinomas is high (Jean and Dua, 2003; Fischer and Zhou, 2004). Currently, there is no consensus on the management of ampullary tumors. Factors that impact treatment strategy include the patient's general health, tumor characteristics, and available expertise. Ampullary adenomas, especially those with high-grade dysplasia, warrant therapy because they are "time bombs" for malignancy and may already harbor malignancy missed on biopsy (Heinrich and Clavien 2010). Although endoscopic resection is widely embraced as first-line therapy in patients with benign ampullary tumors (Binmoeller et al., 1993; Beger et al., 1999; Cheng et al., 2004), the final treatment decision is based on the histological findings of the ampullectomized specimen. The presence of invasive carcinoma in the specimen indicates the need for definitive surgical resection. In patients who are poor candidates for surgery or who refuse surgery, endoscopic resection with ablative therapy can be considered despite unfavorable tumor characteristics (Nguyen et al. 2010). Endoscopic ampullectomy has also been reported to successfully eradicate large ampullary adenomas (Zadorova et al., 2001), early T1 ampullary adenocarcinoma

(Katsinelos et al., 2007), and even lesions with intraductal growth (Bohnacker et al., 2005). Given its tumour behaviour, clinical presentation and treatment modality are very different to that of pancreatic cancer and cholangiocarcinoma, ampullary tumours will not be discussed further in this chapter.

3. Investigations of pancreato-biliary cancers

The imaging modalities involve in the detection, staging and management of pancreatic cancer are computer tomography (CT), magnetic resonance imaging (MRI), endoscopic retrograde cholangiopancreatography (ERCP), endoscopic ultrasound (EUS) and positron emission tomography (PET) (Clarke et al., 2003; Chang et al., 2009; Peddu et al., 2009). The diagnosis can potentially be made by any, or a combination of the above modalities. The roles and relative importance of these imaging modalities have changed over the last few decades and continue to change with rapid technological advancement in medical imaging.

Base on current best available evidence, CT should be used as first line for diagnosis, staging and the assessment of resectability in pancreato-biliary cancer. MRI should be reserved for patients with iodine contrast allergy or who cannot be exposed to radiation or to be used as an adjunct to CT in patients with suspicious liver lesions that need to be better characterized (Clarke et al., 2003; Peddu et al., 2009). MR cholangio-pancreatography (MRPC) is an essential part of the evaluation for cholangiocarcinoma as it can identify the luminal involvement of the cancer as well as the road map of the biliary tree (Patel, 2006). Such information is not only important in local staging but also critical in determining respectability, type of surgery and/or identifying the dominant obstructive ductal system for biliary drainage. In selected cases, cholangioscopy is helpful by providing direct endoscopic visualization of the intra-ductal lesion that responsible for the biliary stricture (Patel, 2006). The recent development of SpyGlass cholangioscopy system has also allowed tissue sample under direct vision.

EUS should be used for local staging and assessment of resectability if it remains inconclusive on non-invasive imaging modalities (Chang et al., 2009; Iglesias Garcia et al., 2009). It should also be used in patients with a high clinical suspicion of a lesion that has not been clearly demonstrated using other modalities. EUS-FNA should also be the biopsy route of choice in patients where a tissue diagnosis or tissue from regional lymph nodes may alter the course of treatment, or if neo-adjuvant treatment is contemplated. If there is disagreement between CT and EUS images, then laparotomy and trial of dissection should be considered (Chang et al., 2009). PET/CT should be used selectively such as when metastatic disease is suspected but has not been demonstrated with other imaging modalities (Nguyen and Bartholomeusz, 2011; Serrano et al. 2010). The availability and local expertise of each imaging modality will also influence their use. A suggested management algorithm for patients with suspected pancreato-biliary cancer is shown in Figure 1.

3.1 Tumour markers

The role of tumour marker in the diagnosis and management of pancreato-biliary cancers remains controversial (Balzano and Di Carlo, 2008). Carbohydrate antigen 19-9 (CA19-9), which is caused by the up-regulation of glycosyl transferase genes, is the most commonly used marker and can provide useful diagnostic and prognostic information (Duffy et al.

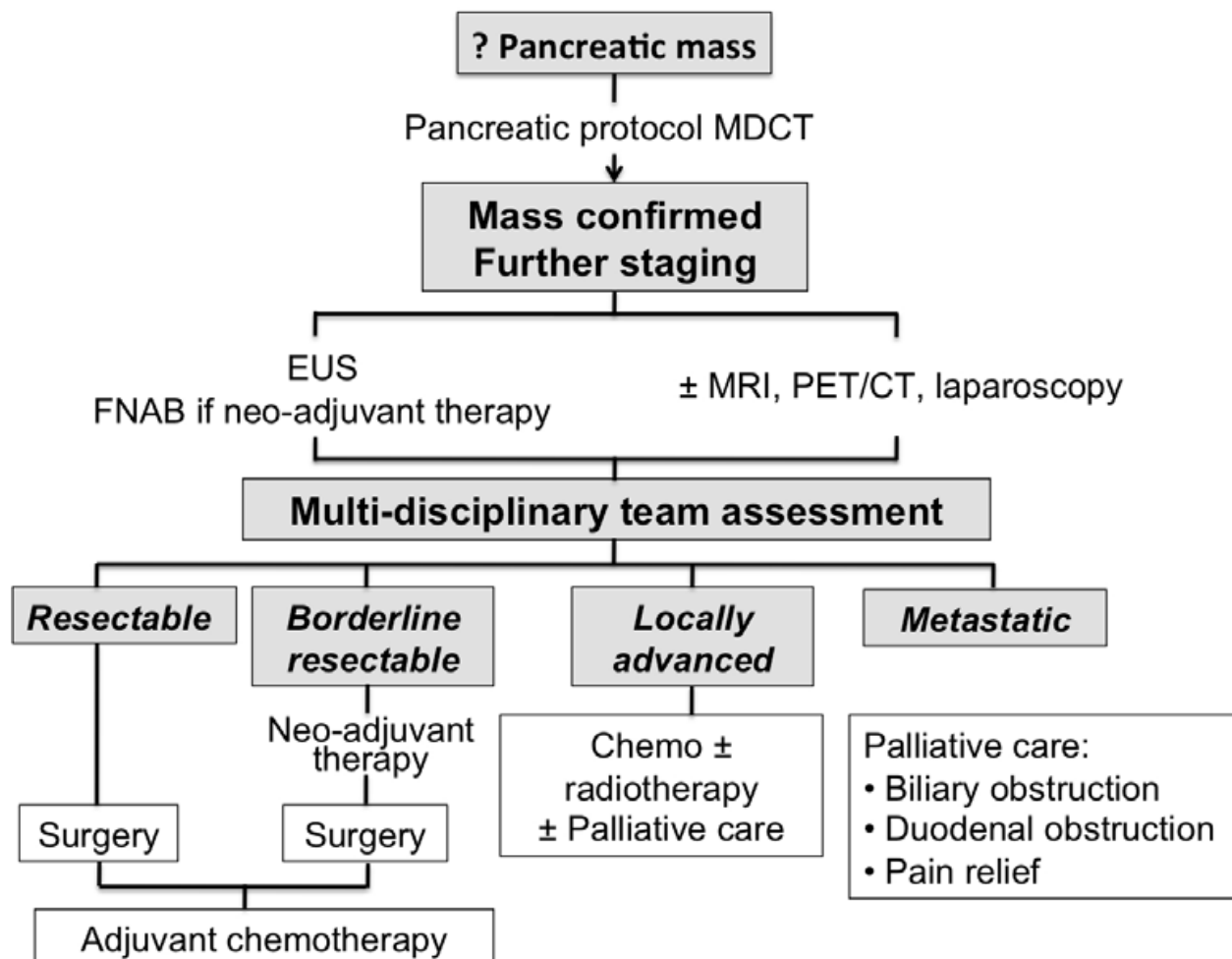


Fig. 1. Suggested algorithm for the evaluation and management of patients with suspected pancreatic.

2010). Its sensitivity (70%-90%) and specificity (43%-91%) for diagnosing pancreatic cancer are only modest and can be falsely increased by high serum bilirubin (Duffy et al. 2010). However, for those with confirmed pancreatic cancer, high serum CA19-9 is associated with a worse survival (Park et al., 2008). Similarly, in patients who undergo curative resection for pancreatic cancer, a normalizing post-operative CA19-9 level is associated with a longer median and disease-free survival compared to those with persistently high level (Duffy et al., 2008; Balzano and Di Carlo, 2008).

3.2 Tissue sampling

A distinct advantage of EUS is its ability to obtain tissue via fine needle aspiration (FNA). This approach is superior to percutaneous biopsy (via US or CT guided) in the investigation of pancreato-biliary malignancies with higher diagnostic yield (84% vs. 62%) and significantly lower risk of tumour seeding from the needle tract (<2% vs. 16%) (Paquin et al., 2005). Apart from biopsy of the primary tumour, it also has the ability to biopsy lymph nodes, liver lesions and ascitic fluid, which is critical in accurate staging and avoiding unnecessary resection (Figure 2). For pancreatic head lesions, the possibility of seeding is eliminated, as the needle track is included in the resection specimen (Yamao et al., 2005). In

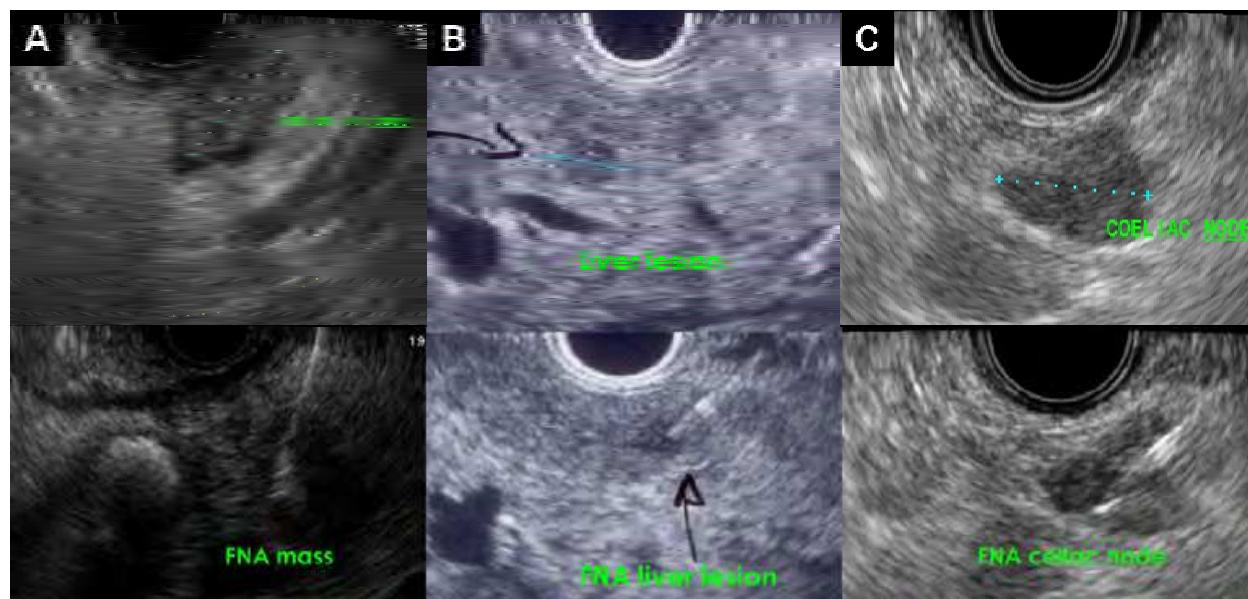


Fig. 2. Examples of EUS-guide FNA of a pancreatic mass in the body (panel A), a liver lesion (panel B) and pathological celiac node (panel C).

contrast, for lesions in the pancreatic body and tail, where the needle track is not resected, the risks and benefits of pre-operative biopsy should be carefully assessed on an individual basis. Due to its anatomical position, tissue acquisition from biliary lesion via EUS guided FNA is more difficult and in general, the diagnostic yield is lower than that for pancreatic cancer and is dependent on the location of the lesion. As it is easier to visualize and access the distal biliary lesions, the diagnostic yield is significantly higher in distal compared with proximal lesions (81% vs 59%) (Mohamadnejad et al. 2011).

3.3 Cholangioscopy

In cases where the diagnosis of the biliary stricture remains unclear after conventional MDCT, MRI and EUS evaluation, directly visualization of the appearance of the ductal strictures and biopsy can be helpful in differentiating benign from malignant disorders (Figure 3). Although video “mother-baby” cholangioscope provides high quality images, it is fragile and often lack of accessory channel for tissue sampling (Nguyen, 2009; Nguyen et al., 2009). The diagnostic yield of malignancy based on cholangioscopic appearance of the intra-ductal lesion varied from 70% to 88% (Nguyen, 2009; Nguyen et al., 2009). Currently, tissue sampling is only possible with the single-operator disposable SpyGlass system, which has a 1.2mm accessory channel. Although SpyGlass guided tissue sample is successful in up to 96% of cases, its overall accuracy in confirming a malignant stricture is only modest (49% of cases) (Nguyen, 2009; Nguyen et al., 2009). This is mainly due to the poor sensitivity of SpyGlass guided biopsy in the diagnosis of malignancy from extrinsic cancers (8%) as compared to that of intrinsic cancers (66%) (Nguyen, 2009; Nguyen et al., 2009).

4. Therapeutic approaches for pancreato-biliary cancers

Patients with suspected or confirmed diagnosis of pancreato-biliary malignancy should be assessed by a multidisciplinary team and stratified as resectable, borderline resectable,

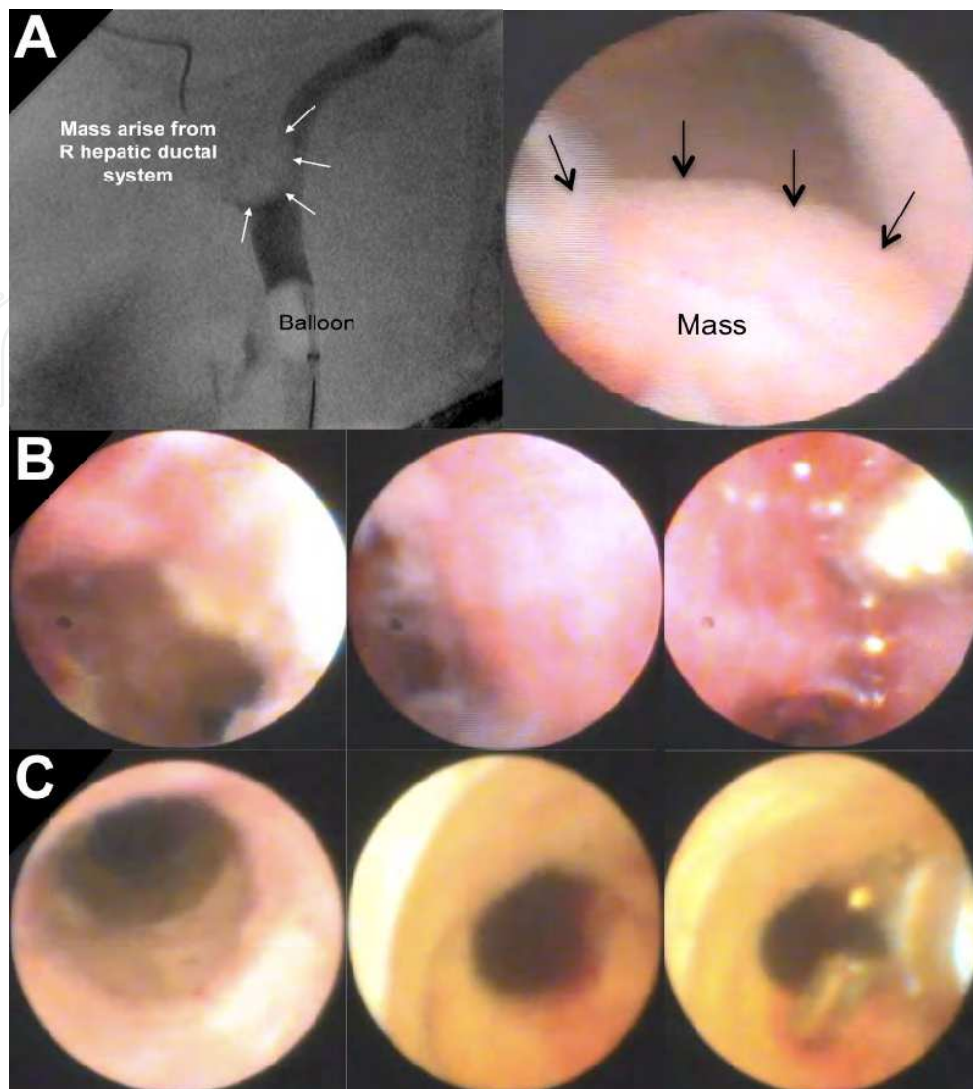


Fig. 3. Cholangioscopic images from SpyScope for investigation of suspected biliary strictures. A case of a hepatoma causing a polypoid protrusion into the right hepatic duct at the hilum, mimicking a cholangiocarcinoma on cholangiography (panel A). A case of cholangiocarcinoma in the upper common bile duct (CBD) stricture, confirmed on SpyGlass guided biopsy (panel B). A case of mid-CBD stricture in a patient with primary sclerosing cholangitis, which appeared benign on SpyScope and was confirmed on biopsy (panel C).

locally advanced unresectable or metastatic disease. Treatment should be planned according to local expertise and established guidelines, as resectable and borderline patients should be referred to surgeons, unresectable and metastatic patients should be referred to medical and radiation oncologists and palliative care teams. Endoscopic interventions to alleviate biliary or duodenal obstruction are also important in improving the performance status and quality of life in these patients. A multidisciplinary approach to pancreato-biliary malignancy is necessary to improve the overall outcome of these patients, especially for borderline resectable or unresectable disease as neo-adjuvant chemo-radiation therapy may play a role in down-staging and the conversion to potentially resectable, and in some case “curable”, disease (Verslype et al., 2007; Chang et al., 2008). The therapeutic approach for pancreatic cancers is summarized in Figure 1.

4.1 Surgery

Surgical resection remains the only possibility of cure for pancreato-biliary cancers as chemotherapy and radiotherapy offering only a modest survival benefit. Patients who undergo complete surgical resection for localized, non-metastatic adenocarcinoma of the pancreas have a 5-year survival rate of approximately 20 to 25%, and a median survival of 22 months (Cameron et al., 2006). Unfortunately less than 20% of patients with pancreatic cancer have disease amendable to surgical resection at the time of presentation (Yeo et al., 1997) because patients often present at an advanced stage with widespread metastatic or locally advanced disease. The type of resection depends on the location of the tumours with Whipple's procedures are most commonly performed as most cancers locate in the head of pancreas.

Similarly, the type and extend of resection for cholangiocarcinoma depends on the location of the tumour. The indication and type of resection of intra-hepatic cholangiocarcinoma is similar to those of liver cancers. In contrast, curative surgery for extra-hepatic cholangiocarcinoma is rare and is only possible for distal ductal tumours (Witzigmann et al., 2008; Lang et al., 2009). Hilar tumours involving the bifurcation are usually contraindicated for surgery and have very poor prognosis. Even in patients whose resection is considered successful, the overall five-year survival rate in the range of 25–30% (Lang et al., 2009).

4.2 Chemo-radiotherapy

Given the high loco-regional recurrence rate and a tendency towards early liver metastasis after pancreatic resection, adjuvant chemotherapy has been employed though its benefits remain controversial with mixed results until recently (Brennan, 2004; Zuckerman and Ryan, 2008). Of the six randomized controlled trials that examined the effects of adjuvant chemotherapy after pancreatic resection (Kaiser and Ellenberg, 1985; Moertel et al., 1994; Neoptolemos et al., 2001; Neoptolemos et al., 2004; Oettle et al., 2007; Regine et al., 2008), only two trials were able to demonstrate a survival benefit of adjuvant chemotherapy (Neoptolemos et al., 2001; Neoptolemos et al., 2004). In the ESPAC-1 study, the survival of patients treated with adjuvant 5-Fluorouracil (5-FU) was significantly longer than that without adjuvant chemotherapy (20.1 months vs 15.5 months) (Neoptolemos et al., 2001; Neoptolemos et al., 2004). Subsequent meta-analysis supports the results of ESPAC-1 trial and indicated that 5-FU reduced the risk of death by 25% (Stocken et al., 2005). More recently, German investigators (Oettle et al., 2007) have demonstrated a disease-free survival advantage of patients who received gemcitabine adjuvant chemotherapy (13.4 months vs 6.9 months), but not the overall survival (22.1 months vs 20.2 months). Given the encouraging data from these trials (Neoptolemos et al., 2001; Neoptolemos et al., 2004; Oettle et al., 2007), adjuvant chemotherapy with either 5-FU or gemcitabine or both is increasingly used in patients with resected pancreatic cancer (Fogelman et al., 2004; Goldstein et al., 2004). Compared with 5-FU, gemcitabine is better tolerated with lesser incidence of grade 3 and 4 haematological toxicity (Oettle et al., 2007; Palmer et al., 2007).

Similarly, in order to convert borderline resectable to resectable tumors or to increase the probability of complete microscopic tumor resection, neo-adjuvant chemo-radiotherapy has also been evaluated (Gillen et al., 2010; Heinrich et al., 2010; van Tienhoven et al., 2011;

Vinciguerra 2011). A recent systematic review evaluating retrospective and prospective studies on neo-adjuvant chemo-radiotherapy from 1966 to 2009 included a total of 111 studies and 4,394 patients suggests that up to one third of patients with previously borderline resectable cancers are eligible for resection after neoadjuvant treatment (Gillen et al. 2010). More importantly, these patients were found to have comparable median survival as those who undergoing resection followed by adjuvant therapy (20.1 vs. 23.6 months, respectively). In contrast, neoadjuvant therapy did not seem to improve overall outcome for patients with resectable cancer at presentation (Gillen et al. 2010).

In contrast to pancreatic cancer, cholangiocarcinoma has been shown to be resistant to common chemotherapy (Anderson and Kim, 2009). Numerous drugs have been tested alone and in combination, and thus far, the response rate has been unacceptably low. Although gemcitabine chemotherapy is often given to patients with unresectable cholangiocarcinoma, the survival benefit has not been proven in a randomised controlled trial (Gruenberger et al. 2010).

5. Palliative endoscopic interventions

Given that up to 80-85% of pancreato-biliary cancers are unresectable and the survival benefit of chemo-radiation therapy is very modest, palliative treatment plays a very important role in the care of these patients. Relief of symptoms secondary to gastro-duodenal obstruction, jaundice and pain are essential to improve their quality of life and overall survival. In the past, surgical palliative approaches, such as gastric bypass and hepatico-enteric decompression, are more common used as the diagnosis of unresectable disease is frequently made in the operating room. With the recent improvement in pre-operative staging, diagnostic laparotomy is rarely performed and biliary or gastro-duodenal obstruction is mostly managed by minimally invasive endoscopic interventions.

5.1 Alleviation of biliary obstruction

Currently, endoscopic biliary stenting is the treatment of choice for unresectable pancreato-biliary cancers with obstructive jaundice (Figure 4). Endoscopic placement of plastic stent(s) was equally effective as surgical technique in palliating obstructive jaundice, but endoscopic stent was associated with fewer procedural complications and death (Taylor et al., 2000). More recently, the invention of larger diameter self-expandable metallic (SEM) biliary stents provides longer stent patency for drainage. Compared to plastic stents, SEM stents are significantly less likely to be occluded and thus, minimized the number of repeated ERCP. As with plastic stents, endoscopic placement of SEM stents has been shown to provide similar overall survival to surgical decompression but is more cost-effective and better quality of life (Knyrim et al., 1993; Prat et al., 1998). The concurrent use of chemotherapeutic agents in patients palliated with SEM stents does not increase the risk for ascending cholangitis (Nakai et al., 2005).

Percutaneous trans-hepatic stenting (PTHS) is often reserved for patients in whom ERCP has failed due to a higher complication rate as well as poorer quality of life (Pinol et al., 2002). More recently, the advent of EUS assisted ductal drainage and stenting has significantly improved the success rate of endoscopic approach and thus, reduced the need for PTHS. This approach involves puncturing a dilated intra-hepatic duct, under direct EUS

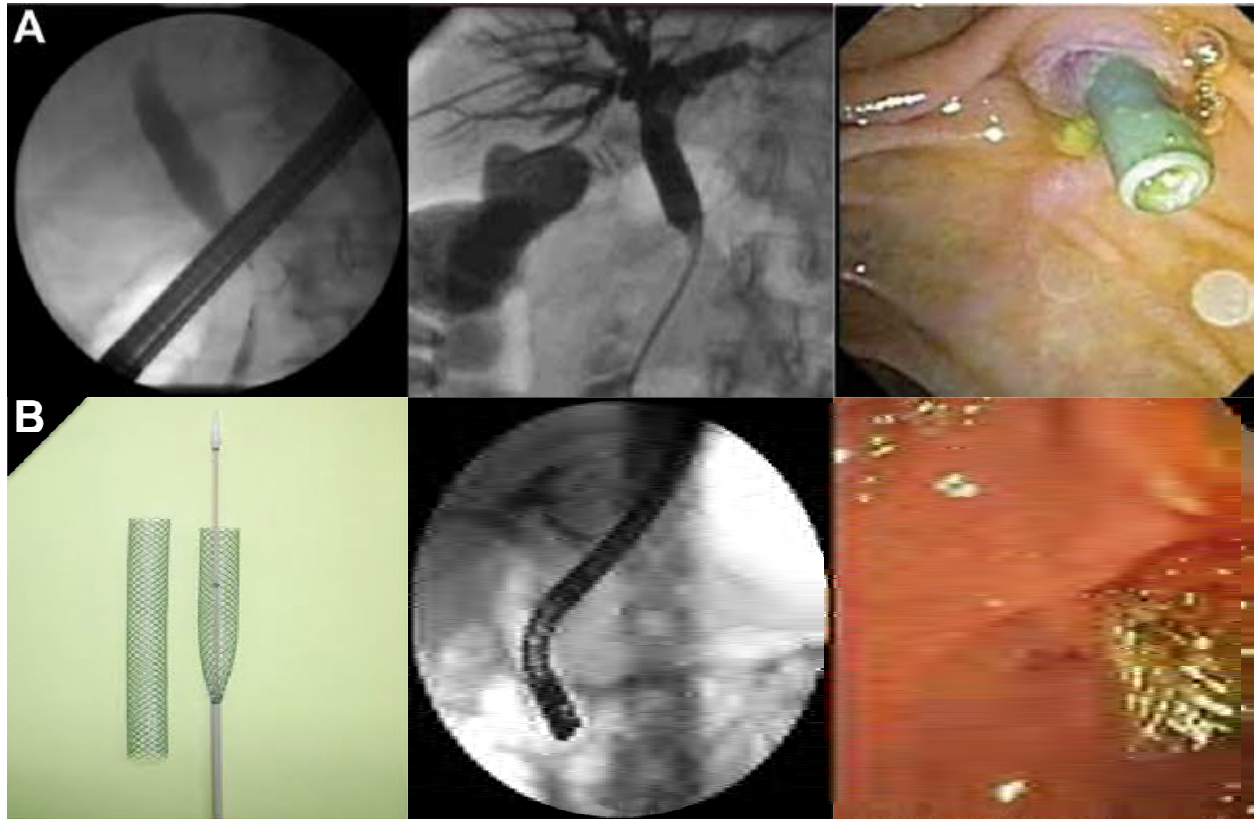


Fig. 4. Examples of biliary obstruction from pancreatic cancer requiring biliary drainage using plastic biliary stent (panel A) and SEM biliary stent (panel B).

guidance, to pass a guide wire into the duodenum, which then allows successful cannulation of the biliar tree via ERCP and stenting (Shami and Kahaleh, 2007). In cases of duodenal obstruction, direct biliary drainage from a dilated intrahepatic duct into the stomach or duodenum via a SEM is an effective alternative for palliation with reasonable safety profile (Iwamuro et al., 2010; Nguyen-Tang et al. 2010). Surgical biliary bypass is only considered for patients who have relatively preserved functional status with obstructive jaundice and have failed on endoscopic stent placement.

5.2 Alleviation of gastro-duodenal obstruction

Although gastric bypass is commonly performed for unresectable patients with gastro-duodenal obstruction, the introduction of self-expanding metallic duodenal stents has changed the options for palliation (Figure 5). Current data suggest that placement of self-expandable metallic duodenal stents for malignant gastric outlet obstruction is successful in 98% of cases with a median duration of patency of 10 months (van Hooft et al., 2009). Serious complications from duodenal stenting, such as gastrointestinal bleeding or perforation, are rare with long-term stent dysfunction occurs in 14% of patients and migration in only 2% (van Hooft et al., 2009). Compared with palliative surgery, stent placement provides a shorter hospital stay, earlier resumption of oral intake, fewer complications and lower hospital costs (Maetani et al., 2004; Maetani et al., 2005). Currently, surgical palliation is often reserved for patients who are expected have a long life-expectancy and need both biliary and gastric bypass.

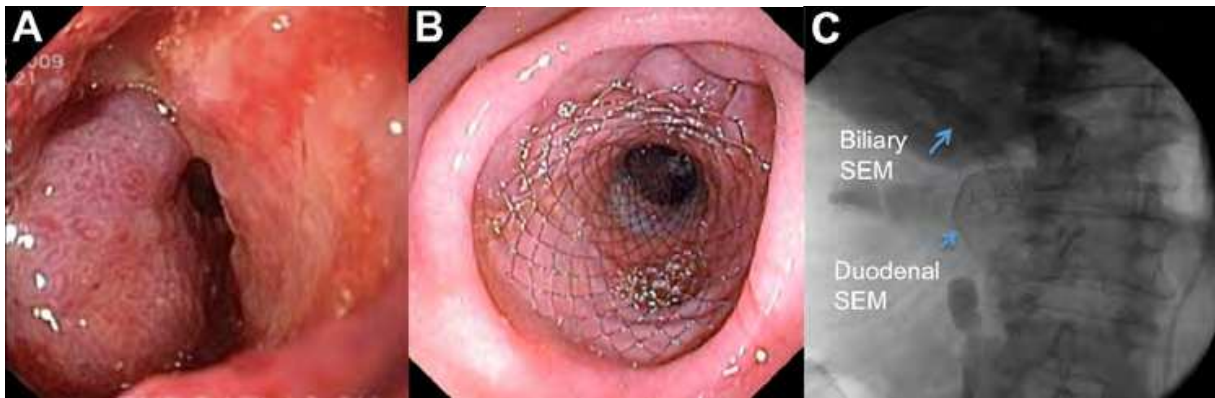


Fig. 5. A case of duodenal obstruction caused by locally advanced pancreatic cancer (A) and was successfully treated with a SEM duodenal stent (B). This patient also had a SEM biliary stent inserted for biliary drainage prior to the duodenal stent placement (C).

5.3 Alleviation of pain

Approximately 70% of patients with unresectable pancreato-biliary cancer develop clinically important pain, which can significantly reduce the quality and quantity of life of these patients (Andren-Sandberg et al., 1999). Good pain relief is, therefore, an essential part of effective palliative care. Although opioid analgesics are most commonly used as the first line pain relieved medication, one third of patients experience inadequate control of pain with significant side effects such as constipation and drowsiness (Andren-Sandberg et al., 1999). In these patients, neurolytic celiac plexus block under radiological or surgical guidance with absolute alcohol can be performed with up to 90% success rate (Mercadante et al., 2003; Wong et al., 2004; Noble and Gress, 2006). Recent studies have shown that EUS-guided neurolysis is equally effective but has significantly fewer serious complications associated with surgical or percutaneous approaches (O'Toole and Schmulewitz, 2009; Puli et al., 2009)

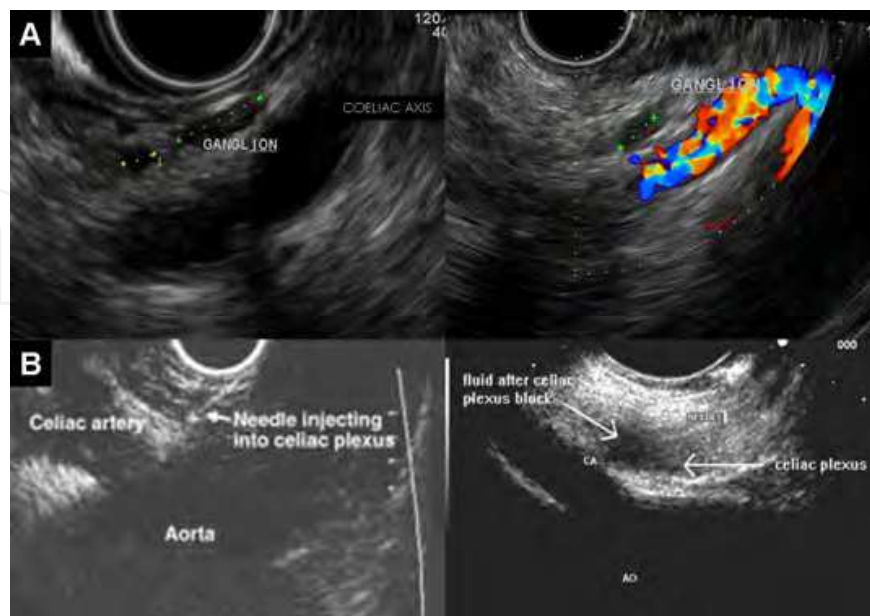


Fig. 6. Celiac ganglia can be visualized clearly on EUS imaging (panel A). Examples of EUS guided celiac ganglion blockage with alcohol injection (panel B).

(Figure 6). A recent double-blind randomized controlled study has also found that celiac plexus block is superior than systemic analgesic therapy in providing pain relief and improving quality of life (Wong et al., 2004). Thus, EUS-guided celiac neurolysis should be considered in all patients who have abdominal pain related to the pancreato-biliary cancer.

6. Conclusions

Despite the recent advances in diagnostic modalities, chemo-radiotherapy, surgical and post-operative care, the overall prognosis of pancreato-biliary malignancies has barely changed over the last few decades. The management of these patients is often complex and requires expertise in many fields. Thus, multidisciplinary teams are necessary to optimize the overall care. As the majority of these patients are diagnosed in advanced stages, good palliative care measures are essential to the management. Fortunately, a number of advances in endoscopic techniques have been made to improve the quality of life of these patients and avoid unnecessary surgery.

7. References

- Anderson, C. and R. Kim (2009). "Adjuvant therapy for resected extrahepatic cholangiocarcinoma: a review of the literature and future directions." *Cancer Treat Rev* 35(4): 322-7.
- Andren-Sandberg, A., A. Viste, A. Horn, D. Hoem and H. Gislason (1999). "Pain management of pancreatic cancer." *Ann Oncol* 10 Suppl 4: 265-8.
- Balzano, G. and V. Di Carlo (2008). "Is CA 19-9 useful in the management of pancreatic cancer?" *Lancet Oncol* 9(2): 89-91.
- Beger, H. G., F. Treitschke, F. Gansauge, N. Harada, N. Hiki and T. Mattfeldt (1999). "Tumor of the ampulla of Vater: experience with local or radical resection in 171 consecutively treated patients." *Arch Surg* 134(5): 526-32.
- Binmoeller, K. F., S. Boaventura, K. Ramsperger and N. Soehendra (1993). "Endoscopic snare excision of benign adenomas of the papilla of Vater." *Gastrointest Endosc* 39(2): 127-31.
- Bohnacker, S., U. Seitz, D. Nguyen, F. Thonke, S. Seewald, A. deWeerth, R. Ponnudurai, S. Omar and N. Soehendra (2005). "Endoscopic resection of benign tumors of the duodenal papilla without and with intraductal growth." *Gastrointest Endosc* 62(4): 551-60.
- Brennan, M. F. (2004). "Adjuvant therapy following resection for pancreatic adenocarcinoma." *Surg Oncol Clin N Am* 13(4): 555-66, vii.
- Cameron, J. L., T. S. Riall, J. Coleman and K. A. Belcher (2006). "One thousand consecutive pancreaticoduodenectomies." *Ann Surg* 244(1): 10-15.
- Chang, D. K., N. D. Merrett and A. V. Biankin (2008). "Improving outcomes for operable pancreatic cancer: is access to safer surgery the problem?" *J Gastroenterol Hepatol* 23(7 Pt 1): 1036-45.
- Chang, D. K., N. Q. Nguyen, N. D. Merrett, H. Dixon, R. W. Leong and A. V. Biankin (2009). "Role of endoscopic ultrasound in pancreatic cancer." *Expert Rev Gastroenterol Hepatol* 3(3): 293-303.

- Cheng, C. L., S. Sherman, E. L. Fogel, L. McHenry, J. L. Watkins, T. Fukushima, T. J. Howard, L. Lazzell-Pannell and G. A. Lehman (2004). "Endoscopic snare papillectomy for tumors of the duodenal papillae." *Gastrointest Endosc* 60(5): 757-64.
- Clarke, D. L., S. R. Thomson, T. E. Madiba and C. Sanyika (2003). "Preoperative imaging of pancreatic cancer: a management-oriented approach." *J Am Coll Surg* 196(1): 119-29.
- David, M., C. Lepage, J. L. Jouve, V. Jooste, M. Chauvenet, J. Faivre and A. M. Bouvier (2009). "Management and prognosis of pancreatic cancer over a 30-year period." *Br J Cancer* 101(2): 215-8.
- Duffy, M. J., C. Sturgeon, R. Lamerz, C. Haglund, V. L. Holubec, R. Klapdor, A. Nicolini, O. Topolcan and V. Heinemann (2010). "Tumor markers in pancreatic cancer: a European Group on Tumor Markers (EGTM) status report." *Ann Oncol* 21(3): 441-7.
- Fischer, H. P. and H. Zhou (2004). "Pathogenesis of carcinoma of the papilla of Vater." *J Hepatobiliary Pancreat Surg* 11(5): 301-9.
- Fogelman, D. R., J. Chen, J. A. Chabot, J. D. Allendorf, B. A. Schrope, R. D. Ennis, S. M. Schreiber and R. L. Fine (2004). "The evolution of adjuvant and neoadjuvant chemotherapy and radiation for advanced pancreatic cancer: from 5-fluorouracil to GTX." *Surg Oncol Clin N Am* 13(4): 711-35, x.
- Ghaneh, P., E. Costello and J. P. Neoptolemos (2008). "Biology and management of pancreatic cancer." *Postgrad Med J* 84(995): 478-97.
- Gillen, S., T. Schuster, C. Meyer Zum Buschenfelde, H. Friess and J. Kleeff (2010). "Preoperative/neoadjuvant therapy in pancreatic cancer: a systematic review and meta-analysis of response and resection percentages." *PLoS Med* 7(4): e1000267.
- Goldstein, D., S. Carroll, M. Apte and G. Keogh (2004). "Modern management of pancreatic carcinoma." *Intern Med J* 34(8): 475-81.
- Gruenberger, B., J. Schueller, U. Heubrandtner, F. Wrba, D. Tamandl, K. Kaczirek, R. Roka, S. Freimann-Pircher and T. Gruenberger (2010). "Cetuximab, gemcitabine, and oxaliplatin in patients with unresectable advanced or metastatic biliary tract cancer: a phase 2 study." *Lancet Oncol* 11(12): 1142-8.
- Heinrich, S. and P. A. Clavien (2010). "Ampullary cancer." *Curr Opin Gastroenterol* 26(3): 280-5.
- Heinrich, S., B. Pestalozzi, M. Lesurtel, F. Berrevoet, S. Laurent, J. R. Delpero, J. L. Raoul, P. Bachellier, P. Dufour, M. Moehler, A. Weber, H. Lang, X. Rogiers and P. A. Clavien (2010). "Adjuvant gemcitabine versus NEOadjuvant gemcitabine/oxaliplatin plus adjuvant gemcitabine in resectable pancreatic cancer: a randomized multicenter phase III study (NEOPAC study)." *BMC Cancer* 11: 346.
- Iglesias Garcia, J., J. Larino Noia and J. E. Dominguez Munoz (2009). "Endoscopic ultrasound in the diagnosis and staging of pancreatic cancer." *Rev Esp Enferm Dig* 101(9): 631-8.
- Iwamuro, M., H. Kawamoto, R. Harada, H. Kato, K. Hirao, O. Mizuno, E. Ishida, T. Ogawa, H. Okada and K. Yamamoto "Combined duodenal stent placement and endoscopic ultrasonography-guided biliary drainage for malignant duodenal obstruction with biliary stricture." *Dig Endosc* 22(3): 236-40.
- Jean, M. and K. Dua (2003). "Tumors of the ampulla of Vater." *Curr Gastroenterol Rep* 5(2): 171-5.
- Jemal, A., R. Siegel, E. Ward, Y. Hao, J. Xu and M. J. Thun (2009). "Cancer statistics, 2009." *CA Cancer J Clin* 59(4): 225-49.


- Kalser, M. H. and S. S. Ellenberg (1985). "Pancreatic cancer. Adjuvant combined radiation and chemotherapy following curative resection." *Arch Surg* 120(8): 899-903.
- Katsinelos, P., J. Kountouras, G. Chatzimavroudis, C. Zavos, G. Paroutoglou, R. Kotakidou, K. Panagiotopoulou and B. Papaziogas (2007). "A case of early depressed-type ampullary carcinoma treated by wire-guided endoscopic resection." *Surg Laparosc Endosc Percutan Tech* 17(6): 533-7.
- Klapman, J. and M. P. Malafa (2008). "Early detection of pancreatic cancer: why, who, and how to screen." *Cancer Control* 15(4): 280-7.
- Knyrim, K., H. J. Wagner, J. Pausch and N. Vakil (1993). "A prospective, randomized, controlled trial of metal stents for malignant obstruction of the common bile duct." *Endoscopy* 25(3): 207-12.
- Lang, H., G. C. Sotiropoulos, G. Sgourakis, K. J. Schmitz, A. Paul, P. Hilgard, T. Zopf, T. Trarbach, M. Malago, H. A. Baba and C. E. Broelsch (2009). "Operations for intrahepatic cholangiocarcinoma: single-institution experience of 158 patients." *J Am Coll Surg* 208(2): 218-28.
- Lillemoe, K. D., C. J. Yeo and J. L. Cameron (2000). "Pancreatic cancer: state-of-the-art care." *CA Cancer J Clin* 50(4): 241-68.
- Luke, C., T. Price, C. Karapetis, N. Singhal and D. Roder (2009). "Pancreatic cancer epidemiology and survival in an Australian population." *Asian Pac J Cancer Prev* 10(3): 369-74.
- Maetani, I., S. Akatsuka, M. Ikeda, T. Tada, T. Ukita, Y. Nakamura, J. Nagao and Y. Sakai (2005). "Self-expandable metallic stent placement for palliation in gastric outlet obstructions caused by gastric cancer: a comparison with surgical gastrojejunostomy." *J Gastroenterol* 40(10): 932-7.
- Maetani, I., T. Tada, T. Ukita, H. Inoue, Y. Sakai and J. Nagao (2004). "Comparison of duodenal stent placement with surgical gastrojejunostomy for palliation in patients with duodenal obstructions caused by pancreaticobiliary malignancies." *Endoscopy* 36(1): 73-8.
- Mercadante, S., E. Catala, E. Arcuri and A. Casuccio (2003). "Celiac plexus block for pancreatic cancer pain: factors influencing pain, symptoms and quality of life." *J Pain Symptom Manage* 26(6): 1140-7.
- Moertel, C. G., L. L. Gunderson, J. A. Mailliard, P. J. McKenna, J. A. Martenson, Jr., P. A. Burch and S. S. Cha (1994). "Early evaluation of combined fluorouracil and leucovorin as a radiation enhancer for locally unresectable, residual, or recurrent gastrointestinal carcinoma. The North Central Cancer Treatment Group." *J Clin Oncol* 12(1): 21-7.
- Mohamadnejad, M., J. M. DeWitt, S. Sherman, J. K. LeBlanc, H. A. Pitt, M. G. House, K. J. Jones, E. L. Fogel, L. McHenry, J. L. Watkins, G. A. Cote, G. A. Lehman and M. A. Al-Haddad "Role of EUS for preoperative evaluation of cholangiocarcinoma: a large single-center experience." *Gastrointest Endosc* 73(1): 71-8.
- Nakai, Y., H. Isayama, Y. Komatsu, T. Tsujino, N. Toda, N. Sasahira, N. Yamamoto, K. Hirano, M. Tada, H. Yoshida, T. Kawabe and M. Omata (2005). "Efficacy and safety of the covered Wallstent in patients with distal malignant biliary obstruction." *Gastrointest Endosc* 62(5): 742-8.
- Neoptolemos, J. P., J. A. Dunn, D. D. Stocken, J. Almond, K. Link, H. Beger, C. Bassi, M. Falconi, P. Pederzoli, C. Dervenis, L. Fernandez-Cruz, F. Lacaine, A. Pap, D.

- Spooner, D. J. Kerr, H. Friess and M. W. Buchler (2001). "Adjuvant chemoradiotherapy and chemotherapy in resectable pancreatic cancer: a randomised controlled trial." *Lancet* 358(9293): 1576-85.
- Neoptolemos, J. P., D. D. Stocken, H. Friess, C. Bassi, J. A. Dunn, H. Hickey, H. Beger, L. Fernandez-Cruz, C. Dervenis, F. Lacaine, M. Falconi, P. Pederzoli, A. Pap, D. Spooner, D. J. Kerr and M. W. Buchler (2004). "A randomized trial of chemoradiotherapy and chemotherapy after resection of pancreatic cancer." *N Engl J Med* 350(12): 1200-10.
- Nguyen-Tang, T., K. F. Binmoeller, A. Sanchez-Yague and J. N. Shah (2010). "Endoscopic ultrasound (EUS)-guided transhepatic anterograde self-expandable metal stent (SEMS) placement across malignant biliary obstruction." *Endoscopy* 42(3): 232-6.
- Nguyen, N. Q. (2009). "Application of per oral cholangiopancreatography in pancreatobiliary diseases." *J Gastroenterol Hepatol* 24(6): 962-9.
- Nguyen, N. Q. and D. F. Bartholomeusz "18F-FDG-PET/CT in the assessment of pancreatic cancer: is the contrast or a better-designed trial needed?" *J Gastroenterol Hepatol* 26(4): 613-5.
- Nguyen, N. Q., K. F. Binmoeller and J. N. Shah (2009). "Cholangioscopy and pancreatoscopy (with videos)." *Gastrointest Endosc* 70(6): 1200-10.
- Nguyen, N. Q., J. N. Shah and K. F. Binmoeller "Outcomes of endoscopic papillectomy in elderly patients with ampullary adenoma or early carcinoma." *Endoscopy* 42(11): 975-7.
- Noble, M. and F. G. Gress (2006). "Techniques and results of neurolysis for chronic pancreatitis and pancreatic cancer pain." *Curr Gastroenterol Rep* 8(2): 99-103.
- O'Toole, T. M. and N. Schmulewitz (2009). "Complication rates of EUS-guided celiac plexus blockade and neurolysis: results of a large case series." *Endoscopy* 41(7): 593-7.
- Oettle, H., S. Post, P. Neuhaus, K. Gellert, J. Langrehr, K. Ridwelski, H. Schramm, J. Fahlke, C. Zuelke, C. Burkart, K. Gutberlet, E. Kettner, H. Schmalenberg, K. Weigang-Koehler, W. O. Bechstein, M. Niedgerthmann, I. Schmidt-Wolf, L. Roll, B. Doerken and H. Riess (2007). "Adjuvant chemotherapy with gemcitabine vs observation in patients undergoing curative-intent resection of pancreatic cancer: a randomized controlled trial." *Jama* 297(3): 267-77.
- Offerhaus, G. J., F. M. Giardiello, A. J. Krush, S. V. Booker, A. C. Tersmette, N. C. Kelley and S. R. Hamilton (1992). "The risk of upper gastrointestinal cancer in familial adenomatous polyposis." *Gastroenterology* 102(6): 1980-2.
- Palmer, D. H., D. D. Stocken, H. Hewitt, C. E. Markham, A. B. Hassan, P. J. Johnson, J. A. Buckels and S. R. Bramhall (2007). "A randomized phase 2 trial of neoadjuvant chemotherapy in resectable pancreatic cancer: gemcitabine alone versus gemcitabine combined with cisplatin." *Ann Surg Oncol* 14(7): 2088-96.
- Paquin, S. C., G. Garipey, L. Lepanto, R. Bourdages, G. Raymond and A. V. Sahai (2005). "A first report of tumor seeding because of EUS-guided FNA of a pancreatic adenocarcinoma." *Gastrointest Endosc* 61(4): 610-1.
- Park, J. K., Y. B. Yoon, Y. T. Kim, J. K. Ryu, W. J. Yoon and S. H. Lee (2008). "Survival and prognostic factors of unresectable pancreatic cancer." *J Clin Gastroenterol* 42(1): 86-91.
- Patel, T. (2001). "Increasing incidence and mortality of primary intrahepatic cholangiocarcinoma in the United States." *Hepatology* 33(6): 1353-7.

- Patel, T. (2006). "Cholangiocarcinoma." *Nat Clin Pract Gastroenterol Hepatol* 3(1): 33-42.
- Peddu, P., A. Quaglia, P. A. Kane and J. B. Karani (2009). "Role of imaging in the management of pancreatic mass." *Crit Rev Oncol Hematol* 70(1): 12-23.
- Pinol, V., A. Castells, J. M. Bordas, M. I. Real, J. Llach, X. Montana, F. Feu and S. Navarro (2002). "Percutaneous self-expanding metal stents versus endoscopic polyethylene endoprostheses for treating malignant biliary obstruction: randomized clinical trial." *Radiology* 225(1): 27-34.
- Prat, F., O. Chapat, B. Ducot, T. Ponchon, G. Pelletier, J. Fritsch, A. D. Choury and C. Buffet (1998). "A randomized trial of endoscopic drainage methods for inoperable malignant strictures of the common bile duct." *Gastrointest Endosc* 47(1): 1-7.
- Puli, S. R., J. B. Reddy, M. L. Bechtold, M. R. Antillon and W. R. Brugge (2009). "EUS-guided celiac plexus neurolysis for pain due to chronic pancreatitis or pancreatic cancer pain: a meta-analysis and systematic review." *Dig Dis Sci* 54(11): 2330-7.
- Regine, W. F., K. A. Winter, R. A. Abrams, H. Safran, J. P. Hoffman, A. Konski, A. B. Benson, J. S. Macdonald, M. R. Kudrimoti, M. L. Fromm, M. G. Haddock, P. Schaefer, C. G. Willett and T. A. Rich (2008). "Fluorouracil vs gemcitabine chemotherapy before and after fluorouracil-based chemoradiation following resection of pancreatic adenocarcinoma: a randomized controlled trial." *Jama* 299(9): 1019-26.
- Serrano, O. K., M. A. Chaudhry and S. D. Leach "The role of PET scanning in pancreatic cancer." *Adv Surg* 44: 313-25.
- Shaib, Y. H., J. A. Davila and H. B. El-Serag (2006). "The epidemiology of pancreatic cancer in the United States: changes below the surface." *Aliment Pharmacol Ther* 24(1): 87-94.
- Shami, V. M. and M. Kahaleh (2007). "Endoscopic ultrasonography (EUS)-guided access and therapy of pancreatobiliary disorders: EUS-guided cholangio and pancreatic drainage." *Gastrointest Endosc Clin N Am* 17(3): 581-93, vii-viii.
- Stocken, D. D., M. W. Buchler, C. Dervenis, C. Bassi, H. Jeekel, J. H. Klinkenbijn, K. E. Bakkevold, T. Takada, H. Amano and J. P. Neoptolemos (2005). "Meta-analysis of randomised adjuvant therapy trials for pancreatic cancer." *Br J Cancer* 92(8): 1372-81.
- Taylor, M. C., R. S. McLeod and B. Langer (2000). "Biliary stenting versus bypass surgery for the palliation of malignant distal bile duct obstruction: a meta-analysis." *Liver Transpl* 6(3): 302-8.
- van Hooft, J. E., M. J. Uitdehaag, M. J. Bruno, R. Timmer, P. D. Siersema, M. G. Dijkgraaf and P. Fockens (2009). "Efficacy and safety of the new WallFlex enteral stent in palliative treatment of malignant gastric outlet obstruction (DUOFLEX study): a prospective multicenter study." *Gastrointest Endosc* 69(6): 1059-66.
- van Tienhoven, G., D. J. Gouma and D. J. Richel (2011). "Neoadjuvant chemoradiotherapy has a potential role in pancreatic carcinoma." *Ther Adv Med Oncol* 3(1): 27-33.
- Verslype, C., E. Van Cutsem, M. Dicato, S. Cascinu, D. Cunningham, E. Diaz-Rubio, B. Glimelius, D. Haller, K. Haustermans, V. Heinemann, P. Hoff, P. G. Johnston, D. Kerr, R. Labianca, C. Louvet, B. Minsky, M. Moore, B. Nordlinger, S. Pedrazzoli, A. Roth, M. Rothenberg, P. Rougier, H. J. Schmoll, J. Tabernero, M. Tempero, C. van de Velde, J. L. Van Laethem and J. Zalcberg (2007). "The management of pancreatic cancer. Current expert opinion and recommendations derived from the 8th World

- Congress on Gastrointestinal Cancer, Barcelona, 2006." *Ann Oncol* 18 Suppl 7: vii1-vii10.
- Vinciguerra, V. (2011). "Adjuvant and neoadjuvant therapy for pancreatic cancer." *Oncology (Williston Park)* 25(2): 192-3.
- Witzigmann, H., H. Lang and H. Lauer (2008). "Guidelines for palliative surgery of cholangiocarcinoma." *HPB (Oxford)* 10(3): 154-60.
- Wong, G. Y., D. R. Schroeder, P. E. Carns, J. L. Wilson, D. P. Martin, M. O. Kinney, C. B. Mantilla and D. O. Warner (2004). "Effect of neurolytic celiac plexus block on pain relief, quality of life, and survival in patients with unresectable pancreatic cancer: a randomized controlled trial." *Jama* 291(9): 1092-9.
- Yamao, K., A. Sawaki, N. Mizuno, Y. Shimizu, Y. Yatabe and T. Koshikawa (2005). "Endoscopic ultrasound-guided fine-needle aspiration biopsy (EUS-FNAB): past, present, and future." *Journal of Gastroenterology* 40(11): 1013-1023.
- Yeo, C. J., J. L. Cameron, T. A. Sohn, K. D. Lillemoe, H. A. Pitt, M. A. Talamini, R. H. Hruban, S. E. Ord, P. K. Sauter and J. Coleman (1997). "Six hundred fifty consecutive pancreaticoduodenectomies in the 1990s: pathology, complications, and outcomes." *Ann Surg* 226(3): 248-257.
- Zadorova, Z., M. Dvofak and J. Hajer (2001). "Endoscopic therapy of benign tumors of the papilla of Vater." *Endoscopy* 33(4): 345-7.
- Zuckerman, D. S. and D. P. Ryan (2008). "Adjuvant therapy for pancreatic cancer: a review." *Cancer* 112(2): 243-9.

IntechOpen



New Advances in the Basic and Clinical Gastroenterology

Edited by Prof. Tomasz Brzozowski

ISBN 978-953-51-0521-3

Hard cover, 546 pages

Publisher InTech

Published online 18, April, 2012

Published in print edition April, 2012

The purpose of this book was to present the integrative, basic and clinical approaches based on recent developments in the field of gastroenterology. The most important advances in the pathophysiology and treatment of gastrointestinal disorders are discussed including; gastroesophageal reflux disease (GERD), peptic ulcer disease, irritable bowel disease (IBD), NSAIDs-induced gastroenteropathy and pancreatitis. Special focus was addressed to microbial aspects in the gut including recent achievements in the understanding of function of probiotic bacteria, their interaction with gastrointestinal epithelium and usefulness in the treatment of human disorders. We hope that this book will provide relevant new information useful to clinicians and basic scientists as well as to medical students, all looking for new advancements in the field of gastroenterology.

How to reference

In order to correctly reference this scholarly work, feel free to copy and paste the following:

Nam Q. Nguyen (2012). Pancreato-Biliary Cancers – Diagnosis and Management, New Advances in the Basic and Clinical Gastroenterology, Prof. Tomasz Brzozowski (Ed.), ISBN: 978-953-51-0521-3, InTech, Available from: <http://www.intechopen.com/books/new-advances-in-the-basic-and-clinical-gastroenterology/pancreato-biliary-cancers-diagnosis-and-management>

INTECH
open science | open minds

InTech Europe

University Campus STeP Ri
Slavka Krautzeka 83/A
51000 Rijeka, Croatia
Phone: +385 (51) 770 447
Fax: +385 (51) 686 166
www.intechopen.com

InTech China

Unit 405, Office Block, Hotel Equatorial Shanghai
No.65, Yan An Road (West), Shanghai, 200040, China
中国上海市延安西路65号上海国际贵都大饭店办公楼405单元
Phone: +86-21-62489820
Fax: +86-21-62489821

© 2012 The Author(s). Licensee IntechOpen. This is an open access article distributed under the terms of the [Creative Commons Attribution 3.0 License](#), which permits unrestricted use, distribution, and reproduction in any medium, provided the original work is properly cited.

IntechOpen

IntechOpen