

We are IntechOpen, the world's leading publisher of Open Access books Built by scientists, for scientists

4,800

Open access books available

122,000

International authors and editors

135M

Downloads

Our authors are among the

154

Countries delivered to

TOP 1%

most cited scientists

12.2%

Contributors from top 500 universities

**WEB OF SCIENCE™**Selection of our books indexed in the Book Citation Index
in Web of Science™ Core Collection (BKCI)

Interested in publishing with us?
Contact book.department@intechopen.com

Numbers displayed above are based on latest data collected.

For more information visit www.intechopen.com

Minimally Invasive Distal Metatarsal Osteotomy for Mild-to-Moderate Hallux Valgus

Ahmed Enan
Mansoura University,
Egypt

1. Introduction

Hallux valgus is a common disorder of the forefoot that results from medial deviation of the first metatarsal and lateral deviation and / or rotation of the great toe (hallux) with or without medial soft-tissue enlargement of the first metatarsal head (bunion) (1).

2. Potential etiology

The pathogenesis of hallux valgus has been described as being due to muscle imbalance.

A. Extrinsic factors

Hallux valgus occurs almost exclusively in shoe - wearing societies. Coughlin and Thompson (2) noting the extremely high prevalence of bunions in American women in the fourth, fifth or sixth decade of life, implicated constricting footwear as a cause of hallux valgus. Likewise, in Japan, Kato and Watanabe (3) noted that the prevalence of hallux valgus in women increased dramatically following the introduction of high - fashion footwear after World War II.

B. Intrinsic factors

While constricting footwear appears to be the major extrinsic cause of hallux valgus, intrinsic factors play a role as well. Inman (4) and Hohmann (5) both suggested pronation of the hindfoot as a major cause of bunion formation, while Mann and Coughlin (6) as well as others (7,8) reported that pes planus plays a minor role in this process. An increased angle between the first and second metatarsals (metatarsus primus varus) is often associated with hallux valgus deformity. (9) Other intrinsic causes of Hallux valgus may include contracture of the Achilles tendon, generalized joint laxity, hypermobility of the first metatarso - cuneiform joint, and neuromuscular disorders (including cerebral palsy and stroke). (10) Heredity is thought to influence the development of hallux valgus in many individuals. Hardy and Clapham noted that 63 % of the patients in their series had a parent who had hallux valgus. (9) The primary symptom of hallux valgus is pain over the medial eminence. Pressure from footwear is the most frequent cause of this discomfort.

2.1 Measurements of the deformity

Two angles frequently are used to describe the anatomical deformity and the effects of a surgical procedure: the first intermetatarsal angle (IMA) and the hallux valgus angle (HVA).

Authors classify mild as an IMA $< 13^\circ$, moderate as IMA $13 - 20^\circ$, and severe as an IMA $> 20^\circ$. Generally, a HVA $> 40^\circ$ is considered severe. (11)

2.2 Surgical treatment

The condition is widely reported in the Western literature. The incidence of hallux valgus was as high as 50 % in a study in South Africans (12) and as low as 2 % in a study on barefoot population. (13) Nonoperative treatment is always the first option for a patient with hallux valgus deformity. Surgery is proposed when the painful hallux valgus is not adequately controlled by the nonoperative treatment. Over the past century, around 150 surgical procedures have been developed to reduce the deformity, and the continued development of new techniques would suggest that previous techniques are not completely successful. Poorly planned or executed surgery may lead to high levels of patient dissatisfaction. In the last few years, several new osteotomies have been described, but often it is difficult to ascertain what the best choice for a given patient is, as evidence-based guidelines are lacking.(1) The main goal of surgical correction of hallux valgus is the morphologic and functional rebalance of the first ray, correcting all other characteristics of the deformity. Historically, distal metatarsal osteotomies have been indicted in cases of mild or moderate deformity with an intermetatarsal angle as large as 15° . Using certain osteotomies, it is possible to correct intermetatarsal angles as large as 20° . Distal osteotomies may also be used to correct deformities characterized by deviation of the distal metatarsal articular angle (DMAA) or to address concomitant stiffness.(14) Since the first operation published by Revenrdin (15) in 1881, many authors have reported their experience using different operations, each of them characterized by different indications, approaches, designs, and fixation.(16-24) There is an increasing concern among orthopaedists towards the potentials of minimally invasive procedures. Applied to foot surgery, minimally invasive surgery (MIS) can be accomplished in shorter time respect of a conventional surgery, together with less distress and problems to the soft tissues. In addition, the operation can be done bilaterally; it allows use of distal anaesthetics blocks and early weight-bearing. In 1986, Van Enoo defined the minimum-incision surgery as an operation done through the smallest incision required for a proper procedure, and the percutaneous surgery as that performed within the smallest possible working incision in a closed fashion. (25) A percutaneous MIS requires the use of dedicated instruments and frequently a fluoroscopy. Lui and other colleagues from Hong Kong have described arthroscopic and endoscopic assisted correction of hallux valgus deformities. (26, 27) Morton Polokoff, a podiatric physician, in 1945 tried to use fine chisels, rasps and spears to perform subdermal surgery. Years later, Leonard Britton accomplished the first osteotomy on bunion deformities with percutaneous exposure of the first metatarsal, a closing wedge osteotomy, and the Akin procedure. North American podiatrists started to adopt MIS of the foot in 1970.(28) The technique percutaneous surgery for hallux valgus correction that we use derives from that described by Lamprecht-Kramer-Bösch in 1982.(16,29) These authors based the procedure on the subcapital metatarsal linear osteotomy of Hohmann.(30) In 1991, Isham described a minimally invasive distal metatarsal osteotomy without implantation.(31) The results of recent French studies showed that patients treated with minimally invasive surgery for hallux valgus needed less hospitalization time and recovered earlier.(32) Minimum incision techniques, by allowing limb safety with reduced damage of soft tissue

or bones trauma should be a first choice indication to patients at high risk of ulceration.(33,34) The characteristics of this technique can be summarized with the abbreviation SERI (simple, effective, rapid, inexpensive).

3. Indications

The SERI technique is indicated to correct mild to moderate reducible deformity when the hallux valgus angle is as large as 40° and the intermetatarsal angle is as large as 20° . The operation is indicated if the metatarsophalangeal joint is either incongruent or congruent, or with modification of the DMAA, and if mild degenerative arthritis is present. The technique is indicated even in cases of recurrent deformity.

4. Contraindications

Specific contraindications of the SERI technique are patients older than 75 years, severe deformity with the intermetatarsal angle larger than 20° , severe degenerative arthritis or stiffness of the metatarsophalangeal joint, and severe instability of the cuneometatarsal or metatarsophalangeal joint. The technique is not indicated in hallux rigidus and in patients in whom a Keller's procedure unsuccessful .(35,36)

5. Preoperative assessment

The preoperative plan includes acquiring a complete history of the patient plus physical and radiographic examination. The patient's complaints of pain, limitation in the use of footwear, and cosmetic concerns should be considered. Moreover, the severity of the prominent medial eminence and the hallux valgus deformity, as well as the great toe mobility at the metatarso - phalangeal joint and the reducibility of the deformity should be evaluated. The latter is tested by pushing laterally the metatarsal head with one hand, and simultaneously the great toe medially with the other hand. Stability of the metatarso - phalangeal and metatarso - cuneiform joints must be assessed. Combined rotational deformity of the great toe or callosities under the first or second and third metatarsal heads must be considered, as well as any associated deformities of the lesser toes. A standard radiographic examination, including anteroposterior and lateral weight-bearing views of the forefoot, allows the assessment of the arthritis and congruency of the joint; measurement of the hallux valgus angle and intermetatarsal angle. The hallux valgus angle was measured by the method of Piggot. (37) The intermetatarsal angle by the method of Coughlin et al . (38) (fig. 1). The relative length of the first metatarsal was measured by the method of Morton. (39) (fig. 2)

6. Surgical technique

This technique was described by the author in the study that was published in *Acta Orthopædica Belgica*, Vol. 76 - 4 - 2010. The patient is placed in the supine position, with a below knee wedge bracket allowing 90° of knee flexion and a plantigrade position of the foot on the operating table. Pneumatic tourniquet was applied in all cases. The operation is performed with either general or ankle - block anesthesia. The fluoroscopic image intensifier must be positioned to the side of the patient while the surgeon stands in front of the patient at the end of the table. Normally with this technique, soft - tissue release is not needed because attenuation is achieved with the lateral offset of the metatarsal head itself. If

a slight stiffness of the metatarsophalangeal joint is present, manual stretching of the adductor hallucis is performed, forcing the big toe into a varus position.

Step 1. Wire insertion. Under image intensifier a 2.0 mm K - wire is inserted starting from the proximal medial corner of the nail of the great toe. (fig. 3- A) The pin is manually driven along the medial border of the proximal phalanx in a distal - to - proximal direction to end distal to the site of the planed osteotomy. It is mandatory to place the wire in an extraperiosteal position in order to allow lateral displacement of the capital fragment at the osteotomy site. (fig. 3- B) The wire must be midway between the dorsal and plantar aspect of the great toe in order to engage the metatarsal head correctly. This represents one of the most important biomechanical aspects of the technique. If the metatarsal head should be shifted plantarward, the pin has to be inserted more dorsally. If the metatarsal head should be shifted dorsally, the K - wire has to be inserted more plantarward. Plantar translation is done more often.

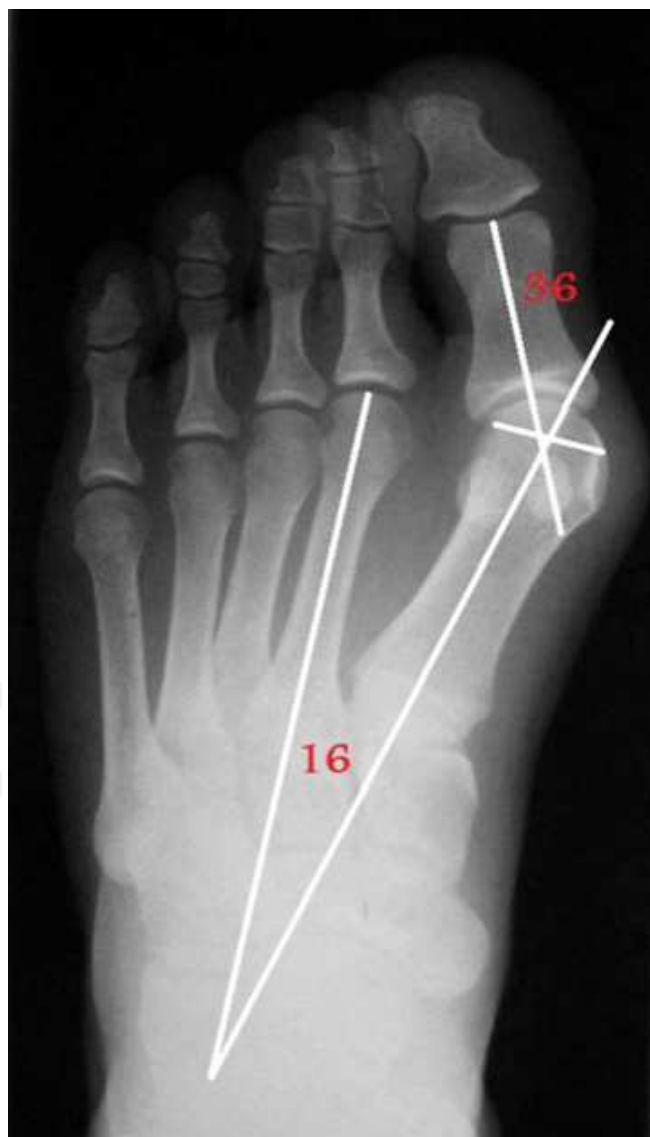

Fig. 1. A-P standing radiograph. Measurement of HVA and first IMA.

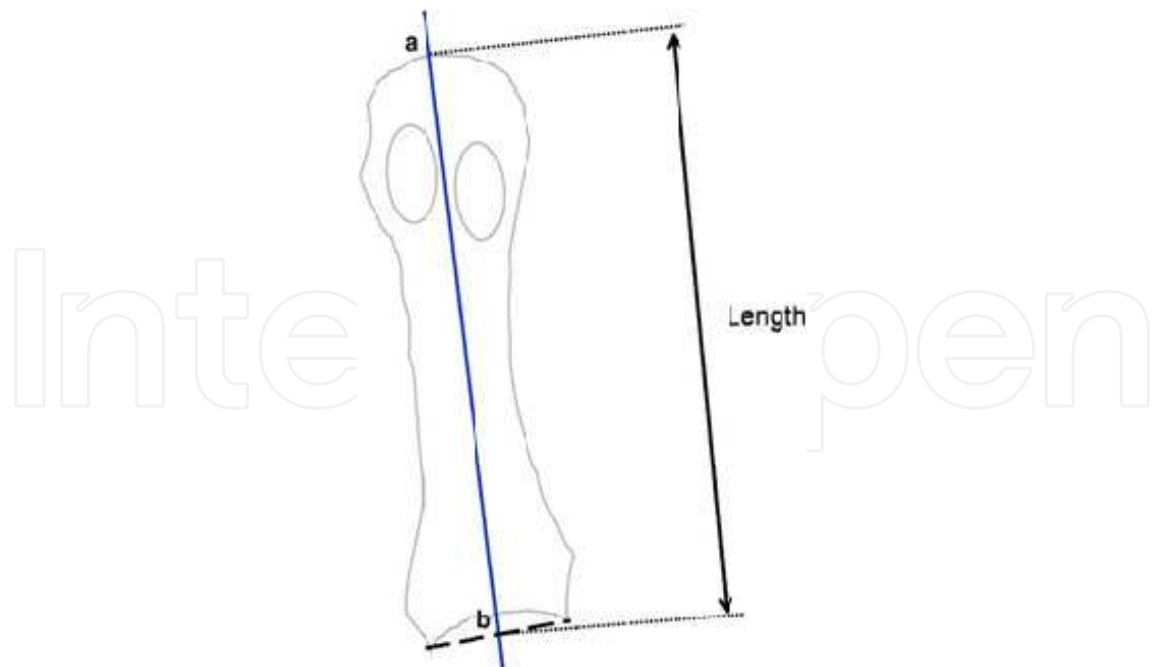
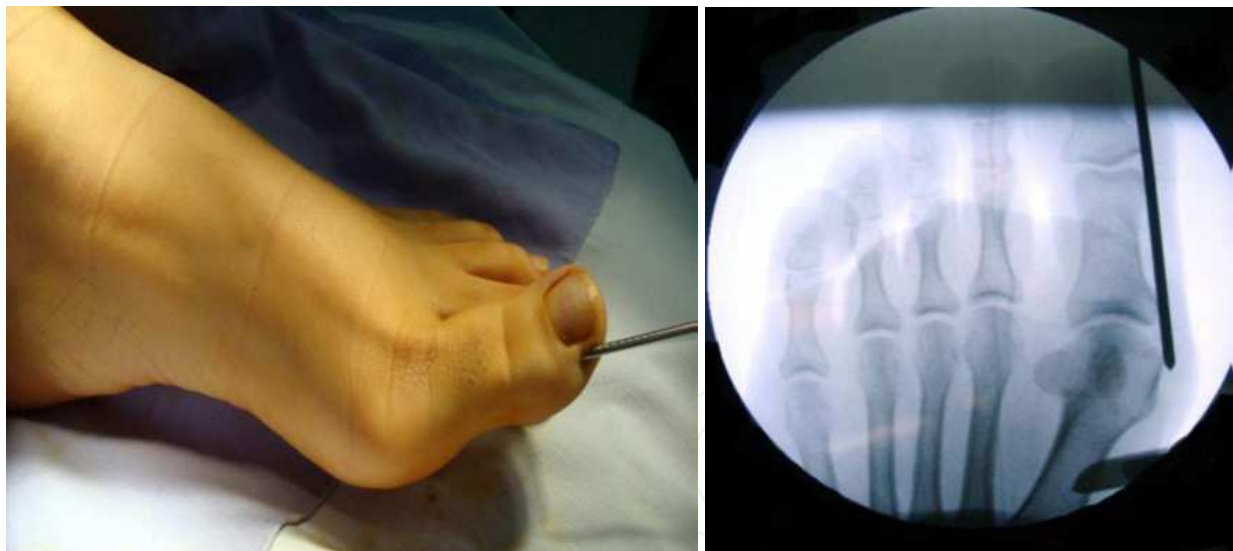

Fig. 2. Method of measuring the length of the first metatarsal. (a) Distal end of the first metatarsal head. (b) Point of intersection of the first metatarsal longitudinal axis with a line connecting the proximal-medial and proximal-lateral ends of the metatarsal base.



A

B

Fig. 3. A. 2 mm Kirschner wire is inserted in the medial corner of the nail of the great toe. B. Extraperiosteal position of the K- wire along the medial border of proximal phalanx

Step 2. Skin incision. A 1.5 cm skin incision was made and centered over the medial aspect of the first metatarsal neck. (fig. 3- C) The incision was carried directly to the bone, cutting the periosteum, with care being taken to remain in the midline equally between the dorsal and plantar aspects of the metatarsal neck in order to avoid the neurovascular bundle.

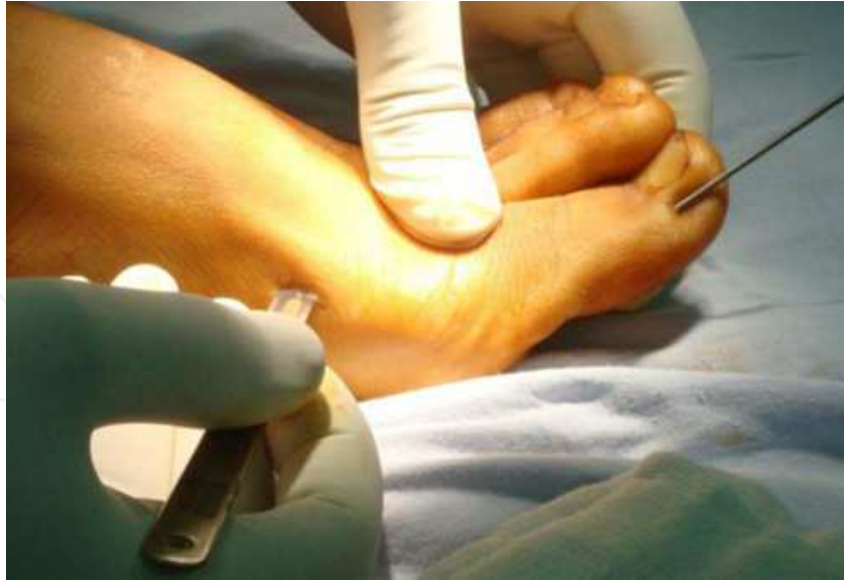

Fig. 3. C. 1.5 cm skin incision centered over the medial aspect of the first metatarsal neck.

Step 3. Periosteal detachment. Next, the periosteum around the osteotomy site is detached dorsally and then plantarly, with use of small scissors inserted through the skin incision. (fig. 3- D) In this way, the soft tissues surrounding the metatarsal shaft can be kept away from the bone cutter (saw).

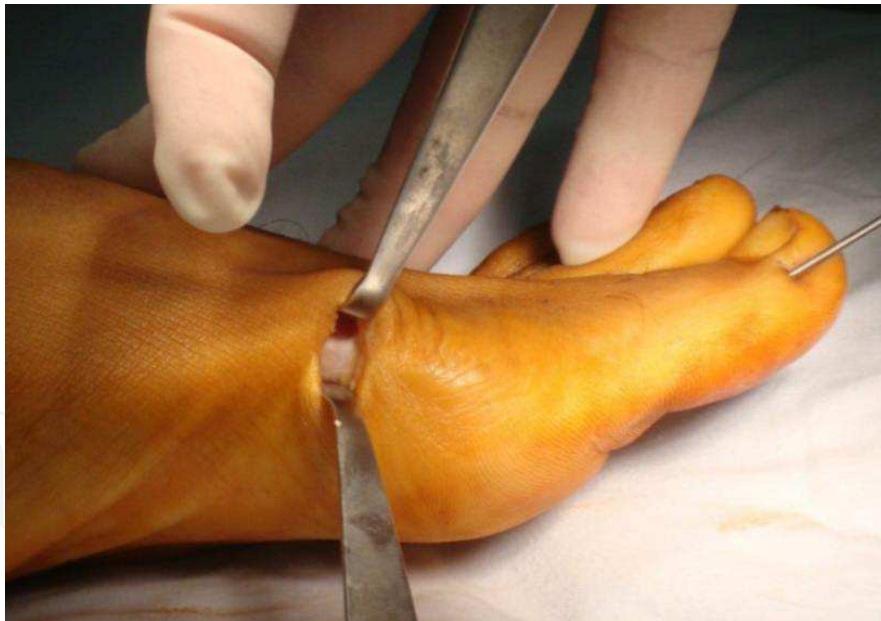

Fig. 3. D. Periosteum around the osteotomy site is detached dorsally and then plantarly

Step 4. Osteotomy. The osteotomy is then performed through the subcapital region of the first metatarsal with an oscillating saw. (fig. 3- E) The level of the cut is first checked under fluoroscopy. The osteotomy is made perpendicular to the long axis of the shaft of the first metatarsal in the sagittal plane. (fig. 3- F) In the frontal plane, the osteotomy should be performed with slight mediolateral obliquity to facilitate lengthening or shortening as dictated by the preoperative plan. Generally, a slight

lengthening is recommended in order to avoid metatarsal shortening. Finally, the osteotomy site is checked manually and under fluoroscopy to confirm sufficient mobility of the metatarsal head.

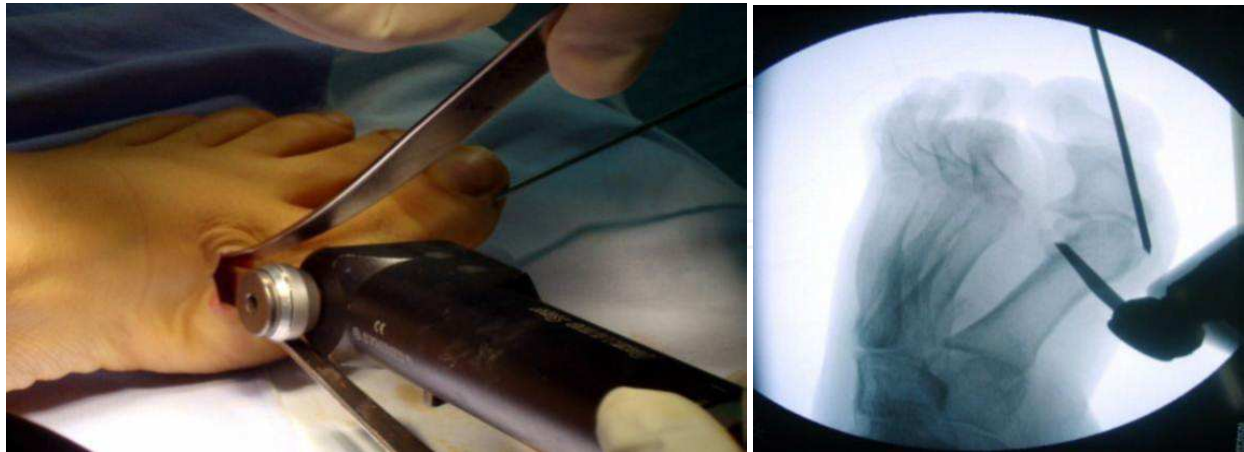


Fig. 3. E. The osteotomy performed through the subcapital region of the first metatarsal with an oscillating saw. F. The level of the cut is checked

Step 5. Metatarsal displacement and correction. The proximal part of the first metatarsal is then displaced medially with the aid of a curved small artery forceps introduced in the medullary canal in order to facilitate the insertion of the K - wire. (fig. 3- G) After lateral translation of the metatarsal head, the wire was introduced under direct vision into the medullary canal of the metatarsal shaft. (fig. 3- H) The correction of the big toe was determined grossly. If pronation of the first metatarsal bone is present, the correction is obtained with a derotation of the big toe up to the neutral position.

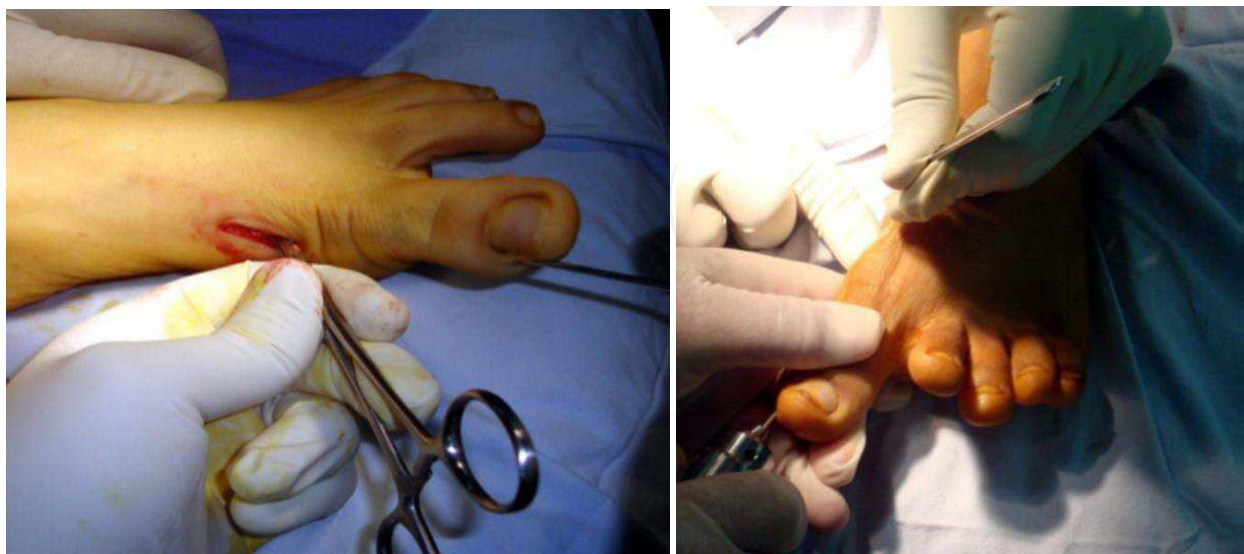


Fig. 3. G. Using a curved small artery forceps the proximal part of first metatarsal is displaced medially. H. Lateral displacement of the head and correction of hallux achieved with the Kirschner wire introduced under direct vision into the medullary canal

Step 6. Advancement of the wire through the mid tarsals. The wire was driven through the first tarsometatarsal joint for greater stabilization. (fig. 3- I)

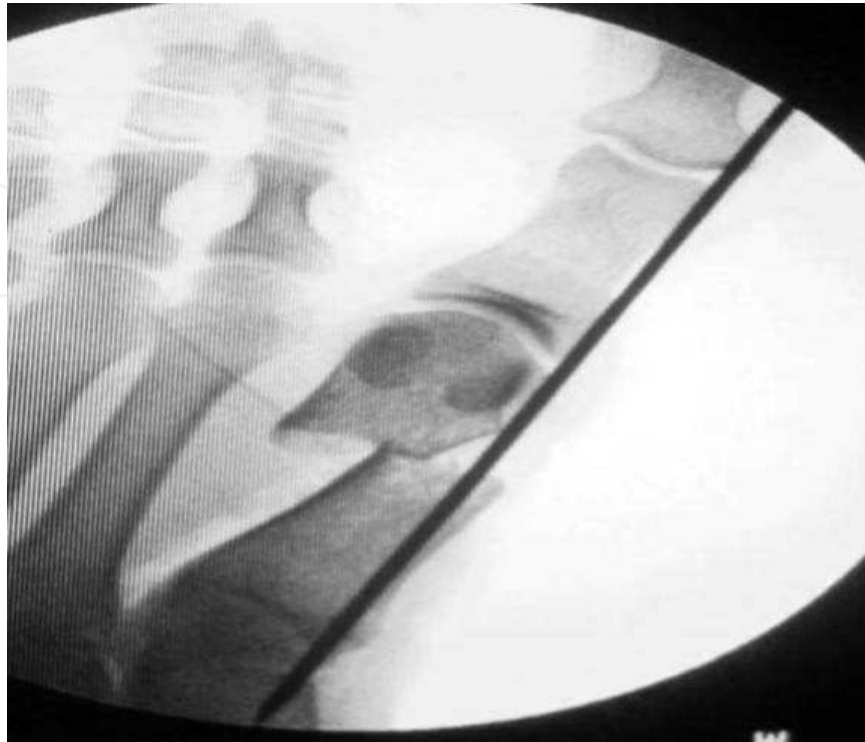

Fig. 3. I. The kirshner wire is driven through the first tarsometatarsal joint for greater stabilization.

Step 7. Closure. The skin is sutured with two 2 - 0 prolene stitches. The distal extremity of the K - wire is curved and cut out of the tip of the toe. (fig. 3- J) A plantar pad was placed under the operated foot to reduce weight - bearing pressure under the first metatarsal head area. An elastic bandage was used as a postoperative dressing to hold the big toe in alignment . It was taped in a supination manner to counteract pronation of the big toe. (fig. 3- K)

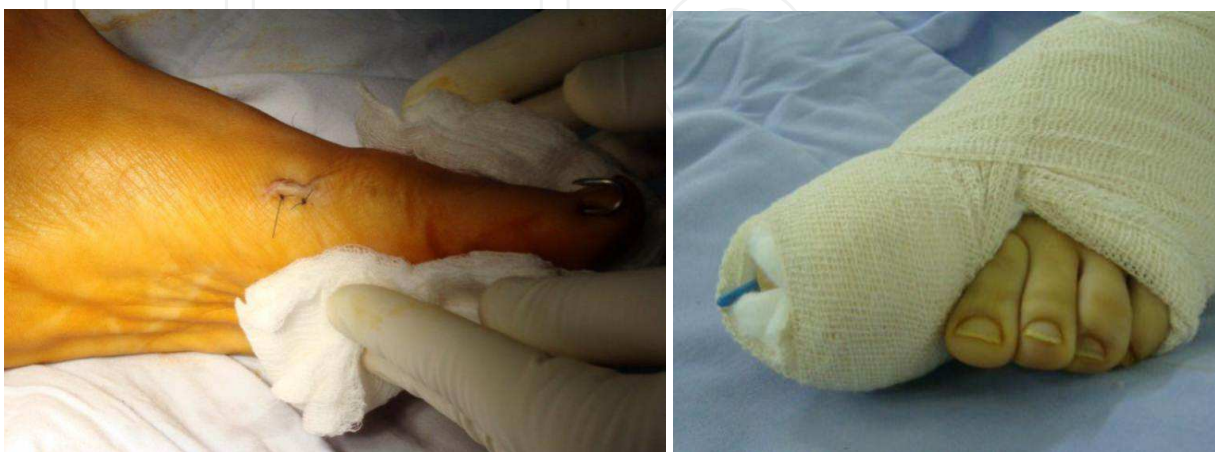

Fig. 3. J. Skin is closed with two 2-0 prolene stitches and the wire bend and cut. K. Elastic bandage was used as a postoperative support to hold the big toe in alignment.

7. Follow-up

Postoperatively, Patients can walk immediately in a flat, rigid sole postoperative shoe, which allows not to put weight through the osteotomy, though in the beginning they are advised to walk for short times only, and to rest with the foot raised while supine or sitting.

The stitches were removed two weeks after surgery, while the K - wire was removed 6 weeks postoperatively.

Patients were allowed to bear weight with normal shoes, and range of motion exercises of the first metatarsophalangeal joint was carried out from then on.

The postoperative examinations included X - ray next day postoperative and then six weeks after the operation. The patient is then reviewed between two and three months later for the third radiological and clinical control. The future follow - up frequency is variable, and usually every 6 months.

Clinically the patients on each follow - up were questioned about the cosmetic appearance of the foot, pain over the metatarsal head and shoe - wear problems. Thorough clinical examination was done looking for appearance, calluses under second and third metatarsal heads (transfer lesions), sensory abnormalities, and the range of motion of first MTP joint.

Furthermore, the clinical rating system for foot and ankle function, established by Kitaoka et al (40) [American Orthopaedic Foot and Ankle Society (AOFAS) Hallux - Metatarsophalangeal - Interphalangeal Score] was used as a quantification of the clinical and subjective evaluation at follow - up. Additionally the patients have been asked whether they were satisfied with the result of the operation or not. During the examination, special attention was paid to the aspect of metatarsalgia. The assessment of the passive range of motion (ROM) of the first metatarso - phalangeal joint was performed according to Okuda et al. (41)

The preoperative and the follow - up radiographs were made with the patient in the weight - bearing position.

Quantitative data were described by mean \pm standard deviation (SD) or if more appropriate by median and range. Statistical analyses were performed using SPSS software V. 16.0 (SPSS Inc., Chicago, IL, USA).

8. Results of our study

Twenty - six patients with symptomatic mild - to - moderate hallux valgus deformities were operated using minimally invasive distal metatarsal osteotomy. Two patients were lost to follow - up and could not complete the minimum follow - up period of 12 months. The study describes the results of 36 feet in 24 patients comprising 20 female and 4 male patients. Twelve patients had a bilateral involvement. The age of the patients ranged from 17 to 52 years, the mean age being 37.8 years. The average follow - up period was 21 months (range 12 - 36 months).

9. Clinical results

Hallux - Metatarsophalangeal - Interphalangeal Scale proposed by the American Orthopaedic Foot and Ankle Society (AOFAS) was used for the clinical assessment. This

system provides a score ranging from 0 to 100 points, which takes into consideration both subjective and objective elements such as pain (maximum score, 40 points), functional capacity (maximum score, 45 points), and hallux alignment (maximum score, 15 points). For all patients were seen at the time of final follow - up, there was no case of worsening of pain and no patient who presented with shoe - wear restriction as primary symptom had such pain after surgery. Eighteen patients (thirty feet; 83.3 %) reported total disappearance of the pain, four patients (four feet; 11.1 %) had only mild occasional pain, two patients (two feet; 5.6 %) had daily moderate pain, and no patient had severe or constant pain. The mean overall pain score was 37.3 ± 4.7 points of the 40 point maximum on the AOFAS.

The functional capacity of the hallux, which was graded by summing the scores for the six different aspects of functional performance on the hallux - metatarsophalangeal - interphalangeal scale, averaged 40.9 ± 3.6 points (maximum score on the scale, 45 points). The maximum score for hallux alignment (15 points, indicating excellent or good alignment) on the hallux - metatarsophalangeal - interphalangeal scale was recorded for thirty feet (83.3%) in 20 patients; mild, asymptomatic malalignment (a score of 8 points) was recorded for six feet (16.7%) in four patients; and symptomatic malalignment (a score of 0 points) was not recorded in our study. The overall mean score for hallux alignment was 12.9 ± 4.2 points.

The total scores at the time of final follow - up according to the system of the American Orthopaedic Foot and Ankle society was 91.2 ± 6.8 points. Motion of the first metatarsophalangeal joint was limited to $< 30^\circ$ in three feet (8.3%). Patients were satisfied with the results of 31 (86%) of the 36 procedures and dissatisfied with the results of five (14%). Satisfaction was evaluated as the patient's willingness to undergo surgery again or not.

10. Radiographic results

According to radiographic results of the 36 consecutive MIDMOs the mean HVA decreased from 27.7° preoperatively to 14.6° at the final follow - up ($p < 0.001$). The first IMA decreased from an average of 11.2° preoperatively to 5.8° at the final follow - up ($p < 0.001$).

Plantar displacement of the first metatarsal head (mainly a plantar translation, with some degree of plantar angulation) was found at the time of follow - up in 17 (47.3%) of the 36 feet, dorsiflexion of the head (mainly angular deformity) was seen in three feet (8.3%), and a position that can be defined as neutral (essentially similar to the preoperative position) was observed in sixteen feet (44.4%). The extent of lateral displacement of the first metatarsal head was $56.2\% \pm 18.4\%$ of the diameter of the first metatarsal shaft in the immediate postoperative period and $36.1\% \pm 15.9\%$ at the time of follow - up. The relative shortening of the first metatarsal was measured in 11 feet (30.6%). In the remaining 25 feet the shortening was not measured. The mean first metatarsal shortening was 2.2 ± 2.8 mm (range: -8 to 3.4 mm). All of the osteotomies healed well, with callus evidence after an average of 3 months. All of the metatarsal bones remodeled themselves over time (fig. 4) even in cases with marked offset at the osteotomy (several millimeters of bony contact). In our experience, the healing of the osteotomy and remodeling capability of the metatarsal bone are not related to the offset at the osteotomy, but it is preferable to obtain a bony contact not less than one third of the metatarsal section.

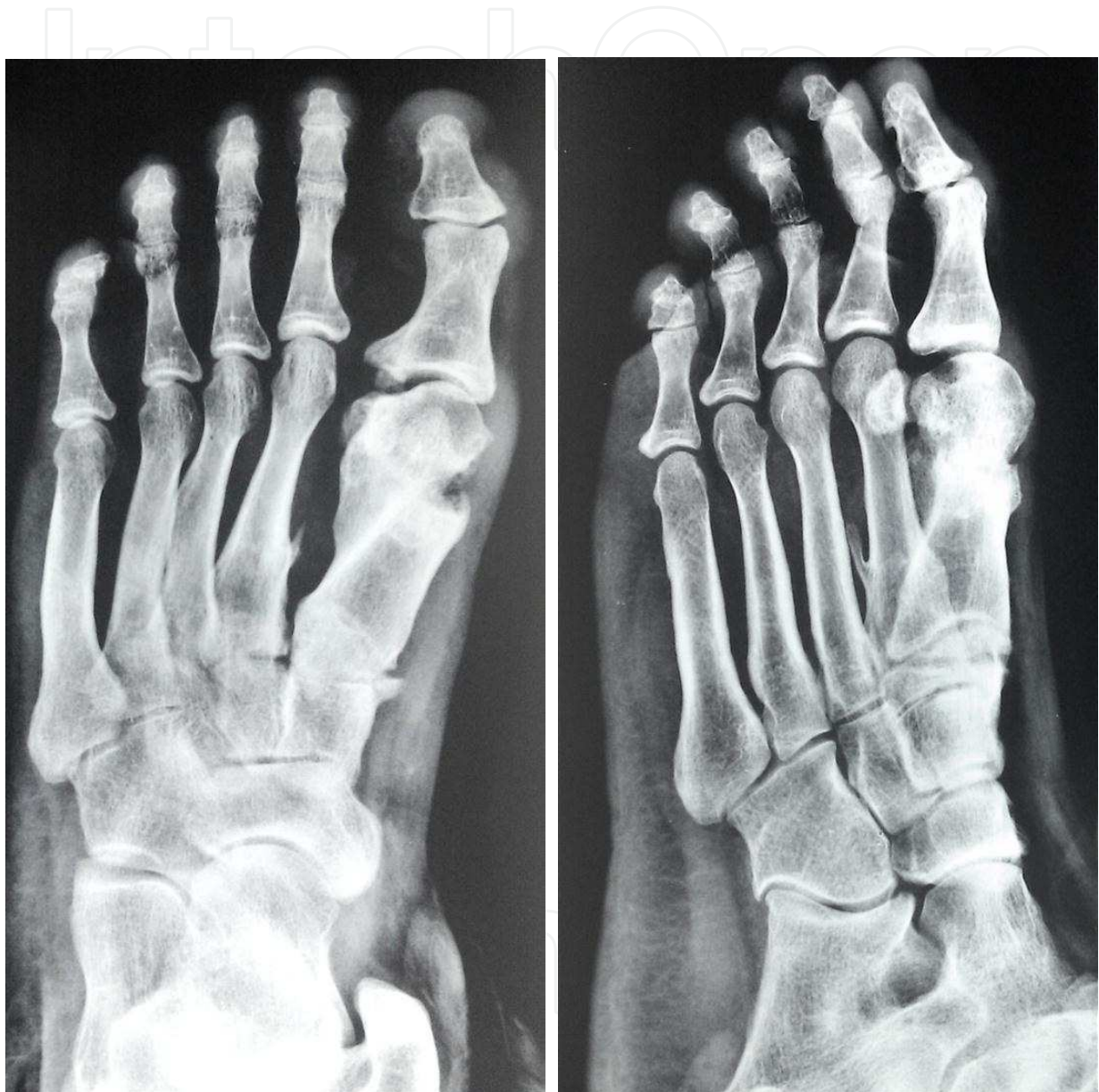

Fig. 4. A-P and oblique standing radiograph, showing remodeling of the First MTP 24 months postoperative.

11. Complications

No intraoperative complications occurred in our study except in one foot some comminution occurred at the osteotomy site but did not affect either the stability of fixation or the union of the osteotomy. After dressing removal, in 3 feet a mild skin inflammatory reaction was present around the outlet of the K - wire at the tip of the toe. There was no need to remove the K - wire before the scheduled time. There were no episodes of nonunion, malunion, transfer metatarsalgia or avascular necrosis of the metatarsal head. No cases of secondary hallux varus were observed despite the slight overcorrection that had been consistently achieved at the time of stabilization of the osteotomy site. No patient underwent a deep venous thrombosis.

12. Discussion

The goal of operative treatment is to offer relief of pain, correction of forefoot deformity and a biomechanically functional foot. For a long time, bunion surgery had a reputation for being very painful with a lengthy recovery period. Indeed, many people put up with their bunions for years rather than face surgery. This was because older techniques involved cutting the bone and not using any form of fixation. Newer techniques introduced during the past decade enabled surgeons to fix the bones into the correct position, reducing pain and promoting a better and more controlled recovery.

However, we are constantly exploring ways of moving from open surgery to minimally invasive techniques, replacing large incisions with small 'ports' through which the surgeon works. In doing so, we offer important benefits for the patient, removing or damaging less tissue, reducing scarring and the subsequent risk of infection.

Minimally invasive distal first metatarsal osteotomy with a percutaneous technique was first described by Bösch et al in 1990 , and a satisfactory result was reported in a 7 - 10 year follow - up study. (30) Portaluri (42) achieved 89% satisfaction rate with the Bösch method and stated that the advantages of this technique included short operation time and low incidence of complications. Sanna and Ruiu (43) reported excellent results in a long - term follow - up study of percutaneous distal first metatarsal osteotomies. Magnan et al (44) reported that the patients were satisfied following 107 (91%) of 118 percutaneous distal first metatarsal osteotomies.

Numerous studies have revealed that minimally invasive hallux valgus surgery can achieve a good satisfaction rate similar to other open techniques. (45,46) The distal metatarsal osteotomy in our study was a minimally invasive, simple bony procedure without other advanced soft tissue procedures. We did not perform bunion resection, formal capsulorrhaphy, lateral release or capsulotomy.

Our study involved twenty - four adult patients (36 feet) in the age range of 17-52 years with mild - to - moderate hallux valgus managed with the minimally invasive distal metatarsal osteotomy (MIDMO). The mean overall pain score was 37.3 ± 4.7 points of the 40 point maximum on the AOFAS. These results are comparable to other series that have reported satisfactory improvement in pain in 80-95% patients using open techniques. In a study of 91 Mitchell osteotomies, in which painful bunion justified surgery in 92% of

patients; Desjardins et al (47) achieved satisfactory improvement of pain in 92% of patients. Johnson et al (48) published their results comparing distal chevron osteotomy to the modified McBride bunionectomy in a retrospective study. Ninety - two percent of patients in the chevron group and 88% of patients in the modified McBride group responded that they were totally satisfied or improved regarding pain relief after surgery.

The results of other series using minimally invasive techniques also reported comparable results to that of our study as the mean overall pain score reported by Magnan et al (44) was (36.3 ± 6.2 points) and that reported by Yu-Chuan Lin et al (49) was (35.7 ± 5 points).

In our study, the mean HVA and first IMA corrections were 13.1° and 5.4° respectively compared with 17.8° and 5.1° in Magnan et al's study and 11.8° and 6.3° in the study by Yu-Chuan Lin et al.

Our results indicate that this minimally invasive technique can achieve angular correction that is as good as that achieved using traditional techniques. It has been demonstrated that the mean HVA correction ranged from 8.8° to 26° , and the mean first IMA correction ranged from 3.8° to 11° in studies that used open techniques. (6, 50, 51)

A limitation of this minimally invasive approach is that we were unable to control the magnitude of lateral translation. This method simply relied on the stiffness of the K - wire and the size of the capital fragment to achieve lateral translation. We believe that the magnitude of angular correction might limit the use of our approach to treat more severe hallux valgus deformities. This explains why the inclusive criterion in our study was set at first intermetatarsal angle $\leq 18^\circ$.

The absence of lateral release or formal capsulorrhaphy might explain the absence of hallux varus after surgery. In Magnan et al's and our studies, there were no episodes of hallux varus (overcorrection).

The valgus deformity recurrence rate reported by Magnan et al was 2.5%. In our study there was no cases of recurrence this may be explained by the smaller number of cases (36 feet) compared with (118 feet) operated by Magnan et al, also due to good selection of the cases according to the inclusion criterion.

The lack of soft tissue surgery does not appear to affect the prevalence of recurrent hallux valgus deformity, perhaps because reorientation of the metatarsal head and reduction of the head on the sesamoids were the consistently achieved primary surgical objectives. In other studies that used open techniques in association with soft tissue procedures, the recurrence rate ranged from 0% to 10%. (17,51,52,53)

Although some of our cases had an increase in HVA after K - wire removal, the HVA and first IMA were significantly decreased at final follow - up. The Kirschner wire insertion level in the study of Yu-Chuan Lin et al was at the middle of the proximal phalanx. In our study and that of Magnan et al, the more distal percutaneous insertion level of the K - wire, might achieve a greater correction of the hallux valgus angle because of a longer level arm to abduct the big toe.

The mean extent of lateral displacement of the first metatarsal head in our study was 56.2% of the diameter of the first metatarsal shaft in the immediate postoperative period and 36.1%

at the time of full consolidation of the osteotomy site. This seems similar to that reported by Magnan et al (52.6%, 32.8% respectively). The action of the long extensor and long flexor tendons on the hallux during the plasticity phase of the healing callus probably offset the slight hypercorrection obtained at the time of surgical stabilization.

In our study the relative length of the first metatarsal was measured by the method of Morton. (39) Morton's method has two advantages: First, it detects the "biomechanical length" of the first metatarsal (medial deviation of the first metatarsal leads to a functional shortening). Second, the probability of a measuring fault caused by perspective distortion of the radiographs is reduced. In our study the relative shortening of the first metatarsal was measured in 11 feet (30.6%). In the remaining 25 feet the shortening was not measured. The mean first metatarsal shortening was 2.2 ± 2.8 mm (range: - 8 to 3.4 mm). The measured lengthening in some cases can be explained by the reduction of the first IMA and the consequent functional lengthening of the first metatarsal.

Transfer metatarsalgia, which might affect clinical outcomes, is a serious complication after first metatarsal osteotomy. Transfer metatarsalgia occurred with a range from 0% to 40% in studies that used other open techniques. (52) It may be found as a sequelae of dorsalization of the first metatarsal head or significant shortening of the first metatarsal. Transfer metatarsalgia was not reported in our series, and it was not mentioned by Magnan et al . This may be explained by that the osteotomy performed in MIDMO was in a single perpendicular plane, which was unable to cause over shortening of the first metatarsal. Also there was mild dorsiflexion of the capital fragment in the lateral radiographic image after surgery in only 3 feet out of the 36 feet in our study.

Stiffness of first metatarsophalangeal joint was reported to range from 0% to 37.8% using open techniques with capsulotomy. (52,54) This may be explained by lengthening of the first metatarsal through an oblique distally oriented osteotomy (dorsal arm) and excessive medial capsular tightening may lead to impaired range of motion of the MPI joint. However, this problem can be treated by early passive mobilization of the MPI joint. Postoperative stiffness of the first metatarsophalangeal joint in our study was calculated as 8.3% while was 6.8% in Magnan et al and 4.26% in that done by Yu-Chuan Lin et al . This problem was related to poor mobilization of the hallux following removal of the tape. However, these patients did not regard the joint motion deficit as disabling, and the rigidity did not cause pain during walking.

We did not have any case of postoperative avascular necrosis of first metatarsal head. This is probably due to the preservation of soft tissues on the lateral side of the metatarsal. These structures on the lateral side are important for the blood supply of the distal fragment. In our study, there were no episodes of nonunion, malunion or deep infection.

13. Conclusions

The results of our study demonstrate that MIDMO with a percutaneous K - wire stabilization under fluoroscopic control, without removal of the eminence and without open lateral release, performing only a manipulation of the great toe is an effective, reliable method of treating mild - to - moderate hallux valgus deformity in adult patients. The results appear to be comparable with those reported following traditional open techniques. Good satisfaction, functional improvement, and low complication rates were achieved with

this technique. Nevertheless, we think that this technique requires a long learning curve and should be learned through both theoretical and practical courses. A well - designed prospective randomized controlled study with long - term results of a large study population is needed to support general use of this minimally invasive technique.

Figure 5 and 6 represent examples of some cases in our series.

IntechOpen

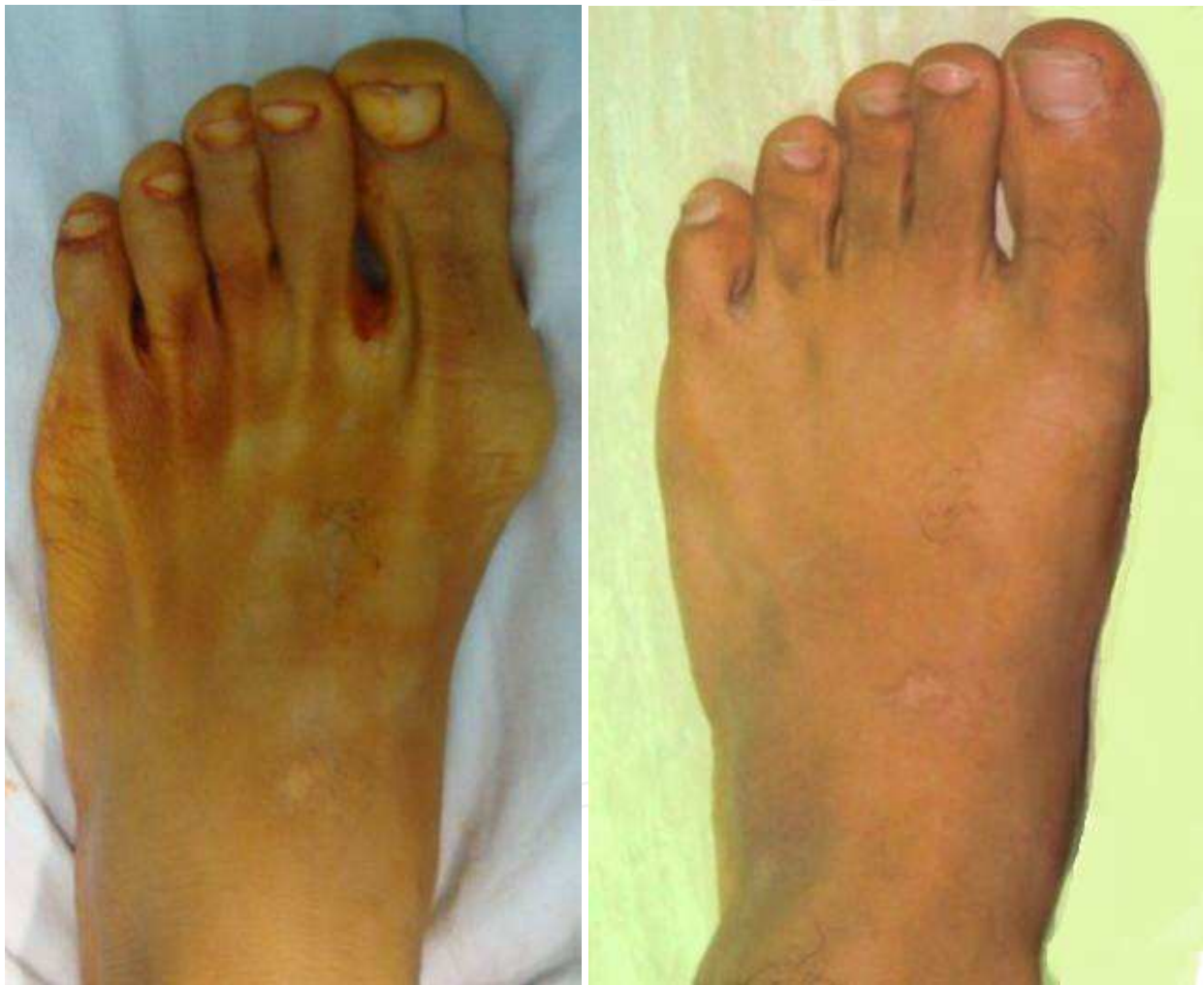

Fig. 5. A & B. Clinical preoperative and six months postoperative photos in 18 y. male patient with moderate hallux valgus deformity.

IntechOpen

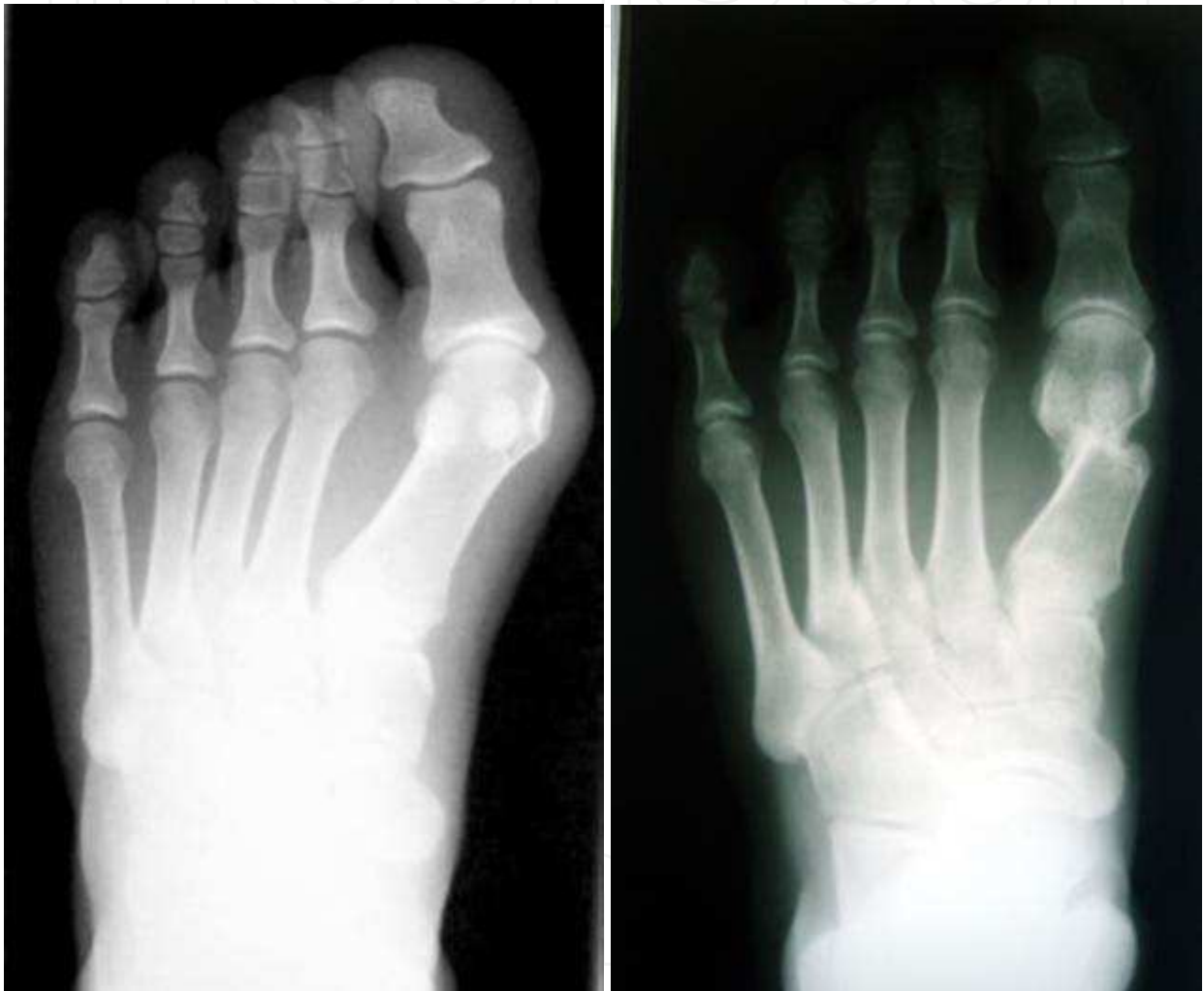

Fig. 5. C & D. Radiological preoperative and 6 months postoperative photos of the same patient

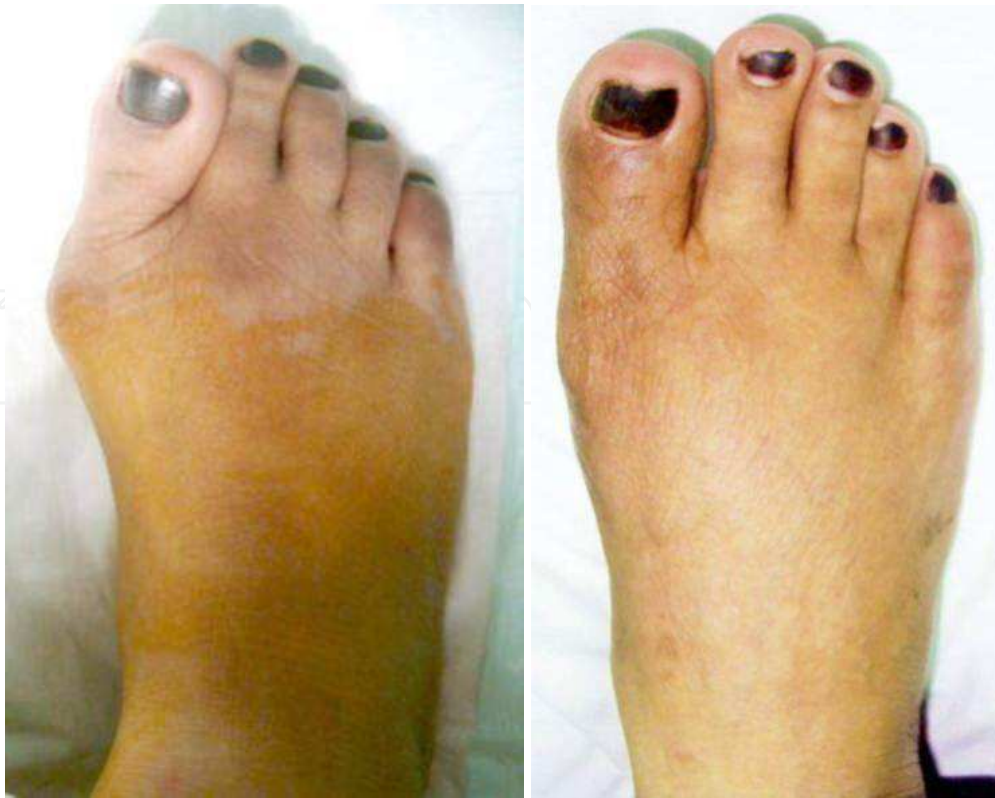

Fig. 6. A & B. Clinical preoperative and 18 months postoperative photos in 45 y. female with moderate hallux valgus.

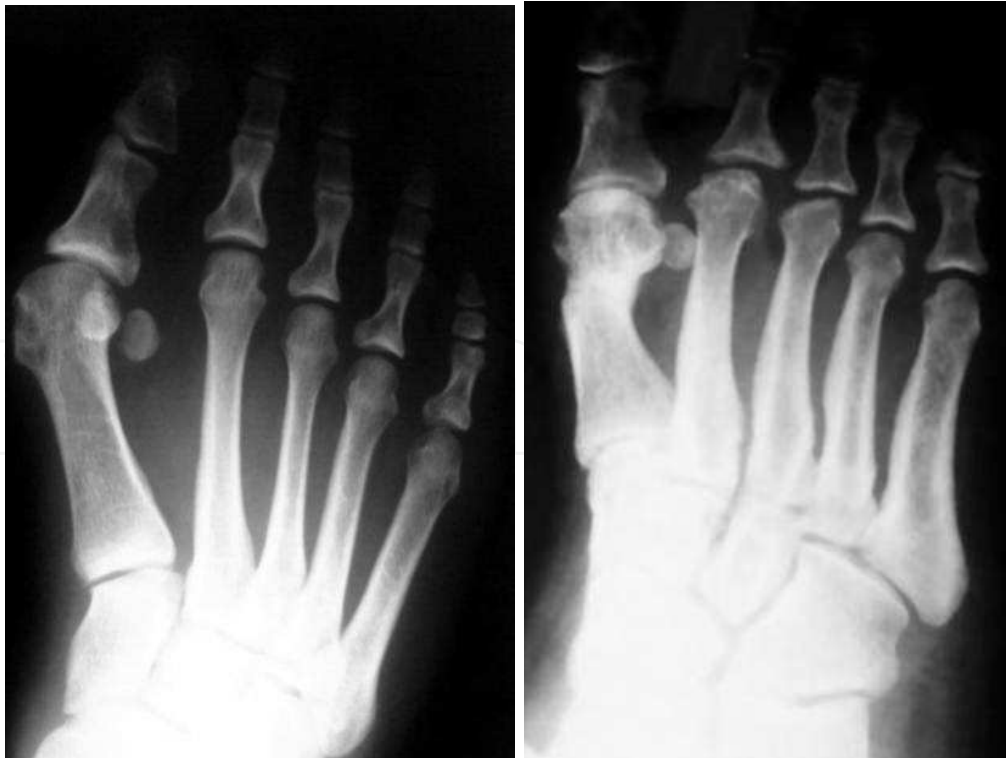

Fig. 6. C & D. Radiological preoperative and 18 months postoperative photos of the same patient

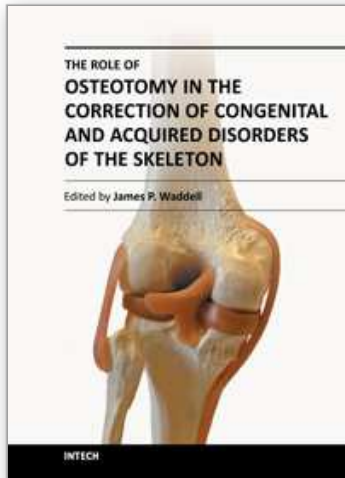
14. References

- [1] Mann RA, Coughlin MJ. Hallux valgus – etiology, anatomy, treatment and surgical considerations. *Clin Orthop Relat Res.* 1981 ; 157 : 31- 41
- [2] Coughlin MJ, Thompson FM. The high price of high - fashion footwear. In *Instructional Course Lectures, Rosemont, Illinois, the American Academy of Orthopaedic Surgeons.* 1995 ; Vol. 44, pp. 371-377.
- [3] Kato T, Watanabe S. The etiology of hallux valgus in Japan. *Clin. Orthop.* 1981 ; 157 : 78-81.
- [4] Inman VT. Hallux valgus : a review of etiologic factors. *Orthop. C/in. North America.* 1974 ; 5 : 59- 66.
- [5] Hohmann G. The hallux valgus and the remaining Toes straightness. *Results. Chir. Orthop.* 1925 ; 18 : 308-376.
- [6] Mann RA, Coughlin MJ. Hallux valgus – etiology, anatomy, treatment and surgical considerations. *Clin Orthop Relat Res.* 1981 ; 157 : 31- 41
- [7] Coughlin MJ. Juvenile hallux valgus : etiology and treatment. *Foot Ankle Int.* 1995 ; 16 : 682- 697.
- [8] Kilmartin TE, Wallace WA. The significance of pes planus in juvenile Hallux valgus. *Foot and Ankle.* 1992 ; 13 : 53- 56.
- [9] Hardy RH, Clapham JC. Observations on hallux valgus ; based on a controlled series. *J Bone Joint Surg Br.* 1951 ; 33 : 376- 391.
- [10] Mann RA, Coughlin MJ. Hallux valgus in adults. In : Coughlin MJ, Mann RA, editors. *Surgery of the foot and ankle.* 7th ed. St Louis: Mosby. 1999 ; p 147- 264
- [11] Robinson AHN, Limbers JP. Modern concepts in the treatment of hallux valgus. *J Bone Joint Surg [Br].* 2005 ; 87-B : 1038–1045.
- [12] Gottschalle FAB, Sallis JG, Beighton PH. A comparison of prevalence of hallux valgus in three South African populations. *S Afr Med Jr.* 1980 ; 57 : 355-357
- [13] Shine I. Incidence of hallux valgus in a partially shoe - wearing Chinese population. *BMJ.* 1965 ; 1 : 1648-1650.
- [14] Chang JT. Distal metaphyseal osteotomies in hallux abducto valgus surgery. In: Banks AS, Downey MS, Martin DE, et al. (eds.), *McGlamry's comprehensive textbook of foot and ankle surgery.* Philadelphia: Lippincott, 2001:505–27
- [15] Revenrdin J. De la deviation en dehors du gros orteil (hallux valgus. Vulg. "oignon" "bunions" "ballen") et de son traitement chirurgical. *Trans Int Med Congr* 1881;2:406–12
- [16] Hohmann G. Symptomatische oder Physiologische Behandlung des Hallux Valgus? *Munch Med Wochenschr* 1921;33:1042–5
- [17] Mitchell CL, Fleming JL, Allen R, et al. Osteotomy bunionectionomy for hallux valgus. *J Bone Joint Surg Am* 1958;40:41–60
- [18] Wilson JN. Oblique displacement osteotomy for hallux valgus. *J Bone Joint Surg Br* 1963;45:552–6
- [19] Austin DW, Leventen EO. A new osteotomy for hallux valgus: a horizontally directed "V" displacement osteotomy of the metatarsal head for hallux valgus and primus varus. *Clin Orthop Relat Res* 1981 Jun;157:25–30
- [20] Youngswick FD. Modifications of the Austin bunionectionomy for treatment of metatarsus primus elevatus associated with hallux limitus. *J Foot Surg* 1982;21:114–6

- [21] Magerl F. Stabile osteotomien zur Behandlung des Hallux valgus und Metatarsale varum. *Orthopade* 1982;11:170-80
- [22] Kalish SR, Spector JE. The Kalish osteotomy: a review and retrospective analysis of 265 cases. *J Am Podiatr Med Assoc* 1994;84: 237-49
- [23] Lair PO, Sirvers SH, Somdhal J. Two Reverdin-Laird osteotomy modifications for correction of hallux abducto valgus. *J Am Podiatr Med Assoc* 1988;78:403-5
- [24] Elleby DH, Barry LD, Helfman DN. The long plantar wing distal metaphyseal osteotomy. *J Am Podiatr Med Assoc* 1992;82:501-6
- [25] Van Enoo RE, Cane EM. Minimal incision surgery: a plastic technique or a cover-up? *Clin Podiatr Med Surg.* 1986;3:321-335.
- [26] Lui TH, Ng S, Chan KB. Endoscopic distal soft tissue procedure in hallux valgus surgery. *Arthroscopy.* 2005;21:1403.e1-1403.e7.
- [27] Lui TH, Chan KB, Chow HT et al. Arthroscopy-assisted correction of hallux valgus deformity. *Arthroscopy.* 2008 Aug;24:875-880.
- [28] De Lavigne C, Guillo S, Laffenêtre O, De Prado M. The treatment of hallux valgus with the mini-invasive technique. *Interact Surg.* 2007;2:31-37.
- [29] Bösch P, Markowski H, Rannicher V. Technik und erste Ergebnisse der subkutanen distalen Metatarsale-I-Osteotomie. *Orthop Praxis.* 1990;26:51-56.
- [30] Bösch P, Wanke S, Legenstein R. Hallux valgus correction by the method of Bösch: a new technique with a seven-to-ten year follow-up. *Foot Ankle Clin.* 2000;5:485-498.
- [31] Isham SA. The Reverdin-Isham procedure for the correction of hallux abducto valgus. A distal metatarsal osteotomy procedure. *Clin Podiatr Med Surg.* 1991;8:81-94.
- [32] Leemrijse T, Valtin B, Besse JL. Hallux valgus surgery in 2005. Conventional, mini-invasive or percutaneous surgery? Uni- or bilateral? Hospitalisation or one-day surgery? *Rev Chir Orthop Reparatrice Appar Mot.* 2008;94:111-127.
- [33] Weitzel S, Trnka H-J, Petroutsas J. Transverse medial slide osteotomy for bunionette deformity: long-term results. *Foot Ankle Int.* 2007;28:794-798.
- [34] Roukis TS, Schade VL. Minimum-incision metatarsal osteotomies. *Clin Podiatr Med Surg.* 2008;25:587-607.
- [35] Magnan B, Samaila E, Viola G, Bortolazzi P. Minimally invasive retrocapital osteotomy of the first metatarsal in hallux valgus deformity. *Oper Orthop Traumatol.* 2008;20:89-96.
- [36] Giannini S, Vannini F, Faldini C et al. The minimally invasive hallux valgus correction (S.E.R.I.) *Interact Surg.* 2007;2:17-23.
- [37] Piggott H. The natural history of hallux valgus in adolescence and early adult life. *J. Bone and Joint Surg.* 1960 ; 42-B (4) : 749-760.
- [38] Coughlin MJ, Saltzman CL, Nunley II JA. Angular measurements in the evaluation of hallux valgus deformities : a report of the Ad Hoc Committee of the American Orthopaedic Foot & Ankle Society on angular measurements. *Foot Ankle Int.* 2002 ; 23 : 68-74.
- [39] Morton DJ. *The human foot.* New York : Columbia University Press; 1935
- [40] Kitaoka HB, Alexander IJ, Adelaar RS et al. Clinical rating systems for the ankle - hindfoot, midfoot, hallux, and lesser toes. *Foot Ankle Int.* 1994 ; 15 : 349-353.
- [41] Okuda R, Kinoshita M, Morikawa J, Yasuda T, Abe M. Proximal metatarsal osteotomy : relation between 1- to greater than 3-years results. *Clin Orthop Relat Res.* 2005 ; 435 :191-196.

- [42] Portaluri M. Hallux valgus correction by the method of Bösch : a clinical evaluation. *Foot Ankle Clin.* 2000 ; 5 : 499-511.
- [43] Sanna P, Ruiu GA. Percutaneous distal osteotomy of the first metatarsal (PDO) for the surgical treatment of hallux valgus. *Chir Organi Mov.* 2005 ; 90 : 365-369.
- [44] Magnan B, Pezze L, Rossi N, Bartolozzi P. Percutaneous distal metatarsal osteotomy for correction of hallux valgus. *J Bone Joint Surg Am.* 2005 ; 87 : 1191-1199
- [45] Schneider W, Knahr K. Keller procedure and chevron osteotomy in hallux valgus : five - year results of different surgical philosophies in comparable collectives. *Foot Ankle Int.* 2002 ; 23 : 321-329.
- [46] Torkki M, Malmivaara A, Seitsalo S et al. Surgery vs orthosis vs watchful waiting for hallux valgus : a randomized controlled trial. *JAMA* 2001 ; 285 : 2474-2480.
- [47] Desjardins AL, Hajj C, Racine L, Fallaha M, Bornais S. Mitchell osteotomy for treatment of hallux valgus. *Ann Chir.* 1993 ; 47 : 894-899.
- [48] Johnson JE, Clanton TO, Baxter DE, Gottlieb MS. Comparison of chevron osteotomy and modified McBride bunionectomy for correction of mild to moderate hallux valgus deformity. *Foot Ankle.* 1991 ; 12 : 61-68.
- [49] Lin YC, Cheng YM, Chang JK, Chen CH, Huang PJ. Minimally invasive distal metatarsal osteotomy for mild -to- moderate hallux valgus deformity. *Kaohsiung J Med Sci.* August 2009 ; Vol 25 : No 8.431-437.
- [50] Caminear DS, Pavlovich JR, Pietrzak WS. Fixation of the chevron osteotomy with an absorbable copolymer pin for treatment of hallux valgus deformity. *J Foot Ankle Surg.* 2005 ; 44 :203-210.
- [51] Schneider W, Knahr K. Keller procedure and chevron osteotomy in hallux valgus : five - year results of different surgical philosophies in comparable collectives. *Foot Ankle Int.* 2002 ; 23 : 321-329.
- [52] Kuo CH, Huang PJ, Cheng YM et al. Modified Mitchell osteotomy for hallux valgus. *Foot Ankle Int.* 1998 ; 19 : 585-589.
- [53] Oh IS, Kim MK, Lee SH. New modified technique of osteotomy for hallux valgus. *J Orthop Surg (Hong Kong)* 2004 ; 12 : 235- 238
- [54] Klosok JK, Pring DJ, Jessop JH, Maffulli N. Chevron or Wilson metatarsal osteotomy for hallux valgus. A prospective randomized trial. *J Bone Joint Surg Br.* 1993 ; 75 : 825-829.

IntechOpen



The Role of Osteotomy in the Correction of Congenital and Acquired Disorders of the Skeleton

Edited by Prof. James Waddell

ISBN 978-953-51-0495-7

Hard cover, 294 pages

Publisher InTech

Published online 11, April, 2012

Published in print edition April, 2012

This book demonstrates specific osteotomy techniques from the skull to the hallux. The role of osteotomy in the correction of deformity is under appreciated in part because of the ubiquitous nature of joint replacement surgery. It should be remembered, however, that osteotomy has a role to play in the correction of deformity in the growing child, the active young adult, and patients of any age with post-traumatic deformity limiting function and enjoyment of life. In this text we bring you a number of papers defining specific problems for which osteotomy is found to be an effective and lasting solution. I hope you find it useful.

How to reference

In order to correctly reference this scholarly work, feel free to copy and paste the following:

Ahmed Enan (2012). Minimally Invasive Distal Metatarsal Osteotomy for Mild-to-Moderate Hallux Valgus, The Role of Osteotomy in the Correction of Congenital and Acquired Disorders of the Skeleton, Prof. James Waddell (Ed.), ISBN: 978-953-51-0495-7, InTech, Available from: <http://www.intechopen.com/books/the-role-of-osteotomy-in-the-correction-of-congenital-and-acquired-disorders-of-the-skeleton/minimally-invasive-distal-metatarsal-osteotomy-for-mild-to-moderate-hallux-valgus>

INTECH
open science | open minds

InTech Europe

University Campus STeP Ri
Slavka Krautzeka 83/A
51000 Rijeka, Croatia
Phone: +385 (51) 770 447
Fax: +385 (51) 686 166
www.intechopen.com

InTech China

Unit 405, Office Block, Hotel Equatorial Shanghai
No.65, Yan An Road (West), Shanghai, 200040, China
中国上海市延安西路65号上海国际贵都大饭店办公楼405单元
Phone: +86-21-62489820
Fax: +86-21-62489821

© 2012 The Author(s). Licensee IntechOpen. This is an open access article distributed under the terms of the [Creative Commons Attribution 3.0 License](#), which permits unrestricted use, distribution, and reproduction in any medium, provided the original work is properly cited.

IntechOpen

IntechOpen