

# We are IntechOpen, the world's leading publisher of Open Access books Built by scientists, for scientists

4,800

Open access books available

122,000

International authors and editors

135M

Downloads

Our authors are among the

154

Countries delivered to

TOP 1%

most cited scientists

12.2%

Contributors from top 500 universities



WEB OF SCIENCE™

Selection of our books indexed in the Book Citation Index  
in Web of Science™ Core Collection (BKCI)

Interested in publishing with us?  
Contact [book.department@intechopen.com](mailto:book.department@intechopen.com)

Numbers displayed above are based on latest data collected.

For more information visit [www.intechopen.com](http://www.intechopen.com)



# Opening Wedge High Tibial Osteotomy

Cristiano Hossri Ribeiro, Nilson Roberto Severino  
and Ricardo de Paula Leite Cury

*Knee Surgery Division, Department of Orthopedics and Traumatology,  
Faculdade de Ciências Médicas da Santa Casa de São Paulo,  
Brazil*

## 1. Introduction

Tibial osteotomy is a procedure that is used to correct misalignment of the lower limb. It aims to improve the pain and/or knee functions, through the correction of varus deformity. The technique has been used for many years, and is now consecrated in medical circles.

In the literature, we find descriptions of the technique dating back to the 50s, with Jackson (Jackson, 1958). However, it was not until the 70s, with the publications of Coventry (Coventry, 1969 and 1973) and Insall (Insall, 1975), that proximal tibial osteotomy became common practice. At that time, closing wedge osteotomies were performed, despite the greater technical difficulty and risks involved, as there were no fixation materials available that could enable opening wedge osteotomy. Only after the development of medial wedge plate fixation that opening wedge osteotomy became applicable (Puddu, 2004).

Proximal tibial osteotomy has been increasingly used, because it is no longer indicated exclusively for the treatment of medial arthrosis resulting from primary varus. This technique is currently indicated for patients with other varus deformities, independent of the presence of arthrosis, such as lesions of the cartilage, meniscus, and ligaments (double and triple varus).

Patients with varus deformity generally have asymmetrical wear of the knee joint. This is due to the concentration of axial force in the medial compartment, which causes greater impact on the subchondral bone of this compartment, intravenous hypertension, and microfractures of the subchondral bone. Over time, this overload results in the deformity and pain that characterize arthrosis (Lobenhoffer et al., 2003).

## 2. Indications

### 2.1 Primary varus

The classical indication of valgizing osteotomy of the tibia is osteoarthritis of the medial compartment of the knee, associated with varus deformity (Murphy, 1994) (primary varus). In this situation, patients complain of pain in the medial compartment, and varus deformity is observed in the clinical examination. In recent years, osteotomy has no longer been an indication that is restricted to cases of primary varus. Patients with joint injuries affecting

the medial compartment, with lesions of the medial meniscus and osteochondral injury associated with genu varum (bow-leggedness) require correction of the leg misalignment, in order to treat the injuries. Another common indication is cases of ligament instability associated with genu varus.

## 2.2 Double varus

Double varus consists of the presence of varus bone deformity accompanied by injury of the central ligament and/or lateral collateral injury, which presents lateral pivot shift of the lateral condyle. Clinically, an opening of the lateral compartment when stress is placed on it is observed in joint varus (Noyes et al., 2000).

## 2.3 Triple varus

Triple varus is characterized by the association of varus deformity with central ligament insufficiency (anterior and posterior cruciate ligaments, ACL and PCL), and failure of the posterolateral corner (Noyes et al., 2000). In this situation, there is an increase in external rotation of the limb during walking, with the presence of recurvatum.

In cases of double and triple varus, opening wedge tibial osteotomy should be carried out simultaneously to the ligament treatment, or in an initial operation (Franco et al., 2002). Correction in a single operation is long and tiring, involving greater risks for the patient. It is preferable to correct the bone in the first operation, as in some cases, an adaptive retensioning of the lateral structures is observed. It should be emphasized that it is common for patients submitted to ligament reconstruction to develop instability due to the failure to correct the mechanical axis (Noyes et al., 2000).

## 3. Contraindications

Osteotomy is contraindicated in patients with signs of tricompartmental arthrosis, injury in the lateral compartment (meniscus and/or osteochondral injury), deformities greater than 20 degrees, extension deficit, or a range of movement of less than 90 degrees. The following are considered relative contraindications: obesity, smoking and patellofemoral pain. Generally, upper tibial osteotomy provides beneficial results, when carried out at the start of evolution of the process of arthrosis in younger individuals. Thus, the procedure is contraindicated in individuals aged over 60 years with a low level of physical activity. These patients would benefit more from arthroplasty (Hernigou et al., 1987).

## 4. Surgical technique

The most common techniques used in tibial osteotomy are: opening wedge, closing wedge, cupuliform and biplanar. This chapter addresses opening wedge osteotomy, as it is the most commonly used and the most widely-cited technique in the recent literature, according to the results of a search on the Pubmed database using the terms "osteotomy", and "genu varus".

Closing wedge tibial valgization osteotomy was frequently used in the 1970s and 1980s, but lost space with the popularization of open wedge osteotomy (Esenkaya and Elmali, 2006,

Benzakour et al, 2010). The procedure consists of making a subtractive wedge in the lateral and proximal region of the tibia (metaphysiary region), which provides correction of major deformities, without requiring a bone graft. However, besides the higher risk of neurovascular lesion due to the lateral access route, it also has the disadvantage that it requires osteotomy of the fibula (Magyar et al., 1999, Gaasbeek et al, 2010).

Opening wedge high tibial osteotomy (HTO) has become popular in recent years because it enables a medial approach, which minimizes the risks of neurovascular lesion and the need for dissection of the soft tissues. It enables the wedge to be opened and closed during the procedure, giving a better end result. Another advantage of this technique is that it enables earlier mobility and immediate weight-bearing, depending on the implant used (Esenkaya and Elmali, 2006).

The main disadvantages of opening wedge are: increased height of the patella, the need to introduce a bone graft, which adds risks of pseudoarthrosis, and delayed consolidation (Puddu, 2000).

#### 4.1 Preoperative planning

The preoperative planning consists of radiographic evaluation of the knee in the anterior-posterior profile and axial views of the patella, lateral view of the knee and panoramic view with full weight-bearing.

In the radiographs, we observe the degree of arthrosis (Ahlbäck, 1968) of the medial compartment, the height and signs of arthrosis of the patella, and the integrity of the lateral compartment, in cases of primary varus (Fig. 1). In patients who present double and triple varus, panoramic radiography can show a larger opening in the lateral compartment, compared with the normal side, due to ligament insufficiency of the lateral structures of the knee.

#### 4.2 Determination of the mechanical axis

Panoramic radiography with full weight-bearing is essential, as it determines the **mechanical axis** of the limb and enables the opening wedge to be calculated. The mechanical axis is measured by drawing a line from the center of the femoral head to the center of the knee, and from this point to the center of the ankle. The intersection of the lines on the knee gives the degree of varism (Dugdale et al., 1992).

Nuclear magnetic resonance imaging is an important complementary exam that should be requested, as it provides important and detailed information on the degree of impairment of the patellofemoral joint cartilage of the medial and lateral compartment. As stated above, the presence of lesion of the cartilage in the lateral compartment or lateral meniscal lesion contraindicates osteotomy for correction of primary varus. Furthermore, in cases of double and triple varus, magnetic resonance imaging helps in the diagnosis of peripheral and central ligament lesions, contributing to the surgical planning (Murphy, 1994).

#### 4.3 Calculation of the opening wedge

The opening wedge is calculated using the method of Dugdale, with the objective of transferring the axis of weight-bearing to 62% of the surface of the tibia laterally, in cases of

primary varus. This correction enables a final angle of 3 to 6 degrees of valgus from the mechanical axis to be obtained (Dugdale et al., 1992). This calculation is done using panoramic radiography with full weight-bearing.

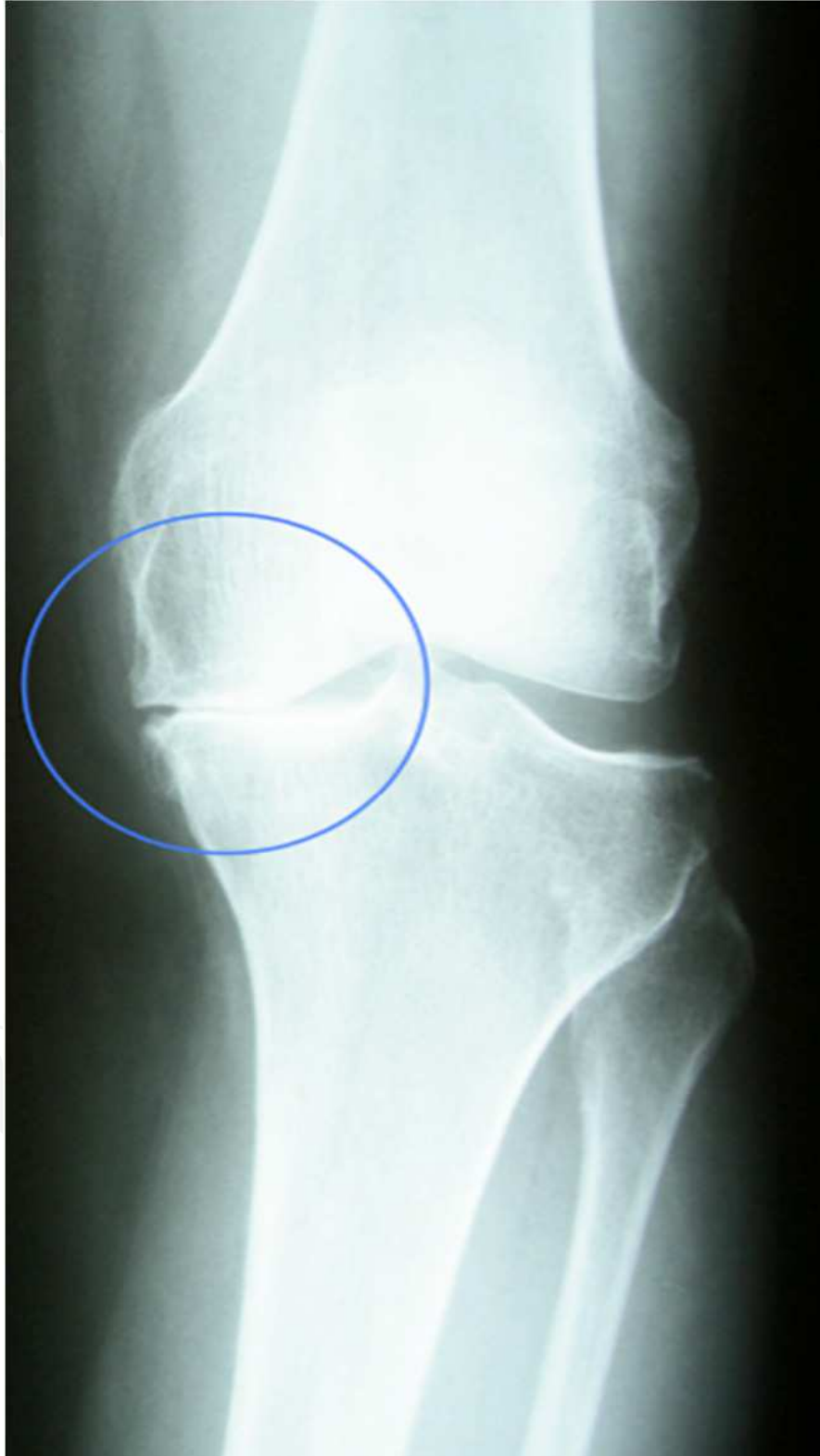

Fig. 1. Radiography of the knee with medial osteoarthritis and varus deformity

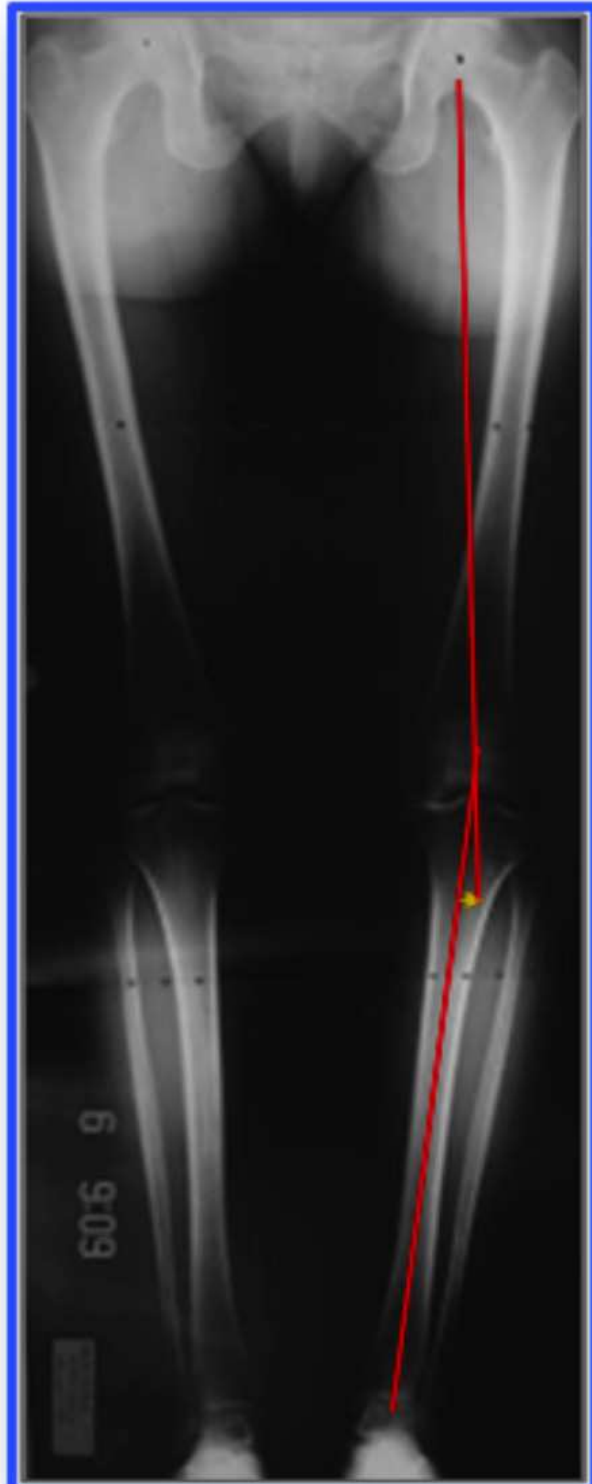


Fig. 2. Panoramic radiography with full weight-bearing on the lower limbs with measuring of the mechanical axis

The **angle of correction** is obtained from the intersection between a line drawn from the center of the femoral head to the point previously found on the surface of the knee for transfer of the axis of weight-bearing (62%) and another line from this point to the center of the ankle (Fig.3) (Dugdale et al., 1992).



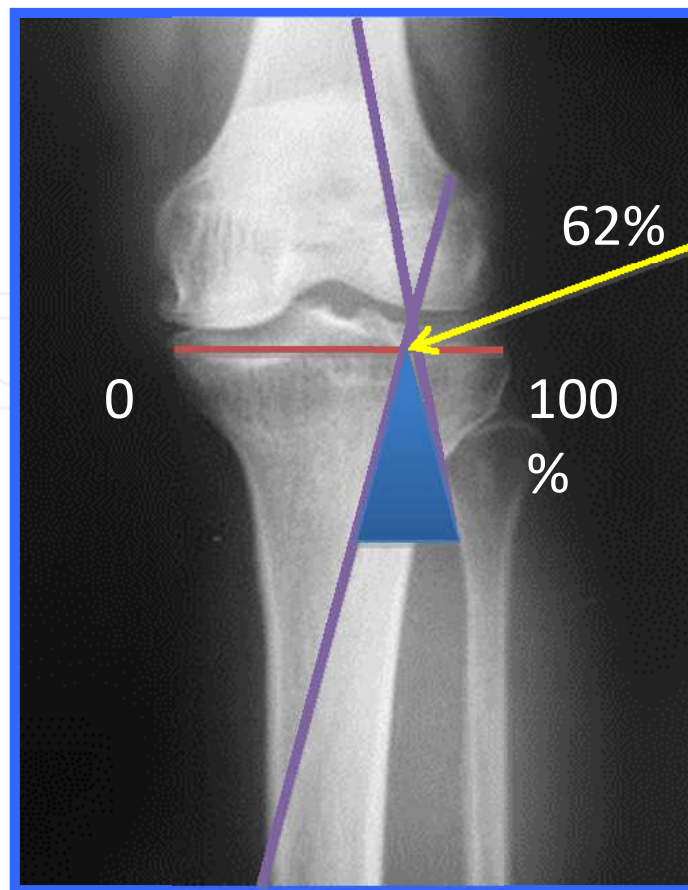


Fig. 3. Measuring the opening wedge

It is important to clarify that the degree of correction influences the final result of the surgery (Hernigou et al., 1987). Hypocorrection gives unsatisfactory clinical results (Insall et al., 1984; Amendola, 2003), as does hypercorrection, which can compromise the lateral compartment more than desired.

In patients with double and triple varus, the aim of calculating the opening wedge is to transfer the axis of weight-bearing to the center of the knee, i.e. to achieve a final mechanical angle of 0 degrees (Noyes et al., 2000). This is done in the same way as in cases of primary varus, but the line from the center of the ankle and from the head of the femur cross in the center of the knee, forming the angle of correction.

#### 4.4 Description of the surgical technique

The surgical procedure is done with the patient in dorsal decubitus, under rachianesthesia. Before osteotomy, arthroscopy of the knee should be performed to treat the joint lesions: meniscus, cartilage and removal of loose bodies.

Opening wedge osteotomy is done with the aid of radioscopy. First, a longitudinal incision is made in the proximal and medial third of the tibia. This is followed by dissection of the pes anserinus (goose's foot) and superficial medial collateral ligament. Two parallel Kirshner wires are passed from medial to lateral in the direction of the head of the fibula, taking care to pass over the anterior tuberosity of the tibia. After confirming that the wires

are in the correct position, the bone is cut, leaving the lateral cortical intact. The wedge opening calculated in the preoperative planning is then performed. The alignment obtained can be checked during the surgery, with the navigation system (Song et al., 2007) or by means of a metallic guide that enables the axis of weight bearing of the knee to be verified, through radioscopy.

For fixation of the osteotomy, there is great variety of plates available that provide stabilization. These differ in terms of design, use of wedge and angular blocking system.

Bone graft is indicated in opening wedges larger than 7.5 degrees (Puđu, 2000), to give added stability and consolidation potential. The graft may be homologous or artificial. The advantages of artificial graft are the shorter surgery time and lower risk for the patient. But we observe, in the radiographic evolution, a longer integration time of this graft compared with homologous graft, which does not influence the time to liberation of weight-bearing for the patient (data not published, submitted to publication).

After the procedure, the patients are not immobilized, and are encourage to become mobile earlier. Partial weight-bearing is allowed at six weeks with full weight-bearing at 10 weeks, on average, accompanied by radiographic consolidation.

## 5. Complications

Various complications of osteotomy have been cited in the literature (Esenkaya & Elmali, 2006; Paccola & Fogagnolo, 2005), such as: fracture of the lateral cortical, intra-articular fracture, hypo or hypercorrection, alteration in tibial slope, infection, pseudoarthrosis, deep vein thrombosis and infection.

### 5.1 Lateral cortical fracture

Lateral cortical fracture is a severe complication that can occur during the surgical act, decreasing axial resistance (47%) and rotational resistance (54%) of the osteotomy (Puđu, 2000). It occurs when the lateral tibial cortex is perforated or cut by the chisel. We also observed this complication when we opened the osteotomy wedge with the anterior and posterior cortexes intact. It is diagnosed during surgery through the observation of subluxation of the osteotomy. When this complication occurs, it is necessary to add a lateral fixation (screw or hook) at the apex of the opening wedge, to increase the stability of the osteotomy (Paccola & Fogagnolo, 2005) (Fig. 4).

### 5.2 Intra-articular fracture

Intra-articular fracture is a rare complication arising from an incorrectly positioned osteotomy cut. Excessive slope in the articular direction, or a cut in which a very thin proximal fragment is left increase the risk of this type of complication (Fig. 5).

To avoid this, it is necessary to pass the guide wires distally on the medial surface of the tibia, 4 cm from the joint surface, positioned towards the head of the fibula, with observation by fluoroscopy. In the case of fracture with deviation, it must be reduced and fixed with screws.



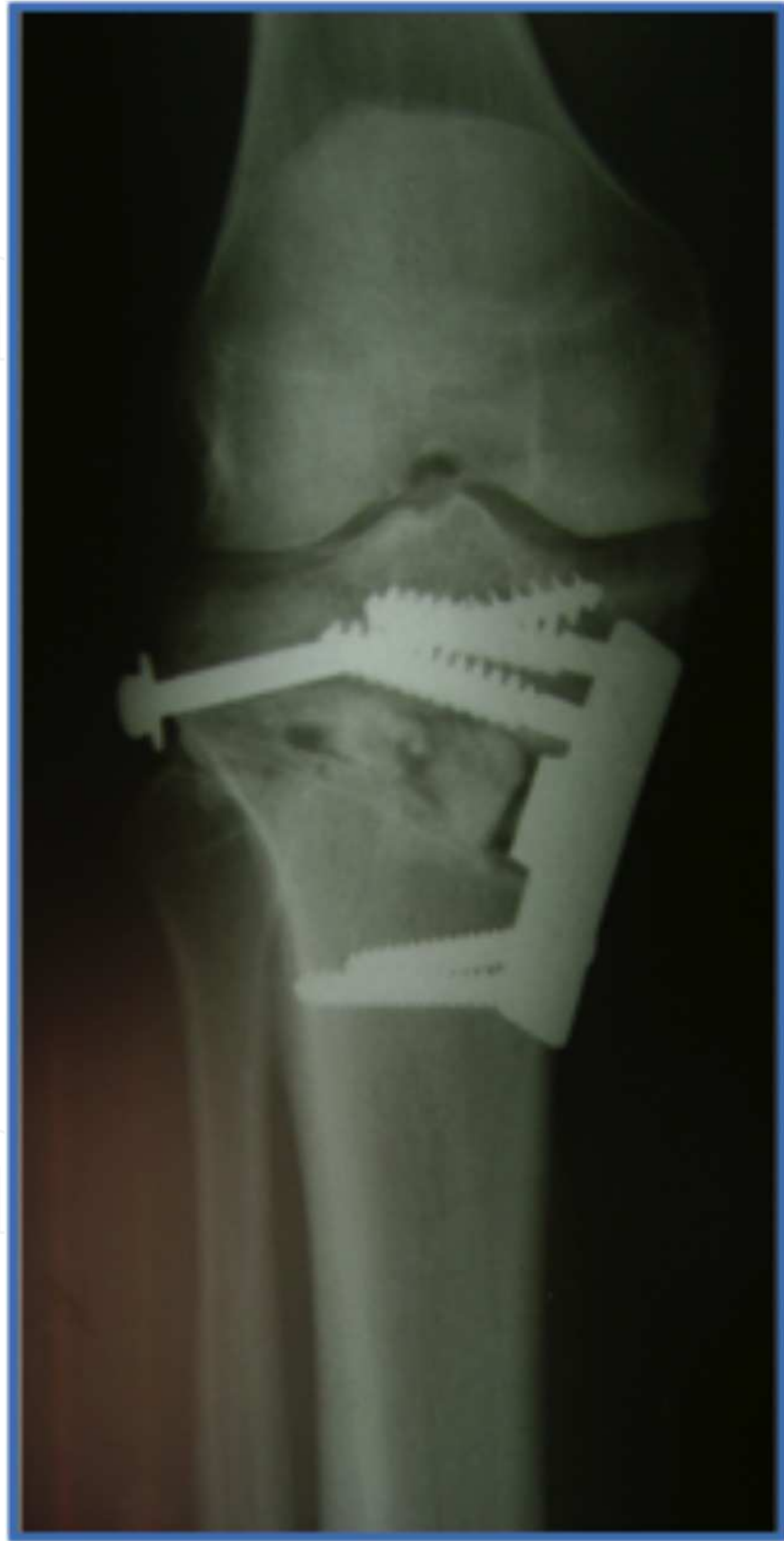

Fig. 4. Screw fixation in fracture of the lateral cortex

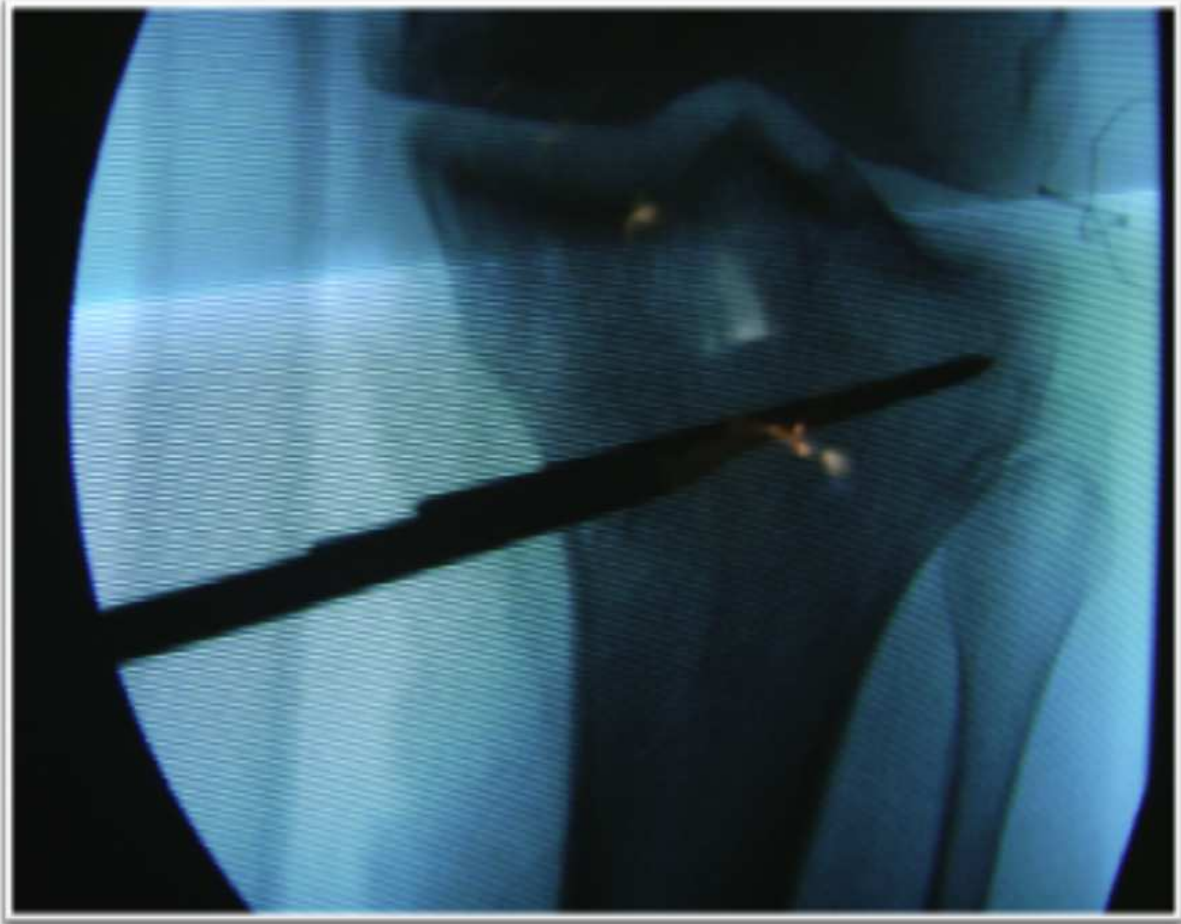

Fig. 5. Correct position of the tibial osteotomy

### 5.3 Hypo- and hypercorrection

Hypo- and hypercorrection in opening wedge valgizing tibial osteotomy are undesirable complications observed in most cases, following surgery (Rinonapoli et al., 1998). This gives an unsatisfactory result, as the level of final correction is directly linked to the end result of the osteotomy (Rinonapoli et al., 1998, Benzakour et al, 2010). Various techniques are used before and during surgery to increase the likelihood of achieving precisely the desired correction. Preoperative planning with radiographies, as described earlier in this chapter, is of great value, and should always be used. During surgery, clinical observation of alignment is used, as well as the technique of guide wire which, positioned by the surgeon on the anatomical points of the lower limb, indicates the site of the weight-bearing axis in the knee, under observation of radioscopy. Recently, we used the navigation system as the main instrument for controlling the degree of correction of the osteotomy (Song et al., 2007). Navigation in the osteotomy adds greater accuracy and precision, despite the longer surgery time (Gebhard et al., 2011).

### 5.4 Slope

The tibial slope is, on average 10 degrees of posterior inclination Clarke et al., (2001). Opening wedge tibial osteotomy enables this slope to be altered. In the vast majority of

cases, we see an undesirable increase in tibial slope, which causes a loss of knee extension, and also an overload in the anterior cruciate ligament (Song et al., 2007). Patients who present insufficiency of this ligament evolve with worsening instability (Song et al., 2007). The best way to control the tibial slope is through observation of the osteotomy wedge opening. This should present an anterior opening of two thirds of the size of the posterior (Song et al., 2007), forming a trapezoidal opening wedge at the medial border of the tibia (Fig. 6). The navigation system is of great help in controlling the mechanical axis and also the tibial slope (Hart et al., 2007).

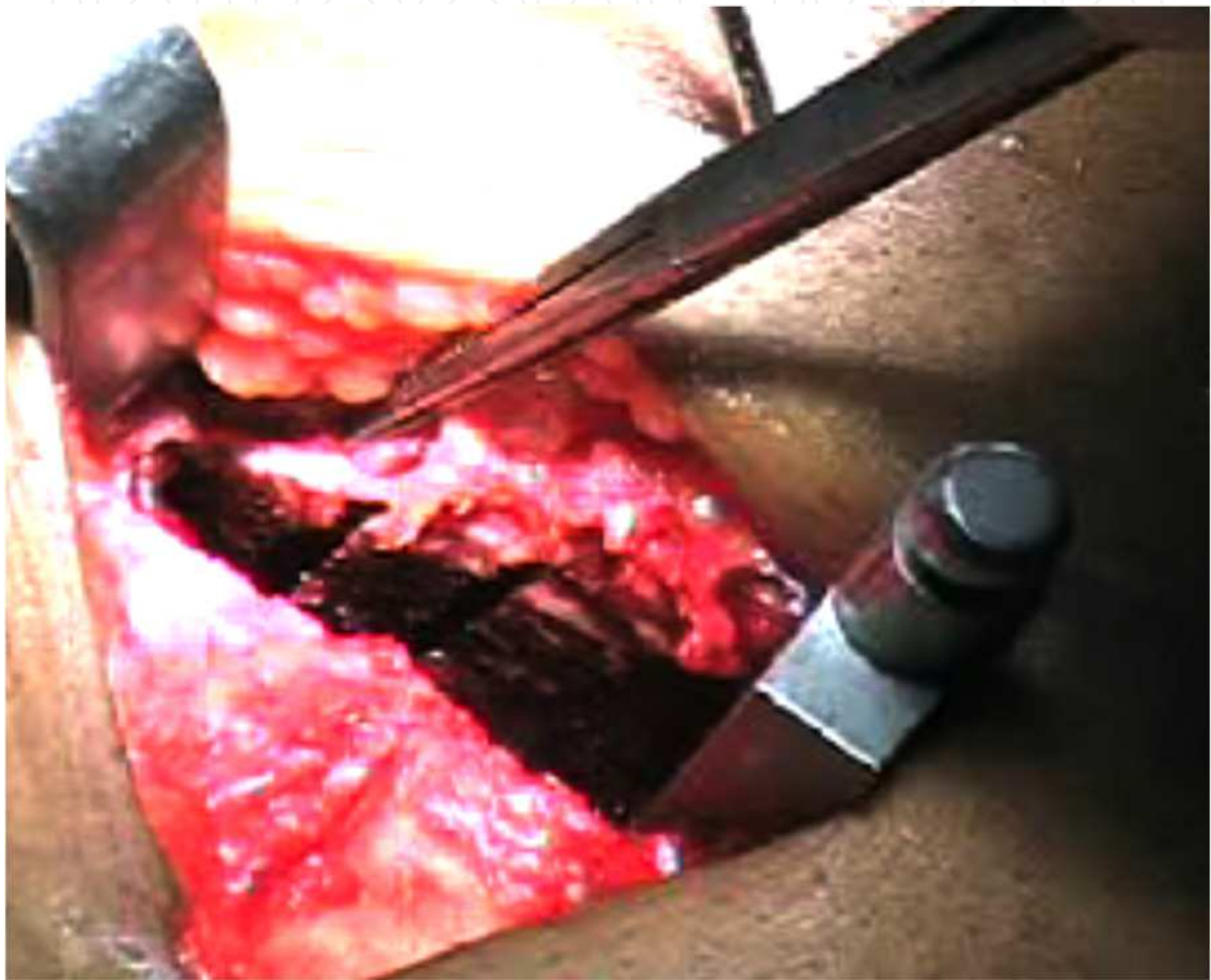


Fig. 6. Opening wedge in trapezoidal form

### 5.5 Pseudoarthrosis

Pseudoarthrosis is a rare complication that occurs in up to 5% of cases (Miller et al, 2009, Meidinger et al,2011, Valkering et al, 2009). It mainly occurs when no stability is added at the osteotomy site, or in the absence of bone graft in the opening wedge (Noyes et al., 2000). It recognizes the introduction of bone graft in openings greater than 7.5 mm (Puddu, 2004).

Deep vein thrombosis and infection are inherent complications to any surgical procedure. Prophylactic care should be followed, according to the clinical criteria of each patient.

Few complications of HTO are described in the literature (Jackson and Waugh, 1974, Rinonapoli et al., 1998; Song et al., 2007; Gebhard et al., 2011, Hart et al., 2007, Ribeiro et al., 2009, Miller et al., 2009, Meidinger et al, 2011, Gaasbeek et al, 2010). However, due to the continuous development of the technique and of new synthesis materials, new studies should be undertaken in order to evaluate the complication rates according to each modality of HTO.

## 6. Recent advances

In recent years, we have seen an increase in the number of publications on the use of the computerized navigation system in osteotomy (Gebhard et al., 2011; Hart et al., 2007). Its purpose is to help obtain the ideal final mechanical axis. Navigation works through the implantation of positioning sensors in the thigh, knee and leg. It provides a very accurate measurement of the mechanical axis of the tibial slope during the surgical procedure. As mentioned earlier, the final mechanical axis obtained directly influences the result of the osteotomy. Simple clinical observation and/or the use of the scalpel handle in the radioscopy do not show great precision (Noyes et al., 2000). But the navigation system gives accuracy and precision to the osteotomy, despite the increased surgery times and the risk of fracture of the femur and tibia (Song et al., 2007; Gebhard et al., 2011; Hart et al., 2007).

## 7. Final considerations

The precise indication for HTO is essential to obtain good results. Clearly, the satisfactory result of the HTO is directly related to the final correction obtained, therefore it is important to carry out preoperative planning and intraoperative follow-up with the navigation or radioscopy. The technical precautions should be carefully observed, to avoid the surgical complications described here.

## 8. References

- Ahlbäck, S. (1968). Osteoarthritis of the knee. A radiographic investigation. *Acta Radiologica: Diagnosis (Stockh)*, Vol.Suppl 277, (January 1968), pp. 7-72, ISSN 0567-8056.
- Amendola, A. (2003) Unicompartmental osteoarthritis in the active patient: the role of high tibial osteotomy. *Arthroscopy*, Vol.19, No.Suppl 1, (December 2003), pp. 109-16, ISSN 0749-8063.
- Benzakour, T, Hefti, A, Lemseffer, M, El Ahmadi, JD, Bouyarmene, H & Benzakour A. (2010). High tibial osteotomy for medial osteoarthritis of the knee: 15 years follow-up. *International orthopaedics*, Vol.34, No.2, (January 2010), pp. 209-15, ISSN 0341-2695.
- Clarke, HD, Scott, WN, Insall, JN, Pedersen, HB, Math, KR, Vigorita, VJ & Cushner, FD. (2001). Anatomy. In: *Surgery of the Knee*. Insall, JN & Scott, N, Eds, pp. 13-76, ISBN 978-14-377-1503-3.



- Coventry, MB (1969). Stepped staple for upper tibial osteotomy. *The Journal of Bone and Joint Surgery. American volume*, Vol.51, No.5, (July 1969), pp. 1011, ISSN 0021-9355.
- Coventry, MB. (1973). Osteotomy about the knee for degenerative and rheumatoid arthritis. *The Journal of Bone and Joint Surgery. American volume*, Vol.55, No.1, (January 1973), pp. 23-48, ISSN 0021-9355.
- Dugdale, TW, Noyes, FR & Styer, D. (1992). Preoperative planning for high tibial osteotomy. The effect of lateral tibiofemoral separation and tibiofemoral length. *Clinical Orthopaedics and Related Research*, No.274, (January 1992), pp. 248-64, ISSN 0009-921X.
- Esenkaya, I & Elmali, N. (2006). Proximal tibia medial open-wedge osteotomy using plates with wedges: early results in 58 cases. *Knee Surgery, Sports Traumatology, Arthroscopy: Official Journal of the ESSKA*, Vol.14, No.10, (October 2006), pp. 955-61, ISSN 0942-2056.
- Franco, V, Cerullo, G, Cipolla, M, Gianni, E & Puddu, G. (2002). Open wedge high tibial osteotomy. *Techniques in Knee Surgery*, Vol.1, No.1, (September 2002), pp. 43-53, ISSN 1536-0636.
- Gaasbeek, RD, Nicolaas, L, Rijnberg, WJ, van Loon, CJ & van Kampen, A. (2010). Correction accuracy and collateral laxity in open versus closed wedge high tibial osteotomy. A one-year randomised controlled study. *International orthopaedics*, Vol.34, No.2, (August 2009), pp. 201-7, ISSN 0341-2695.
- Gebhard, F, Krettek, C, Hübner, T, Grützner, PA, Stöckle, U, Imhoff, AB, Lorenz, S, Ljungqvist, J, Keppler, P & AO CSEG. (2011). Reliability of computer-assisted surgery as an intraoperative ruler in navigated high tibial osteotomy. *Archives of Orthopaedic and Trauma Surgery*, Vol.131, No.3, (March 2011), pp. 297-302, ISSN 0936-8051.
- Hart, R, Stipčák, V, Kucera, B, Filan, P & deCordeiro, J. (2007). Präzise computergestützte Beinachsenkorrektur mit öffnender valgusierender Tibiakopfoosteotomie. [Precise, computed-assisted leg angle correction with open-wedge high tibial osteotomy]. *Der Orthopäde*, Vol.;36, No.6, (June 2007), pp. 577-81, ISSN 0085-4530.
- Hernigou, P, Medevielle, D, Debeyre, J & Goutallier, D. (1987). Proximal tibial osteotomy for osteoarthritis with varus deformity. A ten to thirteen-year follow-up study. *The Journal of Bone and Joint Surgery. American volume*, Vol.69, No.3, (March 1987), pp. 332-54, ISSN 0021-9355.
- Insall, JN, Joseph, DM & Msika, C. (1984). High tibial osteotomy for varus gonarthrosis. A long- term follow-up study. *The Journal of Bone and Joint Surgery. American volume*, Vol.66, No.7, (September 1984), pp. 1040-8, ISSN 0363-5465.
- Insall, JN. (1975). High tibial osteotomy in the treatment of osteoarthritis of the knee. *Surgery Annual*, Vol.7, pp. 347-59, ISSN 0081-9638.
- Jackson, JP & Waugh, W. (1974). The technique and complications of upper tibial osteotomy A review of 226 operations. *The Journal of Bone and Joint Surgery. British volume*, Vol.56, No.2, (May 1974), pp. 226-45, ISSN 0301-620X.
- Jackson, JP. (1958). Osteotomy for osteoarthritis of the knee. *Proceedings and Reports of Universities Colleges, Councils And Associations, United States of America*,

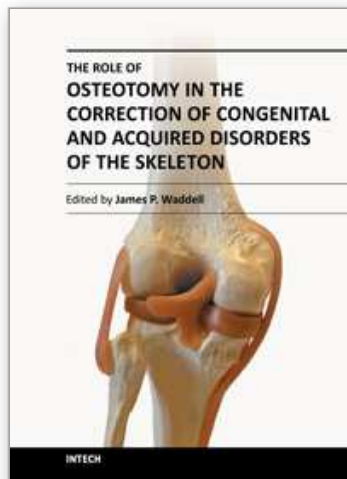
- March 1958. *The Journal of Bone and Joint Surgery. British volume*, Vol.40, No.4, November 1958), pp. 826, ISSN 0301-620X. Retrieved from: <URL: <http://web.jbjs.org.uk/cgi/reprint/40-B/4/817>>
- Lobenhoffer, P & Agneskirchner, JD. (2003). Improvements in surgical technique of valgus high tibial osteotomy. *Knee Surgery, Sports Traumatology, Arthroscopy: Official Journal of the ESSKA*, Vol.11, No.3, (May 2003), pp. 132-8, ISSN 1433-7347.
- Magyar, G, Ahl, TL, Vibe, P, Toksvig-Larsen, S & Lindstrand, A. (1999). Open-wedge osteotomy by hemicallotaxis or the closed-wedge technique for osteoarthritis of the knee. A randomised study of 50 operations. *The Journal of Bone and Joint Surgery. British volume*, Vol.81, No.3, (May 1999), pp. 444-8, ISSN 0301-620X.
- Meidinger, G, Imhoff, AB, Paul, J, Kirchoff, C, Sauerschnig, M & Hinterwimmer, S. (2011). May smokers and overweight patients be treated with a medial open-wedge HTO? Risk factors for non-union. *Knee surgery, sports traumatology, arthroscopy: official journal of the ESSKA*, Vol.19, No.3, (December 2010), pp. 333-9, ISSN 0942-2056.
- Miller, BS, Downie, B, McDonough, EB & Wojtys, EM (2009). Complications after medial opening wedge high tibial osteotomy. *Arthroscopy*, Vol.25, No.6, (June 2009), pp. 639-46, ISSN 0749-8063.
- Murphy, SB (1994). Tibial osteotomy for genu varum. Indications, preoperative planning, and technique. *The Orthopedic Clinics of North America*, Vol.25, No.3, (July 1994), pp. 477-82, ISSN 0030-5898.
- Noyes, FR, Barber-Westin, SD & Hewett, TE. (2000). High tibial osteotomy and ligament reconstruction for varus angulated anterior cruciate ligament-deficient knees. *The American Journal of Sports Medicine*, Vol.28, No.3, (May-June 2000), pp. 282-96, ISSN 0363-5465.
- Paccola, CA & Fogagnolo, F. (2005). Open-wedge high tibial osteotomy: a technical trick to avoid loss of reduction of the opposite cortex. *Knee Surgery, Sports Traumatology, Arthroscopy: Official Journal of the ESSKA*, Vol.13, No.1, (January 2005), pp. 19-22, ISSN 1433-7347.
- Puddu, G & Franco, V. (2000). Femoral antivalgus opening wedge osteotomy. *Operative Techniques in Sports Medicine*, Vol. 8, No.1, (January 2000). Retrieved from: <URL: <http://www.deepdyve.com/lp/elsevier/femoral-antivalgus-opening-wedge-osteotomy-G5nZoP3YAX>>
- Puddu, G. (2004). High tibial osteotomy. The arthritic knee in the young athlete, SYM 15. *Proceedings of 11th ESSKA 2000 Congress and 4th World Congress on Sports Trauma*, Athens, Greece, May 2004. pp. 446-7.
- Ribeiro, CH, Severino, NR, Cury, Rde P, de Oliveira, VM, Avakian, R, Ayhara, T & de Camargo OP. (2009). A new fixation material for open-wedge tibial osteotomy for genu varum. *The Knee*, Vol.16, No.5, (February 2009), pp. 366-70, ISSN 0968-0160.
- Rinonapoli, E, Mancini, GB, Corvaglia, A & Musiello S. (1998). Tibial osteotomy for varus gonarthrosis. A 10- to 21-year followup study. *Clinical Orthopaedics and Related Research*, No.353, (August 1998), pp. 185-93, ISSN 0009-921X.



- Song, EK, Seon, JK & Park, SJ. (2007). How to avoid unintended increase of posterior slope in navigation-assisted open-wedge high tibial osteotomy. *Orthopedics*, Vol.30, No.10 Suppl, (October 2007), pp. S127-31, ISSN 0147-7447.
- Valkering, KP, van den, Bekerom MP, Kappelhoff, FM & Albers GH. (2009) Complications after tomofix medial opening wedge high tibial osteotomy. *The journal of knee surgery*, Vol.22, No.3 (July 2009), pp. 218-25, ISSN 1538-8506.

IntechOpen

IntechOpen



## **The Role of Osteotomy in the Correction of Congenital and Acquired Disorders of the Skeleton**

Edited by Prof. James Waddell

ISBN 978-953-51-0495-7

Hard cover, 294 pages

**Publisher** InTech

**Published online** 11, April, 2012

**Published in print edition** April, 2012

This book demonstrates specific osteotomy techniques from the skull to the hallux. The role of osteotomy in the correction of deformity is under appreciated in part because of the ubiquitous nature of joint replacement surgery. It should be remembered, however, that osteotomy has a role to play in the correction of deformity in the growing child, the active young adult, and patients of any age with post-traumatic deformity limiting function and enjoyment of life. In this text we bring you a number of papers defining specific problems for which osteotomy is found to be an effective and lasting solution. I hope you find it useful.

### **How to reference**

In order to correctly reference this scholarly work, feel free to copy and paste the following:

Cristiano Hossri Ribeiro, Nilson Roberto Severino and Ricardo de Paula Leite Cury (2012). Opening Wedge High Tibial Osteotomy, *The Role of Osteotomy in the Correction of Congenital and Acquired Disorders of the Skeleton*, Prof. James Waddell (Ed.), ISBN: 978-953-51-0495-7, InTech, Available from: <http://www.intechopen.com/books/the-role-of-osteotomy-in-the-correction-of-congenital-and-acquired-disorders-of-the-skeleton/opening-wedge-high-tibial-osteotomy>

**INTECH**  
open science | open minds

### **InTech Europe**

University Campus STeP Ri  
Slavka Krautzeka 83/A  
51000 Rijeka, Croatia  
Phone: +385 (51) 770 447  
Fax: +385 (51) 686 166  
[www.intechopen.com](http://www.intechopen.com)

### **InTech China**

Unit 405, Office Block, Hotel Equatorial Shanghai  
No.65, Yan An Road (West), Shanghai, 200040, China  
中国上海市延安西路65号上海国际贵都大饭店办公楼405单元  
Phone: +86-21-62489820  
Fax: +86-21-62489821

© 2012 The Author(s). Licensee IntechOpen. This is an open access article distributed under the terms of the [Creative Commons Attribution 3.0 License](#), which permits unrestricted use, distribution, and reproduction in any medium, provided the original work is properly cited.

IntechOpen

IntechOpen