

We are IntechOpen, the world's leading publisher of Open Access books Built by scientists, for scientists

4,800

Open access books available

122,000

International authors and editors

135M

Downloads

Our authors are among the

154

Countries delivered to

TOP 1%

most cited scientists

12.2%

Contributors from top 500 universities



WEB OF SCIENCE™

Selection of our books indexed in the Book Citation Index
in Web of Science™ Core Collection (BKCI)

Interested in publishing with us?
Contact book.department@intechopen.com

Numbers displayed above are based on latest data collected.

For more information visit www.intechopen.com



Limb Salvage for Osteosarcoma: Current Status with a Review of Literature

Manish G. Agarwal* and Prakash Nayak

Department of Orthopaedics

P.D Hinduja National Hospital & Medical Research Centre

India

1. Introduction

Osteosarcoma is the most common primary bone tumor. These tumors have long been known to be very aggressive in their natural history and therefore for a very long time amputation was considered to be the only way to achieve local control of the tumor in the limb. Even after an amputation, only 10-20% survived^{1,2}, the rest succumbing to systemic disease^{3,4}.

In the last 30 years a sea of change has occurred in the outlook for these cancers. Chemotherapy has allowed better local and systemic control^{5, 6}. Better imaging with CT and MRI has allowed the surgeon to accurately define the extent and therefore plan tumor resection. Advances in bioengineering have provided exciting options for reconstruction and the world has moved from amputation to limb salvage. In osteosarcoma, survival improved from dismal 10-20% to 50-70%^{7, 8}. Long term studies showed that limb salvage operations, performed with wide margins and chemotherapy did not compromise the survival or local control compared to an amputation⁹⁻¹⁴.

Cheaper and yet effective chemotherapy protocols and low cost indigenously manufactured megaprosthesis have allowed limb salvage surgery to develop even in the poorer countries. Good surgical technique has improved functional results and made limb salvage today, the standard of care for osteosarcoma.

2. Evaluation

The patient is first assessed clinically and a mental impression formed whether the limb is salvageable, borderline or non salvageable. All patients undergo an imaging workup for local extent and distant spread. This is done prior to a biopsy. An MRI of the local area helps further define the extent and relationships to vital structures like the neurovascular bundle. The MRI helps us plan the margins of resection. The commonest site of distant metastases is the chest. An xray of the chest and where limb salvage is considered a CT scan of the chest (if the x-ray is clear) helps to screen for pulmonary metastases. A bone scan is used to screen for skip lesions and osseous metastases. A PET-CT scan is now being increasingly used for staging instead of

* Corresponding Author

CT chest and bone scan. Presence of distant metastases decreases cure rates but with effective treatment when the metastases are resectable, cure rates of 20-40% have been reported.

3. Biopsy

Irrespective of how typical the imaging appearance, a histopathological diagnosis is a vital step in the diagnostic work up of bone tumors. Fine needle aspiration provides only cytologic material and is not the preferred method for diagnosis of primary bone tumors like osteosarcoma¹⁵. For bone tumors, the cellular architecture as well as the quality of matrix has to be studied for a proper diagnosis which FNAC cannot provide. A tissue sample may be obtained either by an open incisional biopsy or a closed core biopsy. Traditionally an open biopsy has been used. Various complications related to open biopsy like incorrect placement of incision, large scale contamination of tissues, infection and pathological fracture have often forced an amputation when otherwise a limb salvage was feasible. This happens more frequently when the open biopsy procedure is performed by individuals not experienced in managing tumors. A badly done biopsy can negatively impact overall survival¹⁶⁻²¹. We therefore recommend that open biopsy should only be performed in specialized units by surgeons experienced in managing tumors.

Percutaneous core biopsy of bone lesions provides early and definitive diagnosis. The biopsy site chosen should be such that the tract can be excised en bloc with the tumour. The periphery of the tumour is the best site and the pre biopsy MRI may help in localizing the most representative area. Necrotic or heavily calcified or ossified areas are avoided. A soft tissue mass is adequately representative for a biopsy. Where necessary an imaging C-arm or CT guidance is used.

4. Patient education

The patient and the patient's family participate in the decision making process. They are counseled in detail especially when limb salvage is considered regarding the costs, change in lifestyle and mobility and risks involved. The possibility of an amputation and other complications is explained. Amputation as an alternative is also offered in an unbiased way and the patient is encouraged to make his own decision. An attempt is made to facilitate a meeting between the prospective limb salvage candidate and a patient who has already undergone the procedure. Photographs and videos are also shown to the patients and their families.

When the patient and the family are fully informed and participate in the choice of treatment, they are much more likely to be satisfied with the ultimate outcome, even if complications and problems arise at a later stage. It is important to stress to patient and their family that limb salvage may require additional procedures either in near or distant future to manage some of the complications.

5. Indications for limb salvage surgery

Long term clinical case studies have shown that a limb salvage procedure has the same survival as an amputation⁹⁻¹⁴. Therefore every patient with a malignant tumor of the extremity is considered for limb salvage if the tumor can be removed with an adequate margin and the resulting limb has satisfactory function. An adequate margin is one that

results in an acceptably low rate of local recurrence of the tumor. An adequate margin is generally wide in most areas. It may be close in some areas for example in the case of a distal femur resection, the popliteal vessels may be on the pseudocapsule but can be easily separated and experience has shown an acceptable low rate of local recurrence. After salvage the limb should have an acceptable degree of function and cosmetic appearance with a minimal amount of pain, and should be capable of withstanding the demands of normal daily activities. It must look and function comparable or better than an artificial limb after amputation. Balancing these sometimes conflicting requirements is what makes limb salvage surgery a complex and difficult, but rewarding process.

In selected cases, limb salvage can be combined with metastatectomy. For patients with uncontrollable disease, limb salvage should be considered if the surgery can be accomplished with minimum morbidity and rapid return to function. These patients can enjoy relief from pain, improved quality of life, and intact body image that limb salvage can offer, even if they may not survive long term.

6. Barriers to limb salvage

Barriers to limb salvage include poorly placed biopsy incisions, major vascular involvement, encasement of a major motor nerve, pathological fracture of the involved bone, infection and inadequate motors after resection. These adverse factors are barriers but not absolute contraindications. For example in pathological fractures, the fracture often heals with chemotherapy and the specimen can be removed with adequate margins. Ability to transfer motors, graft nerves and vessels and provide skin cover with microsurgical methods have allowed successful limb salvage despite many barriers. If the patient has limited financial resources, it is better to spend the money on chemotherapy and do an amputation rather than doing limb salvage and not giving chemotherapy.

7. Surgical resections and reconstructions

For successful local tumor control it is essential to achieve a complete resection of the tumor with an adequate margin (Fig 1). As stated earlier, an adequate margin in any particular case remains controversial²⁵. For high grade sarcomas, a wide margin is considered adequate and will achieve successful control of the primary tumor approximately 95% of the time, whereas marginal or intralesional margins are associated with higher rate of local recurrence and poor outcomes²⁶. For bone 3cm away from the extent on T1-MRI image is adequate²⁷⁻³². The marrow is always sent from the cut end for frozen section evaluation for tumour. If positive the resection is revised. For the soft tissue 1-2cm margin is preferred wherever possible. In practice, the line between a wide and a marginal margin is sometimes difficult to define as the surgeon strives to control the tumor while still leaving the patient with a useful limb. However, when in doubt, the surgeon errs on the side of excess tissue removal. The adequacy of the margin can be judged by bivalving the specimen. If there is any doubt about margins, a frozen section can be done and a decision for an amputation can be made on table. This is the reason that any patient undergoing a limb salvage procedure is forewarned about this possibility and a consent for amputation always obtained.

After completion of the tumor resection, the surgeon must reconstruct the resulting surgical defect. The surgeon must eliminate potential dead space and transfer tissues if necessary to

allow an effective closure. Occasionally, the reconstruction or substitution of a segment of artery or nerve may be required.

Most osteosarcomas occur in the metaphyseal portion of the bone, so that the typical resection involves the whole proximal or distal part of the bone. If the joint is not contaminated by the tumor, an intraarticular resection is performed through the joint. If the joint is contaminated, then an extraarticular resection is required, taking the entire joint and joint capsule, and cutting through the uninvolved bone on the other side of the joint to achieve a wide margin. The gap remaining needs reconstruction either with metal or with bone or a composite of the two. For tumors that involve the diaphyseal portion of a bone, an intercalary resection and reconstruction can be performed that saves the joints at either end. It is now possible to save the joint even if only 1.5-2cms of condyle thickness remain²⁷. For low grade osteosarcoma, a hemicortical excision which removes only a part of the bone circumference is effective in disease control. The reconstruction done often depends on the kind of defect (fig 2).

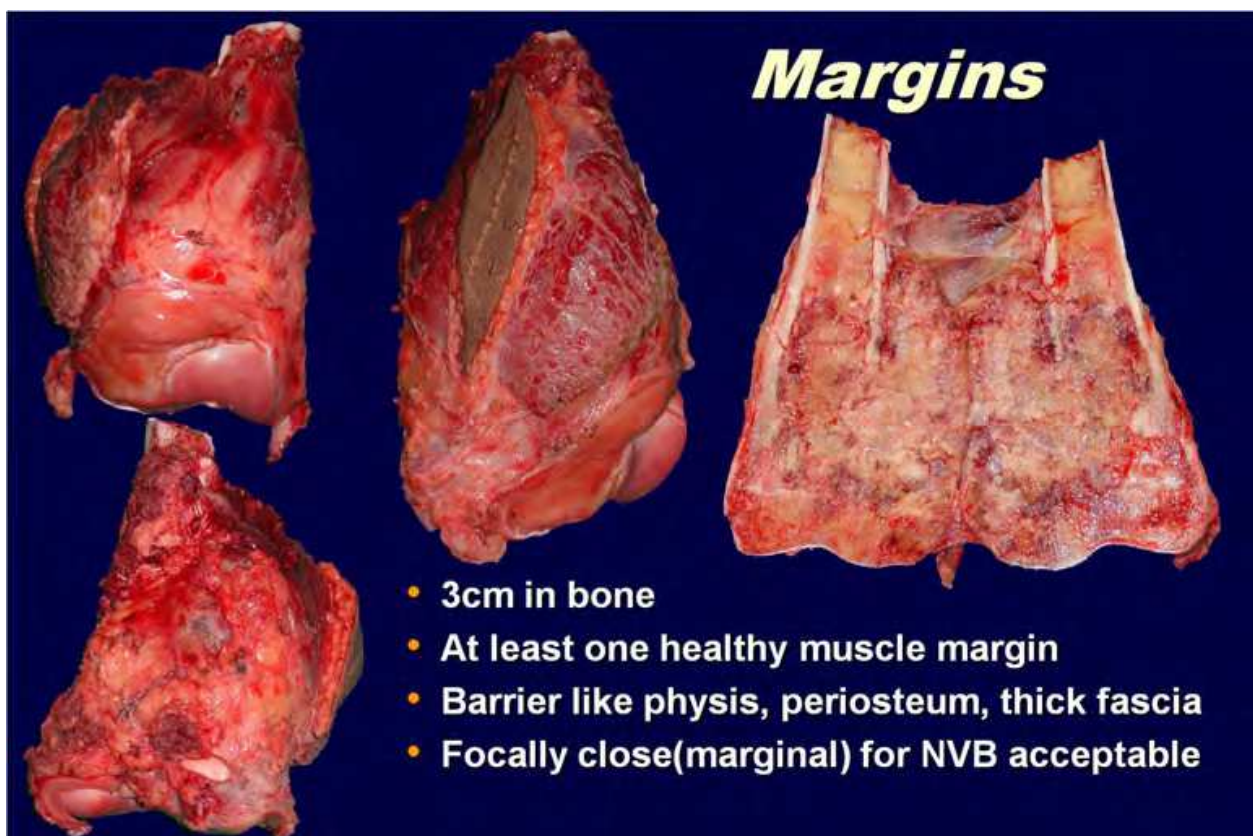


Fig. 1. Margins considered adequate for high grade osteosarcoma excision. The figure shows a resection specimen of the distal femur osteosarcoma. It is covered by an uninvolved muscle layer. The biopsy track has been completely excised en bloc with skin. There is 3cm margin from marrow extent of tumor at proximal end and the joint cartilage as margin for the distal end.

7.1 Hemicortical defects

These result generally from partial circumferential excision of benign or low grade tumors like a parosteal osteosarcoma. Reconstruction of these defects can be done by a shaped

allograft or by fibula or iliac crest strut autograft.²⁸ Because of the large contact area and vascularity of the bed, usual complications associated with allografts like infection, non-union and fracture are rare. We reported our results in ten cases with complete incorporation of the graft in all the cases and no local recurrence.²⁸

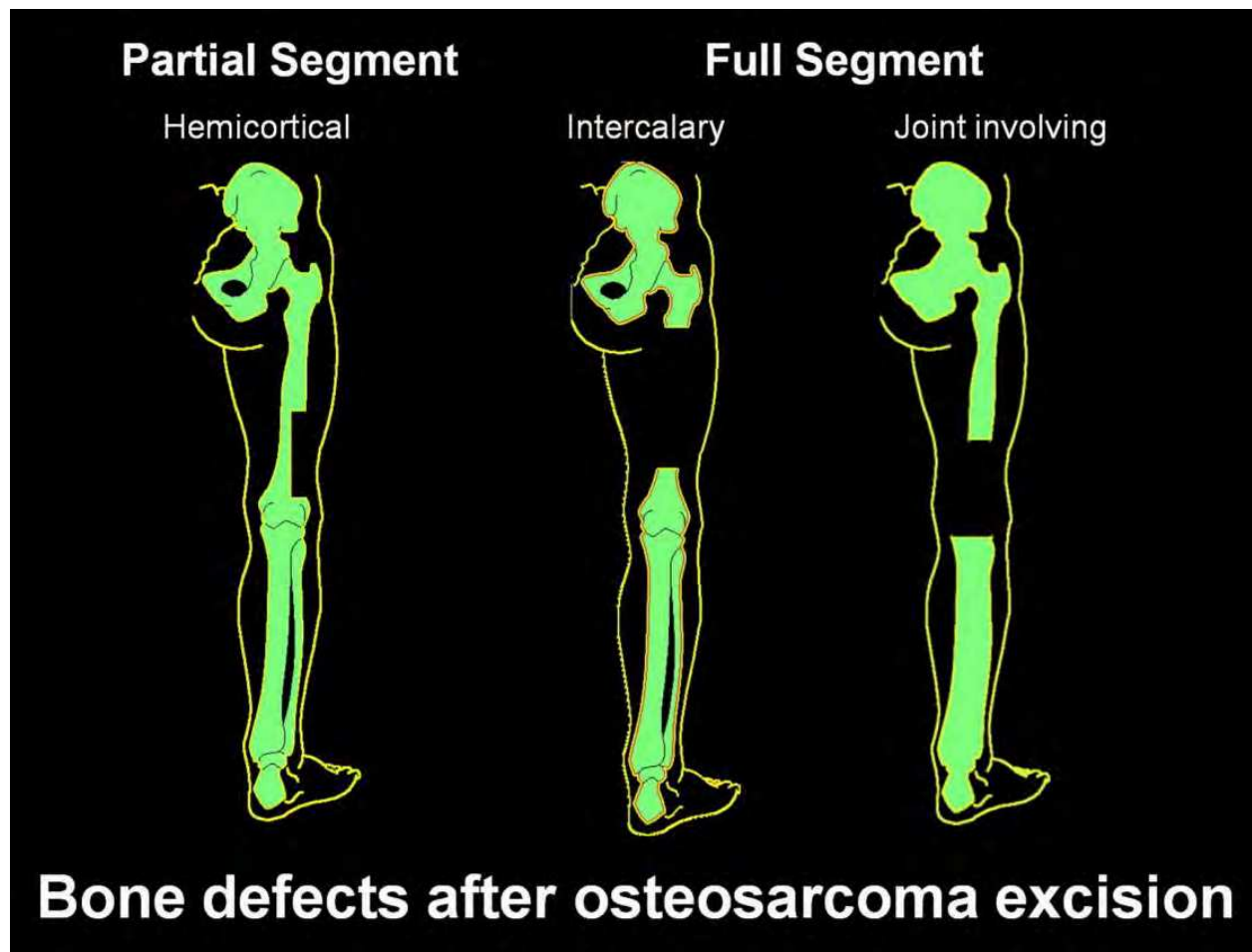


Fig. 2. The various kinds of bone defects resulting from an excision of an osteosarcoma. Hemicortical excision can be done for a low grade osteosarcoma like parosteal osteosarcoma. For all others, a full segment resection is advised.

7.2 Full segment defects

These are a result of complete circumferential excision of bone segments. These can be intercalary or joint involving (Fig 2). Since most tumors occur around the metaphysis, joint involving defects are more common.

7.2.1 Joint involving defects

7.2.1.1 Megaprosthesis

Megaprosthesis is a large metallic joint designed to replace the excised length of bone and the adjacent joint. These are fully constrained hinge joints. They provide an immediate return to function and are not affected by ongoing adjuvant treatment like chemotherapy

and radiotherapy. They thus form the mainstay in limb salvage surgery for reconstruction after tumor resection.

Advances in metallurgy and fabrication have tremendously improved these joints. Joint breakage is now rare and aseptic loosening rates are also very low with the use of rotating hinges and with extracortical bridging between the bone and implant collar.²⁹ Infection and local recurrence are the commonest cause of prosthesis failure and happen in around 15% of cases.

A customised joint has to be ordered as per individual patient's dimensions. It takes 4-6 weeks for fabrication. In contrast modular systems (Fig 3) allow for immediate availability. They also allow intraoperative flexibility. The drawback is that they are expensive and a large inventory of the components has to be kept. A customized prosthesis can be improved with every joint but this is not possible for a modular system. Currently modular systems are used for most adults and children near skeletal maturity as adequate modularity ensures a good fit into the defect for almost all patients. In children or in places where anatomy is distorted, customized implants are used to adjust for smaller or abnormal bone size and to allow expansion.

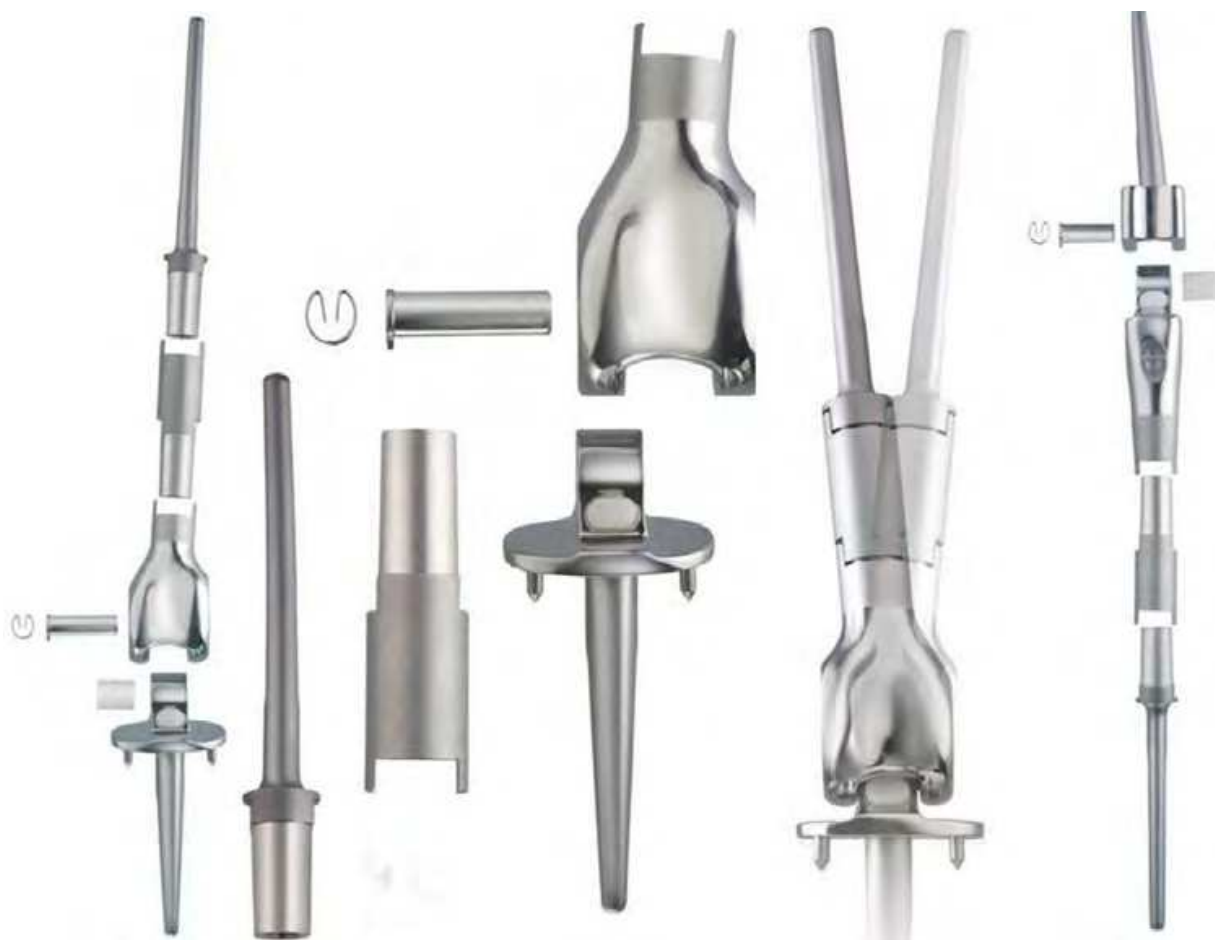

Fig. 3. Figure showing a modular megaprosthesis system for distal femur or proximal tibia resection (RESTOR, Adler Mediquip Pvt Ltd, India). Note that numerous components linked to assemble the complete prosthesis. The modularity allows the implant to be matched to the defect as well as to the bone in which it is to be implanted.

Special attention is paid during closure to ensure that the prosthesis is fully covered by a healthy soft tissue envelope. Wherever possible, as in proximal tibia, tendons are reattached to the construct. In the proximal femur, wherever possible, reattachment of the abductors reduces the limp. In the shoulder, the rotator cuff is lost and the proximal humerus implant works as a mere spacer to allow function of the elbow and hand. Wherever the deltoid and axillary nerve can be preserved, a reverse shoulder implant can be used.³⁰ This allows active flexion and abduction which was not possible with the conventional implant. Scapular endoprosthesis after a scapulectomy may provide better function than simple humeral suspension of the latissimus dorsi, trapezius, deltoid and rhomboids can be preserved with better abduction and flexion.³¹

It is now possible to reconstruct the entire humerus or femur (fig 4) with prosthesis. Though the surgery involves a massive exposure and long duration, the functional results have been superior to that after an amputation and external prosthesis.

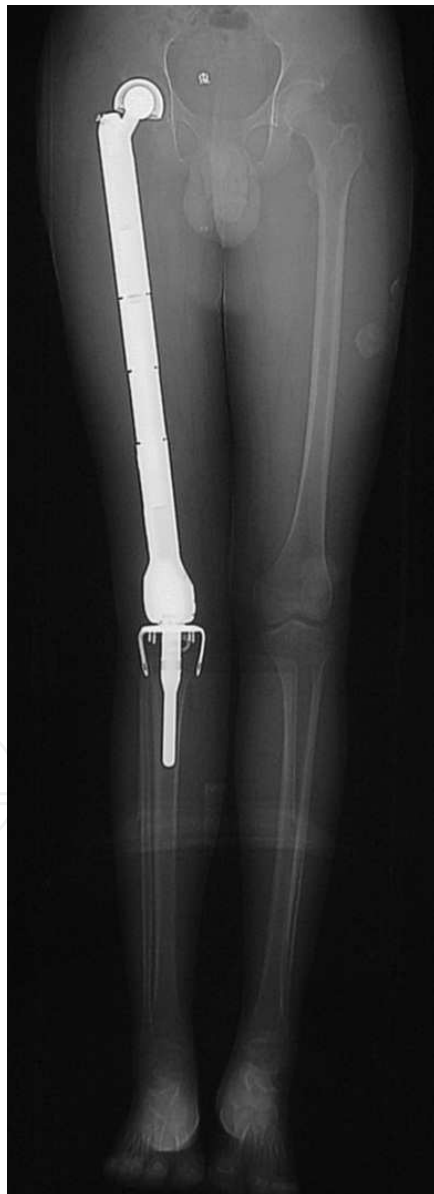

Fig. 4. A total Femoral endoprosthesis replacement

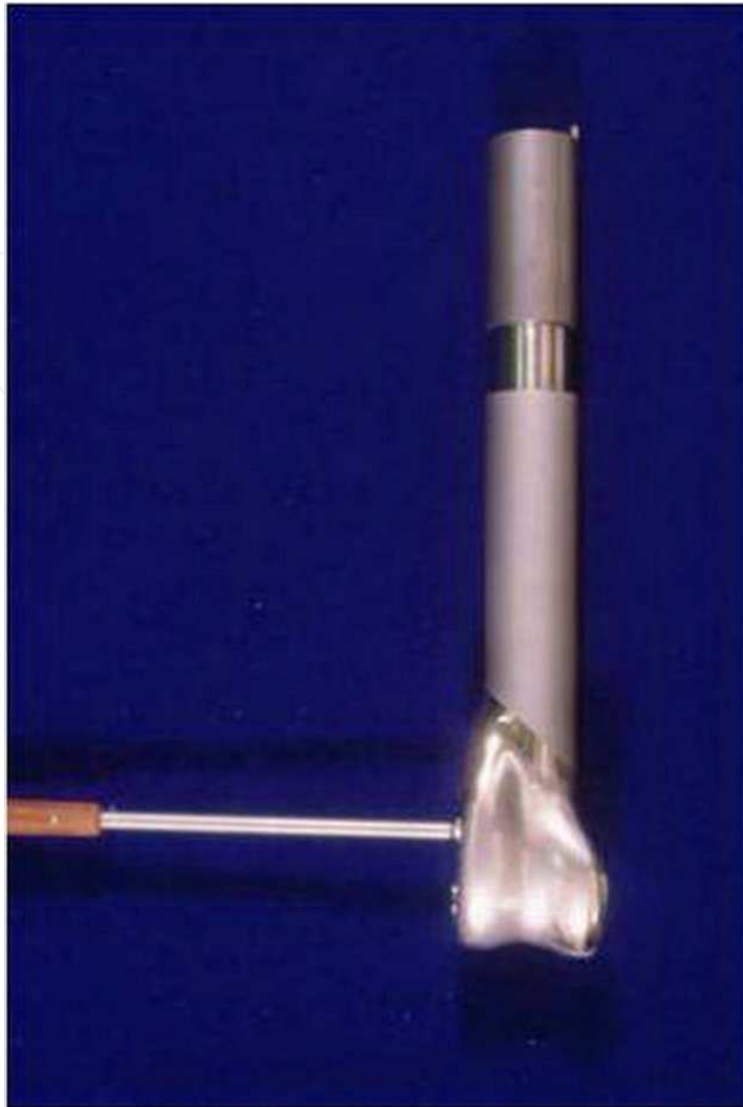

Fig. 5. An expandable distal femur megaprosthesis. This is a minimally invasive expandable system. The screwdriver drives a wormgear mechanism to drive out a telescoping cylinder resulting in lengthening.

Regardless of the method of fixation to the host bone, the prosthesis may loosen over time. Mechanical wear of the polyethylene bearing surfaces can lead to failure of the reconstruction. Rebushing is required more commonly in the fixed hinge implant and generally after five years.^{29, 32} Using an hydroxyapatite coated or porous coated collar to allow extracortical bone bridging between host bone and implant has reduced the rates of aseptic loosening to almost zero.²⁹ Breakages are now rare with the use of stronger metals and superalloys like titanium and Chrome-cobalt. When these implants fail, revision procedures though complex have generally been successful after implantation of a new prosthesis.³³

7.2.1.2 Expandable prosthesis

Managing limb lengths is a challenge in young children treated with limb saving surgery. While they are cured of cancer, the operated leg becomes shorter as the normal leg

continues to grow while the operated leg does not. This required the child to use shoes with a thick heel to compensate for limb length discrepancy but also resulted in limp and poor function. To overcome these problems, a special prosthesis was designed which could be lengthened periodically (expandable prosthesis). The prosthesis had a worm-gear mechanism which allowed a telescoping cylinder to increase the length when a screw was turned (Fig 5). This was done surgically by a small operation in which a small cut was made and a screw driver used on the prosthesis to turn a screw which allowed a tube to telescope out. This had to be done repeatedly as the child grew to keep pace with the growth of the normal side. Though surgery was involved, the fact was that now length could be maintained in these children.

Even with all these advances, it means that the child has to undergo multiple surgical procedures for lengthening. It means admission to hospital, anaesthesia and surgery, all of this adding to the costs of treatment. Also, since we want to minimize the number of operations required, we lengthen more at each operation. We try to lengthen 1cm or more depending on the child and the need. Every surgery results in some stiffness, pain and time to rehabilitate to come to normal as this much growth is not easily adjusted to by the body. Each surgery also increases the risk of infection which is estimated to be about 8% in the current era.³⁴

In order to solve some of the problems above, prostheses have been developed which can be expanded remotely without the need of any surgery. We have used the implant made by stanmore implants worldwide, U.K. The prosthesis has a very sophisticated mechanism sealed inside it which allows lengthening to happen with the help of an electromagnetic field.³⁵ A rare earth magnet is placed along with a motor and a gear system inside the prosthesis. A coil from outside around the implant can now generate an electromagnetic field to turn the motor. Through a system of miniature gears, the movement of the motor can allow the expansion of the implant by moving the telescoping tube out just like it was done with a screw driver. The biggest advantage is that now surgery is not required for lengthening. Small amounts of lengthening are done more like normal growth. There is no pain or stiffness, no hospitalization and no risk of infection. In the long run this turns out to be cheaper than the minimally invasive implant.

7.2.1.3 Osteoarticular allografts

Allografts offer the surgeon additional reconstructive options in bridging large bone defects after tumor excision. Osteoarticular allografts have shown a success rate of 70% at long term follow-up.⁴² Allografts have the advantage of providing biological bed for soft tissue anchorage. The attachment of muscle insertions is more successful in allografts than in prostheses, yielding better function in some sites. Initial enthusiasm for allografts has been tempered by a variety of problems as experience has accumulated. While it was initially hoped that massive allografts would become fully incorporated into the host, retrieval data show that only a small percentage of the allograft actually becomes revascularized, while the rest remains necrotic ^{43, 44}. Rather than a biologic replacement for the excised bone segment, the allograft functions as a biologic spacer. Massive allografts are susceptible to infection (5-15%), fracture (15-20%), Non-union (15-20%) and osteoarthritis from collapse of the articular surface (with osteoarticular graft) ⁴⁵⁻⁴⁹. Chemotherapy and radiotherapy can

adversely affect the union rates⁴⁸⁻⁵². An additional concern is the potential for the transmission of bacterial or viral disease.

7.2.1.4 Alloprosthetic composite and others

Sometimes a composite of an allograft and an endoprosthesis is used for certain limb-salvage reconstructions. An appropriate allograft is selected and implanted to replace the segment of bone resected. The articular surfaces of the graft are excised and replaced using conventional techniques of total joint arthroplasty. The allograft provides a source of bone stock and a site for tendon insertions, while the prosthesis provides a reliable and stable articulation and some support for the allograft. The surgeon can customize the implant for any particular need. An allo-prosthesis construct has a lower fracture rate than allograft alone⁴⁹ and is not susceptible to osteoarthritis.

7.2.1.5 Resection arthrodesis

Arthrodesis for the knee, though disabling can provide a practical low cost option for reconstruction after bone tumor resection especially if patient is likely to engage in heavy manual labour. Even in a developing country it causes difficulty with squatting, traveling in bus, etc. It is therefore not easily accepted and done only occasionally by us. The principles of surgery involve bone grafts coupled with internal fixation, very similar to those of intercalary resections. Allografts alone, unlike in intercalary resections have shown a high failure rate due to infection, fracture and non-union.⁵³⁻⁵⁴ Autografts vascularised or non-vascularised are used along with fixation which is either a locked long nail, or a long plate or sometimes an external fixator.⁵⁵ Distraction osteogenesis has been another option used particularly in benign tumors. An intramedullary nail, double osteotomy, fewer rings and early fixator removal have reduced the complication rates.⁵⁵ We have preferred to use a double barrel live fibula or an allograft combined with a live fibula and neutralized with a long plate.(fig 6)

The defect can be bridged by using autograft or an allograft or a combination. A vascularised live fibula with allograft supplementation is a good alternative and our method of choice. A non vascularised graft always has the risk of fracture. Fixation is either with a plate spanning the defect or with a long customized nail. These patient have to be immobilized for a long time till union. Besides, radiotherapy and chemotherapy can interfere with union. An intercalary long segment allograft can be used with implant fixation but has a high rate of complications⁴⁵. Even with an autograft, non union and fracture rates are high and it is almost a year before arthrodesis is sound. Till this time the patient has to be protected and load bearing restricted.

Functionally, the gait of these patients with knee arthrodesis is a little awkward due to the stiff knee and sitting is difficult. However these patients are not afraid of loading their limb and can engage in strenuous activities⁵⁶.

Very few of our patients opted for an arthrodesis. The ones that did, did it for reasons of cost. The low cost of the megaprosthesis made it easier for patients to opt for a mobile reconstruction. Occasionally a nail and cement arthrodesis is used in cases where long term survival is unlikely (palliative limb salvage). A long K nail is used with cement to bridge the defect. The cement provides rotational stability. In these cases patient can be ambulant immediately.

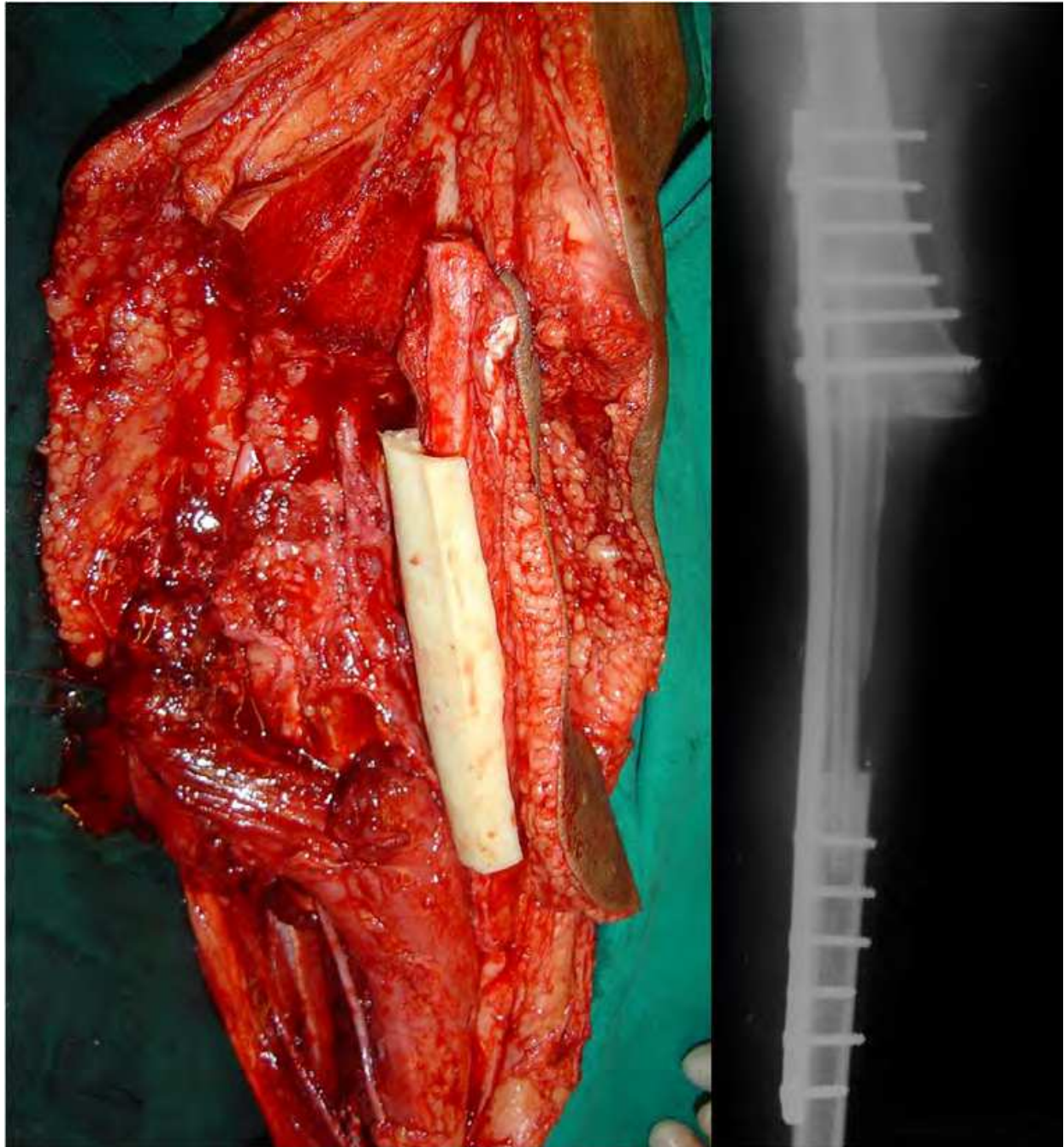


Fig. 6. An allograft with a pedicled (vascularised) fibula for a resection arthrodesis of the knee. The allograft is hemicylindrical to avoid any compression of the pedicle or skin attached to the fibula. The xray shows the union at junctions which happened uneventfully in less than 6 months.

7.2.1.6 Rotationplasty

Rotationplasty is a procedure which allows the ankle to substitute as the knee after 180° rotation of the limb. The original idea was conceived by Borggreve in 1927 to treat a shortened lower limb with stiff knee after tuberculosis and popularized by Van Ness for management of proximal focal femoral deficiency⁵⁷. Salzer in 1974 first used it for malignant tumors around the knee⁵⁸. It is essentially an intercalary limb resection preserving the

continuity of the neurovascular bundle. The limb continuity is established by fusing the Tibia with the proximal femoral remnant after 180° external limb rotation. This allows the ankle joint to come to the level of the knee and its axis of motion corresponding with the original knee. A special external prosthesis then is fitted allowing the patient to ambulate. Ankle movements now simulate knee movements (Fig 7). This reconstruction therefore functions like a below-knee amputation. A big advantage is that the sole being the normal weight bearing area, there is no phantom pain. The stump can be left longer in children to account for subsequent shortening with growth. These patients are able to walk normally, run, participate in leisure outdoor sporting activities, ride a bicycle and drive a car etc.

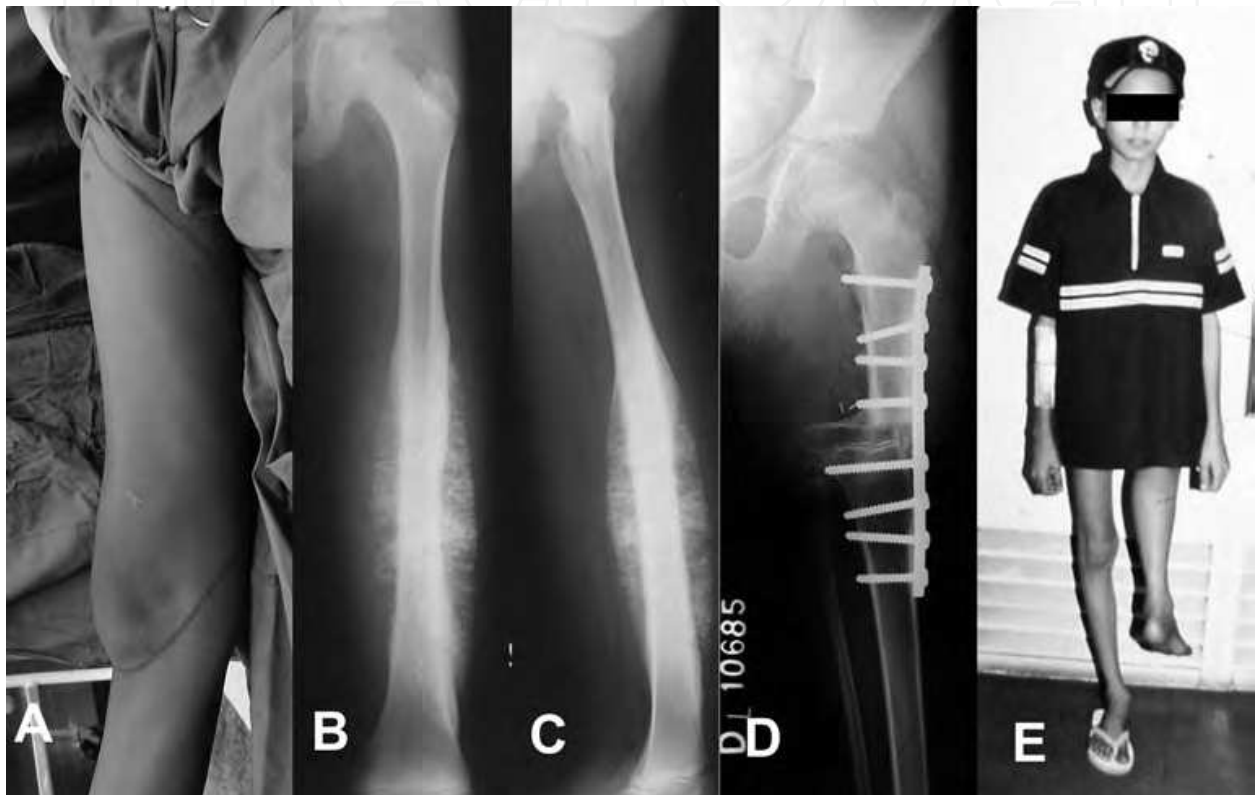


Fig. 7. Rotationplasty. A: the rhomboid incision taken. B & C : The Anteroposterior and lateral xrays of a femoral osteosarcoma after induction chemotherapy. D: postoperative xray showing the osteosynthesis between the proximal femur and proximal tibia using a plate. E: The clinical appearance of rotationplasty

Though very well described in literature with functional results comparable to an endoprosthetic reconstruction⁵⁹⁻⁶², the limb disfigurement produced has been a psychological barrier to widespread acceptance especially in the developed world. Most series for functional evaluation have shown superior functional results compared to megaprotheses, but small numbers in rotationplasty group have made statistical evaluation difficult.⁶²⁻⁶³ Patients with rotationplasty are reported to have less pain and are more likely to participate in sports as compared to megaprotheses.⁶¹ Akahane et al⁶⁴ in a small group of 17 patients reported better function and quality of life results with a rotationplasty than with an endoprosthesis. Rotationplasty is a low cost alternative to prosthesis in a developing country like India.⁶⁵ The surgical procedure is straightforward, the external orthoses cheap and easily available and with no revisions necessary coupled with the ability to squat and load the limb make it an

easily accepted alternative over amputation for the economically backward. In children one can adjust the stump length for growth and avoid all the problems and costs associated with expandable prosthesis and expansions. It also works as an excellent salvage option for a failed megaprosthesis, especially after infection.⁶⁶ Another advantage is that with large tumors and extensive quadriceps involvement (common in a developing country like India), it can still provide functionally good outcome. An osteotomy of the femur early in the procedure allows limb rotation and makes dissection of the neuro-vascular bundle easier.⁶⁶ A specially designed jig helps to cut the bone perfectly perpendicular to the long axis and makes osteosynthesis between tibia and femur easier.⁶⁵⁻⁶⁶ Rotationplasty can be performed in even in smaller hospital setups without need for complex instrumentation. Long term results have not shown any arthroses in the ankle joint proving excellent adaptation.⁶⁷

We have found excellent functional scores and patient satisfaction with this method. This has to be compared with an high above knee amputation or hip disarticulation where even with an artificial limb the function is inferior. Walking speeds, gait, oxygen consumption and general efficiency were better or comparable with other procedures like arthrodesis, endoprosthesis & amputation⁶⁸⁻⁷⁰. Though cosmetically unappealing, functional benefits overshadow the appearance. Prior to surgery the patient is shown photographs and videos and wherever possible meets another similar patient. The mental preparation goes a long way in ultimate acceptance by the patient.

7.3 Intercalary defects

Intercalary defects are broadly classified as diaphyseal, metaphyseal-diaphyseal, or epiphyseodiaphyseal (fig 8).⁶⁸

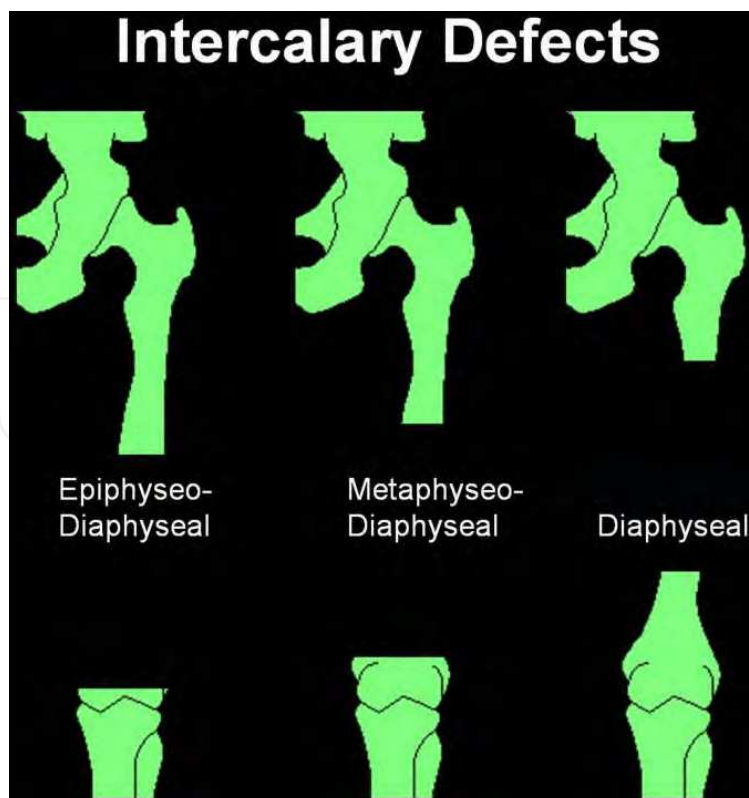


Fig. 8. Various types of intercalary defects depending on the level of distal and proximal cut

7.3.1 Autografts and allografts

Although numerous problems continue to limit the success of allograft reconstructions, they remain a viable choice for selected uses, especially in the upper extremity, for intercalary resections, and for patients who will not need chemotherapy. Intercalary allografts have shown higher success than the osteoarticular ones⁴⁶. Reconstruction of epiphyseo-diaphyseal defects with allografts is challenging. Despite the large cancellous bony contact surface, lack of rigid fixation at the epiphyseal end delayed the average time to union to 18 months compared to 13 months at metaphyseal end.⁶⁸ Vascularised fibula (VF) is a good alternative for intercalary defects especially for longer gaps.⁶⁹⁻⁷⁰ VF showed 93% union rate with only 15% delayed union as compared to allografts which have had 68-90% union rates with 51-57% delayed union rates.⁶⁹ Most of VF patients could return to athletic activity. Donor site morbidity was not a serious problem with most complications resolving with conservative treatment.

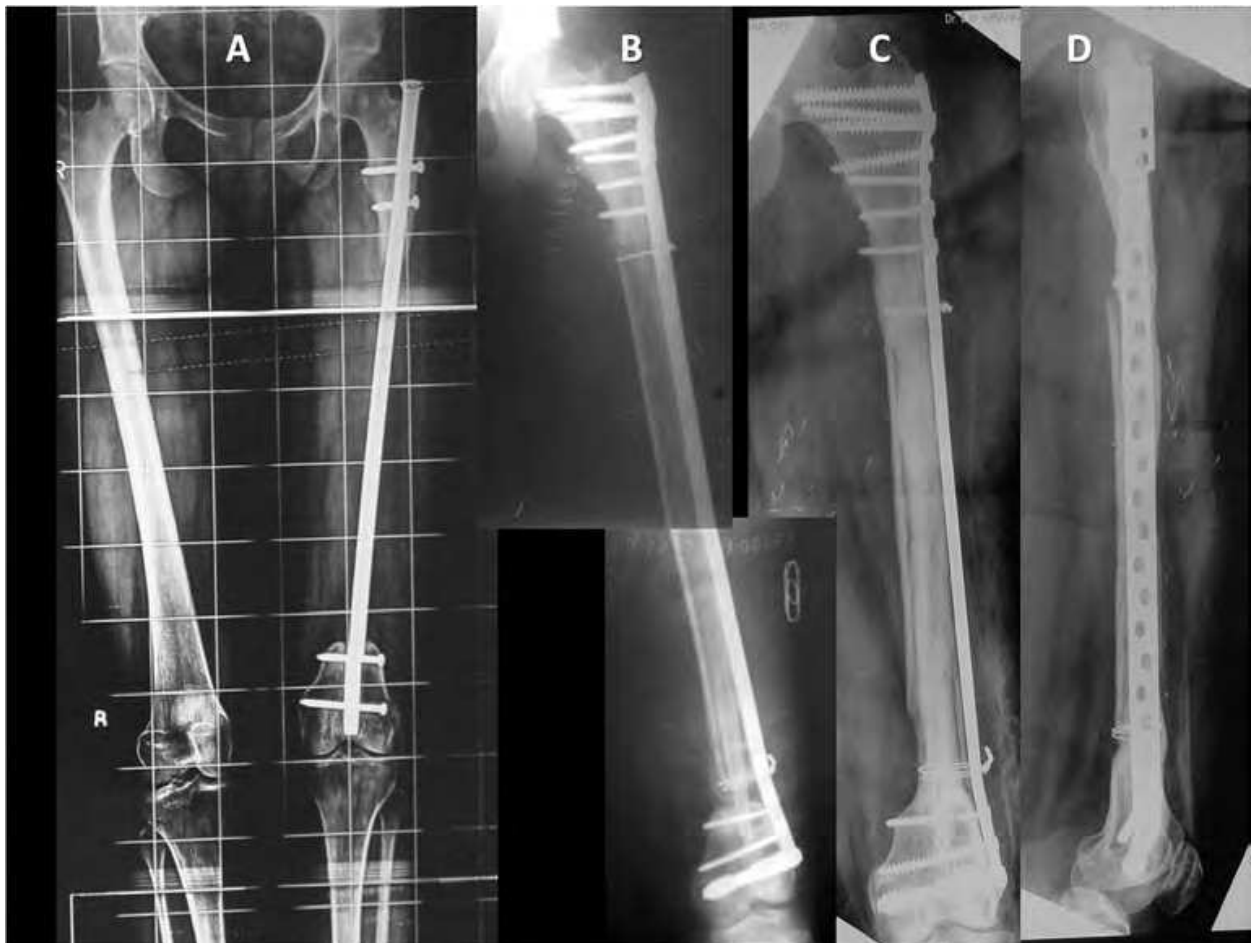


Fig. 9. A: Osteosarcoma of the femur treated by an intercalary resection. The surgeon reconstructed the defect with an interlocking nail only which broke in 2 years. This was replaced by an Allograft with a vascularised fibula placed in the intramedullary canal (B). C & D show the follow up xray at one year showing the excellent incorporation of graft and fibular hypertrophy

Non vascularised fibular autograft can be a simple low cost and yet effective alternative to Allograft or VF. Krieg et al⁷¹ reported from their experience of 31 cases using a non vascularised fibula a primary union rate of 89% in a median time of 24 weeks. 15% had a fatigue fracture with no fractures where a double or triple strut was used. Hypertrophy of the graft was similar to that in VF.

The results of allograft can be improved by combining them with a vascularised fibula either placed in the medullary canal of the allograft or as an onlay by providing vascularity in the centre of the allograft.⁷²⁻⁷³ The healing of the junctions is quick and reliable and the fibula hypertrophies over a period of time. The allograft provides the initial strength and the vascularised autograft provides speed of union. Our experience with radiated allograft alone has been rather disappointing with only about 40% grafts incorporating. Radiation and chemotherapy have probably resulted in poorer incorporation. A single fibula especially in defects over 20cm was prone to fracture. We therefore recommend an allograft combined with a live fibula rather than an allograft alone for long full segment defects. The faster incorporation results in fewer failures and earlier return to full function. For smaller defects with strong and rigid fixation, a VF alone may be adequate.

7.3.2 Reimplantation of tumor bearing bone

Reimplanting the tumor bearing bone after some form of treatment (autoclaving, pasteurization, freezing with liquid nitrogen, or extracorporeal radiation) to kill the tumor cells is another exciting low cost option. Though dead like an allograft, it is perfectly matched to the defect. Autoclaved bone has provided fairly good results as reported from 12 cases from Pakistan with only one non-union and no fractures with an average MSTS score of 70% at a mean follow-up of 49 months.⁷⁴ Yamamoto et al⁷⁵ histologically examined a specimen of autoclaved and reimplanted bone in femur retrieved after 24 months and found most of the graft not incorporated. New bone formation was thin and superficial over the graft and bone scan exaggerated the bone formation. This does not seem to match the clinical experience cited above. In future it may be possible to improve the osteoinductivity of autoclaved bone by coating with rhBMP-2.⁷⁶ A combination of dehydration and thermal denaturing can prevent loss of strength and improve clinical performance.⁷⁷

High temperatures associated with autoclaving are known to damage the collagen matrix leading to loss of strength as well as BMP and osteoinductivity. Pasteurisation involves heating the bone to 60 deg C for 30 min in a water bath and is an effective way of killing all tumor without affecting strength and osteoinductivity. Clinical results with pasteurized graft have shown results at least comparable to allografts.⁷⁸⁻⁷⁹ Freezing in liquid nitrogen is another way of killing the tumor and yet being able to reimplant the bone. Tsuchiya et al⁸⁰ reported bony union at a mean of 6.7 months after the operation in 26/28 patients. There were three deep infections, two fractures, and two local recurrences.

Extracorporeal irradiation (FIG 10) with doses of 5000rad (equivalent to 25kgy of conventional radiation) is also effective in killing all tumor.⁸¹ The rate of non union (7%) is

significantly lower with ECRT as compared to allografts (43%).⁸² The fracture rates were similar and there were no infections. Histological evaluation of specimens from failed ECRT cases show changes of repair and viable osteoblasts after 2-3 years.⁸³

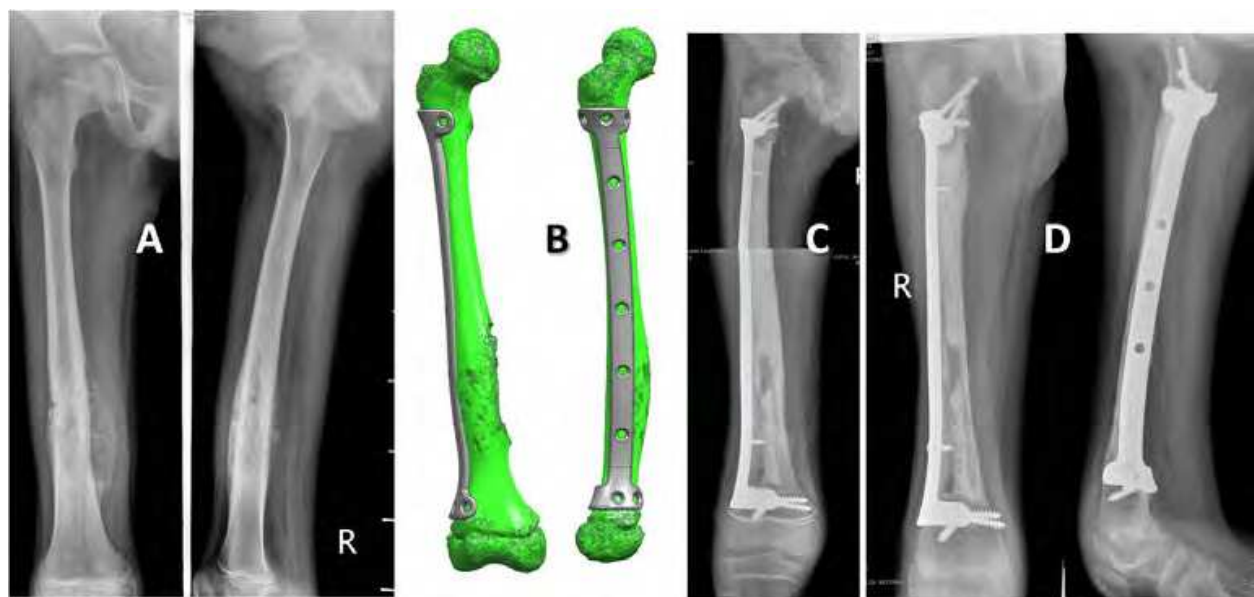


Fig. 10. A: Preoperative xrays of an osteosarcoma of the femur treated with extracorporeal irradiation and reimplantation(ECRT). B: schematic view showing the custom plates made to fix the construct. C: The postoperative xray showing the radiated autograft construct. Note the screws close to the distal physis. D: followup xray showing incorporation of the graft and growth from the distal femoral physis.

As in an allograft, a live fibula improves the results with pasteurized as well as radiation treated bone.^{71, 73, 84}

7.3.3 Prosthesis

Prosthesis can be used to reconstruct non-joint defects. These can be used as physis sparing or joint saving implants.²⁷ Endoprosthetic reconstruction of a diaphyseal defect avoids the donor site morbidity of autograft and the fracture and non-union risk of allograft especially for patients on chemotherapy. It also shortens surgical time significantly as compared to a VF. Clinical results have been at least as good as allografts.^{85, 86} The higher rate of loosening in the upper limb may be due to rotational stresses. The aseptic loosening may be reduced with hydroxyapatite (HA) or porous titanium bead coating.²⁹ Customised HA coated implants have been used for epiphyseo-diaphyseal defects. (fig 5) Early stability is obtained by extracortical plate fixation. No loosening or fractures were reported from 8 cases studied with a short follow up of 3 years.⁸⁷ This implant can be expandable where the physis is resected to maintain limb length with growth.(fig 11) The early results are promising and this could become the method of choice for intercalary reconstruction.

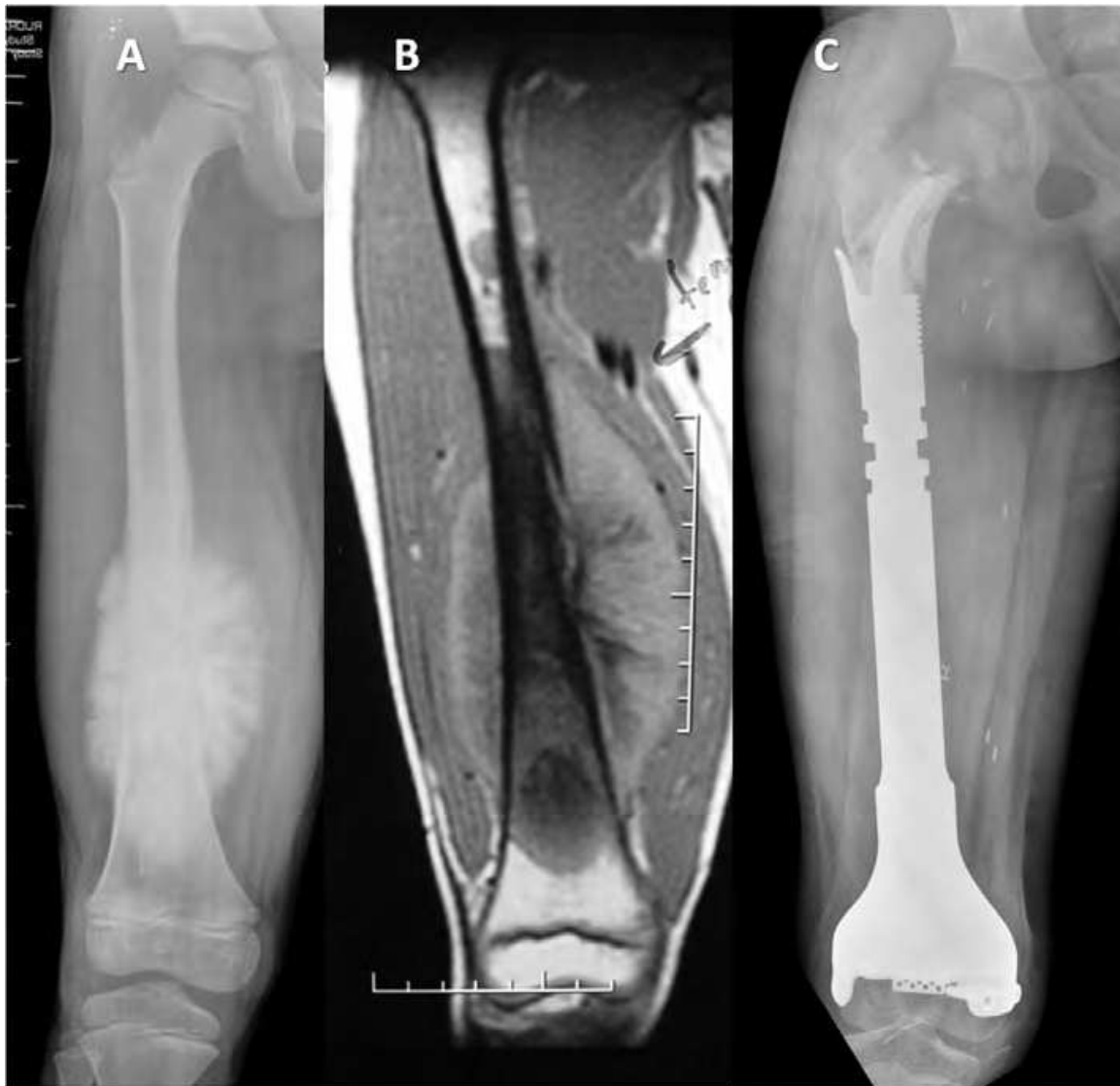

Fig. 11. A: Preoperative xray of a distal femur osteosarcoma. B: The MRI shows the extent just proximal to the distal femoral physis. Note the skip lesion proximally. C: The defect was constructed with a custom prosthesis designed to fit into the small distal and proximal fragment. The distal fixation is with an hydroxyapatite coated surface and small extracortical plates. The proximal fixation is with a curved short intramedullary stem. This prosthesis could be lengthened with a noninvasive expansion mechanism (STANMORE implants, UK)

8. Pelvis

Any tumor in the pelvis is a challenge to an orthopaedic oncologist for resection and osteosarcoma being a high grade malignant tumor is even more challenging. Tumors are often large at presentation and do not always respond well to the preoperative chemotherapy. Osteosarcomas of the pelvis are rare accounting for 7-9% of all osteosarcomas.⁸⁸ Prognosis has been reported to be dismal with 18% 5 year survival^{88,89,90}. Recent report indicates a 50% 5 year survival.⁹¹ Since osteosarcoma does not respond well to radiation, surgical resection with a tumor free margin is the only reliable method for cure.

The surgery is extensive and has the potential for many complications. An external hemipelvectomy has therefore been the standard of care in the past. Though it causes major disfigurement and extensive functional handicap, it was the safest way of getting a chance of cure in a pelvic osteosarcoma. With improvement in imaging as well as surgical technique and technology, limb saving resections have now become feasible and are the standard of care.

Pelvic resections for tumors are amongst the most challenging of operations for any surgeon. A detailed knowledge of anatomy and preparedness and ability to deal with large blood losses is a prerequisite. Pelvic resections are any one or the combination of the following four types. Type I (Iliac), Type II (periacetabular), Type3 (anterior arch) and type IV (sacrum). Classically, internal hemipelvectomy means resection of the entire hemipelvis from the SI joint to the pubic symphysis. Today, the term has come to include resections of the pelvis which include the acetabulum with varying portions of the Ilium & the anterior arch. Resections involving the acetabulum leave behind significantly more instability than the other types of partial pelvic resections.

Pelvic resections are extensive operations associated with the risks of major blood loss as well as wound problems from the extensive exposure and long surgical time. Resection without any reconstruction was done in the past to minimize these complications. With improvement in technique and results, reconstruction using arthodesis (iliofemoral and ischiofemoral fusion)(fig 12), surgical pseudarthrosis (mesh reconstruction), pelvic allografts, custom-made endoprostheses, the saddle prosthesis and reimplantation of the excised hemipelvis after sterilisation by radiation have been used with better cosmetic and functional results.⁹²

It is logical to use these extensive surgical procedures only in those with a chance of cure. To minimize the incidence of local recurrence, only those patients should be selected where the extent of the tumor (judged by a preoperative workup) is such that it is possible to provide adequate margins for local control by surgery.; ie, tumors involving the innominate bone without extension into soft tissue or with minimal or moderate extension into soft tissue such that would permit an en bloc resection through clean planes and allow preservation of the major nerves and vessels for the ipsilateral extremity. Also, the general physical condition and life expectancy of the patient should justify the procedure because of the prolonged rehabilitation period (9-15mo). Involvement by the tumor of one of the major nerves, ie, sciatic or femoral, requiring its sacrifice, should revise the operative plan to that of a standard hemipelvectomy. Of course, such an eventuality should be explained beforehand to the patient, and the appropriate consent obtained.

Tumors located near the sacroiliac joints or pubic symphysis present a special problem in that positive margins of resection may occur unless the procedure is extended to the sacral ala or the contralateral side of the symphysis, respectively. Also, lesions medial to the pelvic bones may be adjacent to the neurovascular bundle and result in positive margins of excision. Induction chemotherapy may be useful to shrink these tumors prior to their surgical removal and thereby facilitate removal with more adequate resection margins.

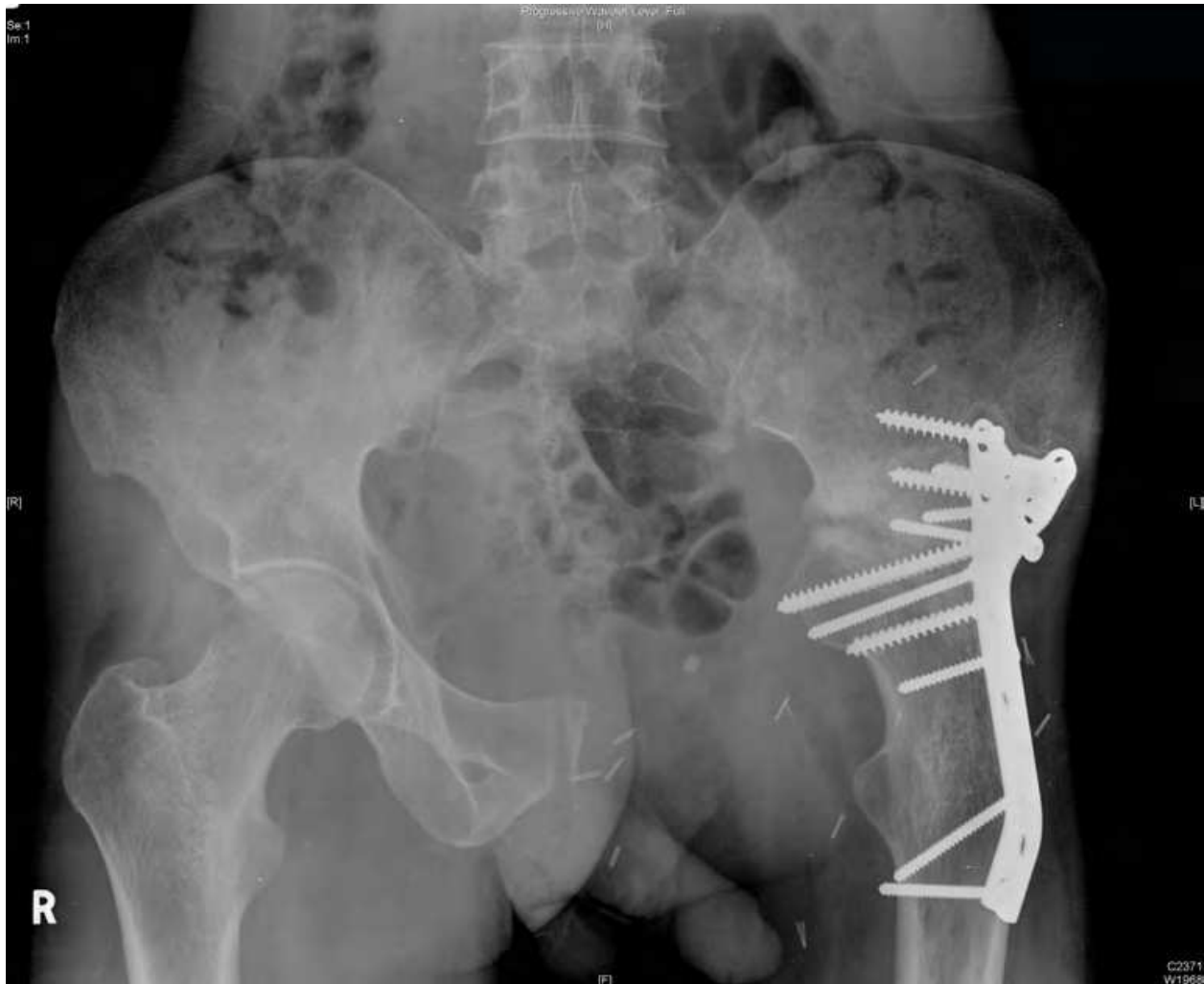


Fig. 12. An Iliofemoral fusion held with a distal femur condyle buttress plate. This is contoured to match the bone contour.

The incisions needed for each case may be different depending on the resection and reconstruction planned. A wrongly done biopsy is very likely to compromise the chance of limb salvage. It is therefore recommended that biopsy be best done by the surgeon who will be performing the final procedure.

In acetabulum involving resection without reconstruction, a 2-3" shortening of the ipsilateral extremity occurs. The patient has normal function at the ankle and knee joints, but no function at the hip area. As fibrosis occurs, these patients can walk in 6-9 months with help of some support like a crutch or walking stick. The functional results could be improved by stabilising the pelvis by reconstructing. Hip transposition (mesh pseudoarthrosis) has given acceptable results with lower complication rates than other methods like prosthesis and allografts.⁹³ Type II resections (periacetabular) have a better outcome with allograft and prosthesis composite as compared to more massive complete hemipelvic resections.⁹⁴ Saddle prosthesis provides better function than a hemipelvectomy but has a considerable complication rate.^{95, 96} Infection (37%), dislocation (22%), fractures (22%), and heterotopic ossification (37%) were the commonest reported complications.⁹⁷ Vertical migration has been noted in some cases. Pelvic allografts have been reported to give

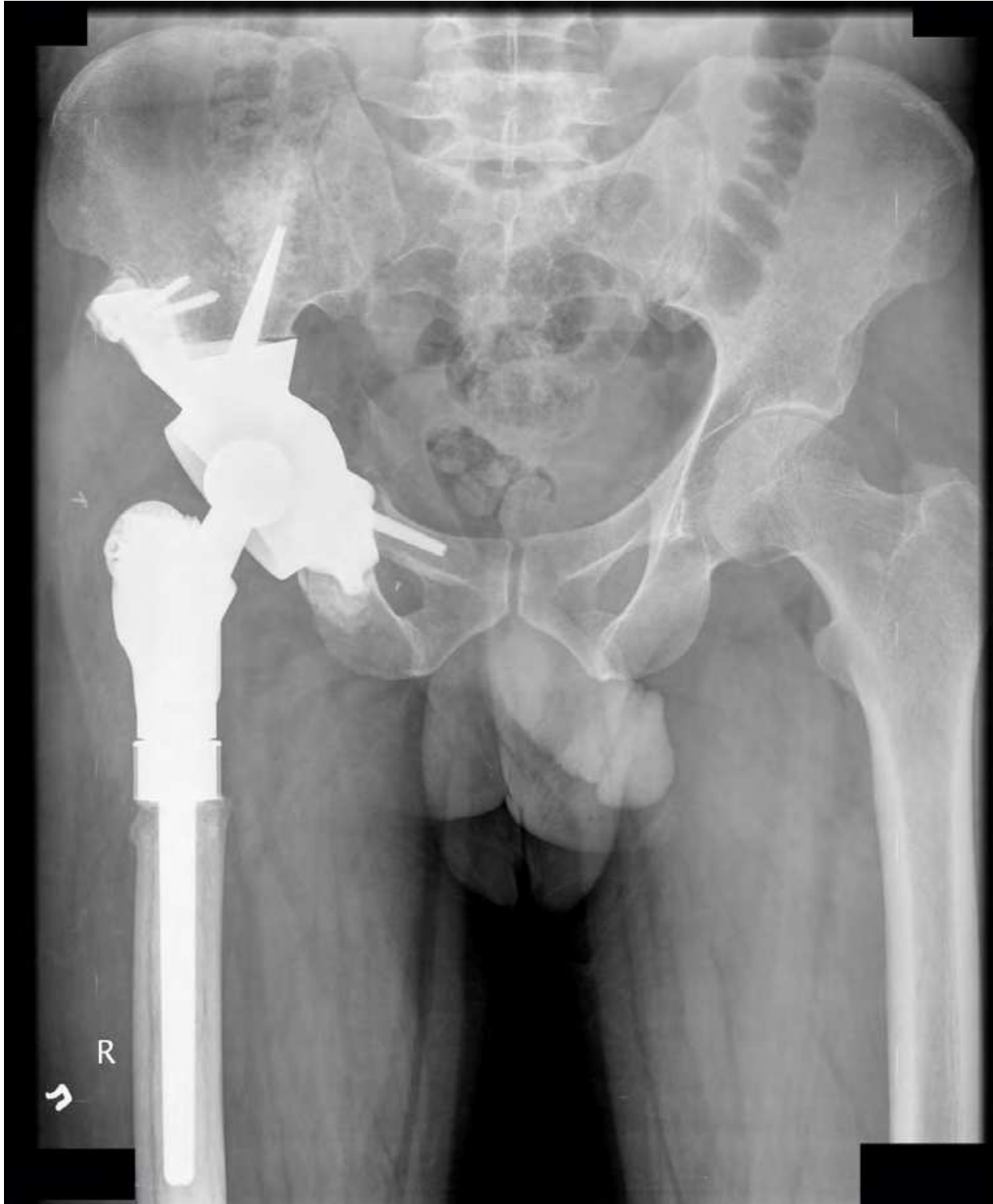

Fig. 13. Reconstruction after an extraarticular resection of the proximal femur. The acetabulum is reconstructed with a custom acetabular prosthesis and femur with a modular proximal femoral megaprosthesis (ISQU Orthopaedics, Capetown, South Africa). The acetabular prosthesis anchors into the posterior ilium, pubis and ischium with small stems which are cemented.

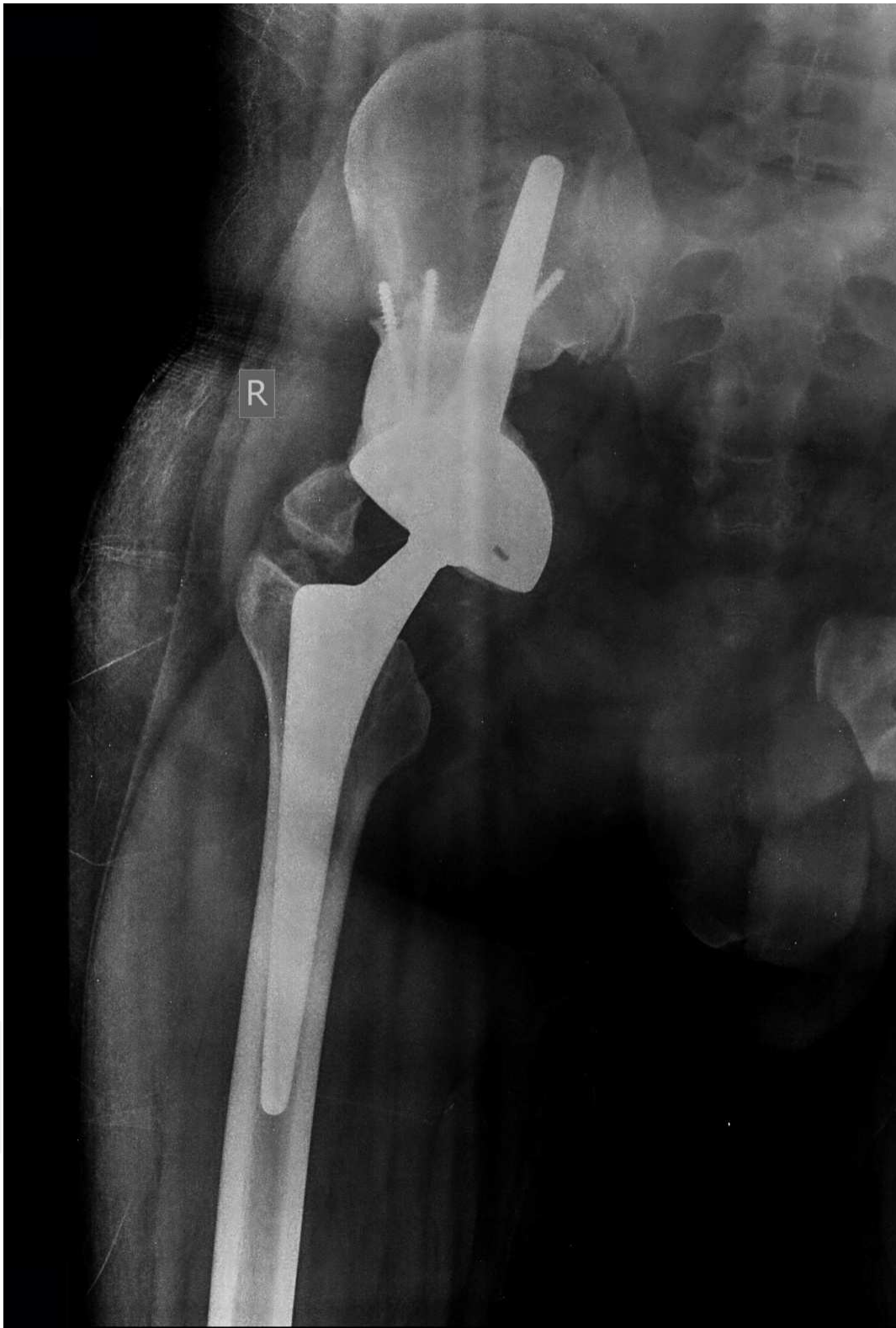

Fig. 14. Acetabulum reconstructed with a modular coned hemipelvic implant (Stanmore implants worldwide, UK). The stem is uncemented and fits into the thick posterior ilium remnant. Additional screws pass into the ilium and the defect is bridged with cement. An uncemented standard femoral component used in hip replacement surgery is placed in the proximal femur and mated to the cup with a constrained liner.

good functional results though the complication rate has been high.⁹⁷ Nonunion, infection and local recurrence were the commonest complications.⁹⁷ Custom or modular acetabular prosthesis have also been used with satisfactory functional results in some reports^{98,99,100} and poor results in others.¹⁰¹ Similarly custom or modular hemipelvic prosthesis have been reported with poor¹⁰¹ or satisfactory results.¹⁰²

Complication rates in various series varies from 42-65%. Infection and local recurrence are the biggest complications. Injury to NV bundle, ureter, bladder & rectum are the other complications described. Injury to the sciatic nerve would severely compromise the functional result. Sciatic and femoral nerve palsies have been reported frequently after pelvic resections and reconstructions.^{93, 95, 97}

We have preferred to use either modular coned hemipelvis (fig 14) from Stanmore implants or extracorporeal irradiation and reimplantation with or without a hip prosthesis. Wherever enough bone stock is present, an arthrodesis like iliofemoral or ischiofemoral fusion is used.(fig 12)

9. Conclusions

The first decade of the new millennium has been globally recognized by the orthopaedic fraternity as the decade of improvements in the treatment of bone and joint disorders. An ideal situation in the management of bone tumors is when the disease can be successfully removed without an amputation and the resulting loss of bone and muscle compensated by a method which retains near normal limb function. Patient survivals have dramatically improved following the availability of newer chemotherapy drugs and this has accentuated the need for durable methods of reconstruction of large musculoskeletal defects. Orthopaedic surgeons have risen to the challenge and it is now possible to offer limb salvage to a large majority of patients with bone tumors. Ever increasing advances in technology and biomaterials combined with a better understanding of biomechanics will further help in increasing the durability of and refining limb salvage procedures.

10. References

- [1] Dahlin DC, Coventry MB : Osteosarcoma - a study of 600 cases. J Bone Joint Surg 49A:101-110.1967.
- [2] Marcove RC, Mike V, Hajeh JV, et al : Osteosarcoma under the age of twenty one: A review of one hundred and forty five operative cases. J Bone Joint Surg 52: 411-423, 1970
- [3] Huth JF, Eilber FR : Patterns of recurrence after resection of osteosarcoma of the extremity: strategies for treatment of metastases. Arch Surg 124: 122-126, 1989.
- [4] Bacci G, Avella M, Picci P et al: Metastatic patterns in osteosarcoma. Tumori 74:421-427,1988.
- [5] Link MP, Goorin AM, Miser AW et al : The effect of adjuvant chemotherapy on relapse free survival in patients with osteosarcoma of the extremity. New Eng J Med 314(25): 1600-1606.1986.
- [6] Eilber F, Giuliano A, EckhardtJ et al: Adjuvant chemotherapy for osteosarcoma: a randomized prospective trial. J. Clin. Oncol.5(1): 21-26,1987.

- [7] Meyers PA, Heller G, Healy J et al :Chemotherapy for non-metastatic osteogenic sarcoma: the Memorial Sloan-Kettering experience : J. Clin. Oncol. 10(11): 5-15,1992.
- [8] Baci G, Ferrari S, Bertoni F, Ruggieri P et al : Long term outcome for patients with non-metastatic osteosarcoma of the extremity treatment at the istituto ortopedico Rizzoli according to the istituto ortopedico Rizzoli / osteosarcoma-2 protocol: an updated report. J. Clin. Oncol. 2000 Dec 15;18(24):4016-27.
- [9] Sim, F. H.; Ivins, J. C.; Taylor, W. F.; and Chao, E. Y. S.: Limb-Sparing Surgery for Osteosarcoma: Mayo Clinic Experience. Cancer Treat. Sympos., 3: 139-154, 1985.
- [10] Lane, J. M.; Glasser, D. B.; Duane, Karen; Healey, J. H.; McCormack, R. R., Jr.; Rosen, Gerald; Sison, Brenda; Huvos, A. G.; Marcove, R. C.; and Cammisa, F. P., Jr.: Osteogenic Sarcoma: Two Hundred Thirty-three Consecutive Patients Treated with Neoadjuvant Chemotherapy. Orthop. Trans., 11: 495, 1987.
- [11] Goorin, A. M.; Perez-Atayde, Antonio; Gebhardt, Mark; Andersen, J. W.; Wilkinson, R. H.; Delorey, M. J.; Watts, Hugh; Link, Michael; Jaffe, Norman; Frei, Emil, III; and Abelson, H. T.: Weekly High-Dose Methotrexate and Doxorubicin for Osteosarcoma: The Dana-Farber Cancer Institute/The Children's Hospital -- Study III. J. Clin. Oncol., 5: 1178-1184, 1987.
- [12] Simon, M. A.; Aschliman, M. A.; Thomas, Neal; and Mankin, H. J.: Limb-Salvage Treatment versus Amputation for Osteosarcoma of the Distal End of the Femur. J. Bone and Joint Surg., 68-A: 1331-1337, Dec. 1986.
- [13] Winkler, K.; Beron, G.; Kotz, R.; Salzer-Kuntschik, M.; Beck, J.; Beck, W.; Brandeis, W.; Ebell, W.; Erttmann, R.; Gobel, U.; Havers, W.; Henze, G.; Hinderfeld, L.; Hocker, P.; Jobke, A.; Jurgens, H.; Kabisch, H.; Preusser, P.; Prindull, G.; Ramach, W.; Ritter, J.; Sekera, J.; Treuner, J.; Wust, G.; and Landbeck, G.: Neoadjuvant Chemotherapy for Osteogenic Sarcoma. Results of a Cooperative German/Austrian Study. J. Clin. Oncol., 2: 617-624,1984.
- [14] Rougraff, B. T., Simon, M. A., Kneisl, J. S., Greenberg, D. B., and Mankin, H. J. : Limb salvage compared with amputation for osteosarcoma of the distal end of the femur. A long-term oncological, functional, and quality-of-life study : J Bone Joint Surg vol. 76-a, no. 5, may 1994, pp. 649-656
- [15] Van der Bijl AE, Taminiau AHM, Hermans J, Beerman H and Hogendoorn PCW. Accuracy of the Jamshidi trocar biopsy in the diagnosis of bone tumors. Clin Ortho Rel Res 1997; 334: 233-43.
- [16] Bickels J, Jelinek JS, Shmookler BM, Neff RS and Malawer MM. Biopsy of musculoskeletal tumors. Clin Ortho Rel Res 1999; 368: 212-9.
- [17] Mankin, Henry J., Mankin, Carole J., Simon, Michael A. : The Hazards of the Biopsy, Revisited. J Bone Joint Surg [Am] 1996; 78-A; 656-63
- [18] Mankin, H. J.; Lange, T. A.; and Spanier, S. S.: The hazards of biopsy in patients with malignant primary bone and soft-tissue tumors. J Bone Joint Surg., 64-A: 1121-1127, Oct. 1982.
- [19] Enneking, W. F.: The issue of the biopsy [editorial]. J. Bone and Joint Surg., 64-A: 1119-1120, Oct. 1982.
- [20] Simon, M. A.: Current concepts review. Biopsy of musculoskeletal tumors. J. Bone and Joint Surg., 64-A: 1253-1257, Oct. 1982.
- [21] Springfield DS, Rosenberg A. Biopsy: complicated and risky [editorial; comment]. J Bone Joint Surg [Am] 1996;78-A(S) :639 – 43.

- [22] Fraser-Hill MA, Renfrew DL. Percutaneous needle biopsy of musculoskeletal lesions. 1. Effective accuracy and diagnostic utility. *AJR* 158: 809-812, Apr 1992.
- [23] Ayala AG, Zomosa J. Primary Bone tumours: Percutaneous needle biopsy-radiologic-pathologic study of 222 biopsies. *Radiology* 1983; 149: 675-679.
- [24] Picci P, Sangiorgi L, Rougraff BT, Neff JR, et al : Relationship of Chemotherapy induced necrosis and surgical margins to Local recurrence in Osteosarcoma. *J Clin Oncol* Vol 12 No 12, 1994, pp2699-2705.
- [25] Wolf RE, Enneking WF. The staging and surgery of musculoskeletal neoplasms. *Orthop Clin N Am* 1996;27(3) :473 – 81.
- [26] Ward WG, Yang R-S, Eckardt JJ. Endoprosthetic bone reconstruction following malignant tumor resection in skeletally immature patients. *Orthop Clin N Am* 1996;27(3) :493 – 502.31
- [27] Agarwal M, Puri A, Gulia A, Reddy K. Joint-sparing or Physeal-sparing Diaphyseal Resections: The Challenge of Holding Small Fragments. *Clin Orthop Relat Res.* 2010 Nov;468(11):2924-32.
- [28] Agarwal M, Puri A, Anchan C et al. Hemicortical Excision for Low-grade Selected Surface Sarcomas of Bone. *Clin Orthop Relat Res.*2007 Jun;459: 161-166
- [29] Myers GJ, Abudu AT, Carter SR, et al. Endoprosthetic replacement of the distal femur for bone tumours: LONG-TERM RESULTS. *J Bone Joint Surg Br.* 2007 Apr;89(4):521-6.
- [30] De Wilde LF, Plasschaert FS, Audenaert EA, Verdonk RC. Functional recovery after a reverse prosthesis for reconstruction of the proximal humerus in tumor surgery. *Clin Orthop Relat Res.* 2005 Jan;(430):156-62.
- [31] Pritsch T, Bickels J, Wu CC, et al. Is A Scapular Endoprosthesis Functionally Superior to Humeral Suspension? *Clin Orthop Relat Res.* 2006 Sep 21
- [32] Frink SJ, Rutledge J, Lewis VO, et al. Favorable long-term results of prosthetic arthroplasty of the knee for distal femur neoplasms. *Clin Orthop Relat Res.* 2005 Sep;438:65-70.
- [33] Agarwal MG, Gulia A, Ravi B, Ghayyar R, Puri A.: Revision of Broken Knee Megaprotheses: New Solution to Old Problems. *Clin Orthop Relat Res.* 2010 Nov;468(11):2904-13.
- [34] Abudu A, Grimer R, Tillman R, Carter S. The use of prostheses in skeletally immature patients. *Orthop Clin North Am.* 2006 Jan;37(1):75-84.
- [35] Gupta A, Meswania J, Pollock R, et al. Non-invasive distal femoral expandable endoprosthesis for limb-salvage surgery in paediatric tumours. *J Bone Joint Surg Br.* 2006 May;88(5):649-54.
- [36] Aisen AM, Martel W, Braunstein EM, et al: MRI and CT evaluation of primary bone and soft-tissue tumors. *Am J Roentgenol* 146:749-756, 1986.
- [37] Cohen MD, Weetman RM, Provisor AJ, et al: Efficacy of magnetic resonance imaging in 139 children with tumors. *Arch Surg* 121:522-529, 1986.
- [38] Gillespy T, Manfrini M, Ruggieri P, et al: Staging of intraosseous extent of osteosarcoma: Correlation of preoperative CT and MR imaging with pathologic macroslices. *Radiology* 167:765-767, 1988.
- [39] Golfieri R, Baddeley H, Pringle JS, et al: MRI in primary bone tumors: Therapeutic implications. *Eur J Radiol* 12:201-207, 1991.

- [40] O'Flanagan SJ, Stack JP, McGee HMJ, et al: Imaging of intramedullary tumour spread in osteosarcoma: A comparison of techniques. *J Bone Joint Surg* 73B:998-1001, 1991.
- [41] Onikul E, Fletcher BD, Parham DM, et al: Accuracy of MR imaging for estimating intraosseous extent of osteosarcoma. *Am J Roentgenol* 167:1211-1215, 1996.
- [42] Mankin, H. J.; Gebhardt, M. C.; Jennings, L. C.; Springfield, D.S.; and Tomford, W. W.: Long-term results of allograft replacement in the management of bone tumors. *Clin. Orthop.*, 324: 86-97, 1996.
- [43] Donald S. Garbuz, Bassam A. Masri, Andrei A. Czitrom : Biology of allografting: *Orthop Clin North Am* Volume 29 • Number 2 • April 1998pp199-204
- [44] Enneking, WF. and Campanacci DA., Retrieved Human Allografts A Clinicopathological Study *J Bone Joint Surg(A)* 83:971-986 (2001)
- [45] Hornicek FJ, Gebhardt MC, Sorger JI, Mankin HJ : Bone Graft Substitutes: Clinical Applications-Tumor Reconstruction: *Orthopedic Clinics of North America* Volume 30 • Number 4 • October 1999
- [46] Ortiz-Cruz, E., Gebhardt, M. C., Jennings, L. C., Springfield, D. S, and Mankin, H. J: The Results Of Transplantation Of Intercalary Allografts After Resection Of Tumors. A Long-Term Follow-Up Study: *J Bone Joint Surg* 79-a, no. 1, january 1997, pp. 97-106
- [47] Berrey, B. H., Jr.; Lord, C. F.; Gebhardt, M. C.; and Mankin, H. J.: Fractures of allografts. Frequency, treatment, and end-results. *J. Bone and Joint Surg.*, 72-A: 825-833, July 1990.
- [48] Muscolo, D. L.; Petracchi, L. J.; Ayerza, M. A.; and Calabrese, M. E.: Massive femoral allografts followed for 22 to 36 years. Report of six cases. *J. Bone and Joint Surg.*, 74-B(6): 887-892, 1992.
- [49] Thompson RC Jr; Garg A; Clohisy DR; Cheng EY: Fractures in Large Segment Allografts. *Clin Orthop* 2000.;370:227-235.
- [50] Hazan EJ, Hornicek FJ, Tomford W, Gebhardt MC, Mankin HJ : The effect of adjuvant chemotherapy on osteoarticular allografts. *Clin Orthop* 2001 Apr;(385):176-81
- [51] Hornicek FJ, Gebhardt MC, Tomford WW, Sorger JI, Zavatta M, Menzner JP, Mankin HJ.: Factors affecting nonunion of the allograft-host junction. *Clin Orthop* 2001 Jan;(382):87-98
- [52] Sorger JI, Hornicek FJ, Zavatta M, Menzner JP, Gebhardt MC, Tomford WW, Mankin HJ: Allograft fractures revisited: *Clin Orthop* 2001 Jan;(382):66-74
- [53] Donati D, Giacomini S, Gozzi E, et al. Allograft arthrodesis treatment of bone tumors: a two-center study. *Clin Orthop* 2002;400:217- 24.
- [54] Muscolo DL, Ayerza MA, Aponte-Tinao LA. Massive allograft use in orthopedic oncology. *Orthop Clin North Am.* 2006 Jan;37(1):65-74.
- [55] Vidyadhara S, Rao SK. Techniques in the management of juxta-articular aggressive and recurrent giant cell tumors around the knee. *Eur J Surg Oncol.* 2007 Mar;33(2):243-51.
- [56] Harris, I. E., Leff, A. R., Gitelis, S., Simon, M. A. Function after amputation, arthrodesis, or arthroplasty for tumors about the knee. *J Bone Joint Surg* VOL. 72-A, No. 10, December 1990, pp. 1477-1485.
- [57] Van Nes. C.P.: Rotationplasty for congenital defects of the femur. Making use of the ankle of the shortened limb to control the knee joint of a prosthesis. *JBJS.*, 32-B(1): 12-16, 1950.

- [58] Kotz R., Salzer M.: Rotationplasty for childhood osteosarcoma of the distal part of the femur. *JBJS.*, 64-A., 7:959, 1982.
- [59] Fuchs B, Kotajarvi BR, Kaufman KR, Sim FH. Functional outcome of patients with rotationplasty about the knee. *Clin Orthop Relat Res.* 2003;415:52-58.
- [60] Hillmann A, Hoffmann C, Gosheger G, et al. Malignant tumor of the distal part of the femur or the proximal part of the tibia: endoprosthetic replacement or rotationplasty: functional outcome and quality-of-life measurements. *J Bone Joint Surg Am.* 1999;81:462-468.
- [61] Hillmann A, Rosenbaum D, Schroter J, et al. Electromyographic and gait analysis of forty-three patients after rotationplasty. *J Bone Joint Surg Am.* 2000;82:187-196.
- [62] Ginsberg JP, Rai SN, Carlson CA, et al. A comparative analysis of functional outcomes in adolescents and young adults with lower-extremity bone sarcoma. *Pediatr Blood Cancer.* 2006 Aug 18; [Epub ahead of print]
- [63] Hopyan S, Tan JW, Graham HK, Torode IP. Function and upright time following limb salvage, amputation, and rotationplasty for pediatric sarcoma of bone. *J Pediatr Orthop.* 2006 May-Jun;26(3):405-8.
- [64] Akahane T, Shimizu T, Isobe K, et al. Evaluation of postoperative general quality of life for patients with osteosarcoma around the knee joint. *J Pediatr Orthop B.* 2007 Jul;16(4):269-272.
- [65] Agarwal M, Puri A, Anchan C, et al. Rotationplasty for Bone Tumors: Is There Still a Role? *Clin Orthop Relat Res.* 2007 Jun;459: 76-81
- [66] Puri A, Agarwal M. Facilitating rotationplasty. *J Surg Oncol.* 2007 Mar 15;95(4):351-4.
- [67] Gebert C, Harges J, Vieth V, et al. The effect of rotationplasty on the ankle joint: long-term results. *Prosthet Orthot Int.* 2006 Dec;30(3):316-23.
- [68] Deijkers RL, Bloem RM, Kroon HM et al. Epidiaphyseal versus other intercalary allografts for tumors of the lower limb. *Clin Orthop Relat Res.* 2005 Oct;439:151-60.
- [69] Chen CM, Disa JJ, Lee HY et al. Reconstruction of extremity long bone defects after sarcoma resection with vascularized fibula flaps: a 10-year review. *Plast Reconstr Surg.* 2007 Mar;119(3):915-24
- [70] Pederson WC, Person DW. Long bone reconstruction with vascularized bone grafts. *Orthop Clin North Am.* 2007 Jan;38(1):23-35
- [71] Krieg AH, Hefti F. Reconstruction with non-vascularised fibular grafts after resection of bone tumours. *J Bone Joint Surg Br.* 2007 Feb;89-B(2):215-221.
- [72] Capanna R, Campanacci DA, Belot N, et al. A new reconstructive technique for intercalary defects of long bones: the association of massive allograft with vascularized fibular autograft. Long-term results and comparison with alternative techniques. *Orthop Clin North Am.* 2007 Jan;38(1):51-60.
- [73] Moran SL, Shin AY, Bishop AT. The use of massive bone allograft with intramedullary free fibular flap for limb salvage in a pediatric and adolescent population. *Plast Reconstr Surg.* 2006 Aug;118(2):413-9.
- [74] Khattak MJ, Umer M, Haroon-ur-Rasheed, Umar M. Autoclaved tumor bone for reconstruction: an alternative in developing countries. *Clin Orthop Relat Res.* 2006 Jun;447:138-44.
- [75] Yamamoto N, Tsuchiya H, Nojima T et al. Histological and radiological analysis of autoclaved bone 2 years after extirpation. *J Orthop Sci.* 2003;8(1):16-9

- [76] Taguchi S, Namikawa T, Ieguchi M, Takaoka K. Reconstruction of Bone Defects Using rhBMP-2-coated Devitalized Bone. *Clin Orthop Relat Res.* 2007 Mar 22; [Epub ahead of print]
- [77] Draenert GF, Delius M. The mechanically stable steam sterilization of bone grafts. *Biomaterials.* 2007 Mar;28(8):1531-8.
- [78] Jeon DG, Kim MS, Cho WH et al. Pasteurized Autograft for Intercalary Reconstruction: An Alternative to Allograft. *Clin Orthop Relat Res.* 2006 456:203-210
- [79] Manabe J, Ahmed AR, Kawaguchi N, et al. Pasteurized autologous bone graft in surgery for bone and soft tissue sarcoma. *Clin Orthop Relat Res.* 2004 Feb;(419):258-66.
- [80] Tsuchiya H, Wan S L, Sakayama K et al. Reconstruction using an autograft containing tumour treated by liquid nitrogen. *J Bone Joint Surg [Br]*2005;87-B:218-25
- [81] Davidson AW, Hong A, McCarthy SW, Stalley PD. En-bloc resection, extracorporeal irradiation, and re-implantation in limb salvage for bony malignancies. *J Bone Joint Surg Br.* 2005 Jun;87(6):851-7.
- [82] Chen TH, Chen WM, Huang CK. Reconstruction after intercalary resection of malignant bone tumours: comparison between segmental allograft and extracorporeally-irradiated autograft. *J Bone Joint Surg Br.* 2005 May;87(5):704-9.
- [83] Hatano H, Ogose A, Hotta T et al. Extracorporeal irradiated autogenous osteochondral graft: a histological study. *J Bone Joint Surg Br.* 2005 Jul;87(7):1006-11.
- [84] Muramatsu K, Ihara K, Hashimoto T, et al. Combined use of free vascularised bone graft and extracorporeally-irradiated autograft for the reconstruction of massive bone defects after resection of malignant tumour. *J Plast Reconstr Aesthet Surg.* 2007 May 9.
- [85] Ahlmann ER, Menendez LR. Intercalary endoprosthetic reconstruction for diaphyseal bone tumours. *J Bone Joint Surg Br.* 2006 Nov;88(11):1487-91.
- [86] Aldlyami E, Abudu A, Grimer RJ, et al. Endoprosthetic replacement of diaphyseal bone defects. Long-term results. *Int Orthop.* 2005 Feb;29(1):25-9.
- [87] Gupta A, Pollock R, Cannon SR, et al. A knee-sparing distal femoral endoprosthesis using hydroxyapatite-coated extracortical plates. Preliminary results. *J Bone Joint Surg Br.* 2006 Oct;88(10):1367-72.
- [88] Ozaki T, Flege S, Kevric M, Lindner N, Maas R, Dellling G, Schwarz R, von Hochstetter AR, Salzer-Kuntschik M, Berdel WE, Jürgens H, Exner GU, Reichardt P, Mayer-Steinacker R, Ewerbeck V, Kotz R, Winkelmann W, Bielack SS. Osteosarcoma of the pelvis: experience of the Cooperative Osteosarcoma Study Group. *J Clin Oncol.*2003 Jan 15;21(2):334-41.
- [89] Isakoff MS, Barkauskas DA, Ebb D, Morris C, Letson GD. Poor Survival for Osteosarcoma of the Pelvis: A Report from the Children's Oncology Group. *Clin Orthop Relat Res.* 2012 Feb 22. [Epub ahead of print]
- [90] Grimer RJ, Carter SR, Tillman RM, Spooner D, Mangham DC, Kabukcuoglu Y. Osteosarcoma of the pelvis. *J Bone Joint Surg Br.* 1999 Sep;81(5):796-802.
- [91] Song WS, Cho WH, Jeon DG, Kong CB, Kim MS, Lee JA, Eid AS, Kim JD, Lee SY. Pelvis and extremity osteosarcoma with similar tumor volume have an equivalent survival. *J Surg Oncol.* 2010 Jun 1;101(7):611-7.
- [92] Hugate R Jr, Sim FH. Pelvic reconstruction techniques. *Orthop Clin North Am.* 2006 Jan;37(1):85-97

- [93] Hoffmann C, Gosheger G, Gebert C, et al. Functional results and quality of life after treatment of pelvic sarcomas involving the acetabulum. *J Bone Joint Surg Am*. 2006 Mar;88(3):575-82.
- [94] Beadel GP, McLaughlin CE, Wunder JS, et al. Outcome in two groups of patients with allograft-prosthetic reconstruction of pelvic tumor defects. *Clin Orthop Relat Res*. 2005 Sep;438:30-5.
- [95] Aljassir F, Beadel GP, Turcotte RE, et al. Outcome after pelvic sarcoma resection reconstructed with saddle prosthesis. *Clin Orthop Relat Res*. 2005 Sep;438:36-41.
- [96] Kitagawa Y, Ek ET, Choong PF. Pelvic reconstruction using saddle prosthesis following limb salvage operation for periacetabular tumour. *J Orthop Surg (Hong Kong)*. 2006 Aug;14(2):155-62
- [97] Delloye C, Banse X, Brichard B, et al. Pelvic reconstruction with a structural pelvic allograft after resection of a malignant bone tumor. *J Bone Joint Surg Am*. 2007 Mar;89(3):579-87
- [98] Abudu A, Grimer RJ, Cannon SR, Carter SR, Sneath RS. Reconstruction of the hemipelvis after the excision of malignant tumours. Complications and functional outcome of prostheses. *J Bone Joint Surg Br*. 1997 Sep;79(5):773-9
- [99] Müller PE, Dürr HR, Wegener B, Pellengahr C, Refior HJ, Jansson V. Internal hemipelvectomy and reconstruction with a megaprosthesis. *Int Orthop*. 2002;26(2):76-9.
- [100] Dai KR, Yan MN, Zhu ZA, Sun YH. Computer-aided custom-made hemipelvic prosthesis used in extensive pelvic lesions. *J Arthroplasty*. 2007 Oct;22(7):981-6.
- [101] Ozaki T, Hoffmann C, Hillmann A, Gosheger G, Lindner N, Winkelmann W. Implantation of hemipelvic prosthesis after resection of sarcoma. *Clin Orthop Relat Res*. 2002 Mar;(396):197-205.
- [102] Guo W, Li D, Tang X, Yang Y, Ji T. Reconstruction With Modular Hemipelvic Prostheses For Periacetabular Tumor. *Clin Orthop Relat Res*. 2007 Apr 19;

IntechOpen



Osteosarcoma

Edited by Dr. Manish Agarwal

ISBN 978-953-51-0506-0

Hard cover, 174 pages

Publisher InTech

Published online 11, April, 2012

Published in print edition April, 2012

This book is aimed at quickly updating the reader on osteosarcoma, a dreaded primary bone cancer. Progress in management of osteosarcoma has been slow after the evolution of chemotherapy and limb salvage surgery. Research is now directed towards identifying molecular targets for systemic therapy. Availability of chemotherapy drugs and low cost implants in developing world have allowed limb salvage surgery to develop. This book looks at current basic knowledge on osteosarcoma and some of the developments in research which have the potential to change the prognosis.

How to reference

In order to correctly reference this scholarly work, feel free to copy and paste the following:

Manish G. Agarwal and Prakash Nayak (2012). Limb Salvage for Osteosarcoma: Current Status with a Review of Literature, Osteosarcoma, Dr. Manish Agarwal (Ed.), ISBN: 978-953-51-0506-0, InTech, Available from: <http://www.intechopen.com/books/osteosarcoma/limb-salvage-in-osteosarcoma>

INTECH
open science | open minds

InTech Europe

University Campus STeP Ri
Slavka Krautzeka 83/A
51000 Rijeka, Croatia
Phone: +385 (51) 770 447
Fax: +385 (51) 686 166
www.intechopen.com

InTech China

Unit 405, Office Block, Hotel Equatorial Shanghai
No.65, Yan An Road (West), Shanghai, 200040, China
中国上海市延安西路65号上海国际贵都大饭店办公楼405单元
Phone: +86-21-62489820
Fax: +86-21-62489821

© 2012 The Author(s). Licensee IntechOpen. This is an open access article distributed under the terms of the [Creative Commons Attribution 3.0 License](#), which permits unrestricted use, distribution, and reproduction in any medium, provided the original work is properly cited.

IntechOpen

IntechOpen