

We are IntechOpen, the world's leading publisher of Open Access books Built by scientists, for scientists

4,800

Open access books available

122,000

International authors and editors

135M

Downloads

Our authors are among the

154

Countries delivered to

TOP 1%

most cited scientists

12.2%

Contributors from top 500 universities



WEB OF SCIENCE™

Selection of our books indexed in the Book Citation Index
in Web of Science™ Core Collection (BKCI)

Interested in publishing with us?
Contact book.department@intechopen.com

Numbers displayed above are based on latest data collected.
For more information visit www.intechopen.com



A Review of Non-Invasive Treatment Interventions for Spinal Deformities

Clare Lewis

*California State University, Sacramento,
USA*

1. Introduction

Spinal deformities of the scoliotic type, affect approximately 2% of the population.¹ When an individual has an s-shaped curve of greater than 20 degrees, treatment is usually indicated. For curves that are not (severe is defined as greater than 45 degrees; requiring surgery) various physical therapy treatment interventions are often tried. These include Electrical muscle stimulation, bracing, exercise programs, and manipulation. All of these interventions are considered conservative treatments that have been commonly used to treat scoliosis.²⁻⁴ The impact of various interventions has been scrutinized in the literature, and their outcomes have been found to have variable levels of effectiveness.³ In addition to the physical impact of scoliosis, the emotional impact of scoliosis must also be addressed since having scoliosis will often dramatically affect a patient's self-image, which in turn can impact their perceived pain levels. Ultimately, scoliosis can result in a number of secondary impairments, which if left untreated, can be severe.^{5,6}

A new conservative treatment device for scoliosis that has recently been written about in the literature is the ATM2™ (active therapeutic movements version 2).⁷ The ATM2™ is a vertical treatment table; a concept that was developed by a physical therapist trained in "Mulligan Techniques" (Mobilization with Movement).⁸ Clinical evidence has been documented for the efficacy of the ATM2™ when used with patients who have types and causes low back pain, hip problems, shoulder problems and cervical problems. The ATM2™ was found to be effective in helping to reverse the curves in a patient with scoliosis who was actually being treated for a frozen shoulder in a recently published case study.⁷ Since this publication, continued study has been undertaken to determine if the ATM2™ is effective in treating mild to moderate scoliosis, particularly its effectiveness in reversing the curves of subjects with scoliosis.

This chapter will review traditional non-invasive physical therapy interventions for scoliosis. It will discuss the effectiveness or lack thereof of exercises, manipulation, bracing, and electrical stimulation. It will introduce the ATM2™ as a new intervention for mild to moderate scoliosis and discuss published research thus far along with ongoing research currently being conducted.

2. Background: Types, causes and diagnosis of scoliosis

2.1 Definition of scoliosis

Scoliosis is used to describe an abnormal curvature of the spine, but it is not in itself a disease or a diagnosis. The curvature of the spine from scoliosis is easily seen as a deviation on the frontal plane and may develop as a single curve (shaped like the letter C) or as two curves (shaped like the letter S).

2.2 Types and causes of scoliosis

Scoliosis usually develops in the upper back (thoracic spine) or area between the upper back and lower back (the thoracolumbar area of the spine). It may also occur only in the lower back (lumbar spine). Scoliosis can be caused by congenital, developmental or degenerative problems, but most cases of scoliosis have no known cause, and are considered to be idiopathic scoliosis. While there are many forms of scoliosis, four of the most common ones include:

- Congenital scoliosis. This is a relatively rare form of congenital malformation of the spine. Patients with congenital scoliosis will often develop scoliotic deformities in their infancy.
- Neuromuscular scoliosis. This may occur when the spine curves laterally due to weakness of the spinal muscles or from other neurologic problems. This form of scoliosis is especially common for individuals who cannot walk due to their underlying neuromuscular condition and are confined to a wheelchair for locomotion (such as muscular dystrophy or cerebral palsy). This may also be called *myopathic scoliosis*.
- Degenerative scoliosis. Scoliosis can also develop later in life, as joints in the spine degenerate and the intervertebral discs lose height, leading to a bending in the back. This condition is sometimes called *adult scoliosis*.
- Idiopathic scoliosis. By far the most common form of scoliosis is idiopathic scoliosis, which most often develops in adolescents and typically progresses during the adolescent growth spurt. Because it most often occurs during adolescence, this condition is sometimes called *adolescent scoliosis*.

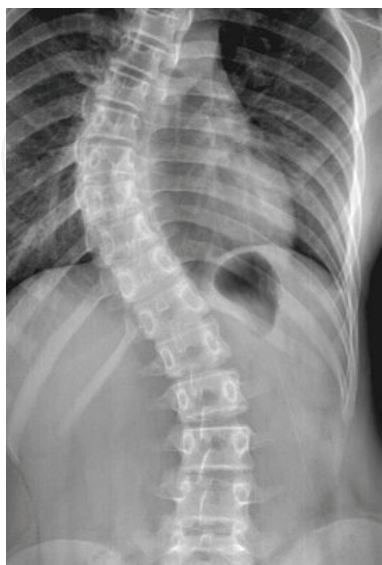

Fig. 1. Idiopathic Scoliosis

Idiopathic scoliosis occurs to some degree in approximately one half million adolescents in the US. There is no known cause of idiopathic scoliosis although it does tend to occur in families.

Idiopathic scoliosis is usually categorized into three age groups:

- From birth to 3 years old - called *infantile scoliosis*
- From 3 to 9 years old - called *juvenile scoliosis*.
- From 10 to 18 years old – called *adolescent scoliosis*.

This last category of scoliosis, which occurs from 10 to 18 years old, comprises approximately 80 percent of all cases of idiopathic scoliosis.

The risk of curvature progression is increased during puberty, when the growth rate of the body is the fastest. Scoliosis with significant curvature of the spine is much more prevalent in girls than in boys, and girls are eight times more likely to need treatment for scoliosis because they tend to have curves that are much more likely to progress. Still, the majority of all cases of scoliosis are mild and do not require treatment.

It is important to note that idiopathic scoliosis results in spinal deformity, and is not typically a cause of back pain. Of course, people with scoliosis can develop back pain, just as most of the adult population can. However, it has never been found that people with idiopathic scoliosis are any more likely to develop back pain than the rest of the population.⁹⁻¹¹

In children and teenagers, scoliosis often does not have any noticeable symptoms and scoliosis is often not noticeable until the curve has progressed significantly.

Scoliosis does not come from any types of sports involvement, the use of backpacks, sleeping positions, posture, or minor leg length differences.

When viewed from the side (in the sagittal plane), a healthy spine curves inward in the lower back (lordosis) and outward in the upper back (kyphosis). When viewed from the back (posteriorly), a spine with normal curves appears as a straight line down the back. A person with scoliosis however, will appear to have a lateral curve in their spine.

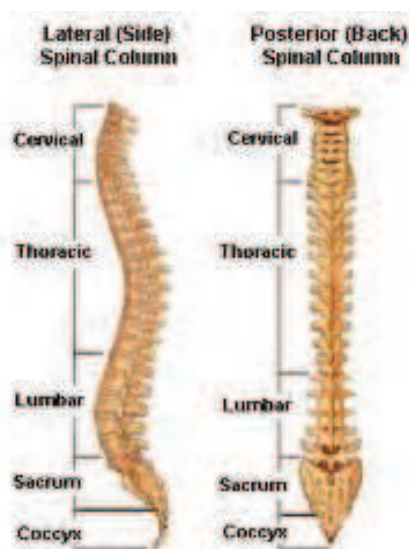

Fig. 2. Normal Spine

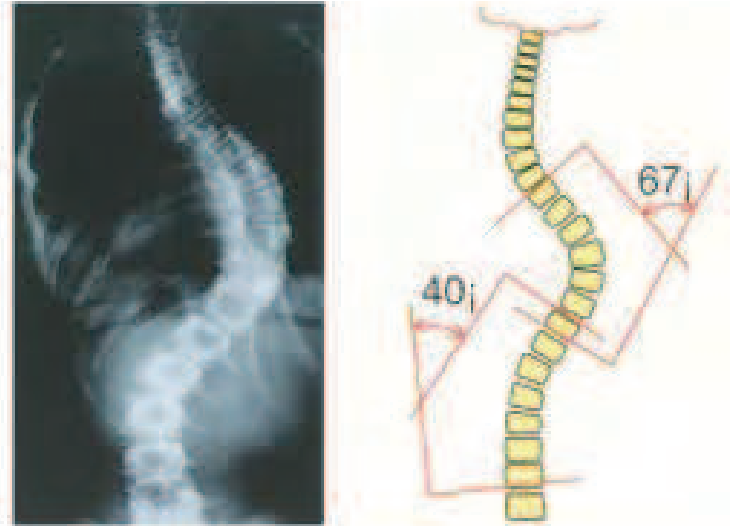


Fig. 3. Spine with Scoliosis

There are several common physical symptoms that may indicate scoliosis. Typically, symptoms of scoliosis may include one or several of the following:

- One shoulder is higher than the other
- One shoulder blade protrudes further than the other
- One side of the rib cage appears higher than the other
- One hip appears higher or more prominent than the other
- The waist appears uneven
- The body tilts to one side
- One leg may appear shorter than the other

Scoliosis Radiographs

The Cobb Method of angle measurement

1. Identify the upper and lower end vertebrae.

2. Draw lines extending along the vertebral borders.

3. Measure the Cobb Angle directly (a) or geometrically (b).

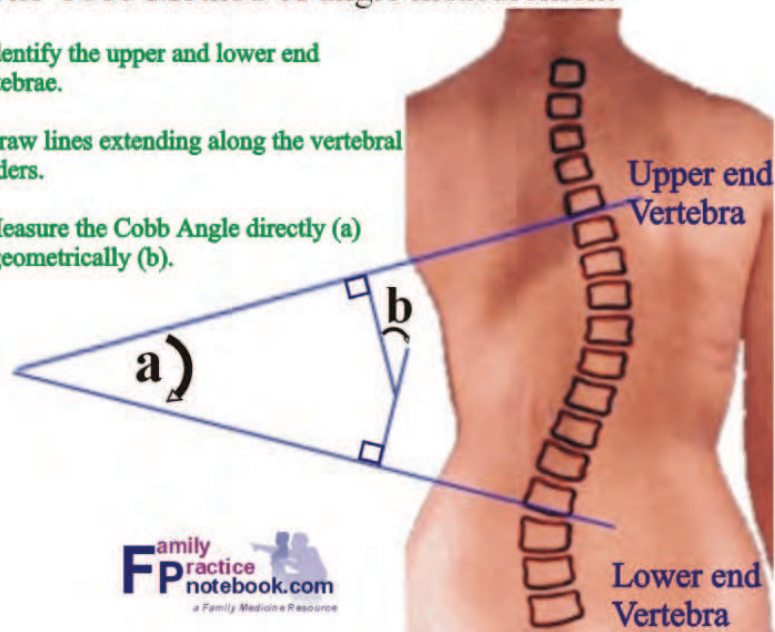


Fig. 4. Cobb Angle

As one can see by reviewing the list above, pain is not a typical symptom of scoliosis. Back pain in a child or teen who has scoliosis may indicate another problem, and the child should be evaluated by a paediatrician and/or spine specialist. If a child or teen has back pain and also has scoliosis, it is very important that he or she see a doctor to determine the cause of the pain, since it is probably something other than the scoliosis and therefore may require additional treatment. Note that neurologic injury is not included in the list above since it is a very rare presenting symptom in most cases of scoliosis.

Early detection is essential for scoliosis treatment to be most effective. In general, people with a family history of spinal deformity are at greater risk for developing scoliosis.

2.3 Diagnoses

Frequently, a scoliosis curve in the spine is first diagnosed in school exams or in a regular check up with a paediatrician. Most students are routinely given the *Adam's forward bend test* in school when they are in fifth and/or sixth grade to determine whether or not they may have scoliosis. The test involves the student bending forward with arms stretched downward toward the floor and knees straight, while being observed by a healthcare professional. This angle most clearly shows any asymmetry in the spine and/or trunk of the adolescent's body.

Because a scoliosis curvature is usually in the thoracic or thoracolumbar spine (upper back or mid back), if a rib hump or asymmetry of the lumbar spine is found, or if the shoulders are at different heights, it is possible that the individual has scoliosis. If this is the case, a follow-up with a physician for a clinical evaluation and an x-ray is the next step.

- Physician's exam. The clinical evaluation with the physician will usually include a physical exam, during which the physician will also test to make sure that there are no neurological deficits. Neurological deficits due to scoliosis are uncommon but it is still necessary to check, because there are rare causes of scoliosis that may have spinal cord involvement.
- X-ray. The x-ray is ordered to both confirm the scoliosis diagnosis and check on the magnitude of the spinal curvature. The x-ray will also give some indication of the skeletal maturity of the patient, which in turn may influence treatment decisions.

In rare instances a physician may also request an MRI scan of the thoracic and/or cervical spine. If there are any neurological deficits that would indicate impingement of the spinal cord (e.g. brisk reflex), if there is a left-sided thoracic curvature (they are almost always right sided), or if the child is very young (8 to 11 years old), an MRI scan is advisable to examine the possibility of an intracanal spinal lesion, which can cause scoliosis.

Depending on the results of the physician's clinical evaluation and the diagnostic tests, a scoliosis treatment plan may be recommended which may include observation, bracing, or possibly surgery to reduce or correct the spinal curve.⁹⁻¹³

2.4 Alternative to x-rays for diagnoses

The Formetric was invented in the 1980's to periodically evaluate the progress in scoliosis treatment without subjecting the patient to potentially harmful x-ray radiation. It has been widely used since 1996 in Germany, and other European countries by orthopedic doctors and surgeons. The Formetric is FDA approved and it works by using a harmless white light

to deliver a fast (40 milliseconds) high-definition optical measurement of the surface of the back to produce graphical, clinical, and analytical information on the spine. It does this and can be used to evaluate scoliosis both in and out of braces.¹⁴



Fig. 5. Formetric System for Scoliosis Measurement

Another non-X-ray method used to analyze the scoliotic curve is the ISIS (Integrated Shape Imaging System). This technique uses structured light to illuminate a patient's back from an angle while a digital photograph is taken. The height of the surface is calculated using Fourier transform profilometry with an accuracy of ± 1 mm. The surface is related to body axes using bony landmarks on the back that have been palpated and marked with small colored stickers prior to photographing.¹⁴

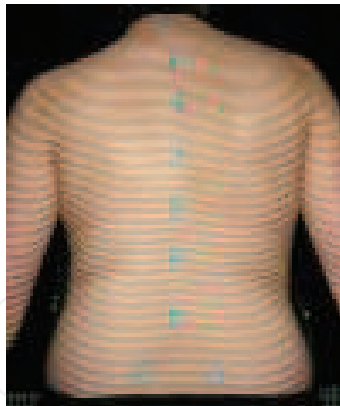

Fig. 6. ISIS

3. Scoliosis treatment

Decisions for scoliosis treatment are primarily based on two factors:

- The *skeletal maturity of the patient* (or rather, how much more growth can be expected)
- The degree of spinal curvature.

Although the cause of idiopathic scoliosis is unknown, the way scoliosis curves behave is fairly well understood. Basically, the younger the patient and the bigger the curve, the more likely the curve is to progress.

Three common scoliosis treatment options used in the United States and the United Kingdom for adolescents include:

- Observation
- Back braces (with and without exercises)
- Scoliosis-specific exercises^{9,10}

3.1 Observation

The scoliosis curvature is measured on x-rays by what is known as the Cobb method. This form of measurement is accurate to within 3 to 5 degrees.

Curves that are less than 10 degrees are not considered to represent scoliosis but rather are referred to as spinal asymmetry. These types of curves are extremely unlikely to progress and generally do not require treatment. If the child is very young and physically immature, then the progress of the curve can be followed during the child's regular check up with his or her paediatrician. If the curve is noted to progress beyond 20 degrees, then the child should be referred to an orthopaedic surgeon with expertise in scoliosis for continued treatment.⁹⁻¹¹

Curves that are between 20 to 30 degrees in a growing child can be observed at 4 to 6 month intervals. Any progression of less than 5 degrees is not considered significant. If the curve progresses more than 5 degrees, then the curve will need treatment. Additionally, any curve over 30 degrees in a skeletally immature individual will need treatment. Scoliosis treatment for patients with progressing curves, or curves over 30 degrees are often treated with the use of a back brace.¹

It is important to note that the treatment for curves of 15-30 degrees in continental Europe differs from that used in the United States. Many physical therapy approaches like SEAS, Schroth, DOBOMED, SpinCore PT, Barcelona method are used for mild curves in Poland Spain, Italy and France. ¹⁵⁻¹⁷

3.2 Back braces

Bracing is designed to stop the progression of the spinal curve, but it does not usually reduce the amount of angulation already present. The majority of curve progression takes place during a child's growth phase, and once the growth has ended, there is little likelihood of progression of a curve. Therefore, bracing is continued until the child is skeletally mature and has finished growing. Curves that are greater than 50 degrees in angulation, tend to continue to progress after skeletal maturity. As a result, the treatment objective is to try to get the child into adulthood with less than a 50-degree curvature.⁹

There are two types of commonly used scoliosis braces in the USA: a thoracolumbar sacral orthosis (TLSO) and a Charleston bending brace.¹⁶ Braces such as the Cheneau, Sforzesco and others are used in continental Europe.¹⁷

The TLSO is a custom molded back brace that applies three-point pressure to the curvature to prevent its progression. It can be worn under loose fitting clothing, and is usually worn 23 hours a day. This type of scoliosis brace can be taken off to swim or to play sports.



Fig. 7. TLSO Brace

A Charleston bending back brace applies more pressure and bends the child against the curve. This type of scoliosis brace is worn only at night while the child is asleep.

Since bracing normally only works to stop the progression of the curvature in a growing child, it is not used for those children who are already skeletally mature or almost mature. It is only used for younger children (e.g. girls who are about 11 to 13 years old, and boys who are about 12 to 14 years). If an older child has a curve greater than 30 degrees and is

almost mature, his or her curvature will be treated with observation only, since there is little growth left and bracing will be unlikely to have much impact on the curve structure.¹⁶



Fig. 8. Charleston Brace

Unfortunately, even with appropriate bracing, some scoliosis spinal curves will continue to progress. For these cases, especially if the child is very young, bracing may still be continued to allow the child to grow before fusing the spine.^{9,10}

3.3 Adult Scoliosis Brace by spinecor

Due to the nature of the adult spine, treatment should be based on a comprehensive evaluation which should include an Orthopedic/Neurological examination, recent upright X-rays, and functional assessment exams. The Spinecor Adult Brace can be used to create spinal translation designed to de-weight the adult spine. However, chronic inflammatory conditions, arthritis, stenosis, and spondylosis must also be carefully considered when applying the orthosis. Principles of neuro-muscular-re-education are employed to reduce chronic pain cycles, and improve muscle memory in postural restoration. Neuromuscular



Fig. 9. Spinecor Brace for Adults

re-education involves teaching the patient how to correctly use agonist and antagonist muscle groups and how to overcome faulty habitual patterns of use. Strengthening of weak muscle groups and stretching of tight muscle are incorporated to help assist with proper muscle usage which otherwise might not be attainable due to muscular dysfunction.

Treatment Objectives- Adult Scoliosis treatment is designed to improve activities of daily living (ADLs) and to provide pain relief. Curvature reduction through improved postural stability may also be considered as an objective. Changes in bone shape are not realistic in the adult spine.

Treatment Outcomes- Initial studies of Adult Spinecor Bracing (Deutchman, Lamantia 2004) reported reduction in Cobb angle measurements in all types of curvatures regardless of curvature location or age. However longitudinal studies are still needed.

*Treatment Protocols-*The Adult Spinecor brace wearing schedule varies depending upon the patient's co-morbidities and treatment objectives. Typical wearing schedules are daytime, only to tolerance. Fatigue may limit brace usage in the first few months of treatment, however the majority of adults find they can build up tolerance to wearing the brace fulltime within the first 3 months. Patients with chronic active pain syndromes are typically fitted in an Adult configuration designed to de-weight the spine and reduce pain. Changes in brace configuration are based on clinical measurements specific to each patient. Brace fittings designed to restrict and re-educate movement patterns are typically used initially in patients without pain. Patients are typically under care for 24 months, however, some patients continue to be cared for and monitored for many years when degeneration and spinal instability are an issue.

Indications- The Spinecor Adult Scoliosis is indicated for Adults with De-Novo (adult onset) Scoliosis, and Adolescent Idiopathic Scoliosis in Adulthood. Patients who are suffering from pain, fatigue or weakness as a result of scoliosis, are typically considered candidates for bracing. Indications also include those patients interested in improving the cosmetic appearance of their waist angles and ribcage. Patients with respiratory conditions secondary to Scoliosis may also be considered for treatment if there is no significant reduction in vital capacity or blood oxygen levels with the brace properly fitted.

Contraindications- Patients with severe stenosis resulting in neurological deficit may not respond well to Adult Scoliosis Bracing. There are contraindications for patients with recent pathological fracture or unstable spondylolysis with neurological deficit. Patients may also be refused treatment if expected outcomes are not reasonably possible.¹⁸

3.3.1 The Spinecor Brace for adolescent scoliosis

The objective of the Spinecor Brace in Adolescence is to stabilize the spine by re-training movement patterns while holding the spine in a corrected (de-rotated) position. Treatment is applied with the compressive force of gravity and the brace in order to influence the shape of growing bones. The Spinecor brace is custom fitted and configured specifically for each patient depending upon the location and direction of the scoliosis. Brace wearing schedules are similar for most adolescence; 20 hours of brace wearing with two breaks separated by at least 4 hours between breaks. Full time wearing is expected within two

weeks of the initial fitting. The length of treatment depends upon when the diagnosis is made. Females typically wear the brace beginning at diagnosis and ending two years beyond their menses, or when the growth plates are completely fused. Males typically continue to grow up until their 17th year, and may benefit from brace wearing into their late teens.

Treatment Outcomes- The Spinecor brace is the only orthosis which has been reported to permanently reverse the curvature associated with Scoliosis. Due to the ease of use, compliance is much higher with Spinecor, as is the psychological well being of patients compared to those who did not receive treatment, or were prescribed a rigid orthosis.^{19,20}

Treatment Indications- Patients diagnosed with Scoliosis from ages 1 thru adolescence with curvatures measuring from 12-50 degrees at the time of diagnosis are considered candidates for bracing. Candidates with smaller curvatures who are less mature are considered ideal; however, individual cases may be accepted on an elective basis with informed consent.

Contraindications- Neuromuscular scoliosis is considered a contraindication, however individual cases are sometimes considered for intervention as long as the patient understands the limitations. Patients who experience significant progression (5 degrees or more) on three consecutive follow-up evaluations may also be released from care, however individual cases may again be exempt from release as long as the patient clearly understands the limitations of treatment effectiveness.²¹

3.3.2 Effectiveness of bracing

In one extensive review of the literature, authors concluded that the effectiveness of bracing is not yet established, but may be promising.^{3,4}

3.4 Electrical stimulation

The usual protocol for using electrical stimulation to treat scoliosis is to place the electrodes so that they are on the convex side(s) of the spinal curve. The convex side of the curve is considered to be the long and weak side, while the concave side of the curve is considered to be strong and tight. The intention of the treatment is to stimulate those long and weak muscles and thereby result in the ability of the newly strong muscles to pull the spine into a more vertical position.

3.4.1 Effectiveness of electrical stimulation

Clinical studies have not shown efficacy for electrical stimulation as a treatment intervention for scoliosis.^{3,4}

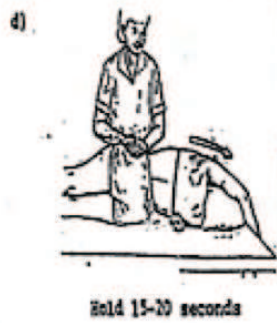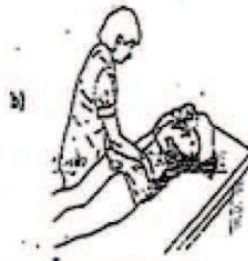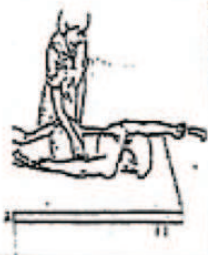3.5 Exercise methods

Scoliosis specific physical therapy exercises that were developed in the 1950's consist of movements that are designed to help stretch out the concave side of the curve and to strengthen the convex side of the curve. These are often done on the floor on a mat starting from a quadruped or side lying position. Hanging from a bar is also included in these exercises.²²

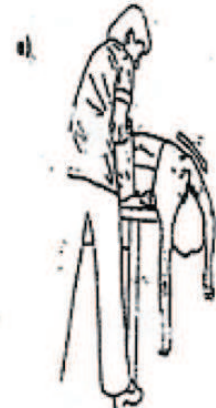SCOLIOSIS EXERCISE PROGRAM

Goals of Exercise

- 1) Improve the strength and postural control of trunk musculature
- 2) Increase the mobility of any tight structures in the trunk
- 3) Improve overall posture

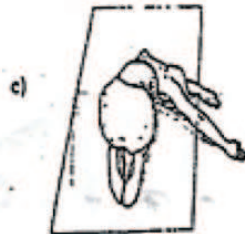


Hold 15-20 seconds



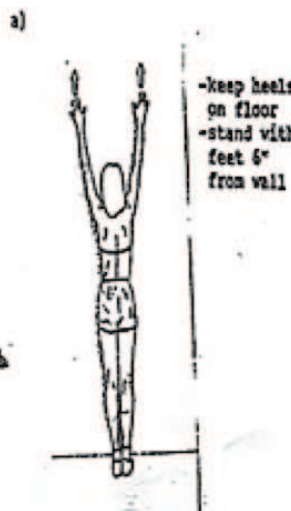
Hold 15-20 seconds

I) **STRETCHING TIGHT MUSCLES ON CONCAVE SIDE OF CURVE**
Hold each position 15-20 seconds

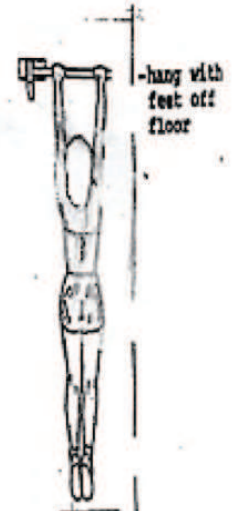


Hold 15-20 seconds

II) **TO ELONGATE THE TRUNK**



-keep heels on floor
-stand with feet 6" from wall



-hang with feet off floor

Fig. 10. Scoliosis Exercise Program

Scoliosis exercise

Abdominal Strengthening

continued

a) pelvic tilt

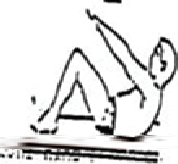

-hold low back flat to floor for 10 seconds, relax and repeat

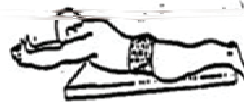d) Do the above exercise with arms outstretched and slightly out to the side, lift one arm at a time with your hand positioned so the thumb is up. Alternate arms for each repetition.

b) Repeat exercise III a (above) with knees extended

c) Partial sit up - hold 10-15 seconds

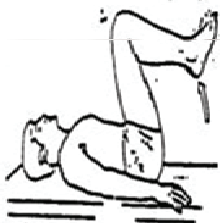


Progress difficulty by:
a) crossing arms across chest
b) fold hands behind head

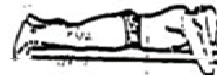


e) Lie on stomach, clasp hands behind head, tuck chin into chest. Raise elbows and chest off floor and hold. Slowly return to starting position.

d) Double leg lowering




-extend knees
-slowly lower legs - only as long as you are able to maintain posterior pelvic tilt



BACK EXTENSION STRENGTHENING

Hold each position 10-15 seconds

Lie on stomach, arms at side, tuck chin into chest. Pull shoulder blades together, lift head and shoulders off floor.



Do the above exercise with arms out to sides at 90°.

Do the above exercise with arms out to sides at 90° and the shoulder and elbows bent 90°.

Patient Exercise Hand-out, Adapted from Therapeutic Exercise for body alignment and function¹⁴
Note: most of these exercises address only one plane of deformity

Fig. 11. Scoliosis Exercise

3.5.1 Effectiveness of exercise

In one extensive review of the literature, authors concluded that the effectiveness of exercise is not yet established, but may be promising.³ In another extensive review of the literature, only one study demonstrated efficacy for exercises in reducing both the rate of progression or the magnitude of the Cobb angle at the end of treatment. However, this study was categorized as poor quality, and failed to provide solid evidence for or against the efficacy of physical exercises in the treatment of adolescent idiopathic scoliosis. Nevertheless, considering that exercises could also be proposed on the basis that benefits rather than to avoid progression have been shown in the literature, and since results contained in published studies suggest an effect on the primary goal of preventing progression, there is a basis for including exercises.²³

With the advent of newer *exercise methods*, especially those using a more three-dimensional approach, more research will be needed to determine the effectiveness of these interventions.

3.6 Schroth Method

The Schroth Method was developed in Germany in 1927 by Katarina Schroth to treat her own scoliosis. This exercise method incorporates a three dimensional therapy to reshape the ribcage and reduce the deformity associated with Scoliosis. The aim of these scoliosis specific exercises for adults and children should reduce the incidence of scoliosis progression, reduce postural rotation, improve mobility, improve postural stability, reduce pain, and improve cardiopulmonary function.



Fig. 12. Schroth Method Exercises to Elongate the Spine

3.6.1 Schroth breathing (focused inspiration)

Through focused expansion of the flattened portion of the ribs (within the thoracic concavity) during inspiration, and forced contraction of the rib hump(s) on exhalation, the Schroth Method has been shown to successfully reshape the rib cage, decrease rotation of the vertebral bodies, and improve vital lung capacity (Ottman et al 2005) in patients with Scoliosis. Patients are taught to breathe while in seated, lying and specific standing postures.

3.6.2 Schroth exercises (isometric postures)

Scoliosis is not a primary problem with the muscles, however, the stabilizer muscles of the trunk, pelvis and spine do become imbalanced, and, can be reconditioned to help slow, stop and reverse the scoliosis curvature. This is especially true of the lumbar spine. The Schroth Exercises are designed to be isometric contractions of the core while in mechanically advantageous positions. In other words, patients are shown postures which would help reduce the postural deformity associated with their scoliosis, and are asked to hold those postures during Schroth breathing.



Fig. 13. Schroth Exercise with Mirror Feedback

3.6.3 Schroth walking (dynamic postural control)

The pelvis can rotate in Scoliosis causing lumbar rotation, hip height discrepancy, pain and progression of the Scoliosis. Often Schroth therapy and manually applied treatment are necessary to improve flexibility in this area. When a patient can create pelvic corrections, which improve the alignment, he or she can learn to move with the pelvis in this more desirable position. This is done in the very beginning by having the patient consciously hold the pelvis during controlled walking ("walking through tall grass"). Schroth described 5 pelvic corrections, basically all degrees of freedom should be considered, 3 rotations and 3 translations, and with every combination in between. For the most part the corrections can be visualized without diagnostic measures.

Vestibular Rehabilitation: Neurological connections between the eyes and the spine have long been neglected in non-surgical treatment of scoliosis, despite the many studies which identify vestibular and oculomotor dysfunction in the majority of patients with Scoliosis. Habituation training and vestibular enhancement exercises may be appropriate in patients with vestibular involvement in their Scoliosis. Therapies and exercises to improve the central neurological controls of posture may include home, computer usage, or in office procedures. Following a functional neurological evaluation, including the use of state-of-the-art diagnostic equipment to evaluate vestibular function, a neurological retraining program is designed for patients on an individual basis.

Scoliosis Exercises for Pain Relief: Scoliosis pain in adults can be relieved with proper exercises designed to help activate neglected muscles; however, not all exercises are appropriate for patients with chronic pain. Often the use of an Elastic Tension Orthosis is more appropriate for these patients, and when pain relief is evident, exercises may be more effective for stabilization.

Scoliosis Exercises for Lumbar Scoliosis: Lumbar Scoliosis can result in pain in adults and can be progressive if measuring over 30 degrees Cobb angle. Scoliosis exercises for lumbar scoliosis are designed to activate muscles which straighten and de-rotate the scoliosis.

Scoliosis Exercises for Thoracic Scoliosis: Scoliosis exercises for Thoracic scoliosis are designed to expand the flat area of the thoracic concavity and de-rotate the rib hump using respiration and posture correction.²⁴⁻²⁸

3.6.3 Effectiveness of the Schroth Method

As indicated above, the Schroth Method has been found to be effective using the forced inspiration method. Another study of 813 patients who completed the Schroth in-patient program, showed an increase in chest expansion of more than 20%. The conclusion of the study author was that a course of inpatient treatment of the Schroth method resulted in an increase in vital capacity and chest expansion.²⁵ In another study by Weis, 118 inpatients with an average Cobb measurement of 31 degrees were treated with the Schroth method and tracked for four years. Results showed that 16.1% had progression of their curve, 68.7% had stabilization of their curve and 15.2% had an improvement of more than 5 degrees. The author concluded that in patients with idiopathic scoliosis, the Schroth method appeared to retard the natural progression of scoliosis compared to the natural history of scoliosis without intervention.²⁶

3.7 Yoga and scoliosis

Yoga practice can be instrumental in potentially limiting the progression of a functional scoliosis and possibly a structural scoliosis. A yoga practice may also help reduce pain and bring more balance and alignment to a body with scoliosis. With a functional scoliosis, an appropriate yoga practice can release tightened muscle groups that distort the spine, thus alleviating an underlying cause of scoliosis. In yoga for both functional and structural scoliosis, this may be accomplished in asana (poses/postures), through breath work, and through the process of being mindfully aware of the body's position and movements. In doing so, one gains insight and information from the body and proceeds in the practice with an increasing awareness and understanding of what one's body truly needs. Yoga can also develop (build-up) weakened muscle groups. This brings greater balance to the body's muscles. With asana and breath-work, the yoga practitioner can create more separation between the vertebrae and therefore in the body in general. By elongating the spine, the disks between the vertebrae can be nourished and relieved of pressure from the collapsing which takes place when the curved spine is fighting gravity and is being drawn down. Strengthening the muscles along the spine can help prevent the lateral curvature from increasing. In various asana, one can manipulate the spine in the direction opposite its lateral curves, and also de-rotate the spine in the direction opposite its twist. Developing the deeper abdominal muscles provides support to the spine that is learning symmetry, and

strengthening the legs provides the same benefit. The yoga practitioner can utilize the breath to release areas of tension in the body and also to bring a “filling” into spaces where the body is more collapsed, such as a lung or one side of the ribs. In yoga for scoliosis, or a yoga practice that emphasizes alignment, one learns to align the body with the structural system; in other words, the bones. In practicing poses and learning to stand in a manner that utilizes the bones for support (finding the body’s “plumb line”), rather than overtaxing muscles, joints, and ligaments by moving or standing with the bones misaligned, one can re-organize the body and function more harmoniously with gravity, rather than working against it. Through yoga, one can discover a more refined symmetry in the body, rather than the constant experience of the body’s compensating act for imbalance and asymmetry. When the yoga practitioner with scoliosis begins to discover this more refined manner of aligning the body, one’s curvatures may then more easily co-exist with gravity, and in this the yoga practitioner may find they experience less pain and more balance.²⁹

3.7.1 Effectiveness of yoga for scoliosis

Few studies have been conducted about the effectiveness of yoga in the treatment of scoliosis but several testimonials from people who have scoliosis have found it to be effective in improving their posture and other factors such as improved vital capacity. One case study was published which involved a 46-year-old woman who was diagnosed with idiopathic scoliosis. She had been recommended as a candidate for spinal fusion during her early adolescent years. She instead chose to work with conservative therapy sessions for the period of one year. She then opted to practice somatic movement reeducation techniques and yoga, mainly Body-MindCentering™, The Feldenkrais Method™, swimming, and Iyengar Yoga. The yoga regimen was shown to help the patient to stabilize weak muscles; enhance her range of respiration; increase postural tone in standing, sitting, and lying; and strengthen and lengthen the spine through specific postures used as traction. Movement reeducation based on the integration of concepts of bio-mechanics and motor development improved the subject’s proprioception, sensibility, and awareness of functional movement. At the time of publication, the subject was pain-free, living a functional and active life.³⁰

Another study done in Korea³¹ examined the effect of yoga on twenty women with scoliosis. These women ranged in age from twenty to fifty. The results of this study showed a statistically significant decrease of 3.7-degrees correction in the Cobb angles of this sample. It is important to note that these results must be interpreted with caution as the results are within the margins of measurement error (5 degrees) as mentioned above.

3.8 The ATM2™ in the treatment of scoliosis

The ATM2™ was never intended as a treatment specifically for treating scoliosis, so it was with much surprise when it was discovered by accident, that a patient who was being treated for a frozen shoulder was also getting as a secondary benefit, an improvement of her longstanding scoliosis and kyphosis. After her first treatment, the patient explained, that she immediately noticed when she sat in her car, that her head was touching the headrest of her car seat. She had never been able to do this before because her thoracic kyphosis prevented her head from going back far enough to touch the headrest. At her second treatment session, documentation of the patients posture began, along with other measurements related to her scoliosis. After several treatment sessions aimed at treating her

postural faults, significant improvements were evident in the patient's posture from the ATM2™ interventions alone. This was the first time such documentation had taken place for postural improvements noted while using the ATM2™, although many clinicians have noted similar improvements in their patients' posture after treatment with the ATM2™.⁷

Since publication of the above case study, further study was undertaken to determine if the ATM2™ would be effective in treating scoliosis by reversing the curves of other subjects with mild to moderate scoliosis.

The following information is from the current study:

4. Methods and materials

Thirty-eight subjects (34 female, 4 male) with a diagnosis of mild to moderate scoliosis were recruited from a scoliosis support group and by advertising to local physicians. Inclusion criteria were as follows: subjects were between the ages of 12-65 with a diagnosis of scoliosis curve between 20° and 50°. Exclusion criteria were as follows: a previous surgery to correct the curve, current pregnancy, any serious medical co-morbidities, any history of claustrophobia or currently suffering from severe back pain that required medication. Subjects were put on the ATM2™ and performed *pain free* movements in several directions. All subjects performed resisted extension and side bending into their convexity, in order to move into the direction that reversed their curve. The subjects were progressed from 1 set of 10 repetitions to 3 sets of 10 repetitions in each direction. All subjects completed at least 1 round of treatments, which consisted of between 8-10 sessions. Some subjects who were available completed a second round of sessions for a total of 20 treatments. Objective measures utilized in this study included:

- Numeric Pain Rating Scale
- SF-36
- Oswestry Disability Index
- Cobb angles from pre and post intervention x-rays
- Height
- Trunk ROM measurements including:
 - Flexion and Extension (measured using double inclinometer method)
 - Side Bending (measured fingertips to floor, with measuring tape)
 - Rotation (measured with goniometer)

4.1 Results

All outcome measures were analyzed using a paired t-test. Multiple outcome measures demonstrated statistically significant change at the 0.05 Level of Significance including:

- Right Side Bending ($p=0.007$)
- Right Rotation ($p=0.003$)
- Left Rotation ($p=3.07 \times 10^{-5}$)
- Trunk Flexion ($p=0.1$ *approaching significance, note: majority of subjects able to touch fingers to floor at the beginning of the study so no change expected in this variable)
- Height ($p=.005$)
- Numeric Pain Rating ($p=0.0002$)
- Oswestry Disability Index ($p=0.01$)

Five subjects were able to obtain pre and post treatment x-rays. Decreases in angle of curvature were seen in 3 subjects when determining Cobb angles. Statistical analysis was not run because of the small sample size. Cobb angles improved or were unchanged for the 5 subjects for whom x-rays were obtained. The Minimal Clinically Significant Difference (MCSD) for Cobb angles is ~7 degrees in adolescents (MCSD not available for adults). SF-36 data showed statistical significance for the majority of variables.

4.2 Discussion and conclusion

This study was done to determine if the ATM2™ can treat scoliosis by reversing spinal curvature. The hypothesis for efficacy is that by stabilizing a scoliotic curve, and then moving into resistance, the apex of the curve would receive mobilization while the active movement from the subject would achieve neuromuscular re-education of the supporting musculature. X-rays taken before and after intervention showed decreases in Cobb angles for three subjects who were able to provide post treatment x-rays. Before and after photos also showed changes in those who began with greater spinal curvatures. Some subjects reported they received comments about improved posture from family and friends. Subjects also reported improved self-image as a result of the study. In addition, several objective measures of ROM, as well as height, pain rating and the Oswestry Disability Index have been found to be statistically significantly improved after treatment with the ATM2™. The ATM2™ was shown to be effective in reducing the Cobb angles of three subjects, as well as observationally with pre and post intervention posture pictures. Based on the results of this study, treatment with the ATM2™ positively affects perceived level of health, self-image, visible posture correction, ROM, height, and self-reported disability measures.

Further study is ongoing with the goal of improving the power of current the study by increasing the sample size, especially with regard to Cobb angle data. The ATM2™ intervention continues to provide significant positive results for the subjects who have been involved in our study.³²



Fig. 14. The ATM2™

5. Emotional and psychological considerations

Although this chapter deals with non-surgical physical methods of treatment for scoliosis, the emotional and psychological impact of such physical interventions cannot be ignored. Physical impairments and disabilities often result in low self-evaluation, reduced self-worth, poor self-image and lessened self-respect. Emotional fatigue, hopelessness, helplessness and depression may ensue. In turn, a weakened mental state will down-regulate general functional abilities. Such is often the case with individuals suffering from scoliosis. This spinal affliction not only causes discomfort, and sometimes pain, but often self-consciousness from the associated physical deformities that are very evident to the patient. These include difference in shoulder height, difference in hip height position, difference in shoulder blade height or position, with the head not centered with the rest of the body. These deviations from normal cumulate in obvious (to the person with scoliosis) or not so obvious deformity. In addition the required physical examinations for many years may also result in further self-consciousness for the adolescent. The application of bracing which is most often the treatment of choice can further add to poor body image. As can be expected, having scoliosis has significant psychological implications.⁵ Many of our subjects have talked about the emotional aspect of their scoliosis and the huge benefit that they gained in improved self-esteem as a result of the intervention.

As an example of an intervention to specifically address the emotional component of scoliosis, an education program called “success coaching” was developed. It has been touted as an important component in the treatment of scoliosis. The famous psychologist and personality theorist, Alfred Adler, stated that the primary goal of all human behavior is *self-perfection*. He further stated that when we face our weaknesses with optimism and courage, we “will then make the necessary effort to *compensate* for such weaknesses.” Such efforts often result in superior achievement. Feelings of inferiority and inadequacy must be combated at all costs. The concept of *Success Coaching* focuses on self-acceptance and places emphasis on the identification of individual strengths. Success coaching incorporates realistic goal setting for high achievement in all aspects of life. Specific aims include the following:

1. Overcoming feelings of inadequacy
2. Overcoming social isolation
3. Overcoming of “feeling different and disabled”
4. Learning psychosocial coping skills
5. Learning realistic goal setting
6. Establishing internal locus of control (self-reliance and motivation for high achievement)
7. Peak performance training (using one’s potentials to the upper limit)
8. Realistic self-appraisal in both cognitive and social domains
9. Elimination of negative and self-defeating behaviors

Success coaching also entails informative lectures on stress management and coping strategies associated with all aspects of daily life (work, school, social and family). Supportive individual and group discussion sessions are tailored to specific areas of difficulty and adjustment problems.³³


In summary, many different physical interventions have been tried for the treatment of scoliosis. Some have shown better efficacy than others. As new effective interventions are being discovered, the future of non-surgical success for scoliosis looks bright and promising.

6. References

- [1] Scoliosis Research Society Web site. Available at:
<http://www.SRS.org/htm/glossary/medterms.htm>
- [2] Skaggs DL, Bassett GS. Adolescent idiopathic scoliosis: an update. *Am Fam Physician*.1996 ;53:2327-2335.
- [3] Lenssinck M., et al. Effect of Bracing and Other Conservative Interventions in the Treatment of Idiopathic Scoliosis in Adolescents: A Systematic Review of Clinical Trials. *Physical Therapy*. 2005 ;85:1329-1339
- [4] Surface Electrical Stimulation Versus Brace in Treatment of Idiopathic Scoliosis. Durham, J., Moskowitz A., Whitney J. *Spine*. 1990 :15;888-892
- [5] Payne B, Ogilvie J, Resnick M, et al. Does scoliosis have a psychological impact and does gender make a difference? *Spine*.1997 ;22:1380-1384.
- [6] Sapountzi-Krepia DS, Valavanis J, Panteleakis GP, et al. Perceptions of body image, happiness, and satisfaction in adolescents wearing a Boston brace for scoliosis treatment. *J Adv Nurs*. 2001 ;35:683-690.
- [7] Lewis, C., Erhard, R., Drysdale, G. Kyphoscoliosis Improvement While Treating a Patient for Adhesive Capsulitis Using the Active Therapeutic Movement Version 2. *JMPT*. 2008 :31;715-722
- [8] Vicenzion B., Hing W., Rivett D., Hall T. *Mobilisation with Movement: The art and the science*. Churchill Livingstone, Australia, 2011 ISBN: 9780729538954
- [9] <http://www.webmd.com/osteoarthritis/guide/arthritis-scoliosis>
- [10] www.spine-health.com/conditions/scoliosis/scoliosis-what-you-need-know
- [11] [www,srs,org](http://www.srs.org)
- [12] www.spine-health.com/conditions/scoliosis/scoliosis-surgery
- [13] <http://www.nlm.nih.gov/medlineplus/ency/article/001241.htm>
- [14] www.biometrixmedica.com/en/products/formetric.3D.html
- [15] <http://www.eurospine.org/p31000269.html>
- [16] <http://www.spine-health.com/conditions/scoliosis/types-scoliosis-braces>
- [17] Negrini S. et al. Effectiveness of complete conservative treatment for adolescent idiopathic scoliosis (bracing and exercises) based on SOSORT management criteria: results according to the SRS criteria for bracing studies - SOSORT Award 2009 Winner. *Scoliosis*. 2009 :4;19
- [18] www.spinecorporation.com/English/ScientificInformation/%20Vachon%20-%20Effectiveness%20of%20the%20SpineCor%20brace.pdf
- [19] <http://www.spinecorbrace.us/scientificinformation.htm> ref
[scoliosissystems.com/Spinecor_Brace.html](http://www.scoliosissystems.com/Spinecor_Brace.html)
- [20] <http://www.spinecorresearch.com/>
- [21] www.gillettechildrens.org/fileupload/vol11no3.pdf
- [22] Daniels L and Worthingham C. *Therapeutic Exercise for body alignment and function*. WB Saunders, Philadelphia, 1977.
- [23] Negrini S. et al. Physical exercises as a treatment for adolescent idiopathic scoliosis. A systematic review. 2003 :6;227-235
- [24] <http://www.schrothmethod.com/clinical-scoliosis-studies>
- [25] Weiss, R. The Effect of an Exercise Progrm on Vital Capacity and Rib Mobility in Patients with Idiopathic Scoliosis. *Spine*. 1991:88-93.

- [26] Weiss, R. The Progression of Idiopathic Scoliosis Under the Influence of a Physiotherapy Rehabilitation Exercise Program. *Physiotherapy*. :78
- [27] www.scoliosissystems.com/Schroth_3_Dimensional_Scoliosis_Rehabilitation.html
- [28] Lehnert-Schroth. *The Schroth Method: Three-Dimensional Treatment for Scoliosis*. ISBN: 978-0-914959-02-1
- [29] <http://yogaquest.wordpress.com/yoga-for-scoliosis/>
- [30] Monroe, M. Yoga and movement re-education for the treatment of idiopathic scoliosis. From 7th International Conference on Conservative Management of Spinal Deformities Montreal, Canada, 20-22 May 2010.
- [31] Hoe-Won, K. The Effect of a Yoga Correction Exercise Program for Scoliosis. KACEP Annual Meeting, Korean Association of Certified Exercise Professionals; 2007.
- [32] Lewis study in progress
- [33] http://www.ehow.com/about_5568171_psychological-effects-scoliosis.html

IntechOpen



Physical Therapy Perspectives in the 21st Century - Challenges and Possibilities

Edited by Dr. Josette Bettany-Saltikov

ISBN 978-953-51-0459-9

Hard cover, 386 pages

Publisher InTech

Published online 05, April, 2012

Published in print edition April, 2012

This book contains new information on physical therapy research and clinical approaches that are being undertaken into numerous medical conditions; biomechanical and musculoskeletal conditions as well as the effects of psychological factors, body awareness and relaxation techniques; specific and specialist exercises for the treatment of scoliosis and spinal deformities in infants and adolescents; new thermal agents are being introduced and different types of physical therapy interventions are being introduced for the elderly both in the home and clinical setting. Additionally research into physical therapy interventions for patients with respiratory, cardiovascular disorders and stroke is being undertaken and new concepts of wheelchair design are being implemented.

How to reference

In order to correctly reference this scholarly work, feel free to copy and paste the following:

Clare Lewis (2012). A Review of Non-Invasive Treatment Interventions for Spinal Deformities, Physical Therapy Perspectives in the 21st Century - Challenges and Possibilities, Dr. Josette Bettany-Saltikov (Ed.), ISBN: 978-953-51-0459-9, InTech, Available from: <http://www.intechopen.com/books/physical-therapy-perspectives-in-the-21st-century-challenges-and-possibilities/a-review-of-non-invasive-treatment-interventions-for-spinal-deformities>

INTECH
open science | open minds

InTech Europe

University Campus STeP Ri
Slavka Krautzeka 83/A
51000 Rijeka, Croatia
Phone: +385 (51) 770 447
Fax: +385 (51) 686 166
www.intechopen.com

InTech China

Unit 405, Office Block, Hotel Equatorial Shanghai
No.65, Yan An Road (West), Shanghai, 200040, China
中国上海市延安西路65号上海国际贵都大饭店办公楼405单元
Phone: +86-21-62489820
Fax: +86-21-62489821

© 2012 The Author(s). Licensee IntechOpen. This is an open access article distributed under the terms of the [Creative Commons Attribution 3.0 License](#), which permits unrestricted use, distribution, and reproduction in any medium, provided the original work is properly cited.

IntechOpen

IntechOpen