

We are IntechOpen, the world's leading publisher of Open Access books Built by scientists, for scientists

4,800

Open access books available

122,000

International authors and editors

135M

Downloads

Our authors are among the

154

Countries delivered to

TOP 1%

most cited scientists

12.2%

Contributors from top 500 universities



WEB OF SCIENCE™

Selection of our books indexed in the Book Citation Index
in Web of Science™ Core Collection (BKCI)

Interested in publishing with us?
Contact book.department@intechopen.com

Numbers displayed above are based on latest data collected.

For more information visit www.intechopen.com



Acute Renal Cortical Necrosis

Manohar Lal
*Jinnah Postgraduate Medical Center, Karachi
Pakistan*

1. Introduction

Acute renal cortical necrosis is a rare cause of acute renal failure secondary to ischemic necrosis of the renal cortex. It accounts for only 2% of all causes of acute renal failure in developed countries (Grünfeld et al., 1981), but occurs more frequently in developing world (Chugh et al., 1976; Chugh et al., 1983; Hassan et al., 2009; Parkash et al., 1995). The obstetric complications are the commonest (50 - 70%) cause of renal cortical necrosis (Hassan et al., 2009), non-obstetric causes account for 20-30% of all cases of cortical necrosis and in these circumstances the incidence is higher in men than in women (Duff & More, 1941). Majority of the patients become dialysis dependent and occasional patients may recover partial kidney function and are dialysis-independent.

Acute cortical necrosis is usually a bilateral condition, rarely being unilateral (Blau et al., 1971). The lesions are usually caused by significant prolonged diminished renal arterial perfusion secondary to vascular spasm, micro-vascular injury, or intravascular coagulation.

Renal cortical necrosis is usually extensive although local or localized forms occur.

Most of the patients present as acute renal failure and suspicion of the condition arises following prolonged oliguria and/or anuria. The kidney biopsy is the gold standard for the diagnosis.

2. Etiology

2.1 Pregnancy related

- Abruptio placentae
- Severe pre-eclampsia / eclampsia
- Criminal / Septic Abortion (Gram negative septicemia)
- Hyperemesis gravidarum
- Prolonged intrauterine death

2.2 Infections

2.2.1 Children

- Diarrhea, vomiting (Dehydration)
- Peritonitis
- Septicemia
- Congenital heart disease
- Fetal maternal transfusion

- Dehydration.
- Perinatal asphyxia
- Placental hemorrhage
- Hemolytic uremic syndrome (HUS).

2.2.2 Adults & adolescents

- Scarlet fever
- Streptococcal Infections
- Peritonitis
- Cholera

2.3 Hemodynamic causes

Acute tubular necrosis progressing to acute cortical necrosis with shock and crush injury.

2.4 Trauma

- Head injuries
- Burns
- Gastrointestinal hemorrhage
- Thrombotic thrombocytopenic purpura
- Pancreatitis
- Dissecting aneurysm

2.5 Snake bite

Due to direct toxic effect or shock, hemorrhage, haemoptysis

2.6 Drugs

Nonsteroidal anti-inflammatory drugs and contrast media.

2.7 Hyper acute kidney transplant rejection

2.8 Poisonous plants

- Fava Beans
- Exposure to Sap of Marking-nut tree
- Almond Extract (? Cyanide)

2.9 Glycol poisoning

- Dioxane
- Di ethylene Glycol (anti freeze)

2.10 Metallic & other poisoning

- Arsenic
- Cadmium
- Lithium Carmine
- Pyrazolene
- Camphor
- Phosphorus

2.11 Idiopathic

In a small number of cases, no cause is apparent even after extensive search. These cases are labeled as idiopathic in origin.

3. Pathology

The classic description of this condition by Sheehan & Moore (1952) still holds true to this day. They described the lesion at different stages in evolution as seen in autopsy material. They divided the fully developed form into various types, depending on the extent of the lesion.

3.1 Focal form

In this small scattered foci of necrosis are seen that vary from lesion of individual glomeruli to areas of cortical necrosis 0.5 mm in diameter. On gross examination kidneys usually are slightly enlarged and have punctuate red areas on cut section and on the sub capsular surface. Histologically, only few glomeruli in any one focus are affected, showing necrosis often with thrombosis at the vascular pole (Figure 1). Proximal convoluted tubules are always necrotic, and the distal tubules are affected similarly in the centre of larger lesions. In the remainder of the cortex, many proximal convoluted tubules appear necrotic, but glomeruli and distal convoluted tubules show no changes of consequence. There may be an overlap between acute tubular necrosis and cortical necrosis (Sheehan & Moore, 1952).

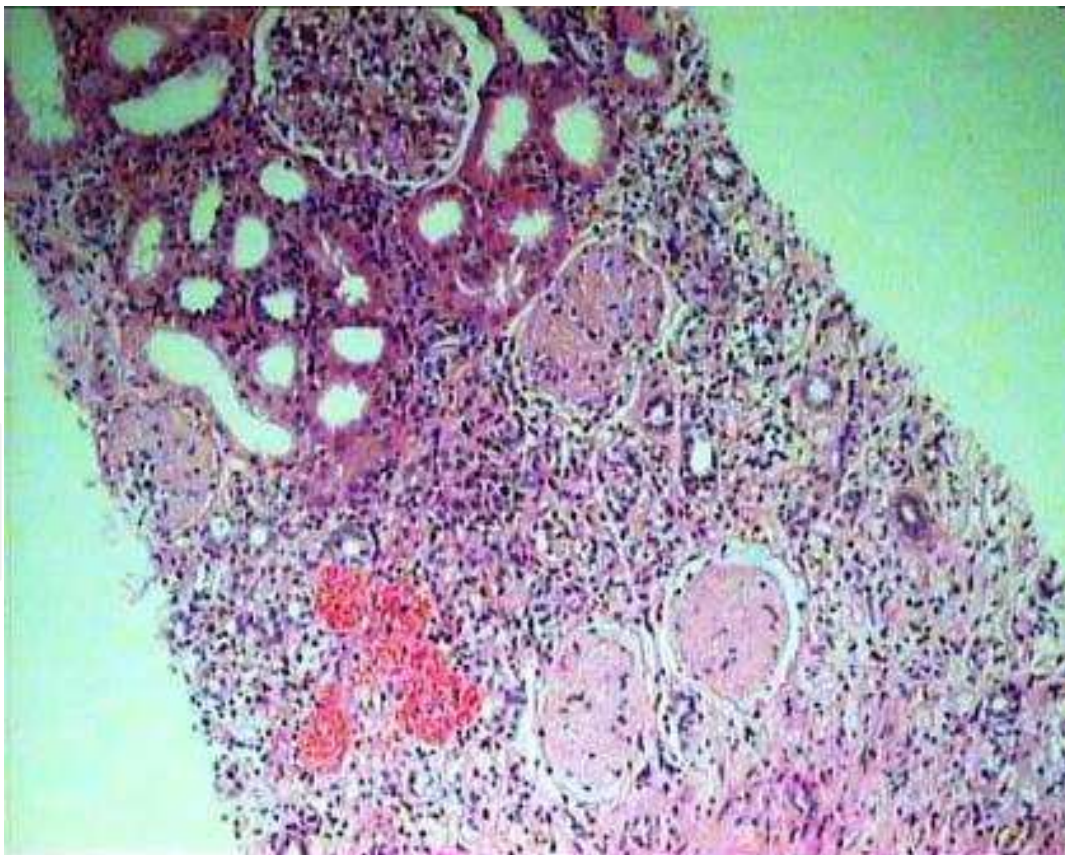


Fig. 1. Low-power view showing part of renal cortex. Three glomeruli in the lower part of the field are infarcted, while one glomerulus along with surrounding tubules, is still viable, in a case of focal cortical necrosis. (H&E stain, $\times 100$).

3.2 Minor form

The changes are similar to those described previously on gross description, except that lesions upto 3 mm in diameter are found.

Grossly, the affected foci have white centers with a red congested rim.

Histologically, in the affected foci there is necrosis of all elements including afferent arteriole, and interlobular artery. These and the glomeruli often contain thrombus material. Polymorphonuclear leucocytes are found sometime in portions of the necrotic lesion analogous to the peripheral dead zone of small infarct. Extensive proximal tubular necrosis is found in the remainder of the cortex.

3.3 Patchy form

Numerous larger polar areas of necrosis are found, sometimes occupying most of the width of the cortex, with a zone of congestion and hemorrhage around the periphery. The congestion is particularly pronounced in the inner cortex. The patches of cortical necrosis occupy about one third to two thirds of the cortex, but the columns of Bertini are usually spared. The kidneys are moderately enlarged.

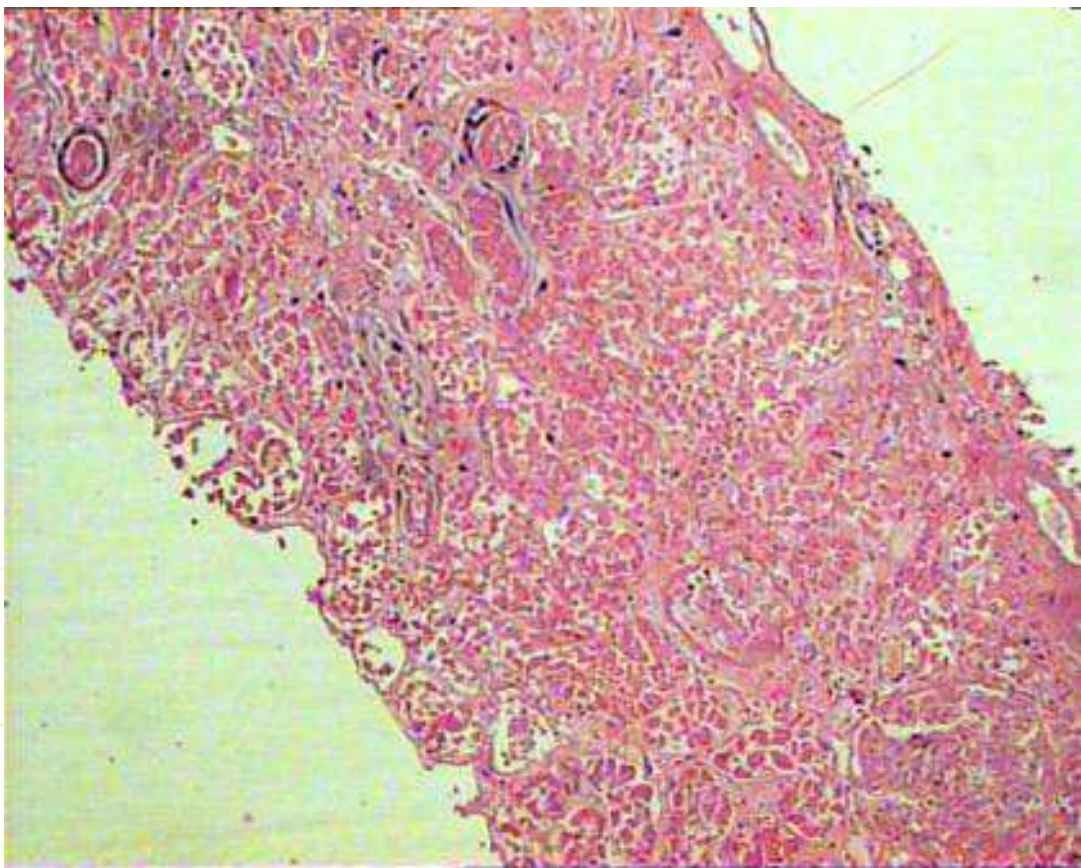


Fig. 2. Low-power view showing complete infarction of both the glomeruli and the surrounding renal parenchyma in a case of acute cortical necrosis. (H&E stain, $\times 100$).

Histologically the foci of cortical necrosis are large enough to show a central dead zone. All the structures within the necrotic areas usually are necrotic although occasionally collecting ducts appear undamaged. The arteries and arterioles are necrotic and dilated, and contain thrombus material in cases seen more than 2 days after onset.

3.4 Gross renal cortical necrosis

The cortex is almost entirely necrotic with the exception of thin surviving areas immediately under the capsule & at the cortico-medullary junctions. The kidneys are usually enlarged when the condition is well developed. Almost the entire cortex is yellowish white except from the spared zones in the sub capsular and juxtamedullary cortex. If seen earlier, the affected cortex is somewhat hemorrhagic or congested with whitish yellow streaks. The columns of Bertini are necrotic.

Histologically, changes similar to those seen in the patchy form are seen, but with arteries showing necrosis and thrombosis over a greater length than in the patchy form (Figure 2).

3.5 Confluent focal cortical necrosis

This condition is very common in those not associated with abruptio placentae (Sheehan & Moore, 1952). In this type there are widespread lesions of glomeruli and tubules, but there is no involvement of arteries. The lesions vary greatly from nephron to nephron both in severity and in apparent age. The glomeruli either appear normal or show various changes such as congestion, thrombosis of capillaries or of the vascular pole, or frank necrosis. Many proximal convoluted tubules appear normal but others are necrotic. Distal convoluted tubules appear normal. On gross inspection in the early stages the kidney has a red congested cortex with punctuate hemorrhages or pale mottling, but no white infarcted areas.

3.6 Calcification in cortical necrosis

In some cases, in which partial recovery occurs & patient survives for several weeks/months calcification of necrotic cortex may occur which can be seen on radiology (Alwall et al., 1958; Effersoe et al., 1962; Oram et al., 1964; Phillips, 1962).

3.7 Necrosis in other organs

Other organs may show necrosis in cases of renal cortical necrosis e.g., anterior lobe of pituitary, adrenals, spleen, lungs, gastro intestinal tract, liver, pancreas etc. (Sheldon & Hertig, 1942).

4. Pathogenesis

The pathogenesis of cortical necrosis is far from clear, and probably many factors are involved.

4.1 Vasospasm

Following abruptio placentae, there is an initial vaso spasm that reduces blood flow for periods varying from several minutes to six hours. The spasm then abates and recirculation of blood occurs. If the spasm is of short duration and good flow is re-established, acute tubular necrosis occurs. However in patients who develop cortical necrosis, a new spasm is thought to occur, this time more proximally in the vascular tree & lasting for upto 30 hours, causing necrosis of the arteries beyond the obstruction. Then thrombosis occurs, with permanent blockage to the circulation (Matlin & Gary, 1974; Schrieiner, 1979).

It has long been suggested that vasculature in pregnancy is more prone than usual to vasoconstriction which may partly account for the greater frequency of cortical necrosis in this state.

4.2 Generalized Schwartzman reaction

Similarity has been shown between cortical necrosis & the generalized Schwartzman reaction in rabbits. In this reaction, two small doses of bacterial endotoxin given 24 hours apart, cause microscopic thrombosis that involves the glomerular capillaries and leads to development of renal cortical necrosis (Moss et al., 1977; Sporn, 1978). This mechanism may be active during septic abortions.

The sequence of events starts with sudden widespread dilation of glomerular capillaries, followed by an escape of plasma by filtration. Increased viscosity of the blood follows, with stasis and formation of thrombi, which extend backward to arteries of increasing size, which become necrotic.

4.3 Vascular thrombosis

The importance of fibrin and fibrinogen deposition in the glomeruli and small vessels has been demonstrated. This may result from mechanical obstruction with blood flow through the glomeruli.

However, there is disagreement about the chain of events; whether coagulation or vasomotor dependence phenomena occur earlier. Endotoxaemia and/or bacterial sepsis is by far the most common factor responsible for intravascular coagulation.

Immunologic mechanisms also may play a role in the pathogenesis of acute cortical necrosis. Gelfand et al. (1970) found lymphocytotoxic antibody in 27% of patients with acute cortical necrosis and anti-platelet antibody in 79%.

5. Clinical features

In those cases of acute cortical necrosis associated with abruptio placentae patient may present with:

- Severe lower abdominal pain
- Per vaginal bleeding
- Hypotension / Shock
- Oliguria / anuria.

Without abruptio placentae:

- Oliguria / anuria
- Infection / diarrhea / symptoms of predisposing disease.

Acute renal failure as a result of acute cortical necrosis cannot be distinguished readily from other forms of acute renal failure such as acute tubular necrosis and renal biopsy is the only sure way of making the diagnosis during life (Lauler & Schreiner, 1958).

6. Diagnosis

6.1 Ultrasonography

Initially shows enlarged, swollen kidneys with reduced blood flow. Cortical tissue becomes shrunken later in the course of disease (Sefczek et al., 1984).

6.2 KUB X-ray

Plain X ray of the kidney shows calcification weeks or months later (Moell, 1973).

6.3 Contrast enhanced CT scanning

Contrast enhanced CT scanning is the most sensitive modality. Diagnostic features include absent opacification of the renal cortex and enhancement of sub-capsular and juxtamedullary areas and of the medulla without excretion of contrast medium (Kleinknecht et al., 1973).

6.4 DTPA renal scan

It reveals markedly diminished perfusion with delayed or no function. It is more helpful in transplant kidneys.

6.5 Kidney biopsy

Kidney biopsy provides the definitive diagnosis and prognostic information.

7. Unilateral cortical necrosis

Unilateral cortical necrosis may occur rarely with ureteric obstruction on the uninvolved side (Blau et al., 1971). The mechanism is not clear, but experimentally, ureteric occlusion has a similar effect on the cortical necrosis found in the generalized Schwartzman reaction.

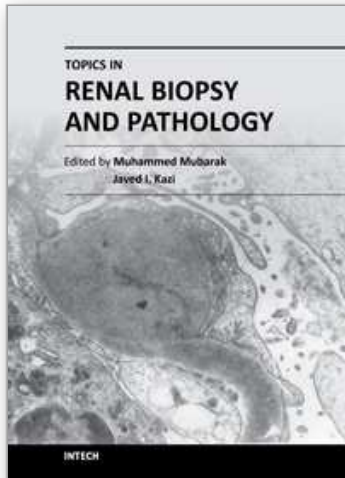
8. Recovery from cortical necrosis

Partial recovery of renal function has been reported and it is likely that recovery is governed by the extent of the lesion (Walls et al., 1968). Schrieiner (1979) emphasized that there is high evidence of hypertension in patients who recover from cortical necrosis and Kleinknecht et al. (1973) found that patients who recover, may exhibit a slower decline in renal functions associated with a progressive reduction in renal mass.

9. References

- Alwall N, Erlanson P, Tornberg A, Moell H, & Fajers CM. (1958). Two cases of gross renal cortical necrosis in pregnancy with severe oliguria and anuria for 116 and 79 days respectively; clinical course, roentgenological studies of the kidneys (size, outlines and calcifications), and post-mortem findings. *Acta Med Scand*, Vol. 161, No. 2, pp. 93-8.
- Blau EB, Dysart N, Fish A, Michael A, & Vernier R. (1971). Unilateral renal cortical necrosis. Case report and experimental observations. *Am J Dis Child*, Vol. 122, No. 1, pp. 31-3.
- Chugh KS, Singhal PC, Kher VK, Gupta VK, Malik GH, Narayan G, & Datta BN. (1983). Spectrum of acute cortical necrosis in Indian patients. *Am J Med Sci*, Vol. 286, No. 1, pp. 10-20.
- Chugh KS, Singhal PC, Sharma BK, Pal Y, Mathew MT, Dhall K, & Datta BN. (1976). Acute renal failure of obstetric origin. *Obstet Gynecol*, Vol. 48, No.6, pp.642-6.
- Duff GL, & More RH. (1941). Bilateral cortical necrosis of the kidney. *Am J Med Sci*, Vol. 201, pp. 429.
- Effersoe P, Raaschou F, Thomsen AC. (1962). Bilateral renal cortical necrosis. A patient followed up over eight years. *Am J Med*, Vol. 33, pp. 455-8.
- Gelfand MC, & Friedman EA. (1970). Prognosis of renal allotransplants in patients with bilateral renal cortical necrosis. *Transplantation*, Vol. 10, No. 5, pp. 442-6.

- Grünfeld JP, Ganeval D, & Bournérias F. (1980). Acute renal failure in pregnancy. *Kidney Int*, Vol. 18, No. 2, pp. 179-91.
- Hassan I, Junejo AM, & Dawani ML. (2009). Etiology and outcome of acute renal failure in pregnancy. *J Coll Physicians Surg Pak*, Vol. 19, No. 11, pp. 714-7.
- Kleinknecht D, Grünfeld JP, Gomez PC, Moreau JF, & Garcia-Torres R. (1973). Diagnostic procedures and long-term prognosis in bilateral renal cortical necrosis. *Kidney Int*, Vol. 4, No. 6, pp. 390-400.
- Lauler DP, Schreiner GE. (1958). Bilateral renal cortical necrosis. *Am J Med*, Vol. 24, No. 4, pp. 519-29.
- Matlin RA, & Gary NE. (1974). Acute cortical necrosis. Case report and review of the literature. *Am J Med*, Vol. 56, No. 1, pp. 110-8.
- Moell H. (1957). Gross bilateral renal cortical necrosis during long periods of oliguria-anuria; roentgenologic observations in two cases. *Acta radiol*, Vol. 48, No. 5, pp.355-60.
- Oram S, Ross G, Pell L, Winterler J. (1964). Renal cortical calcification after snake bite. *Am Heart J*, Vol. 67, pp. 714-5.
- Phillips MJ. (1962). Bilateral renal cortical necrosis associated with calcification: report of a case and a review of etiology. *J Clin Pathol*, Vol. 15, No. 1, pp. 31-5.
- Prakash J, Tripathi K, Pandey LK, Sahai S, Usha, & Srivastava PK. (1995). Spectrum of renal cortical necrosis in acute renal failure in eastern India. *Postgrad Med J*, Vol. 71, No. 834, pp. 208-10.
- Schreiner GE. (1979) Bilateral cortical necrosis. In: Hamburger J, Crosnier J, Grunfeld JP (Eds): *Nephrology*. New York, Wiley, pp. 411-30.
- Sefczek RJ, Beckman I, Lupetin AR, & Dash N. (1984). Sonography of acute renal cortical necrosis. *AJR Am J Roentgenol*, Vol. 142, No. 3, pp. 553-4.
- Sheehan HL, & Moore HC. (1952). *Renal cortical necrosis and the kidney of concealed accidental haemorrhage*. Blackwell, Oxford.
- Sheldon WH, & Hertig A. (1942). Bilateral cortical necrosis of the kidney. A report of 2 cases. *Arch Pathol*, Vol. 34, pp. 866.
- Sporn IN. (1978). Renal cortical necrosis. *Arch Intern Med*, Vol. 138, No.12, pp. 1866.
- Moss SW, Gary NE, & Eisinger RP. (1977). Renal cortical necrosis following streptococcal infection. *Arch Intern Med*, Vol. 137, No. 9, pp. 1196-7.
- Walls J, Schorr WJ, Kerr DN. (1968). Prolonged oliguria with survival in acute bilateral cortical necrosis. *Br Med J*, Vol. 26, No. 4, pp. 220-2.



Topics in Renal Biopsy and Pathology

Edited by Dr. Muhammed Mubarak

ISBN 978-953-51-0477-3

Hard cover, 284 pages

Publisher InTech

Published online 04, April, 2012

Published in print edition April, 2012

There is no dearth of high-quality books on renal biopsy and pathology in the market. These are either single author or multi-author books, written by world authorities in their respective areas, mostly from the developed world. The vast scholarly potential of authors in the developing countries remains underutilized. Most of the books share the classical monotony of the topics or subjects covered in the book. The current book is a unique adventure in that it bears a truly international outlook and incorporates a variety of topics, which make the book a very interesting project. The authors of the present book hail not only from the developed world, but also many developing countries. The authors belong not only to US but also to Europe as well as to Pakistan and Japan. The scientific content of the book is equally varied, spanning the spectrum of technical issues of biopsy procurement, to pathological examination, to individual disease entities, renal graft pathology, pathophysiology of renal disorders, to practice guidelines.

How to reference

In order to correctly reference this scholarly work, feel free to copy and paste the following:

Manohar Lal (2012). Acute Renal Cortical Necrosis, Topics in Renal Biopsy and Pathology, Dr. Muhammed Mubarak (Ed.), ISBN: 978-953-51-0477-3, InTech, Available from: <http://www.intechopen.com/books/topics-in-renal-biopsy-and-pathology/acute-renal-cortical-necrosis>

INTECH
open science | open minds

InTech Europe

University Campus STeP Ri
Slavka Krautzeka 83/A
51000 Rijeka, Croatia
Phone: +385 (51) 770 447
Fax: +385 (51) 686 166
www.intechopen.com

InTech China

Unit 405, Office Block, Hotel Equatorial Shanghai
No.65, Yan An Road (West), Shanghai, 200040, China
中国上海市延安西路65号上海国际贵都大饭店办公楼405单元
Phone: +86-21-62489820
Fax: +86-21-62489821

© 2012 The Author(s). Licensee IntechOpen. This is an open access article distributed under the terms of the [Creative Commons Attribution 3.0 License](#), which permits unrestricted use, distribution, and reproduction in any medium, provided the original work is properly cited.

IntechOpen

IntechOpen