

# We are IntechOpen, the world's leading publisher of Open Access books Built by scientists, for scientists

**4,800**

Open access books available

**122,000**

International authors and editors

**135M**

Downloads

Our authors are among the

**154**

Countries delivered to

**TOP 1%**

most cited scientists

**12.2%**

Contributors from top 500 universities



**WEB OF SCIENCE™**

Selection of our books indexed in the Book Citation Index  
in Web of Science™ Core Collection (BKCI)

Interested in publishing with us?  
Contact [book.department@intechopen.com](mailto:book.department@intechopen.com)

Numbers displayed above are based on latest data collected.

For more information visit [www.intechopen.com](http://www.intechopen.com)



# Skull Expansion by Spring-Mediated Bone Regeneration

Rodrigo Dornelles, Vera Cardim  
and Nivaldo Alonso  
*University of São Paulo  
Brazil*

## 1. Introduction

Paleontologists discovered the skull of a *Homo heidelbergensis* individual, ancestor of the 530-thousand-year-old Neanderthal, that belonged to a craniosynostotic child aged between five and 12 years, in the Spanish province of Burgos, and dated the oldest case of this condition. There was a time when cranial malformations were considered a result of divine or supernatural reasons and there are pictures of Chinese gods that display tall heads or great projections in their frontal region. (Guimarães-Ferreira, Miguéns et al. 2004) To such an extent that this intentional cranial deformation became part of the culture of ancient peoples. In the Americas, cases dated 8000 BC and this tradition only ceased in 1752 under the Spanish colonial domain. As a result of this intentional deformation, by distorting the normal directions of cranial growth, there is a change in the normal process of cranial suture closure. Many of these skulls presented premature suture ossification whereas others presented sutures that remained with no closure until more advanced age (Abreu 2002; Tubino and Alves 2009).

The famous work “*De Vulneribus Capitis Liber*”, by Hippocrates (460-367 BC) apud Guimarães-Ferreira (Guimarães-Ferreira, Miguéns et al. 2004), begins with the sentences: “Human heads are not similar among themselves. Neither are sutures the same in terms of number and location”, as an evidence that the variability of cranial sutures and their closures were already observed.

Craniofacial sutures are important regions for facial and cranial bone growth with major development during embryogenesis. Their important functions are twofold:

1. Maintaining skull malleability during the passage through the birth canal.
2. Enabling the separation between cranial bones during intrauterine and perinatal life.

Craniosynostosis is the premature fusion of one or more cranial sutures with resultant cranial and/or facial deformity and affects approximately one in 1,700 to 4,000 live births (Renier, Le Merrer et al. 2006). In addition to shape, function may also be compromised because limitation in development can cause increased intracranial pressure, visual disorders, mental retardation, among other anomalies. (Guimarães-Ferreira, Miguéns et al. 2004; Renier, Le Merrer et al. 2006).

Lycosthene (1557) described a child with deformities in skull and limbs, acrocephalosyndactyly, which was later described by Apert (1906)\* apud McCarthy (McCarthy, Epstein et al. 1990).

The term craniosynostosis was first used by Otto in 1830 (McCarthy, Epstein et al. 1990; Slater, Lenton et al. 2008), however, Rudolf Ludwig Carl Virchow\*, in 1851, published an article still important to date describing a series of 29 skulls with malformations in an attempt to elucidate cases of cretinism. Virchow quotes Stahl, Gibson and Sommering, and Hyrtl as pioneers of the idea that the premature closure of a cranial suture leads to cranial deformation, but indicates compensations during growth and attempts to establish predictive general patterns, apud Persing (Persing, Jane et al. 1989).

- Apert, E. De l'acrocephalosyndactylie. Bull. Soc. Med. Hop. Paris, 23:1310,1906
- Virchow, R. Ueber den Cretinismus, namentlich in Franken, und ueber pathologische Schädelformen. Verh. Physikalisch. Med. Ges. Wurzburg 2:230,185

## 1.1 Aim

The aim of this study is:

To evaluate bone regeneration and cephalometric changes with the implantation of expandable springs in the interparietal and parasagittal region in post-craniectomy rabbits through radiologic and histologic analyses.

## 2. History of treatments

### 2.1 Craniectomies

Lannelongue (1890)\* apud Guimarães (Guimarães-Ferreira, Miguéns et al. 2004) reported the first surgical treatment with strip craniectomy and for many years, despite the high morbidity of this procedure, surgeries utilizing craniectomy of involved sutures were performed. In the mid-twentieth century, many surgeons produced techniques for cranial reshaping with complex osteotomies, surgeries for removing involved sutures and, in some cases, of those not involved, resulting in cases of extensive cranial bone resections with post-operative protection with helmets, taking into consideration that reossification is unpredictable. The interposition of materials between sutures and caustic substances to inhibit suture closure and other procedures also presented high morbidity with elevated rates of mortality additionally had their indications (Guimarães-Ferreira, Miguéns et al. 2004; Greensmith, Holmes et al. 2008).

The first correction techniques were developed in order to prevent the evolution towards an increase in intracranial pressure (ICP) and/or mental retardation. The modern techniques, introduced by Tessier (Tessier 1971), also tried to correct dysmorphia preserving the psychological balance of children (Arnaud, Marchac et al. 2006). In the 14th International Plastic Surgery Congress (1967), held in Rome, Paul Tessier baffled the scientific community by exhibiting his results on the treatment of craniofacial stenoses with endocranial approach. Using techniques developed from his experience in the treatment of complex craniofacial and Le Fort I, II and III fractures, he demonstrated a multidisciplinary approach with results that revolutionized the history and changed the treatment of craniosynostoses.

Afterwards, with the introduction of rigid internal fixation materials, i.e. microfixation plates and screws, at first made of titanium and recently of absorbable material, there has been an evolution in approach, as described by Marchac (Marchac and Renier 1979), Ortiz-Monastério (Ortiz-Monasterio, Fuente del Campo et al. 1978), Van Der Meulen\* apud McCarthy (McCarthy, Epstein et al. 1990), and others.

If craniosynostosis is not corrected, the deformity progresses involving the facial skeleton and may cause changes in facial symmetry and malocclusion. We may state that, therefore, in order to reduce craniofacial changes resulting from synostosis, the surgery must be performed early because (Panchal and Uttchin 2003) :

- With brain growth, altered growth vectors will cause greater deformity as individual ages.
- There is an increase in intracranial pressure in nonsyndromic single-suture craniosynostoses (Gault, Renier et al. 1992; Heller, Heller et al. 2008). In experimental models, compensatory changes in the neurocranium do not allow the adequate expansion of the neurocapsular matrix (Singhal, Mooney et al. 1997).
- Before one year of age, bone defects ossify in an efficacious manner.
- Delay in performing corrections in the first nine to 12 months causes deformities in the cranial base with abnormal facial growth with maxillary and mandibular asymmetry.
- From three to nine months cranial bones are malleable.

Current techniques present some problems related to bone detachment, both from the subperiosteum and dura mater (Arnaud, Marchac et al. 2006). Namely regarding infants, considering complementary surgeries will have a greater degree of difficulty. Whenever increase in ICP occurs, or in cases of pansynostoses, marking of cerebral convolutions in the inner table, indicated by the so-called copper-beaten appearance in radiographic evidence, greater difficulty of detachment with increased blood loss and risks of approach on the venous sinuses is added. Furthermore, the detachment of functioning sutures is equally difficult, due to adherences.

In cases of extensive cranioplasty, with great dura mater detachment, there is a risk of extradural dead space with hematoma formation. Although this is a rare event, it is especially undesirable when airways are manipulated, as in those cases for correcting craniofacial stenoses.

- Lannelongue, J. De la craniectomie dans la microcephalie. C. R. Acad. Sci., 110:1382, 1890
- Van der Meulen, J. C. Medial faciotomy. Br. J. Plast. Surg., 32:339, 1979

## 2.2 Osteogenic distraction

The fundamentals of the so-called osteogenic distraction date back the early work conducted by Codivilla\* (1905) apud McCarthy (McCarthy, Stelnicki et al. 2001), with the denominated "continuous lengthening" and further applied to long bones by Ilizarov et al. (Ilizarov 1989; McCarthy, Schreiber et al. 1992). These authors established the principles of bone elongation for the treatment of bone defects and non-union for the upper and lower extremities. Wasmund (1926)\* and Rosenthal (1927)\* apud Hönig (Hönig, Grohmann et al. 2001) described, respectively, bone distraction for mandibular elongation using intraoral devices

with progressive mechanical activation and advancement of the maxilla mediated by elastic forces. For nearly 50 years, this possibility of treatment was disregarded by the scientific community, but interest arose with the study conducted by Snyder et al. (Snyder, Levine et al. 1973) that published an article reporting mandibular elongation in dogs for correcting crossbite in 1973.

This technique consists in the use of an external device attached to two pins with threaded adjustment that enables lengthening of the distance between them. The pins are placed in the bone to be elongated and a corticotomy is performed between them. Afterwards, distraction is progressively and constantly carried out until reaching the desired elongation. In the gap between the separated stumps, a bone callus is formed. After distraction is performed, a period of time is allowed for consolidation and the device is removed.

McCarthy et al. (McCarthy, Schreiber et al. 1992) published their first successful cases of mandibular osteogenic distraction in humans (Figure 25) and the consolidation of this technique for the treatment of mandibular osteogenic distraction happened with the series of cases published by Ortiz-Monasterio and Molina (Ortiz-Monasterio and Molina 1994; Molina and Ortiz-Monasterio 1995).

Osteogenic distraction progressed as treatment for changes in the craniofacial skeleton and was applied for maxillary distraction with Le Fort I and III osteotomies and frontofacial advancements. One of its last indications was cranial distraction. In 1997, Tung et al. (Tung, Robertson et al. 1999) published an experimental study of osteogenic distraction in membranous bones of the craniofacial skeleton in rabbits affecting cranial volume and skull shape. In this study an external distractor was used on the cranial suture with no osteotomy.

The advantages of this method include (Guimarães-Ferreira, Miguéns et al. 2004):

1. Bone neoformation preventing bone grafts and intermaxillary fixation.
2. Preventing dura mater dissection by creating dead space, limiting infection risks, need for transfusion and bone reabsorption.
3. Concurrent expansion of adjacent soft tissues.

Osteogenic distraction was found to be a promising form of treatment in cranial vault bones (Imai, Komune et al. 2002), so that the principles of less detachment and procedure morbidity reduction could be applied in the treatment of craniosynostosis.

- Codivilla, A. On the means of lengthening in the lower limbs, the muscles and tissues which are shortened through deformity. *Am. J. Orthop. Surg.* 2:353, 1905
- Wassmund, M. *Frankturen und Luxationen des Gesichtschädels.* Berlin : Meuser, 1926. P.360
- Rosenthal, W. In E. Sonntag and W. Rosenthal (Eds.), *Lehrbuch der Mund und Kieferchirurgie.* Leipzig; Georg. Thieme, 1930. Pp. 173-175

### 2.3 Expansile springs

In classic physics, a spring may be regarded as a device that stores potential energy by stretching the ligations among atoms from the same elastic material.

Hooke's law (wikipedia 2009) is the law of physics related to the elasticity of materials used to calculate the deformation caused by the force exerted on a body that equals to the

displacement of the mass from its equilibrium position times the constant feature of the spring or body that will endure deformation:

$$F = k \cdot \Delta l$$

In the International System of Units (SI),  $F$  is expressed in newtons,  $k$  in newton/meter and  $\Delta l$  in meters.

The force produced by a spring is directly proportional to its displacement from its initial position (equilibrium). Spring equilibrium occurs when it is in its natural state, i.e. without being compressed or stretched. After compressing or stretching a spring, it pulls back and its force is calculated by the equation above.

The principles were already applied in remodeling facial skeleton, for instance in palatal expansion (Haas 1970). In 1986, Persing et al. (Persing, Babler et al. 1986) described a cranial expansion using a device named spring. In this study the authors were able to reverse abnormalities produced by brachycephaly caused by the premature restriction in sutural development. Results from the study carried out in rabbits were shown to be better than those obtained with linear craniectomy of suture alone. Subsequently, an expansion of the skull base and the suture contralateral to that affected with the use of springs was observed (Persing, Morgan et al. 1991).

The first clinical description of a cranioplasty using expansible springs dates back to 1998 (Lauritzen, Sugawara et al. 1998), in which the principle of the dynamic expansion of internal implantable springs was used (Lauritzen, Sugawara et al. 1998; Lauritzen and Tarnow 2003). This study consisted in linear craniectomies with spring interposition in order to stimulate bone edges in an expansive or compressive manner (or both). Unlike other external distractors, it was totally implantable and reduced the risks of using pins and screws for activation. The action of springs in infant skulls with malleable bones of membranous nature is not exclusively restricted to bone edges, but extends to adjacent cranial vault. In the first 100 cases, Lauritzen et al. (Lauritzen, Davis et al. 2008) indicated springs for treating metopic, bicoronal, multisutural synostosis, advancements of the middle third of the face, and others. No serious complications were observed.

In 2001, an experimental study was published demonstrating a change in the form of cranial growth in rabbits using springs (Gewalli, Guimaraes-Ferreira et al. 2001).

In 2008, Cardim et al., based on their experience with elastic distraction of the middle third of the face (Cardim, Dornelles et al. 2002), published their experiment using expansible springs conducted since 2002 for treating craniosynostosis and craniofacial stenoses (Dornelles, Cardim et al. 2007). In this series, scaphocephaly patients underwent spring placement through bilateral parasagittal linear craniotomy, which yielded satisfactory cranial expansion and reshaping results, even when the synostotic suture was maintained.

Mackenzie et al. (Mackenzie, Davis et al. 2009) published their first comparative study of craniosynostosis treatments with craniectomy, cranioplasty with absorbable plates and use of expansible springs. Blood loss, operative time and hospital stay were evaluated. The study concluded that the use of springs provide adequate skull shape and present minimal morbidity.



Skull expansion with totally implantable springs differs from the principles of osteogenic distraction because there is no latency period and the effect of the spring starts at the very moment it is placed by exerting a continuous force with no external control. No control of ossification at the osteotomy site is verified and spring expansion ceases prior to its total opening capacity. The indication, number and force of springs, as well as their implantation site are determined. (Pyle, Glazier et al. 2009)

### 3. Material and method

#### 3.1 Material

Thirteen female New Zealand white rabbits (*Oryctolagus cuniculus*) aged four weeks with mean weight of 2,400 g, from the Central Animal Facility of the São Paulo University Medical School (FMUSP), were used for this study. The study was conducted in the Microsurgery Experimental Laboratory (LIM4) at FMUSP. This research complied with the ethical principles for animal experiments established by the Brazilian College of Animal Experimentation (COBEA) and the rules in the Guide for Care and Use of Laboratory Animals (Institute of Laboratory Animal Resources, Commission on Life Science, National Research Council, Washington, DC, 1996). All animals remained in the animal facility of this laboratory during the experimental period. All animals were separately housed in individual cages, were fed pellets and given water ad libitum on a 12-hour light-dark cycle at room temperature of 21°C.

In order to analyze the changes in rabbit skulls under the action of expansible springs, the animals were divided into four groups as follows:

	<ul style="list-style-type: none"> <li>• GROUP I</li> <li>• Parasagittal amalgam markers were placed on the cranial vault</li> <li>• ONE ANIMAL</li> </ul>
	<ul style="list-style-type: none"> <li>• GROUP II</li> <li>• Parasagittal amalgam markers were placed and a craniectomy was performed along the sagittal suture</li> <li>• FOUR ANIMALS</li> </ul>



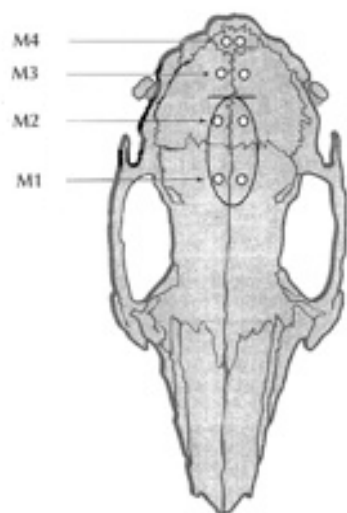
	<ul style="list-style-type: none"> <li>• GROUP III</li> <li>• Parasagittal amalgam markers were placed and springs were placed in the suturectomy site</li> <li>• FOUR ANIMALS</li> </ul>
	<ul style="list-style-type: none"> <li>• GROUP IV</li> <li>• Parasagittal amalgam markers were placed and springs were implanted parallel to the sagittal suture with no suturectomy</li> <li>• FOUR ANIMALS</li> </ul>

Table 1. Groups



- M1 - Marker 1: 5 mm (either side) of the midline and 5 mm anterior to the coronal suture;
- M2 - Marker 2: 5 mm (either side) of the midline and 5 mm posterior to the coronal suture;
- M3 - Marker 3: 5 mm (either side) of the midline and 5 mm anterior to the lambdoid suture;
- M4 - Marker 4: 3 mm (either side) of the midline and 5 mm posterior to the lambdoid suture.
- spring placement between M2 e M3

Table 2. Schematic representation of marker and spring placement

### 3.2 Springs

Springs were manually manufactured by the first author from nickel-chromium stiff elastic wire for orthodontics. A 0.020"-bend diameter wire with 18-mm arm length and 25-mm deflection range at rest was used. For the purpose of obtaining prior standardization, all springs had their expansion force checked by a WAFIOS WG 3/2® dynamometer. Mean



force obtained from measurements was 335 grams force (Schneider and De Souza 2003) with 2-mm opening.

### 3.3 Procedure

All rabbits were anesthetized with IM injections of ketamine hydrochloride (35 mg/kg) associated with xylazine hydrochloride (5 mg/kg). Trichotomy in the cranial region from the nasion to the occipital region was performed.

After anesthesia, a local infiltration of 0.2%-lidocaine hydrochloride with 1:200,000 adrenaline (final concentration) was administered, respecting the maximum dose of 7mg/kg for lidocaine.

After trichotomy was carried out in rabbit skulls, the animals were placed in ventral decubitus position. Antisepsis with chlorhexidine gluconate was applied in all the animal heads followed by the placement of sterile drapes.

Surgical approach was performed through a 20-mm longitudinal incision in the cranial region exposing the sagittal suture with minimal periosteal detachment.

Amalgam markers were placed in all rabbit skulls through craniotomy using a low-rotation micro motor with round bur of 1.8 mm in diameter.

In order to obtain spring maintenance at the placement site, an incisure was made in the bone edges between M2 and M3.

All animals received a single dose of IM benzathine benzilpenicillin 100.000 IU/kg.

In group I amalgam markers were placed and no craniotomy was performed. The incision was sutured closed through the approximation and fixation of tissues with continuous stitches using 5-0 monofilament nylon thread.

In group II, a 1.8-mm wide strip craniotomy was done including the sagittal suture reaching one millimeter beyond the coronal and lambdoid sutures. Sagittal suturectomy was performed using a low-rotation round bur with 1.8 mm in diameter. The incision was sutured closed through the approximation and fixation of tissues with continuous stitches using 5-0 monofilament nylon thread.

In group III, a 1.8-mm wide strip craniotomy was done including the sagittal suture reaching one millimeter beyond the coronal and lambdoid sutures. Osteotomy was performed using a low-rotation round bur with 1.8 mm in diameter. The spring was positioned with minimal dura mater detachment in the stipulated position between M2 and M3. Fixation was maintained by the spring force in the bone incisures made on the edge of the craniotomy. The incision was sutured closed through the approximation and fixation of tissues with continuous stitches using 5-0 monofilament nylon thread.

In group IV, a 1.8-mm wide strip craniectomy was performed in the right parasagittal region and a spring was placed in the stipulated position. The incision was sutured closed through the approximation and fixation of tissues with continuous stitches using 5-0 monofilament nylon thread.

### 3.4 Evaluation

The evaluation of new bone formation of the effects from springs in the sagittal and parasagittal region was carried out for all groups at weeks two, four, eight, and twelve after the surgery for spring placement. Longitudinal body weight recordings were obtained from rabbits at each time point, radiographs were taken and all animals were euthanized with the anesthetic solution previously described through subsequent asphyxia in an individual carbon dioxide (CO<sub>2</sub>) chamber and operated on for harvesting tissue sample from the cranial vault for histopathologic analysis.

In order to obtain histopathologic data for assessing new bone formation, samples for post mortem analysis were collected from a segment containing involved suture with anterior and posterior bone edges. A quadrangular shaped osteotomy was performed using low speed bur with 1.8 mm in diameter and the bone fragment was separated from the cranial vault preserving its continuity with the dura mater.

Fragments preserved in 10%-formaldehyde solution were sent to the Buccal Pathology Department of the Odontology School of São Paulo University where they were fixed in 10%-buffered formaldehyde solution and decalcified in 5% formic acid. The material was dehydrated in increasing ethanol concentrations, deparaffinized in xylene and embedded in paraffin. A series of tissue sections was obtained from cuts perpendicular to the osteotomy line with 5µm thickness. Sections comprised the cranial and the caudal transverse perspective of the intermediate distance from M2 and M3, consistent with spring support. Histologic analysis was carried out with material stained with hematoxylin and eosin (Alberius, Malmberg et al.).

Histologic evaluation was carried out with a Zeiss® microscope, Axio Imager A1 model, magnification 100x, by a pathologist for the areas of interest. The following parameters were chosen for assessment:

- Granulation tissue
- Osteoblasts
- Osteoclasts
- Bone trabeculae

Parameters were evaluated with the following classification:

- (-) absence
- (+) little/scarce
- (++) moderate
- (+++)

For granulation tissue and bone trabeculae, the evaluation took into consideration:

- (+) up to 25% of defect
- (++) up to 50% of defect
- (+++)

To obtain craniometric data and evaluate the variation of the distance between amalgam markers, radiographs of rabbit skulls were taken in the facilities of the Radiology Department of the Veterinary School of São Paulo University. All animals were anesthetized

as previously described to allow their adequate positioning for radiographic projections with distance standardized at one meter. They were subsequently placed in ventral decubitus position to provide ventrodorsal projection and in lateral decubitus position to provide lateral projection.

A centimeter-scale lead marker was placed beside the skull, above the neck, at the same vertical distance as the device to provide gauging at the moment the distances between amalgam markers were measured and to standardize findings.

A 500-mA, 125-k V diagnostic x-ray unit, RT 500/125 model (RAY-TEC®, Brazil) with a microprocessor controlled system, full-wave, rectified silicon generator, radiographic table with anti-scatter grid, recipromatic Bucky, and rotating anode x-ray tube was used in radiographic examinations. TMS-1® and MXG/PLUS®, 24x30-cm radiographic films were used and placed on a metal chassis with CRONEX HI plus® intensifier screens. Films were developed and fixed in an Automatic RPX-OMAT Processor®, after appropriate luminescent identification.

All measurements were made with image digitalization and calculated by the first author using MIRROR® (Canfield Imaging Systems, Fairfield, NJ) software. Metric gauging was done using a lead marker, as well as linear measurement. In ventrodorsal projections, the distance between amalgam markers was measured using the center of the positions M1, M2, M3, and M4 as reference. In lateral projection, for the determination of points to be used as reference for cranial base measurement, the following diagram was used (Figure 1):

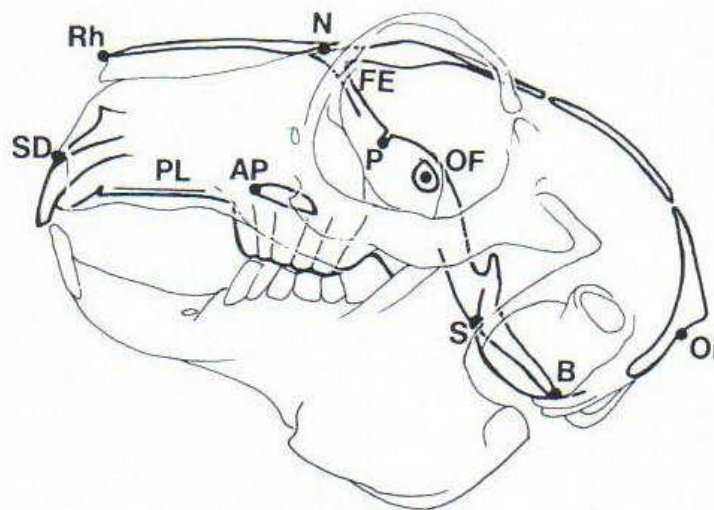


Fig. 1. Rabbit skull schematic diagram with craniometric points used for measuring cranial base length.

Where:

FE-P – Cribform plate length (anterior cranial base)

P-S – Pre-sphenoid length

S-B – Posterior cranial base length

For measuring lateral projection, the following craniometric points were used: (Figure 2):

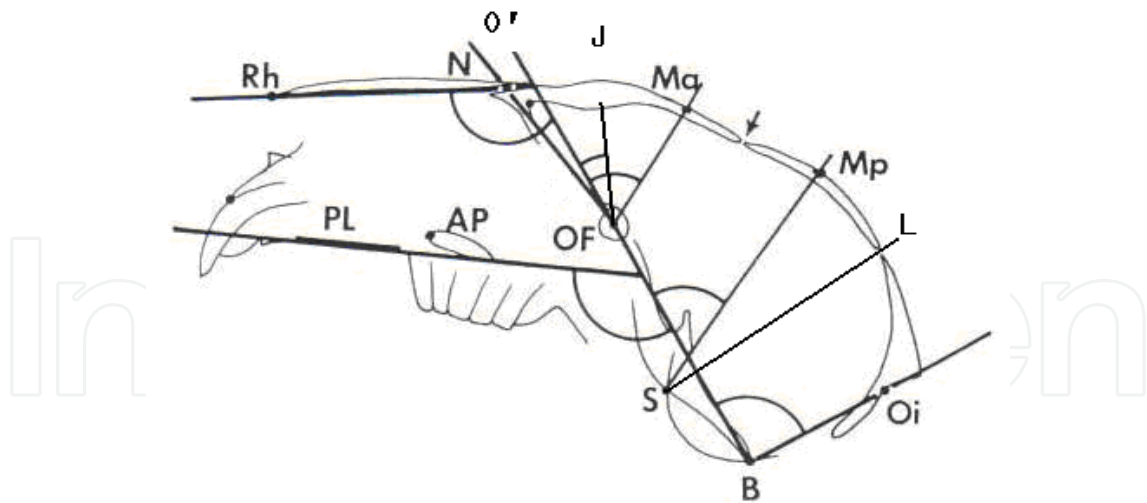


Fig. 2. Rabbit skull schematic diagram, lateral view with cephalometric points and angles.

Where:

O - a point in the center of the optic foramen

O<sub>i</sub> - the deepest point in the outer contour of the occipital bone between the foramen magnum and the external occipital protuberance

M<sub>p</sub> - the most posterior point on the anterior marker in the left parietal bone

M<sub>a</sub> - the most anterior point on the posterior marker in the left frontal bone

J - the tip of the endocranial ridge in which the frontal bone separates the anterior and the middle cranial fossae

S - the deepest point on the cartilaginous spheno-occipital synchondrosis

PL - a line tangential to the lower rim of the hard palate

BO' - the extension of the line through the points B and O

The following angles were obtained:

BO'/PL - angle formed between and below the lines BO' and PL (maxillary-basilar angle)

BO'/RhN - angle formed between and above the lines BO' and RhN (rhino-basilar angle)

BO'/NO - angle formed between and above the lines BO' and NO (naso-basilar angle)

BO'/JO - angle formed between and above the lines BO' and JO (basilar-olfactory angle)

BO'/MaO - angle formed between and above the lines BO' and MaO (anterior mark-basilar angle)

BO'/MpS - angle formed between and above the lines BO' and MpS (posterior mark-basilar angle)

BO'/LS - angle formed between and above the lines BO' and LS (lambdoid-basilar angle)

BO'/BO<sub>i</sub> - angle formed between and above the lines BO' and BO<sub>i</sub> (foraminal-basilar angle)

### 3.5 Method for data evaluation

This study was observational and descriptive, in which artificial intelligence techniques were used through the applications of annotated paraconsistent logic in order to parametrize and contextualize craniometric variables.

Whenever a rabbit variable was entered into one of the fields, it was compared with a normal variable from the data bank containing means of normal variables that, for the purpose of this study, were considered as those from the rabbit in group I.

Parametrization was carried out within the working interval for paraconsistent logic, i.e. values between "0" and "1" were attributed. All normal variables received value "1" and rabbit variables, proportional values according to the following criterion: if a rabbit variable equaled the normal variable, a degree of abnormality evidence = 0 was attributed to that variable. The degree of abnormality evidence, therefore, was an indicator of the discrepancy between the measurement of the animal variable and a normal variable.

The degree of abnormality evidence of a rabbit variable was close to 1 when its measurement was approximately threefold the standard deviation value established for that variable in the data bank used in this study.

All angular measurements were contextualized with cranial base measurement, so that firstly normalization of measurements was carried out using the following equation (1):

$$x = 1 / (1 + (\text{reference} / \text{measurement}))^{|\text{measurement} - \text{reference}|} \quad (1)$$

Where:

x - normalization

Reference - normal variable

Measurement - measurement variable

Next, the basic structural equation (BSE) of the paraconsistent logic was applied in order to contextualize the measurement through the equation (2):

$$\mu r = ((\mu - \lambda) + 1) / 2 \quad (2)$$

Where:

$\mu r$  - resultant degree of evidence

$\mu$  - favorable evidence ( $\mu = x$ , which will be the measurement of the cranial base)

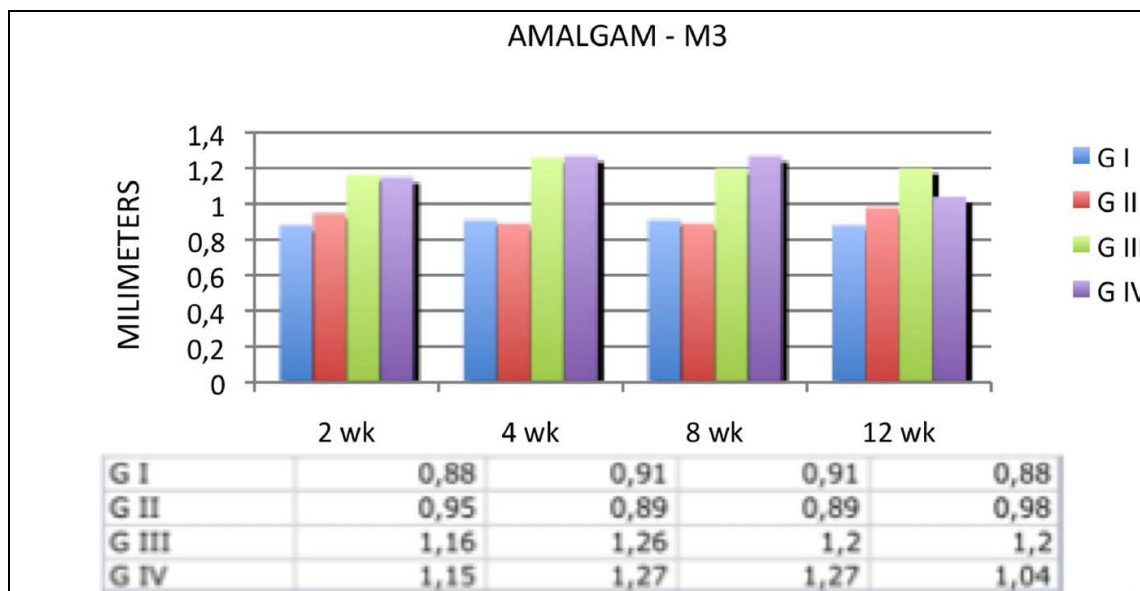
$\lambda$  - contrary evidence (in this case  $\lambda = y$ , where y is the normalized measurement)

The curve of evidence degree variation for each variable was molded with standard deviation ranging in accordance with variable values. Such effect caused the curves to have features of different inclinations according to different variable values, as well as symmetrical shape, what made them to be closer to real cases.

## 4. Results

### 4.1 Radiologic aspects

Considering the parameter of implanted amalgam markers, cranial expansion occurred so that the distance between markers at the M3 position was greater in the groups with springs than in those without springs at all time points studied. Measured values are presented in the graph. (Graph 1).



Graph 1. Results measured in millimeters between amalgam markers at M3.

Angle measurements were tabulated and are presented in Tables 3, 4, 5, and 6:

Group I

	2 wk		4 wk		8 wk		12 wk	
	Pré	Pós	Pré	Pós	Pré	Pós	Pré	Pós
BO'NO	9,3	13,8	9,3	12,1	9,3	15	9,3	13,6
BO'/RhN	116,8	119,9	116,8	122,8	116,8	123,2	116,8	120,9
BO'/MaO	59,1	55,3	59,1	54	59,1	55,3	59,1	61,9
BO'/PL	120,9	119,5	12,9	123,4	120,9	124,9	120,9	120,7
BO'/MpS	68,4	69	68,4	71,3	68,4	74	68,4	70,1
BO'/Boi	83	77,2	83	75,3	83	75,2	83	71
BO'/LS	68,4	79,1	68,4	82,3	68,4	85	68,4	80,5
BO'/JO	22,4	29,4	22,4	31,3	22,4	33,6	22,4	30,7

Table 3. Results of angles obtained in Group I

Group II

	2 wks		4 wks		8 wks		12 wks	
	Pré	Pós	Pré	Pós	Pré	Pós	Pré	Pós
BO'NO	12,9	10,2	11,5	11,4	13,5	10,7	13	12,1
BO'/RhN	122,4	120,2	123,5	120,5	119,7	122,9	119	122,7
BO'/MaO	64	63,5	54,2	53,5	69,6	50	68,2	62,3
BO'/PL	119,8	119,7	122,2	120,5	116,9	121,4	119,9	120
BO'/MpS	68,6	71	79,5	71,3	72,5	76,2	67,4	71,1
BO'/Boi	79,7	76,5	97,9	85,4	81,2	81,3	75,5	75,6
BO'/LS	81,3	86,6	94	87,9	84,3	92,2	78,5	86,9
BO'/JO	24,5	24,9	29,1	24	28,7	26	28,7	28,9

Table 4. Results of angles obtained in Group II

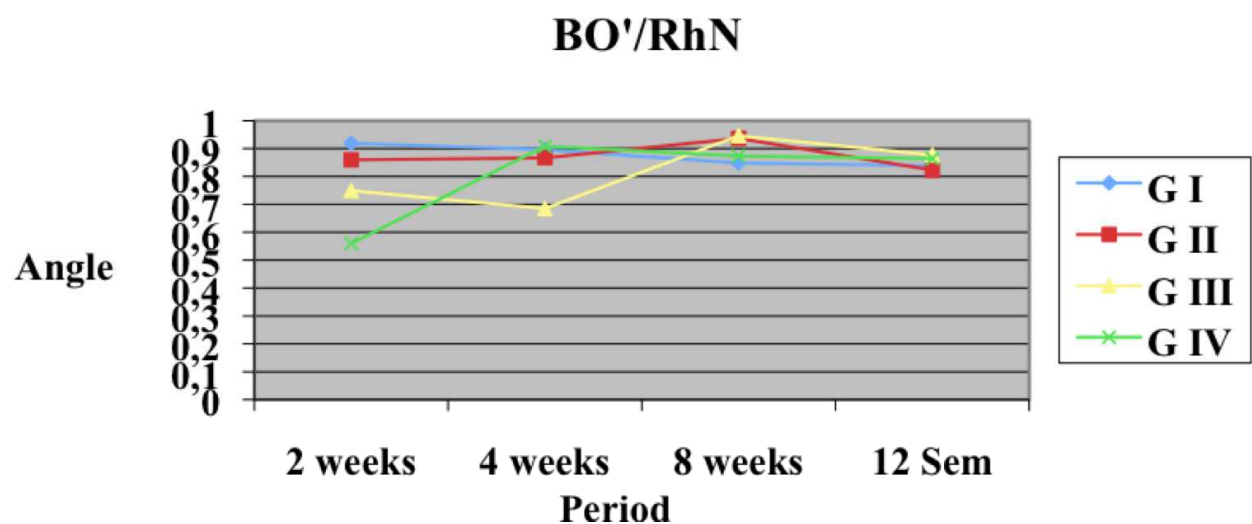
Group III								
	2 wks		4 wks		8 wks		12 wks	
	Pré	Pós	Pré	Pós	Pré	Pós	Pré	Pós
BO'NO	10,5	11,5	10,4	10,1	8,6	15,1	7,5	13,2
BO'/RhN	122,1	120,7	121,1	121,8	124	120,2	128,1	121,9
BO'/MaO	69	48,5	55,6	55,1	67,2	50	51,4	58,9
BO'/PL	121,1	118,7	123,8	123	121,3	119,9	124,2	116,5
BO'/MpS	74,8	68,6	71,5	70,5	73,6	70,5	72,9	69,3
BO'/Boi	77,2	78	81,8	80,6	71,5	75,2	78,8	74,7
BO'/LS	88,7	88,1	90	90	91,9	87,7	88,2	86,1
BO'/JO	25,6	23,2	20,4	27,4	24,4	22,5	26,7	30,8

Table 5. Results of angles obtained in Group III

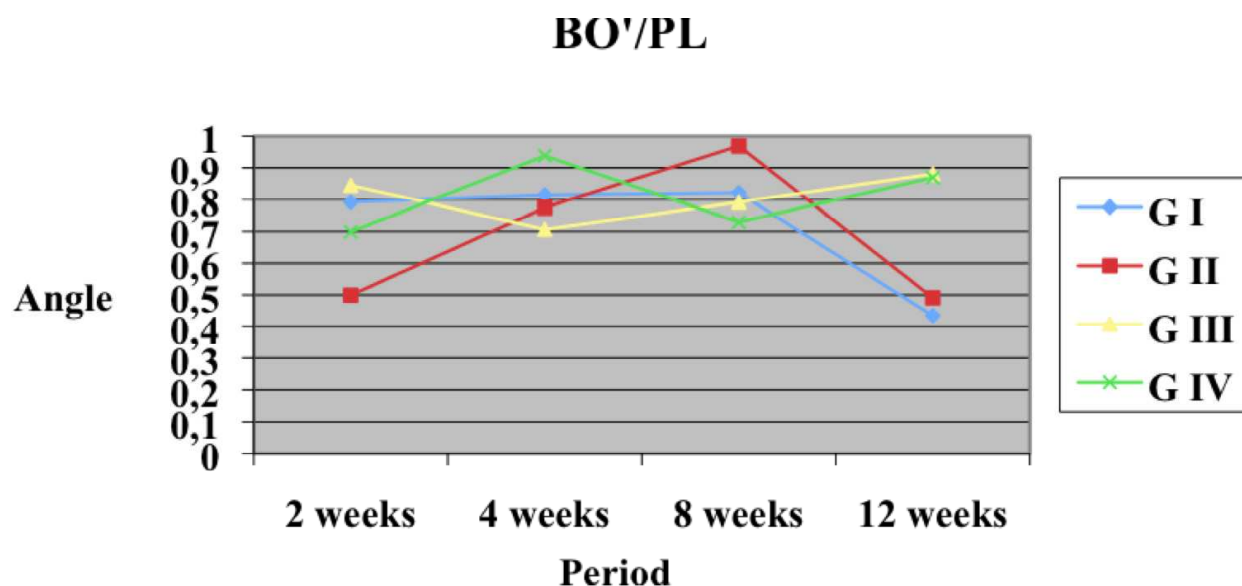
Group IV								
	2 wks		4 wks		8 wks		12 wks	
	Pré	Pós	Pré	Pós	Pré	Pós	Pré	Pós
BO'NO	10,1	9,8	10,5	12,1	9,5	13,1	5,9	12,3
BO'/RhN	121,8	122,1	122,9	120,2	125,5	121,6	123,1	118,5
BO'/MaO	45,7	54,7	61,7	52,6	51,8	51,4	56,5	55,4
BO'/PL	122,6	121,7	122,5	119,1	123,3	121,8	124	119,1
BO'/MpS	70,3	65,7	79,8	70,3	74,9	72,2	76,3	71,7
BO'/BOi	79,5	71	81,2	78	78,5	76,6	78,3	77
BO'/LS	89,4	92,8	92,7	89,5	90,2	86,9	92,2	88,5
BO'/JO	27,1	31,3	28,9	28,8	26,4	26	28	28,5

Table 6. Results of angles obtained in Group IV

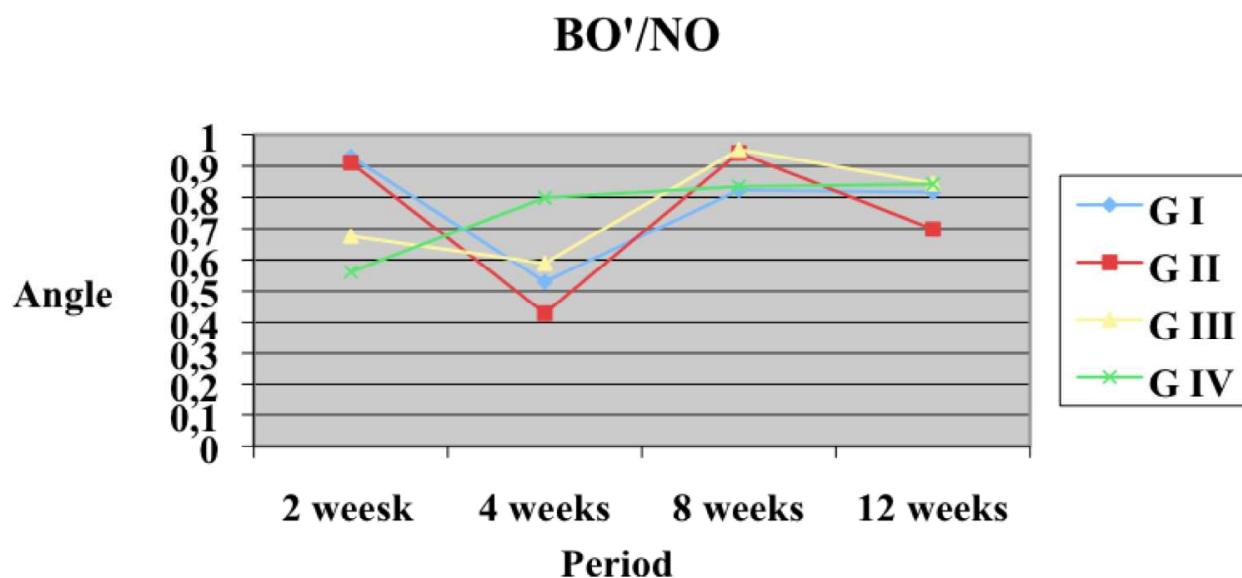
After all measurements were normalized and contextualized, the results were transferred to graphs, so that changes are presented in Graphs 2, 3 and 4.



Graph 2. Graphic representation of the contextualized measurements of BO'/RhN angle.



Graph 3. Graphic representation of the contextualized measurements of BO'/PL angle.



Graph 4. Graphic representation of the contextualized measurements of BO'/NO angle.

#### 4.2 Histologic aspects

Histologic aspects:

\* 2 weeks (Figure 3)

Group II: Histologic sections revealed dense, highly cellular connective tissue with new fibroblasts and newly formed vessels, in addition to moderate inflammatory mononuclear cell infiltration characterizing granulation tissue, which fills the area of bone defect. Along the edges of the defect there is intense peripheral activity, as well as initial bone deposition. Rare, small fragments of mineralized sphere-shaped tissue are observed permeating the granulation tissue.



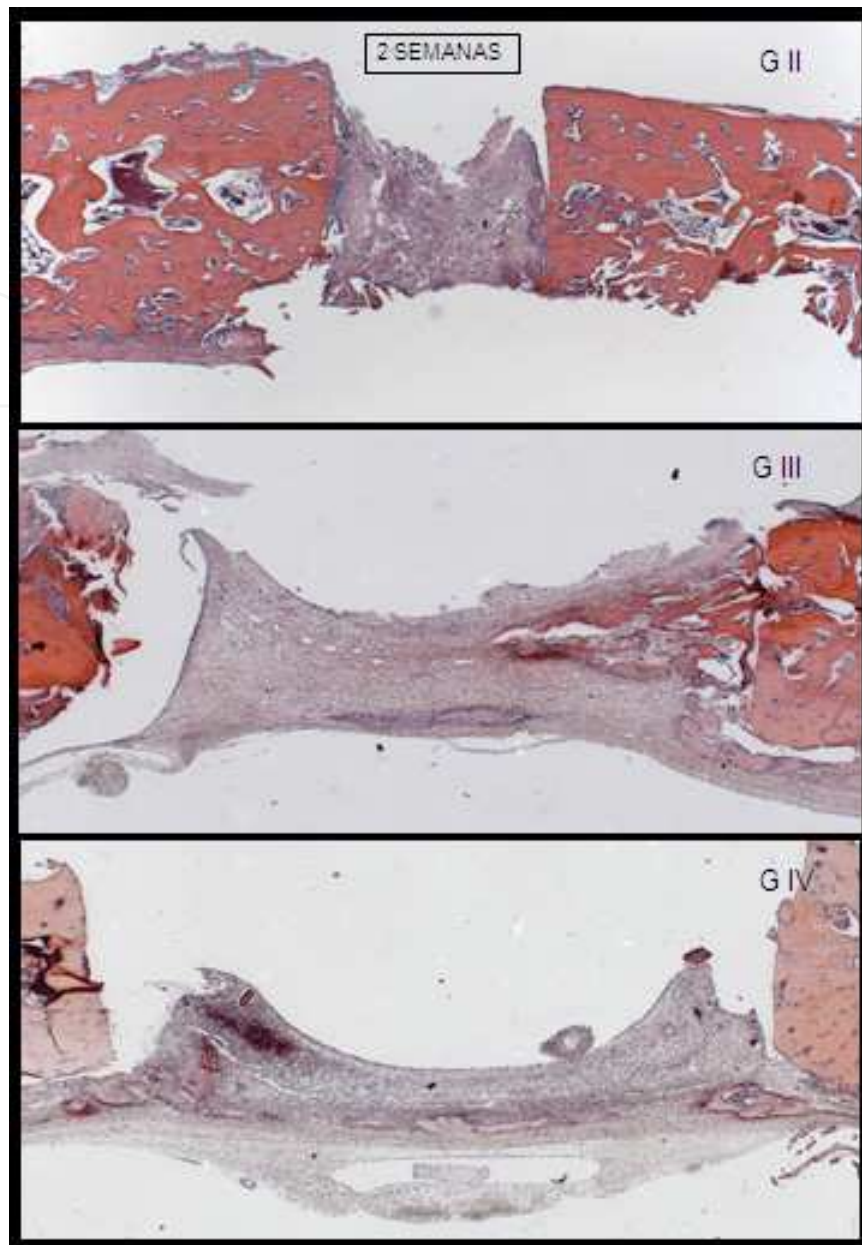


Fig. 3. Histologic sections of the skull at M3 in Groups II, III and IV after 2 weeks

Group III: The defect area was found to be totally filled with new, richly cellular connective tissue permeated by inflammatory mononuclear infiltration. Initial bone deposition may be observed in both the area of remaining bone stump and connective tissue permeating the area.

Group IV: Histologic sections revealed granulation tissue permeated by diffuse, slightly inflammatory mononuclear infiltration with many newly formed vessels showing important newly formed bone areas concentrated around one of the stumps and also in the internal area.

\* 4 weeks (Figure 4)

Group II: The area of bone defect is almost totally filled with newly formed bone tissue still under intense deposition activity. The internal bone surface is found to have less new bone formation compared with the external surface.

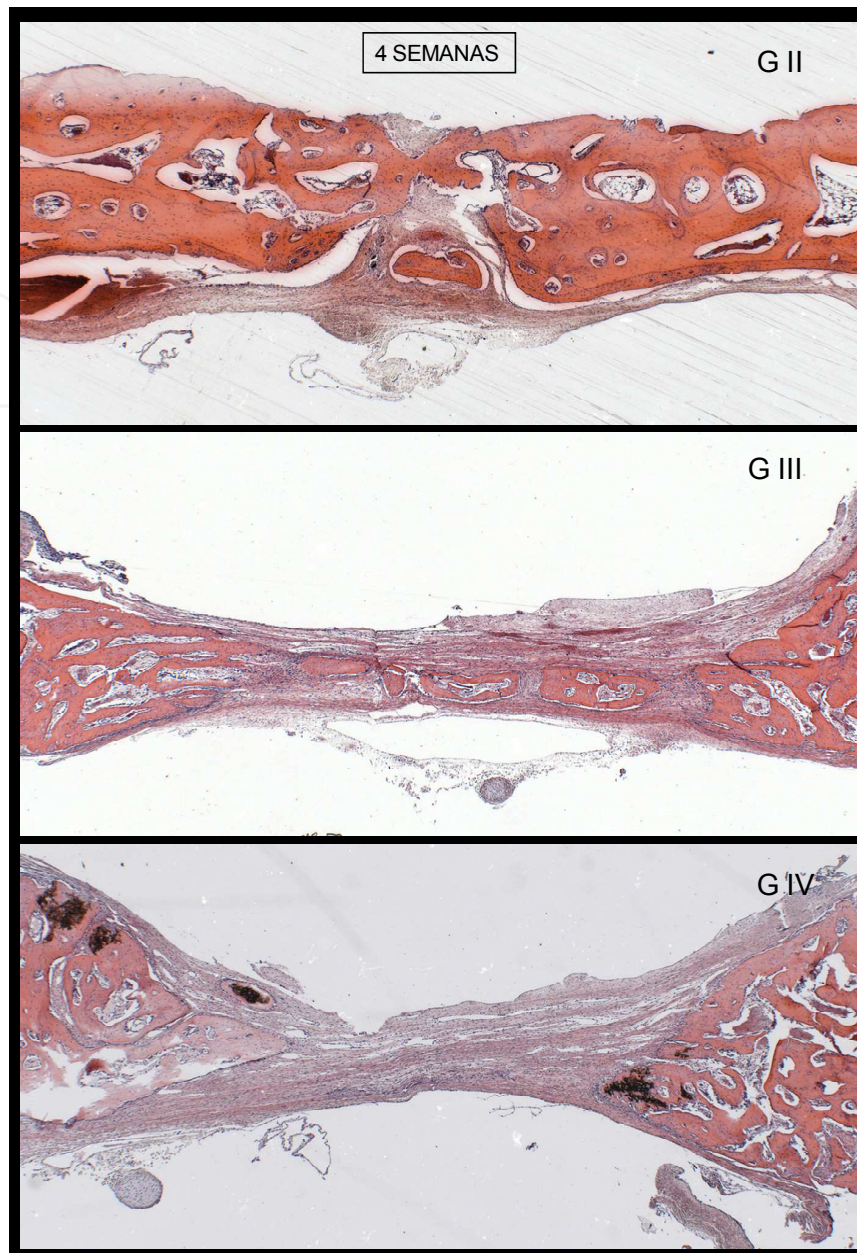


Fig. 4. Histologic sections of the skull at M3 in Groups II, III and IV after 4 weeks

Group III: The area of bone defect presents intense new bone formation in the shape of new trabeculae and spherical depositions scattered throughout the remaining granulation tissue.

Group IV: The area of bone defect is almost exclusively filled with new connective tissue. There is deposition of immature bone tissue, in the shape of trabeculae bound to the lateral stumps.

\* 8 weeks (Figure 5)

Group II: Status is observed to be the same for this group at week 2.

Group III: The external area of the cortical bone presents initial lamellar and gap formation filled with osteocytes regularly deposited. Along this cortical formation, immature trabeculae fill the total width of the defect produced. In the internal area, bone deposition in

less advanced stage and new connective tissue may be observed, however with no inflammatory cell infiltration.

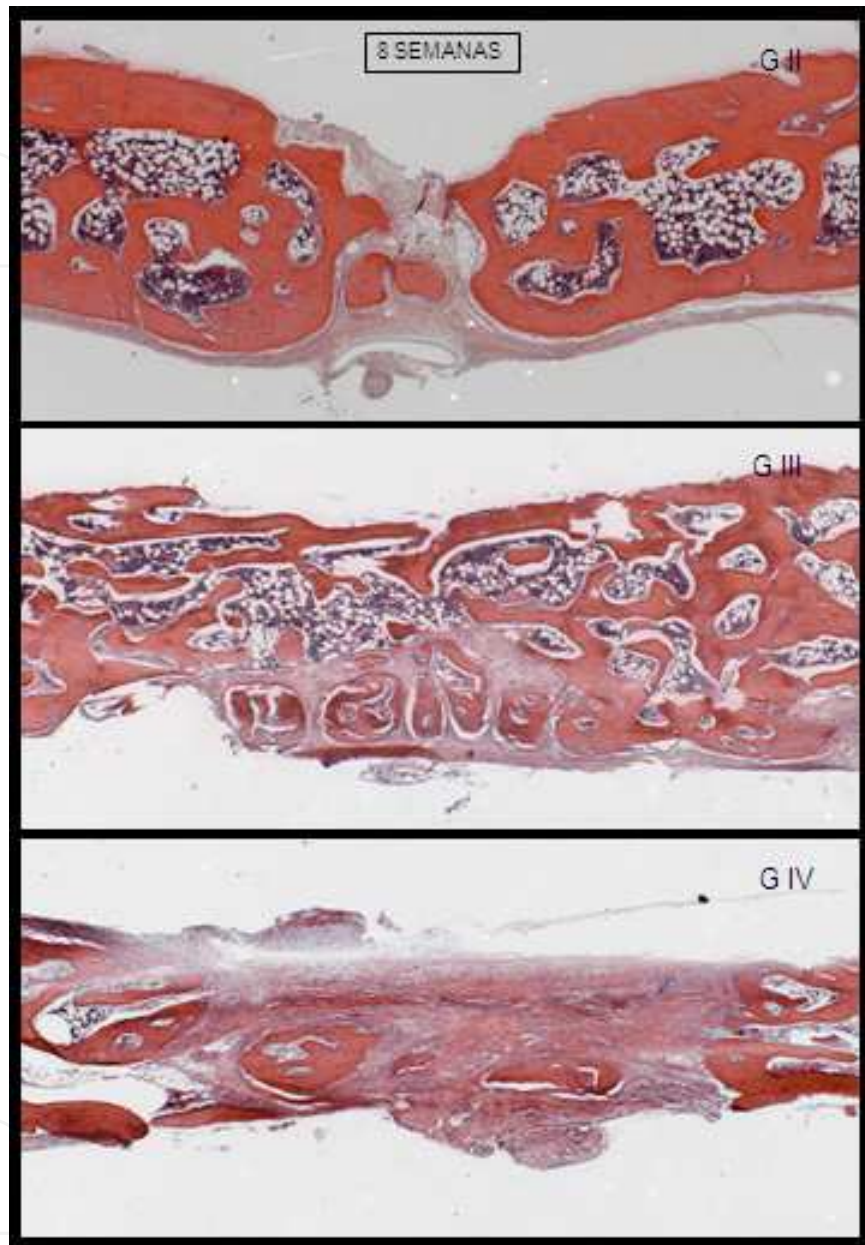


Fig. 5. Histologic sections of the skull at M3 in Groups II, III and IV after 8 weeks

Group IV: Although significant new bone formation may be observed, there is no continuous cortical presence on the external surface so far, despite the fact that the areas filled with new connective tissue are more abundant than those in group III.

\* 12 weeks

Group I: The histologic analysis of the cranial vault of the animal in this group revealed normal aspect of the cortical and trabecular bone in the area.

Group II: The sections present initial bone tissue organization with sutural aspect. Bone tissue is almost totally lamellar. Hematopoietic bone marrow with normal aspect fills the gaps between trabeculae.

Group III: Status is observed to be the same for this group at week 8.

Group IV: The area of defect is almost totally filled with trabeculae of lamellar bone tissue and hematopoietic bone marrow with normal aspect. The thickness of the deposited bone is smaller than that of the remaining areas.

## 5. Discussion

Rabbits have been widely used as experimental model in studies of behavior of cranial sutures, intracranial pressure, craniometric variations, evolution of fixation materials, and distraction of craniofacial structures (Mabbutt and Kokich 1979; Persson, Roy et al. 1979; Alberius and Selvik 1983a; Alberius, Selvik et al. 1986; Persing, Babler et al. 1986; Alberius, Malmberg et al. 1990; Smith, Mooney et al. 1996; Singhal, Mooney et al. 1997; Losken, Mooney et al. 1998; Mooney, Siegel et al. 1998; Mooney, Siegel et al. 1998; Mooney, Siegel et al. 1999; Wendy, Fellows-Mayle et al. 2000; Gwalli, Guimaraes-Ferreira et al. 2001; Putz, Smith et al. 2001; Abreu 2002; David, Gwalli et al. 2002; Gosain, Santoro et al. 2002; David, Proffer et al. 2004; Guimarães-Ferreira, Miguéns et al. 2004; Cooper, Singhal et al. 2006; Cardoso, Caçado et al. 2007; Davis, Windh et al. 2008; Davis, Windh et al. 2009). Cerebral growth curve of rabbit specimens is similar to those of newborn human children: craniofacial growth in rabbits is accelerated immediately after birth, progressively decreasing from two to thirty-four weeks of age (Alberius, Selvik et al. 1986; Abreu 2002). These animals have perinatal brain growth, making young rabbits adequate for the study of cranial suture immobilization. Additionally, they have characteristics similar to humans, namely the internally curved cranial base (Babler, J.A. et al. 1982; Abreu 2002). Some authors, as Wong (Wong and al. 1991), reported that a 7-week-old rabbit corresponds to a one-year-old infant. Nonetheless, the fact that rabbits were breast-fed up to week four (Cardoso, Caçado et al. 2007) limited studies from that age upwards due to difficulties in management and restrictions for releasing the rabbits from the central animal facility before they were weaned. During surgeries performed at weeks two, four, eight and twelve, a progressive thickening of the cranial vault thickness was observed as the animal aged and a higher resilience to osteotomies, considering that along the observed period of time, up to 16 weeks of life, a continuous maturation of the cranial development occurred.

The duration of anesthesia effect was completely satisfying for performing the procedures with no need for dose reinforcement in any of the cases. Surgical dissection was facilitated by vasoconstrictive action of the adrenaline used in infiltration and no hemostasis was necessary. After exposing the cranial vault, sutures were easily exposed and identified. Tissue management was facilitated with the use of self-retaining retractors developed for the procedures.

Springs were made of orthodontic wire with standard opening tension and demonstrated capacity for exerting expansion force able to promote spacing between osteotomized bone edges. Prior to the start of the experimental study, pilot surgeries were performed to test springs with thickness of various material and forms and to develop inclusion standardization using a support to immobilize springs. For this reason, no displacement or

material extrusion was observed, so that in all cases springs were externally palpable during lodging period, however no pressure was caused to the soft parts, which could lead to extrusion, infection and result in the withdrawal of an individual from the experiment.

Ten Cate et al. (Ten Cate, Freeman et al. 1977), in 1977, conducted a study in rats using a spring device similar to the one used in palatal expansion as described by Haas (Haas 1970). In this study, the force applied through springs on normal sutures and expansion of bone remodeling were observed. From this study regeneration is defined as “the complete reconstitution of an injured organ or tissue with resulting complete restoration of its original architecture” and repair as “reconstitution with new structures (scar), with variable degree of architectural distortion” as one of the inevitable consequences. These authors additionally suggest that sutural expansion involves an injury followed by repair phenomenon, which leads to scar tissue in other tissues, nonetheless it promotes regeneration in the suture area.

The behavior of suture is compared to that of gomphosis (bone, ligament, tooth), which as fibrotic joints have a similar response to expansion techniques, i.e. regeneration after orthopedic treatment instead of scar formation or tissue repair.

These findings are compatible with the observation of cranial behavior when springs are placed in the interparietal position. However, in group IV, in which springs were positioned in a non-suture area, a significant difference in ossification would be expected, but it did not occur. The evolution was very similar in skulls in groups III and IV, that is, in suture and non-suture areas. These observations suggest that regeneration does not depend on the suture area.

The use of rabbits that did not present synostosis was not a limitation for cranial expansion under the expanding action of springs, corroborating reports from the literature (Ten Cate, Freeman et al. 1977; Persing, Morgan et al. 1991; Gewalli, Guimaraes-Ferreira et al. 2001; David, Gewalli et al. 2002; Davis, Windh et al. 2008; Davis, Windh et al. 2009). Tanaka et al. (Tanaka, Miyawaki et al. 2000; Tanaka, Miyawaki et al. 2000) published a study analyzing the local response to spring placement at the interparietal suture in healthy rats. The presented biomechanical properties validate suture response with an increase in production of type III collagen along the expansion period. Radiologic changes indicate that a cranial expansion occurred, both when changes in spacing between amalgam markers and angle changes at the cranial base are observed. Therefore, the expansible effect of springs did not appear to depend on skull physiologic changes present in craniosynostosis, as for instance in a change in intracranial pressure or responsiveness of sutures adjacent to the expansible action.

During the harvesting of fragments for histopathologic analysis, springs were observed to maintain their expansible force at the moment one of their extremities was removed. Their opening was longer than the final distance obtained during expansion after ossification and returned to the distance of their original rest position. This behavior, also observed in clinical cases, suggests that the stabilization of expansion process may be determined by both the dynamic equilibrium between the pressure exerted by springs with the resistance of bone edges and tissue osteogenic action. The latter is associated with a local inflammatory process stimulated by expansion and would promote ossification between osteotomy edges even before the expansible action of springs was completed.

Hooke's law (wikipedia 2009) may be applied provided that the elastic limit of the material is not exceeded. The elastic behavior of materials comply with the elastic regime from Hooke's law up to a determined force value; from this value upwards, the relationship of

proportionality cannot be defined anymore (although the body returns to its initial length after removal of the respective force). If this force continues to increase, the body loses its elasticity and deformation becomes permanent (inelasticity), leading to the rupture of the material.

The knowledge on the principles of spring behavior may confer an inherent property that expansion stabilization is a feature of the equilibrium reached between spring action force and bone resistance to the maintenance of a “residual” force of opening. This does not mean that expansion has necessarily ceased by ossification and consequent increase of tissue resistance under spring action, but the probability that equilibrium was established between these forces and ossification followed its natural course in the area, due to the osteogenic action of the dura mater and scalp.

In the study conducted by Persson et al. (Persson, Roy et al. 1979) a premature fusion of coronal sutures in rabbits through suture immobilization bilaterally was induced with further removal. Changes occurred in cranial angular dimensions with anteroposterior shortening and, after a craniectomy was performed to release immobilized sutures, a return to normal patterns of measurements was observed. Also, in the control group, suture removal was shown to cause changes in measurements, however fewer than those observed in the groups with immobilized sutures. Suture removal was not followed by significant changes in angular dimensions of the skull base in nonsynostotic animals.

Accordingly, cranial expansion behavior was considered to possibly be validated in the groups of rabbits with springs. The mere fact of removing a suture does not appear to permanently change craniometric behavior. The removal of sagittal suture in groups II, III and IV was observed to alter until week 4 the total length of the cranial base with less increase relative to group I, however in remaining time points an increase regarding the latter occurred.

Mooney et al. (Mooney, Siegel et al. 1998) and Putz et al. (Putz, Smith et al. 2001) demonstrated that changes in the cranial base in intracranial pressure occur when synostotic rabbits underwent suturectomy. This is a key observation to understand skull behavior subjected to expansion because in addition to the expansile force exerted by springs, their effect is strengthened through altered intracranial pressure, which when stabilized probably accelerates the ossification process through ceasing the tensile action on bone edges.

In 1986, Persing et al. published a study with rabbits in which immobilization of the unilateral coronal suture was performed at 9 days of life, leading to cranosynostosis (Persing, Babler et al. 1986). At 60 days of age, suture osteotomy was performed in one group and the same osteotomy with expansible spring placement in another. As a result, greater expansion was observed in the group of rabbits with springs. A shortening and a distortion in cephalometric data in this group was also observed. Nonetheless, no histologic behavior was reported. Even without using a mechanism of suture contention, in the present study it was possible to observe that the expansion was followed by some singular histologic features at each time point, mainly in group III, which remained with the presence of granulation tissue and osteoblasts until week 12 with suture tissue appearance. Therefore, suture features were maintained even after the surgical removal of bone segment corresponding to the local distraction of the bone edges.

Gewalli et al. (Gewalli, Guimaraes-Ferreira et al. 2001) report that despite the quick opening of springs regarding established bone distraction procedures (Ilizarov 1989; McCarthy, Schreiber et al. 1992), ossification occurs in the gap between bone edges separated by

springs and no progressive, gradual bone distraction process is necessary. The hypothesis that a minor detachment of the dura mater may be associated with this finding is established by Mabbutt and Kokich (Mabbutt and Kokich 1979) and is clearly evidenced by Gosain et al. (Gosain, Santoro et al. 2002) who also observed that the defect created in adult animals was maximized by maintaining the contact with the pericranium (bone growth from peripheral areas) and dural contact (bone growth from depth). Similar finding is observed in Groups III and IV (Figure 4).

Although the pericranium was not approximated, bone deposition occurred from both bone edges and isolated bone islands in the lower part next to the dura mater, demonstrating a multicenter process of ossification. At first, at week two, all groups presented characteristics of inflammatory tissue and immature bone pattern. During the first four postoperative weeks an increased deposition activity occurred with further stabilization and also synchronism in the maturation of newly formed tissue, in which group III presented earlier new bone formation compared with group II and IV. After 12 weeks uniform bone regeneration occurred in the expanded area in groups III and IV, but the total thickness of the vault was smaller than that in group II.

Morphometric measurement methods are not comparable among themselves (Alberius P 1986; Alberius, Malmberg et al. 1990; Abreu 2002) to the extent that comparisons of various studies are not possible, however conclusions drawn from a specific project might be valid (Alberius P 1986). Cranial expansion evolution is indirectly affected by behavior, from the influence of minimum trauma, such as amalgam placement in cranial expansion (Alberius and Selvik 1983a), variation in body weight (Alberius P 1986), changes in growth vector of adjacent sutures and cranial base (Losken, Mooney et al. 1998; Davis, Windh et al. 2008), among others. The difference of expansion among the groups of rabbits with springs was minimal, but expansion was observed to be greater in both groups compared to that without springs, suggesting an action of cranial expansion caused by this device and indicating a similarity between the group with springs in the interparietal and parasagittal areas, even though suture was maintained in the latter.

In order to evaluate cranial expansion from the distance between amalgam markers, data collected from the measurement of the spacing between markers at the M3 position were considered to be the most representative, since they were positioned next to the spring in a site of great resistance and due to the section of histopathologic studies.

A conventional cephalometric analysis enabled the comparison of measurements from an individual with a pattern. Such information at best suggests the degree of deviation from normality for that particular variable.

A better scenario was to know how much the value of a given variable for a specific animal was deviated regarding its similar norm (Persing, Babler et al. 1986), however in a contextualized and non-individualized manner. In other words, measuring how much a suggested deviation occurred in practical terms, a significant deviation for that particular situation. In reality, the difference between these two situations only reflects a limitation in the practicality of conventional mathematical tools applied to cephalometry (Mario 2006).

With the knowledge-based system, the degree of abnormality evidence was evaluated for each value measured considering the general context in which this value was entered into. By measuring the degrees of contextualized evidence, expansion behavior may be identified.

Future perspectives:

The descriptive studies may be populational or individual, as reports of cases and case series (Dos Reis, Ciconelli et al. 2002). The data obtained through descriptive studies serve as basis for formulating hypotheses for future studies. When hypotheses are formulated, analytical studies are necessary for their confirmation or rejection. In this observational study some hypotheses could be formulated, such as:

- The ossification of the expanded cranial area occurred through local osteogenic action and not through gradual distraction of bone edges.
- The cranial expansion with springs is directly related to the interaction among tissues at the site and not to a craniosynostosis-dependent phenomenon.
- The expansible spring action is directly related to its force.

The findings corroborated the clinical results obtained so far, however the applicability of springs of non-suture areas must be better investigated regarding spring action on cranial growth vectors.

Bone distraction is a well-established phenomenon in medicine. Various designs of bone distraction devices have been presented, not only for treating craniofacial abnormalities but also for other areas. In orthopedics, for instance, there are various types of devices for elongating long bones, correcting vertebral scoliosis, changing rib cages, and others. The use of springs is widely diffused. There is research for determining both the amount of material and its best shape. There are possibilities, including springs made of absorbable material, what would reduce even more procedure morbidity because there would be no second surgery for material removal.

## 6. Conclusions

Spring-mediated cranial expansion in rabbits, through the observation of the results of cephalometric and histopathologic behavior present the following features:

- Cranial expansion presents similar evolution patterns both when the device is used directly in the region of the removed suture and also when springs are used in the parasagittal region for maintaining sagittal suture. In both cases, changes are greater than those occurred with the simple removal of the sagittal suture.
- Bone regeneration fills expansion areas due to regenerative stimulating activity induced by maintaining attachment of the dura mater and maintaining the contact with the pericranium.

## 7. References

(1984). *Nomina Anatomica*. Rio de Janeiro.

Abreu, A. (2002). Análise de métodos de aferição morfométrica empregados para avaliação do crescimento craniofacial: estudo em coelhos. *Faculdade de Odontologia*. Porto Alegre, PUCRS. Doutorado: 230.

Alberius, P., M. Malmberg, et al. (1990). "Variability of measurements of cranial growth in the rabbit." *J Craniofac Surg* 188: 393-400.

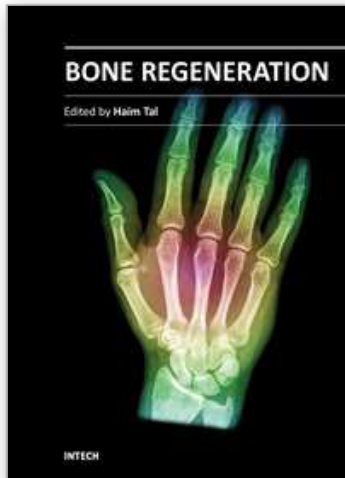
Alberius, P. and G. Selvik (1983a). "Roentgen stereophotogrammetric analysis of growth at cranial vault sutures in the rabbit." *Acta Anat* 117: 10.



- Alberius, P., G. Selvik, et al. (1986). "Postnatal sutural growth of the calvarium: a survey with special reference to the rabbit." *Gegenbaurs Morphol Jahrb* 132(4): 519-534.
- Alberius P, S. G., Fahlman MT (1986). "Postnatal Sutural Growth of the Calvarium: A Survey With Special Reference to the Rabbit." *Gegenbaurs Morphol Jahrb* 132(4): 519-534.
- Arnaud, E., D. Marchac, et al. (2006). "Le traitement des craniosténoses: indications et techniques." *Neurochirurgie* 52(2-3): 264-291.
- Babler, W. J., P. J.A., et al. (1982). "Skull growth after coronal suturectomy, periostectomy, and dural transection." *J Neurosurg* 56(4): 529-535.
- Cardim, V. L., R. F. V. Dornelles, et al. (2002). "Distração Elástica del Tercio medio en la Disyunción Craneo-Facial." *Cir Plást Iberlatinamer* 28(4): 267-275.
- Cardoso, E. S., R. P. Cançado, et al. (2007). Estudo exploratório descritivo do emprego de coelhos brancos da Nova Zelândia (*Orytolagus cuniculus*) como modelo animal na avaliação dos padrões de crescimento craniofacial. *Rev Odonto Cienc Porto Alegre, Fac. Odonto/PUCRS*. 22.
- Cooper, G. M., V. K. Singhal, et al. (2006). "Intracranial volume changes in craniostotic rabbits: effects of age and surgical correction." *Plast Reconstr Surg* 117: 1886-1890.
- David, L. R., F. Gewalli, et al. (2002). "Dynamic spring-mediated cranioplasty in a rabbit model." *J Craniofac Surg* 13(6): 794-801.
- David, L. R., P. Proffer, et al. (2004). "Spring-mediated cranial reshaping for craniostosis." *J Craniofac Surg* 15: 810-816.
- Davis, C., P. Windh, et al. (2008). "Spring-assisted cranioplasty alters the growth vectors of adjacent cranial sutures." *Plast Reconstr Surg* 123(2): 470-474.
- Davis, C., P. Windh, et al. (2009). "Do expansile cranial springs erode through the cranium?" *J Craniofac Surg* 20(1): 168-170.
- Dornelles, R. F. V., V. L. N. Cardim, et al. (2007). The Use of implantable springs in the dynamic expansion to craniostosis treatment: 17 cases analysis. XII International Congress of the International Society of Craniofacial Surgery. . Bahia, Brasil, Abstract book: 64.
- Dos Reis, F. B., R. M. Ciconelli, et al. (2002). "Pesquisa científica: a importância da metodologia." *Rev Bras Ortop* 37: 51-55.
- Gault, D. T., D. Renier, et al. (1992). "Intracranial pressure and intracranial volume in children with craniostosis." *Plast Reconstr Surg* 90(3): 377-381.
- Gewalli, F., J. P. S. Guimaraes-Ferreira, et al. (2001). "Expander elements in craniofacial surgery: an experimental study in rabbit." *Scand J Plast Reconstr Surg Hand Surg* 35(2): 149-156.
- Gosain, A. K., T. C. Santoro, et al. (2002). "Osteogenesis in calvarial defects: contribution of the dura, the pericranium, and the surrounding bone in adult versus infant animals." *Plast Reconstr Surg* 112(2): 12.
- Greensmith, A. L., A. D. Holmes, et al. (2008). "Complete correction of severe scaphocephaly: the melbourne method of total vault remodeling." *Plast Reconstr Surg* 121(4): 1300-1310
- Guimaraes-Ferreira, J., J. Miguéns, et al. (2004). "Advances in craniostosis research and management." *Adv Tech Scand Neurosurg*: 29.
- Haas, A. J. (1970). "Palatal expansion: just the beginning of dentofacial orthopedics." *Am J Orthod* 57: 219.
- Heller, J. B., M. M. Heller, et al. (2008). "Intracranial volume and cephalic index outcomes for total calvarial reconstruction among nonsyndromic sagittal synostosis patients." *Plast Reconstr Surg* 121(1): 187-195

- Hönig, J. F., U. A. Grohmann, et al. (2001). "Facial bone distraction osteogenesis for correction of malocclusion: a more than 70-year-old concept in craniofacial surgery." *Plast Reconstr Surg* 109(1): 41-44.
- Ilizarov, G. A. (1989). "The tension-stress effect on the genesis and growth of tissues: Part II. The influence of the rate and frequency of distraction." *Clin Orthop* 239: 22.
- Imai, K., H. Komune, et al. (2002). "Cranial remodeling to treat craniosynostosis by gradual distraction using a new device." *J Neurosurg* 96: 654-659.
- Lauritzen, C., Y. Sugawara, et al. (1998). "Spring mediated dynamic craniofacial reshaping. Case report." *Scand J Plast Reconstr Surg Hand Surg* 32(3): 331-338.
- Lauritzen, C. and P. Tarnow (2003). "Craniofacial surgery over 30 years in Goteborg." *Scand J Surg* 92(4): 274-280.
- Lauritzen, C. G. K., C. Davis, et al. (2008). "The evolving role of springs in craniofacial surgery: the first 100 clinical cases." *Plast Reconstr Surg* 121(2): 545-554
- Losken, H. W., M. P. Mooney, et al. (1998). "Internal calvarial bone distraction in rabbits with delayed-onset coronal suture synostosis." *Plast Reconstr Surg* 102(4): 1109-1119.
- Mabbutt, L. W. and V. G. Kokich (1979). "Calvarial and sutural re-development following craniectomy in the neonatal rabbit." *J Anat* 129(2): 9.
- Mackenzie, K. A., C. Davis, et al. (2009). "Evolution of surgery for sagittal synostosis: the role of new technologies." *J Craniofac Surg* 20(1): 29-133.
- Marchac, D. and D. Renier (1979). "Le front flottant": traitement precoce des facio-cranioestenoses." *Ann Chir Plast* 24: 121121.
- Mario, M. C. (2006). Modelo de análise de variáveis craniométricas através das Redes Neurais Artificiais Paraconsistentes. Faculdade de Medicina. São Paulo, Universidade de São Paulo. Doutor em Ciências: 176.
- McCarthy, J. G., F. J. Epstein, et al. (1990). *Craniosynostosis. Plastic Surgery*. J. McCarthy. New York, Saunders Company. 4: 3013-3053.
- McCarthy, J. G., J. Schreiber, et al. (1992). "Lengthening the human mandible by gradual distraction." *Plast Reconstr Surg* 89(1): 1-8.
- McCarthy, J. G., E. J. Stelnicki, et al. (2001). "Distraction osteogenesis of the craniofacial skeleton." *Plast Reconstr Surg* 107(7): 1812-1827.
- Molina, F. and F. Ortiz-Monasterio (1995). "Mandibular elongation and remodeling by distraction: a farewell to major osteotomies." *Plast Reconstr Surg* 96(4): 825-840.
- Mooney, M., M. I. Siegel, et al. (1998). "A rabbit model of human familial, nonsyndromic unicoronal suture synostosis I. Synostotic onset, pathology, and sutural growth patterns." *Childs Nerv Syst* 14: 236-246.
- Mooney, M. P., M. I. Siegel, et al. (1998). "A rabbit model of human familial, nonsyndromic unicoronal suture synostosis II. Intracranial contents, intracranial volume, and intracranial pressure." *Childs Nerv Syst* 14: 247-255.
- Mooney, M. P., M. I. Siegel, et al. (1999). "Increased intracranial pressure after coronal suturectomy in craniosynostotic rabbits." *J Craniofac Surg* 10(2): 104-106.
- Ortiz-Monasterio, F., A. Fuente del Campo, et al. (1978). "Advancement of the orbits and the midface in one piece, combined with frontal repositioning for the correction of Crouzon's deformities." *Plast Reconstr Surg* 61(4): 507.
- Ortiz-Monasterio, F. and F. Molina (1994). "Mandibular Distraction in Hemifacial Microsomia." *Operative Techniques in Plastic and Reconstructive Surgery* 1(2): 105-112.
- Panchal, J. and V. Utchin (2003). "Management of Craniosynostosis." *Plast Reconstr Surg* 111(6): 2032-2049.

- Persing, J. A., W. J. Babler, et al. (1986). "Skull expansion in experimental craniosynostosis." *Plast Reconstr Surg* 78(5): 594-603.
- Persing, J. A., J. A. Jane, et al. (1989). "Virchow and the pathogenesis of craniosynostosis: a translation of his original work." *Plast Reconstr Surg* 83(4): 738-742.
- Persing, J. A., E. P. Morgan, et al. (1991). "Skull base expansion: craniofacial effects." *Plast Reconstr Surg* 87(6): 1028-1033.
- Persson, K. M., W. A. Roy, et al. (1979). "Craniofacial growth following experimental craniosynostosis and craniectomy in rabbits." *J Neurosurg* 50: 10.
- Putz, D. A., T. D. Smith, et al. (2001). "Cranial base changes following coronal suturectomy in craniosynostotic rabbits." *Orthod Craniofac Res* 5: 13.
- Pyle, J., S. Glazier, et al. (2009). "Spring-assisted surgery - a surgeon's manual for the manufacture and utilization of springs in craniofacial surgery." *Journal of Craniofacial Surgery* 20(6): 1962-1968.
- Renier, D., M. Le Merrer, et al. (2006). "Étiologie des craniosténoses." *Neurochirurgie* 52(2-3): 228-237.
- Schnaider, T. B. and C. De Souza (2003). "Aspectos Éticos da experimentação animal." *Rev Bras Anesthesiol* 53: 278-285.
- Singhal, V. K., M. P. Mooney, et al. (1997). "Age related changes in intracranial volume in rabbits with craniosynostosis." *Plast Reconstr Surg* 100(5): 1121-1128.
- Slater, B. J., K. A. Lenton, et al. (2008). "Cranial sutures: a brief review." *Plast Reconstr Surg* 121(4): 170e-178e
- Smith, T. D., M. P. Mooney, et al. (1996). "Postnatal changes in the cranial base in rabbits with congenital coronal suture synostosis." *J Craniofac Genet Dev Biol* 16: 107-117.
- Snyder, C. C., G. A. Levine, et al. (1973). "Mandibular Lengthening by Gradual Distraction: Preliminary Report." *Plast Reconstr Surg* 51(5): 506-508.
- Tanaka, E., Y. Miyawaki, et al. (2000). "Changes in the biomechanical properties of the rat interparietal suture incident to continuous tensile force application." *Arch Oral Biol* 45: 1059-1064.
- Tanaka, E., Y. Miyawaki, et al. (2000). "Effects of tensile forces on the expression of type III collagen in rat interparietal suture." *Arch Oral Biol* 45: 1049-1057.
- Ten Cate, A., E. Freeman, et al. (1977). "Sutural development: structure and its response to rapid expansion." *Am J Orthod* 71(6): 14.
- Tessier, P. (1971). "The definitive plastic surgical treatment of the severe facial deformities of craniofacial dysostosis: Crouzon's and Apert's diseases." *Plast Reconstr Surg* 48(5): 419-442.
- Tubino, P. and A. Alves. (2009). "História da Medicina." from [http://www.unb.br/fm/hismed/arquivos/medicina\\_pre-colombiana.pdf](http://www.unb.br/fm/hismed/arquivos/medicina_pre-colombiana.pdf).
- Tung, T. H., B. R. Robertson, et al. (1999). "Successful distraction osteogenesis across a growing cranial suture without an osteotomy." *Plast Reconstr Surg* 103(2): 362-370.
- Wendy, K., M. A. Fellows-Mayle, et al. (2000). "Age-related changes in intracranial pressure in rabbits with uncorrected familial coronal suture synostosis." *Cleft Palate Craniofac J* 37(4): 370-378.
- Wikipedia. (2009). from <http://pt.wikipedia.org/wiki/Mola>.
- Wong, L. and e. al. (1991). "The effect of rigid fixation on growth of the neurocranium." *Plast Reconstr Surg* 88(3): 8.



## **Bone Regeneration**

Edited by Prof. Haim Tal

ISBN 978-953-51-0487-2

Hard cover, 340 pages

**Publisher** InTech

**Published online** 04, April, 2012

**Published in print edition** April, 2012

Bone is a specialized connective tissue, most prominently characterized by its mineralized organic matrix that imparts the physical properties that allow bone tissue to resist load, to support functional organs, and to protect highly sensitive body parts. Bone loss and bone damage may occur as a result of genetic conditions, infectious diseases, tumours, and trauma. Bone healing and repair, involves integrative activity of native tissues and living cells, and lends itself to the incorporation of naturally derived or biocompatible synthetic scaffolds, aimed at replacing missing or damaged osseous tissues. There are several modalities of bone regeneration including tissue engineering, guided bone regeneration, distraction osteogenesis, and bone grafting. This book concentrates on such procedures that may well be counted among the recent outstanding breakthroughs in bone regenerative therapy.

### **How to reference**

In order to correctly reference this scholarly work, feel free to copy and paste the following:

Rodrigo Dornelles, Vera Cardim and Nivaldo Alonso (2012). Skull Expansion by Spring-Mediated Bone Regeneration, Bone Regeneration, Prof. Haim Tal (Ed.), ISBN: 978-953-51-0487-2, InTech, Available from: <http://www.intechopen.com/books/bone-regeneration/bone-regeneration-on-a-spring-mediated-skull-expansion->

**INTECH**  
open science | open minds

### **InTech Europe**

University Campus STeP Ri  
Slavka Krautzeka 83/A  
51000 Rijeka, Croatia  
Phone: +385 (51) 770 447  
Fax: +385 (51) 686 166  
[www.intechopen.com](http://www.intechopen.com)

### **InTech China**

Unit 405, Office Block, Hotel Equatorial Shanghai  
No.65, Yan An Road (West), Shanghai, 200040, China  
中国上海市延安西路65号上海国际贵都大饭店办公楼405单元  
Phone: +86-21-62489820  
Fax: +86-21-62489821

© 2012 The Author(s). Licensee IntechOpen. This is an open access article distributed under the terms of the [Creative Commons Attribution 3.0 License](#), which permits unrestricted use, distribution, and reproduction in any medium, provided the original work is properly cited.

IntechOpen

IntechOpen