

We are IntechOpen, the world's leading publisher of Open Access books Built by scientists, for scientists

4,800

Open access books available

122,000

International authors and editors

135M

Downloads

Our authors are among the

154

Countries delivered to

TOP 1%

most cited scientists

12.2%

Contributors from top 500 universities



WEB OF SCIENCE™

Selection of our books indexed in the Book Citation Index
in Web of Science™ Core Collection (BKCI)

Interested in publishing with us?
Contact book.department@intechopen.com

Numbers displayed above are based on latest data collected.
For more information visit www.intechopen.com



Augmentation and Preservation of the Alveolar Process and Alveolar Ridge of Bone

Haim Tal, Zvi Artzi, Roni Kolerman,
Ilan Beitlitum and Gal Goshen

*Department of Periodontology and Dental Implantology,
Tel Aviv University
Israel*

1. Introduction

1.1 The alveolar process and alveolar ridge of bone in health and disease

The alveolar process is the part of the maxilla and the mandible that house and support the alveoli of the teeth. It develops in conjunction with the development and eruption of the teeth, over the basal bone and coronal to it. The alveolar process consists of an outer layer of *cortical bone*, an inner *cancellous bone*, and a special layer - alveolar bone proper - which together with the root, cementum and the periodontal membrane constitutes the dental attachment apparatus. The attachment apparatus supports the tooth in the jaw, on the one hand, and distribute forces generated by the teeth to the alveolus and bone peripheral to it, on the other hand. The forces transferred to the jaw due to teeth activities, influence the structure, architecture, size and density of the cancellous bone trabeculae. Fig. 1a-c shows a cross section through dentate sites in the mandible at a level corresponding to the roots and through an edentulous site (d). In health, the bone lining the wall of the socket (alveolar bone proper) is continuous with the cortical bone at the lingual and buccal aspects of the alveolar process (Fig.1a-c,e) however, if the buccal plate of bone is extremely thin (Fig.1. a,c) the buccal cortical plate and the alveolar bone proper unite having no cancellous bone between them. The different structures of the alveolar process, i.e. cortical and cancellous bone, are constantly undergoing remodeling in response to functional forces acting on the teeth. Once teeth are lost, the attachment apparatus is destroyed, and the alveolar process, mainly the alveolar ridge, undergoes significant structural changes; these are referred to as "disuse atrophy" (Fig. 1a,c,f).

Immediately after extraction the bony walls of the alveolus present significant resorption, the central part of the socket is partly filled up with woven bone and the extraction site becomes markedly reduced in size. Pietrokovski & Massler (1967) and Schropp *et al.* (2003) have shown that the edentulous site diminishes in all dimensions i.e. bucco-lingual, bucco-palatal and apico-coronal. At the same time, the soft tissues in the extraction site undergo adaptive changes that clinically may appear as deformations of the jaw (Fig. 2).

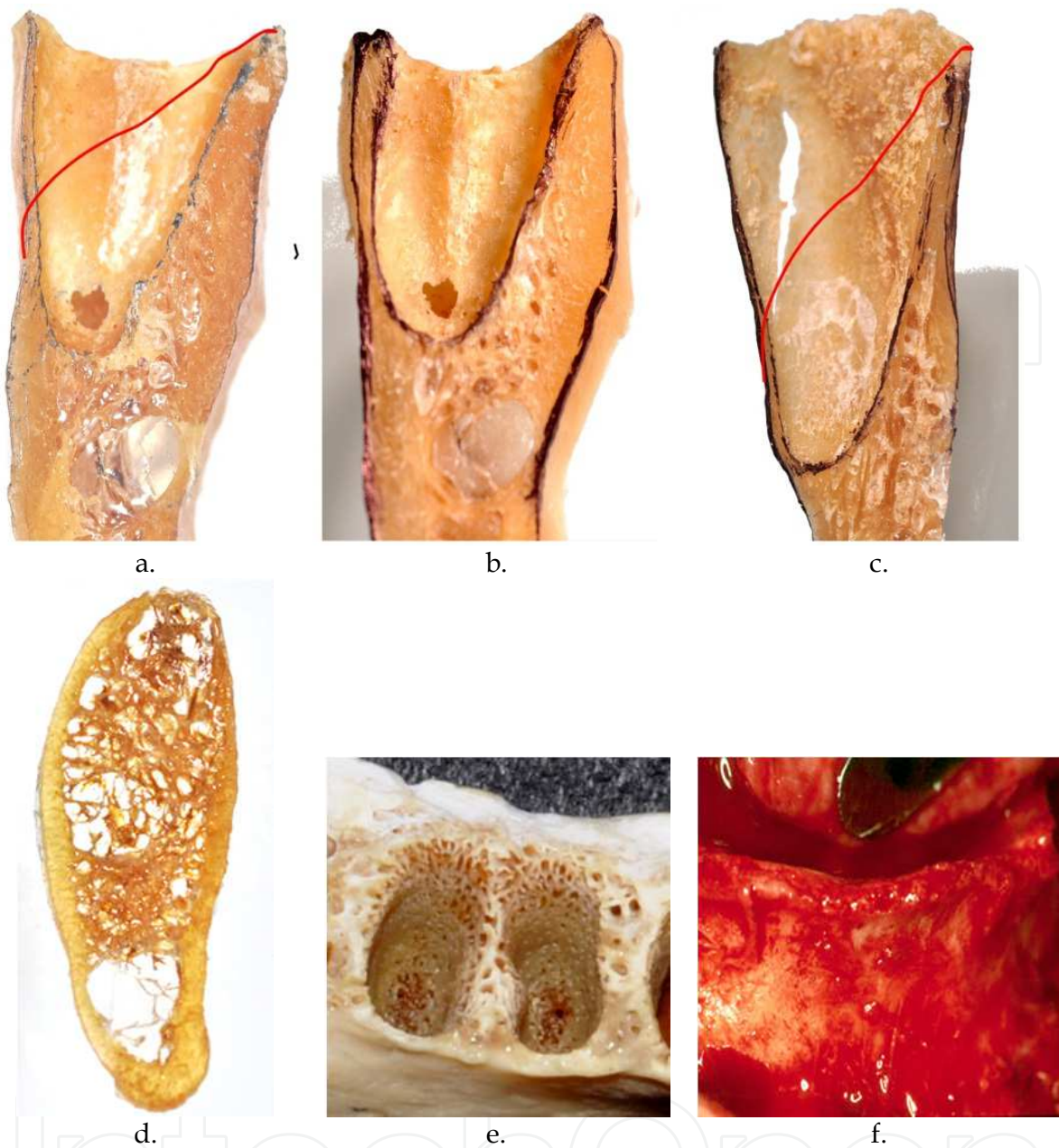


Fig. 1. Different views of sites of a dry mandible. a. cross section through an empty alveolar socket of a mandibular canine tooth; the red line represents the expected bone contour that would be established had the tooth been removed; note that the buccal wall contains exclusively cortical bone. b. cross section through an empty alveolar socket of a mandibular premolar tooth; note that the buccal wall contains exclusively cortical bone in spite of its being relatively thick c. cross section through an empty alveolar socket of a mandibular canine tooth; the red line represents the expected bone contour that would be established had the tooth been removed; note that the buccal wall is extremely thin ("paper thin") and contains exclusively cortical bone d. cross section of an edentulous inter-radicular site a few months after tooth loss; there is less bone loss in this area compared with extraction socket sites. e. upper view of an empty socket of the lower second molar showing the cribriform alveolar bone proper f. clinical view of the anterior segment of an edentulous mandible 1 year after extraction; severe disuse atrophy is noted.

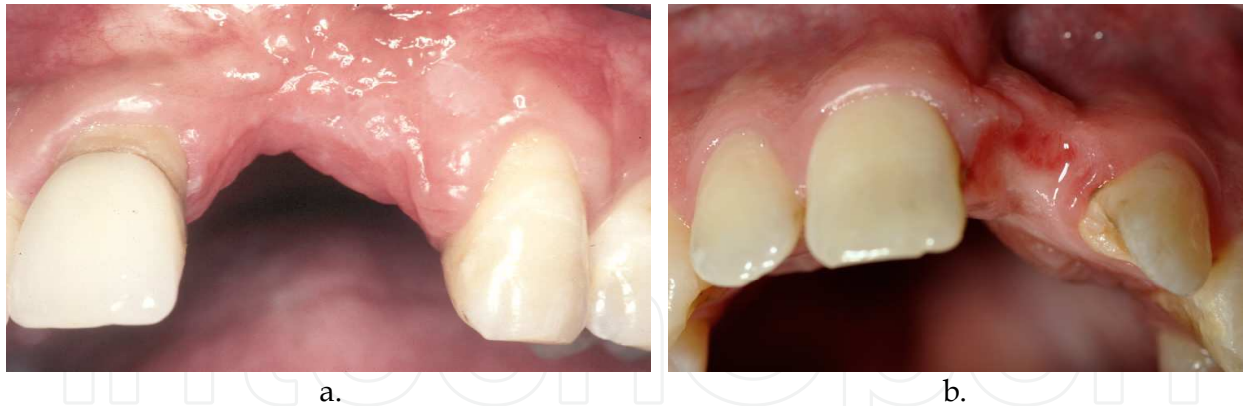

Fig. 2. Deformations of the jaw due to severe bone loss and soft tissues adaptation in extraction sites associated with a. implant failure and b. traumatic injury; in the esthetic zone this deformations needs regenerative and/or plastic therapy.

1.2 The alveolar process status in relation to implant placement

Re-establishment of the natural dimensions of the alveolar process is essential for both functional rehabilitation and esthetic restoration; if missing teeth are to be restored with implant supported prostheses, restoring these dimensions is of crucial importance. It is agreed that endosseous implants should be completely embedded in bone and preferably surrounded by not less than 2 mm of bone in all aspects. In view of the changes in bone dimensions after tooth extraction, the issue relating to the "optimal" timing of implant placement has received much attention (Hammerle *et al.* 2004). Attempts made to identify the advantages and disadvantages of **early**, **delayed**, and **late** implant placement, led to incorporation of the knowledge in this field into a classification relating the timing of implant placement to the condition of soft and hard tissue healing as follows (Hammerle *et al.* 2004):

- **Type 1:** the implant is placed immediately following tooth extraction (Fig. 3a)
- **Type 2:** the implant is placed after soft tissues have healed and a mucosa is covering the socket entrance (Fig. 3b)
- **Type 3:** the implant is placed after substantial amounts of new bone have formed in the extraction socket (Fig. 3c)
- **Type 4:** the implant is placed in a fully healed ridge. (Fig. 3d)

Preservation of the alveolar process is dependent on the presence of teeth; after the teeth are lost the alveolar process poses gradual regression. The loss of teeth, and the loss of function within and peripheral to the socket results in adaptive alterations of the edentulous portion of the ridge; the alveolar ridge becomes markedly reduced in all dimension. The magnitude of this change was described by Pietrokovski and Massler (1967) who studied anthropometrically dry jaws, and Schropp *et al.* (2003) who clinically studied bone and soft tissue volume changes following the extraction of single premolars and molars. The later concluded that the buccal-lingual/palatal dimension during the first 3 months was reduced about 30%, and after 12 months the edentulous site had lost at least 50% of its original width. Furthermore, after 12 months of healing the buccal prominence was reduced to a level 1.2 mm apical of its lingual/palatal counterpart. It is noteworthy that frequently, the

alveolar process has undergone pathologic changes prior to tooth loss due to traumatic injuries, chronic or aggressive periodontitis, periapical lesions, root fractures and resorption as well as severe periimplantitis. (Fig. 4).

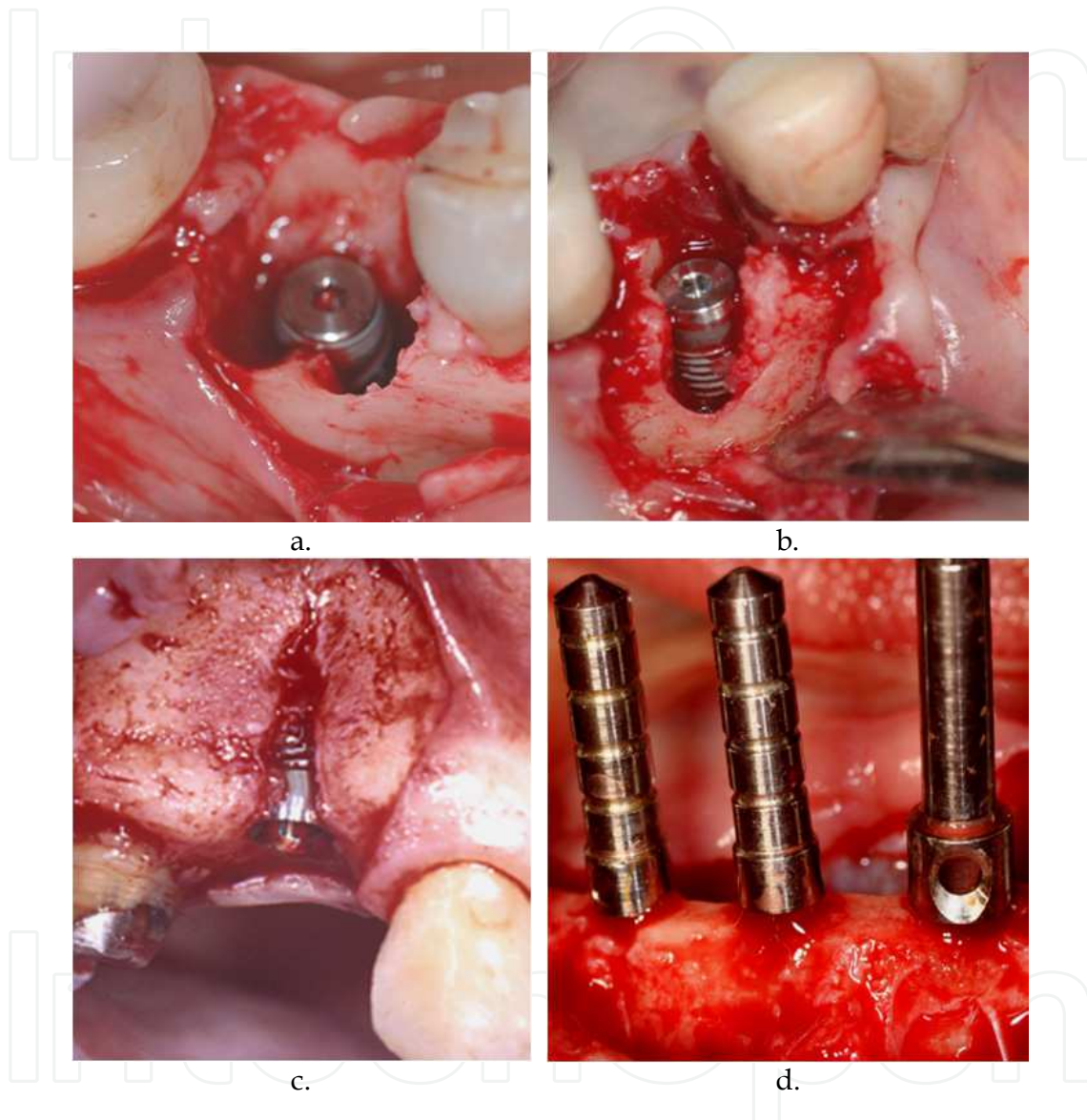


Fig. 3. Classification relating the timing of implant placement a. Type 1: an implant is placed immediately following a molar tooth extraction. b. Type 2: an implant is placed 2 months after implant removal. The soft tissues have healed and the mucosa covering the socket entrance was intact c. Type 3: an implant is placed 4 months after extraction of the upper left first premolar. Substantial amounts of new bone have formed in the extraction socket; a buccal dehiscence defect is associated with the buccal aspect of the implant. d. delayed implant placement in a fully healed (type 4) ridge, 1 year after extractions. Both, vertical and horizontal bone loss is evident.

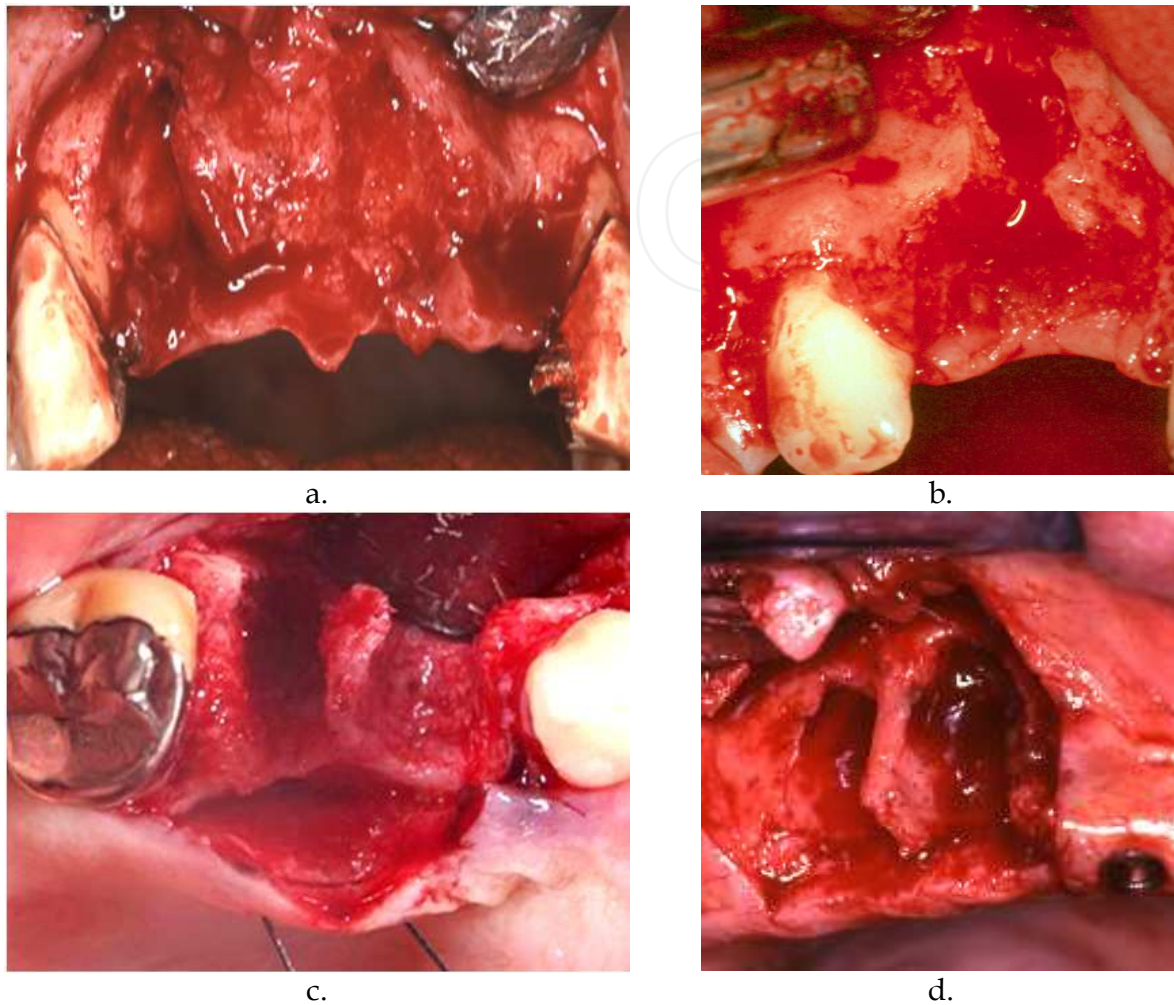


Fig. 4. Clinical view of bone destruction in the alveolar process a. immediately after tooth removal due to advanced periodontitis b. immediately after removal of tooth remnants due to root resorption c. complete destruction of the alveolar buccal plates observed after removal of the first and second maxillary bicuspids d. immediately after removal of dental implants due to advanced peri-implantitis.

Radiographic studies dealing with the atrophy of the alveolar process have shown that in the first few months bone loss is obvious in the alveolar crest region, simultaneous to bone gain in the socket. Gain of bone in the socket continued until 6 months following extraction, being replaced by bone remodeling during the next 6 months to follow. Based on the volume of remaining bone, the edentulous sites were classified by Lekholm and Zarb (1985) into five different categories: A and B groups represent sites in which substantial amounts of the alveolar process still remain, whereas in groups C, D, and E, there are only minute remnants of the alveolar process present (Fig. 4)

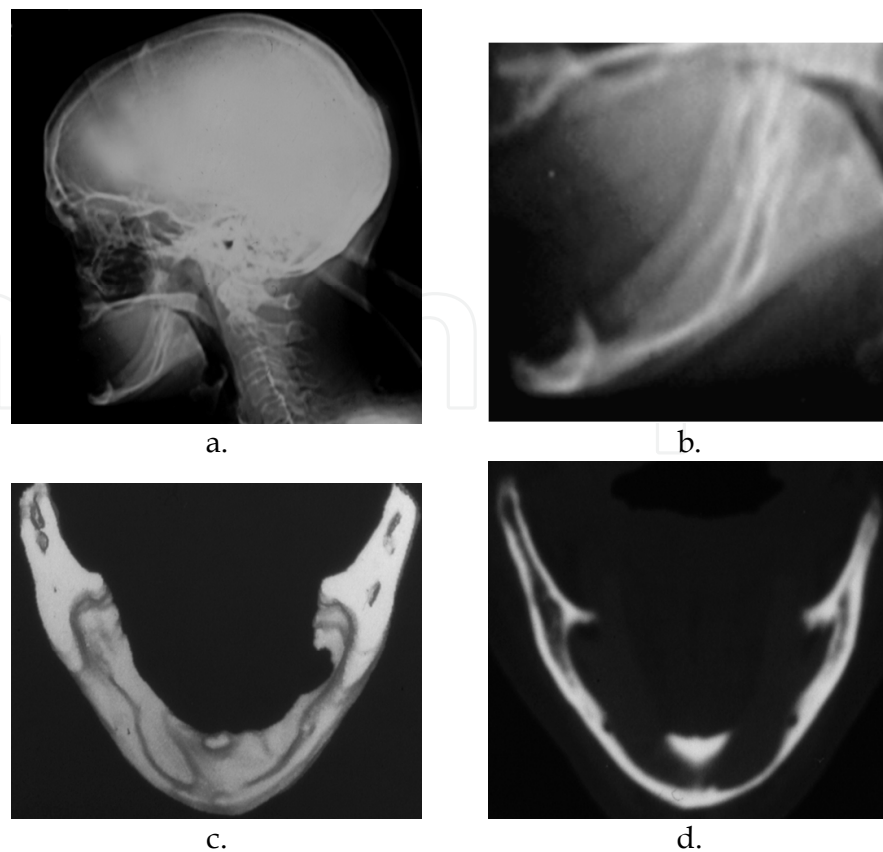


Fig. 5. CT scan demonstrating very severe (group E) bone loss due to implant failure followed by usage of a full removable denture over a 20 years period of time. Bone loss include the whole alveolar process and most of the basal bone. a. mid-sagittal section view through of the maxilla and mandible. b. higher magnification of the mid-sagittal section view through the mandible c. 3D view of the mandible from above; vertical bone loss beyond the level of the mental foramina is evident d. coronal section of the mandible at the level of the mental foramina.

Lekholm and Zarb (1985) further classified the residual bone according to “quality”: Class 1 and class 2 relate to residual alveolar process presenting thick cortical plates and relatively small volume of bone marrow, while sites belonging to class 3 and class 4, present relatively thin walls of cortical bone and large amount of cancellous bone including trabeculae of lamellar bone and marrow. While the definition of the alveolar process is clear, there seems to be no distinct boundary between the alveolar process and the basal bone of the jaws. However, by definition the alterations, modifications and adjustments occurring in the alveolar process and ridge following tooth extraction include *intra-alveolar processes* and *extra-alveolar Processes*; these were described in details by Amler (1969), and later by Evian (1982).

Understanding the changes occurring to the alveolar process after extraction is of utmost importance when planning the rehabilitation of the edentulous jaw. Araújo & Lindhe (2005) studied histologically the processes alterations following tooth extraction in the dog at 1, 2, 4, and 8 weeks of healing. At 1 week after tooth extraction the socket was occupied by a coagulum. The presence of osteoclasts on the inner surface of the socket walls indicated that

the bundle bone was being resorbed. At 2 weeks newly formed immature (woven) bone resided in the apical and lateral parts of the socket. In several parts of the socket walls the bundle bone has been replaced with woven bone. At 4 weeks after extraction the entire socket was occupied with woven bone and at some areas the newly formed woven bone was being replaced with a more mature type of bone. At 8 weeks a layer of cortical bone covered the entrance to the extraction site. The woven bone had been replaced with bone marrow and some trabeculae of lamellar bone. Signs of ongoing hard tissue resorption were observed on the outside and on the top of the buccal and lingual bone wall and the buccal bone wall was located apical of its lingual counterpart. Araújo & Lindhe (2005) concluded that the process of modeling and remodeling that occur following tooth extraction results in pronounced resorption of the various components of the alveolar ridge. The resorption of the buccal bone wall is more pronounced than that of the lingual/palatal wall and hence the center of the ridge will move in lingual/palatal direction. In the extreme case, the entire alveolar process may be lost and in such situations only the bone of the base of the mandible or the maxilla remains. In fact, with time, depending on functional and parafunctional activities, significant parts of the basal bone may be lost leaving but the cortical envelop in situ (Fig 5). Since this subject is beyond the scope of this book, for a systematic description of the histological and morphometrical changes in the alveolar process following tooth extraction the reader is referred to a detailed long-term experiment in the dog carried out by Cardaropoli *et al.* (2003).

1.3 The role of dental implants in bone healing and bone regeneration

Augmentation and regeneration procedures of the alveolar process and alveolar ridge have received special attention soon after the introduction of modern implant therapy (1970's). Successful restoration of health, function and esthetic appearance using dental implants require the establishment of conditions that promote bone and soft tissue integration to the implant. In addition, in a growing number of cases, treatment must also satisfy esthetic demands. After tooth removal it takes about 4–8 weeks before granulation tissue and provisional connective tissue/woven bone fill the extraction socket and its surface becomes covered with epithelium (Amler 1969; Zitzmann *et al.* 1999; Nemcovsky & Artzi 2002). The maturation of the soft tissue may require an even longer healing time before the soft tissue quality allows for precise management of a mucosal flap. This timing however, must be matched against the hard tissue reduction that results in by the socket walls resorption, especially that of the buccal plate of bone. Special care should be taken with flap elevation at sites where the mucosa adheres to the underlying bone or underlying scar tissue; in such cases flap separation from the bone may rupture the soft tissue resulting in soft tissue dehiscence, local infection, and compromised healing (Zitzmann *et al.* 1997). Thus, if bone height apical to the tip of the root is less than 3 mm, and obtaining primary implant stability in the bone is impossible, a more delayed approach is preferable and it is advised to wait until substantial bone fill has occurred, i.e. 10–16 weeks (Evian *et al.* 1982). At that time newly formed woven bone occupies the socket area, however, by that time the walls of the socket are frequently severely resorbed. At this stage of healing it is possible to place the implant in a position that facilitates the prosthetic phase of the treatment. Six to 12 months after tooth extraction, the alveolar ridge is characterized by dense cortical bone that is lined by a mature keratinized mucosa. The advantage of placing implants into the mature

edentulous ridge is since at that delayed stage of healing, further changes of the ridge morphology may be minimal and very slow. The main disadvantages of such delayed implant placement is that the overall reduction of the ridge volume is significant, and its external contours may be deformed.

Depending on the pre-extraction bone loss, and the time elapsed from extraction to implant placement, the loss of ridge volume and changes in contours may require bone augmentation varying from minimal ridge preservation in the fresh extraction cases, to more complicated bone augmentation procedures in the very pronounced ones. Although each case requires a "custom made" treatment planning, in most cases, whenever possible, tooth replacement should be done as early as possible; the final decision regarding the timing for implant placement must however be based on a thorough understanding of the structural changes that occur in the alveolar process following tooth extraction, with and without implant placement. (Hämmerle *et al.* 2006)

1.4 Ridge correction in conjunction with implant placement

Implants may be placed immediately after the removal of teeth. Many claims have been made regarding the advantages of immediate implant placement (Chen *et al.* 2004) including implant positioning and bone preservation at the site of implantation, (Werbitt & Goldberg 1992; Barzilay 1993; Schwartz-Arad & Chaushu 1997a; Hammerle *et al.* 2004). It was proposed that placement of an implant in a fresh extraction socket may allow the preservation of bone tissue of the socket and the surrounding jaw by stimulating bone formation and osseointegration and hence counteract the adaptive alterations that occur to bone tissue following tooth loss (e.g. Denissen *et al.* 1993; Watzek *et al.* 1995; for review see Chen *et al.* 2004). Human clinical studies (Botticelli *et al.* 2004; Covani *et al.* 2004) and dog experiments (Araujo & Lindhe 2005; Araujo *et al.* 2006a,b) have shown that after 4 months of healing post extraction and immediate implant placement, the marginal gap between implants and socket bony walls had completely resolved, however, the thickness of the buccal as well as the palatal bone walls had become markedly reduced so that the implant surface could be seen through the very thin remaining buccal bone wall. The alveolar process next to implants placed in the palatal socket of the fresh extraction sites of extracted first maxillary premolars and next to implants placed in healed edentulous ridge at similar positions have been entirely resolved and the distance between the implant and the outer surface of the buccal bone plate had become markedly reduced. Based on clinical measurements, Botticelli *et al.* (2004) reported that during 4 months of healing following tooth extraction and implant placement the reduction of the buccal dimension was 56% (1.9 mm) while the reduction of the lingual dimension was 27% (0.8 mm). These findings which were based on measurements at 21 sites in 18 subjects, show that after implant placement all marginal gaps had practically become resolved and suggest that that implant placement in a fresh extraction socket may, in fact, not prevent the physiologic modeling/remodeling that occurs in the ridge following tooth removal. These findings further demonstrate that the bone(woven bone)-to-implant contact that was established during the early phase of socket healing following implant installation, was in part lost when the buccal bone wall underwent continued atrophy.

In summary, It is obvious that the alveolar process following tooth extraction will adapt to the altered functional demands by atrophy, and that an implant, in this respect, is unable to

substitute for the tooth. The clinical problem associated with immediate implant placement may be that unless the implant is placed palatal or lingual to the natural position of the root, bone loss frequently cause the buccal portion of the implant to gradually lose its hard tissue coverage, and the metal surface may become visible through a thin peri-implant mucosa or even be exposed and cause functional and/or esthetic concerns (Fig. 6).

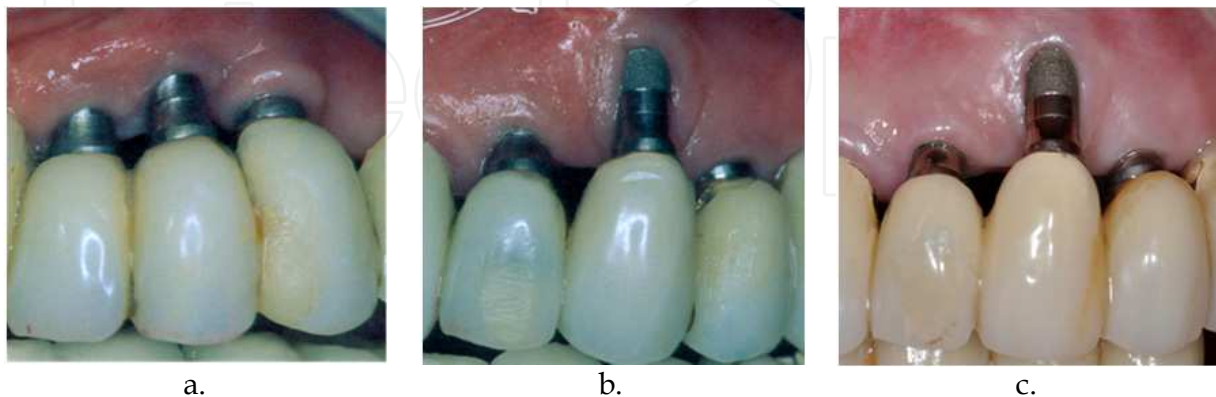


Fig. 6. Gradual bone loss associated with the buccal portion of an implant placed in the natural position of the extracted root. Bone loss results in exposure of the metal surface and causing esthetic concerns. a. one year after implant loading b. three years after implant loading. c. eight years after implant loading.

These findings were supported by a recent clinical study (Grunder, 2011) who have shown that following implant placement into fresh extraction sockets the average horizontal loss of hard and soft tissue measured 1.06 mm. Placing a subepithelial connective tissue graft using the tunnel technique in the labial area resulted in a slight (0.3mm) increase in the horizontal dimension of the ridge. Figure 7 presents a clinical case in which an implant is immediately placed after extraction of the mandibular first right molar tooth. An osteotomy at the center of the socket, through the septum, results in the establishment of an intimate contact between the surface of the implant body and the buccal and lingual base of the septum, the walls of the socket and the bone apical to it. Implant is stabilized at 45N. Osseoconductive graft material* and a coagulum resides in the void between the contact regions and peripheral bony walls of the socket. Six months later the implant is fully loaded. The final outcome after 1 year clearly shows that the buccal profile of the ridge is reduced in width, in spite of the atraumatic extraction, and immediately placed implant.

Atrophy of the edentulous ridge following tooth loss seems to be a biologic principle resulting in reduction of the width and the height of both the buccal and lingual bone plates; it is unavoidable and cannot be prevented by placing implants into the fresh extraction socket. This pathological phenomenon may be reduced by anchoring the implant deeper into the fresh socket, apical to it, and in a more lingual/palatal portion to that of the extracted tooth. In that case, bone regeneration procedures may be required to improve or retain bone volume and the buccal contour at a fresh extraction site. Adding a subepithelial connective tissue graft in the labial area may be favorable in the esthetic zone (Grunder 2011).

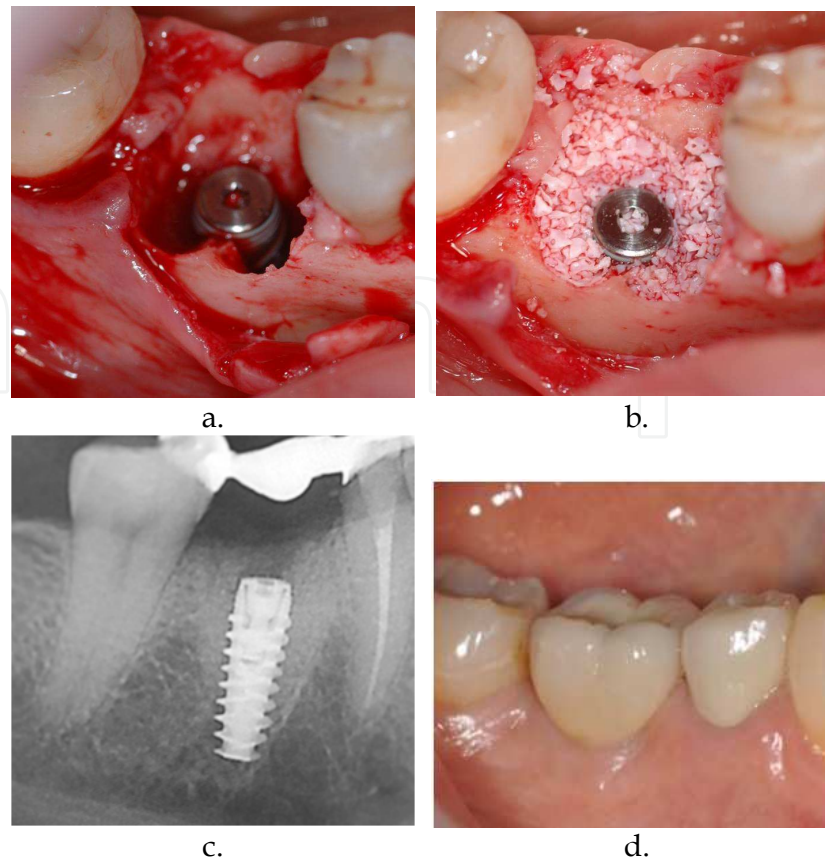


Fig. 7. Immediate placement of an endosseous implant in a lower molar fresh extraction socket. a. clinical view immediately after extraction and implant placement; implant surface is engaging the buccal and lingual remnants of the interradicular septum. b. the gaps between the implant surface and the socket walls is grafted with xenograft material*. c. periapical radiograph 6 months after implant placement. d. clinical view one year after extraction and implant placement shows a mild buccal deformation in the jaw owing to buccal bone loss and soft tissue adaptation.

2. Bone regeneration in the alveolar process of the jaw

Successful oral rehabilitation following tooth loss requires replacement of the missing roots, and satisfactory restoration of an adequate volume of bone; this is influenced mainly by health necessities, functional requirements, implant placement (Lekholm *et al.* 1986), and esthetic demands. Four methods have been described to achieve these goals: **osteinduction** using growth factors (Urist 1965; Reddi 1981); **osteoconduction** using grafting material as a scaffold for new bone growth (Buch *et al.* 1986; Reddi *et al.* 1987); **distraction osteogenesis**, by which the two fragments of a surgically induced fracture are slowly pulled apart (e.g. Ilizarov 1989a,b); **guided bone regeneration (GBR)**, which allows spaces maintained by barrier membranes to be filled with new bone (Dahlin *et al.* 1988, 1991a; Nyman & Lang 1994).

* Bio-Oss®, Geistlich Biomaterials, Wolhusen, Switzerland) alloplast 4Bone™ SBS: BioMATLANE SARL, France. Particles size of 0.25-1 mm

2.1 Guided bone 1 regeneration in the alveolar process of bone

Guided bone regeneration (GBR) which is better documented than the other methods for the treatment of localized bone defects in the jaws will be dealt in this chapter in depth; for other techniques the reader is referred to chapters (8-10). GBR allows the placement of endosseous implants in areas of the jaw with insufficient bone volume. Lack of bone volume may be due to congenital, post-traumatic or postsurgical defects or results in from disease processes (Figs. 4,5). It has been claimed that the predictability and success which can be achieved with GBR procedures enable the clinician to obtain similar rates of treatment success at sites with bone defects compared to sites without defects (Hammerle *et al.* 2002). (see also chapter 6).

Guided bone regeneration frequently forms a part of complex treatments, but this chapter focuses on the aspects of bone augmentation at localized defects in the alveolar process. More than two decades have passed since the introduction of GBR into clinical practice. Today, general understanding of the mechanisms leading to regeneration of desired tissues still agrees with the initially published statements regarding guided tissue regeneration (Karring *et al.* 1980; Nyman *et al.* 1980, 1989). In brief, when a space is formed, cells from the adjacent tissues grow into this space to form their parent tissue, i.e. the tissue they migrated in from. In order to give preference to cells from desired tissues, tissue barriers, most commonly membranes, are placed to prevent cells from undesired tissues having access to the space. (Figure 8)

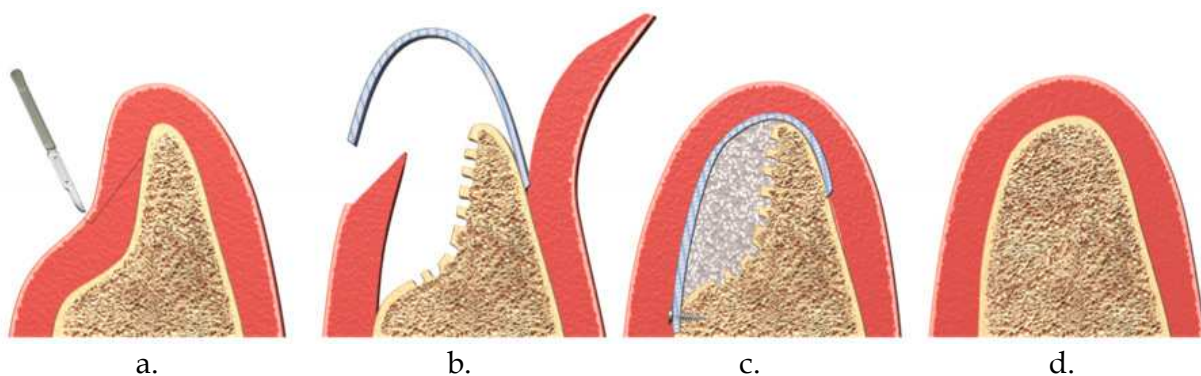


Fig. 8. Guided bone regeneration scheme describing the use of a resorbable barrier membrane. a. bony defect is diagnosed b. the defect is debrided, bone cortex is perforated, and a membrane supporting scaffold material is placed. c. the membrane is stabilized and shaped to dictate the desired bone contours d. a few months later bone regeneration is observed restoring the desired shape of the jaw.

Experimental research regarding ridge augmentation using GBR has shown that in large surgically created defects in the alveolar ridge, treatment with membranes with or without the addition of grafts, entirely filled the space between the membrane and the bone with bone; in the absence of membranes, bone formation was lacking (Seibert & Nyman 1990). These findings received further support by later investigators who reported that GBR procedures can successfully be employed in the regeneration of alveolar ridge defects (Seibert & Nyman 1990; Schenk *et al.* 1994; Smukler *et al.* 1999). While intrabony alveolar ridge defects and lateral ridge augmentation has been shown to be predictable (Nyman *et al.* 1990; Dahlin *et al.* 1991b; Becker *et al.* 1994b; Buser *et al.* 1996; von Arx *et al.* 2005), vertical bone gain was initially less promising. Intensive efforts in GBR therapy were focused on vertical ridge augmentation, due to the great demands of this procedure. Clinical experiments have shown promising results

when placing of autogenous bone grafts or bone substitute materials in combination with e-PTFE membranes of various configurations (Simion *et al.* 1994b, 1998 Tinti *et al.* 1996; Tinti & Parma-Benfenati 1998; Chiapasco *et al.* 2004). The membranes were supported either by the graft alone or additionally by implants protruding vertically from the host bone for various lengths. Employing vertical GBR, it was possible to achieve bone gain above the external borders of the jaw (Lundgren *et al.* 1995; Hämmerle *et al.* 1996, 1999; Schliephake & Kracht 1997; Schmid *et al.* 1997; Lorenzoni *et al.* 1998). Although in some experiments vertical bone formation reached up to 4 mm above the previous border of the alveolar crest, clinical attempts to regenerate vertical bone was not predictable, and bone growth to the top of the membrane was not consistently achieved. (Simion *et al.* 1994a).

Advances in guided bone regeneration had become possible thanks to a series of biomaterials including tissue barriers, bone grafts and bone graft substitutes. Recently, growth and differentiation factors and tissue engineering means have been added to the available stock of such materials. These biomaterials are briefly mentioned at the end of this chapter and are dealt with more thoroughly in chapters 11-14 Successful GBR depends on the ability of the different materials to provide a space into which bone originated granulation tissue can proliferate exclusively, partly due to peripheral cell occlusiveness achieved

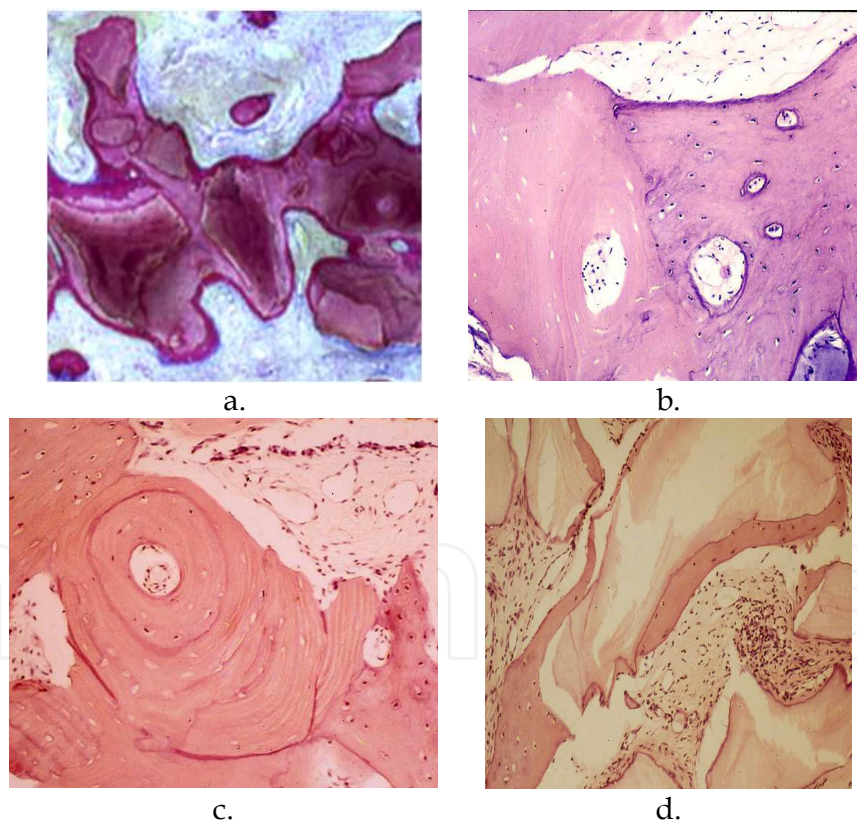


Fig. 9. Biopsy specimens demonstrating bone growth in the presence of osseoinductive and osseoconductive bone scaffold grafts. a. deproteinized bovine bone mineral completely surrounded with intimately integrated new bone in a GTR procedure b. demineralized freeze-dried bone allograft (left) in intimate contact with new bone (right) c. demineralized freeze-dried bone allograft in intimate contact with new bone. Notice a centrally developing osteon. d. deproteinized bovine bone mineral surrounded with new bone in a GBR procedure.

by tissue barriers. Success rates of the GBR procedure further depends on the stability of the healing site, minimal or no tissue reactions resulting from the presence and/or resorption of the occluding barriers, bone substitutes (Gottlow 1993), and osseointensity/conductivity of the bone scaffold in use (Figs. 9,10).

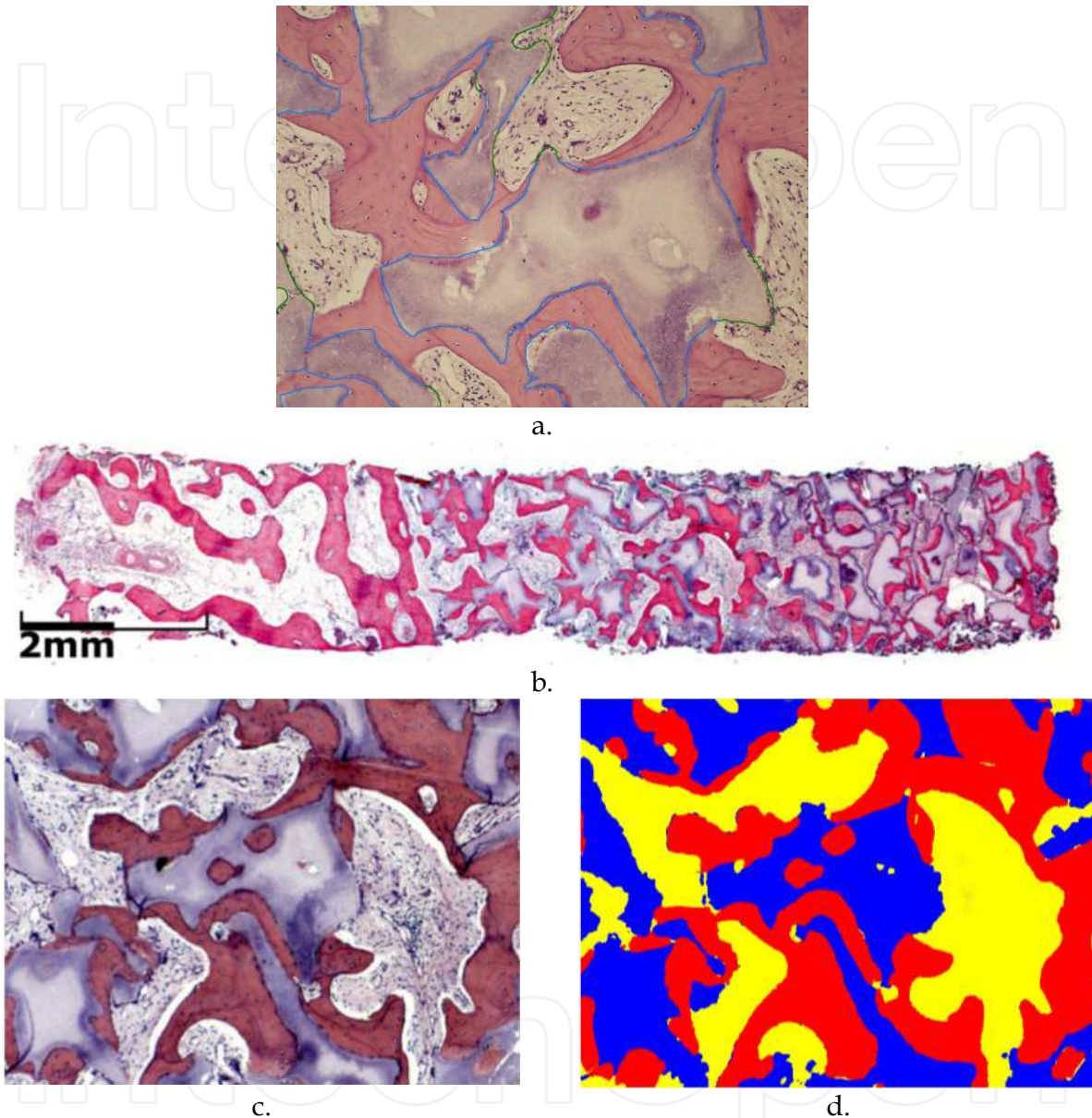


Fig. 10. a. A 9 months biopsy sample demonstrating allopast graft particles** surrounded by vital bone and connective tissue. Bone to graft contact areas are marked with a blue line. (Hematoxylin & Eosin, original magnification x400) Histological view of a specimen obtained from a regenerating tissue in the sinus demonstrating allopast graft particles** surrounded by vital bone and connective tissue. b. (H&E original magnification x10). c. higher magnification from fig 10b. d. computer analysis of surface areas of new bone (red), graft material (blue), and connective tissue (yellow). (x40)

** A fully synthesized homogenous hydroxyapatite and beta tricalcium phosphate (HA : β -TCP) 60 : 40 allopast 4Bone™ SBS: BioMATLANE SARL, France. Particles size of 0.25-1 mm

2.2 Biomaterials for guided bone regeneration in the jaws – Animal and human studies

Extensive research has been conducted in search for the ideal enhancing bone repair and regeneration substance. Among the many available materials, bovine bone mineral (BBM) (Bio-Oss®, Geistlich Biomaterials, Wolhusen, Switzerland) is perhaps the most extensively researched one, presenting very favorable biocompatibility and osteoconductive qualities (Spector 1994; Jensen et al. 1996; Berglundh & Lindhe 1997; Boyne 1997; Hämmerle et al. 1997; Skoglund et al. 1997; Artzi & Nemcovsky 1998 Artzi et al 2000, 2001a,b,c, 2002). Based on the authors experience as well as other investigators, it has proved to be an appropriate scaffold in ridge deficiencies, peri-implant destruction, and sinus augmentation procedures (Smiler et al. 1992; Wetzel et al. 1995; Dies et al. 1996; Hürzeler et al. 1997; Valentini & Abensur 1997; Piattelli et al. 1999; Artzi et al. 2000, 2001a,b, 2002, 2003a,b 2005; Hallman et al. 2001b, 2002a).

In a 24 months comparative study (Artzi et al 2003a), the healing of surgical experimental defects grafted with bovine bone mineral was studied in the dog mandible, with and without tissue barrier membranes. Average bone area fraction at the bovine bone mineral uncovered sites was 23.1%, 44%, 63.4%, and 58.8% at 3, 6, 12, and 24 months, respectively. Differences were statistically significant between 3 to 6 and 6 to 12 months ($P < 0.001$). At the membrane-protected sites, average bone area fraction was 26.4%, 51.7%, 61.2%, and 52.4%, at the respective periods. Differences were statistically significant between 3 to 6 months ($P < 0.05$). However, Differences between the two sites with regard to the newly formed bone and particle presence were insignificant. At 3 and 6 months, newly formed bone, woven in nature, was incorporated with the grafted particles. High cellular bone with occasional osteoclasts was noted towards the surface of the mineral particles. Osteons were established in direct contact to particle configuration (Fig. 11.)

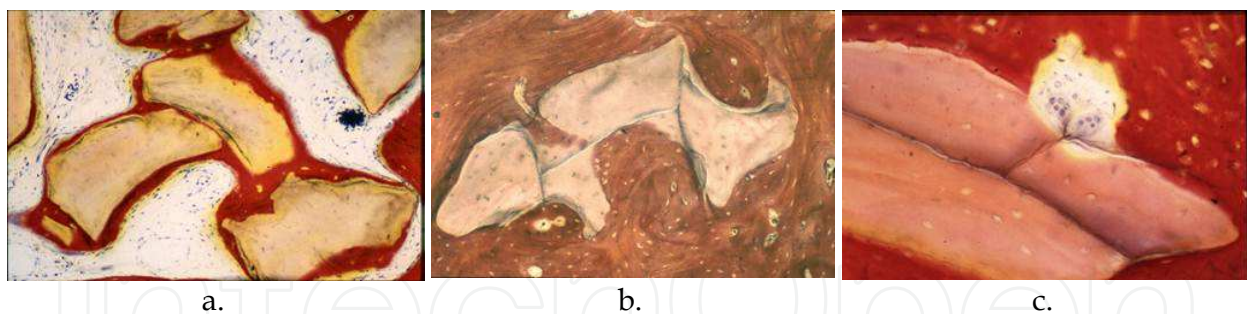


Fig. 11. Photomicrograph of a bony defect grafted with bovine bone mineral (BBM). a. At 3 months, newly formed bone primarily surrounds the grafted BBM particles (Stevenel's blue and Van Gieson's picro fuchsin staining; original magnification $\times 100$). b. At 12 months, Haversian canal system; i.e., osteons, is established in proximity to the BBM particle and in accordance to its configuration (Stevenel's blue and Van Gieson's picro fuchsin staining; original magnification $\times 100$). c. On higher magnification, note presence of multinucleated cells i.e., osteoclasts in proximity to the particle (Stevenel's blue and Van Gieson's picro fuchsin staining; original magnification $\times 400$).

At 1 and 2 years, the grafted sites showed complete bone healing configuration, however, the grafted particles - completely surrounded by the newly formed bone - were still predominant (Fig. 12). Osteons and lamellar bone arrangement were established but the

bone was still highly cellular and osteoclasts could still be identified. The biomaterial did not show any substantial resorption within 2 years observation period of time.

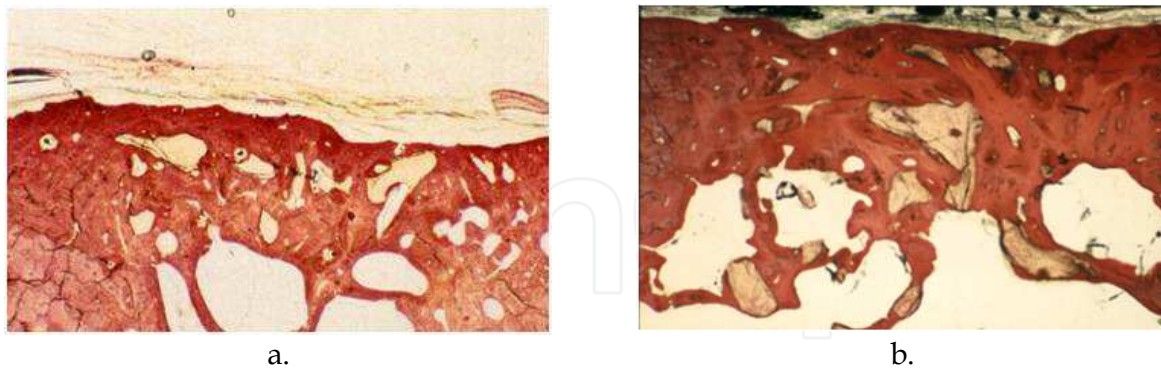


Fig. 12. Photomicrograph of a bony defect grafted with bovine bone mineral particles a. At 12 months, protected by the membrane, the entire defect is filled with bone (Stevenel's blue and Van Gieson's picro fuchsin staining; original magnification $\times 20$) b. At 24 months, the bovine bone mineral grafted site is filled with newly formed bone surrounding a substantial amount of grafted particles (Stevenel's blue and Van Gieson's picro fuchsin staining; original magnification $\times 20$).

When bovine bone mineral was grafted under a configured titanium mesh serving as a contained stabilized vehicle to restore a deficient alveolar ridge (Artzi et al 2003), average bone fill of $81.2\% \pm 7.98$ was measured with remarkable height gain of 5.2 ± 0.79 mm. Picrosirius red stained sections examined under polarized illumination, showed a gradual increase in new lamellar bone from the coronal to the most apical sections, reaching highest bone density near the most apical zone. (Fig 13 a,b).

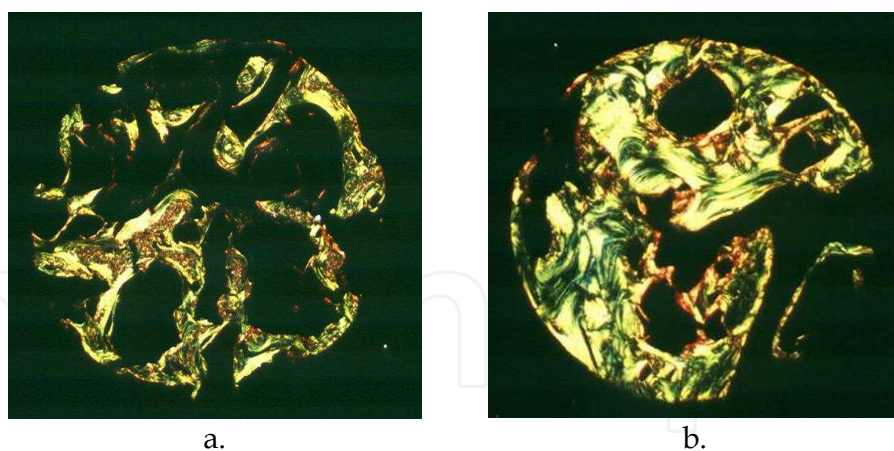


Fig. 13. a. Photomicrograph of coronal section, mainly woven bone, containing both unorganized thin and thick collagen fibers with polarization colors of green to greenish-yellow (Picrosirius red staining with polarizing microscopy, $\times 20$ magnification). b. Apical section presenting a higher percentage of lamellar bone at 9 months consisting mainly of fibers with greenish-yellow and yellow polarization colors (Picrosirius red staining with polarizing microscopy, $\times 20$ original magnification).

Beta tricalcium phosphate (β -TCP) (Cerasorb®, Curasan, Kleinostheim, Germany), a ceramic alloplast, is another popular graft material, extensively researched with pleasing results

(Breitbart et al. 1995; Gao et al. 1997; Buser et al. 1998; Ohsawa et al. 2000; Szabo et al. 2001). β -TCP is biocompatible (Rosa et al 1995, Hossain et al 1996, Ohsawa, et al 2000) , ,and achieves favorable volumetric maintenance. (Breitbart et al 1995, ; Gao et al. 1997) In a comparative histomorphometric study in miniature pigs (Merten et al 2001), β -TCP has shown very favorable qualities of biodegradation and substitution.

Unlike deproteinized bovine bone mineral xenograft, β -TCP has shown extensive resorption within 12 to 84 months after grafting (Yamada et al. 1997; Wiltfang et al. 2002), raising the question on the relationship between the material resorption rate and amount of newly formed bone in the augmented sites. Looking into this query we have undertaken to explore the osteoconductive and resorbability expressed by both deproteinized bovine bone mineral and β -TCP in identical defects performed in the dog mandible (Artzi et al 2004). At the bovine bone mineral sites, newly formed bone was incorporated and primarily established near the native defect walls and around the grafted particles at 3 months. At 6 months most of the defect ($51.7\% \pm 2.5$) was filled with bone. At 12 and 24 months, complete bone regeneration was evident, but the grafted mineral particles still dominated the grafted sites (Fig 14).

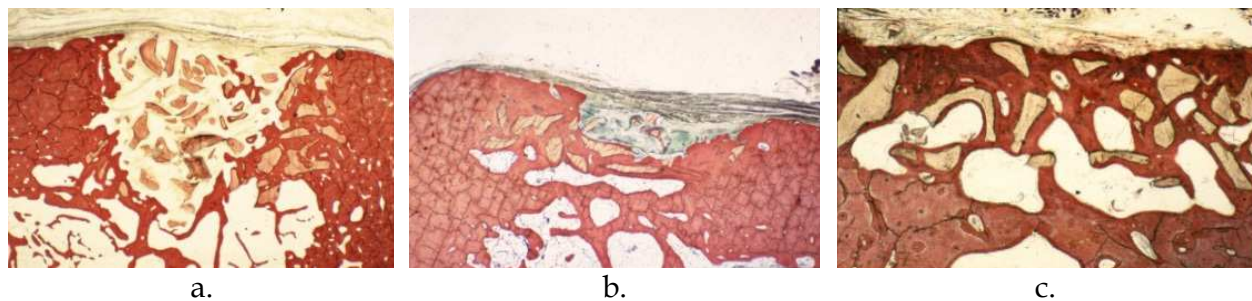


Fig. 14. Photomicrograph of a bony defect grafted with bovine bone mineral particles. a. At 3 months, newly formed bone surrounds part of the grafted IBB particles mainly close to the native bony walls (Stevenel's blue and Van Gieson's picro fuchsin staining, original magnification x20). b. At 6 months, most of the defects are filled with newly formed bone incorporated around the grafted particles (Stevenel's blue and Van Gieson's picro fuchsin staining, original magnification x20). c. At 24 months, bovine bone mineral particles dominate the grafted site and completely incorporate with the newly formed bone to achieve complete healing site configuration (Stevenel's blue and Van Gieson's picro fuchsin staining, original magnification x20).

Under high power magnification, osteoid formation was noted even after 1 month. At 3 months, highly cellular newly formed bone was observed mainly around the grafted particles. At 6 months most of the particles were surrounded by newly-formed bone that filled the majority part of the defect.(Fig 15)

At the β -TCP sites, aggregates of β -TCP particles were still predominated at 3 months, while newly formed bone was noted primarily near the native bone (Fig16a.). At 6 months, defects showed almost complete bone fill. The grafted particles were completely embedded in the newly formed regenerated bone (Fig 16b). At 12 months, there were only remnants of the particles, particularly in the center of the defect, distal from the bony walls and at 24 months, particles were completely resorbed and the entire defect was filled with new bone in both in membrane-protected and unprotected defects. (Fig. 16c)

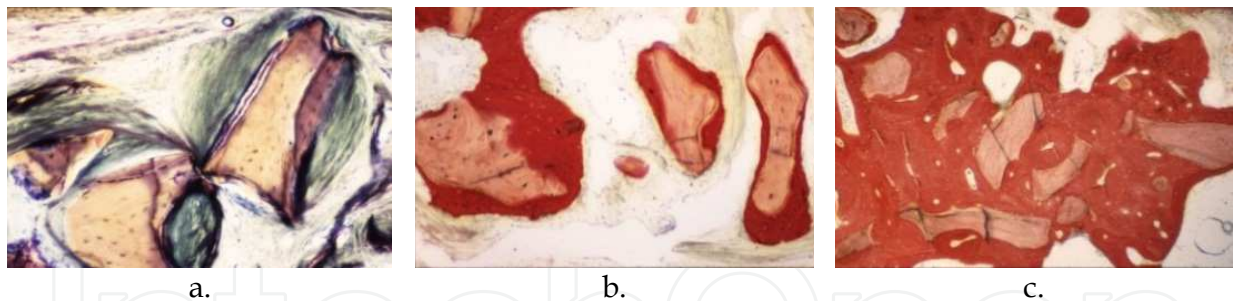


Fig. 15. Photomicrograph of a bony defect grafted with bovine bone mineral particles. a. At 1 month, bovine bone mineral is already surrounded by the greenish staining of osteoid formation (Stevenel's blue and Van Gieson's picro fuchsin staining, original magnification x200). b. Newly formed bone primarily surrounding the grafted particles (Stevenel's blue and Van Gieson's picro fuchsin staining, original magnification x100). c. At 3 months, newly formed bone is filled the space and interconnecting the grafted particles (Stevenel's blue and Van Gieson's picro fuchsin staining, original magnification x40).

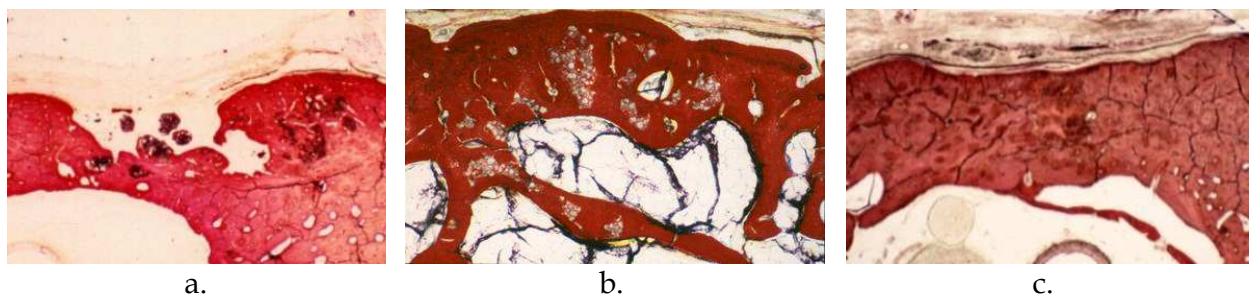


Fig. 16. Photomicrograph of a bony defect grafted with β -tri-calcium phosphate particles (β -TCP). a. At 3 months at the membrane-protected sites, newly formed bone (Stevenel's blue and Van Gieson's picro fuchsin staining, original magnification x20). b. At 6 months, there was complete newly formed bone bridging the defect (Stevenel's blue and Van Gieson's picro fuchsin staining, original magnification x20). c. At 24 months healing period, β -TCP particles were fully resorbed and the defect was completely regenerated by newly formed bone (Stevenel's blue and Van Gieson's picro fuchsin staining, original magnification x20).

High power magnification reveals that, β -TCP particles were surrounded by highly cellular newly formed bone showed grafted particles in advancing stages of resorption and/or significant degradation. Osteoclasts were observed near the resorbed particles (Fig 17).

Additional osseoconductive bone-graft substitute which is noteworthy is a biphasic hydroxyapatite/ β -tricalcium phosphate (HA/TCP) produced by a single process to prevent clustering and to establish a new homogeneous molecule. Its 60:40 ratio of hydroxyapatite: β -tricalcium phosphate, gives it two phases of activity. HA/TCP offers an interconnected porosity of 90% (pores ranging from 100-500 μ m in diameter) to support cellular penetration. While the HA - biphasic TCP compound have shown promising results extra-orally (Russotti *et al.* 1987; Brook *et al.* 1991; St John *et al.* 1993; Emery *et al.* 1996; Gauthier *et al.* 2001; Le Nihouannen *et al.* 2005; Schopper *et al.* 2005; Blouin *et al.* 2006; Fellah *et al.* 2006) and in animal studies also intra-orally (Hashimoto-Uoshima *et al.* 1995; Boix *et al.* 2004, 2006), it still lacks clinical validation in intra-oral applications in humans.

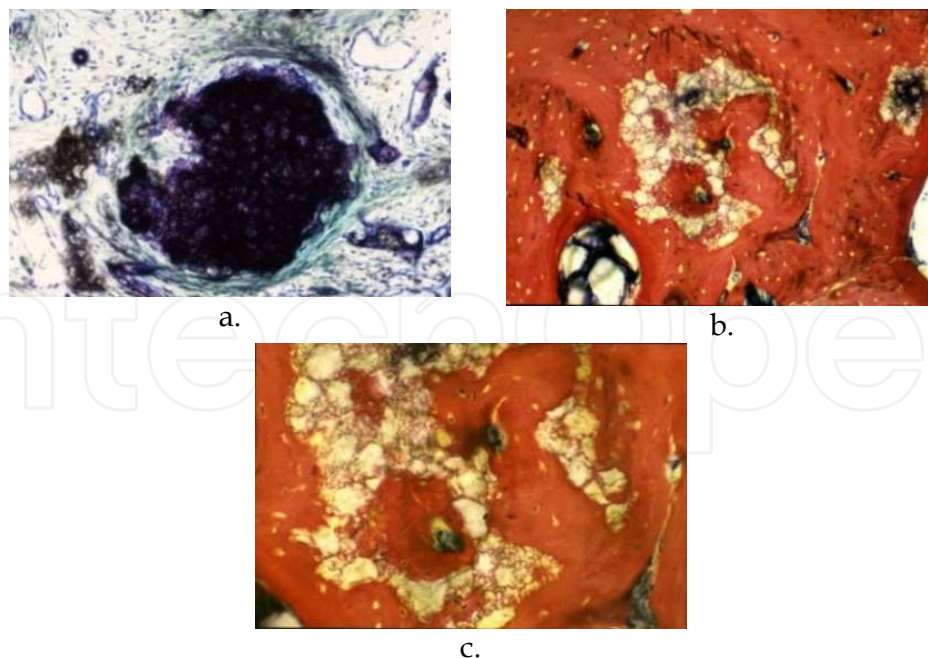


Fig. 17. Photomicrograph of a bony defect grafted with β -tri-calcium phosphate particles (β -TCP). a. Greenish staining of osteoid formation was evident around β -TCP particles, which was not in proximity to the native bony walls (Stevenel's blue and Van Gieson's picro fuchsin staining, original magnification x600). b. Newly formed bone incorporated with the grafted β -TCP particles that were in an advanced stage of resorption (Stevenel's blue and Van Gieson's picro fuchsin staining, original magnification x100). c. Higher magnification of panel b. Osteoclasts observed near the resorbed β -TCP particles (Stevenel's blue and Van Gieson's picro fuchsin staining, original magnification x200).

To evaluate HA/TCP with autogenous particulate cancellous bone, this composite graft combination was examined in sinus augmentation procedures (Artzi et al 2008). Newly formed bone around the grafted particles was found in all samples. The encircling, highly cellular bone followed the outline of the grafted particles in direct contact (Fig. 18a-b). Both woven and lamellar types of bone were observed (Fig. 19)

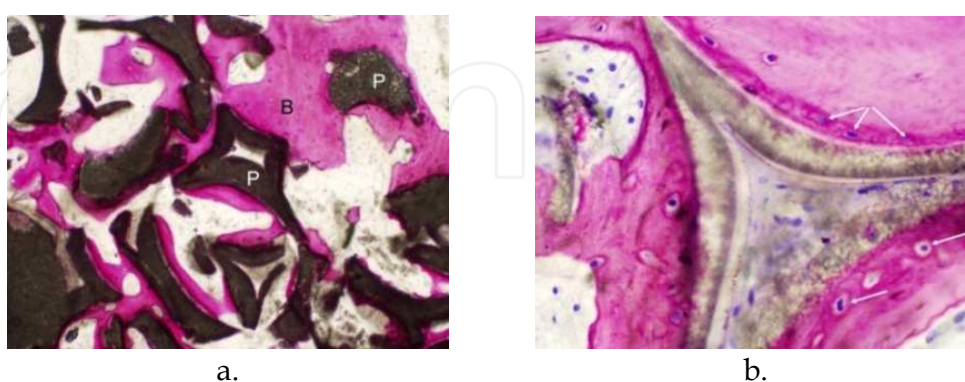


Fig. 18. Photomicrograph of a bony defect grafted with a biphasic hydroxyapatite/tricalcium phosphate (HA/TCP) a. Most of the grafted particles (P) surrounded by newly formed bone (B) (Paragon staining, original magnification x150). b. Osteocytes (arrows) lining the interface osseous zone in direct contact with the grafted HA/TCP particle (Paragon staining, original magnification x600).

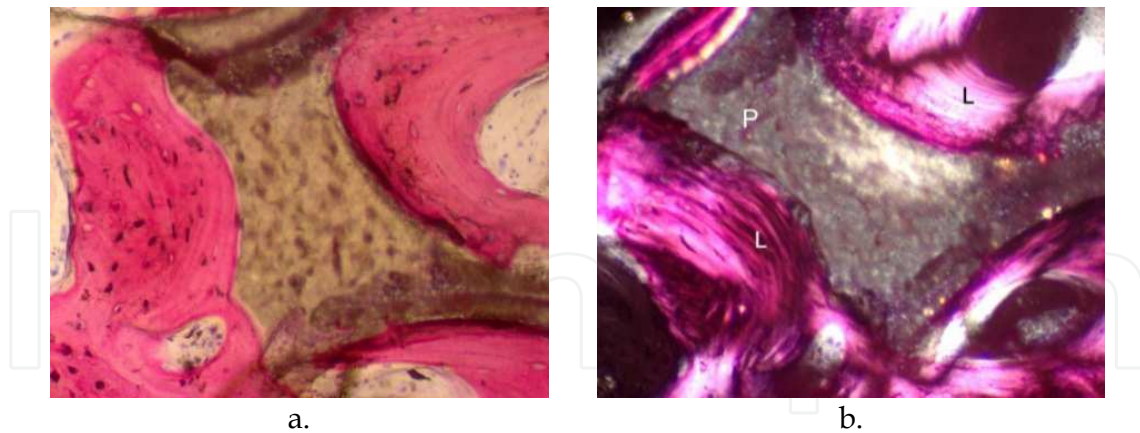


Fig. 19. Photomicrograph of a bony defect grafted with a biphasic hydroxyapatite/tricalcium phosphate (HA/TCP). a. A high magnification of a 6-month grafted particle fully surrounded by newly-formed bone (Paragon staining, original magnification x600). b. Polarized light image of the specimen shown in fig. 3a.; bone lamellar structure is displayed adjacent to the grafted particle (P) (L). (Paragon staining, original magnification x600).

Morphometrically, mean bone area fraction increased from $28.6\% \pm 7.8$ at 6 months to $41.6\% \pm 8.3$ at 9 months. In resemblance to bovine bone mineral, this biomaterial occupied a surface average of 25% at both observation periods. This alloplast as a composite with autogenous bone chips promotes newly formed bone, which increases in its fraction along an extended healing period.

3. Alveolar ridge preservation

3.1 Alveolar ridge preservation after extractions

Since the most frequent cause for alveolar ridge augmentation is implant site development, long term studies examining different scaffold materials and GBR procedures have focused on GBR at implant sites. The survival rate of implants placed into GBR treated sites varies between 79% and 100% with over 90% survival rate after being in function for at least 1 year. These data are comparable to those reported for implants placed into native, untreated sites. For more data the reader is referred to a few systematic reviews that have focused on the subject of survival and success rates of implants placed within regenerated bone (Hammerle *et al.* 2002; Fiorellini & Nevins 2003; Chiapasco *et al.* 2006).

Augmentation and preservation of the alveolar process and ridge poses a few treatment strategies, depending on the bony defect morphology available. According to the bone morphology immediately after extraction, one out of two procedures is selected: a) the one-step (combined) approach (immediate implant placement plus GBR) is preferred if anchorage of the implant with primary stability is possible or b) the two-step (staged) approach is preferred when the defect morphology precludes primary implant stability; the two-step approach requires bone augmentation to a degree allowing implant placement in a second intervention (Figure 20).

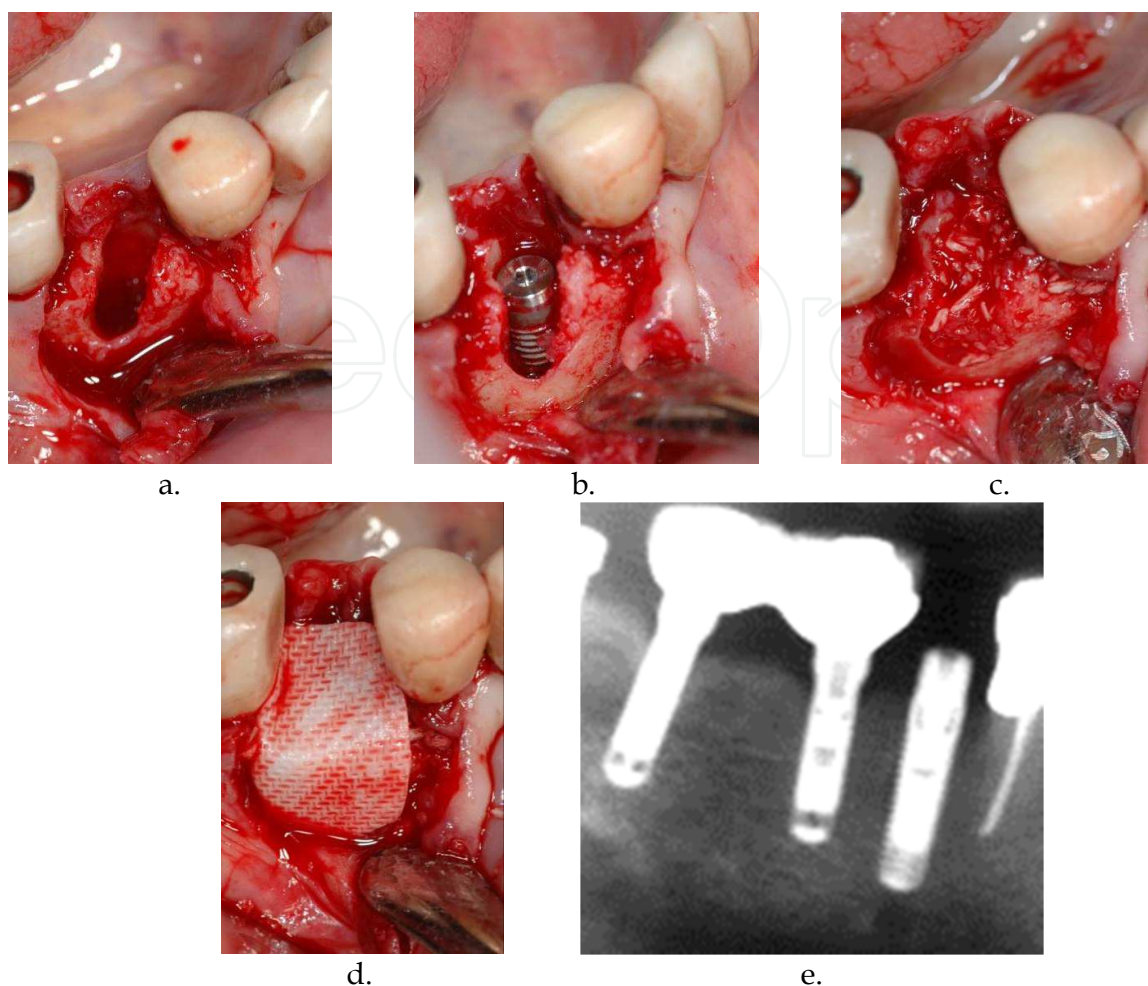


Fig. 20. One staged implant placement in a Type 2 bony defect in the mandible. a. bone defect due to extraction made 8 weeks earlier. b. endosseous implant anchored in the peripheral and apical bone. c. peri-implant gaps are filled with autogenous bone chips mixed with alloplast graft material. d. defect is covered with a cross linked collagen membrane***.

Since in most cases suffering from bone loss and/or ridge deformations there is lack of soft tissue in addition to lack of bone, it is advisable to improve the soft tissue coverage as early as possible, preferably at the time of hard tissue augmentation. Clinical attempts to maintain the ridge contours and improve the soft tissue biotype by grafting particulate autogenous bone or non-resorbable materials into the fresh extraction socket were carried out with partial success. GBR used to preserve or augment the alveolar ridge at the time of tooth extraction was employed by grafting "supporting materials" into fresh extraction sockets and covering it by non-resorbable membranes (Nemcovsky & Serfaty 1996; Lekovic *et al.* 1997; Fowler *et al.* 2000). Two main shortcomings of this procedure were a. histological findings revealed that some "supporting materials" like DFDBA presented "dead" particles with no evidence of bone formation on the surfaces of the implanted particles and no evidence of osteoclastic resorption of the grafted particles. (Becker *et al.* 1994a) and b. the lack of soft tissue to completely cover the grafted site.

*** Ossix-P™ Colbar, Ramat Hasharon, Israel

3.2 Histological and histomorphometrical studies of ridge preservation after extractions

Histologic and Histomorphometric comparison of specimens from sites treated with GBR and non treated sites revealed that more vital bone had formed in the first group. Both osteoconductivity and resorbability of the materials apparently influenced new bone formation in a positive manner (Artzi *et al.* 2000; Bolouri *et al.* 2001; Froum *et al.* 2002). Artzi *et al.* (2000,2001a,b) have shown that when bovine bone mineral was used solely to fill the socket without applying GBR principles, the average clinical overall bone fill of the augmented socket sites was 82.3%. Newly formed bone encircled and adhered to the grafted material in most specimens. Osteoblasts were present within an osteoid layer, lining the interface zone of the bovine mineral particles and the new osseous tissue. Histomorphometric measurements showed an increase of mean bone tissue area along the histological sections from 15.9% in the coronal part to 63.9% apically with overall average of 46.3% (Fig.21 a-b). Newly formed bone was characterized by abundance of cellular woven-type bone in the coronal area, while lamellar arrangements could be identified mainly in the more apical region. Woven/lamellar bone ratio analyzed using polarized microscopy about 10 folds in favor of the woven bone at the crestal region whereas it was nearly 1:1 ratio at the apical zone of the grafted socket (Fig21 c-d).

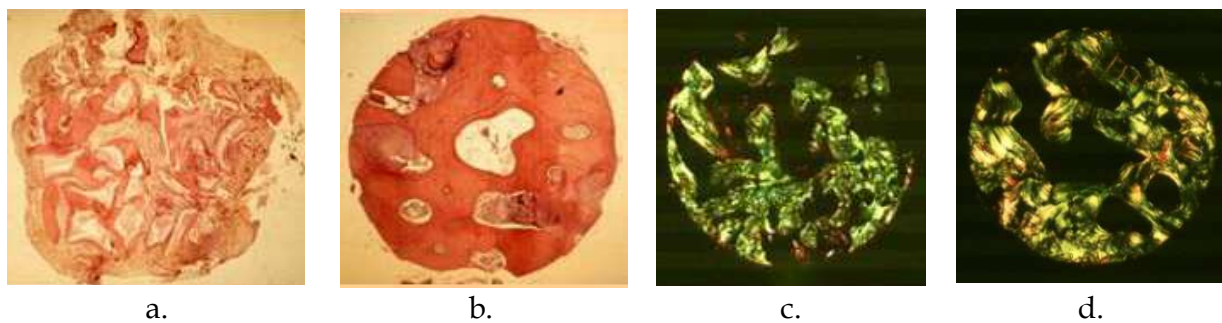


Fig. 21. Photomicrograph of a socket site grafted with bovine bone mineral particles at 9 months. a. A crestal section cut disclosed abundant amount of connective tissue and bovine mineral particles and only occasional osseous fragments. (HE staining X 20 magnification). b. An apical section cut: most of the area fraction is occupied by osseous tissue, while bovine mineral particles are well demonstrated. Only a small amount of connective tissue could be identified. (HE staining X 20 magnification). c. Polarizing microscopy of a crestal section cut of bovine bone mineral grafted socket site. The bone area is woven type (Picrosirius red staining; original magnification X 20). d. An apical section cut under polarizing microscopy. Note the dominance of the yellowish-orange lamellar bone type (Picrosirius red staining; original magnification X 20).

3.3 Timing of augmentation and implant placement

As previously mentioned, early implant placement concurrent with guided bone regeneration technique has shown encouraging results (Donos *et al.*, 2008; Buser *et al.*, 2009). It has also been claimed that obtaining initial stability of the implant is a prerequisite for successful osseointegration no matter what technique is applied (Wikesjo & Nilveus 1990, Rasmusson *et al.*, 1999, Lundgren *et al.*, 1999, Becker 2005, Lioubavina-Hack *et al.*, 2006). However, today there is no clear evidence whether simultaneous GBR procedure affects implants survival rate (Donos *et al.*, 2008).

Implant stability and soft tissue condition are the principal tools in evaluating healing and function. Most researchers and clinicians have used probing depth, bleeding on probing, and implant stability as the main parameters to assess and monitor implants success or failure. Despite the amenable healing response shown after implant placement in a simultaneously augmented bone sites, both simultaneously or in a 2-stage mode, we found a great interest in following up implants placed in either of the two techniques.

In a longitudinal study implant placement and bone augmentation as either a combined or staged procedure were monitored at 8 and 16 months post implant placement (Artzi et al 2012). Using clinical parameters such as peri-implant soft tissue conditions and implant stability. It was found that while probing depth and bleeding on probing improved along the time, implant stability was significantly higher when using the delayed mode. We concluded that both techniques may be accepted safe.

In another study in the dog, a qualitative and quantitative evaluation on the degree of osseointegration was conducted to explore the efficacy of implant placement and GBR procedure performed simultaneously or as a 2-stage procedure (Artzi et al 2010). Morphometric analysis disclosed that a similar osseointegration level over time was shown at the simultaneous (mean of $77.95\% \pm 11.24$) and delayed ($79.82\% \pm 7.54$) techniques (Figs 22, 23).

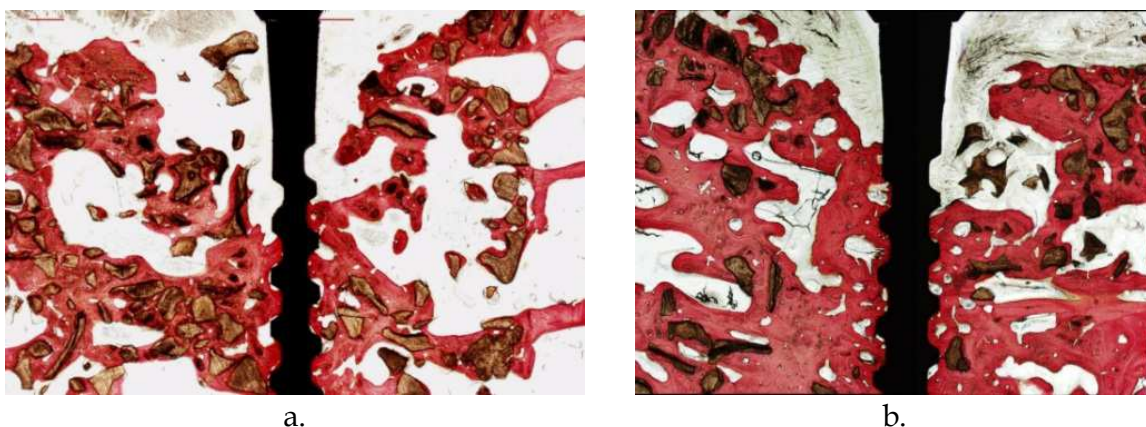


Fig. 22. Photomicrograph of an experimental intrabony site grafted with bovine bone mineral (BBM) a. At 8 months, a coronal part of a simultaneous implant placement and bone augmentation procedure using bovine bone mineral particles. Note the crestal bone level in reference to the implant neck. (The implant core was trimmed due to lack of interest and to allow an expanded view at the periphery). (Stevenel's blue and Van Gieson's picro fuchsin staining x35 original magnification). b. A coronal part of an implant placed at a 6-month regenerated grafted BBM site at 8 months (Stevenel's blue and Van Gieson's picro fuchsin staining x35 original magnification).

In both techniques, newly-formed bone enhancement was observed proximal to the rough surface of the implant. However, the staged approach showed enhanced newly-formed bone (63.42 ± 9.41 vs. 55.04 ± 5.60 ; $p < 0.05$), less crestal bone resorption (0.92 ± 0.33 vs. 1.11 ± 0.26 ; $p < 0.05$), and smaller vertical bone defect (0.50 ± 0.37 vs. 0.88 ± 0.43 ; $p < 0.05$) over time compared to the combined approach. The staged approach showed also better significant results in regard to higher osteoconduction around the grafted mineral particles ($71.42 \pm$

18.29 vs. 37.71 ± 24.31 ; $p < 0.05$), however, only at 8-month period. Practically, although the staged approach showed enhanced bone level and higher bone density, timing of the augmentation procedure did not influence the degree of osseointegration or the clinical outcome.

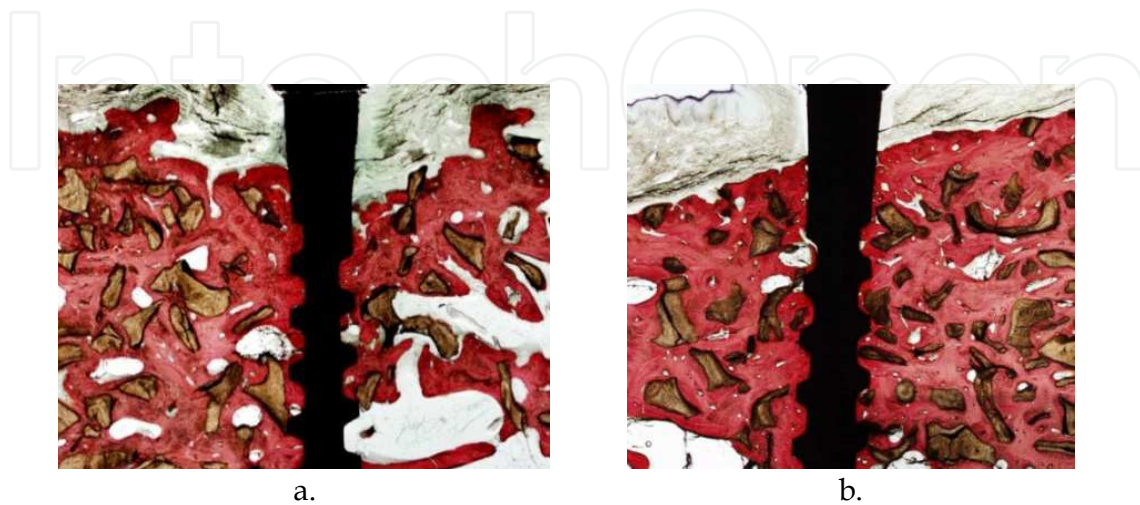

Fig. 23. Photomicrograph of an experimental intrabony site grafted with bovine bone mineral (BBM) a. At 16 months, a coronal part of a simultaneous implant placement and bone augmentation procedure. Note the improved crestal bone level (Stevenel's blue and Van Gieson's picro fuchsin staining x35 original magnification). b. A coronal part of an implant placed at a 6-month regenerated grafted BBM site at 16 months (Stevenel's blue and Van Gieson's picro fuchsin staining x35 original magnification).

3.4 Soft tissue management in alveolar ridge preservation procedures

Applying GBR procedures resulted in reduced rate of resorption of the alveolar process in comparison with untreated control sites (Lekovic *et al.* 1997, 1998; Yilmaz *et al.* 1998; Camargo *et al.* 2000). Complications with soft tissue dehiscences, however, frequently occurred in GBR-treated sites (Fowler *et al.* 2000; Yang *et al.* 2000). GBR procedures applied for ridge volume preservation have two main shortcomings: a. it requires a 5-6 months healing period of time before endosseous implants can be placed; b. soft tissue coverage are technique sensitive procedures and may lead to a compromised esthetic result. Significant improvement regarding the profile of the alveolar ridge has been achieved with the introduction of various techniques aimed at improving the soft tissue conditions. Evian & Cutler (1994) described the use of autogenous soft tissue grafts to seal extraction sites at the time of implant placement. The technique was further improved by using free gingival grafts as socket sealers before (Landsberg & Bichacho 1994) or at the time of implant placement (Landsberg 1997) (Figs.24,25,26). The main problem associated with this technique was necrosis of the transplanted mucosa (Tal 1999) and poor color integration at the recipient site.

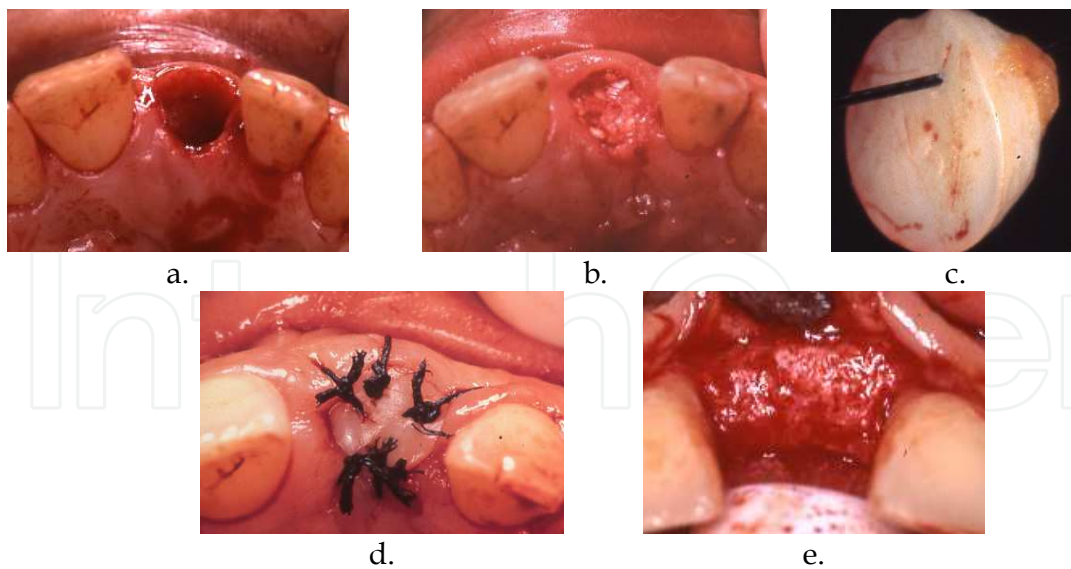


Fig. 24. Ridge preservation (implant site development) at the time of extraction using a free gingival graft as socket sealer. a. atraumatic extraction and complete circumferential curettage of the pocket epithelium. b grafting the fresh extraction sockets with demineralized freeze-dried bone allograft. c. free connective tissue graft obtained from an upper distal edentulous ridge d. socket orifice is sealed with the free gingival graft e. six months post extraction ridge preservation is demonstrated at the time of implant placement.

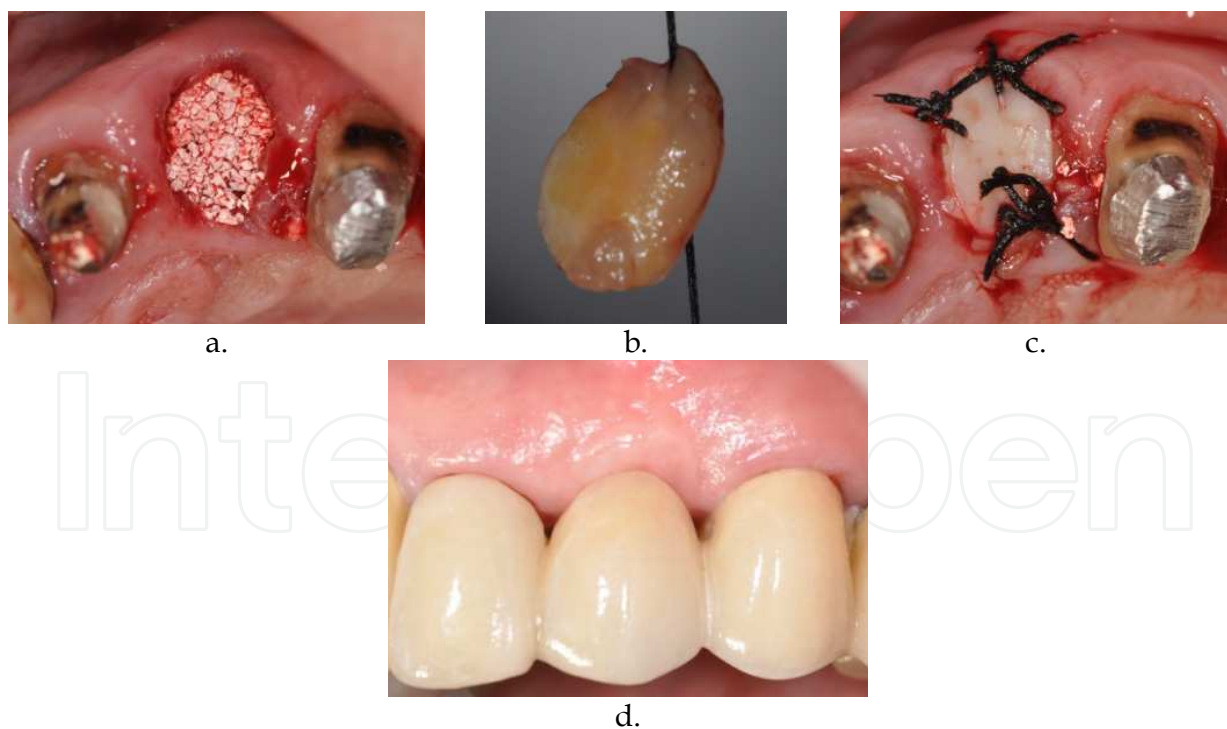


Fig. 25. Ridge preservation at the time of extraction using a free gingival graft as socket sealer. a. grafting a fresh extraction sockets with 4Bone alloplast ** material b. inner side of a free connective tissue graft obtained from the palate c. socket orifice is sealed with the free gingival graft d. Five months post-extraction the alveolar ridge preserves its natural contours, and is ready for a tooth supported 3 units bridge.

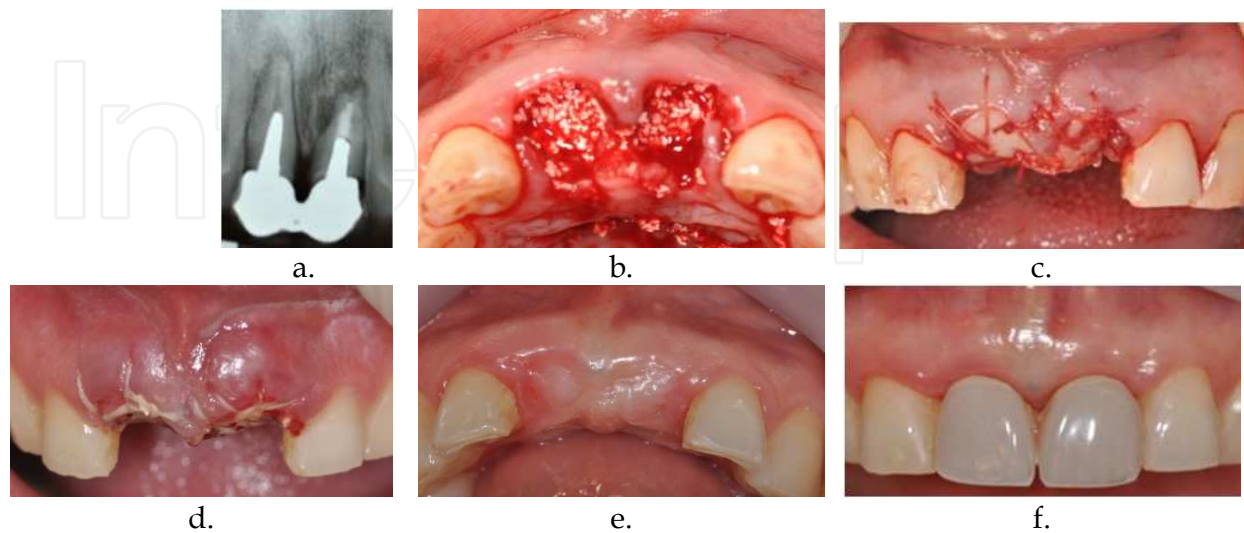


Fig. 26. Ridge preservation at the time of extraction using free gingival graft (left) and granulation reactive connective tissue (right) as socket sealers. a. radiographic view of the upper central incisors before extraction b. atraumatic extraction is followed by grafting the fresh extraction sockets with 4Bone alloplast**. c. sockets orifice is sealed with a free gingival graft (right) and socket granulation reactive connective tissue and a free gingival graft (left). e. and f. six months post extraction complete healing is demonstrated without and with a temporary restoration.

In search for a more predictable technique two additional approaches were applied. Mardinger et.al.(2010) have used intra-socket reactive soft tissue for primary closure during augmentation of infected extraction sites exhibiting severe bone loss prior to implant placement or as part of ridge preservation procedures. Porous bovine xenograft bone mineral was grafted into extraction sites demonstrating extensive bone loss. The intra-socket reactive soft tissue was sutured over the grafting material to seal the coronal portion of the socket. Biopsies of the healed mucosa and bone cores retrieved at implant placement revealed that the intrasocket reactive soft tissue demonstrated features compatible with granulation tissue and long junctional epithelium. The mucosal samples at implant placement demonstrated histopathological characteristics of keratinized mucosa with no residual elements of granulation tissue. The mean composition of the bone cores was - vital bone $40 \pm 19\%$ (13.7-74.8%); bone substitute $25.7 \pm 13\%$ (0.6-51%); connective tissue $34.3 \pm 15\%$ (13.8-71.9%). These authors concluded that intrasocket reactive soft tissue may successfully be used for primary closure of grafted fresh extraction sockets aiming to preserve the edentulous ridge. (Fig. 27)

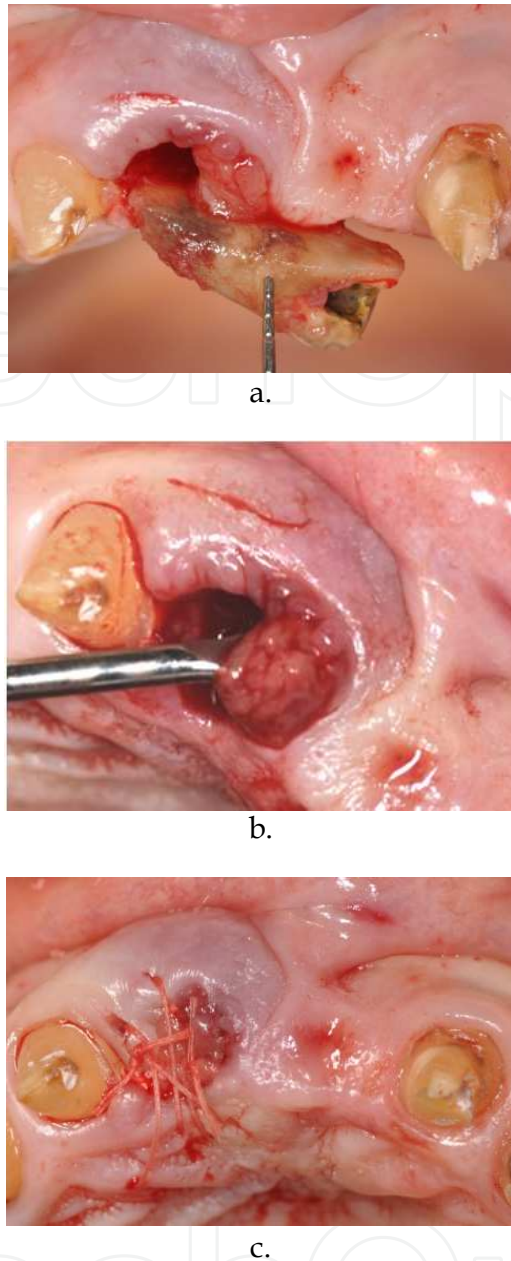


Fig. 27. Intra-socket reactive soft tissue used for primary closure during augmentation of an infected extraction site exhibiting severe bone loss as part of ridge preservation procedures. a. during tooth extraction care is taken to avoid disconnecting the reactive tissue from its blood sources. b. the intra-socket reactive soft tissue is prepared and moved aside to allow insertion of graft material. c. the reactive soft tissue sutured over the grafting material to seal the coronal portion of the socket.

A coronal and lateral sliding pedicle flaps to cover the orifice of the grafted extraction socket have been employed by Nemcovsky & Serfaty (1996). Their technique resulted in almost 100% survival rates of the connective tissue grafts (Tal et al 2004). Figures 28,29 describe the socket seal surgery using the lateral palatal pedicle flap technique employed in an immediate implant placement procedures (Fig.28) and augmentation of edentulous sites for esthetic purposes (Fig. 29).

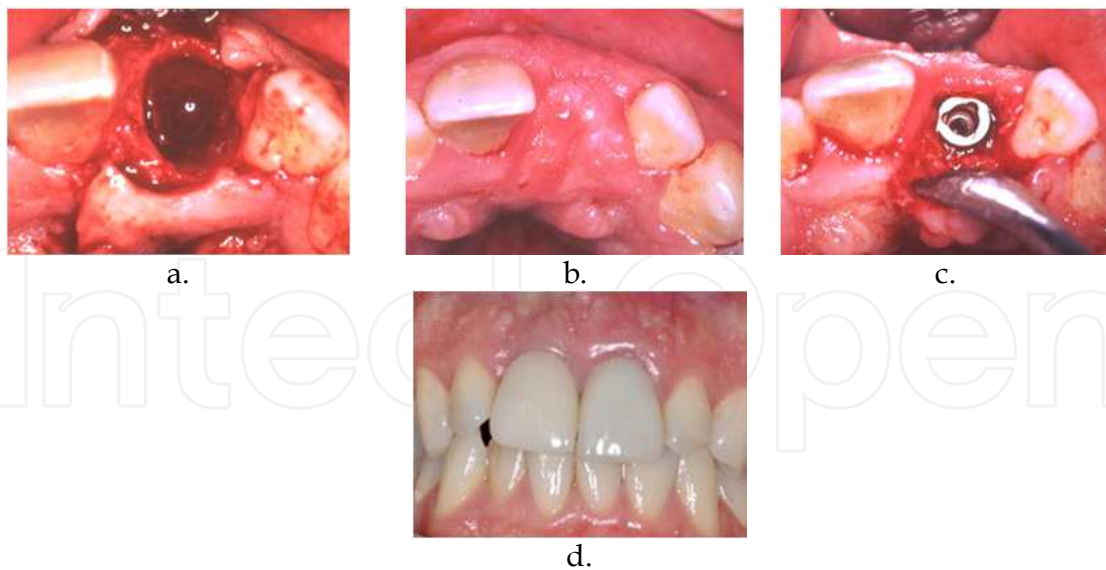


Fig. 28. Socket seal surgery using the lateral pedicle flap technique employed in an immediate implant placement procedure at the upper left central incisor. a. palatal pedicle flap is prepared for the sealing of a fresh extraction socket after placement of an endosseous implant and bone scaffold material. b. occlusal view six month following extraction c. implant exposure allows to keep the papillae and buccal soft tissue untouched d. Clinical view 8 years after restoration.

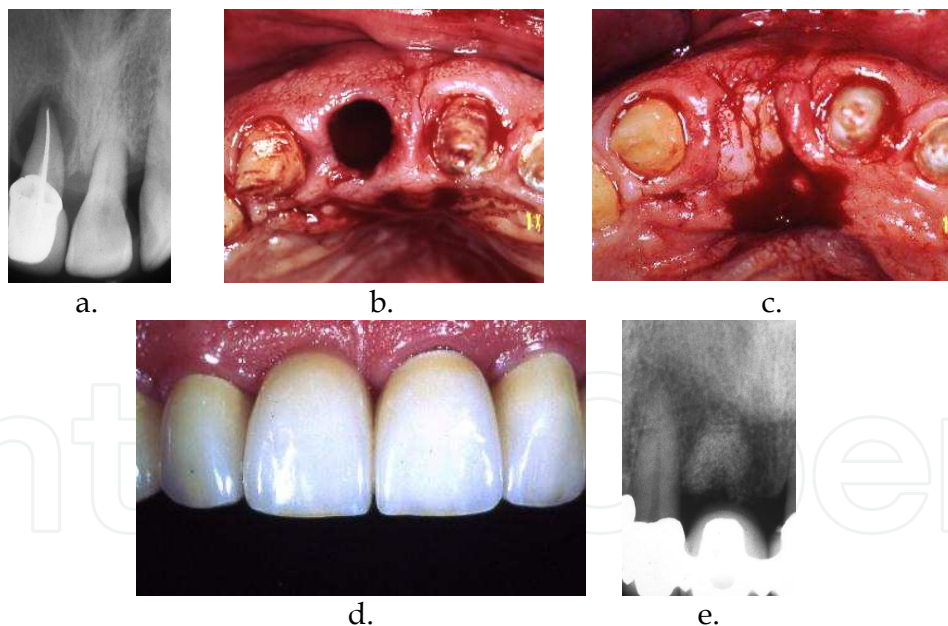


Fig. 29. Augmentation of an edentulous sites for esthetic purposes applying a modification of the palatal pedicle flap technique for covering a grafted fresh extraction socket. a. periapical lesion in an hopeless upper right central incisor. b. the fresh extraction socket is debrided and pocket epithelium removed. c. rotated palatal flap cover the orifice of the socket, after grafting with bone scaffold material. d. clinical view of a 4 unit porcelain to metal fused bridge after 6 years shows very pleasing adaptation of the pontic to the underlying soft tissue. e. radiographic view 6 years after grafting presenting a radio-opaque area at the previous extraction site.

In defects which combine a fresh extraction socket and a bony dehiscence resulted in by partial destruction of the buccal bone, a membrane may be placed within the socket against the buccal wall and the dehiscence, and the socket is filled with a membrane-supporting material which is adapted to support the membrane. If an implant is placed simultaneously, the material is placed into the space between the walls of the socket and the implant surface. In the esthetic zone, additional augmentation of the bone, beyond the labial wall of the socket is indicated; in that case, correction of the ridge contour is an additional task, added to the preservation of the volume of the socket. Such improvement can be achieved by combining the ridge preservation/augmentation procedures and the socket seal free gingival graft technique with a facially placed sub-epithelial connective tissue graft; this modification aims at improving the vertical and labial contours of the extraction site (Grunder 2011). Figure 30 presents a modified socket seal and subepithelial CT graft procedure, when both are indicated.

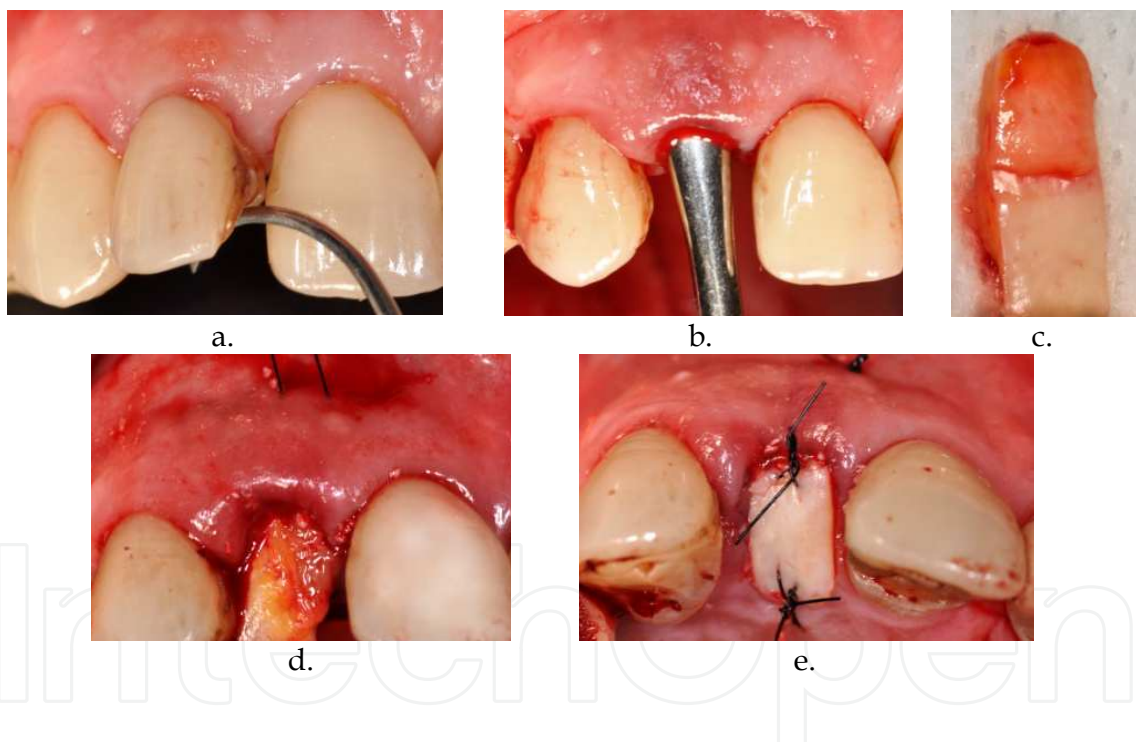


Fig. 30. Clinical view of a combined socket seal – subepithelial graft procedure. a. The upper right lateral incisor has to be removed following a traumatic injury. b. the mucosa buccal to the extraction socket is separated from the buccal plate of the bone, creating a pouch. c. a connective tissue graft is obtained from the palate; epithelium is removed from the portion which is designed to be placed into the pouch. d. the connective tissue graft is inserted into the pouch, directed to place and stabilized by the mattress suture which is connected to it and penetrates the buccal gingiva. e. once in place, the margins of the epithelialized portion of the graft are adapted to the orifice of the socket and stabilized by a few additional peripheral simple interrupted sutures.

5. Vertical bone augmentation procedures using extra-oral bone blocks

The augmentation of horizontal or vertical bone loss of the alveolar procedures are beyond the scope of this chapter. Briefly, it is believed that for the augmentation of this type of bone defects intraoral or Extraoral autogenous block transplants are preferred (Becker *et al.* 1994a; Buser *et al.* 1996; von Arx *et al.* (2005). The advantages of autogenic block grafts are mainly its handling properties, stabilization of the healing site and optimal biologic properties. The disadvantages include donor site morbidity, technical difficulties of the harvesting procedures, and the impossibility of using the graft as a carrier for growth factors. Harvesting procedures from intraoral sites have generally been preferred over extraoral sources since it may be performed under intraoral local anesthesia, it results in less morbidity, and it may provide sufficient amount of bone for the treatment of localized bone defects (Joshi & Kostakis 2004). Common intraoral donor sites are the chin and the retromolar region in the mandible. The limitations and disadvantages of intraoral bone harvesting were described by Nkenke *et al.* (2001) and von Arx *et al.* (2005). Figures 31 and 32 describe vertical bone augmentation procedures using bone blocks harvested from the iliac crest and from the skull respectively.

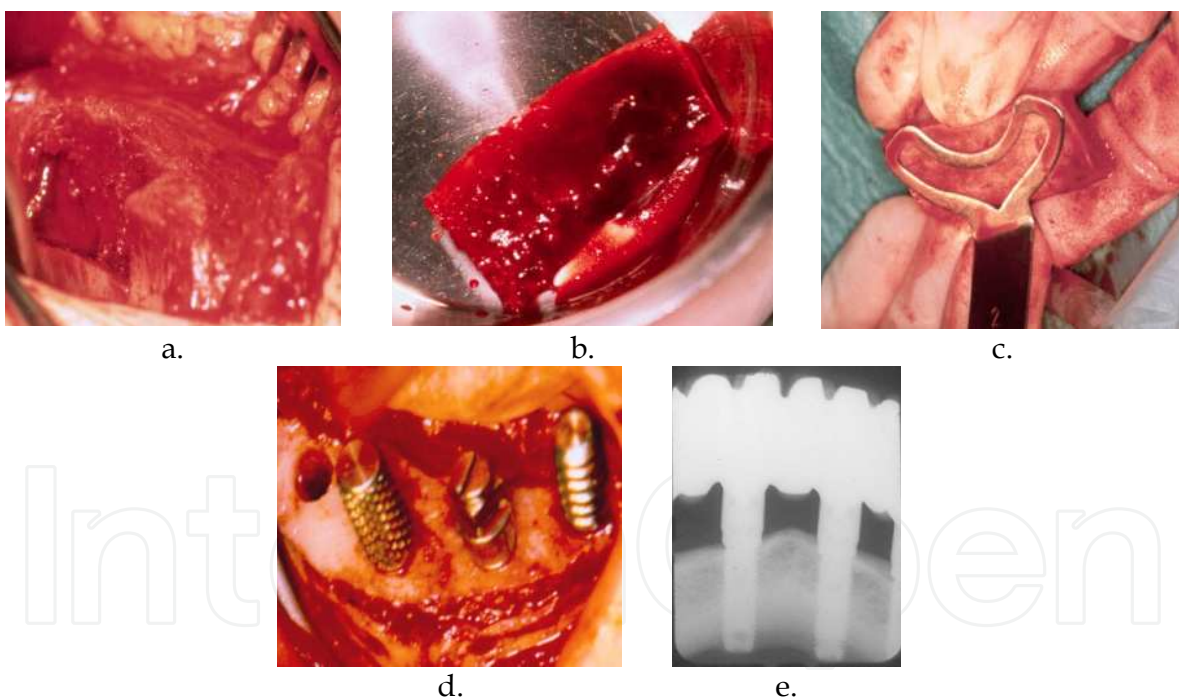


Fig. 31. Vertical bone augmentation using a bone block from the iliac crest. a. A block of bone measuring 4x1.5x2cm is removed from the iliac crest. b. clinical view of the harvested bone block c. the block is being molded using a prefabricated or custom made shablone. d. the trimmed block is placed keeping intimate contact with the exposed jaw and stabilized with 4 endosseous implants (operator P.I. Brenemark) e. radiographic view 19 years after rehabilitation. (Reprinted from Moses & Tal 2007).

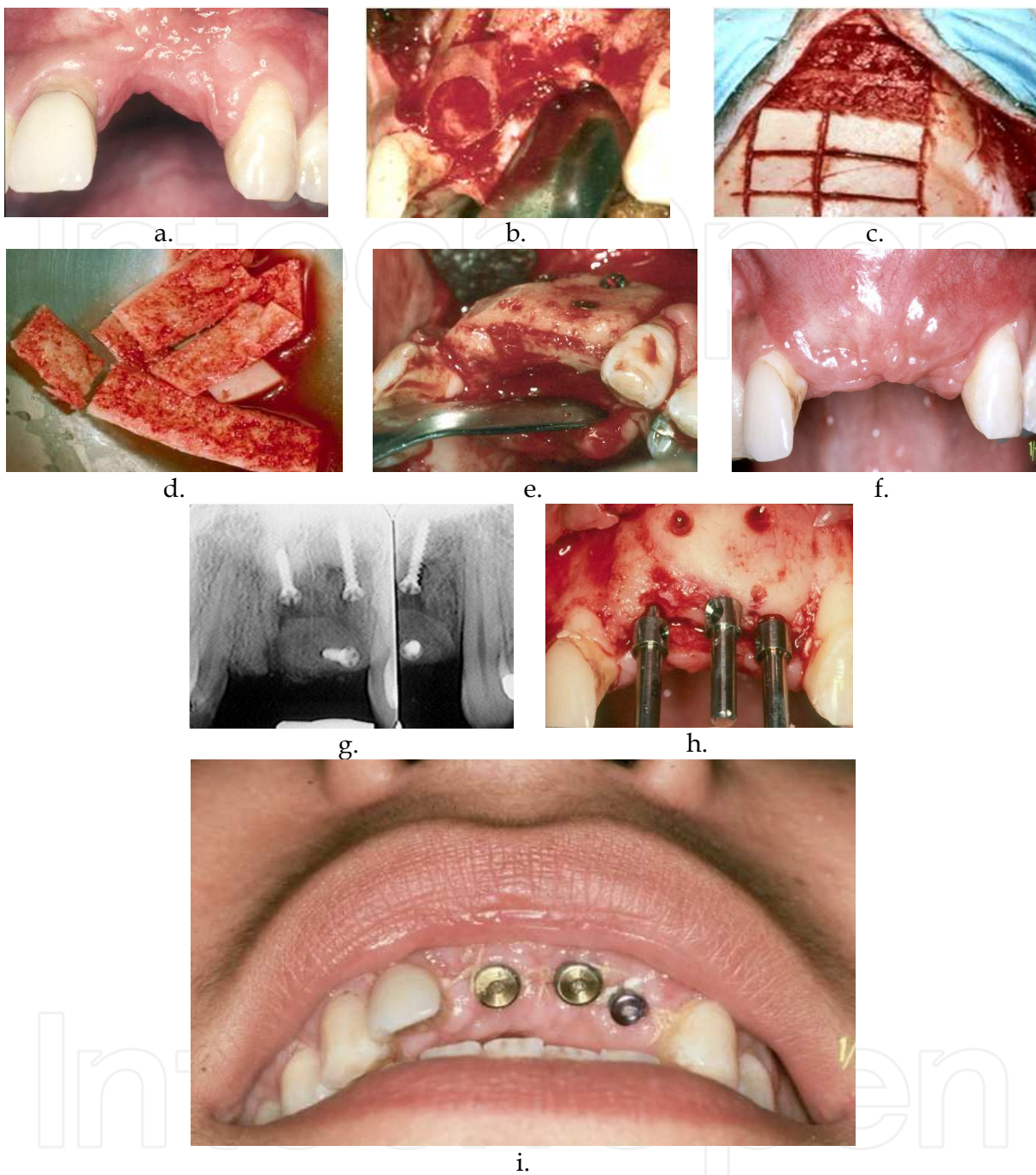


Fig. 32. Vertical bone augmentation using bone blocks from the skull. a. severe defect in the alveolar process following implant failure. b. surgical exposure of the alveolar process reveals severe bone loss requiring vertical and horizontal bone augmentation before implant placement can be considered. c. and d. bone blocks and particulated bone are removed from the skull e. bone blocks are trimmed and stabilized to the edentulous bony ridge with titanium mini screws; gaps between the blocks and jaw are filled with particulate bone. f. clinical view 6 month after the procedure g. radiographic examination 6 months after grafting. h. implant placement procedure 8 months after grafting. h. clinical view of healing 10 days after implant placement.

6. Growth and differentiation factors for alveolar ridge augmentation

Scaffold osteoconductive materials lack osseoinductive components. Therefore, an attempt to enhance bovine bone properties was conducted by adding the synthetic peptide component P-15 (Qian and Bhatnagar 1996, Bhatnagar et al 1999). P-15, a synthetic peptide analog of collagen is a replica of the organic 15 amino-acid sequences within the sequential residues involved in bone formation in type I collagen (Bhatnagar et al 1997). A combination of this cell-binding peptide (P-15) attached to the mineral particles has been developed. It is assumed that the addition of such an organic replica component to an osteoconductive material, such as bovine bone, may enhance cell attachment by cell binding and differentiation, eventually resulting in accelerated periodontal ligament fibroblasts attachment (Lallier et al 2001) and enhanced osseous formation (Bhatnagar et al 1999). Initially produced as a particulate material, PepGen/P-15 was later replaced by flow and putty forms (Nguyen et al 2003). PepGen/P-15® (Dentsply Friadent Ceramed, Lakewood, CO, USA) has been used in several bone augmentation procedures, such as socket site preservation, (Hahn et al 2003, Tehemar et al 2003) ridge deficiency (Barboza et al 2002), maxillary sinus grafting, (Krauser et al 2000, Degidi et al 2004, Gelbart et al 2005, Philippart et al 2005) and periodontal defects (Yukna et al 1998, 2000, 2002, Walters et al 2003). However, to a large extent, the above data rely on *in vitro* observations (Qian and Bhatnagar 1996, Bhatnagar et al 1999, Bhatnagar et al 1997, Lallier et al 2001, Acil et al 2002, Kubler et al 2004, Trasatti et al 2004, Hole et al 2005, Turhani et al 2005).

When PepGen/P-15 was examined in surgical fenestrated membrane-protected periodontal defects in dogs (Artzi et al 2006), it proved to be biocompatible and osteoconductive material (Fig. 33). While newly-formed bone achieved similar outcome ($36.1\% \pm 3.6$ and $31.4\% \pm 1.9$, at grafted and non-grafted sites), the non-grafted membrane-protected sites showed greater amount of new cementum ($73.9\% \pm 2.0$ vs. $59.5\% \pm 3.2$; $p < 0.02$). It appears that PepGen/P-15 application in membrane-protected defects did not enhance regeneration. Similar findings were obtained in critical size defects (CSD) in the rat skull (Artzi et al 2008). In that study, Pepgen/P15 was applied with and without a GTR membrane while non-grafted membrane-protected and non-protected served as positive and negative controls. At 12 weeks, histomorphometric measurements showed CSD osseous build-up at mean of $60.6\% \pm 4.5$ at the membrane-protected non-grafted sites which was greater ($p < 0.05$) than at the grafted protected ($50.6\% \pm 4.4$) and grafted non-protected ($44.2\% \pm 5.5$) sites. While anorganic bovine mineral/cell-binding peptide contributes in volume, apparently, membrane application is the determinant factor to establish the gain in bone regeneration (Fig. 34).

In search for more effective techniques that predictably promote the bone natural regenerative ability current research is focused on the application of natural proteins and polypeptide that regulate tissue regeneration. Growth and differentiation factors are currently believed to contribute to alveolar ridge augmentation include platelet-derived growth factor (PDGF), insulin-like growth factor (IGF-I and IGF-II), transforming growth factor beta (TGF-β), fibroblast growth factor (a-FGF and b-FGF), and bone morphogenetic proteins (BMPs 1–15). Among these, bone morphogenetic protein (BMP) is the most widely considered in the dental literature. From a biologic point of view, the growth and

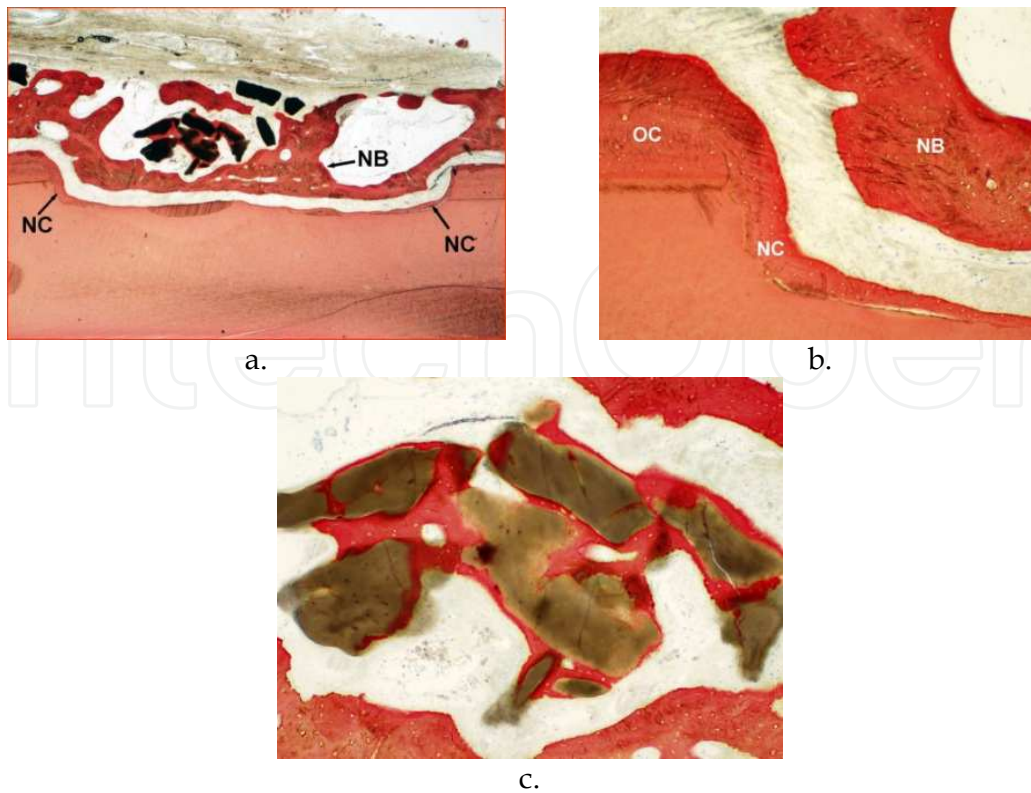


Fig. 33. Photomicrograph of an experimental fenestrated-type defect along the canine root surface grafted with PepGen/p-15 in the dog. a. Segments of new cementum (NC) are evident along the fenestrated and planed root surface. Residual PepGen/P-15 particles (black) are defined from the root surface by new bone (NB) formation. b. High-power magnification of panel a. New cellular cementum (NC) runs continuously out of the old cementum (OC) and lines the defected root surface floor concurrent with NB formation in the vicinity. However, the connective tissue arrangement in between is not yet defined. c. The grafted PepGen/P-15 particles are almost completely surrounded by NB. (Stevenel's blue and Van Gieson's picro fuchsin; original magnification: a - X20; b and c - X100.)

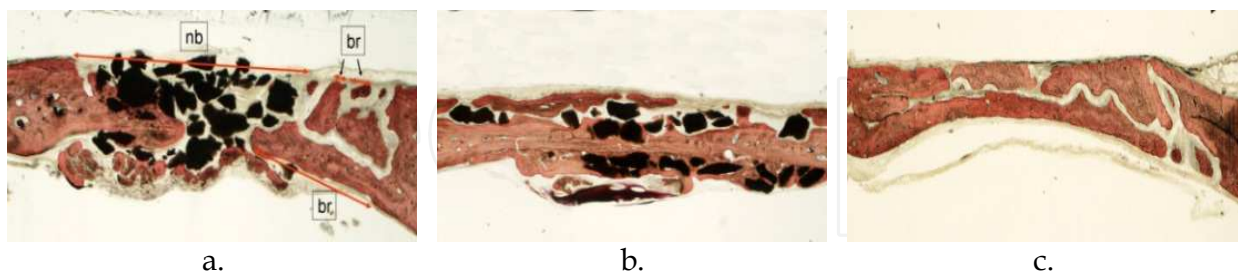


Fig. 34. Photomicrograph of an experimental critical sized defect grafted with PepGen/p-15 in the rat skull. a. Partial internal and external bone bridging (br) and a remarkable no external bridging (nb) in the Pepgen/P15 uncovered CSD site (Stevenel's blue and Van Gieson's picro fuchsin x25 original magnification). b. Non-decalcified section of the Pepgen/P15 membrane-protected CSD site. Newly formed bone surrounds Pepgen/P15 particles. (Stevenel's blue and Van Gieson's picro fuchsin x25 original magnification). c. Complete bone bridging evident at the non-grafted membrane-protected sites (Stevenel's blue and Van Gieson's picro fuchsin x25 original magnification).

differentiation factors may induce earlier bone growth into the area to be regenerated. Figure 35 presents an experimental regenerative procedure in the dog mandible using a BMP based "biologic glue". For more information on tissue engineering of bone the reader is referred to chapters 1-5.

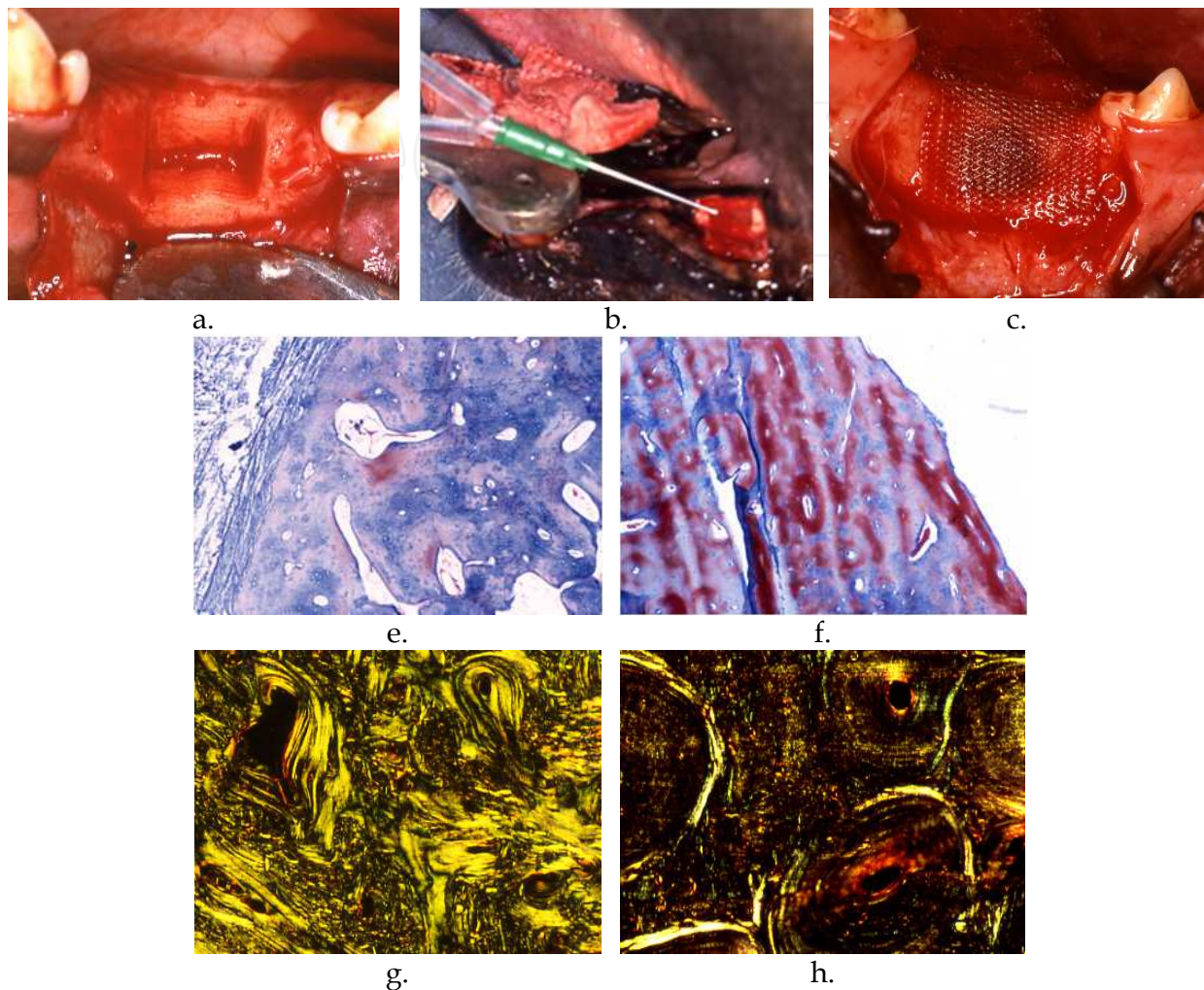


Fig. 35. Experimental regenerative procedure in the dog mandible using a. BMP based "biologic glue" a. experimental defect in an edentulous ridge in the mandible of a dog. b. experimental BMP based "biologic glue" gel is injected into the bony defect c. the gel filled defect is covered with an absorbable polyglactin membrane d., e. bucco-lingual histological sections through the jaw show newly regenerated woven bone (left) filling the defect vs. mature pristine bone (right) from the lingual aspect of the jaw. f., g. histological specimens treated with picosirius red stain observed under polarized illumination show "young" collagen bundles with organizing osteons (f) vs. well established osteons and mature collagen fibers (g).

The possible relationship between susceptibility to periodontal disease and other systemic diseases and bone regeneration in the oral cavity has not been established. It has been demonstrated that implant therapy in patients who have lost their teeth due to advanced periodontitis are subject to higher rates of implant failure and complications involving the supporting tissues, compared with those who have lost their teeth due to other reasons

(Mengel *et al.* 2001; Hardt *et al.* 2002; Karoussis *et al.* 2003; Wennstrom *et al.* 2004). It is generally agreed that certain general health conditions represent a risk for successful GBR procedures. However there are no conclusive data with respect to bone augmentation procedures in patients suffering from systemic diseases which cause impaired tissue healing. Similarly, there seems to be no proof that patients who show behaviors (e.g. smoking, poor compliance) which lead to impaired tissue healing or to a higher susceptibility for disease development, (Mombelli & Cionca 2006) should be performed with these uncertainties in mind, when planning implant therapy in the presence of bone defects.

7. Conclusions

The alveolar process and alveolar ridge of bone contain the supporting attachment apparatus of teeth; therefore its primary function is provision of anchorage to the dentition. The major development in esthetic dentistry, and more so the introduction of implant dentistry, led to significant developments aimed to regenerate or restore bony defects and bone loss in the edentulous ridge. Most clinical efforts in the developments in bone augmentation procedures are related to either simplifying clinical handling or influencing of biologic processes. These include constant improvements of the tissue barriers in use, new membrane supporting materials providing space for tissue regeneration, and finally growth and differentiation factors that induce earlier and rapid bone growth into the healing site. It is believed that the new developments would allow treatment of larger bone defects, will reduce the need for autogenous block grafts and membranes, and would reduce the technique sensitivity of the different procedures.

8. Acknowledgement

Production of this chapter was supported by The Gerald A Niznick Chair of Implantology.

9. References

- Acil Y, Springer IN, Broek V, Terheyden H, Jepsen S (2002). Effects of bone morphogenetic protein-7 stimulation on osteoblasts cultured on different biomaterials. *J Cell Biochem*;86:90-98.
- Amler, M.H. (1969). The time sequence of tissue regeneration. in human extraction wounds. *Oral Surgery, Oral Medicine and Oral Pathology* 27, 309-318.
- Araújo, M.G. & Lindhe, J. (2005). Dimensional ridge alterations following tooth extraction. An experimental study in the dog. *Journal of Clinical Periodontology* 32, 212-218.
- Araujo, M.G., Sukekava, F., Wennstrom, J.L. & Lindhe, J. (2006a). Tissue modeling following implant placement in fresh extraction sockets. *Clinical Oral Implants Research* 17, 615-624.
- Araujo, M.G., Wennstrom, J.L. & Lindhe, J. (2006b). Modeling of the buccal and lingual bone walls of fresh extraction sites following implant installation. *Clinical Oral Implants Research* 17, 606-614.
- Artzi, Z. & Nemcovsky, C.E. (1998) The application of deproteinized bovine bone mineral for ridge preservation prior to implantation. Clinical and histological observations in a case report. *Journal of Periodontology* 69, 1062-1067.

- Artzi, Z., Tal, H. & Dayan, D. (2000) Porous bovine bone mineral in healing of human extraction sockets. Part 1. Histomorphometric evaluation at 9 months. *Journal of Periodontology* 71, 1015-1023.
- Artzi Z, Tal H, Dayan D. (2001a) Porous bovine bone mineral in healing of human extraction sockets. Part 2. Histochemical observations at 9 months. *J Periodontol* Vol. 72, pp.152-159
- Artzi, Z., Nemcovsky, C.E., Tal, H. & Dayan, D. (2001b) Histopathological morphometric evaluation of 2 different hydroxyapatite-bone derivatives in sinus augmentation procedures: a comparative study in humans. *Journal of Periodontology* 72, 911-920.
- Artzi, Z., Nemcovsky, C.E. & Tal, H. (2001c) Efficacy of porous bovine bone mineral in various types of osseous deficiencies. Clinical observations and literature review. *International Journal of Periodontics & Restorative Dentistry* 21, 395-405.
- Artzi, Z., Nemcovsky, C.E. & Dayan, D. (2002) Bovine-HA spongiosa blocks and immediate implant placement in sinus augmentation procedures. Histopathological and histomorphometric observations on different histological stainings in 10 consecutive patients. *Clinical Oral Implants Research* 13, 420-427
- Artzi, Z., Givol, N., Rohrer, M.D., Nemcovsky, C.E., Prasad, H.S. & Tal, H. (2003a) Qualitative and quantitative expression of bovine bone mineral in experimental bone defects. Part 1: Description of a dog model and histological observations. *Journal of Periodontology* 74, 1143-1152.
- Artzi, Z., Givol, N., Rohrer, M.D., Nemcovsky, C.E., Prasad, H.S. & Tal, H. (2003b) Qualitative and quantitative expression of bovine bone mineral in experimental bone defects. Part 2. Morphometric analysis. *Journal of Periodontology* 74, 1159-1160
- Artzi Z., Nemcovsky C.E., Dayan D., Alpern Y. (2003) Vertical ridge augmentation using xenogenic material supported by a configured titanium mesh: Clinicohistopathologic and histochemical study. *International Journal of Oral & Maxillofacial Implants* 18, 440-446
- Artzi, Z., Weinreb, M., Givol, N., Rohrer, M.D., Nemcovsky, C.E., Prasad, H.S. & Tal, H. (2004) Biomaterial resorbability and healing site morphology of inorganic bovine bone and beta tricalcium phosphate in the canine. A 24-month longitudinal histologic study and morphometric analysis. *International Journal of Oral & Maxillofacial Implants* 19:357-68.
- Artzi Z, Kozlovsky A, Nemcovsky CE, Weinreb M (2005) The amount of newly formed bone in sinus grafting procedures depends on tissue depth as well as the type and residual amount of the grafted material. *J of Clinical Periodontology* 32,193-9.
- Artzi Z, Weinreb M, Tal H, Nemcovsky CE, Rohrer MD, Prasad HS, Kozlovsky A.(2006) Experimental intrabony and periodontal defects treated with natural mineral combined with a synthetic cell-binding Peptide in the canine: morphometric evaluations *J Periodontol.* 77:1658-64.
- Artzi Z, Kozlovsky A, Nemcovsky CE, Moses O, Tal H, Rohrer MD, Prasad HS, Weinreb M.(2008) Histomorphometric evaluation of natural mineral combined with a synthetic cell-binding peptide (P-15) in critical-size defects in the rat calvaria *Int J Oral Maxillofac Implants.* 23:1063-70

- Artzi Z, Weinreb M, Lev Dor R, Carmeli G, Dard M, Nemcovsky CE (2008) Histomorphometric assessment of bone formation in sinus augmentation utilizing a combination of autogenous and hydroxyapatite/biphasic tricalcium phosphate graft materials: at 6 and 9 months in humans. *Clinical Oral Implant Research* 2008 Jul;19(7):686-92
- Artzi Z, Nemcovsky CE, Weinreb M, Tal H, Rohrer MD, Prasad HS, Kozlovsky A (2010) Simultaneous vs. 2-stage implant placement and bone augmentation in the canine. Histomorphometry at 8 and 16 months *Journal of Clinical Periodontology* 37:1029-38
- Artzi Z, Nemcovsky CE, Tal H, Kozlovsky A (2012) Timing of implant placement and augmentation with bone replacement material: Clinical assessment at 8 and 16 months *Clinical Implant Dentistry and Related Research*
- Barboza EP, de Souza RO, Caula AL, Neto LG, Caula F de O, Duarte ME. (2002) Bone regeneration of localized chronic alveolar defects utilizing cell binding peptide associated with anorganic bovine-derived bone mineral: A clinical and histological study. *J Periodonto* 1159-73:1153;
- Barzilay, I. (1993). Immediate implants: their current status. *International Journal of Prosthodontics* 6, 169-175.
- Becker, W., Becker, B.E. & Caffesse, R. (1994a). A comparison of demineralized freeze-dried bone and autologous bone to induce bone formation in human extraction sockets. *Journal of Periodontology* 65, 1128-1133.
- Becker W, Sennerby L, Bedrossian E, Becker BE, Lucchini JP Implant stability measurements for implants placed at the time of extraction: a cohort, prospective clinical trial. *J Periodontol* 2005; 76:391-7.
- Berglundh, T. & Lindhe, J. (1997) Healing around implants placed in bone defects treated with Bio Oss. *Clinical Oral Implants Research* 8, 117-124.
- Bhatnagar RS, Qian JJ, Wedrychowska A, Sadeghi M, Wu YM, Smith N. (1999) Design of biomimetic habitats for tissue engineering with P-15, a synthetic peptide analogue of collagen. *Tissue Eng*;5:53-65.
- Bhatnagar RS, Qian JJ, Gough CA (1997). The role in cell binding of a beta-bend within the triple helical region in collagen alpha 1 (I) chain: Structural and biological evidence for conformational tautomerism on fiber surface. *J Biomol Struct Dyn*;14:547-560.
- Blouin, S., Moreau, M.F., Weiss, P., Daculsi, G., Basle, M.F. & Chappard, D. (2006) Evaluation of an injectable bone substitute (β -TCP/hydroxyapatite/hydroxypropyl-methyl-cellulose) in severely osteopenic and aged rats. *Journal of Biomedical Materials Research A* 78: 570-580.
- Boix, D., Gauthier, O., Guicheux, J., Pilet, P., Weiss, P., Grimandi, G. & Daculsi, G. (2004) Alveolar bone regeneration for immediate implant placement using an injectable bone substitute: an experimental study in dogs. *Journal of Periodontology* 75: 663-671.
- Boix, D., Weiss, P., Gauthier, O., Guicheux, J., Bouler, J.M., Pilet, P., Daculsi, G. & Grimandi, G. (2006) Injectable bone substitute to preserve alveolar ridge resorption after tooth extraction: A study in dog. *Journal of Material Science and Material Medicine* 17: 1145-1152.

- Bolouri, A., Haghghat, N. & Frederiksen, N. (2001). Evaluation of the effect of immediate grafting of mandibular postextraction sockets with synthetic bone. *compendium of Continuing Education Dentistry* 22, 955-958.
- Botticelli, D., Berglundh, T. & Lindhe, J. (2004). Hard-tissue alterations following immediate implant placement in extraction sites. *Journal of Clinical Periodontology* 31, 820-828.
- Boyne, P.J. (1997) Bone grafts: Materials. In: Osseous reconstruction of the maxilla and the mandible, ed. Evensen, L., pp. 13-21. Carol Stream, IL: Quintessence Publishing Co.
- Breitbart, A.S., Staffenberg, D.A., Thorne, C.H., Glat, P.M., Cunningham, N.S., Reddi, A.H., Ricci, J. & Steiner, G. (1995) Tricalcium phosphate and osteogenin: a bioactive onlay bone graft substitute. *Plastic and Reconstructive Surgery* 96, 699-708.
- Brook, I.M., Craig, G.T. & Lamb, D.J. (1991) In vitro interaction between primary bone organ cultures, glass-ionomer cements and hydroxyapatite/tricalcium phosphate ceramics. *Biomaterials* 12: 179-186.
- Buser, D., Dula, K., Hirt, H.P. & Schenk, R.K. (1996). Lateral ridge augmentation using autografts and barrier membranes. A clinical study in 40 partially edentulous patients. *International Journal of Oral & Maxillofacial Surgery* 54, 420-432.
- Buser, D., Hoffmann, B., Bernard, J.P., Lussi, A., Mettler, D. & Schenk, R.K. (1998) Evaluation of filling materials in membrane-protected bone defects. A comparative histomorphometric study in the mandible of miniature pigs. *Clinical Oral Implants Research* 9, 137-150.
- Buser, D., Halbritter, S., Hart, C., Bornstein, M.M., Grütter, L., Chappuis, V. & Belser, U.C. (2009) Early implant placement with simultaneous guided bone regeneration following single-tooth extraction in the esthetic zone: 12-month results of a prospective study with 20 consecutive patients. *Journal of Periodontology* 80, 152-162.
- Buch, F., Albrektsson, T. & Herbst, E. (1986). The bone growth chamber for quantification of electrically induced osteogenesis. *Journal of Orthopedic Research* 4, 194-203.
- Camargo, P., Lekovic, V., Weinlaender, M., Klokkevold, P., Kenney, E., Dimitrijevic, B., Nedic, M. & Jancovic, S.M.O. (2000). Influence of bioactive glass on changes in alveolar process dimensions after exodontia. *Oral Surgery Oral Medicine Oral Pathology Oral Radiology and Endodontics* 90, 581-586.
- Cardaropoli, G., Araújo, M. & Lindhe, J. (2003). Dynamics of bone tissue formation in tooth extraction sites. An experimental study in dogs. *Journal of Clinical Periodontology* 30, 809-818.
- Chen, S.T., Wilson, T.G., Jr. & Hammerle, C.H. (2004). Immediate or early placement of implants following tooth extraction: review of biologic basis, clinical procedures, and outcomes. *International Journal of Oral and Maxillofacial Implants* 19 (Suppl), 12-25.
- Chiapasco, M., Romeo, E., Casentini, P. & Rimondini, L. (2004). Alveolar distraction osteogenesis vs. vertical guided bone regeneration for the correction of vertically deficient edentulous ridges: a 1-3-year prospective study on humans. *Clinical Oral Implants Research* 15, 82-95.
- Chiapasco, M., Zaniboni, M. & Boisco, M. (2006). Augmentation procedures for the rehabilitation of deficient edentulous ridges with oral implants. *Clinical Oral Implants Research* 17 (Suppl 2), 136-159.

- Covani, U., Crespi, R., Cornelini, R. & Barone, A. (2004). Immediate implants supporting single crown restoration: a 4-year prospective study. *Journal of Periodontology* 75, 982-988.
- Dahlin, C., Linde, A., Gottlow, J. & Nyman, S. (1988). Healing of bone defects by guided tissue regeneration. *Plastic and Reconstructive Surgery* 81, 672-677.
- Dahlin, C., Alberius, P. & Linde, A. (1991a). Osteopromotion for cranioplasty. An experimental study in rats using a membrane technique. *Journal of Neurosurgery* 74 (3), 487-491.
- Dahlin, C., Andersson, L. & Linde, A. (1991b). Bone augmentation at fenestrated implants by an osteopromotive membrane technique. A controlled clinical study. *Clinical Oral Implants Research* 2, 159-165.
- Degidi M, Piattelli M, Scarano A, Iezzi G, Piattelli A (2004.) Maxillary sinus augmentation with a synthetic cellbinding peptide: Histological and histomorphometrical results in humans. *J Oral Implantol*;30:376-383.
- Denissen, H.W., Kalk, W., Veldhuis, H.A. & van Waas, M.A. (1993). Anatomic consideration for preventive implantation. *International Journal of Oral and Maxillofacial Implants* 8(2), 191-196.
- Dies, F., Etienne, D., Bou Abboud, N. & Ouhayoun, J.P. (1996) Bone regeneration in extraction sites after immediate placement of an e-PTFE membrane with or without a biomaterial. Report on 12 consecutive cases. *Clinical Oral Implants Research* 7, 277-285.
- Donos, N., Mardas, N. & Chadha, V. (2008) Clinical outcomes of implants following lateral bone augmentation: systematic assessment of available options (barrier membranes, bone grafts, split osteotomy). *Journal of Clinical Periodontology* 35 (suppl.), 173-202.
- Emery, S.E., Fuller, D.A. & Stevenson, S. (1996) Ceramic anterior spinal fusion. Biologic and biomechanical comparison in a canine model. *Spine* 21: 2713-2719 .
- Evian, C.I., Rosenberg, E.S., Cosslet, J.G. & Corn, H. (1982). The osteogenic activity of bone removed from healing extraction sockets in human. *Journal of Periodontology* 53, 81-85.
- Evian, C. & Cutler, S. (1994). Autogenous gingival grafts as epithelial barriers for immediate implants: case reports. *Journal of Periodontology* 65, 201-210.
- Fellah, B.H., Weiss, P., Gauthier, O., Rouillon, T., Pilet, P., Daculsi, G. & Layrolle, P. (2006) Bone repair using a new injectable self-crosslinkable bone substitute. *Journal of Orthopaedic Research* 24: 628-635.
- Fiorellini, J.P. & Nevins, M.L. (2003). Localized ridge augmentation/preservation. A systematic review. *Annals of Periodontology* 8, 321-327.
- Fowler, E., Breault, L. & Rebitski, G. (2000). Ridge preservation utilizing an acellular dermal allograft and demineralized freeze-dried bone allograft: Part II. Immediate endosseous implant placement. *Journal of Periodontology* 71, 1360-1364.
- Froum, S., Wallace, S., Tarnow, D. & Cho, S. (2002). Effect of platelet-rich plasma on bone growth and osseointegration in human maxillary sinus grafts: three bilateral case reports. *International Journal of Periodontics and Restorative Dentistry* 22, 45-53.
- Gao, T.J., Lindholm, T.S., Kommonen, B., Ragni, P., Paronzini, A. & Lindholm, T.C. (1997) Stabilization of an inserted tricalcium phosphate spacer enhances the healing of a

- segmental tibial defect in sheep. *Archives of Orthopaedic and Trauma Surgery* 116, 290-294.
- Gauthier, O., Goyenvalle, E., Bouler, J.M., Guicheux, J., Pilet, P., Weiss, P. & Daculsi, D. (2001) Macroporous biphasic calcium phosphate ceramics versus injectable bone substitute: a comparative study 3 and 8 weeks after implantation in rabbit bone. *Journal of Material Science and Material Medicine* 12: 385-390.
- Gelbart M, Friedman R, Burlui V, Rohrer M, Atkinson B. (2005) Maxillary sinus augmentation using a peptidemodified graft material in three mixtures: A prospective human case series of histologic and histomorphometric results. *Implant Dent* 2005;14:185-193
- Gottlow J. (1993) Guided tissue regeneration using bioresorbable and non-resorbable devices: initial healing and long-term results. *J Periodontol.* 64 (Suppl):1157-65. Review.
- Grunder U. (2011) Crestal ridge width changes when placing implants at the time of tooth extraction with and without soft tissue augmentation after a healing period of 6 months: report of 24 consecutive cases. *Int J Periodontics Restorative Dent.* 2011; 31(1):9-17.
- Hahn J, Rohrer MD, Tofe AJ.(2003) Clinical, radiographic, histologic, and histomorphometric comparison of PepGen P-15 particulate and PepGen P-15 flow in extraction sockets: A same-mouth case study. *Implant Dent* ;12:170-174.
- Hallman, M., Lundgren, S. & Sennerby, L. (2001b) Histologic analysis of clinical biopsies taken 6 months and 3 years after maxillary sinus floor augmentation with 80% bovine hydroxyapatite and 20% autogenous bone mixed with fibrin glue. *Clinical Implant Dentistry & Related Research* 3, 87-96.
- Hallman, M., Hedin, M., Sennerby, L. & Lundgren, S. (2002a) A prospective 1-year clinical and radiographic study of implants placed after maxillary sinus floor augmentation with bovine hydroxyapatite and autogenous bone. *Journal of Oral and Maxillofacial Surgery* 60, 277-284.
- Hämmerle, C.H.F., Schmid, J., Olah, A.J. & Lang, N.P. (1996). A novel model system for the study of experimental bone formation in humans. *Clinical Oral Implants Research* 7, 38-47.
- Hämmerle, C.H.F., Olah, A.J., Schmid, J., Fluckiger, L., Gogolewski, S., Winkler, J.R. & Lang, N.P. (1997) The biological effect of deproteinized bovine bone on bone neoformation on the rabbit skull. *Clinical Oral Implants Research* 8, 198-207.
- Hämmerle, C.H.F. (1999). Membranes and bone substitutes in guided bone regeneration. Paper presented at the 3rd European Workshop on Periodontology, Ittingen, Switzerland
- Hämmerle, C.H., Jung, R.E. & Feloutzis, A. (2002). A systematic review of the survival of implants in bone sites augmented with barrier membranes (guided bone regeneration) in partially edentulous patients. *Journal of Clinical Periodontology* 29 (Suppl 3), 226-231; discussion 232-223.
- Hämmerle, C.H., Chen, S.T. & Wilson, T.G., Jr. (2004). Consensus statements and recommended clinical procedures regarding the placement of implants in extraction sockets. *International Journal of Oral and Maxillofacial Implants* 19 Suppl, 26-28.

- Hämmerle CH, van Steenberghe D. In: The first EAO Consensus Conference 16-19 February 2006, Pfäffikon, Switzerland. *Clinical Oral Implants Research*. 2006 Oct;17 Suppl 2:1.
- Hämmerle, C.H.F., Araújo M & Lindhe J .Timing of Implant Placement, In: *Clinical periodontology and implant dentistry*: Ed: Jan Lindhe, Niklaus P. Lang & Thorkild Karring. –Fifth edition 2008(pp. 1053-76). : Blackwell Publishing Ltd
- Hardt, C.R., Grondahl, K., Lekholm, U. & Wennstrom, J.L. (2002). Outcome of implant therapy in relation to experienced loss of periodontal bone support: a retrospective 5- year study. *Clinical Oral Implants Research* 13, 488–494.
- Hardwick, R., Scantlebury, T.V., Sanchez, R., Whitley, N. & Ilizarov, G.A. (1989a). The tension-stress effect on the genesis and growth of tissues: Part I. The influence of stability of fixation and soft tissue preservation. *Clinical Orthopaedics* 238, 249–281.
- Hashimoto-Uoshima, M., Ishikawa, I., Kinoshita, A., Weng, H.T. & Oda, S. (1995) Clinical and histologic observation of replacement of biphasic calcium phosphate by bone tissue in monkeys. *International Journal of Periodontics and Restorative Dentistry* 15: 205-213.
- Hole BB, Schwarz JA, Gilbert JL, Atkinson BL. (2005) A study of biologically active peptide sequences (P-15) on the surface of an ABM scaffold (PepGen P-15) using AFM and FTIR. *J Biomed Mater Res A*; 74:712-721.
- Hossain MZ, Kyomen S, Tanne K (1996). Biologic responses of autogenous bone and beta-tricalcium phosphate ceramics transplanted into bone defects to orthodontic forces. *Cleft Palate-Craniofac J*;33:277-283.
- Hürzeler, M.B., Quiñones, C.R., Kirsch, A., Gloker, C., Schupbach, P., Strub, J.R. & Caffesse, R.G. (1997) Maxillary sinus augmentation using different grafting materials and dental implants in monkeys. Part I. Evaluation of anorganic bovine-derived bone matrix. *Clinical Oral Implants Research* 8, 476-486.
- Ilizarov GA. (1989a). The tension-stress effect on the genesis and growth of tissues. Part I. The influence of stability of fixation and soft-tissue preservation. *Clinical Orthopaedics Related Research*. 238:249-81.
- Ilizarov, G.A. (1989b). The tension-stress effect on the genesis and growth of tissues: Part II. The influence of the rate and frequency of distraction. *Clinical Orthopaedics Related Research*. 239, 263–285.
- Jensen, S.S., Aaboe, M., Pinholt, E.M., Hjørting-Hansen, E., Melsen, F. & Ruyter, I.E. (1996) Tissue reaction and material characteristics of four bone substitutes. *International Journal of Oral & Maxillofacial Implants* 11, 55-66.
- Joshi, A. & Kostakis, G. (2004). An investigation of postoperative morbidity following iliac crest graft harvesting. *British Dental Journal* 196, 167–171.
- Karoussis, I.K., Salvi, G.E., Heitz-Mayfield, L.J., Bragger, U. Hammerle, C.H. & Lang, N.P. (2003). Long-term implant prognosis in patients with and without a history of chronic periodontitis: a 10-year prospective cohort study of the ITI Dental Implant System. *Clinical Oral Implants Research* 14, 329–339.
- Karring, T., Nyman, S. & Lindhe, J. (1980). Healing following implantation of periodontitis affected roots into bone tissue. *Journal of Clinical Periodontology* 7, 96–105.
- Kostopoulos, L. & Karring, T. (1994). Augmentation of the rat mandible using guided tissue regeneration. *Clinical Oral Implants Research* 5, 75–82.

- Krauser JT, Rohrer MD, Wallace SS (2000). Human histologic and histomorphometric analysis comparing OsteoGrafN with PepGen P-15 in the maxillary sinus elevation procedure: A case report. *Implant Dent*;9: 302-298
- Kubler A, Neugebauer J, Oh JH, Scheer M, Zoller JE.)2004(Growth and proliferation of human osteoblasts on different bone graft substitutes: An in vitro study. *Implant Dent*;13:171-179.
- Lallier TE, Yukna R, St Marie S, Moses R (2001). The putative collagen binding peptide hastens periodontal ligament cell attachment to bone replacement graft materials. *J Periodontol*;72:990-997.
- Landsberg, C. & Bichacho, N. (1994). A modified surgical/prosthetic approach for optimal single implant supported crown. Part I - The socket seal surgery. *Practical Periodontics and Aesthetic Dentistry* 6, 11-17
- Landsberg, C. (1997). Socket seal surgery combined with immediate implant placement: a novel approach for single-tooth replacement. *International Journal of Periodontics and Restorative Dentistry* 17, 140-149.
- Le Nihouannen, D., Daculsi, G., Saffarzadeh, A., Gauthier, O., Delplace, S., Pilet, P. & Layrolle, P. (2005) Ectopic bone formation by microporous calcium phosphate ceramic particles in sheep muscles. *Bone* 36: 1086-1093.
- Lekholm, U. & Zarb, G.A. (1985). Patient selection. In: Brånemark, P-I., Zarb, G.A. & Albrektsson, T., eds. *Tissue Integrated Prostheses. Osseointegration in Clinical Dentistry*. Chicago: Quintessence, pp. 199-209.
- Lekholm, U., Adell, R. & Lindhe, J. (1986). Marginal tissue reactions at osseointegrated titanium fixtures. (II) A crosssectional retrospective study. *International Journal of Oral & Maxillofacial Surgery* 15, 53-61.
- Lekovic, V., Kenney, E.B., Weinlaender, M., Han, T., Klokkevold, P.R., Nedic, M. & Orsini, M. (1997). A bone regenerative approach to alveolar ridge maintenance following tooth extraction. Report of 10 cases. *Journal of Periodontology* 68,563-570.
- Lekovic, V., Camargo, P.M., Klokkevold, P.R., Weinlaender, M., Kenney, E.B., Dimitrijevic, B. & Nedic, M. (1998). Preservation of alveolar bone in extraction sockets using bioabsorbable membranes. *Journal of Periodontology* 69, 1044-1049.
- Lioubavina-Hack N, Lang NP, Karring T Significance of primary stability for osseointegration of dental implants. *Clin Oral Implants Res* 2006; 17:244-250.
- Lorenzoni, M., Pertl, C., Keil, K. & Wegscheider, W.A. (1998). Treatment of peri-implant defects with guided bone regeneration: a comparative clinical study with various membranes and bone grafts. *International Journal of Oral & Maxillofacial Implants* 13, 639-646.
- Lundgren, D., Lundgren, A.K., Sennerby, L. & Nyman, S. (1995). Augmentation of intramembranous bone beyond the skeletal envelope using an occlusive titanium barrier. An experimental study in the rabbit. *Clinical Oral Implants Research* 6, 67-72.
- Lundgren S, Rasmusson L, Sjostrom M, Sennerby L Simultaneous or delayed placement of titanium implants in free autogenous iliac bone grafts. Histological analysis of the bone graft-titanium interface in 10 consecutive patients. *Int J Oral Maxillofac Impl* 1999; 28:31-37

- Mardinger O, Vered M, Chaushu G, Nissan J. (2010) Histomorphometrical Analysis following Augmentation of Infected Extraction Sites Exhibiting Severe Bone Loss and Primarily Closed by Intra socket Reactive Soft Tissue. *Clin Implant Dent Relat Res*.
- Mengel, R., Schroder, T. & Flores-de-Jacoby, L. (2001). Osseointegrated implants in patients treated for generalized chronic periodontitis and generalized aggressive periodontitis: 3- and 5-year results of a prospective long-term study. *Journal of Periodontology* 72, 977-989.
- Merten HA, Wiltfang J, Grohmann U, Hoenig JF.(2001) Intraindividual comparative animal study of alpha- and beta-tricalcium phosphate degradation in conjunction with simultaneous insertion of dental implants. *J Craniofac Surg*;12:59-68.
- Mombelli, A. & Cionca, N. (2006). Systemic diseases affecting osseointegration therapy. *Clinical Oral Implants Research* 17 (Suppl 2), 97-103.
- Moses O, Nemcovsky CE, Langer Y, Tal H. (2007). Severely resorbed mandible treated with iliac crest autogenous bone graft and dental implants: 17-year follow-up. *Int J Oral Maxillofac implants*.;22:1017-21
- Nemcovsky, C. & Serfaty, V. (1996). Alveolar ridge preservation following extraction of maxillary anterior teeth. Report on 23 consecutive cases. *Journal of Periodontology* 67, 390-395.
- Nemcovsky, C.E. & Artzi, Z. (2002). Comparative study of buccal dehiscence defects in immediate, delayed, and late maxillary implant placement with collagen embranes: clinical healing between placement and second-stage surgery. *Journal of eriodontology* 73, 754-761.
- Nguyen H, Qian JJ, Bhatnagar RS, Li S.(2003) Enhanced cell attachment and osteoblastic activity by P-15 peptidecoated matrix in hydrogels. *Biochem Biophys Res Commun* ;311:179-186.
- Nkenke, E., Schultze-Mosgau, S., Radespiel-Tröger, M., Kloss, F. & Neukam, F.W. (2001). Morbidity of harvesting of chin grafts: a prospective study. *Clinical Oral Implants Research* 12, 495-502.
- Nyman, S., Karring, T., Lindhe, J. & Planten, S. (1980). Healing following implantation of periodontitis affected roots into gingival connective tissue. *Journal of Clinical Periodontology* 7, 394-401.
- Nyman, S., Lindhe, J. & Karring, T. (1989). Reattachment - new attachment. In: Lindhe, J., ed. *Textbook of Clinical Periodontology*, 2nd edn. Copenhagen: Munksgaard, pp. 450-473.
- Nyman, S., Lang, N.P., Buser, D. & Brägger, U. (1990). Bone regeneration adjacent to titanium dental implants using guided tissue regeneration. A report of 2 cases. *International Journal of Oral & Maxillofacial Implants* 5, 9-14.
- Nyman, S.R. & Lang, N.P. (1994). Guided tissue regeneration and dental implants. *Periodontology 2000* 4, 109-118
- Ohsawa K, Neo M, Matsuoka H, Akiyama H, Ito H, Kohno H, et al. (2000) The expression of bone matrix protein mRNAs around beta-TCP particles implanted into bone. *J Biomed Mater Res* 2000;52:460-466.
- Philippart P, Daubie V, Pochet R(2005). Sinus grafting using recombinant human tissue factor, platelet-rich plasma gel, autologous bone, and anorganic bovine bone

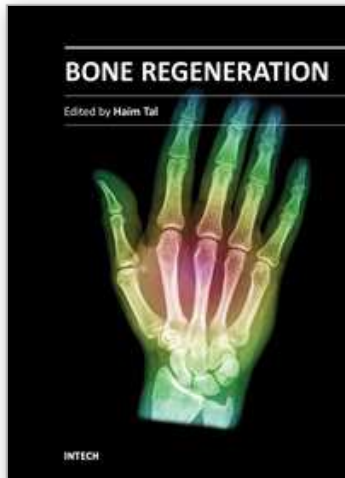
- mineral xenograft: Histologic analysis and case reports. *Int J Oral Maxillofac Implants*;20:274-281.
- Piattelli, M., Favero, G.A., Scarano, A., Orsini, G. & Piattelli, A. (1999) Bone reactions to anorganic bovine bone (Bio-Oss) used in sinus procedures: A histologic long-term report of 20 cases in humans. *International Journal of Oral & Maxillofacial Implants* 14, 835-840.
- Pietrokovski, J. & Massler, M. (1967). Alveolar ridge resorption following tooth extraction. *Journal of Prosthetic Dentistry* 17, 21-27.
- Qian JJ, Bhatnagar RS. (1996) Enhanced cell attachment to anorganic bone mineral in the presence of a synthetic peptide related to collagen. *J Biomed Mater Res*;31:545-554.
- Rasmusson L, Meredith N, Cho IH, Sennerby L The influence of simultaneous versus delayed placement on the stability of titanium implants in onlay bone grafts. A histologic and biomechanic study in the rabbit. *Int J Oral Maxillofac Surg* 1999; 28:224-231.
- Reddi, A.H. (1981). Cell biology and biochemistry of endochondral bone development. *Collagen Related Research* 1, 209-226.
- Reddi, A.H., Weintraub, S. & Muthukumaran, N. (1987). Biologic principles of bone induction. *Orthopedic Clinics of North America* 18, 207-212.
- Rosa AL, Brentegani LG, Grandini SA. (1995) Hydroxylapatite and tricalcium phosphate implants in the dental alveolus of rats. A histometric study. *Brazilian Dent J*; 6:103-109.
- Russotti, G.M., Okada, Y., Fitzgerald, R.H., Jr, Chao, E.Y. & Gorski, J.P. (1987) Efficacy of using a bone graft substitute to enhance biological fixation of a porous metal femoral component. *Hip* 15: 120-154.
- Schenk, R.K., Buser, D., Hardwick, W.R. & Dahlin, C. (1994). Healing pattern of bone regeneration in membrane protected defects: a histologic study in the canine mandible. *International Journal of Oral and Maxillofacial Implants* 9, 13-29.
- Schliephake, H. & Kracht, D. (1997). Vertical ridge augmentation using polylactic membranes in conjunction with immediate implants in periodontally compromised extraction sites: an experimental study in dogs. *International Journal of Oral & Maxillofacial Implants* 12, 325-334.
- Schmid, J., Hämmerle, C.H.F., Flückiger, L., Gogolewski, S., Winkler, J.R., Rahn, B. & Lang, N.P. (1997). Blood filled spaces with and without filler materials in guided bone regeneration. A comparative experimental study in the rabbit using bioresorbable membranes. *Clinical Oral Implants Research* 8, 75-81.
- Schopper, C., Ziya-Ghazvini, F., Goriwoda, W., Moser, D., Wanschitz, F., Spassova, E., Lagogiannis, G., Auterith, A. & Ewers, R. (2005) HA/TCP compounding of a porous CaP biomaterial improves bone formation and scaffold degradation--a long-term histological study. *Journal of Biomedical Materials Research B Applied Biomaterials* 74: 458-467.
- Schropp, L., Wenzel, A., Kostopoulos, L. & Karring, T. (2003). Bone healing and soft tissue contour changes following single-tooth extraction: a clinical and radiographic 12-month prospective study. *International Journal of Periodontics & Restorative Dentistry* 23, 313-323.

- Schwartz-Arad, D. & Chaushu, G. (1997a). The ways and wherefores of immediate placement of implants into fresh extraction sites: A literature review. *Journal of Periodontology* 68, 915-923.
- Skoglund, A., Hising, P. & Young, C. (1997) A clinical and histologic examination in humans of the osseous response to implanted natural bone mineral. *International Journal of Oral & Maxillofacial Implants* 12, 194-199.
- Seibert, J. & Nyman, S. (1990). Localized ridge augmentation in dogs: a pilot study using membranes and hydroxyapatite. *Journal of Periodontology* 3, 157-165.
- Simion, M., Baldoni, M., Rossi, P. & Zaffe, D. (1994a). A comparative study of the effectiveness of e-PTFE membranes with and without early exposure during the healing period. *International Journal of Periodontics and Restorative Dentistry* 14, 167-180.
- Simion, M., Trisi, P. & Piattelli, A. (1994b). Vertical ridge augmentation using a membrane technique associated with osseointegrated implants. *International Journal of Periodontics and Restorative Dentistry* 14, 497-511.
- Smiler, D.G., Johnson, P.W., Lozada, J.L., Misch, C., Rosenlicht, J.L., Tatum, O.H., Jr. & Wagner, J.R. (1992) Sinus lift grafts and endosseous implants: Treatment of the atrophic posterior maxilla. *Dental Clinics of North America* 36, 151-186.
- Smukler, H., Landi, L. & Setayesh, R. (1999). Histomorphometric evaluation of extraction sockets and deficient alveolar ridges treated with allograft and barrier membrane: a pilot study. *International Journal of Oral & Maxillofacial Implants* 14, 407-416.
- Spector, M. (1994) Anorganic bovine bone and ceramic analogs of bone mineral as implants to facilitate bone regeneration. *Clinics in Plastic Surgery* 21, 437-444.
- St John, K.R., Zardiackas, L.D., Black, R.J. & Armstrong, R. (1993) Response of canine bone to a synthetic bone graft material. *Clinical Materials* 12: 49-55.
- Szabo G, Suba Z, Hrabak K, Barabas J, Nemeth Z. (2001) Autogenous bone versus beta-tricalcium phosphate graft alone for bilateral sinus elevations (2-and 3-dimensional computed tomographic, histologic, and histomorphometric observations): preliminary results. *Int J Oral Maxillofac Implants*;16:681-692.
- Tal, H. (1999). Autogenous masticatory mucosal grafts in extraction socket seal procedures: a comparison between sockets grafted with demineralized freeze-dried bone and deproteinized bovine bone mineral. *Clinical Oral Implants Research* 10, 289-296.
- Tal, H, Bichacho N, Imber S, Kornowski Y, Nemcovsky CE. (2004) Rotated palatal flaps: A functional and aesthetic solution in edentulous sites. *Pract Proced Aesthet Dent*. 16(8):599-606.
- Tehemar S, Hanes P, Sharawy M.(2003) Enhancement of osseointegration of implants placed into extraction sockets of healthy and periodontally diseased teeth by using graft material, an ePTFE membrane, or a combination. *Clin Implant Dent Relat Res* 2003;5:193-211.
- Tinti, C., Parma-Benfenati, S. & Polizzi, G. (1996). Vertical ridge augmentation: what is the limit? *International Journal of Periodontics and Restorative Dentistry* 16, 220-229.
- Tinti, C. & Parma-Benfenati, S. (1998). Vertical ridge augmentation: surgical protocol and retrospective evaluation of 48 consecutively inserted implants. *International Journal of Periodontics and Restorative Dentistry* 18, 445-443.

- Trasatti C, Spears R, Gutmann JL, Opperman LA.(2004) Increased TGF- β 1 production by rat osteoblasts in the presence of PepGen P-15 in vitro. *J Endod* ;30: .217-213
- Turhani D, Weissenbock M, Watzinger E, et al.(2005) In vitro study of adherent mandibular osteoblast-like cells on carrier materials. *Int J Oral Maxillofac Surg* ;34: .550-543
- Urist, M.R. (1965). Bone: formation by autoinduction. *Science* 150, 893–899.
- von Arx, T., Cochran, D.L., Hermann, J.S., Schenk, R.K., Higginbottom, F.L. & Buser, D. (2001). Lateral ridge augmentation and implant placement: An experimental study evaluating implant osseointegration in different augmentation materials in the canine mandible. *International Journal of Oral & Maxillofacial Implants* 16, 343–354.
- Valentini, P. & Abensur, D. (1997) Maxillary sinus floor elevation for implant placement with demineralized freeze-dried bone and bovine bone (Bio-Oss): A clinical study of 20 patients. *International Journal of Periodontics & Restorative Dentistry* 17, 233-241.
- von Arx, T., Hafliger, J. & Chappuis, V. (2005). Neurosensory disturbances following bone harvesting in the symphysis: a prospective clinical study. *Clinical Oral Implants Research* 16, 432–439.
- Walters SP, Greenwell H, Hill M, Drisko C, Pickman K, Scheetz J.P.(2003) Comparison of porous and non-porous teflon membranes plus a xenograft in the treatment of vertical osseous defects: A clinical reentry study. *J Periodontol*;74:1161-1168.
- Watzek, G., Haider, R., Mensdorff-Pouilly, N. & Haas, R. (1995). Immediate and delayed implantation for complete restoration of the jaw following extraction of all residual teeth: A retrospective study comparing different types of serial immediate implantation. *International Journal of Periodontics and Restorative Dentistry* 12, 206–217.
- Wennstrom, J.L., Ekestubbe, A., Grondahl, K., Karlsson, S. & Lindhe, J. (2004). Oral rehabilitation with implant supported fixed partial dentures in Periodontitis susceptible subjects. A 5-year prospective study. *Journal of Clinical Periodontology* 31, 713–724.
- Werbitt, M.J. & Goldberg, P.V. (1992). The immediate implant: bone preservation and bone regeneration. *International Journal of Periodontics and Restorative Dentistry* 12, 206–217.
- Wetzel, A.C., Stich, A. & Caffesse, R.G. (1995) Bone apposition onto oral implants in the sinus area filled with different grafting materials. A histological study in beagle dogs. *Clinical Oral Implants Research* 6, 155-163.
- Wikesjo UM, Nilveus R Periodontal repair in dogs: Effect of wound stabilization on healing. *J Periodontol* 1990; 61: 719-724.
- Wiltfang J, Merten HA, Schlegel KA, Schultze-Mosgau S, Kloss FR, Rupprecht S, et al. Degradation characteristics of alpha and beta tri-calcium-phosphate (TCP) in minipigs. *J Biomed Mater Res* 2002;63:115-121.
- Yamada S, Heymann D, Bouler JM, Daculsi G. Osteoclastic resorption of calcium phosphate ceramics with different hydroxyapatite/beta-tricalcium phosphate ratios. *Biomater* 1997;18:1037-1041.
- Yang, J., Lee, H. & Vernino, A. (2000). Ridge preservation of dentition with severe periodontitis. *Compendium of Continuing Education Dentistry* 21, 579–583.
- Yilmaz, S., Efeoglu, E. & Kilic, A. (1998). Alveolar ridge reconstruction and/or preservation using root form bioglass cones. *Journal of Clinical Periodontology* 25, 832–839.
- Yukna RA, Callan DP, Krauser JT, et al(1998). Multi-center clinical evaluation of combination anorganic bovinederived hydroxyapatite matrix (ABM)/cell binding

- peptide (P-15) as a bone replacement graft material in human periodontal osseous defects. 6-month results. *J Periodontol* ;69:655-663.
- Yukna RA, Krauser JT, Callan DP, Evans GH, Cruz R, Martin M.(2000) Multi-center clinical comparison of combination anorganic bovine-derived hydroxyapatite matrix (ABM)/cell binding peptide (P-15) and ABM in human periodontal osseous defects. 6-month results. *J Periodontol* 2000;71:1671-1679.
- Yukna RA, Krauser JT, Callan DP, Evans GH, Cruz R Martin M (2002). Thirty-six month follow-up of 25 patients treated with combination anorganic bovine-derived hydroxyapatite matrix (ABM)/cell-binding peptide (P-15)(bone replacement grafts in human infrabony defects. I. Clinical findings. *J Periodontol*;73:123-128.
- Yukna R, Salinas TJ, Carr RF.(2002) Periodontal regeneration following use of ABM/P-15: A case report. *Int J Periodontics Restorative Dent* ;22:146-155.
- Zitzmann, N.U., Naef, R. & Schäfer, P. (1997). Resorbable versus nonresorbable membranes in combination with Bio-Oss for guided bone regeneration. *International Journal of Oral & Maxillofacial Implants* 12, 844–852.
- Zitzmann, N.U., Schäfer, P. & Marinello, C.P. (1999). Factors influencing the success of GBR. *Journal of Clinical Periodontology* 26, 673–682.

IntechOpen



Bone Regeneration

Edited by Prof. Haim Tal

ISBN 978-953-51-0487-2

Hard cover, 340 pages

Publisher InTech

Published online 04, April, 2012

Published in print edition April, 2012

Bone is a specialized connective tissue, most prominently characterized by its mineralized organic matrix that imparts the physical properties that allow bone tissue to resist load, to support functional organs, and to protect highly sensitive body parts. Bone loss and bone damage may occur as a result of genetic conditions, infectious diseases, tumours, and trauma. Bone healing and repair, involves integrative activity of native tissues and living cells, and lends itself to the incorporation of naturally derived or biocompatible synthetic scaffolds, aimed at replacing missing or damaged osseous tissues. There are several modalities of bone regeneration including tissue engineering, guided bone regeneration, distraction osteogenesis, and bone grafting. This book concentrates on such procedures that may well be counted among the recent outstanding breakthroughs in bone regenerative therapy.

How to reference

In order to correctly reference this scholarly work, feel free to copy and paste the following:

Haim Tal, Zvi Artzi, Roni Kolerman, Ilan Beitlitum and Gal Goshen (2012). Augmentation and Preservation of the Alveolar Process and Alveolar Ridge of Bone, Bone Regeneration, Prof. Haim Tal (Ed.), ISBN: 978-953-51-0487-2, InTech, Available from: <http://www.intechopen.com/books/bone-regeneration/augmentation-and-preservation-of-the-alveolar-process-and-alveolar-ridge-of-bone>

INTECH
open science | open minds

InTech Europe

University Campus STeP Ri
Slavka Krautzeka 83/A
51000 Rijeka, Croatia
Phone: +385 (51) 770 447
Fax: +385 (51) 686 166
www.intechopen.com

InTech China

Unit 405, Office Block, Hotel Equatorial Shanghai
No.65, Yan An Road (West), Shanghai, 200040, China
中国上海市延安西路65号上海国际贵都大饭店办公楼405单元
Phone: +86-21-62489820
Fax: +86-21-62489821

© 2012 The Author(s). Licensee IntechOpen. This is an open access article distributed under the terms of the [Creative Commons Attribution 3.0 License](#), which permits unrestricted use, distribution, and reproduction in any medium, provided the original work is properly cited.

IntechOpen

IntechOpen