

We are IntechOpen, the world's leading publisher of Open Access books Built by scientists, for scientists

4,800

Open access books available

122,000

International authors and editors

135M

Downloads

Our authors are among the

154

Countries delivered to

TOP 1%

most cited scientists

12.2%

Contributors from top 500 universities



WEB OF SCIENCE™

Selection of our books indexed in the Book Citation Index
in Web of Science™ Core Collection (BKCI)

Interested in publishing with us?
Contact book.department@intechopen.com

Numbers displayed above are based on latest data collected.

For more information visit www.intechopen.com



Zoonosis Caused by *Baylisascaris procyonis*

José Piñero, Jacob Lorenzo-Morales, Carmen Martín-Navarro, Atteneri López-Arencibia, María Reyes-Batlle and Basilio Valladares
 University Institute of Tropical Diseases and Public Health of the Canary Islands,
 Department of Parasitology, Ecology and Genetics, University of La Laguna,
 Spain

1. Introduction

The raccoon roundworm, *Baylisascaris procyonis*, is classified under the Phylum Nematelminthes (the roundworms) and Class Nematoda. It is a member of Family Ascaridae and Superfamily Ascaridoidea, which represents intestinal worms with direct life cycles. Other, more familiar ascarids are *Ascaris lumbricoides*, *Toxocara canis*, and *Toxocara cati*, nematode parasites of humans, dogs, and cats, respectively.

Baylisascaris procyonis was first named as *Ascaris columnaris* and isolated from raccoons in the New York Zoological Park in 1931 (McClure, 1933). It was later recognized as a different species (*Ascaris procyonis*) in raccoons in Europe (Stefanski & Zarnowski, 1951). The genus *Baylisascaris* was defined by Sprent in 1968 and included eight recognized and two provisional species previously classified as members of the *Ascaris* or *Toxascaris* genus (Sprent, 1968). The new genus was named after H. A. Baylis, formerly member of the British Museum of Natural History, London, United Kingdom. The possibility of human infection was anticipated by Beaver (Beaver, 1969) and later by Kazacos (Kazacos & Boyce, 1989). The marked zoonotic potential of *B. procyonis* has become apparent only in the last 2 decades. The first confirmed cases of NLM in humans were described to have occurred in two young boys, in 1984 and 1985 (Huff et al., 1984; Fox et al., 1985).

This parasite is common in raccoons (*Procyon lotor*) in North America and Europe and also is frequent in raccoons kept in zoos or peltry farms. Other members of this genus are found in bears, skunks, badgers and other carnivores. There is also evidence that dogs can acquire patent *B. procyonis* infections after scavenging intermediate, hosts.

Baylisascaris procyonis is considered the most common cause of clinical larva migrans (LM) in animals, in which it is usually associated with fatal or severe neurological disease. In humans, particularly children, has emerged in recent years as one of the most serious causes of zoonotic visceral, ocular, and neural LM (VLM; OLM; NLM) and has been recognized as a source of severe, often fatal, neurologic disease.

2. Morphology and life cycle

B. procyonis biologically and morphologically resembles the intestinal roundworm of dogs *Toxocara canis*. Adult worms measure are tan-white in color, cylindrical and tapered at both

ends. The female reaching 20–22 cm long and the male 9–11 cm long (Kazacos, 2001). Cervical alae are vestigial and inconspicuous, the vulva is located one-fourth to one-third the body length from the anterior end, and males possess pericloacal roughened areas. The egg itself is a typical ascarid egg, although smaller than a *Toxocara canis* egg, with a thick pitted shell and a large, dark zygote that almost completely fills the shell. The eggs of *B. procyonis* are ellipsoidal in shape, brown in color, and have a thick shell with a finely granular surface; they range in size from 63–88 x 50–70 µm, with most averaging 68–76 x 55–61 µm.

Adult female worms in the small intestine of raccoons and produce between 115,000 and 179,000 eggs/worm/day. In nature, infected raccoons shed an average of 20,000 to 26,000 eggs per gram of feces, with higher shedding rates in juvenile raccoons than in adults, and can shed in excess of 250,000 eggs per gram of feces. Thus, infected raccoons can shed millions of *B. procyonis* eggs daily, leading to widespread and heavy environmental contamination. The numbers of eggs produced by infected raccoons combined with their defecation behaviour, ensures that latrine sites will become heavily contaminated. The eggs possess a sticky proteinaceous outer coat that enables them to adhere to objects and facilitates transmission. *B. procyonis* eggs become infective (second stage larva) in ~2–4 weeks, depending on environmental temperature and moisture. *B. procyonis* eggs are very resistant to environmental conditions, especially in moist soil. Although they can be killed eventually by extreme heat and dryness, the eggs survive harsh winters, and under appropriate conditions, they can remain viable for years, contributing to the long-term danger posed by latrines.

Young raccoons become infected by ingesting infective eggs, whereas older raccoons become infected by ingesting third-stage larvae (L3's) in paratenic hosts, usually rodents. Young raccoons become infected at an early age by ingesting eggs from their mother's contaminated teats or fur, from the contaminated den, or from raccoon latrines near their den.

In young raccoons, larvae hatching from eggs enter the mucosa of the small intestine and develop there several weeks before reentering the intestinal lumen to mature, the worms reaching patency in 50–76 days. In older raccoons, larvae from intermediate hosts develop to adults in the intestinal lumen, reaching patency in 32–38 days.

The higher parasite burden of juvenile raccoons (mean burden, 48 to 62 worms) than in adults (mean burden, 12 to 22 worms) likely reflects differences in mechanisms of infection.

Like other parasite (*Toxocara* spp.) *B. procyonis* can be borne by intermediate hosts when eggs are swallowed by a different vertebrate. Most commonly the intermediate host is a rodent, birds or lagomorph. In these animals, parasite eggs hatch in the small intestine, penetrate the intestinal wall and are get to the bloodstream through the liver to the lungs, where they are eventually distributed via the blood to various organs. Larvae eventually become encapsulated within eosinophilic granulomas, where they remain viable until they are ingested by raccoons for the lifetime of the host (Kazacos & Boyce, 1989).

B. procyonis larvae often invading the central nervous system (CNS). Invasion of the brain seems to be particularly common in rodents, rabbits, birds and primates. In mice, approximately 5–7% of *B. procyonis* larvae are estimated to enter the CNS. These larvae can

cause considerable damage, both from mechanical damage during migration and from the inflammatory reaction they stimulate. Larvae in the eye can damage the retina and other structures. Eventually the larvae encyst, mainly in the connective tissues and muscles.

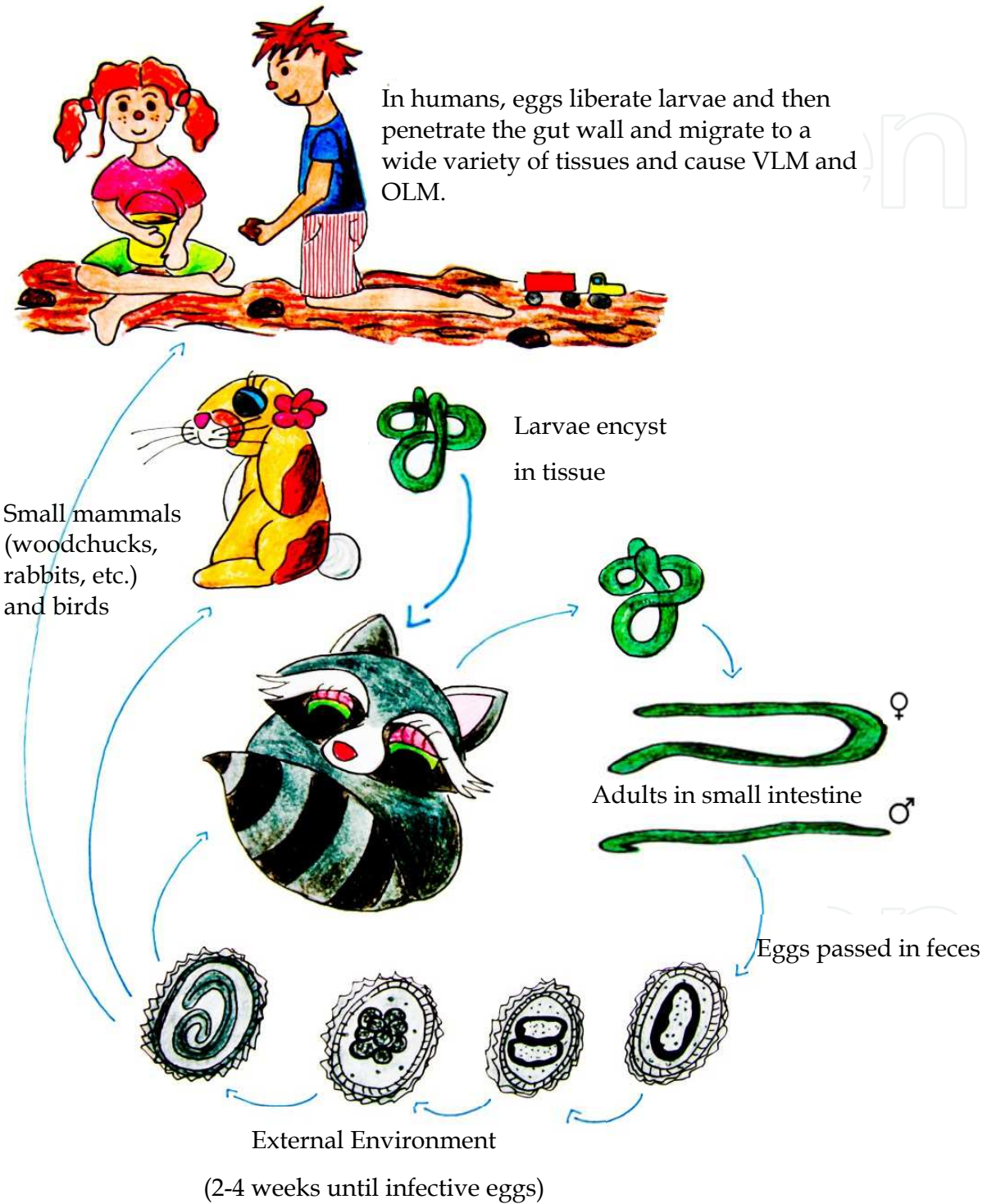


Fig. 1. Life cycle of *Baylisascaris procyonis*.

Humans are accidental intermediate hosts and infection typically occurs in young children with pica or geophagia after ingestion of infective *B. procyonis* eggs from environments or items contaminated with raccoon feces (Kazacos, 2000).

In humans, *B. procyonis* larvae have a tendency to invade the eyes, spinal cord, and brain, causing inflammatory reactions and tissue damage. The result can be blindness, neurological damage, and even death. *B. procyonis* infection typically results in fatal disease or severe sequelae.

3. Epidemiology

Raccoons, which are the definitive hosts for *B. procyonis*, are native to the Americas, where they can be found from Canada to Panama. They were introduced into Europe, the former U.S.S.R. and Asia for the commercial fur trade and into Japan as pets, and have become naturalized in some of these areas. The prevalence of *B. procyonis* infection is high in wild raccoons in Germany and those kept in zoos or as pets in Japan (Baeur & Gey, 2002; Kazacos, 2001; Miyashita, 1993; Sato et al., 2001). Although surveys of feral raccoons in Japan have not detected this organism, it is possible that some pets released into the wild were infected.

In areas where *B. procyonis* is common in raccoons, it has much higher prevalence in juvenile raccoons (> 90%) than in adults (37%-55%). Average parasite intensity ranges from 43 to 52 worms, with juvenile raccoons having a higher mean intensity (48-62, range 1-480) than adult raccoons (12-22, range 1-257) (Snyder & Fitzgerald 1985; Ermer & Fodge 1986; Kazacos, 2001).

In United State *B. procyonis* roundworms are most prevalent in the midwestern, northeastern, and Pacific western states. Numerous surveillance studies have been conducted in the southeastern United States, and parasite are most common in the mountainous regions of Virginia, Kentucky, and West Virginia (Kazacos, 2001; Souza et al., 2009). Geographic expansion of *B. procyonis* roundworms has been recently documented in Georgia (Eberhard et al., 2003; Blizzard et al., 2010a) and into northwestern and southeastern of Florida (Blizzard et al., 2010b). Recently, a study about the prevalence of *B. procyonis* in raccoons in Portland, Oregon, showed that 58% of sampled raccoons were found to be infected with parasite (Yeitz et al., 2009).

In Canada, the prevalence of *B. procyonis* was estimated in 37.1% of the urban raccoon population of Winnipeg (Manitoba) (Sexsmith et al., 2009).

In most areas where raccoons occur, there should be no environmental limitations on the presence of *B. procyonis*, although conditions for optimal egg development and survival will vary based on temperature and humidity. *Baylisascaris procyonis* eggs become infective in 11-14 days at 22°C-25° C and 100% humidity (Sakla et al. 1989), similar to eggs of *B. columnaris* (11-16 d) (Berry, 1985). Under natural conditions, with cooler and/or fluctuating temperatures, egg development will be slower and will take several weeks to months.

Under sufficiently warm but fluctuating temperatures (e.g., cooler nights), most eggs should reach infectivity in 3-4+ weeks. Embryonated *B. procyonis* eggs stored 9-12 years at 4° C retained their infectivity and central nervous system pathogenicity for mice (Kazacos, 2001). Given adequate moisture, embryonated eggs will last years in the soil, including through

harsh winters (Kazacos 1986, 1991; Kazacos & Boyce 1989). Conditions of extreme heat and dryness, as occur in barn lofts and attics in summer months, will kill *B. procyonis* eggs by desiccation, probably in a few weeks or months (Kazacos & Boyce 1989).

The epidemiology of *Baylisascaris* infection is linked to the defecation habits of raccoons. Presumably for communication or territorial reasons, individuals and groups of raccoons habitually defecate in focal areas called "latrines", where large amounts of feces and *B. procyonis* eggs accumulate (Kazacos, 2001; Roussere et al., 2003; Page et al., 1998; Page et al., 1999). Raccoon latrines are found directly on the ground, particularly at the base of trees; along and on the tops of fences; on roofs, decks, and stored firewood; and in outbuildings, attics, and various other locations (Kazacos, 2001; Roussere et al., 2003; Page et al., 1998). Homeowners are often unaware that there are latrines on roofs or hidden elsewhere on their property, thus increasing the risk of exposure to raccoon feces. Moreover, decomposition of the feces can occur rapidly under outdoor conditions, making it less obvious that these areas are contaminated.

The primary risk factors for human *B. procyonis* infection include contact with raccoon latrines, pica/geophagia, young age (<4 years), and male sex. Older persons who have pica or exhibit geophagia are also at risk for significant infection. People are commonly exposed to the eggs of this parasite in peridomestic areas where infected raccoons are common.

4. Pathology

4.1 Infections in humans

Baylisascaris procyonis causes neurologic disease in wild, zoo, and domestic animals as well as human beings. The full clinical spectrum of human baylisascariasis is unknown but includes VLM, NLM, and OLM. In addition, preliminary evidence suggests that asymptomatic infection also occurs.

The severity of CNS disease is related to the number of eggs ingested, the extent and location of larval migration, and the severity of ensuing inflammation and necrosis (Kazacos 2000, 2001). When infective *B. procyonis* eggs are ingested, infective larvae emerge from the eggs, penetrate the gut, and after migrating through the liver and lungs, become distributed via the bloodstream to various somatic tissues, including skeletal muscles, the viscera, brain, and eyes; here, they continue to migrate and eventually become encapsulated in granulomas (Kazacos, 1997, 2001). The pathogenicity of the larvae is related to their aggressive migratory behavior in the tissues and the fact that they molt and grow considerably during migration (Kazacos, 1997, 2000, 2001; Goldberg et al., 1993). Only 5%–7% of ingested larvae enter the CNS (Kazacos, 2000, 2001); thus, although they are not neurotropic per se, their large size, aggressive migration, and stimulation of intense eosinophilic inflammatory reactions cause extensive damage to nervous (and ocular) tissues (Kazacos, 1997). *Baylisascaris* larvae entering the brain migrate there for extended periods before becoming walled off by host reactions. In heavy infections, the brain undergoes postinflammatory atrophy, leading to the progressive neurologic impairment and severe incapacitation seen in surviving patients with neural LM (Gavin et al., 2002a; Rowley et al., 2000a). Pathologic changes are further exacerbated by diagnostic and treatment delays.

The incubation period in humans is uncertain, but NLM may occur as soon as 2 to 4 weeks after ingestion of the eggs.

NLM occurs when the parasites migrate through the CNS, and the symptoms vary with the location and number of the migrating larvae. The initial signs may be mild, with subtle behavioral changes, lethargy, somnolence or irritability, weakness, speech defects and/or mild changes in vision, but they can rapidly become severe. A variety of symptoms including ataxia, paresis or paralysis, developmental regression, tremors, torticollis, nystagmus and coma have been reported. Seizures are common and can be severe. Ocular signs, including blindness, also occur in many cases.

NLM is associated with eosinophilic meningoencephalitis, an elevated peripheral cerebrospinal fluid eosinophilia can be detected in cases of meningoencephalitis.

Some cases of NLM are fatal, almost all surviving patients have been left with serious neurological defects despite treatment. It has been reported only a one case of a child who developed relatively mild symptoms (headache, right arm pain, vomiting, mild upper extremity tremors and dysmetria, progressing to ataxia) and appeared to recover completely.

OLM has been reported more frequently than neural larva migrans, and can occur without neurological signs. Inflammatory and degenerative changes are mainly seen in the retina and optic disk, usually only in one eye. The clinical signs may include transient obscuration of the vision, photophobia, other signs of diffuse unilateral subacute neuroretinitis (DUSN) and loss of vision. Some visual defects can be permanent.

VLM by *B. procyonis* showed non-specific signs such as low-grade fever, nausea and lethargy. Invasion of the liver can result in hepatomegaly, and migration through the lung may cause symptoms of pneumonitis. A macular rash, seen mainly on the face and trunk, has also been reported. VLM is associated with eosinophilic cardiac pseudotumors (cardiac myofibroblastic tumors with high percentage of eosinophils). Subclinical cases might also occur in infection with *B. procyonis*.

Human infections with *B. procyonis* have been documented most often in the U.S., but suspected cases have been reported from Europe, and a patient with neural larva migrans was reported in Canada in 2009. One case of ocular larva migrans in Brazil was reported as a probable *B. procyonis* infection, but the identification was not definitive. No exposure to raccoons was documented in the latter case, although the patient had been exposed to skunks.

Other *Baylisascaris* species have been less well studied, but probably occur in most areas where their definitive hosts are found.

Year of published report	Location	Age	Sex	Clinical	Risk factor	Diagnostic method	Treatment	Outcome
1975	Missouri	18 mo	Female	Eosinophilic meningo-encephalitis	Geophagia	Serologic (cross-reacting)		Persistent weakness and spastic right arm and leg
1984	Pennsylvania	10 mo	Male	Eosinophilic meningo-encephalitis	Pica	Autopsy, serologic	None	Death

Year of published report	Location	Age	Sex	Clinical	Risk factor	Diagnostic method	Treatment	Outcome
1985	Illinois	18 mo	Male	Eosinophilic meningo-encephalitis	Down syndrome and pica	Autopsy, serologic	Thiabendazole	Death
1991	Germany	48 y	Female	Diffuse unilateral subacute neuroretinitis				Ocular sequelae
1992	California	29y	Male	Diffuse unilateral subacute neuroretinitis	Exposure to raccoons	Serologic	None	Ocular sequelae
1993	Michigan	9 mo	Male		Pica	Serologic	Not recorded	Neurologic deficits, cortical blindness
1994	Oregon	21 y	Male	Encephalopathy	Developmental delay, pica/geophagia		Not recorded	Persistent residual deficits
1994	New York	13 mo	Male	Eosinophilic meningo-encephalitis	Pica	Serologic	Thiabendazole, ivermectin, and prednisone	Neurologic deficits, cortical blindness, brain atrophy
1995	Massachusetts	10 y	Male	Eosinophilic cardiac pseudotumor	Not date	Not date	None	Death
2000	California	11 mo	Male	Eosinophilic encephalitis	Pica	Serologic	Albendazole and Methyl-prednisolone	Neurologic deficits, seizures, profound visual impairment
2000	California	13 mo	Male	Eosinophilic meningo-encephalitis	Pica/geophagia	Brain biopsy, serologic	Solumedrol and prednisolone	Neurologic deficits, blindness, seizures, brain atrophy
2001	Minnesota	13 mo	Male	Eosinophilic meningo-encephalitis	Unknown	Serologic	Methyl-prednisolone, vincristine, and thioguanine	Death
2001	Minnesota	19 mo	Male	Eosinophilic meningo-encephalitis	Klinefelter syndrome	Serologic	Prednisone, vincristine, and thioguanine	Death
2002	California	17 y	Male	Eosinophilic meningo-encephalitis	Developmental delay and geophagia	Brain biopsy, serologic	Albendazole and antiinflammatories	Death
2002	California	11 mo	Male	Eosinophilic meningo-encephalitis	Pica/geophagia	Serologic	Albendazole and antiinflammatories	Neurologic deficits, cortical blindness, seizures

Year of published report	Location	Age	Sex	Clinical	Risk factor	Diagnostic method	Treatment	Outcome
2002	Illinois	2.5 y	Male	Progressive encephalopathy	Pica/geophagia	Serologic	Albendazole and solumedrol	Neurologic deficits, blindness, generalized spasticity
2002	Illinois	6 y	Male	Progressive encephalopathy, diffuse unilateral subacute neuroretinitis	Developmental delay, pica/geophagia	Serologic	Albendazole and prednisone	Neurologic deficits, seizures
2003	Michigan	6 y	Male	Diffuse unilateral subacute neuroretinitis, neurologic deficits	Pica	Serologic		Severe neurologic sequelae
2003	Michigan	2 y	Male	Eosinophilic meningo-encephalitis, chorioretinitis	Pica	Serologic		Severe neurologic sequelae
2004	Louisiana	4 y	Male	Eosinophilic meningitis	Raccoons in neighborhood	Serologic	Dexamethasone albendazole	Full recovery
2009	Oregon	17 y	Male	Eosinophilic meningo-encephalitis	Geophagia and substance abuse	Serologic	Methyl-prednisolone	Aphasia and memory deficits
2009	Toronto	7 y	Male	Eosinophilic meningo-encephalitis	Autism, raccoons in backyard	Serologic	Albendazole, methyl-prednisone, prednisone	No longer used speech to communicate, cortical visual impairment, seizure disorder
2010	New York	12 mo	Male	Eosinophilic encephalomyelitis	Geophagia	Serologic	Albendazole, prednisone and methyl-prednisolone	Neurologic deficits

Table 1. Reported human cases caused by *Baylisascaris procyonis*.

4.2 Infections in animals

Susceptibility to *Baylisascaris larva migrans* varies among animal groups and species (Wirtz 1982; Sheppard & Kazacos 1997). Animal groups particularly susceptible to parasite NLM include rodents, rabbits, primates, and birds, based on the number of cases and species affected. For example, in 2007 a *Baylisascaris procyonis* infection in a Moluccan cockatoo (*Cacatua moluccensis*), was reported. An adult female Moluccan cockatoo was evaluated for a 10-day history of progressive ataxia and weakness. The bird had been exposed intermittently over a 3-day period to a cage that had previously housed juvenile raccoons. Results of diagnostic tests were inconclusive and, despite supportive care, the bird died 7 days after the initial presentation. Histopathologic examination revealed a single nematode larva in the midbrain that was consistent with *Baylisascaris* species and multifocal granulomas in the left ventricle of the heart (Wolf et al., 2007).

Some animal groups and species are only marginally susceptible, with limited migration occurring in the intestinal wall or viscera; others appear to be resistant. For example, no cases of *B. procyonis* NLM have been documented in opossums, which are commonly exposed through foraging at raccoon latrines (Page et al., 1998, 1999), or in adult domestic livestock or zoo hoofstock, which are commonly exposed through contaminated hay. Very limited or no migration was seen in sheep, goats, and swine experimentally infected with *B. procyonis* (Dubey, 1982; Snyder, 1983; Kazacos & Kazacos 1984). No cases have been documented in cats or raptors, which eat rodents possibly contaminated with eggs and/or containing L3's. (Kazacos, 2001). The apparent species limitations to *Baylisascaris* infection should be regarded with caution.

Except in very heavy infections with intestinal obstruction, raccoons infected with *B. procyonis* appear clinically normal with no outward signs of infection. Similarly, other species with *Baylisascaris* larva migrans usually are asymptomatic if no larvae enter the brain. The severity and progression of central nervous system disease in NLM depends on the number of eggs ingested, the number of larvae entering the brain, the location and extent of migration damage and inflammation in the brain, and the size of the brain. Thus, clinical disease will vary from mild, insidious, slowly progressive central nervous system disease with subtle clinical signs to acute, fulminating, rapidly progressive central nervous system disease with marked clinical signs. Although larvae enter the somatic tissues, eyes, and brain of some species as early as 3 days postinfection, clinical central nervous system disease is not usually apparent before 9–10 days postinfection, and in many cases not until 2–4+ weeks postinfection, due to the lag time in causing central nervous system damage and inflammation (Kazacos, 1997; Sheppard & Kazacos, 1997).

5. Diagnostic

The diagnosis of baylisascariasis is difficult in live patients; there is no widely available, non-invasive definitive test. The combination of encephalopathy with cerebrospinal fluid (CSF) and peripheral eosinophilia and diffuse white matter disease on neuroimaging, with or without eye disease, in a patient from North America or Europe should strongly suggest the diagnosis of *Baylisascaris* NLM, and a history of exposure to raccoons or their feces should be sought.

Unless a brain biopsy is done and a larva is found, antemortem diagnosis usually depends on serology, with supportive evidence from other tests.

5.1 Serology

In neural larva migrans, antibodies to *Baylisascaris* can be found in serum and CSF; a rising titer is usually seen. An enzyme linked immunosorbent assay (ELISA), indirect immunofluorescence and immunoblotting (Western blotting) have been developed to detect anti-*Baylisascaris* antibodies. These serological assays are not commercially available, but they may be provided by university research laboratories. In the U.S., an ELISA is available from the Department of Comparative Pathobiology at Purdue University, West Lafayette, IN. Indirect immunofluorescence tests use frozen sections of *B. procyonis* third-stage larvae as an antigen. Enzyme-linked immunosorbent assay and Western blotting use excretory-

secretory products from *in vitro* cultures of *B. procyonis* larvae as the antigen (Boyce et al., 1989). Larval excretory-secretory antigens have been characterized as complex glycoproteins, with molecular masses of 10 kDa to 200 kDa, that contain several different sugar residues (Boyce et al., 1989). Protein epitopes of 33-kDa to 45-kDa antigens appear to be recognized selectively by antibodies from *B. procyonis*-infected humans and animals but not by normal human or *T. canis* antibody-positive sera (Boyce et al., 1989). In addition, children with clinical *B. procyonis* NLM are strongly positive for anti-*Baylisascaris* antibodies in CSF and serum and have consistently been negative for anti-*Toxocara* antibodies (Cunningham et al., 1994; Fox et al., 1985; Gavin et al., 2002; Kazacos, 2001; Moertel et al., 2001; Murray, 2002; Park et al., 2000; Rowley et al., 2000). In several of these cases, positive *B. procyonis* serology was confirmed by brain biopsy or at autopsy (CDC, 2002; Fox et al., 1985; Huff et al., 1984; Rowley et al., 2000). Acute and convalescent-phase titers characteristically demonstrate several fold increases in both serum and CSF anti-*Baylisascaris* antibody levels (Gavin et al., 2002; Moertel et al., 2001).

Although *B. procyonis* excretory-secretory (BPES) antigen-based ELISA and Western blot assays are useful in the immunodiagnosis of this infection, cross-reactivity remains a major problem. Recently, a recombinant *B. procyonis* antigen, BpRAG1, was reported for use in development of improved serological assays for the diagnosis of *Baylisascaris larva migrans* (Dangoudoubiyam et al., 2010). In a recent study, authors tested a total of 384 human patient serum samples in a BpRAG1 ELISA, including 20 patients with clinical *Baylisascaris larva migrans*, 137 patients with other parasitic infections (8 helminth and 4 protozoan), and 227 with unknown/suspected parasitic infections. A sensitivity of 85% and specificity of 86.9% was observed with the BpRAG1 ELISA, compared to only 39.4% specificity with the BPES ELISA. In addition, the BpRAG1 ELISA had a low degree of cross-reactivity with antibodies to *Toxocara* spp. infection (25%), while the BPES antigen showed 90.6% cross-reactivity. Based on these results, BpRAG1 antigen has a high degree of sensitivity and specificity and should be very useful and reliable in the diagnosis and seroepidemiology of *Baylisascaris larva migrans* by ELISA (Dangoudoubiyam et al., 2011)

5.2 Laboratory tests

Although no routine laboratory test is considered diagnostic of *B. procyonis* NLM by itself, a number of studies provide additional supporting evidence. Most importantly, the presence of eosinophilia, particularly eosinophilic meningitis,

should alert the physician to the possibility of a parasitic etiology (Lo Re & Gluckman, 2003; Rothenberg, 1998; Weller, 1993). Eosinophils are not normally present in CSF; their presence narrows the differential diagnosis of CNS disease and provides an early or the only etiologic clue. In documented cases of NLM, the peripheral white blood cell count is usually mildly elevated, but eosinophilia may be marked. Cerebrospinal fluid cell counts may be normal at presentation and generally demonstrate only mild leukocytosis, again with eosinophilia. Notably, even in the absence of pleocytosis, demonstrable CSF eosinophilia may be evident. Because eosinophils are easily missed in unstained or Gram-stained CSF, it may be necessary to request Wright's or Giemsa stain of cytocentrifuged CSF specimens. In documented cases of NLM, CSF protein is generally normal or only mildly elevated, while

CSF glucose levels are normal. Although the finding of elevated serum isohemagglutinins, caused by cross-reactions between larval glycoproteins and human blood group antigens, is not specific for baylisascariasis, it does provide an additional clue to the diagnosis (Boyce et al., 1989).

5.3 Other techniques

Imaging techniques and encephalography provide supportive evidence and help rule out other causes. In ocular larva migrans, an ophthalmoscopic examination may occasionally reveal large, motile larvae in the retina, as well as choroidoretinitis and other signs of DUSN. The presence of *Baylisascaris* larvae in the eye is also suggestive in cases with neurological signs. Biopsies of the CNS are occasionally definitive, but larvae are often absent from the sample. A definitive diagnosis can also be made retrospectively from CNS samples taken at autopsy. *Baylisascaris* larvae are much larger (up to 80 μm in diameter and up to 1900 μm long) than *Toxocara* larvae, and can also be distinguished by their morphology. However, parasite larvae can be difficult to identify within tissues, and misidentification is common. In tissues, the third stage larvae of *B. procyonis* cannot be differentiated from *B. columnaris* or *B. melis*. Epidemiological evidence, such as a history of exposure to raccoons but not skunks or badgers, can be suggestive.

6. Treatment

The prognosis for *B. procyonis* NLM is grave with or without treatment; among documented cases, there are no neurologically intact survivors. In this parasite is very important early clinical suspicion of raccoon roundworm meningoencephalitis.

The majority of cases have been treated with anthelmintics and corticosteroids. Empirical anthelmintic treatment with thiabendazole, fenbendazole, tetramisole, or ivermectin has failed to prevent death or unfavorable outcomes. Animal data suggest that albendazole and diethylcarbamazine have the best CSF penetration and larvicidal activity (Kazacos, 2001).

Treatment with albendazole is protective in animal models if eggs have been ingested, but symptoms have not yet developed. In humans, albendazole has been used prophylactically after exposure to raccoon latrines or other sources of eggs. Whether it is helpful in patients with clinical signs is uncertain, because the death of the parasite might worsen the inflammation.

Albendazole appears to have the more favorable pharmacologic profile, with good absorption, high serum concentrations of the active metabolite, good penetration across the blood-brain barrier, and minimal toxicity (de Silva et al., 1997; Jung et al., 1990).

Most clinical cases have been treated concurrently with anthelmintics and corticosteroids; the corticosteroids are used to suppress inflammation caused by the death of the larvae, as well as to dampen the existing inflammatory response. In a recent case a early intervention with both, albendazole and steroids, may have contributed to patient's partial recovery (Hajek et al., 2009) and a mild case of suspected *B. procyonis* infection, with apparent early complete response after cerebellar edema, was treated with early corticosteroids and later albendazole (Pai et al., 2007).

Other supportive therapy may also be given. Recently, an acute eosinophilic meningoencephalitis, caused by *Baylisascaris procyonis* in a previously healthy teenager with a history of substance abuse, was treated with methylprednisolone; no antihelmintic drugs were administered (Chun et al., 2009).

Laser photocoagulation, systemic corticosteroids and other therapies have been used in ocular larva migrans (Goldberg et al., 1993; Kazacos et al., 1985).

In many cases, significant damage has already occurred by the time treatment is begun, and improvement is not seen. The best chance of recovery is expected with a very early diagnosis and treatment.

7. Prevention and control

In intermediate hosts, the risk of infection can be decreased by avoiding contact with raccoons, other definitive hosts and their feces. Raccoons can be discouraged from visiting homes and farms with the same measures that are used to prevent disease in humans. Infections are difficult to prevent completely in pets allowed outdoors, as the infective eggs can survive for long periods in the environment. In dogs, monthly heartworm/nematode preventatives appear to decrease the risk of intestinal infection with *B. procyonis*. In high-risk areas, dogs that are not on these preventatives should receive regular fecal examinations to decrease the risk that they will shed eggs.

In zoos and other facilities, the housing for intermediate hosts should be designed to minimize exposure to raccoons, skunks and other definitive hosts. Captive raccoons and skunks should be kept in dedicated cages that can be cleaned, if necessary, with the harsh methods required to destroy *Baylisascaris* eggs. They should be tested regularly and dewormed when necessary, and they should not be fed wild animals that might carry larvae. Newly acquired definitive hosts should be quarantined and dewormed. Once contamination has occurred, it can be difficult to remove completely. Intermediate hosts in exhibits are sometimes treated prophylactically with pyrantel tartrate or ivermectin. Similarly to humans, animals with recent exposure might also be treated with albendazole to prevent the development of clinical signs.

In humans, risk of infection is greatest when infants or toddlers with geophagia or pica come in contact with raccoon latrines or an environment contaminated by infected raccoon feces. Young infants and toddlers, particularly those with pica or geophagia, should be kept away from potentially contaminated areas.

Raccoon latrines in and around homes and play areas should be cleaned up and decontaminated. However, the longevity of *B. procyonis* eggs and their resistance to disinfection or decontamination makes successful environmental cleanup difficult. Recently a publication (Shafir et al., 2011) showed that eggs survived complete desiccation for at least 6 months at room temperature. Total loss of viability was observed after 7 months of desiccation. Eggs frozen at -15°C for 6 months demonstrated no reduction in viability. Freeze-thaw, including exposure to 5 cycles, did not affect survival. Although they did not specifically design experiments to assess the effect of chlorine on inactivation of *B. procyonis* eggs, exposure to undiluted household bleach for 90 min to remove the mammillated layer

did not affect viability. In this study (Shafir et al., 2011) *B. procyonis* eggs showed a low thermal death point at <62°C, similar to that reported for other ascarids (Shafir et al., 2007; Feachem et al., 1983). Heat is by far the best method of killing *B. procyonis* eggs (Kazacos, 2001). Boiling water, steam-cleaning, flaming, or fire are highly effective and practical methods for decontamination of large or small areas. The use of direct flames from a propane flame-gun is a favored method (Kazacos, 2001). For heavily contaminated areas a combination of removal and disposal of the top few inches of surface soil with flaming is most effective.

8. Acknowledgment

Jacob Lorenzo Morales was funded by a "Ramón y Cajal" grant 2011 from the Spanish Ministry of Science and Innovation. Carmen M^a Martín was supported by a Ph.D. grant "Beca de Investigación CajaCanarias para Postgraduados 2010" from the University of La Laguna, Spain. Atteneri López was funded by the grant "Ayudas del Programa de Formación de Personal Investigador para la realización de Tesis Doctorales" from the Agencia Canaria de Investigación, Innovación y Sociedad de la Información from the Canary Islands Government. This work was funded by project RICET (project no. RD06/0021/0005 of the program of Redes Temáticas de Investigación Cooperativa, FIS), Spanish Ministry of Health, Madrid, Spain and the project "Protozoosis emergentes por amebas de vida libre: Aislamiento y caracterización molecular, identificación de cepas transportadas de otros agentes patógenos y búsqueda de quimioterapias" PI10/01298, Spanish Ministry of Science and Innovation, Madrid, Spain. Authors are thankful to Cecilia Arrate for drawing the *Baylisascaris procyonis* life cycle.

9. References

- Anderson, D.C.; Greenwood, R.; Fishman, M. & Kagan, I.G. (1975). Acute infantile hemiplegia with cerebrospinal fluid eosinophilic pleocytosis: an unusual case of visceral larva migrans. *The Journal of Pediatrics*, Vol.86, n^o2, (February 1975), pp. 247-249.
- Baeur, C. & Gey, A. (1995). Efficacy of six anthelmintics against luminal stages of *Baylisascaris procyonis* in naturally infected raccoons (*Procyon lotor*). *Veterinary Parasitology*, Vol.60, n^o1-2, (November 1995), pp. 155-159, ISSN 0304-4017
- Beaver, P. (1969). The nature of visceral larva migrans. *The Journal of Parasitology*, Vol.55, n^o1, (February 1969), pp. 3-12, ISSN 0022-3395
- Berry, J.F. (1985). Phylogenetic relationship between *Baylisascaris* spp. Sprent, 1968 (Nematoda: Ascarididae) from skunks, raccoons and groundhogs in southern Ontario. M.S Thesis. University of Guelph, Guelph, Ontario, 99 pp.
- Blizzard, E.L.; Davis, C.L.; Henke, S.; Long, D.B.; Hall, C.A. & Yabsley, M.J. (2010a). Distribution, prevalence, and genetic characterization of *Baylisascaris procyonis* in selected areas of Georgia. *The Journal of Parasitology*, Vol.96, n^o6, (December 2010), pp. 1128-33, ISSN 0022-3395.
- Blizzard, E.L.; Yabsley, M.J.; Beck, M.F. & Harsch, S. (2010b). Geographic expansion of *Baylisascaris procyonis* roundworms, Florida, USA. *Emerging Infectious Diseases*, Vol.16, n^o11, (November 2010), pp. 1803-4, ISSN 1080-6059.

- Boyce, W.M.; Asai, D.J.; Wilder, J.K. & Kazacos, K.R. (1989). Physiochemical characterization and monoclonal and polyclonal antibody recognition of *Baylisascaris procyonis* larval excretory-secretory antigens. *The Journal of Parasitology*, Vol.75, pp. 540-548.
- Centers for Disease Control. 2002. Raccoon roundworm encephalitis – Chicago, Illinois, and Los Angeles, California, 2000. *Morbidity and Mortality Weekly Report*, Vol.50, n°51, (January 2002), pp. 1153-1155, ISSN 0149-2195.
- Chun, C.S.; Kazacos, K.R.; Glaser, C.; Bardo, D.; Dangoudoubiyam, S. & Nash, R. (2009). Global neurologic deficits with baylisascaris encephalitis in a previously healthy teenager. *The Pediatric Infectious Diseases Journal*, Vol.28, n°10, (October 2009), pp. 925-7, ISSN 0891-3668.
- Cunningham, C.K.; Kazacos, K.R.; Lucas, J.A.; McAuley, J.B.; Wozniak, E.J. & Weiner, L.B. (1994). Diagnosis and management of *Baylisascaris procyonis* infection in an infant with nonfatal meningoencephalitis. *Clinical Infectious Diseases*, Vol.18, n°6, (June 1994), pp. 868-872, ISSN 1058-4838.
- Dangoudoubiyam, S.; Vemulapalli, R.; Hancock, K. & Kazacos, KR. (2010). Molecular cloning of an immunogenic protein of *Baylisascaris procyonis* and expression in *Escherichia coli* for use in developing improved serodiagnostic assays. *Clinical and Vaccine Immunology*, Vol17, n°12, (December 2010), pp. 1933-9, ISSN 1556-6811
- Dangoudoubiyam, S.; Vemulapalli, R.; Ndao, M. & Kazacos KR. (2011). A recombinant antigen-based enzyme-linked immunosorbent assay for specific diagnosis of *Baylisascaris procyonis* larva migrans. *Clinical and Vaccine Immunology* CVI Accepts, (published online ahead of print on 10 August 2011) doi:10.1128/CVI.00083-11
- De Silva, N.; Guyatt, H. & Bundy, D. (1997). Anthelmintics. A comparative review of their clinical pharmacology. *Drugs* Vol.53, n°5, (May 1997), pp. 769-788, ISSN 0012-6667.
- Dubey, J.P. (1982). *Baylisascaris procyonis* and eimerian infections in raccoons. *Journal of the American Veterinary Medical Association* Vol.181, n°11, (December 1982), pp. 1292-1294, ISSN 0003-1488.
- Eberhard, M.L.; Nace, E.K.; Won, K.Y.; Punkosdy, G.A.; Bishop, H.S. & Johnston, S.P. (2003). *Baylisascaris procyonis* in the metropolitan Atlanta area. *Emerging Infectious Diseases*, Vol9, n°12, (December 2003), pp. 1636-7, ISSN 1080-6059.
- Ermer, E.M. & Fodge, J.A. (1986). Occurrence of the raccoon roundworm in raccoons in western New York. *New York Fish and Game Journal*, Vol.33, pp. 58-61, ISSN 0028-7210.
- Feachem, R.; Bradley, D.J.; Garelick, H. & Mara, D.D. 1983) *Ascaris* and ascariasis. In: *Sanitation and disease: health aspects of excreta and wastewater management*, John Wiley & Sons for World Bank Studies in Water Supply and Sanitation, p. 391, Washington.
- Fox, A.S.; Kazacos, K.R.; Gould, N.S.; Heydemann, P.T.; Thomas, C. & Boyer, K.M. (1985). Fatal eosinophilic meningoencephalitis and visceral larva migrans caused by the raccoon ascarid *Baylisascaris procyonis*. *The New England Journal of Medicine* Vol.312, n°25, (June 1985), pp. 1619-1623, ISSN 0028-4793.

- Gavin, P.J.; Kazacos, K.R.; Tan, T.Q.; Brinkman, W.B.; Byrd, S.E.; Davis, A.T.; Mets, M.B. & Shulman, S.T. (2002). Neural larval migrans caused by the raccoon roundworm *Baylisascaris procyonis*. *The Pediatric Infectious Disease Journal*, Vol.21, n°10, (October 2002), pp. 971–975, ISSN 0891-3668.
- Goldberg, M.A.; Kazacos, K.R.; Boyce, W.M.; Ai, E. & Katz, B. (1993). Diffuse unilateral subacute neuroretinitis: morphometric, serologic, and epidemiologic support for *Baylisascaris* as a causative agent. *Ophthalmology*, Vol.100, n°11, (November 1993), pp. 1695–701, ISSN 0161-6420.
- Hajek, J.; Yau, Y.; Kertes, P.; Soman, T.; Laughlin, S.; Kanani, R.; Kazacos, K.; Dangoudoubiyam, S. & Opavsky, M.A. (2009). A child with raccoon roundworm meningoencephalitis: A pathogen emerging in your own backyard?. *The Canadian Journal of Infectious Diseases & Medical Microbiology*, Vol. 20, n°4, (Winter 2009), pp. 177-80, ISSN 1712-9532.
- Hoffmann, C.O. & Gottschang, J.L. (1977). Numbers, distribution and movements of a raccoon population in a suburban residential community. *Journal of Mammalogy*, Vol.58, No.4, (November 1977), pp. 623-36, ISSN 0022-2372.
- Huff, D.S.; Neafie, R.C.; Binder, M.J.; Leon, G.A.D.; Brown, L.W. & Kazacos, K.R. (1984). The first fatal *Baylisascaris* infection in humans. *Pediatric Pathology*, Vol.2, n°3, (pp. 345–52, ISSN 0277-0938.
- Jung, H.; Hurtado, M.; Sanchez, M.; Medina, M. & Sotelo, J. (1990). Plasma and CSF levels of albendazole and praziquantel in patients with neurocysticercosis. *Clinical Neuropharmacology*, Vol.13, n°6, (December 1990), pp. 559–564, ISSN 0362-5664.
- Kazacos, K.R. (1986). Raccoon ascarids as a cause of larva migrans. *Parasitology Today*, Vol.2, n°9, (September 1986), pp. 253–255, ISSN 0169-4758.
- Kazacos, K.R. (1991). Visceral and ocular larva migrans. *Seminars in Veterinary Medicine and Surgery (Small Animal)*, Vol.6, n°3, (August 1991), pp. 227–235, ISSN 0882-0511.
- Kazacos, K.R. (1997). Visceral, ocular, and neural larva migrans. In: *Pathology of infectious diseases, Vol. II*. Connor, D.H.; Chandler, F.W.; Schwartz, D.A.; Manz, H.J. & Lack, E.E., pp. 1459–73, Appleton & Lange, Stamford, CT.
- Kazacos, K.R. (2000). Protecting children from helminthic zoonoses. *Contemporary Pediatrics*, Vol.95, n°3, (Suppl) pp. 1–24, ISSN 8750-0507.
- Kazacos, K.R. (2001). *Baylisascaris procyonis* and related species. In: *Parasitic diseases of wild mammals. 2nd ed.* Samuels, W.M.; Pybus, M.J. & Kocans, A.A., pp. 301–41, Iowa State University Press/Ames, Iowa.
- Kazacos, K.R. & Kazacos, E.A. (1984). Experimental infection of domestic swine with *Baylisascaris procyonis* from raccoons. *American Journal of Veterinary Research*, Vol.45, n°6, (June 1984), pp. 1114–1121, ISSN 0002-9645.
- Kazacos, K.R.; Raymond, L.A.; Kazacos, E.A. & Vestre, W.A. (1985). The raccoon ascarid. A probable cause of human ocular larva migrans. *Ophthalmology*, Vol.92, n°12, (December 1985), pp. 1735–1743, ISSN 0161-6420.
- Kazacos, K.R. & Boyce, W.M. (1989). *Baylisascaris* larva migrans. *Journal of the American Veterinary Medical Association*, Vol.195, n°7, (October 1989), pp. 894-903, ISSN 0003-1488.


- Lo Re, V.III & Gluckman, S.J. (2003). Eosinophilic meningitis. *The American Journal of Medicine*, Vol.114, n°3, (February 2003), pp. 217-223, ISSN 0002-9343.
- McClure, G. (1933). Nematode parasites of mammals. From specimens collected in the New York Zoological Park, 1931. *Zoologica (New York)* Vol.15 pp. 29-47.
- Mets, M.B.; Noble, A.G.; Basti, S.; Gavin, P.; Davis, A.T.; Shulman, S.T. & Kazacos K.R. (2003). Eye findings of diffuse unilateral subacute neuroretinitis and multiple choroidal infiltrates associated with neural larva migrans due to *Baylisascaris procyonis*. *American Journal of Ophthalmology*, Vol.135, n°6, (June 2003), pp. 888-90, ISSN 0002-9394.
- Miyashita, M. (1993). Prevalence of *Baylisascaris procyonis* in raccoons in Japan and experimental infections of the worm to laboratory animals. *Journal Urban Living Health Association*, Vol.37, pp. 137-151. (In Japanese.)
- Moertel, C.L.; Kazacos, K.R.; Butterfield, J.H.; Kita, H.; Watterson, J. & Gleich, G.J. (2001). Eosinophil-associated inflammation and elaboration of eosinophil-derived proteins in two children with raccoon roundworm (*Baylisascaris procyonis*) encephalitis. *Pediatrics*, Vol.108, n°5, (November 2001), pp. E93, ISSN 0031-4005.
- Murray, W.J. (2002). Human infections caused by the raccoon roundworm, *Baylisascaris procyonis*. *Clinical Microbiology Newsletter*, Vol.24, n°1, pp. 1-7, ISSN 0196-4399.
- Murray, W.J. & Kazacos, K.R. (2004). Raccoon roundworm encephalitis. *Clinical Infectious Diseases*, Vol.39, n°10, (November 2004), pp. 1484-92, ISSN 1058-4838.
- Page, L.K.; Swihart, R.K. & Kazacos, K.R. (1998). Raccoon latrine structure and its potential role in transmission of *Baylisascaris procyonis* to vertebrates. *American Midland Naturalist*, Vol.140, n° 1, (July 1998), pp. 180-185, ISSN 0003-0031.
- Page, L.K.; Swihart, R.K. & Kazacos, K.R. (1999). Implications of raccoon latrines in the epizootiology of baylisascariasis. *Journal of Wildlife Diseases*, Vol.35, n°3, (July 1999), pp. 474-80, ISSN 0090-3558.
- Pai, P.J.; Blackburn, B.G.; Kazacos, K.R.; Warriar, R.P. & Bégué RE. (2007). Full recovery from *Baylisascaris procyonis* eosinophilic meningitis. *Emerging Infectious Diseases*, Vol.13, n°6, (June 2007), pp. 928-30, ISSN 1080-6040.
- Park, S.Y.; Glaser, C.; Murray, W.J.; Kazacos, K.R.; Rowley, H.A.; Fredrick, D.R. & Bass, N. (2000). Raccoon roundworm (*Baylisascaris procyonis*) encephalitis: Case report and field investigation. *Pediatrics*, Vol.106, n°4, (October 2000), pp. E56, ISSN 0031-4005.
- Perlman, J.E.; Kazacos, K.R.; Imperato, G.H.; Desai, R.U.; Schulman, S.K.; Edwards, J.; Pontrelli, L.R.; Machado, F.S.; Tanowitz, H.B. & Saffra, N.A. (2010). *Baylisascaris procyonis* neural larva migrans in an infant in New York City. *Journal of Neuroparasitology*, Vol.1, (June 2010), pp., ISSN 2090-2344
- Rothenberg, M.E. (1998). Eosinophilia. *The New England Journal of Medicine*, Vol.338, n°22, (May 1998), pp. 1592-600, ISSN 0028-4793.
- Roussere, G.P.; Murray, W.J.; Raudenbush, C.B.; Kutilek, M.J.; Levee, D.J. & Kazacos, K.R. (2003). Raccoon roundworm eggs near homes and risk for larva migrans disease, California communities. *Emerging Infectious Diseases*, Vol.9, n°12, (December 2003), pp. 1516-22, ISSN 1080-6040.

- Rowley, H.A.; Uht, R.M.; Kazacos, K.R.; Sakanari, J.; Wheaton, W.V.; Barkovich, A.J. & Bollen, A.W. (2000). Radiologic-pathologic findings in raccoon roundworm (*Baylisascaris procyonis*) encephalitis. *AJNR. American Journal of Neuroradiology*, Vol.21, n°2, (February 2000), pp. 415-420, ISSN 0195-6108.
- Sakla, A.A.; Donnelly, J.J.; Khatami, M. & Rockey, J.H. (1989). *Baylisascaris procyonis* (Stefanski and Zarnowski, 1951) Ascarididae: Nematoda. I. Embryonic development and morphogenesis of second stage larvae. *Assiut Veterinary Medical Journal*, Vol.21, pp. 68-76.
- Sato, H.; Furuoka, H. & Kamiya, H. (2002). First outbreak of *Baylisascaris procyonis* larva migrans in rabbits in Japan. *Parasitology international*, Vol.51, n°1, (March 2002), pp. 105-108, ISSN 1383-5769.
- Sexsmith, J.L.; Whiting, T.L.; Gree, C.; Orvis, S.; Berezanski, D.J. & Thompson A.B. (2009). Prevalence and distribution of *Baylisascaris procyonis* in urban raccoons (*Procyon lotor*) in Winnipeg, Manitoba. *The Canadian Veterinary Journal*, Vol.50, n°8, (August 2009), pp. 846-50, ISSN 0008-5286.
- Shafir, S.C.; Wang, W.; Sorvillo, F.J.; Wise, M.E.; Moore, L., Sorvillo, T. & Eberhard, M.L. (2007). Thermal death point of *Baylisascaris procyonis* eggs. *Emerging Infectious Diseases*, Vol.13, n°1, (January 2007) pp. 172-3, ISSN 1080-6040.
- Shafir, S.C.; Sorvillo, F.J.; Sorvillo, T. & Eberhard, M.L. (2011). Viability of *Baylisascaris procyonis* Eggs. *Emerging Infectious Diseases*, Vol.17, n°7, (July 2011), pp. 1293-5, ISSN 1080-6040.
- Sheppard, C.H. & Kazacos, K.R. (1997). Susceptibility of *Peromyscus leucopus* and *Mus musculus* to infection with *Baylisascaris procyonis*. *The Journal of Parasitology*, Vol.83, n°6, (December 1997), pp. 1104-1111, ISSN 0022-3395.
- Snyder, D.E. (1983). The prevalence, cross-transmissibility to domestic animals and adult structure of *Baylisascaris procyonis* (Nematoda) from Illinois raccoons (*Procyon lotor*). Ph.D. Thesis, University of Illinois at Urbana-Champaign, Urbana, IL, 233 pp.
- Snyder, D.E. & Fitzgerald, P.R. (1985). The relationship of *Baylisascaris procyonis* to Illinois raccoons (*Procyon lotor*). *The Journal of Parasitology*, Vol.71, n°5, (October 1985), pp. 596-598, ISSN 0022-3395.
- Souza, M.J.; Ramsay, E.C.; Patton, S. & New, J.C. (2009). *Baylisascaris procyonis* in raccoons (*Procyon lotor*) in eastern Tennessee. *Journal of Wildlife Diseases*, Vol.45, n°4, (October 2009), pp. 1231-4, ISSN 0090-3558.
- Sprent, J.F.A. (1968). Notes on *Ascaris* and *Toxascaris*, with a definition of *Baylisascaris* gen. nov. *Parasitology*, Vol.58, n°1, (February 1968), pp. 185-198, ISSN 0031-1820.
- Stefanski, W. & Zarnowski, E. (1951). *Ascaris procyonis* n. sp. z jelita szopa (*Procyon lotor* L.) *Ascaris procyonis* n. sp. provenant de l'intestin de *Procyon lotor*. *Ann. Mus. Zool. Polonici*, Vol.14, pp. 199-202.
- Weller, P. F. (1993). Eosinophilic meningitis. *The American Journal of Medicine*, Vol.95, n°3, (September 1993), pp. 250-253, ISSN 0002-9343.
- Wirtz, W.L. (1982). Cerebrospinal nematodiasis due to the raccoon ascarid, *Baylisascaris procyonis*. M.S. Thesis, Purdue University, West Lafayette, IN, 90 pp

- Wolf, K.N.; Lock, B.; Carpenter, J.W. & Garner, M.M. (2007). *Baylisascaris procyonis* infection in a Moluccan cockatoo (*Cacatua moluccensis*). *Journal of Avian Medicine and Surgery*, Vol.21, n°3, (September 2007), pp. 220-5, ISSN 1082-6742.
- Yeitz, J.L.; Gillin, C.M.; Bildfell, R.J. & Debess, E.E. (2009). Prevalence of *Baylisascaris procyonis* in raccoons (*Procyon lotor*) in Portland, Oregon, USA. *Journal of Wildlife Diseases*, Vol.45, n°1, (January 2009), pp. 14-8, ISSN 0090-3558.

IntechOpen

IntechOpen



Zoonosis

Edited by Dr. Jacob Lorenzo-Morales

ISBN 978-953-51-0479-7

Hard cover, 436 pages

Publisher InTech

Published online 04, April, 2012

Published in print edition April, 2012

Zoonotic diseases are mainly caused by bacterial, viral or parasitic agents although "unconventional agents" such as prions could also be involved in causing zoonotic diseases. Many of the zoonotic diseases are a public health concern but also affect the production of food of animal origin thus they could cause problems in international trade of animal-origin goods. A major factor contributing to the emergence of new zoonotic pathogens in human populations is increased contact between humans and animals. This book provides an insight on zoonosis and both authors and the editor hope that the work compiled in it would help to raise awareness and interest in this field. It should also help researchers, clinicians and other readers in their research and clinical usage.

How to reference

In order to correctly reference this scholarly work, feel free to copy and paste the following:

José Piñero, Jacob Lorenzo-Morales, Carmen Martín-Navarro, Atteneri López-Arencibia, María Reyes-Batlle and Basilio Valladares (2012). Zoonosis Caused by *Baylisascaris procyonis*, Zoonosis, Dr. Jacob Lorenzo-Morales (Ed.), ISBN: 978-953-51-0479-7, InTech, Available from:

<http://www.intechopen.com/books/zoonosis/zoonosis-caused-by-baylisascaris-procyonis>

INTECH
open science | open minds

InTech Europe

University Campus STeP Ri
Slavka Krautzeka 83/A
51000 Rijeka, Croatia
Phone: +385 (51) 770 447
Fax: +385 (51) 686 166
www.intechopen.com

InTech China

Unit 405, Office Block, Hotel Equatorial Shanghai
No.65, Yan An Road (West), Shanghai, 200040, China
中国上海市延安西路65号上海国际贵都大饭店办公楼405单元
Phone: +86-21-62489820
Fax: +86-21-62489821

© 2012 The Author(s). Licensee IntechOpen. This is an open access article distributed under the terms of the [Creative Commons Attribution 3.0 License](#), which permits unrestricted use, distribution, and reproduction in any medium, provided the original work is properly cited.

IntechOpen

IntechOpen