

# We are IntechOpen, the world's leading publisher of Open Access books Built by scientists, for scientists

4,800

Open access books available

122,000

International authors and editors

135M

Downloads

Our authors are among the

154

Countries delivered to

TOP 1%

most cited scientists

12.2%

Contributors from top 500 universities



WEB OF SCIENCE™

Selection of our books indexed in the Book Citation Index  
in Web of Science™ Core Collection (BKCI)

Interested in publishing with us?  
Contact [book.department@intechopen.com](mailto:book.department@intechopen.com)

Numbers displayed above are based on latest data collected.  
For more information visit [www.intechopen.com](http://www.intechopen.com)



# Radio-Guided Surgery and Intraoperative iPTH Determination in the Treatment of Primary Hyperparathyroidism

Paloma García-Talavera and José Ramón García-Talavera  
*Universidad de Salamanca  
 Spain*

## 1. Introduction

Different opinions exist regarding surgical techniques in the case of primary hyperparathyroidism (PHPT). Traditionally, all patients who underwent surgery were given a bilateral neck exploration.

Since the main cause of PHPT is solitary adenoma, Tibblin et al. (1982) described the possibility of performing a unilateral neck exploration. Up till that time, the greatest limitation for this technique was the lack of precision in preoperative localization protocols. Nowadays, thanks to  $^{99m}\text{Tc}$ -methoxy-isobutyl-isonitrile (MIBI) scintigraphy (Fig 1) and high resolution ultrasonography, unilateral neck exploration is successfully applied.  $^{99m}\text{Tc}$ -MIBI imaging has been widely acknowledged as a basic test for preoperative localization and planning of the operation, being the test of choice in patients with persistent or recurrent PHPT, suspect of ectopic adenomas or in those who have been submitted to thyroidectomy or to other previous neck operations (Papathanassiou et al., 2008).

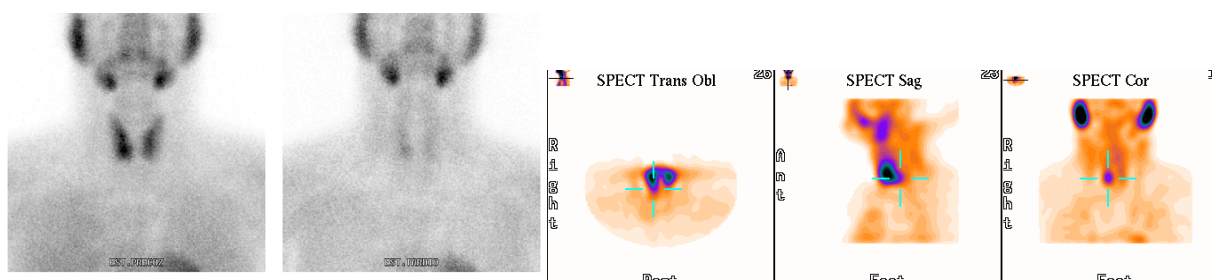


Fig. 1. Double phase  $^{99m}\text{Tc}$ -MIBI scintigraphy: Planar images and early SPECT in a patient with a right inferior single adenoma.

Besides, in many occasions, intraoperative intact parathyroid hormone (ioPTHi) detection allows a unilateral neck approach, avoiding extensive surgery and increasing success rates.

Moreover, due to the use of other intraoperative methods, such as the gamma probe, it is possible to perform even more limited surgery (minimally invasive parathyroidectomy -MIP). At some medical centres, the combination of these techniques has allowed to perform outpatient surgery, with a clear benefit from the cost-efficiency point of view, compared to

general anaesthesia and much more extensive cervical dissection. Nevertheless, it should be kept in mind that in the case of minimally invasive methods patients must be carefully selected to make sure there is no multiglandular disorder (e.g., MEN or secondary hyperparathyroidism).

Another intraoperative technique which needs further investigation is the use of portable gamma-cameras. As yet few studies with a limited number of patients have been published concerning this new technique.

Consequently, PHPT surgical treatment differs in accordance with the surgeon's preference and the availability of preoperative techniques.

## 2. Gamma probe

The same year when Norman & Chheda (1997) proposed the use of  $^{99m}\text{Tc}$ -MIBI mapping to guide minimally invasive parathyroidectomy, Bonjer et al. (1997) suggested using a probe during a bilateral cervical exploration for intraoperative detection of parathyroid adenomas not visualised preoperatively by scintigraphy.

The technique of intra-operative gamma-detection is based on the differences between the kinetics of MIBI in hyperfunctioning parathyroid tissue and in its surrounding tissue, including thyroid and lymph nodes. MIBI localizes non-specifically in the mitochondria and cytoplasm in response to elevated membrane potentials across the membrane bilayers. It is concentrated in tissues that have increased cell activity or higher numbers of mitochondria.

The method consist in the intraoperative detection of the tissue to be extirpated, which shows uptake as a result of the radiotracer administered to the patient prior to surgery. Localization is carried out with a manual gamma radiation detector which the surgeon introduces into the surgical field (Fig 2). By means of an acoustic signal and a digital counter measuring over-background radioactive emissions (*in vivo* counting), the damaged tissue is localized and subsequently extirpated.

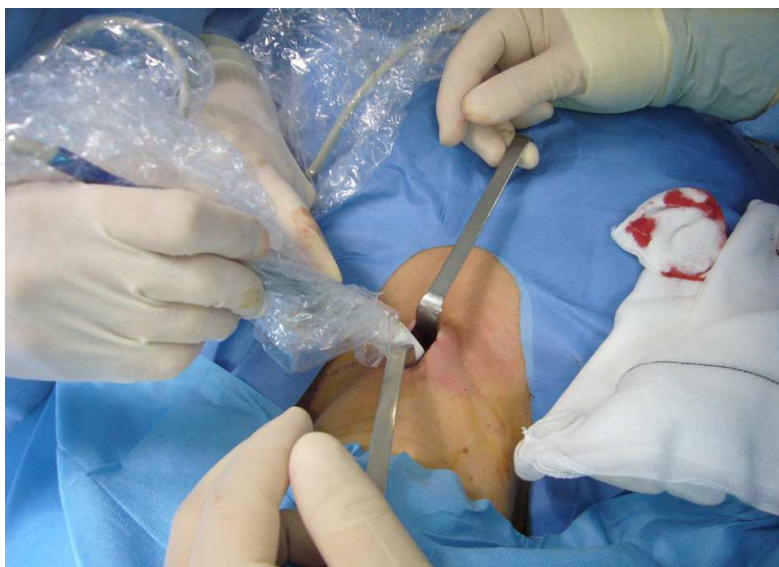

Fig. 2. The surgeon introducing the gamma probe through the incision in a MIP due to a single adenoma.

A further advantage reported is that use of the gamma probe reduces surgery time. In addition, *ex vivo* counting of the extirpated tissue and counting of the empty parathyroid bed, after the excision of the adenoma, serve to assess how successful surgery was.

This technique has been reported a sensitivity between 84.6% and 93% in localizing adenomas, and 63% in the case of disorders compromising multiple glands.

Although this is the traditional way to perform radioguided surgery in hyperparathyroidism, it has been recently reported a case in which authors used a preoperative injection of macroaggregate human albumin (MAA) labeled with  $^{99m}\text{Tc}$  into the lesion and ultrasonographic guidance to localize an ectopic parathyroid gland (Aliyev et al., 2010).

### 2.1 Technique: Doses and time of injection

There is a certain controversy in radioguided surgery with regard to the optimal dose and the optimal time of injection prior to the operative procedure. Norman & Chheda (1997) performed the MIBI scintigraphy on the day of surgery, thus reducing economic cost and radiation doses to the patients. However, in some cases this protocol does not allow planning the type of surgery, while most authors believe that in cases of thyroid pathology a bilateral exploration should be carried out instead of a minimally invasive surgery (Casara et al., 2002). For this reason, in areas of endemic goitre, it is preferable to apply a different-day protocol. Using the latter, Rubello et al. (2006a) propose to carry out a double tracer scintigraphy on the first day and to inject 37 MBq on the day of surgery, 10 to 30 minutes before the minimally invasive parathyroidectomy. In this way, the radiation dose to the surgery team is minimized and false negatives due to parathyroid adenomas with rapid washout are avoided (Rubello et al., 2003).

On the other hand, the time from injection to surgery varies between several minutes (Rubello et al., 2006b) and 3-3.5 h prior to surgery (Dackiw et al., 2000; Mc Greal et al., 2001; Murphy & Norman, 1999), with some authors choosing the proper time depending on when the best ratio is reached between MIBI uptake by the parathyroid tissue and the surrounding tissues (Ugur et al., 2004).

Doses ranging from 37MBq (Rubello et al., 2006b) to 740-925MBq (Goldstein et al., 2003; Mc Greal et al., 2001; Murphy & Norman, 1999) have been reported. In particular, we initially injected 740MBq, 3 h before surgery, but modified our protocol to 370MBq, 10-60 minutes before surgery, in order to reduce radiation doses while keeping the same detection ability.

### 2.2 Ex vivo and in vivo counting

There are also different approaches regarding the selection of the reference area to measure background: the thyroid gland (Chen et al., 2003, 2005; Takeyama et al., 2004; Ugur et al., 2004, 2006), the lung vertex contralateral to the pathological thyroid gland (Rubello et al., 2003), the right shoulder (Takeyama et al., 2004), the central area of the neck (Goldstein et al., 2003), the lateral region of the incision (Friedman et al., 2007) or the post-exeresis thyroid bed (Mc Greal et al., 2001; Murphy & Norman, 1999; Takeyama et al., 2004; Ugur et al., 2004, 2006).

Takeyama et al. (2004) use the *in vivo* counting as well as the *ex vivo* counting. The *in vivo* counting is used for the localization and removal of the tumor (with the background being obtained as the maximum of two measurements: one on the right shoulder and one on the

thyroidal isthmus). The completeness of the excision is confirmed by means of the *ex vivo* counting, which uses the Murphy & Norman procedure (1999) to calculate the corresponding percentage with respect to background.

Ugur et al. (2006) compare the *in vivo* counting of the parathyroid lesion to the thyroidal background of the contralateral side and the *ex vivo* parathyroid counting to the post-exeresis background of the surrounding normal tissues.

Most authors (Chen et al., 2003, 2005; Dackiw et al., 2000; Goldstein et al., 2003; Mc Greal et al., 2001; Murphy & Norman, 1999; Olson et al. 2006; Takeyama et al., 2004), however, use the *ex vivo* counting alone. They confirm a correct exeresis by determining the *ex vivo* counting of the specimens and applying the so-called “rule of 20” (i.e., *ex vivo* counts must exceed background by at least 20%). They generally consider the post-exeresis bed as background. When the suspected adenoma is removed, there is a radioactivity decline there and all quadrants show an equal score count (Norman & Chheda, 1997).

According to Rubello et al. (2003a, 2003b), a value for the index determined by the bed and the apex of the lung contralateral to the pathological parathyroid gland close to unity would suggest the complete excision of the hyperactive parathyroidal tissue. These authors (Rubello et al., 2003a) describe an *ex vivo* index (parathyroid gland/background) higher than 40% in all cases of adenoma and in at least one of the pathological parathyroid gland of a multiglandular disease.

Friedman et al. (2007) consider a background measurement made at the skin of the neck, in the lateral zone of the incision. According to their findings, the *ex vivo* counting of the normal parathyroid glands is significantly lower than that of the pathological glands, for which the percentage over background exceeds 40%.

We use the *in vivo* counting to guide surgeon excision. To do so, we obtain a background measurement after incision by placing the probe over the thyroidal isthmus. Once the incision is made, an operative mapping is taken in the four quadrants for bilateral surgeries or in the region of the suspected adenoma for MIP. The *in vivo* index is defined as the ratio of *in vivo* counting to background (García-Talavera et al., 2010, 2011).

The *ex vivo* counting is also used for differentiating between pathological parathyroid tissue and fat, lymphatic nodes, or thymus (Friedman et al., 2007; Norman & Chheda, 1997). We performed this measuring the parathyroid gland outside the operative field (*ex vivo* counting), and comparing it with the empty bed (*ex vivo* index). As stated below, we use the ioPTHi to confirm the complete exeresis of the pathological parathyroid tissue.

### 2.2.1 Adenoma vs hyperplasia

The traditional procedure to differentiate between adenomas and hyperplasic glands is the histological evaluation by frozen section. However, surgeons do not always provide enough tissue to the pathologist or the tissue sections are not cut appropriately, which results in a substantial false positive and false negative rate (Murphy & Norman, 1999). Furthermore, frozen section analysis is often unreliable in distinguishing hyperfunctioning and normally active parathyroid tissue, as this method only provides a view of a single portion of the gland (Irvin & Bagwell, 1979; Murphy & Norman, 1999), with specimens often interpreted as “non diagnostic parathyroid tissue” (Irvin & Bagwell, 1979). Dewan et al. (2005) report



that errors in gross tissue evaluation, by both the surgeon and pathologist, give rise to a 6% operative failure rate.

Because of these drawbacks, the *ex vivo* and the *in vivo* counting have been used by some authors to differentiate between adenomas and hyperplastic glands. According to Murphy & Norman (1999), the *ex vivo* counting in adenomas differs from that in hyperplastic glands: <16% radioactivity over background for non-parathyroidal tissues and normal and hyperplastic parathyroid glands *vs* 59±9% (variation range: 18%-136%) for adenomas. Mc Greal et al. (2001) also found statistically significant differences in the *ex vivo* index between single adenomas and other types of tissues; they concluded that, in patients with a MIBI positive scintigraphy, a 20% counting over background for the excised tissue gives a strong evidence of a single adenoma while the counting for lymph nodes, thyroid tissue and normal or hyperplastic glands would not exceed the said value.

On the contrary, Friedman et al. (2007) argue that the *ex vivo* counting can differentiate between pathological parathyroid glands and other tissues, but it is unable to differentiate between adenomas and hyperplasias, given that, although the counting was statistically higher for adenomas than for hyperplasias, the results overlapped in some cases. This view is supported by Chen et al. (2003), who did not find statistically differences between the *in vivo* counting of adenomas and hyperplasias. On the contrary, Ugur et al. (2006), propose an *in vivo* index cut-off value of 103% to differentiate between adenoma and hyperplastic glands, achieving 82.5% sensitivity and 65% specificity.

In our study (García-Talavera et al., 2011), significant differences were found, on one hand, between the *in vivo* index for adenomas and double adenomas ( $p=0.009$ ) and, on the other, between adenomas and hyperplasias ( $p=0.002$ ). However for adenomas and multiglandular disease, there is a region of overlapping values. Using a cut-off value of 1.51, we obtained a 67% sensitivity and 87% specificity. With this cut-off value, we reached a PPV of 95% that would allow, in positive cases, to exclude the existence of a second pathological gland with a high confidence. Rubello et al. (2006b) and EANM parathyroid guidelines (Hindié et al., 2009) reported as well that an *in vivo* index greater than 1.5 strongly suggests the presence of a solitary adenoma.

### 2.2.2 Glandular size

The glandular size and weight have been described to influence the counting of the abnormal glands. Ugur et al. (2004) described a correlation between the *ex vivo* counting and the size of the gland. Thus, he warns that large hyperplastic glands may behave like a parathyroid adenoma as with regard to their total count.

Friedman et al. (2007) concluded, as well, that the percentage of radioactivity above background is proportional to the mass of the specimen, which has significant implications when decision are being made based on radioactive counts obtained from whole excised parathyroid adenomas *vs* biopsy specimens of hyperplastic or normal glands.

On the contrary, in the experience of Chen et al. (2003), gland weight does not directly correlate with *ex vivo* radionuclide counts. They explained that although very large glands tended indeed to have high *ex vivo* counts, the variation range of *ex vivo* counts for smaller glands was very large.

In our experience, a significant non-linear correlation (Spearman,  $p=0.005$ ) is found between *in vivo* counting and gland volume (García-Talavera et al., 2011).

### 2.3 Benefits and failures of the probe

The reported benefits of the probe are manifold. As mentioned above, the probe may be used to differentiate between parathyroid adenoma and hyperplasia as well as between pathological parathyroid glands and other macroscopically similar tissues, as for instance, adipose and lymphoid tissues [Murphy & Norman, 1999].

Besides, as often reported (Berland et al., 2005; Chen et al., 2003; Rubello et al., 2003a; Weigel et al., 2005; García-Talavera et al., 2010), an important contribution of the probe is its usefulness in locating ectopic glands: at deep cervical locations, in the mediastinum or in an intrathyroid location.

In particular the gamma probe is very helpful in patients with persistent or recurrent PHPT (Bonjer et al., 1997), and in patients with previous cervical surgery due to thyroid or parathyroid disease (Dackiw et al., 2000). For these patients, the technique allows the extent of reoperation to be minimized reducing complications (Casara et al., 2002). At this point, it must be stated that in cases of persistent disease the failure of the surgery is usually caused by an ectopic adenoma and the detection of this latter improves with the use of the probe.

Compared to the scintigraphy (Chen et al., 2005; García-Talavera et al., 2010, 2011), the probe eliminates FP scintigraphical results, contributing to minimize the extent of surgical intervention. It also avoids the persistence of the disease detecting FN scintigraphic results, because of small adenomas, but especially due to multiglandular disease. This supports the theory that a radioguided surgery can be performed despite a negative scintigraphy (Mc Greal et al., 2001; Rubello et al. 2006b). Dackiw et al. (2000) described possible causes of these negative results: for instance, a relatively weak labeling of the parathyroid tissue with MIBI, relatively small parathyroid adenomas, or background interferences (mediastinal structures, multinodular thyroid gland). In patients with negative scintigraphic results, the advantages of the intraoperative gamma probe over the preoperative scintigraphy include the ability to move interfering structures (thyroid) out of the way of the probe and the ability to perform *ex vivo* counting. Nevertheless, these authors only recommend using intraoperative probe in carefully selected patients with negative or unequivocally MIBI scintigraphies that are undergoing re-operative procedures. In such patients, Norman & Denham (1998) advocated to suppress thyroid function preoperatively with thyroxine.

As previously mentioned, the probe allows verifying the efficacy and completeness of the parathyroidectomy. In this way, it can minimize the extent of dissection (Chen et al., 2003) and allows to perform a MIP, shortening surgery time and hospital stays (Rubello et al., 2003a) thus decreasing costs (Flynn et al., 2000; Goldstein et al., 2000) and improving the esthetic results without major surgical complications.

There are, however, certain shortcomings to radioguided surgery. The most important is its poor use when there is concomitant thyroid pathology (Bonjer et al., 1997). Some authors discourage its use for such patients, since the existence of thyroid nodules with MIBI uptake largely worsens its performance except in those with ectopic or deep cervical adenomas. To detect nodules with a high uptake (which may lead to false positive scintigraphy and errors

in radioguided surgery), it has been proposed to acquire a preoperative double-tracer scintigraphy (Casara et al., 2002). Instead, we perform other imaging techniques (ultrasonography, CT or MRI) in addition to the scintigraphy.

The EANM (Hindié et al., 2009) has recently issued guidelines on the application to parathyroidectomy of the gamma detecting probe, as well as scintigraphy and other imaging localization techniques. They review the main indications for the use of the gamma probe, which, as stated above, do not include patients with concomitant thyroid nodules. However, in our experience (García-Talavera et al., 2010), patients with concomitant thyroid pathology should not be excluded *a priori* from MIP, provided that other adjuvant techniques are used along with the gamma probe. The ioPTHi determination can detect FP and indicates whether surgery can be ended or should be continued or converted into a unilateral or bilateral approach.

Another shortcoming is that the sensitivity of the gamma probe decreases in cases of multiglandular disease (Bonjer et al., 1997; Dackiw et al., 2000). The ioPTHi determination has an important role to avoid the rate of FN, as well (García-Talavera et al., 2011).

Despite the many reports supporting radioguided surgery in patients with PHPT, several authors are not so enthusiastic about this technology. Many of them pointed out the high success rate of parathyroidectomy when performed by experienced surgeons and emphasize that radioguided techniques do not routinely provide any additional information. In a series of 60 patients with PHPT, Inabnet et al. (2002) found that although radioguided surgery was helpful in 40% of cases, it provided confusing or inaccurate information in 48% of cases. Jaskowiak et al. (2002) found radioguided technique only helpful in 22% of patients (out of 57 patients with PHPT). However, these authors admit the benefits of this technique in cases of persistent or recurrent PHPT and in the re-operative neck. They added that the gammaprobe localization proved also useful in some cases of ectopic glands.

In our opinion, although the results may vary depending, among other factors, on the skilfulness of surgeon and probe operator, the gamma probe is a useful tool, especially allowing a MIP or unilateral surgery and localizing adenomas in ectopic locations. This technique, in addition to preoperative localization imaging (double phase scintigraphy), increased the overall success rate from 79% to 94% (Table 1), even in a population with a high prevalence of thyroid pathology (García-Talavera et al., 2010). We use this technique as well in reoperations (previous thyroid or parathyroid surgery) with good results, and in bilateral neck exploration where it shortens surgery time and improves the location of ectopic adenomas.

	Without thyroid pathology	With thyroid pathology	Total
Scintigraphy	85.2%	69.7%	79.3%
Scintigraphy & probe	96.3%	90.9%	94.3%
Scintigraphy & ioPTHi	94.4%	93.9%	94.3%
All techniques	98.2%	97.0%	97.7%

Table 1. Success of the combined use of the techniques regarding to the presence or not of concomitant thyroid pathology.



### 3. Intra-operative intact PTH (ioPTHi)

In the last few years, ioPTHi determination has been incorporated into hyperparathyroidism surgery, as a means of detecting the decrease of this hormone in plasma following excision of all the diseased parathyroid tissue. Information obtained with pre-operative localization procedures, together with the biological confirmation by ioPTHi that the whole hyperfunctioning parathyroid tissue has dried up, makes a unilateral neck approach possible, in many cases, thereby avoiding extensive surgery and increasing the success rate.

In 1988, Nussbaum et al. described a method for rapid ioPTHi detection, namely, by modifying the non-competitive radioimmunoassay technique (IRMA) employed for serum iPTH quantification. Since then, many authors have successfully used this procedure, which requires a radioactive isotope and takes about 30-35 min (from sample collection till the result is available).

Some years later, we saw the commercialisation of a chemiluminescent immunometric assay (ICMA), which has several advantages over the IRMA. With a reduction in total assay time to 15 minutes and without the need for radioactive isotopes, it is even possible to conduct this test in the operating theatre. This technique, developed and documented by Irvin et al. (1993), is being employed, with good results, in surgical treatment of primary and secondary hyperparathyroidism. In a latter study, Irvin & Deriso (1994) assessed that a reduction of more than 50%, ten minutes after excision, is indicative of total extirpation of the diseased parathyroid tissue and highly suggestive of post-operative eucalcemia. With this procedure, they obtained sensitivity and specificity figures of 95% and 100%, respectively.

#### 3.1 Reference values

Carneiro et al. (2003) compared the so-called Miami criterion (ioPTHi drop  $\geq 50\%$ , 10 minutes after gland excision, with respect to the maximum of the pre-incision and the pre-excision level,) to other five published criteria used to predict complete resection. In their study, the Miami criterion showed the highest accuracy. The use of any of the others would minimize the false positive results, but would cause unnecessary neck explorations in searching for multiglandular disease.

Riss et al. (2007) compared the incidence of false positives, using three different criteria, specifically, the "Vienna" criterion ( $> 50\%$  decline of the pre-incision baseline level, 10 minutes after excision), the "Hale" criterion (decline of the ioPTHi level to  $\leq 35$  pg/ml, within 15 minutes after excision) and the "Miami" criterion. In 207 patients, the use of the Vienna criteria was shown to produce a lower incidence of false positives, thereby decreasing the risk of multiglandular disease when compared to the other criteria evaluated.

Bergson et al. (2004) took samples before skin incision or induction of anesthesia (baseline 1); pre-excision, after identification but before removal of an abnormal gland (baseline 2); at 5 and 10 minutes after gland excision; and at variable intervals thereafter. In cases of multiglandular disease, samples were generally drawn at 10 minutes intervals after each gland was excised. A decrease in ioPTHi level by 50% from baseline 1 and into the normal range ( $< 65$  pg/ml) was used to indicate successful removal of all abnormal parathyroid tissue.

Nevertheless, Thompson et al. (1999) suggested that a cut-off of 70% would result in the identification of a higher proportion of patients with multiglandular disease. On the other hand, Dackiw et al. (2000) proposed that, when using the ioPTHi determination in patients with MEN1, it is reasonable to apply the same target used by Clary et al. (1997) – an approximately 80% decrease in ioPTHi level– in patients with secondary hyperparathyroidism and parathyroid hyperplasia. Analogously, for Hughes et al. (2011), if a multiglandular disease is detected during the operation, a more stringent criterion for determining adequate resection can improve cure rates. They reported that a decrease of  $\geq 75\%$  and into the normal range improves the PPV from 93.2 to 96.6, when compared to the standard criterion of a 50% decrease in the ioPTHi baseline level.

We use the classic criteria of a  $> 50\%$  decrease of ioPTHi, 10 minutes after gland extirpation, compared to the pre-incision level (baseline). As for persistent hyperfunctioning parathyroid tissue, we take samples 10 minutes after every gland excision.

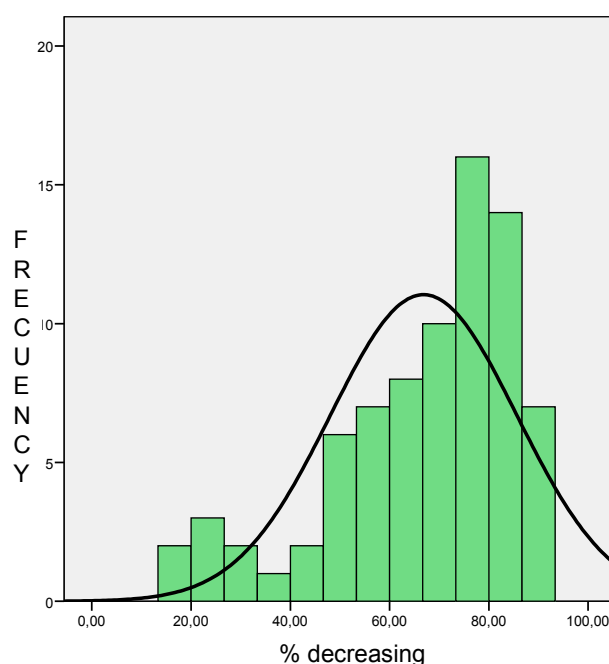


Fig. 3. Distribution of the decreasing of the ioPTHi level at 10 minutes in a population of 78 patients with surgery for PHPT (mean=66.8%; SD=18.8%) (García-Talavera. Unpublished data).

### 3.2 Indications

Dackiw et al. (2000) summarize the following main indications of the ioPTHi determination:

1. Predicting clinical cure or indicating the need for bilateral neck exploration and the likelihood of multiglandular disease in patients undergoing a unilateral or minimally invasive parathyroidectomy.
2. Predicting the cure in patients undergoing an anatomically directed reoperative parathyroidectomy.
3. Indicating the need for additional resection of hyperplastic parathyroid tissue in patients with secondary hyperparathyroidism and MEN1.

4. Suggesting the potential need for autografting and cryopreservation in patients with final ioPTHi values below the lower limit of detection, particularly in patients undergoing a reoperative parathyroidectomy and in patients undergoing a near-total parathyroid excisions.

In addition, the final ioPTHi level has been described to predict those at risk for recurrence after parathyroidectomy. Heller & Blumberg (2009) reported that those patients with a final level of 40 pg/ml or higher are at risk of having persistent hyperparathyroidism and should be followed-up closely and indefinitely following parathyroidectomy.

The ioPTHi determination has been described, as well, to be useful in detecting false negatives of imaging techniques. Sugino et al. (2010) divided patients who underwent minimally invasive parathyroidectomy into two groups, depending on the determination or not of the ioPTHi. The overall cure rate increased from 93.1%, in the group without ioPTHi determination, to 97.5%, in the group with ioPTHi. These authors concluded that although preoperative localization studies are accurate and essential, ioPTHi monitoring improves the cure rate. The ioPTHi monitoring is a valuable adjunct to achieve adequate intraoperative decision-making, recognizing and resecting additional image-negative hyperfunctioning lesions.

Finally, as mention before, it is a useful tool to detect false positives of the gamma probe in patients with concomitant thyroid pathology (García-Talavera et al., 2010).

### 3.3 Controversy on the ioPTHi usefulness

At the beginning, the use of the ioPTHi was considered as a tool with a low rate of failures, but in the last few years several investigators have reported an important rate of inadequate drop of ioPTHi levels in the presence of persistent hyperfunctioning parathyroid tissue, especially in cases of double adenomas.

Hacıyanlı et al. (2003) support that ioPTHi does not reliably predict double adenomas. The same conclusion was made by Gauger et al. (2010), who reviewed 20 cases of double adenomas identified at bilateral neck exploration, measuring ioPTHi although it was not used to guide surgical decision making. They found that in 55% of the cases, using ioPTHi to make a decision on the removal of all abnormal parathyroid tissue would have resulted in failure to detect the second adenoma. Siperstein et al. (2004) also studied ioPTHi in 350 patients who had been underwent bilateral neck exploration after preoperative <sup>99m</sup>Tc-MIBI scintigraphy and ultrasonography. If a unilateral exploration based on the imaging test had been performed, ioPTHi level would have failed to predict the presence of multiglandular disease in 9% of patients. Multiglandular disease would have been missed in 15% of patients if a MIP had been performed.

However, there are a lot of publications advocating for the use of this technique to improve the success of parathyroidectomy. Furthermore, ioPTHi determination has been reported as the most accurate predictor of multiglandular disease (Sugg et al., 2004). In a smaller series, Stratmann et al. (2002) found that the ioPTHi measurement accurately predicted the presence of multiglandular disease in 8 out of 8 patients with PHPT suspected of having a solitary adenoma on preoperative MIBI scintigraphy. Kandil et al. (2009) studied 47 patients with double adenomas and concluded that ioPTHi monitoring accurately predicted the success of parathyroidectomy in 98% of patients with double adenomas.

In our experience, as we previously mentioned, the ioPTHi determination is a valuable method to detect FN of the gamma probe due to multiglandular disease. Furthermore, in association with the scintigraphy, it improved the success rate in our study from 79% to 94% (Table 1). Despite this fact, we agree with other authors that the ioPTHi technique is not without errors.

### 3.4 Causes of failures in the ioPTHi technique

Several factors have been associated to the inadequate drop in ioPTHi levels. Some authors have reported false positive decrease in ioPTHi levels, as Zetting et al. (2002), who described the case of a recurrence hyperparathyroidism due to the existence of a suppressed double adenoma. The theoretical explanation is that in rare occasions smaller abnormal parathyroid glands can be suppressed and may become hypersecretory if they are left *in situ* after surgical removal of the larger gland. Regarding this matter, Sitges-Serra et al. (2010) reported that two-thirds of the patients with double adenomas showed a false-positive decline of ioPTHi after resection of the first adenoma. This appears to be due to the initial removal of the larger lesion when there are marked differences between the two enlarged glands. They think that extending ioPTHi sampling for 15-20 minutes after excision of the first adenoma (in search of a normalization of PTH levels) would be a good choice. Nevertheless, due to the low prevalence of double adenomas, adopting other criteria to define a biochemical intraoperative cure would lead to make surgery more tedious for more than 95% of patients with single gland disease submitted to limited surgery (it prolongs the operating room waiting time too much and may lead to spurious reconversions into bilateral neck exploration). Gordon et al. (1999) support these results; their group, on the validation of the quick ioPTHi assay, included 14 patients with double adenoma. These authors described that 4 of 14 patients with double adenoma cases showed a greater than 50% decrease in ioPTHi after resection of the first lesion, which was always heavier than the second.

Carneiro et al. (2003) specifically analyzed the false positive results in the decrease of ioPTHi in this series. One of them involved an undiagnosed parathyroid cancer, another was due to a verified technical assay error, and the third case had a very high pre-excision level from an intraoperative rupture of a parathyroid cyst.

Another cause of failure in the ioPTHi determination is the existence of false negative decrease of the ioPTHi. Yang et al. (2001) described a possible cause; they reported a spike in parathyroid hormone level during exploration caused by the mobilization of the adenoma. This spike can be unrecognized if baseline values are measured during the early stages. Due to this fact, they changed their protocol by measuring ioPTHi at the time of neck incision, at the time of complete removal of the adenoma, and 10 minutes after excision.

Some authors (Chen et al., 2005) related elder patients and high levels of creatinine to the lack of decrease of ioPTHi after a successful excision. In these cases, the half-life of iPTH may be greater than the 3 to 4 minutes, valid for the majority of patients.

## 4. Choice among techniques

There are different views regarding the association of intraoperative tools (frozen section, the gamma probe and the ioPTHi determination) during limited parathyroidectomy.

Some (as Jacobson et al., 2004) believe that selected patients with PHPT due to single-gland disease and unequivocally positive preoperative MIBI scintigraphy can safely and successfully be managed with a focused unilateral cervical exploration without either ioPTHi determination or use of the gamma probe. Smith et al. (2009) think, as well, that ioPTHi determination may be eliminated in MIP surgery in a carefully selected group of patients who have preoperative localizing MIBI scintigraphy with concordant US. In their experience, 2 concordant preoperative localization studies result in a 97% rate of successfully performed MIP *vs* an 80% success rate with one positive study alone. In the other hand, adding an ioPTHi measurement in patients with concordant preoperative studies provided only a minor benefit. If the ioPTHi were eliminated in these patients, it would be possible to reduce the cost associated with laboratory fees, operating room time, and anaesthesia time.

Other authors use the ioPTHi determination with previous preoperative imaging techniques. For instance, Bergson et al. (2004) think that preoperative MIBI scintigraphy and ioPTHi measurement allow a successful MIP, with cure rates comparable to traditional results using bilateral neck exploration. In their experience, the ioPTHi allows an accurate identification of multiglandular disease in 88% of cases.

Sidell et al. (2010) support the use of the ioPTHi and frozen section during parathyroidectomy because they help to maximize patient safety, improve confidence, and minimize operative failure.

There are some investigators who support the use of the gamma probe alone, as Murphy & Norman (1999). They state that, if a tissue is removed from a patient with HPTP who has a positive MIBI scintigraphy and this tissue contains more than 20% of the radioactivity in the operative basin, frozen section analysis do not need to be performed and the intraoperative measurement of parathyroid hormone is unnecessary. According to these authors, the use of the ioPTHi is costly, time consuming, applicable primarily to patients with adenomas, and still with errors. In this group, we could include Goldstein et al. (2003) who reported an excellent cure rate for the radioguided MIP technique with a preoperative positive MIBI scintigraphy without ioPTHi determination. But these authors, consider the association of ioPTHi useful in some occasions, such as complicated reoperative settings or suspicion of multiglandular disease.

There are several authors who trust in the association of techniques to achieve the highest success. Dackiw et al. (2000) would always combine preoperative MIBI imaging with the gamma probe and the ioPTHi determination when performing anatomically directed operations, including minimally invasive operations, to help ensure postoperative resolution of hypercalcemia. They claim that the intraoperative gamma probe localization is particularly useful in assisting in the identification of ectopic parathyroid adenomas, whereas the ioPTHi assists in the identification and management of patients with multiglandular disease. Ugur et al. (2004) compared the *ex vivo* and *in vivo* counting to frozen section, and their conclusion is that the two former methods are more accurate than the latter. On the other hand, they consider the quick ioPTHi assay very helpful, especially in asymmetric hyperplasia cases, because large hyperplastic glands may produce radioactivity countings as high as adenomas do. Chen et al. (2003) found that radioguided surgery facilitated intraoperative localization (especially of ectopically located glands), allowed to give up intraoperative frozen section analysis, and was equally effective for adenomatous and hyperplastic parathyroid glands.



Nevertheless, they believe that the radioguided techniques complement the ioPTHi assay but cannot replace it. In a later publication, these authors (Chen et al., 2005) compared the use of MIBI scanning, radioguided surgery and ioPTHi determination. ioPTHi reached the highest sensitivity (99%), positive predictive value (99.6%) and accuracy (98%). The gamma probe obtained 93%, 88% and 83%, respectively, whereas the scintigraphy achieved 84%, 81%, and 72%, respectively. In the EANM guidelines (Hindié et al., 2011), it is stated that, due to the good ability of the gamma probe to identify hyperactive parathyroid tissue, the probe can replace frozen section, but in order to confirm the complete parathyroid removal the gamma probe should be used in association with ioPTHi measurements. We support as well the combined use of techniques (scintigraphy, gamma probe and ioPTHi), reaching a success rate of 98% (see Table 1).

## 5. Portable gamma camera

Another useful tool in minimally invasive surgery which still requires more experience and validation is the portable gamma camera. The first portable gamma camera was patented by Soluri et al. (1997) and validated by Scopinaro et al. (1999) for sentinel lymph node biopsy in breast cancer patients. Nowadays these cameras have become smaller and lighter. They have a high degree of sensitivity and spatial resolution, with values approximated to those of the gamma probe. Moreover, dynamic real-time images can be taken, including lateral images of the neck and mediastinal space.

Fuji et al. (2011) used a handheld semiconductor-based gamma camera. They included eleven patients with PHPT and positive scintigraphy, acquiring images before skin incision, after adenoma localization, after adenoma excision, and *ex vivo* imaging of the specimen. The gamma camera allowed them to intraoperatively identify and remove parathyroid adenomas in all cases.

Ortega et al. (2007) made an intra-operative comparison of the utility of a conventional intra-operative probe and a new-generation portable gamma camera. In addition, they determined ioPTHi so as to verify the total extirpation of parathyroid tissue. Consequently, the portable camera could be used together with the intra-operative probe or perhaps it could replace it, as has been suggested by these authors. In a later study, Cassinello et al. (2009) included 20 patients; in 15 cases, ioPTHi was not used for intraoperatively diagnosis and the miniature gamma camera was the only diagnostic tool employed to perform the operation. All cases were successfully operated by a MIP. They concluded that the portable gamma camera can be used as complementary to the standard tools or even to replace them, at least in selected cases of single adenomas.

A possible benefit of this procedure is the application in patients with a thyroid disorder, as illustrated by Ferrer-Rebolleda et al. (2008). However, cost is its biggest disadvantage. As a result, its use would be only justified in centres with a wide range of applications (sentinel lymph node, ROLL, etc.).

## 6. Conclusion

Nowadays, thanks to the preoperative MIBI scintigraphy and the availability of intraoperative techniques, such as the gamma probe and the ioPTHi determination, MIP can be performed for the surgical treatment of PHPT. This surgical approach improves the

aesthetic results, decreases the morbidity and shortens the surgical time, hospital stay and consequently cost, achieving similar successful rates to the bilateral approach.

The benefits of these two techniques (gamma probe and ioPTHi) in bilateral neck exploration have been documented as well. They shorten surgical time and guarantee the completeness of the exeresis of the pathological glands. The general applications of these techniques are the localization of ectopic adenomas (for the gamma probe) and the detection of multiglandular disease (for the ioPTHi test) which have been reported as the main causes of persistent and recurrent PHPT in the traditional surgery. There is a certain controversy over the protocols used (doses, time from injection to surgery, percentage of decrease in ioPTHi...) and accuracy of these tools depending on the authors. Consequently, PHPT surgical treatment differs in accordance with the surgeon's preference and the availability of preoperative techniques.

A new aiding tool in radioguided surgery is the use of the portable gamma camera, combined or not, to other intraoperative techniques. This new device seems to offer good results but further investigation is needed.

## 7. References

- Aliyev, A.; Kabasakal, L.; Simsek, O.; Paksoy, M.; Halac, M. & Uslu, I. (2010). Ectopic parathyroid adenoma localized with MIBI scintigraphy and excised with guide of macroaggregated human serum albumin injection. *Clinical Nuclear Medicine*, Vol.35, No.3 (March 2010), pp. 151-153, ISSN 0363-9762
- Bergson, E.J.; Sznyter, L.A.; Dubner, S.; Palestro, C.J. & Heller, K.S. (2004). Sestamibi scans and intraoperative parathyroid hormone measurement in the treatment of primary hyperparathyroidism, *Archives of Otolaryngology- Head & Neck Surgery*, Vol.130, No.1 (Jan 2004), pp. 87-91, ISSN 0886-4470
- Berland, T.; Smith, S.L. & Huguet, K.L. (2005). Occult fifth gland intrathyroid parathyroid adenoma identified by gamma probe. *American Surgery*, Vol.71, No.3 (Mar 2005), pp. 264-266.
- Bonjer, H.J.; Bruining, H.A.; Pols, H.A.; de Herder, W.W.; Van Eijck, C.H.J.; Breeman, W.A.P.; et al. (1997). Intraoperative nuclear guidance in benign hyperparathyroidism and parathyroid cancer. *European Journal of Nuclear Medicine*, Vol.24, No.3 (March 1997), pp. 246-251, ISSN 0340-6997
- Carneiro, D.M.; Solorzano, C.C.; Nader, M.C.; Ramirez, M. & Irvin, G.L. 3<sup>rd</sup> (2003). Comparison of intraoperative iPTH assay (QPTH) criteria in guiding parathyroidectomy: which criterion is the most accurate? *Surgery*, Vol.134, No.6 (Dec 2003), pp. 973-979, ISSN 0039-6060
- Casara, D.; Rubello, D.; Cauzzo, C. & Pelizzo, M.R. (2002). 99mTc-MIBI radioguided minimally invasive parathyroidectomy: experience with patients with normal thyroids and nodular goiters. *Thyroid*, Vol.12, No.1 (Jan 2002), pp. 53-61, ISSN 1050-7256
- Casara, D.; Rubello, D.; Pelizo, M.R. & Shapiro, B. (2001). Clinical role of 99mTcO<sub>4</sub>/MIBI scan, ultrasound and intraoperative gamma probe in the performance of unilateral and minimally invasive surgery in primary hyperparathyroidism.

- European Journal of Nuclear Medicine*, Vol.28, No.9, (Sep 2001), pp. 1351-1359, ISSN 0340-6997
- Cassinello, N.; Ortega, J. & Lledo, S. (2009). Intraoperative real-time (99m)Tc-sestamibi scintigraphy with miniature gamma camera allows minimally invasive parathyroidectomy without ioPTHi determination in primary hyperparathyroidism. *Langenbeck's Archives of Surgery*, Vol.394, No.5 (Sep 2009), pp. 869-874, ISSN 0004-0010
- Chen, H.; Mack, E. & Starling, J.R. (2003). Radioguided parathyroidectomy is equally effective for both adenomatous and hyperplastic glands. *Annals of Surgery*, Vol.238, No.3 (Sep 2003), pp. 332-338, ISSN 1528-1140
- Chen, H.; Mack, E. & Starling, J.R. (2005). A comprehensive evaluation of perioperative adjuncts during minimally invasive parathyroidectomy. Which is most reliable? *Annals of Surgery*, Vol.242, No.3 (Sep 2005), pp. 375-383, ISSN 1528-1140
- Clary, B.M.; Garner, S.C.; Leight, G.S.Jr. (1997). Intraoperative parathyroid hormone monitoring during parathyroidectomy for secondary hyperparathyroidism. *Surgery*, Vol.122, No.6 (Dec 1997), pp. 1034-1038, ISSN 0039-6060
- Dackiw, A.P.B.; Sussman, J.J.; Fritsche, H.A.; Delpassand, E.S.; Stanford, P.; Hoff, A. et al. (2000). Relative contributions of Tc99m Sestamibi scintigraphy, intraoperative gamma probe detection, and the rapid parathyroid hormone assay to the surgical management of hyperparathyroidism. *Archives of Surgery*, Vol.135, No.5 (May 2000), pp. 550-557, ISSN 0004-0010
- Dewan, A.K.; Kapadia, S.B.; Hollenbeak, C.S. & Stack B.C.Jr. (2005). Is routine frozen section necessary for parathyroid surgery? *Otolaryngology-Head and Neck Surgery*, Vol.133, No.6 (Dec 2005), pp. 857-862, ISSN 0194-5998
- Ferrer-Rebolleda, J.; Sopena, P.; Estremens, P.; Guallart, F.; Reyes, M.D.; Caballero, E. et al. (2008). Aportación de una minigammacámara portátil en el tratamiento quirúrgico del hiperparatiroidismo primario. *Revista Española de Medicina Nuclear*, Vol.27, No.2, (Mar-Apr. 2008), pp. 124-127, ISSN 0212-6982
- Flynn, M.B.; Bumpous, J.M.; Schill, K. & McMasters, K.M. (2000). Minimally invasive radioguided parathyroidectomy. *Journal of the American College Surgery*, Vol.191, No.1 (Jul 2000), pp. 24-31, ISSN 1072-7515
- Friedman, M.; Gurpinar, B.; Schalch, P. & Joseph, N.J. (2007). Guidelines for radioguided parathyroid surgery. *Archives of Otolaryngology- Head & Neck Surgery*, Vol.133, No.12 (Dec 2007), pp. 1235-1239, ISSN 0886-4470
- Fujii, T.; Yamaguchi, S.; Yajima, R.; Tsutsumi, S.; Uchida, N.; Asao, T. et al. (2011). Use of a handheld, semiconductor (cadmium zinc telluride)-based gamma camera in navigation surgery for primary hyperparathyroidism. *American Surgery*, Vol.77, No.6 (Jun 2011), pp. 690-693
- García-Talavera, P.; González, C.; García-Talavera, J.R.; Martín, M.E.; Martín, M. & Gómez, A. (2010). Radioguided Surgery of primary hyperparathyroidism in a population with a high prevalence of thyroid pathology. *European Journal of Nuclear Medicine & Molecular Imaging*, Vol.37, No.11 (Nov 2010), pp. 2060-2067, ISSN: 1619-7070
- García-Talavera, P.; García-Talavera, J.R.; González, C.; Martín, M.E.; Martín, M. & Gómez, A. (2011). Efficacy of in vivo counting in parathyroid radioguided surgery

- and usefulness of its association with scintigraphy and intraoperative PTHi. *Nuclear Medicine Communications*, Vol. 32, No. 9 (Sep 2011), pp 847-85, ISSN 0143-3636
- Gauger, P.G.; Agarwall, G.; England, B.G.; Delbridge, L.W.; Matz, K.A.; Wilkinson, M.; Robinson, B.G. & Thompson, N.W. (2001). Intraoperative parathyroid hormone measurement fails to detect double parathyroid adenomas: a 2-institution experience. *Surgery*, Vol.130, No.6 (Dec 2001), pp. 1005-1010, ISSN 0039-6060
- Goldstein, R.E.; Blevins, L.; Delbeke, D. & Martin, W.H. (2000). Effect of minimally invasive radioguided parathyroidectomy on efficacy, length of stay, and cost in the management of primary hyperparathyroidism. *Annals of Surgery*, Vol.231, No.5 (May 2000), pp. 732-742, ISSN 1528-1140
- Goldstein, R.E.; Billheimer, D.; Martin, W.H. & Richards, K. (2003). Sestamibi scanning and minimally invasive radioguided parathyroidectomy without intraoperative parathyroid hormone measurement. *Annals of Surgery*, Vol.237, No.5 (May 2003), pp. 722-731, ISSN 1528-1140
- Gordon, L.; Snyder, W.H.; Wians, F.; Nwariaku, F. & Kim, L.T. (1999). The validity of quick intraoperative parathyroid hormone assay: an evaluation in seventy-two patients based on gross morphologic criteria. *Surgery*, Vol.126, No.6 (Dec 1999), pp. 1030-1035, ISSN 0039-6060
- Haciyanli, M.; Lal, G.; Morita, E.; Duh, Q.Y.; Kebebew, E. & Clark, O.H. (2003). Accuracy of preoperative localization studies and intraoperative parathyroid hormone assay in patients with primary hyperparathyroidism and double adenoma. *Journal of the American College of Surgeons*, Vol.197, No.5 (Nov 2003), pp. 739-746, ISSN 1072-7515
- Heller, H.S. & Blumberg, S.N. (2009). Relation of final intraoperative parathyroid hormone level and outcome following parathyroidectomy. *Arch Otolaryngol Head Neck Surg*, Vol.135, No.11 (Nov 2009), pp. 1103-1107, ISSN: 0886-4470
- Hindié, E.; Ugur, Ö.; Fuster, D.; O'Doherty, M.; Grassetto, G.; Ureña, P. et al. (2009). 2009 EANM parathyroid guidelines. *European Journal of Nuclear Medicine and Molecular Imaging*, Vol.36, No.7 (Jul 2009), pp. 1201-1216, ISSN 1619-7070
- Hughes, D.T.; Miller, B.S.; Doherty, G.M. & Gauger, P.G. (2011). Intraoperative parathyroid hormone monitoring in patients with recognized multiglandular primary hyperparathyroidism. *World Journal of Surgery*, Vol.35, No.2 (Feb 2011), pp. 336-341, ISSN: 0364-2313
- Inabnet, W.B. III; Kim, C.K.; Haber, R.S. & Lopchinsky, R.A. (2002). Radioguidance is not necessary during parathyroidectomy. *Archives of Surgery*, Vol.137, No.8 (Aug 2002), pp. 967-960, ISSN: 0004-0010
- Irvin, G. & Bagwell, C. (1979). Identification of histologically undetectable parathyroid hyperplasia by flow cytometry. *American Journal of Surgery*, Vol.138, N<sup>o</sup>4 (Oct 1979), pp. 567-571, ISSN 0002-9610
- Irvin, G.L. 3<sup>rd</sup>; Dembrow, V.D. & Prudhomme, D.L. (1993). Clinical usefulness of an intraoperative "quick parathyroid hormone" assay. *Surgery*, Vol.114, No.6 (Dec 1993), pp. 1019-1022, ISSN: 0039-6060



- Irvin, G.L. 3<sup>rd</sup> & Deriso, G.T. (1994). A new practical intraoperative parathyroid assay. *American Journal of Surgery*, Vol.168, No.5 (Nov 1994), pp 466-468, ISSN: 0002-9610
- Jacobson SR, van Heerden JA, Farley DR, Grant CS, Thompson GB, Mullan BP, and Curlee KJ. Focused cervical exploration for primary hyperparathyroidism without intraoperative parathyroid hormone monitoring or use of the gamma probe. *World Journal of Surgery*, Vol.28, No.11 (Nov 2004), pp. 1127-1131, ISSN 0364-2313
- Jacobson, S.R.; van Heerden, J.A.; Farley, D.R.; Grant, C.S.; Thompson, G.B.; Mullan, B.P. et al. (2004). Focused cervical exploration for primary hyperparathyroidism without intraoperative parathyroid hormone monitoring or use of the gamma probe. *World Journal of Surgery*, Vol.28, No.11 (Nov 2004), pp 1127-1131, ISSN: 0364-2313
- Jaskowiak, N.T.; Sugg, S.L.; Helke, J.; Koka, M.R. & Kaplan, E.L. (2002). Pitfalls of intraoperative quick parathyroid hormone monitoring and gamma probe localization in surgery for primary hyperparathyroidism. *Archives of Surgery*, Vol.137, No.6 (Jun 2002), pp. 659-668, ISSN: 0004-0010
- Kandil, E.; Alabbass, H.H.; Bansal, A.; Islam, T.; Tufaro, A.P. & Tufano, R.P. (2009). Intraoperative Parathyroid hormone assay in patients with primary hyperparathyroidism and double adenoma. *Archives of Otolaryngology- Head & Neck Surgery*, Vol.135, N°12 (Dec 2009) , pp. 1206-1208, ISSN 0886-4470
- McGreal, G.; Winter, D.C.; Sookhai, S.; Evoy, D.; Ryan, M.; O'Sullivan, G.C. et al. (2001). Minimally invasive, radioguided surgery for primary hyperparathyroidism, *Annals of Surgical Oncology*, Vol.8, No.10 (Dec 2001), pp. 856-860, ISSN 1068-9265
- Murphy, C. & Norman, J. (1999). The 20% rule: a simple, instantaneous radioactivity measurement defines cure and allows elimination of frozen sections and hormone assays during parathyroidectomy. *Surgery*, Vol.126, No.6 (Dec 1999), pp. 1023-1029, ISSN: 0039-6060
- Norman, J. & Chheda, H. (1997). Minimally invasive parathyroidectomy facilitated by intraoperative nuclear mapping. *Surgery*, Vol.122, No.6 (Dec 1997), pp. 998-1004, ISSN: 0039-6060
- Norman, J. & Denhan, D. (1998). Minimally invasive radioguided parathyroidectomy in the reoperative neck. *Surgery*, Vol.124, No.6 (Dec 1998), pp 1088-1092, ISSN: 0039-6060
- Nussbaum, S.R.; Thompson, A.R.; Hutcheson, K.A.; Gaz, R.D. & Wang, C.A. (1988). Intraoperative measurement of parathyroid hormone in the surgical management of hyperparathyroidism. *Surgery*, Vol.104, No.6 (Dec 1988), pp. 1121-1127, ISSN: 0039-6060
- Olson, J.; Replinger, D.; Bianco, J. & Chen, H. (2006). Ex vivo radioactive counts and decay rates of tissues resected during radioguided parathyroidectomy. *Journal of Surgery Research*, Vol.136, No.2 (Dec 2006), pp. 187-191, ISSN: 0022-4804
- Ortega, J.; Ferrer-Rebolleda, J.; Cassinello, N.; Lledo, S. (2007). Potential role of a new hand-held miniature gamma camera in performing minimally invasive parathyroidectomy. *European Journal of Nuclear Medicine and Molecular Imaging*, Vol.34, No.2 (Feb 2007), pp 162-164. ISSN 1619-7070




- Papathanassiou, D.; Flament, J.B.; Pochart, J.M.; Patey, M.; Marty, H.; Liehn, J.C. et al. (2008). SPECT/CT in localization of parathyroid adenoma or hyperplasia in patients with previous neck surgery. *Clinical Nuclear Medicine*, Vol.33, No.6 (Jun 2008), 394-397, ISSN: 0363-9762
- Riss, P.; Kaczirek, K.; Heinz, G.; Bieglmayer, C. & Niederle, B. (2007). A "defined baseline" in PTH monitoring increases surgical success in patients with multiple gland disease. *Surgery*, Vol.142, No.3 (Sep 2007), pp. 398-404, ISSN: 0039-6060
- Rubello, D.; Al-Nahhas, A.; Mariani, G.; Gross, M.D.; Rampin, L. & Pelizzo, M.R. (2006). Feasibility and longterm results of focused radioguided parathyroidectomy using a low 37 MBq (1 mCi) 99mTcsestamibi protocol. *International Seminars in Surgical Oncology*, Vol.3 (Sep 2006), p. 30, ISSN: 1477-7800
- Rubello, D.; Casara, D.; Giannini, S.; Piotto, A.; de Carlo E.; Muzzio, P.C. & Pelizzo, M.R. (2003). Importance of radioguided minimally invasive parathyroidectomy using hand- help gammaprobe and low 99mTc MIBI dose. Technical considerations and long- term clinical result. *Quarterly Journal of Nuclear Medicine*, Vol.47, No.2 (Jun 2003), pp. 129-138, ISSN: 0392-0208
- Rubello, D.; Casara, D. & Pelizzo, M.R. (2003). Symposium on parathyroid localization. Optimization of peroperative procedures. *Nuclear Medicine Communications*, Vol.24, No.2 (Feb 2003), pp. 133-140, ISSN: 0143-3636
- Rubello, D.; Mariani, G.; Al-Nahhas, A. & Pelizzo, M.R. (2006). Minimally invasive radioguided parathyroidectomy: long-term results with the "low 99mTc-sestamibi protocol". *Nuclear Medicine Communications*, Vol.27, No.9 (Sep 2006), pp 790-713, ISSN: 0143-3636
- Scopinaro, F.; Di Luzio, E. & Pani, R. (1999). Sentinel lymph node biopsy in breast cancer: use of an imaging probe. In: Limouris, G.S.; Shukla, S.K. & Biersack, H.J., eds. Radionuclides for lymph nodes. Athens: Mediterranean Publishers, 1999; p. 60-5.
- Sebag, F., Shen, W.; Brunaud, L.; Kebebew, E.; Duh, Q.Y. & Clark, O.H. (2003). Intraoperative parathyroid hormone assay and parathyroid reoperations. *Surgery*, Vol.134, No.6 (Dec 2003), pp 1049-1055, ISSN: 0039-6060
- Sidell, D.; Wang, J. & Sercarz, J. (2010). Spurious decline in intraoperative parathyroid hormone: false positives in parathyroid surgery. *American Journal of Otolaryngology*, Vol.31, No.6 (Nov-Dec 2010), pp. 479-481, ISSN 0196-0709
- Siperstein, A.; Berber, E.; Mackey, R.; Alghoul, M.; Wagner, K. & Milas, M. (2004). Prospective evaluation of sestamibi scan, ultrasonography, and rapid PTH to predict the success of limited exploration for sporadic primary hyperparathyroidism. *Surgery*, Vol.136, No.4 (Oct 2004), pp 872-880, ISSN 0039-6060
- Sitges-Serra, A.; Díaz-Aguirregoitia, F.J.; de la Quintana, A.; Gil-Sánchez, J.; Jimeno, J.; Prieto, R. et al. (2010). Weight difference between double parathyroid adenomas is the cause of false positive ioPTHi test after resection of the first lesion. *World Journal of Surgery*, Vol.34, No.6 (Jun 2010), pp 1337-1342, ISSN 0364-2313
- Smith, N.; Magnuson, J.S.; Vidrine, D.M.; Kulbersh, B. & Peters, G.E. (2009). Minimally invasive parathyroidectomy. Use of intraoperative parathyroid assays after 2

- preoperative localization studies. *Archives of Otolaryngology- Head & Neck Surgery*, Vol.135, No.11 (Nov 2009), pp 1108-1111, ISSN: 0886-4470
- Solórzano, C.C.; Mendez, W.; Lew, J.I.; Rodgers, S.E.; Montano, R.; Carneiro-Pla, D.M. & Irvin, G.L. 3rd. (2008). Long-term outcome of patients with elevated parathyroid hormone levels after successful parathyroidectomy for sporadic primary hyperparathyroidism. *Archives of Surgery*, Vol.143, No.7 (Jul 2008), pp. 659-663, discussion p. 663, ISSN 0004-0010
- Soluri A et al, inventors. Miniaturized gamma camera with very high spatial resolution. Italian patent RM97A000233, April 23,1997; US patent 6 242 744 B1, June 5, 2001.
- Stratmann, S.L.; Kuhn, J.A.; Bell, M.S.; Preskitt, J.T.; O'Brien, J.C.; Gable, D.R.; Stephens, J.S. & McCarty, T.M. (2002). Comparison of quick parathyroid assay for unilateral and multiglandular disease. *American Journal of Surgery*, Vol.184, No.6 (Dec 2002), pp. 578-581, ISSN 0002-9610
- Sugg, S.L.; Krzywda, E.A.; Demeure, M.J. & Wilson, S.D. (2004). Detection of multiple gland primary hyperparathyroidism in the era of minimally invasive parathyroidectomy. *Surgery*, Vol.136, No.6 (Dec 2004), pp. 1303-1309, ISSN: 0039-6060
- Sugino, K.; Ito, K.; Nagahama, M.; Kitagawa, W.; Shibuya, H.; Ohkuwa, K. et al. (2010). Minimally invasive surgery for primary hyperparathyroidism with or without intraoperative parathyroid hormone monitoring. *Endocrine Journal*, Vol.57, No.11, pp. 953-958, ISSN 0918-8959
- Takeyama, H.; Shioya, H.; Mori, Y.; Ogi, S.; Yamamoto, H.; Kaoto, N. et al. (2004). Usefulness of radio-guided surgery using Technetium-99m Methoxyisobutylisonitrile for primary and secondary Hyperparathyroidism. *World Journal of Surgery*, Vol.28, No.6 (Jun 2004), pp. 576-582, ISSN 0364-2313
- Thompson, G.B. ; Grant, C.S. ; Perrier, N.D. et al. Reoperative (1999). Parathyroid surgery in the era of sestamibi scanning and intraoperative parathyroid hormone monitoring. *Archives of Surgery*, Vo.134, No.7 (Jul 1999), pp. 699-705, ISSN 0004-0010
- Tibblin, S.; Bondeson, A.G. & Ljungberg, O. (1982). Unilateral parathyroidectomy in hyperparathyroidism due to single adenoma. *Annals of Surgery*, Vol.195, No.3 (March 1982), pp 245-252, ISSN 1528-1140
- Ugur, Ö.; Bozkurt, M.F.; Hamaloglu, E.; Sokmensuer, C.; Etikan, I.; Ugur, Y. et al. (2004). Clinicopathologic and radiopharmacokinetic factors affecting gamma probe-guided parathyroidectomy. *Archives of Surgery*, Vol.139, No.11 (Nov 2004), pp 1175-1179, ISSN 0004-0010
- Ugur, Ö.; Kara, P.Ö.; Bozkurt, M.F.; Hamaloglu, E.; Tezel, G.G.; Salanci, B.V, et al. (2006). In vivo characterisation of parathyroid lesions by use of gamma probe: comparison with ex vivo count method and frozen section results. *Otolaryngology-Head and Neck Surgery*, Vol.134, No.2 (Feb 2006), pp. 316-320, ISSN 0194-5998
- Weigel, T.L.; Murphy, J.; Kabbani, L.; Ibele, A. & Chen, H. (2005). Radioguided thoracoscopic mediastinal parathyroidectomy with intraoperative parathyroid hormone testing. *The Annals of Thoracic Surgery*, Vol.80, No.4 (Oct 2005), pp. 1262-1265, ISSN 0003-4975
- Yang, G.P.; Levine, S. & Weigel, R.J. (2001). A spike in parathyroid hormone during neck exploration may cause a false negative intraoperative assay result. *Archives of Surgery*, Vol.136, No.8 (Aug 2001), pp. 945-949, ISSN 0004-0010

Zettinig, G.; Kurtaran, A.; Prager, G.; Kaserer, K.; Dudczak, R. & Niederle, B. (2002). "Suppressed" double adenoma -a rare pitfall in minimally invasive parathyroidectomy. *Hormone Research.*, Vol.57, No.1-2, pp. 57-60, ISSN: 0301-0163

IntechOpen

IntechOpen



## **Hyperparathyroidism**

Edited by Dr. Gonzalo Diaz Soto

ISBN 978-953-51-0478-0

Hard cover, 96 pages

**Publisher** InTech

**Published online** 04, April, 2012

**Published in print edition** April, 2012

This book is the result of the collaboration between worldwide authorities of different specialities in hyperparathyroidism. It aims to provide a general but deep view of primary/secondary and tertiary hyperparathyroidism, from a physiological basis to hyperparathyroidism in hemodialyzed patients, as well as new treatment approaches, techniques and surgical scenarios. We hope that the medical and paramedical researchers will find this book helpful and stimulating. We look forward to sharing knowledge of hyperparathyroidism with a wider audience.

### **How to reference**

In order to correctly reference this scholarly work, feel free to copy and paste the following:

Paloma Garcia-Talavera and Jose Ramon Garcia-Talavera (2012). Radio-Guided Surgery and Intraoperative iPTH Determination in the Treatment of Primary Hyperparathyroidism, Hyperparathyroidism, Dr. Gonzalo Diaz Soto (Ed.), ISBN: 978-953-51-0478-0, InTech, Available from:

<http://www.intechopen.com/books/hyperparathyroidism/radio-guided-surgery-and-intraoperative-iphth-determination-in-the-treatment-of-primary-hyperparathyroidism>

# **INTECH**

open science | open minds

### **InTech Europe**

University Campus STeP Ri  
Slavka Krautzeka 83/A  
51000 Rijeka, Croatia  
Phone: +385 (51) 770 447  
Fax: +385 (51) 686 166  
[www.intechopen.com](http://www.intechopen.com)

### **InTech China**

Unit 405, Office Block, Hotel Equatorial Shanghai  
No.65, Yan An Road (West), Shanghai, 200040, China  
中国上海市延安西路65号上海国际贵都大饭店办公楼405单元  
Phone: +86-21-62489820  
Fax: +86-21-62489821

© 2012 The Author(s). Licensee IntechOpen. This is an open access article distributed under the terms of the [Creative Commons Attribution 3.0 License](#), which permits unrestricted use, distribution, and reproduction in any medium, provided the original work is properly cited.

IntechOpen

IntechOpen