

# We are IntechOpen, the world's leading publisher of Open Access books Built by scientists, for scientists

**4,800**

Open access books available

**122,000**

International authors and editors

**135M**

Downloads

Our authors are among the

**154**

Countries delivered to

**TOP 1%**

most cited scientists

**12.2%**

Contributors from top 500 universities



**WEB OF SCIENCE™**

Selection of our books indexed in the Book Citation Index  
in Web of Science™ Core Collection (BKCI)

Interested in publishing with us?  
Contact [book.department@intechopen.com](mailto:book.department@intechopen.com)

Numbers displayed above are based on latest data collected.

For more information visit [www.intechopen.com](http://www.intechopen.com)



# Testicular Germ Cell Tumours – A European and UK Perspective

Nikhil Vasdev and Andrew C. Thorpe  
*Department of Urology  
Freeman Hospital  
Newcastle upon Tyne  
United Kingdom*

## 1. Introduction

Testicular Germ Cell tumours (TGCTs) account for between 1% and 1.5% of male neoplasms and 5% of urological tumours in general, with 3-10 new cases occurring per 100,000 males/per year in Western society (1-3). Testicular germ cell tumours (TGCTs) are the most frequent solid tumour of Caucasian adolescents and young adult males and are a diverse group of neoplasms that can also present in extragonadal sites. Within Europe, there has been a general increase in the incidence of TGCTs noted initially in the 1970s and 1980s (4). Over recent years the incidence of TGCTs has risen markedly, making it imperative to understand how and why these tumours arise.

In this book chapter we present the incidence and clinical presentation, classification, epidemiology and aetiology, molecular developments, tumour markers, staging, management strategies including the role of chemotherapy, radiotherapy and Reteroperitoneal lymph node dissection (RPLND) and follow up protocol followed in the United Kingdom (UK) and Europe as per the 2011 European Association of Urology (EAU) guidelines.

## 2. Incidence and clinical presentation

Testicular Germ Cell tumours (TGCTs) are broadly divided into Seminomas, which resemble primordial germ cells (PGCs) and Non-Seminoma, which are either undifferentiated (embryonal carcinoma) or differentiated (exhibiting a degree of embryonic (teratoma) or extra-embryonic (yolk sac choriocarcinoma) pattern (5). The commonest age range of presentation of TGCTs is between 20-45 years. Patients rarely tend to be younger than 15 years or older than 60 years. Based on the type of TGSTs, Seminomas typically arise later in life, with a mean age at presentation of 35 years of age compared with 25 years of age for non-seminomas. Although these morphologies and differences in age at presentation could suggest underlying differences between seminomas and non-seminomas, several lines of evidence support a common underlying pathogenesis. Approximately 15% of TGCTs are mixed tumours that contain both seminoma and non-seminoma elements (6).

The commonest presentation of TGCTs is a painless unilateral mass in the scrotum when the patient feels the mass itself. In other situations the patient has an incidental mass diagnosed when presenting with other symptoms of a concomitant testicular pathology such as epididymitis. It is interesting to note that 10% of patients presenting with epididymitis present can present with a TGCTs (1, 2). Another common symptom of presentation is testicular pain (1) seen in up to 20% of patient with TGCTs. In certain cases up to 27% of patients have local pain which could be attributed to a degree of local invasion (1). Up to 1-2% of TGCTs present bilaterally. Paraneoplastic symptoms such as gynecomastia can be seen in up to 7% of patients at initial presentation. Additional symptoms include lower back pain and loin pain (1, 2).

When a patient presents with a testicular mass it is extremely important to elicit a detailed history which includes duration of symptoms, whether the mass is painful or painless, change in size of mass, sexual history, concomitant lower urinary tract symptoms, previous history of surgery, infertility or mumps and family history of testicular cancer. There is evidence to suggest that delay in presentation is more of a problem than delay in referral and this has prompted some authors to suggest that a public education campaign might be helpful (7,8).

The radiological investigation of choice for testicular cancer is an ultrasound throughout Europe. The main advantage lies with the fact that an ultrasound is non radiation exposure scan and is relatively inexpensive. The current sensitivity and specificity of an ultrasound of testis is 100% (9). In patients with an equivocal diagnosis a Magnetic resonance imaging (MRI) offers a sensitivity of 100% and a specificity of 95-100% (10), but its high cost does not justify its use for diagnosis.

### 3. Classification

As the 2011 European Association of Urology (EAU) guidelines testicular cancer is classified according to the 2004 World health organization (WHO) guidelines (11). From the perspective of this book chapter we will confine our discussion to Testicular Germ Cell Tumours only.

1. Germ cell tumours
  - Intratubular germ cell neoplasia, unclassified type (IGCNU)
  - Seminoma (including cases with syncytiotrophoblastic cells)
  - Spermatocytic seminoma (mention if there is sarcomatous component)
  - Embryonal carcinoma
  - Yolk sac tumour
  - Choriocarcinoma
  - Teratoma (mature, immature, with malignant component)
  - Tumours with more than one histological type (specify percentage of individual components)
2. Sex cord/gonadal stromal tumours
  - Leydig cell tumour
  - Malignant Leydig cell tumour
  - Sertoli cell tumour
    - lipid-rich variant
    - sclerosing
    - large cell calcifying

- Malignant Sertoli cell tumour
  - Granulosa cell tumour
    - adult type
    - juvenile type
  - Thecoma/fibroma group of tumours
  - Other sex cord/gonadal stromal tumours
    - incompletely differentiated
    - mixed
  - Tumours containing germ cell and sex cord/gonadal stromal (gonadoblastoma)
3. Miscellaneous non-specific stromal tumours
- Ovarian epithelial tumours
  - Tumours of the collecting ducts and rete testis
  - Tumours (benign and malignant) of non-specific stroma.

#### 4. Epidemiology and aetiology

The Epidemiology and Aetiology of TGCTs has evolved over the past two decades.

##### 4.1 Age

In the paediatric population i.e., patients  $\leq 16$  years, the commonest form of Testicular Tumours are Mature teratomas, rhabdomyosarcoma, epidermoid cyst, yolk sac and germ cell tumours. The commonest age group of patients affected with TGCTs is between 20-45 years. Teratomas are common between the age of 20-35 years while seminomas are more common between the ages of 25-45 years. In men above the age of 60 years the commonest tumour is a lymphoma.

##### 4.2 Cryptorchidism

When patients present with cryptorchidism, there is risk of development of testicular tumour on both the effected side and contralateral side in the long term. The risk of TGCT in the Undescended Testis (UDT) is increased by 4 - 13 , with up to 7-10% of Testicular Cancers developing in UDT (12). There is a 5-10% risk of developing testicular cancer in the contralateral testis in those with a history of UDT (13). Premalignant changes within the UDT commence by the age of 3 years. However, an early orchidopexy does not completely eliminate the risk of developing testicular cancer in the long term.

##### 4.3 Intratubular Germ Cell Neoplasia (IGCNU)

Intratubular germ cell neoplasia (IGCNU) is also known as carcinoma *in situ* (CIS) of the testis. The incidence of IGCNU in the overall population is 0.9%. Intratubular germ cell neoplasia is defined as a pre-invasive testicular germ cell lesion and is now believed an important precursor of TGCTs. The only TGCT not associated with IGCNU is a spermatocytic seminoma. When IGNU is present, the probability of progression to TGCTs increases by 50% over a duration of 5 years. At 7 years, the cumulative probability of developing a TGCTs increased to 70% (14).

The incidence of IGCNU in the contralateral testis in patients with TGCTs is 5-9%. The incidence however rises to 34% when the primary TGCTs has been diagnosed before the age

of 40 years and the testicular volume is less than 12 ml. In both the above mentioned scenarios, the EAU guidelines recommend a biopsy of the contralateral testis. It is important to note that the presence of IGCNU in the ipsilateral testis does not have any bearing on the patient's overall prognosis. Risk factors for IGCNU include cryptorchidism (UDT), extra-gonadal germ cell tumour, previous or contralateral TGCT (5%), atrophic testicle with a volume of less than 12 ml, early age of diagnosis of TGCTs i.e.,  $\leq 40$  years, 45XO karyotype, Klinefelter's syndrome and infertility. Once IGCNU is diagnosed, local radiotherapy is the treatment of choice in solitary testis. Because this may produce infertility, the patient must be carefully counselled before treatment commences.

#### **4.4 Maternal oestrogen exposure**

Maternal Oestrogen Exposure (MOE) increases during pregnancy and hence increases the risk of cryptorchidism and TGCT in the male offspring. The MOE with diethylstilboestrol increases the risk of TGCTs by a relative risk of 2.8 - 5.3% (13).

#### **4.5 Subfertility**

A history of subfertility and poor quality semen analysis increases the risk of testicular cancer by up to 1.6 times and from the Surveillance Epidemiology and End Results database by 20 times (14).

#### **4.6 Family history**

Familial history of testicular tumours among first-grade relatives (father/brothers) has been associated with isochromosome of the short arm of chromosome 12 - i(12p) (15).

#### **4.7 Additional factors**

Additional factors such as tallness, previous history of Marijuana exposure, vasectomy, trauma, mumps and Human Immunodeficiency Virus (HIV) infection continue to be evaluated (13-15).

### **5. Genetic and cellular markers**

Current research has identified deregulation in the pluripotent programme of fetal germ cells (identified by specific markers such as M2A, C-KIT and OCT4/NANOG) is probably responsible for the development of IGCNU and germ cell neoplasia. There is overlap in the development to seminoma and embryonal carcinoma as shown by genomewide expression analysis and detection of alpha-fetoprotein (AFP) mRNA in some atypical seminoma (16,17). Continued genome wide screening studies and gene expression analysis data suggest testis cancer specific gene mutations on chromosomes 4, 5, 6 and 12 (namely expressing SPRY4, kit-Ligand and Synaptopodin) (18-20). Intratubular germ cell neoplasia shows alterations in the p53 in up to 66% of cases.

Newer developments continue to be made with regards to further molecular profiling of TGCTs. The current molecular developments include characterization of newer markers such as MAGEC2 expression. This newer marker allows a reliable distinction of seminoma

from embryonal carcinomas. Therefore, MAGEC2 represents an additional tool for the differential diagnosis of testicular germ cell tumours (21).

## 6. Serum markers for TGCTs

For the successful management of TGCTs it is crucial to understand the molecular details, half lives and clinical applications of testicular tumour markers. In clinical practice with Europe and the UK, the three common tumour markers used include Alpha-fetoprotein (AFP),  $\beta$ - human chorionic gonadotrophin ( $\beta$ -HCG) and lactate dehydrogenase (LDH). All testicular tumour markers contribute to the patients diagnosis and more importantly to the final prognosis. When a patient is diagnosed with a TGCTs, tumour markers will be elevated in 51% of cases (22).

Alpha-fetoprotein (AFP) is expressed by trophoblastic elements within 50-70% of non-seminomatous germ cell tumour (NSGCT) and yolk sac tumours. In patients with an elevated AFP with Seminoma alone, this raises the suspicion of the presence of Non-seminomatous elements. The half life of AFP is 5-7 days and the normal serum levels are <10 ng/ml.  $\beta$ - human chorionic gonadotrophin ( $\beta$ -HCG) is produced by syntiotrophoblast elements. In patients with choriocarcinomas,  $\beta$ -HCG is elevated in 100% of cases. From the perspective of other TGCTs,  $\beta$ -HCG is elevated in 40% of cases of NSGCT and 10% of Seminomas. The half life of  $\beta$ -HCG is 24-36 hours and normal serum levels are < 5mIU/ml. About 90% of non-seminomatous tumours present with a rise in one or two of the markers.

Lactate dehydrogenase (LDH) is a less specific marker and is an ubiquitous enzyme elevated in serum from various causes, therefore is less specific. It is elevated in 10-20% of seminomas but may be elevated in 80% of patients with advanced testicular cancer (23). Other markers studied include Placental alkaline phosphatase (PLAP), which may be of value in monitoring patients with pure seminoma. placental alkaline phosphatase (PLAP) is a foetal enzyme and may be falsely elevated in smokers. Cytogenetic and molecular markers are available in specific centres, but at present only contribute to research studies. Measurement of serum AFP, hCG and LDH is mandatory, while that of PLAP is optional.

Testicular tumour serum markers are normally measured when a patient presents with a TGCT clinically. In Europe the Testicular tumour markers are measured 1-2 weeks following radical orchidectomy. The testicular tumour markers play an important role in assessing response to treatment and follow up. The presence of normal testicular tumour markers prior to orchidectomy does not normally exclude the presence of micrometastatic disease. However, the persistence of testicular tumour markers following post radical inguinal orchidectomy may occur in patients with hepatic dysfunction, hypogonadotropism and most importantly in metastatic disease.

It is also important to note that other malignancies may cause an elevation of testicular tumour markers. Liver, pancreatic, gastric and lung malignancies may cause an elevated AFP level. Pancreatic, liver, gastric, lung, breast, kidney and bladder cancer may cause an elevated  $\beta$ -HCG level. Prior to commencing chemotherapy all tumour markers must be performed to classify patients according to the International Germ Cell Cancer Collaborative Group (IGCCCG) risk classification.

## 7. Staging

Once a patient is diagnosed with a TGCTs the patient is staged with a thorough history and clinical examination. In the patients history it is important to ask the following questions with regards to the testicular lump. The crucial points in the history include the duration of symptoms, whether the lump is painful or painless, change in size of the lump, previous surgical history of UDT, sexual history, history of lower urinary tract symptoms and family history. Clinical examination includes assessment of supraclavicular lymph node, chest examination and abdominal examination for inguinal lymph nodes. At this stage a full set of Testicular tumour markers is performed which includes serum AFP,  $\beta$ -hCG and LDH is mandatory, while that of PLAP is optional. In cases of disseminated disease and life-threatening metastases, it is current practice to start with up-front chemotherapy, and orchidectomy may be delayed until clinical stabilisation has occurred.

In patients with a suspected testicular mass a radical inguinal orchidectomy is performed. The main principal of this procedure lies with exteriorisation of the testicle within its tunics. Prior to mobilization of the testis and cord, the cord is isolated and clamped to allow control of the draining lymphatics in order to minimize spillage and metastatic spread. If the diagnosis is not clear, a testicular biopsy (an enucleation of the intraparenchymal tumour) is taken for frozen section histological examination.

When the testicle is sent for pathological analysis, the EAU 2011 guidelines recommend a mandatory assessment of the specimen for the following features as these features further help prognosticate the patients outcome. The features include :-

1. Macroscopic features: side, testis size, maximum tumour size, and macroscopic features of epididymis, spermatic cord, and tunica vaginalis.
2. Sampling: a 1 cm<sup>2</sup> section for every centimetre of maximum tumour diameter, including normal macroscopic parenchyma (if present), albuginea and epididymis, with selection of suspected areas. At least one proximal and one distal section of spermatic cord plus any suspected area.
3. Microscopic features and diagnosis: histological type (specify individual components and estimate amount as percentage) according to WHO 2004 (11):-
  - a. Presence or absence of peri-tumoural venous and/or lymphatic invasion;
  - b. Presence or absence of albuginea, tunica vaginalis, rete testis, epididymis or spermatic cord invasion;
  - c. Presence or absence of intratubular germ cell neoplasia (IGCNU) in non-tumour parenchyma intratubular germ cell neoplasia.
  - d. pT category according to Tumour Node Metastasis (TNM) 2009.
  - e. Immunohistochemical studies: in seminoma and mixed germ cell tumour, AFP and hCG.

Following radical inguinal orchidectomy, the main aim of clinical staging is to determine whether the patient has metastatic or occult disease at the time of presentation. The investigations of choice to determine the above and accurately stage the TGCTs at presentation include the post-orchidectomy half-life kinetics of serum tumour markers; the status of retroperitoneal and supraclavicular lymph nodes, and the liver; the presence or absence of mediastinal nodal involvement and lung metastases; the status of brain and bone, if any suspicious symptoms are present. At this point all patients must have a serial

testicular tumour markers measured and a thorough assessment of the retroperitoneum staging CT of the Chest, Abdomen and Pelvis. Retroperitoneal and mediastinal lymph nodes are best assessed by means of a CT scan. The supraclavicular nodes are best assessed by physical examination.

Hence, in Europe and the UK all patients with newly diagnosed TGCTs have the following investigations performed:-

- a. Serum testicular tumour markers (AFP,  $\beta$ -hCG and LDH)
- b. CT - Chest, Abdomen and Pelvis
- c. Ultrasound Testis (Bilateral)

A bone scan is organized in patients with suspected advanced metastatic disease. A Brain CT is organized in patients in case of symptoms and patients with metastatic disease with multiple lung metastases and high beta-hCG levels. In some centres a detailed hormonal profile (Serum Testosterone, FSH, LH) and semen analysis is performed.

In all patients undergoing a radical inguinal orchidectomy it is important to counsel patients on the options of sperm banking and insertion of a testicular prosthesis. The 2011 EAU guidelines recommend cryopreservation of sperm prior to orchidectomy. This should be specifically offered in all patients with a history of subfertility and atrophic contralateral testis. In patients keen to pursue the insertion of a testicular prosthesis at the time of an inguinal orchidectomy, the risk of a possible delay to chemotherapy secondary to prosthesis related infection (0.6-2%) (24) must be highlighted.

### 7.1 Staging and prognostic classifications

The staging system recommended in these guidelines is the 2009 TNM of the International Union Against Cancer (UICC) (25) include the following parameters :-

- a. Determination of the anatomical extent of disease
- b. Assessment of serum tumour markers, including nadir values of hCG, AFP and LDH after orchidectomy (S category)
- c. Clear definition of regional nodes
- d. N-category modifications related to node size

The 2009 TNM of the International Union Against Cancer (UICC) is summarized in Table 1.

#### 1. pT Primary tumour

pTX Primary tumour cannot be assessed

pT0 No evidence of primary tumour (e.g. histological scar in testis)

pTis Intratubular germ cell neoplasia (testicular intraepithelial neoplasia)

pT1 Tumour limited to testis and epididymis without vascular/lymphatic invasion: tumour may invade tunica albuginea but not tunica vaginalis

pT2 Tumour limited to testis and epididymis with vascular/lymphatic invasion, or tumour extending through tunica albuginea with involvement of tunica vaginalis

pT3 Tumour invades spermatic cord with or without vascular/lymphatic invasion



pT4 Tumour invades scrotum with or without vascular/lymphatic invasion

2. Regional lymph nodes clinical

NX Regional lymph nodes cannot be assessed

N0 No regional lymph node metastasis

N1 Metastasis with a lymph node mass 2 cm or less in greatest dimension or multiple lymph nodes, none more than 2 cm in greatest dimension

N2 Metastasis with a lymph node mass more than 2 cm but not more than 5 cm in greatest dimension, or multiple lymph nodes, any one mass more than 2 cm but not more than 5 cm in greatest dimension

N3 Metastasis with a lymph node mass more than 5 cm in greatest dimension

3. pN Pathological

pNX Regional lymph nodes cannot be assessed

pN0 No regional lymph node metastasis

pN1 Metastasis with a lymph node mass 2 cm or less in greatest dimension and 5 or fewer positive nodes, none more than 2 cm in greatest dimension

pN2 Metastasis with a lymph node mass more than 2 cm but not more than 5 cm in greatest dimension; or more than 5 nodes positive, none more than 5 cm; or evidence of extranodal extension of tumour

pN3 Metastasis with a lymph node mass more than 5 cm in greatest dimension

4. M Distant metastasis

MX Distant metastasis cannot be assessed

M0 No distant metastasis

M1 Distant metastasis

M1a Non-regional lymph node(s) or lung

M1b Other sites

5. S Serum tumour markers

Sx Serum marker studies not available or not performed

S0 Serum marker study levels within normal limits

	<b>LDH (U/l)</b>	<b>hCG (mIU/ml)</b>	<b>AFP (ng/ml)</b>
S1	<1.5 X N and	< 5000 and	< 1000
S2	1.5 - 10 X N or	5000 - 50,000 or	1,000-10,000
S3	> 10 X N or	> 50,000 or	> 10,000

Table 1.

On the attaining the TNMS information using the 2009 TNM of the International Union Against Cancer (UICC), patients are then staged using the American Joint Committee of Cancer (AJCC) staging classification (26) summarized in Table 2.

<b>Stage 0</b> pTis, N0, M0, S0	<b>Stage I</b> pT1-4, N0, M0, SX	<b>Stage II</b> Any pT/Tx, N1-3, M0, SX	<b>Stage III</b> Any pT/Tx, Any N, M1, SX
	<b>Stage IA</b> pT1, N0, M0, S0	<b>Stage IIA</b> Any pT/Tx, N1, M0, S0 Any pT/Tx, N1, M0, S1	<b>Stage IIIA</b> Any pT/Tx, Any N, M1a, S0 Any pT/Tx, Any N, M1a, S1
	<b>Stage IB</b> pT2, N0, M0, S0 pT3, N0, M0, S0 pT4, N0, M0, S0	<b>Stage IIB</b> Any pT/Tx, N2, M0, S0 Any pT/Tx, N2, M0, S1	<b>Stage IIIB</b> Any pT/Tx, N1-3, M0, S2 Any pT/Tx, Any N, M1a, S2
	<b>Stage IC</b> Any pT/Tx, N0, M0, S1-3	<b>Stage IIC</b> Any pT/Tx, N3, M0, S0 Any pT/Tx, N3, M0, S1	<b>Stage IIIC</b> Any pT/Tx, N1-3, M0, S3 Any pT/Tx, Any N, M1a, S3 Any pT/Tx, Any N, M1b, Any S

Table 2. The AJCC staging groupings of Testicular Tumours

## 8. Management

Within Europe and the UK the management of TGCTs differs mainly for the indications of Retroperitoneal Lymph Node Dissection (RPLND) in both Stage I and Stage II disease. We classify the management of TGCTs as followed in Europe and the UK based on whether the tumour is a Seminoma or Non-Seminoma.

### 8.1 Management of Seminoma

Of all Seminomas diagnosed, 75% are confined to the testicle itself at the time of clinical presentation and a complete cure is thus achieved with a thorough radical inguinal orchidectomy. In upto 10-15% of patients metastasis is present at the time of diagnosis with a further 5-10% of patients having more advanced disease.

In patients with Non-metastatic Stage I seminoma (T1N0M0S0-1) the risk of subsequent para-aortic lymph node relapse is 20%. Adjuvant therapy with either chemotherapy or radiotherapy reduces the risk of recurrence to <1%.

#### 8.1.1 Management of stage I Seminoma

The options in a patient with Stage 1 Seminoma include surveillance, adjuvant chemotherapy or adjuvant radiotherapy. The option of surveillance is indicated as 75% of Seminoma are cured following a radical inguinal orchidectomy. In a large study of 1500 patients (28) indicated the overall rate of retroperitoneal disease relapse to be 16.8%. It is important to characterize patients with high risk Stage I Seminoma based on initial pathology. The 2 most important factors associated with poor prognosis includes the presence of rete-testis invasion and tumours size of  $\geq 4$  cm. The overall cancer-specific survival rate reported with surveillance performed by experienced centres is 97-100% for seminoma stage I (29-31). The main drawback of surveillance is the need for more intensive

follow-up, especially with repeated imaging examinations of the retroperitoneal lymph nodes, for at least 5 years after orchidectomy.

Prognostic Group	Progression free survival (PFS) and overall survival (OS)	Clinical Criteria
Good prognostic group (Non Seminoma)	<i>Non-seminoma (56% of cases)</i> 5-year PFS 89% 5-year survival 92%	<i>All of the following criteria:</i> <ul style="list-style-type: none"> <li>• Testis/retroperitoneal primary</li> <li>• No non-pulmonary visceral metastases</li> <li>• AFP &lt; 1,000 ng/mL</li> <li>• hCG &lt; 5,000 IU/L (1,000 ng/mL)</li> <li>• LDH &lt; 1.5 x ULN</li> </ul>
Good prognostic group (Seminoma)	<i>Seminoma (90% of cases)</i> 5-year PFS 82% 5-year survival 86%	<i>All of the following criteria:</i> <ul style="list-style-type: none"> <li>• Testis/retroperitoneal primary</li> <li>• No non-pulmonary visceral metastases</li> <li>• AFP &lt; 1,000 ng/mL</li> <li>• hCG &lt; 5,000 IU/L (1,000 ng/mL)</li> <li>• LDH &lt; 1.5 x ULN</li> </ul>
Intermediate prognosis group (Non Seminoma)	<i>Non-seminoma (28% of cases)</i> 5 years PFS 75% 5-year survival 80%	<ul style="list-style-type: none"> <li>• Testis/retroperitoneal primary</li> <li>• No non-pulmonary visceral metastases</li> <li>• AFP 1,000 - 10,000 ng/mL or</li> <li>• hCG 5,000 - 50,000 IU/L or</li> <li>• LDH 1.5 - 10 x ULN</li> </ul>
Intermediate prognosis group (Seminoma)	<i>Seminoma (10% of cases)</i> 5-year PFS 67% 5-year survival 72%	<i>Any of the following criteria:</i> <ul style="list-style-type: none"> <li>• Any primary site</li> <li>• Non-pulmonary visceral metastases</li> <li>• Normal AFP</li> <li>• Any hCG</li> <li>• Any LDH</li> </ul>
Poor prognosis group (Non Seminoma)	<i>Non-seminoma (16% of cases)</i> 5-year PFS 41% 5-year survival 48%	<i>Any of the following criteria:</i> <ul style="list-style-type: none"> <li>• Mediastinal primary</li> <li>• Non-pulmonary visceral metastases</li> <li>• AFP &gt; 10,000 ng/mL or</li> <li>• hCG &gt; 50,000 IU/L (10,000 ng/mL) or</li> <li>• LDH &gt; 10 x ULN</li> </ul>
Poor prognosis group (Seminoma)	No patients classified as poor prognosis	N/A

Table 3. Prognostic-based staging system for metastatic germ cell cancer (International Germ Cell Cancer Collaborative Group).

Patients with Stage I Seminoma can also be given adjuvant chemotherapy with one cycle of Carboplatin (33). An alternative to surveillance or chemotherapy in patients with radiotherapy (34).

Within Europe and the UK, a RPLND is not recommended in patients with Stage 1 Seminoma. In prospective, non-randomised study comparing radiotherapy and RPLND in stage I seminoma, there was a trend towards a higher incidence of retroperitoneal relapses (9.5%) after RPLND as primary treatment (35).

In summary, it is important to stratify patients with Stage 1 Seminoma into high risk based on the presence of rete testis invasion and tumour volume of  $\geq 4$  cm. In these patients the

option of adjuvant chemotherapy and radiotherapy is justifiable. In patients without rete testis invasion or in whom the testicular tumour volume is  $\leq 4$  cm the option of surveillance alone is recommended.

### 8.1.2 Management of stage II Seminoma

The options in a patient with Stage II Seminoma is radiotherapy. However, chemotherapy is an alternative management strategy.

## 8.2 Management of Non-Seminoma

In patients with Non-Seminomas, 30% with Stage I disease will have subclinical metastases and will relapse if surveillance alone is applied following orchidectomy. Within this groups of patients the options of treatment include surveillance, chemotherapy and RPLND. It is important to stratify Non-Seminomas into high risk based tumours depending on the following parameters which include the presence of Vascular/lymphatic in or peritumoural invasion, proliferation rate  $> 70\%$  or percentage of embryonal carcinoma  $> 50\%$ .

### 8.2.1 Management of stage I Non-Seminoma

In patients on surveillance, the incidence of relapse is 30% (36). When a patient relapses about 35% have normal levels of serum tumour markers at relapse and approximately 60% of relapses are within the retroperitoneum. Upto 11% of relapsing patients have large-volume recurrent disease at representation. Based on the above, the option of surveillance should be offered to a compliant patient who will agree for very regular and close follow up.

The commonest option of management of patients within Europe and the UK with Stage I Non-Seminoma is chemotherapy. The current recommendation is two courses of chemotherapy with cisplatin, etoposide and bleomycin (PEB) as primary treatment for high-risk patients (having about 50% risk of relapse). Patient receiving adjuvant chemotherapy must be monitored closely as there is a risk of slow-growing retroperitoneal teratomas after primary chemotherapy.

A Nerve sparing / template based RPLND can also be offered to patient who are not keen to receive chemotherapy. It is interesting to note that about 30% of patients are diagnosed to have a retroperitoneal lymph node metastases corresponding to pathological stage II (PS2) disease. In patients with no retroperitoneal metastases found at RPLND (PS1), approximately 10% of the PS1 patients relapse at distant sites. Within the UK, RPLND is normally indicated in post chemotherapy recurrence.

As with seminomas a further risk adaptive strategy can be adapted for Non-Seminomas. If the risk-adapted policy is applied, patients with vascular invasion are recommended to undergo adjuvant chemotherapy with two cycles of PEB, and patients without vascular invasion are recommended to undergo surveillance. In summary patients with CS1A (pT1, no vascular invasion), low risk Stage I Non Seminoma can be offered the option of surveillance. If patients are not willing (or suitable) to undergo surveillance, adjuvant chemotherapy or nerve-sparing RPLND are alternative treatment options. If RPLND reveals PN+ (nodal involvement) disease, chemotherapy with two courses of PEB should be considered. Patients with Stage I Non-Seminoma CS1B (pT2-pT4) high risk disease receive either primary chemotherapy with two

courses of PEB or Surveillance or nerve-sparing RPLND in high-risk patients remain options for those not willing to undergo adjuvant chemotherapy.

### 8.2.2 Management of stage II Non-Seminoma

In patients with Stage II Non-Seminoma with normal testicular tumour markers can be managed with primary RPLND or surveillance. In patients with elevated tumour markers primary chemotherapy is recommended. When surveillance is commenced for a lesion the lesion can either regress, resolve or progress with either a rise or no rise in concomitant testicular markers.

When a lesion regresses in the absence of rising tumour markers it is unlikely to be a malignancy. A lesion growing represents either a teratoma or a well differentiated tumour in the absence of rising testicular tumour markers. In this situation a RPLND should be performed by an experienced surgeon. Patients with a growing lesion and a concomitant increase in tumour markers AFP or beta-hCG should not undergo surgery. These patients require chemotherapy with PEB according to the treatment algorithm for patients with metastatic disease and IGCCCG. Patients who are unwilling to commence primary chemotherapy have an option of a nerve-sparing RPLND with adjuvant chemotherapy (two cycles of PEB) in case of metastatic disease (pII A/B).

## 9. Follow up

Follow-up care with an oncologist, urologist or both, is vital for the patient with testicular cancer. Regular assessments are required to monitor tumour markers in the blood, chest X-rays, CT scans of the abdomen and a full medical examination with psychological support. This process may continue for several years and may vary depending on the type and stage of the disease.

## 10. Conclusion

In conclusion the management of TGCTs within the UK and Europe is based on the individuals management (surveillance, chemotherapy or radiotherapy) which has to be balanced according to clinical features and the risk of short-term and long-term toxic effects. Although cure rates for Stage 1 disease are high, there continues to be significant morbidity due to chemotherapy, RPLND and Radiotherapy for concomitant additional treatment. We recommend individualizing patient treatment using a Multidisciplinary team approach using the latest regional, national and international guidelines and developments.

## 11. Abbreviations

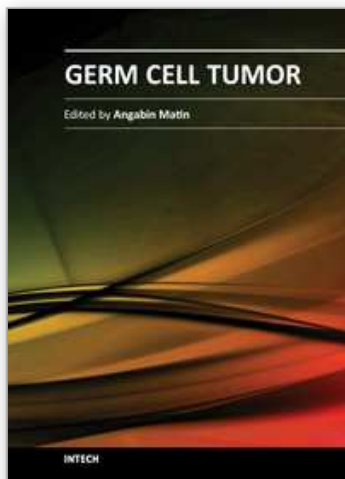
TGCTs	Testicular Germ Cell tumours
PGC	Primordial germ cells
UDT	Undescended Testis
IGCNU	Intratubular germ cell neoplasia
MOE	Maternal Oestrogen Exposure

HCG	Human chorionic gonadotrophin
AFP	Alpha-fetoprotein
LDH	Lactate dehydrogenase
PLAP	Placental alkaline phosphatase
IGCCCCG	International Germ Cell Cancer Collaborative Group
AJCC	American Joint Committee of Cancer
RPLND	Retroperitoneal Lymph Node Dissection

## 12. References

- Aparicio J, García del Muro X, Maroto P, et al. Spanish Germ Cell Cancer Cooperative Group (GG). Multicenter study evaluating a dual policy of postorchidectomy surveillance and selective adjuvant single-agent carboplatin for patients with clinical stage I seminoma. *Ann Oncol* 2003 Jun;14(6):867-72.
- Bode PK, Barghorn A, Fritzsche FR, Riener MO, Kristiansen G, Knuth A, Moch H. MAGEC2 is a sensitive and novel marker for seminoma: a tissue microarray analysis of 325 testicular germ cell tumours. *Mod Pathol*. 2011 Jun;24(6):829-35
- Bosl GJ, Motzer RJ. Testicular germ-cell cancer. *N Engl J Med* 1997 Nov;337(4):242-53.
- Calvert AH, Newell DR, Gumbrell LA, et al. Carboplatin dosage: prospective evaluation of a simple formula based on renal function. *J Clin Oncol*. 1989;7:1748-1756.
- Cancer Incidence in Five Continents, Vol IX. Curado MP, Edwards B, Shin R, et al eds. IARC Scientific Publication 2007, No. 160.
- Cassidy FH, Ishioka KM, McMahon CJ, et al. MR imaging of scrotal tumors and pseudotumors. *Radiographics* 2010 May; 30(3):665-83.
- Chung P, Parker C, Panzarella T, et al. Surveillance in stage I testicular seminoma-risk of late relapse. *Can J Urol* 2002 Oct;9(5):1637-40.
- Engholm G, Ferlay J, Christensen N, et al. NORDCAN--a Nordic tool for cancer information, planning, quality control and research. *Acta Oncol* 2010 Jun;49(5):725-36
- Fosså SD, Horwich A, Russell JM, et al. Optimal planning target volume for stage I testicular seminoma: A Medical Research Council Testicular Tumor Working Group randomized trial. *J Clin Oncol* 1999 Apr;17(4):1146
- Freedman LS, Parkinson MC, Jones WG, et al. Histopathology in the prediction of relapse of patients with stage I testicular teratoma treated by orchidectomy alone. *Lancet* 1987 Aug;2(8554):294-8.
- Henderson BE, Benton B, Jing J, Yu MC, Pike MC. Risk factors for cancer of the testis in young men. *Int J Cancer*. 1979 May 15;23(5):598-602.
- Horwich, A., Shipley, J. & Huddart, R. Testicular germ-cell cancer. *Lancet* 367, 754–765 (2006)
- Huyghe E, Matsuda T, Thonneau P. Increasing incidence of testicular cancer worldwide: a review. *J Urol* 2003 Jul;170(1):5-11.
- International Germ Cell Cancer Collaborative Group. International Germ Cell Consensus Classification: a prognostic factor-based staging system for metastatic germ cell cancers. *J Clin Oncol* 1997 Feb;15(2):594-603.
- Kanetsky PA, Mitra N, Vardhanabhuti S, et al. Common variation in KITLG and at 5q31.3 predisposes to testicular germ cell cancer. *Nat Genet* 2009 Jul;41(7):811-5.

- Kim W, Rosen MA, Langer JE, et al. US-MR Imaging correlation in pathologic conditions of the scrotum. *Radiographics* 2007 Sep-Oct; 27(5):1239-53.
- Korkola JE, Houldsworth J, Feldman DR, et al. Identification and validation of a gene expression signature that predicts outcome in adult men with germ cell tumors. *J Clin Oncol* 2009 Nov 1;27(31):5240-7.
- La Vecchia C, Bosetti C, Lucchini F, et al. Cancer Mortality in Europe, 2000-2004, and an overview of trends since 1995. *Ann Oncol*. 2010 Jun; 21(6):1323-60. Epub 2009 Nov 30
- Looijenga LH, Gillis AJ, Stoop H, et al. Relevance of microRNAs in normal and malignant development, including human testicular germ cell tumours. *Int J Androl* 2007 Aug;30(4):304-14; discussion 314-15.
- Marshall S. Potential problems with testicular prostheses. *Urology*. 1986 Nov;28(5):388-90
- Oliver RT, Mason MD, Mead GM, et al. MRC TE19 collaborators and the EORTC 30982 collaborators. Radiotherapy versus single-dose carboplatin in adjuvant treatment of stage I seminoma: a randomised trial. *Lancet* 2005 Jul;23-29;366(9482):293-300.
- Oosterhuis, J. W. & Looijenga, L. H. Testicular germ-cell tumours in a broader perspective. *Nature Rev. Cancer* 5, 210-222 (2005).
- Peyret C. Tumeurs du testicule. Synthèse et recommandations en onco-urologie. *Prog Urol* 1993;2:60-4.
- Rapley EA, Turnbull C, Al Olama AA, et al; UK Testicular Cancer Collaboration. A genome-wide association study of testicular germ cell tumor. *Nat Genet* 2009 Jul;41(7):807-10.
- Reuter VE. Origins and molecular biology of testicular germ cell tumors. *Mod Pathol* 2005 Feb;18(Suppl 2):S51-S60.
- Schottenfeld D, Warshauer ME, Sherlock S, Zauber AG, Leder M, Payne R. The epidemiology of testicular cancer in young adults. *Am J Epidemiol*. 1980 Aug;112(2):232-46
- Skakkebaek NE, Berthelsen JG, Müller J. Carcinoma-in-situ of the undescended testis. *Urol Clin North Am*. 1982 Oct;9(3):377-85
- Sobin LH, Gospodariwicz M, Wittekind C (eds). TNM classification of malignant tumors. UICC International Union Against Cancer, 7th edn. Wiley-Blackwell, 2009 Dec; pp 249-254.
- Tandstad T, Smaaland R, Solberg A, et al. Management of Seminomatous Testicular Cancer: A Binational Prospective Population-Based Study From the Swedish Norwegian Testicular Cancer Study Group (SWENOTECA). *J Clin Oncol*. 2011 Jan 4
- Testis. In: American Joint Committee on Cancer: AJCC Cancer Staging Manual. Philadelphia, Pa: Lippincott-Raven Publishers, 5th ed., 1997, pp 225-230.
- Thornhill JA, Conroy RM, Kelly DG, Walsh A, Fennelly JJ, Fitzpatrick JM. Public awareness of testicular cancer and the value of self examination. *Br Med J* 1986;293(6545):480-1.
- Thornhill JA, Fennelly JJ, Kelly DG, Walsh A, Fitzpatrick JM. Patients' delay in the presentation of testis cancer in Ireland. *Br J Urol* 1987;59(5):447-51.
- Wanderas EH, Tretli S, Fossa SD. Trends in incidence of testicular cancer in Norway 1955-1992. *Eur J Cancer* 1995 Nov;31A(12):2044-8.
- Warde P, Jewett MAS. Surveillance for stage I testicular seminoma. Is it a good option? *Urol Clin North Am* 1998 Aug;25(3):425-33.
- Warszawski N, Schmucking M. Relapses in early-stage testicular seminoma: radiation therapy versus retroperitoneal lymphadenectomy. *Scan J Urol Nephrol* 1997 Aug;31(4):335-9.
- WHO histological classification of testis tumours, In: Eble JN, Sauter G, Epstein JI, Sesterhenn IA, eds. Pathology & Genetics. Tumours of the urinary system and male genital organs. Lyons: IARC Press, 2004: 218, pp. 250-262.



## **Germ Cell Tumor**

Edited by Dr. Angabin Matin

ISBN 978-953-51-0456-8

Hard cover, 150 pages

**Publisher** InTech

**Published online** 30, March, 2012

**Published in print edition** March, 2012

The book aims to provide an overview of current knowledge regarding germ cell tumors. It deals with the clinical presentations, treatment modalities, the biology and genetics of germ cell tumors in children and adults. Most chapters are focused on testicular germ cell tumors whose incidence has been increasing in young males. Included are reviews on the pathogenesis, risk factors, diagnosis and treatment regimens applied to precursor, pre-invasive lesions as well as to seminomatous and non-seminomatous germ cell tumors of the testes. In addition, a review is included on the diagnosis and current management options for intracranial germ cell tumors in children. Authors have also contributed articles on the genetics and epigenetics of germ cell tumor development in humans and in the mouse model system. This book will be of interest to scientists, physicians and lay readers wishing to review recent developments in the field of germ cell cancers.

### **How to reference**

In order to correctly reference this scholarly work, feel free to copy and paste the following:

Nikhil Vasdev and Andrew C. Thorpe (2012). Testicular Germ Cell Tumours - A European and UK Perspective, Germ Cell Tumor, Dr. Angabin Matin (Ed.), ISBN: 978-953-51-0456-8, InTech, Available from: <http://www.intechopen.com/books/germ-cell-tumor/testicular-germ-cell-tumour>

**INTECH**  
open science | open minds

### **InTech Europe**

University Campus STeP Ri  
Slavka Krautzeka 83/A  
51000 Rijeka, Croatia  
Phone: +385 (51) 770 447  
Fax: +385 (51) 686 166  
[www.intechopen.com](http://www.intechopen.com)

### **InTech China**

Unit 405, Office Block, Hotel Equatorial Shanghai  
No.65, Yan An Road (West), Shanghai, 200040, China  
中国上海市延安西路65号上海国际贵都大饭店办公楼405单元  
Phone: +86-21-62489820  
Fax: +86-21-62489821



© 2012 The Author(s). Licensee IntechOpen. This is an open access article distributed under the terms of the [Creative Commons Attribution 3.0 License](#), which permits unrestricted use, distribution, and reproduction in any medium, provided the original work is properly cited.

IntechOpen

IntechOpen