

We are IntechOpen, the world's leading publisher of Open Access books Built by scientists, for scientists

4,800

Open access books available

122,000

International authors and editors

135M

Downloads

Our authors are among the

154

Countries delivered to

TOP 1%

most cited scientists

12.2%

Contributors from top 500 universities



WEB OF SCIENCE™

Selection of our books indexed in the Book Citation Index
in Web of Science™ Core Collection (BKCI)

Interested in publishing with us?
Contact book.department@intechopen.com

Numbers displayed above are based on latest data collected.

For more information visit www.intechopen.com



The Research on Bolster for Self-Replacement Combined with Percutaneous Vertebroplasty in Treatment of Vertebral Compression Fractures

Mo Wen¹, Cheng Shaodan² and Hu Zhijun¹

*¹Department of Orthopedics, Longhua Hospital,
Shanghai University of Traditional Chinese Medicine, Shanghai*

*²Department of Lu's Traumatology, Huashan Hospital, Fudan University,
Jing'an Branch, Shanghai,
China*

1. Introduction

Percutaneous vertebroplasty (PVP) is a minimally invasive spinal surgery technique arising in the past 20 years, which has been widely used in the treatment of vertebral compression fractures (VCF). However, people have gradually found that the approach can not completely restore the vertebral height and has a high incidence of leakage, etc. From August 2006 to August 2007, 26 cases of VCF underwent traditional bolster for self-replacement treatments before PVP; furthermore, we conducted from 1 to 12 months of follow-up visits. The results are as follows.

2. Materials and methods

2.1 Clinical materials

There were 6 men and 20 women in the 26 cases of VCF studied. Ages ranged from 51 to 80 years, with a mean of 64.5 years. There was one case in the 51 to 55 age range, 4 cases in the 56 to 60 age range, 14 cases in the 61 to 70 age range and 7 cases in the 71 to 80 age range; 5 cases involved a single thoracic body, 6 cases involved 1 thoracic body and 1 lumbar body, 8 cases involved a single lumbar body, 6 cases involved 2 lumbar bodies and 1 case involved 3 lumbar bodies; all cases were osteoporotic vertebral compression fractures, duration of 1 to 15 days. At admission to hospital and before surgery patients had no neurological symptoms or signs of root damage. Preoperative CT scans of vertebra showed a complete posterior vertebral body.

2.2 Therapeutic methods

2.2.1 Bolster for self-replacement: When patients were admitted to hospital, they were laid on a hard bed with a bolster under the waist. This could be tolerated in the case of daily elevation of the pillow (generally a maximum of 10cm), so that the spine was hyper

extended, for 3 to 7 days; in the meantime, patients were encouraged to adopt the "five-point support method" exercise as soon as possible, to aid reset.

2.2.2 PVP treatment: General admission electrocardiogram and other tests were used to understand the patient's conditions as well as the function of important organs. Blood glucose, prothrombin time, liver and kidney function tests as well as iodine allergy tests were completed to exclude the possibility of surgical contraindications.

A preparation of 0.09g luminal was taken orally for preoperative sedation. Surgery was performed with patients in the prone position, the two shoulders and two iliacs were elevated; puncturing and injecting of bone cement was achieved using a pressurized syringe device (Israel Disc-0-Tech). The bone cement was a special bone cement used for the PVP / PKP (polymethylmethacrylate, PMMA, Tianjin Synthetic Material Research Institute products).

The operation was carried out under the surveillance of the C-arm, all adaptors were used with a unilateral needle (vertebral compression heavier side in the anteroposterior position). Thoracic and lumbar punctures were achieved through the lateral vertebral neck. An anteroposterior fluoroscopy C-arm tube was used to adjust the angle so that both lateral vertebral necks showed clearly, two Kirschner wires crossed and were fixed on the skin surface, the surface projection of lateral vertebral neck coincided with the intersection of the two Kirschner wires. The puncture point lay slightly outside and above, 1 ~ 1.5cm from the coincidence point. After local anesthesia, keeping the transfixion pin and sagittal body appearing 15° ~ 30° angle, after the transfixion pin got into the lateral vertebral neck, then pushed the transfixion pin 1 ~ 2cm. Checking under lateral fluoroscopy to confirm correct transfixion point, Penetrated with slow rotation, so that the transfixion pin tip was in the central of vertebral body in the anteroposterior and the anterior 1 / 3 in the lateral; Then injected 3~ 5 mL of iohexol contrast agent, observed the contrast agent to confirm the filling of the vertebral body. If there was no significant vascular leakage, then connected the rotation pressure syringe, slowly pushed the cement into the vertebral body under fluoroscopy.

When bone cement was near the posterior margin of the vertebral body, stopped pushing.

If injection caused local gas pains, pains in the legs, numbness or burning feeling, stopped injecting for a moment. If the sensory disturbances disappeared within 30s, the patients had good locomotor activity, bone cement did not exceed the posterior margin of the vertebral body for 3mm, we could continue to inject.

After injection, removed the pressure syringe, inserted and rotated the inner core needle. After about 3 ~ 5 minutes, pulled out the transfixion pin. These operation could ensure the needle not sticking together with the bone cement, and also could prevent the bone cement remaining in the transfixion pin because of premature pulling out.

Kept the patients remain in the prone position for 10 minutes or so. At the same time, observed the blood pressure, pulse and other vital signs without exception, turned over patients so that they were supine on a trolley and were transferred into the ward. Patients must continue to lie in bed for three days. Then they might get out of bed wearing abdominal belt. Routine antimicrobial drugs were used during surgery and 1 day after surgery; generally 5 to 7 days later, the patients could discharge.

2.3 Follow-up method

Patients were taken the CT scan of vertebral compression fracture before operation to clear the posterior wall of vertebral body was integrity, and the filling condition of the bone cement in the vertebral body were observed again through CT scan of vertebral compression fracture after operation. At admission to hospital, preoperative, 3 days after operation, 1 month, 3 months, 6 months and 12 months after operation, taking the operative vertebral body as the center, the standard anteroposterior position and lateral position thoracic or lumbar vertebrae X-ray were examined. Vertebral bodies height were measured using Vernier (central compression fracture, the central height was measured; anterior border compression fracture, the anterior border height was measured, accurate to 0.1 mm). Then the loss rate of vertebral body height, posterior salient angle, rectification rate of posterior salient angle, VAS Score, analgesic usage score and locomotor activity score were observed at admission, preoperative, 3 days, 1 month, 3 months, 6 months and 12 months after operation.

2.3.1 Vertebral height measurement: The distance between the superior margin and the inferior margin in central part or leading edge of compressed vertebral body were measured. Then calculated the compressibility of vertebral height as follows: Using measurements from lateral X-rays, vertebral heights preoperative and postoperative could be found. Vertebral height lost = estimate of the original vertebral height - current height of the vertebral body, vertebral height loss rate (%) = loss of vertebral height / estimated original vertebral height x 100%.

2.3.2 Measurement methods of Kyphosis angle (Cobb angle): The vertical line of upper endplate on the upper vertebrae of the suffered and the vertical line of lower endplate on the lower vertebrae had an angle, that was the upper and lower endplate angle, reflecting the degree of the kyphosis severity. Calculating vertebral kyphosis correction rate in following way: In normal vertebral lateral X-ray, the upper endplate parallels to the lower. Vertebral kyphosis correction rate (%) = (preoperative vertebral kyphosis angle - postoperative vertebral kyphosis angle) / preoperative vertebral kyphosis angle.

2.3.3 VAS score: 0 point - turning round and coughing without pain; 1 point - quiet prostration without pain, coughing and turning round with pain; 2 points - pain when coughing, deep breathing without pain; 3 points - lying without pain, coughing and deep breathing with pain; 4 points - quiet prostration with intermittent pain; 5 points - quiet prostration with persistent pain; 6 points - quiet prostration with more pain; 7 points - severe pain, flip-flop and discomfort, being tired; 8 points - continuous, unbearable pain, sweating evidently all over the body; 9 points - severe unbearable pain accompanied by a sense of living death.

2.3.4 Analgesic usage score: 0 point: no usage of drugs; 1 point: use of non-steroidal anti-inflammatory drugs; 2 points: irregular use of narcotic analgesics; 3 points: regular usage of narcotic analgesics; 4 points: vein or muscle injections of narcotic analgesics.

2.3.5 Activity score: 1 point: acting without apparent difficulty; 2 points: difficulty walking and needing help; 3 points: only using a wheelchair or remain sitting; 4 points: being forced to lie in bed.

2.4 Statistical analysis

Numerical variables and ordinal variables were presented as mean \pm standard deviation(SD).The vertebral height recovery rate and the Cobb angle correction rate were showed by percentage. Compared with the indicators at different time points by using SPSS11.0 for single-factor analysis of variance, A P value less than 0.05 was considered statistically significant.

3. Results

In this group of patients, the volume of bone cement injected in each vertebral was 3 ~ 6.5ml. When intraosseous vertebral venography were performed before the injection of bone cement, paravertebral vascular developed an image in 5 cases, then filled the gelatin sponge; peripheral cement leakage was found in 4 cases, intervertebral disc leakage was found in 2 cases and posterior margin leakage was seen in 2 cases (posterior longitudinal ligament is not exceeded), no clinical symptoms appeared. No nerve root or spinal cord injury, no pulmonary embolism or other complications were recorded. All patients had no further vertebral fractures. At admission,preoperative and postoperative X-ray films were shown in Figure 1-7. Figure 2 showed that bolster for self-replacement restored vertebral body height, corrected the kyphosis angle. Figure 5-7 showed that the PVP surgery could maintain and enhance the effect.The stata was showed in Table 1. Bolster for self-replacement combined with percutaneous vertebroplasty significantly improved VAS scores, analgesic use score and activity score, The results were shown in Table 2.

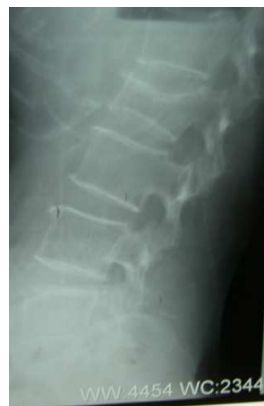

Fig. 1. Lateral X-ray at admission.

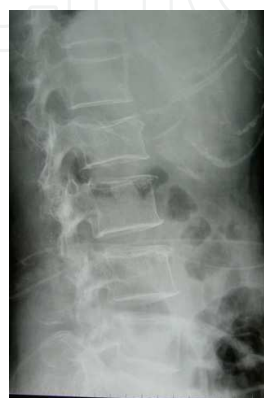

Fig. 2. Lateral X-ray before operation.

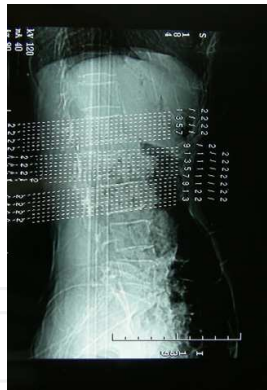

Fig. 3. Locating CT film before operation.

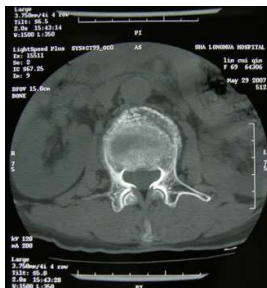

Fig. 4. CT plain scanning before operation.

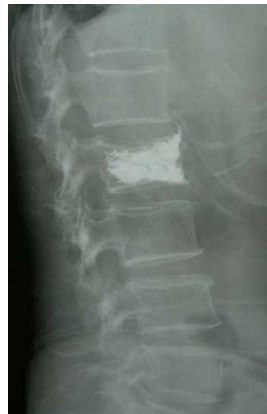

Fig. 5. Lateral X-ray after operation.

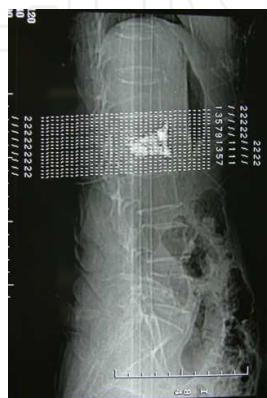

Fig. 6. Locating CT film after operation.

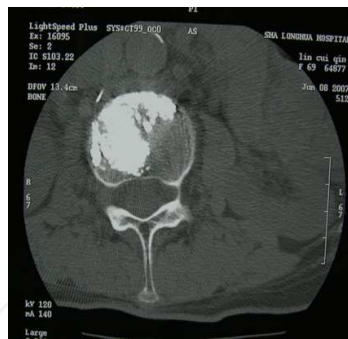

Fig. 7. CT plain scanning after operation.

Stage	Cases	Loss rate of vertebral body height	posterior salient angle	rectification rate of posterior salient angle
Admission	26	36.4 ± 0.2	27.1 ± 2.3	/
Pre-operating	26	8.4 ± 0.2 #	11.2 ± 2.2 #	58.7 ± 1.5
3 days after operation	26	8.4 ± 0.3 # *	9.9 ± 1.9 # *	63.5 ± 1.4*
1 month after operation	26	8.3 ± 0.2 # *	9.8 ± 1.8 # *	63.8 ± 1.4*
3 months after operation	26	8.3 ± 0.1 # *	9.9 ± 2.2 # *	63.5 ± 1.3*
6 months after operation	26	8.2 ± 0.2 #*	9.7 ± 2.2 #*	64.2 ± 1.4*
1 year after operation	26	8.2 ± 0.1 #*	9.7 ± 2.3 #*	64.1 ± 1.3*

Note: Comparing with admission, # $P < 0.01$; Different stages after operation comparing with each other and comparing with Pre-operating, * $P > 0.05$

Table 1. The results of loss rate of vertebral body height, posterior salient angle, rectification rate of posterior salient angle ($\bar{x} \pm s$).

Stage	Cases	VAS Score	antalgica usage score	locomotor activity score
Admission	26	7.6 ± 0.02	1.4 ± 0.04	3.3 ± 0.02
Pre-operating	26	5.3 ± 0.02 Δ	1.3 ± 0.03 \blacktriangle	3.1 ± 0.01 \blacktriangle
3 days after operation	26	1.3 ± 0.01 $\Delta\Delta$	0.5 ± 0.04 $\Delta\Delta$	1.2 ± 0.03 $\Delta\Delta$
1 month after operation	26	0.3 ± 0.01 $\Delta\Delta\Delta\blackstar$	0.1 ± 0.04 $\Delta\Delta\Delta\blackstar$	1.1 ± 0.04 \blackstar
3 months after operation	26	0.2 ± 0.01 $\Delta\Delta\Delta\blackstar$	0.1 ± 0.03 $\Delta\Delta\Delta\blackstar$	1.0 ± 0.02 \blackstar
6 months after operation	26	0.1 ± 0.03 $\Delta\Delta\Delta\blackstar$	0.1 ± 0.02 $\Delta\Delta\Delta\blackstar$	1.0 ± 0.02 \blackstar
1 year after operation	26	0.1 ± 0.02 $\Delta\Delta\Delta\blackstar$	0.1 ± 0.01 $\Delta\Delta\Delta\blackstar$	1.0 ± 0.03 \blackstar

Note: VAS Score, comparing with admission, $\Delta P < 0.05$. Antalgica usage score and locomotor activity score, Pre-operating comparing with admission, $\blacktriangle P > 0.05$; 3 days after operation comparing with Pre-operating, $\Delta\Delta P < 0.01$. VAS Score and antalgica usage score, other stages after operation comparing with 3 days after operation, $\Delta\Delta\Delta P < 0.01$. locomotor activity score, other stages after operation comparing with 3 days after operation, $\blackstar P > 0.05$. 1 month after operation, 3 months after operation, 6 months after operation and 1 year after operation comparing with each other, $P > 0.05$.

Table 2. The results of VAS Score, antalgica usage score and locomotor activity score ($\bar{x} \pm s$).

As could be seen from Table 1, in all cases after bolster for self-replacement, patients had a different degree of vertebral height restoration, and had significant differences compared

with conditions at admission; vertebral height did not change significantly after PVP. Bolster for self-replacement was effective in restoring vertebral body height to compensate for the lack of PVP. Follow-up found no significant loss of vertebral height after surgery, indicating the effectiveness of PVP.

As could be seen from Table 2, although there were some recovery of vertebral height after bolster for self-replacement, that did not solve the problem of pain; After PVP, the patient's pain, activity had significantly improved, and these effects were stable in middle and long-term observation.

4. Discussion

4.1 Compressed vertebral body height restoration

Do not try to restore compression with PVP to normal vertebral body height [1]. The normal vertebral body height is the foundation of stable spine, when compression fractures occur, the trabeculars in the bone break, the breakage of cortical bone region occurs. When injecting bone cement during the plasty of the vertebral, it can have a good dispersion in the trabecular bone by applying appropriate pressure. But if we try to inject bone cement by larger pressure to restore vertebral height, the bone cement may have a leakage from the split to the vertebral surface, then flow into the peripheral of vertebral and canalis spinalis, causing neurological and vascular symptoms, fat embolism may also occur [2]. Xuyi^[3] etc. considered that the injection volume of bone cement for thoracic and lumbar was 4 ~ 6ml, this dose had been able to achieve therapeutic purposes, the injection of large doses made it easy to cause vertebral body break and bone cement spillage, especially in elderly osteoporotic compression fractures. We should not be in the pursuit of simply increasing the amount of bone cement to improve the clinical effects of treatment. In addition, the compression level is more than 50% with instable fracture, PVP should be used with caution.

4.2 The choice of puncture site

As to unilateral or bilateral transpedicular percutaneous vertebroplasty, various reports are different. We believe that as long as the transfixion pin tip is just in the central of vertebral body in the anteroposterior and the anterior 1 / 3 in the lateral, most of the bone cement within vertebral fill well to the opposite side; what's more it is not that the more bone cement in vertebral body the better, so we have chosen unilateral transpedicular percutaneous vertebroplasty, it has obtained good clinical efficacy and also reduced the burden of patients.

4.3 Management of leakage of intravascular contrast agent showing

VCF, especially osteoporotic VCF, most blood sinus in the vertebral body communicates with the larger blood vessels outside the vertebral body. When PVP is carried out, bone cement may flow with blood flowing which leads to embolism in other parts. Thus, in contrast agent imaging, such as found in large vessels (diameter > 3mm) imaging, we should change the puncture site or choose contralateral puncture site, if this still cannot be avoided, it is best to abandon the surgery. If the contrast agent images in small vessels (diameter < 3mm), fill the vertebral body with the gelatin sponge, pressing with a guide needle and then intraosseous vertebral venography should be performed again. If it is not

obvious, we can continue to inject. For such patients, by increasing the viscosity of bone cement, inject bone cement of 0.5ml at first, wait for 2-3minutes and then adopt the slow injection method, which allows the formation of lumps of bone cement to block transport vessels, to avoid the infiltration of blood vessels and embolism that may be caused further.

4.4 Control of bone cement viscosity

The bone cement viscosity can be controlled by adjusting the ratio of powder and liquid during the surgery. For serious osteoporosis, the magnitude of the contrast agent widely distributed in the vertebral body, or vascular imaging, the bone cement viscosity should be increased; on the contrary, the bone cement viscosity should be reduced to enable better diffusion in the vertebral body.

4.5 Notice

Because there is still 0.5ml bone cement in the transfixion needle tubing, when we insert inner core needle at the end, the bone cement will get into the vertebral body too. So when the bone cement get close to the hinder margin of vertebral body (<1 mm) in the surgery, inserting must be stopped to prevent the leakage of bone cement.

In recent years, surgical techniques tend to be minimally invasive, that's to say, minimize iatrogenic trauma to a minimum in order to obtain the desired effect^[4]. PVP has the advantages such as less trauma, shorter operative time, obvious analgetic effect, rapid postoperative recovery and so on, especially for elderly osteoporotic patients, it has less systemic interference and higher security, patients can have ambulation as early as possible to avoid leading to complications because of prolonged bed rest, therefore, it has broad application prospects. But its long-term clinical efficacy remains to be observed.

Moreover, PMMA which is the earliest and most widespread used in clinic has the disadvantages such as heart and pulmonary toxicity, heat production, leakage and so on. Some researchers have tried to use biodegradable Calcium acid phosphate bone cement (CPC) and calcium phosphate bone cement/bone morphogenetic protein (CPC/BMP) with bone conduction and tissue compatibility to replace PMMA. However, animal experiments have found that^[5], CPC and CPC / BMP can't restore the strength and stiffness of the vertebral body well in the near future, it is not conducive to osteoporotic vertebral compression fracture healing, therefore it can not completely replace PMMA. So PMMA is the mainly filler in application now^[6]. It is believed that with the development of science and technology, especially the development of biological materials science, safer and more rational fillings are bound to come out in the future^[7].

5. Comparative study between vertebroplasty using bolster technique and balloon kyphoplasty

Simple PVP treatment can not recover the losed height of the vertebral, balloon kyphoplasty (PKP) are developing at recent years. Part 1 to part 4 indicated that bolster for self-replacement combined with PVP had good clinical effect in treatment of vertebral compression fractures. In order to compare the curative effects between bolster for self-replacement combined with PVP and PKP, this study was underwent.

6. Materials and methods

6.1 Bolster for self-replacement combined with PVP

The clinical materials and therapeutic methods were uniformity with Part 1 to part 4.

6.2 PKP

Clinical materials

There were 18 men and 67 women in the 85 cases of VCF studied. Ages ranged from 47 to 94 years, with a mean of 75.03 ± 9.77 years. All cases had no neurological symptoms or signs of root damage. Pre-operative CR and CT scans of vertebra showed a complete posterior vertebral body.

Therapeutic methods

The operation was carried out under the surveillance of the C-arm, Thoracic and lumbar punctures were achieved through the lateral neck of vertebral. An anteroposterior fluoroscopy C-arm tube was used to adjust the angle, so that both lateral neck of vertebrals showed clearly, two Kirschner wires crossed and were fixed on the skin surface, the surface projection of lateral vertebral neck coincided with the intersection of the two Kirschner wires. The puncture point lay slightly outside and above, 1 ~ 1.5cm from the coincidence point. After local anesthesia, the transfixion pin and body sagittal appeared $15^\circ \sim 30^\circ$ angle, after the transfixion pin got into the lateral vertebral neck, then pushed the transfixion pin 1 ~ 2cm. Checking under lateral fluoroscopy to confirm correct transfixion point, Penetrated with slow rotation, so that the transfixion pin tip was in the central of vertebral body in the anteroposterior and the anterior 1 / 3 in the lateral; After reaming with hollow drill, gelatin sponge were filled, then balloon dilatation catheter was inserted slowly to anteroposterior and the anterior 1 / 3 of the vertebral body, pressurizing gradually. Vertebral bodies height recovered under the surveillance of the C-arm, balloon dilatation catheter exited. Then injected 4~6 mL cement into the vertebral body under fluoroscopy. When bone cement was near the posterior margin of the vertebral body, stopped pushing.

After injection, removed the pressure syringe, inserted and rotated the inner core needle. After about 3 ~ 5 minutes, pulled out the transfixion pin. These operation could ensure the needle not sticking together with the bone cement, and also could prevent the bone cement remaining in the transfixion pin because of premature pulling out.

6.3 Observed indexes

VAS Score, analgesic usage score, Oswestry disability index of functional, Cobb angle were observed pre-operation and 3 months after operation. Cement leakages were observed in the operation.

6.4 Statistical analysis

Numerical variables and ordinal variables were presented as mean \pm standard deviation (SD). The cement percolation rate were showed by percentage. Compared with the indicators by using SPSS18.0 for single-factor analysis of variance, A P value less than 0.05 was considered statistically significant.

7. Results

The statistical analysis were not statistically significant in the curative effects between bolster for self-replacement combined with PVP and PKP, the stata was showed in Table 3. The cement percolation rate of PKP was lower than that of bolster for self-replacement combined with PVP, the stata was showed in Table 4. Preoperative and postoperative X-ray films of PKP were shown in Figure 8-9.

Methods	Cases	VAS Score		antalgica usage score		Oswestry disability index		Cobb's angle	
		pre	post	pre	post	pre	post	pre	post
PVP	26	5.30±	0.2±	1.30±	0.10±	42.15±	8.96±	11.20±	9.9 0±
		0.02	0.01*	0.03	0.03*	0.89	1.38*	2.20	2.10**
PKP	85	6.77±	0.19±	1.73±	0.15±	41.88±	9.08±	21.14±	9.76±
		1.27##	0.98*#	0.45##	0.048*#	1.24#	1.16*#	1.49###	1.48*#

Note: Comparing with pre-operation, * P < 0.01, ** P > 0.05; Comparing with PVP using bolster, # P > 0.05, ## P < 0.05, ### P < 0.01

Table 3. The curative effects between PVP using bolster and PKP (x +s).

Methods	Cases	Percolation cases	percolation rate (%)	Cobb's angle before operation	Cement quantity (ml)
PVP	26	13	50.0	11.15±2.51	4.52±0.75
PKP	85	11	12.9###	21.15±1.49###	4.43±1.11#

Note: Comparing with PVP using bolster, ### P < 0.01, # P > 0.05.

Table 4. The cement percolation rate between PVP using bolster bolster and PKP.

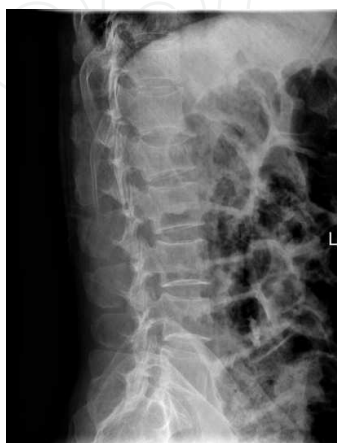

Fig. 8. Lateral X-ray before PKP.

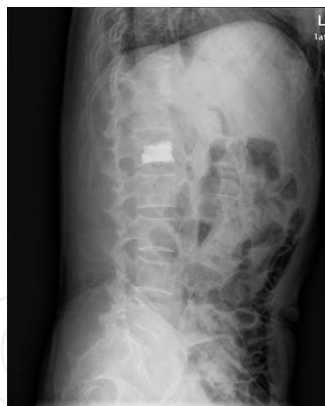

Fig. 9. Lateral X-ray after PKP.

8. Discussion

8.1 The role of bolster for self-replacement

As simple PVP treatment can not recover the lost height and has leakage or other shortcomings, balloon kyphoplasty (percutaneous kyphoplasty, PKP) has appeared in recent years. Although PKP can increase vertebral body height, and also reduce the leakage of bone cement into the vessel, therefore avoiding the formation of thrombosis^[8], it has some disadvantages. For example, it cannot control the direction of expansion and the compliance of the balloons in the vertebral body are not good enough, there is a 20% balloon rupture rate in the expansion process, it can only be used for fresh fractures^[9], while the price is relatively more expensive and many patients cannot afford. No balloon rupture appeared in our study, it may be because of that the sample size is not large.

While PKP is more relatively difficult than PVP in the operation, so PKP is subject to certain restrictions in the application. Therefore, PVP is still the most common method for VCF treatment. The restorations of thoracic and lumbar height mainly rely on the reposition of body position. The device resetting plays a role on the basis of reposition of body position and the main role is to maintain reduction^[10]. So before the operation we can restore the vertebral height gradually by traditional measures such as lying on the back on a hard wood bed with a bolster under the back and "five-point support method" which exercises lumbar-back muscular function (typically the recovery happens in 3 to 5 days, without the formation of trabecular malunion), then take the PVP treatment to compensate for the weakness in restoring vertebral height.

In addition, we used the method reported by some literatures^[11] that bone cement should be placed at -4 °C refrigerator for 5 ~ 10 minutes before operation to extend the operating time, thereby reducing the incidence of complications and obtaining good efficacy. In spite of with 50% cement percolation rate, no clinical symptoms were observed.

8.2 The curative effects between PVP using bolster and PKP

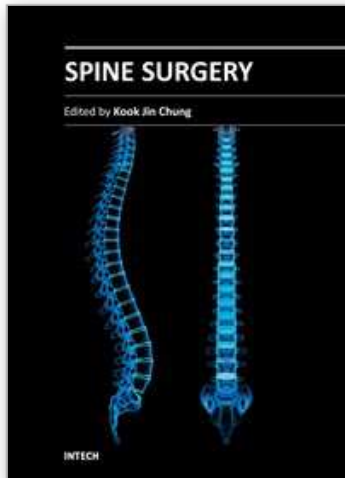
Simple PVP treatment can not recover the lost height of the vertebral body^[12]. Bolster for self-replacement can recover the lost height of the vertebral body before PVP. So PVP using bolster has the same effects comparing with PKP on reducing VAS Score, analgesic usage score, Oswestry disability index of functional, Cobb's angle^[13]. Because we found that

the effects of PVP using bolster have been stable from 3 months after operation, so we only compare the indexes before operation and 3 months after operation between PVP using bolster and PKP.

Because PVP using bolster has 50% cement percolation rate and balloon kyphoplasty has lower percolation rate (12.9%), broken instable VCF should be treated by balloon kyphoplasty first.

9. References

- [1] Tan ZJ, Xu JZ, Zhou Q. Experience and key point in vertebroplasty. *J Trauma Surg*, 2005,7:347-348.
- [2] Koessler MJ, Ebli N, Pitto RP. Fat and bone marrow embolism during percutaneous vertebroplasty. *Anesth Analg*, 2003,97:293.
- [3] Xu Y, Liu YJ, Dong Y. Classification, prevention and treatment of bone cement leakage following percutaneous vertebroplasty. *J Fourth Mil Med Univ*, 2006, 27: 155-157.
- [4] Wu Zhenping, Cheng Shaodan, Yang Hao, et al. Clinical research progress in interventional therapy of femoral head necrosis. *J Tradi Chin Orthop and Trauma*, 2003,15:630-631.
- [5] Li D, Yin YS, Liu W, et al. Experimental study on the different injectable material in vertebroplasty. *Chin Remedies & Clinics*, 2005,6(3):175-178.
- [6] Cheng Shao-dan, Mo Wen, Hu Zhi-jun, et al. Bone cement infusion and complications during percutaneous vertebroplasty. *Journal of Clinical Rehabilitative Tissue Engineering Research*. 2009,13(8):1593-1596
- [7] Mo Wen, Cheng Shaodan, Hu Zhijun, et al. The research on bolster for self-replacement combined with percutaneous vertebroplasty in treatment of vertebral compression fractures. *Chinese Journal of Osteoporosis*, 2008,14(12):903-907
- [8] Coumans JV, Reinhardt MK, Lieberman IH. Kyphoplasty for vertebral compression fractures: 1 year clinical outcomes from a prospective study. *J Neurosurg*, 2003,99(1S):44-50.
- [9] Lieberman IH, Dudeney S, Reinhardt MK, et al. Initial outcome and efficacy of kyphoplasty in the treatment of painful osteoporotic vertebral compression fracture. *Spine*, 2001,26:1631-1638.
- [10] Ma Yz, Zhen ZG. *Clinical Internal Fixation of Bone*. Anhui Science and technology publishing house, 1999:348-349.
- [11] Cheng Shaodan, Mo Wen, Shi Qi, et al. Research progress in percutaneous vertebroplasty curing vertebral fracture. *Chinese Journal of Osteoporosis*, 2007, 13(12):879-883.
- [12] Marek Szpalski, Robert Gunzburg. *Vertebral Osteoporotic Compression Fracture*. Lippincott Williams & Wikins, U.S.A, 2003.
- [13] Yu Zhixing, Mo Wen, Ma Junming, et al. A retrospective analysis about 111 cases of PVP/PKP in the treatment of thoracolumbar osteoporotic fractures. *Chinese Journal of Osteoporosis*, 2011,17(9):26-31.



Spine Surgery

Edited by Dr. Kook Jin Chung

ISBN 978-953-51-0469-8

Hard cover, 148 pages

Publisher InTech

Published online 28, March, 2012

Published in print edition March, 2012

"Spine Surgery" is an authoritative and didactic textbook on the various fields of spine. It is written by many authors, internationally honorable experts to share their opinions with you. The chapters cover from anatomy of spine, spinal imaging technique, biology of spine, bone graft substitute, minimally invasive spinal surgery to even spinal deformity. It has many up to date results to help readers including university graduate students, medical instrumentation developers, and medical professionals including orthopaedic and neurosurgeons, rehabilitative professionals. The readers are provided with precious information and valuable guide in your daily practice.

How to reference

In order to correctly reference this scholarly work, feel free to copy and paste the following:

Mo Wen, Cheng Shaodan and Hu Zhijun (2012). The Research on Bolster for Self-Replacement Combined with Percutaneous Vertebroplasty in Treatment of Vertebral Compression Fractures, Spine Surgery, Dr. Kook Jin Chung (Ed.), ISBN: 978-953-51-0469-8, InTech, Available from: <http://www.intechopen.com/books/spine-surgery/the-research-on-bolster-for-self-replacement-combined-with-percutaneous-vertebroplasty-in-treatment->

INTECH
open science | open minds

InTech Europe

University Campus STeP Ri
Slavka Krautzeka 83/A
51000 Rijeka, Croatia
Phone: +385 (51) 770 447
Fax: +385 (51) 686 166
www.intechopen.com

InTech China

Unit 405, Office Block, Hotel Equatorial Shanghai
No.65, Yan An Road (West), Shanghai, 200040, China
中国上海市延安西路65号上海国际贵都大饭店办公楼405单元
Phone: +86-21-62489820
Fax: +86-21-62489821

© 2012 The Author(s). Licensee IntechOpen. This is an open access article distributed under the terms of the [Creative Commons Attribution 3.0 License](#), which permits unrestricted use, distribution, and reproduction in any medium, provided the original work is properly cited.

IntechOpen

IntechOpen