

We are IntechOpen, the world's leading publisher of Open Access books Built by scientists, for scientists

4,800

Open access books available

122,000

International authors and editors

135M

Downloads

Our authors are among the

154

Countries delivered to

TOP 1%

most cited scientists

12.2%

Contributors from top 500 universities



WEB OF SCIENCE™

Selection of our books indexed in the Book Citation Index
in Web of Science™ Core Collection (BKCI)

Interested in publishing with us?
Contact book.department@intechopen.com

Numbers displayed above are based on latest data collected.

For more information visit www.intechopen.com



Correction of Inverted Nipple: Comparison of Techniques with Novel Approaches

Ercan Karacaoglu

*Yeditepe University/School of Medicine Department of Plastic Surgery
Turkey*

1. Introduction

The nipple is of tremendous importance as a visual and sexual focus of the female body. As a third focus, the nipple has a nutritive function as in breastfeeding basis. That is why body image, sexuality and breastfeeding are adversely affected by its abnormal conditions.

In order to achieve a successful breast-feeding, an infant needs to suck the whole bulk of nipple and almost hundred to eighty percentage of the areola. That is why abnormal nipple conditions such as inverted nipple may result in problems with starting, establishing and maintaining breast-feeding (Hyttén 1954). Nipple inversion may cause cosmetic, functional, and psychological problems. Some of the physical signs may be irritation, inflammation, and interference with breast-feeding (Kim et al., 2003).

Inverted nipple is defined as a non-projectile nipple (Sanghoo & Yoon, 1999; Kim et al., 2003; Stevens et al., 2004) (Fig 1). The nipple is located on a plane lower than the areola. The nipple is invaginated and instead of pointing outward, is retracted into the breast parenchymal and stromal tissue.

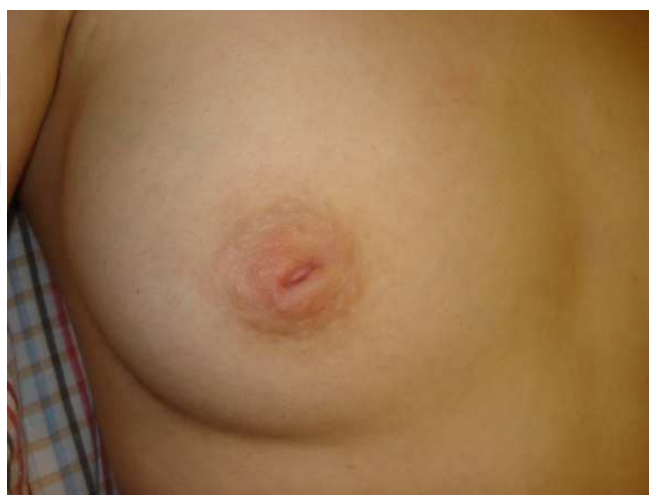

Fig. 1. A 24-year-old nulliparous woman with a history of congenital inverted nipple is seen. AP view.

The terms retraction and inversion often are used interchangeably, but such usage is inexact. Retraction is properly applied when only a slit shape area is pulled inward, whereas inversion applies to cases in which the entire nipple is pulled inward occasionally, far enough to lie below the surface of the breast (Nicholson et al, 2009). Inverted nipple may be seen in different forms and structures related to the severity of fibrosis, lack of soft tissue bulk, and lactiferous ductus. In some cases, the nipple may be temporarily protruded if stimulated, but in others, the inversion remains regardless of stimulus.

Inverted nipple is not an uncommon deformity. It was first described by Cooper in 1849 and surgical repair of the inverted nipple was first described by Kehrer in 1888 (Sanghoo & Yoon, 1999, 4).

The nipple is the symbol of the female body with the breast. It is why nipple inversion adversely affects a woman's self-esteem and why they often seek correction of it.

2. Anatomy of the nipple and areola: Nipple-areolar complex

The anatomy of nipple-areola is complex. It is therefore not surprising that the detection of disorders of the nipple-areolar region may be challenging. Although the scope of this chapter is inverted nipple a thorough understanding of anatomic variants of this complex, and the imaging features specific to each is the necessary basis for a comprehensive and appropriate imaging assessment, diagnosis, and treatment. It should also be kept in mind that concurrent benign and pathologic conditions of this complex could be a fact of possibility.

Age is also a variant of nipple areola complex anatomy. It is key to understand the maturation of breast in order to evaluate the abnormal consequences of nipple areola complex. During puberty, the breast mound increases in size. Subsequent enlargement and outward growth of the areola result in a secondary mound (Seltzer, 1994). Eventually, the areola subsides to the level of the surrounding breast tissue, leaving a single breast mound (Seltzer, 1994; Michael, 1991). At full development, the nipple-areolar complex overlies the area between the 2nd and 6th ribs, with a location at the level of the 4th intercostal space being typical for a breast that is not ptotic. The adult breast consists of approximately 15–20 segments demarcated by mammary ducts that converge at the nipple in a radial arrangement. Like the number of segments, the number of mammary ducts may vary. The collecting ducts that drain each segment, which typically measure about 2 mm in diameter, coalesce in the subareolar region into lactiferous sinuses approximately 5–8 mm in diameter (Kopans, 2007). Women occasionally detect a normal lactiferous sinus as a palpable finding at self-examination. In the typical breast, there are 9–20 orifices that drain the segments at the nipple (Kopans 2007, Love 2004).

The nipple-areolar complex contains the Montgomery glands, large or intermediate-stage sebaceous glands that are embryologically transitional between sweat glands and mammary glands and are capable of secreting milk (Kopans, 2007). The Montgomery glands open at the Morgagni tubercles, which are small (1–2-mm-diameter) raised papules on the areola. The nipple-areolar complex also contains many sensory nerve endings, smooth muscle, and an abundant lymphatic system called the subareolar or Sappey plexus. Because the skin of

the nipple is continuous with the epithelium of the ducts, cancer of the ducts may spread to the nipple (Kopans 2007).

3. Classification, grading and pathologic basis of the deformity

Nipple inversion can be either acquired or congenital.

Acquired inverted nipple: Nipple inversion secondary to the previous breast surgery, infiltrating ductal carcinoma, and mastitis are examples of the acquired types.

Congenital inverted nipple: Congenital inverted nipple is the most frequent type. The prevalence is reported as 2-10% (Lee et al., 2003; Alaxander & Campbell 1997).

Congenital inverted nipple is clinically classified into three groups:

1. Grade I nipple can be easily pulled out manually and maintains its projection quite well without traction. The nipple is popped out by gentle palpation around the areola. The soft tissue is intact in this form and the lactiferous ducts are normal.
2. Grade II nipple is also popped out by palpation but not as easily as in grade I. The nipple tends to retract. The nipple has moderate fibrosis and the lactiferous ductus is mildly retracted but does not need to be cut to release the fibrosis. These nipples have been shown to have rich collagenous stromata with numerous bundles of smooth muscle.
3. Grade III nipple is a severe form in which inversion and retraction are significant. Manually popping out the nipple is extremely difficult. A traction suture is needed to keep these nipples protruded. The fibrosis beneath the nipple is significant and the soft tissue is markedly insufficient. On histologic examination, the terminal lactiferous ductus and lobular units are atrophic and replaced with severe fibrosis (Sanghoo & Yoon, 1999, Kim et al., 2003)

4. Management

Numerous techniques have been reported to correct the inverted nipple (Alaxander & Campbell, 1997; Kim et al., 2006; Serra-Renom et. Al, 2004; Jiang et al., 2008; Yamada et al., 2004; Ritz et al., 2005; Huang , 2003; Crestinu, 2001; Pompei & Tedesco, 1999) It was also reported that no single technique is appropriate for correcting all types of nipple deformities because different grades of inverted nipple have different levels of fibrosis, soft tissue bulk, and lactiferous ductus structure (Lee et al., 2003).

The best approach for correction is described as simple and reliable. In addition, a technique with low recurrence rate, with less or no scar, that requires no bulky or special dressing, and that preserves lactiferous ductus function is desirable (Kim et al., 2003).

Here, you will find the most useful techniques used to correct inverted nipple.

4.1 Antenna flap technique (Karacaoglu, 2009)

In this chapter a novel technique for the repair of recurrent grade III inverted nipple is also described in detail. In this technique, dermo adipose flaps that were generated within the area of de-epithelialization during mastopexy were used. The flap is called the "antenna flap" because of its way of design.

Preoperative Marking: Preoperative planning started with the patient standing. The preliminary marking was identical to that for circumvertical mastopexy. The midline, breast meridian with its extrapolation on the chest wall, and the inframammary fold were marked. The lateral and medial markings were made while pushing the breast laterally and medially with an slight upward rotation, in accordance with the vertical axis drawn below the breast. The new areola was then marked in a classical dome shape. Finally, the lower marking was made. This joined the medial and lateral markings at a level 2 cm above the preexisting fold. The marked area below the areola was used to mark the antenna flap. Marking was done to optimally use the existing de-epithelialization area (Fig. 2, 3).

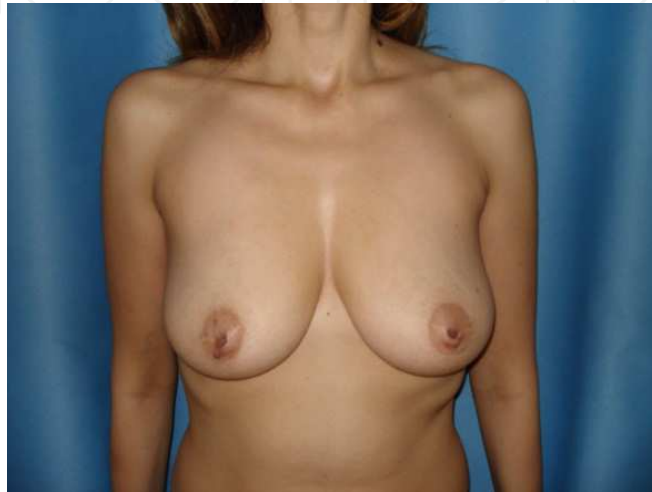

Fig. 2. A woman with a history of congenital inverted nipple is seen. AP view.

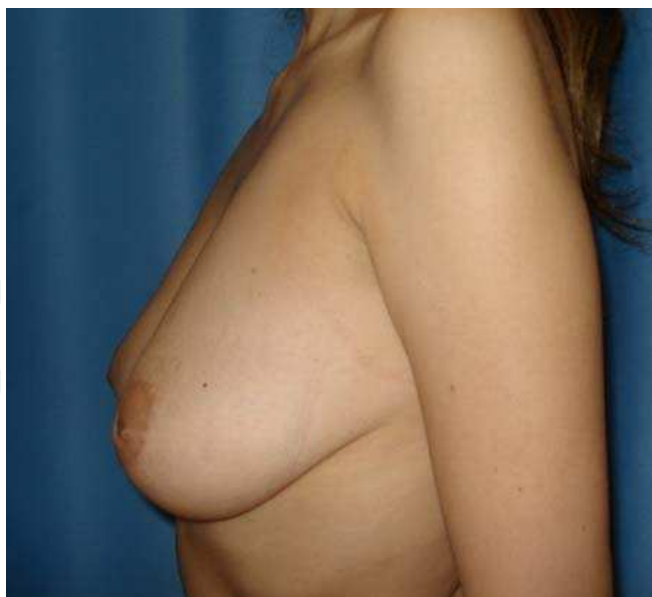

Fig. 3. Lateral view of the same woman in Fig 2.

Surgical Technique: The operative sequence for augmentation mammoplasty was more straightforward. The marked area below the areola was de-epithelialized. Antenna flaps were marked on this area (Fig. 4).

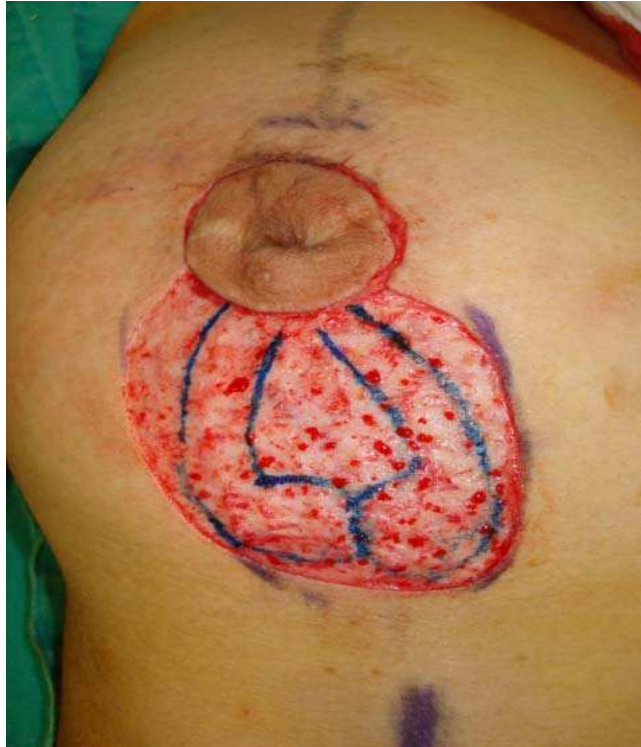

Fig. 4. The marked area below the areola was de-epithelialized. Antenna flaps were marked on this area.

Flaps were elevated to include dermis and 5 mm of fat tissue beneath and attached to the dermal flap using an electrocautery (Fig. 5).

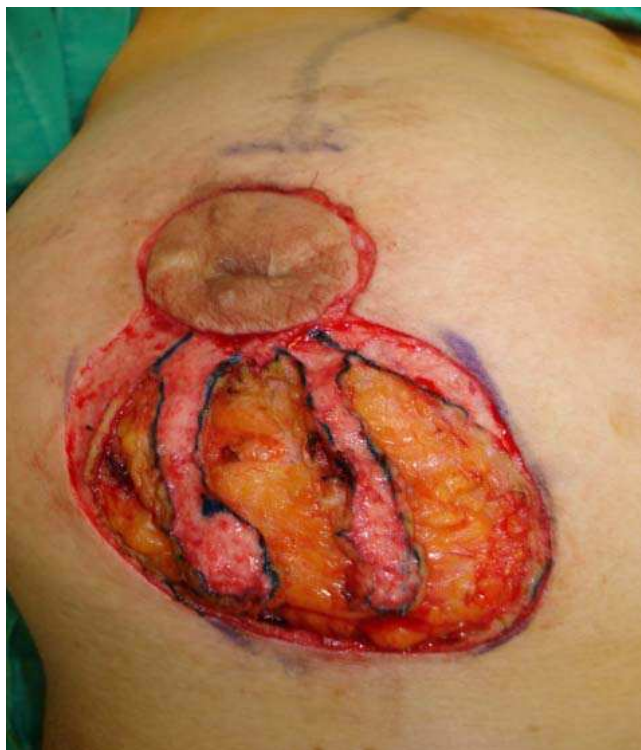

Fig. 5.

These flaps were left intact and the procedure went on with augmentation mastopexy. The breast parenchyma and adipose tissue below the nipple-areola complex were removed within the limits of the markings. A pocket was created in the submuscular space. Once the implant was placed in the pocket, the preliminary markings around the areola and the lateral and medial markings below the areola were reevaluated. Once the implant was in place the nipple position and planned vertical breast closure are tailor-tacked with staples with the patient in a sitting position. A slight flattening of the lower pole was allowed for parenchyma and skin accommodation postoperatively. The edges of the vertical temporary closure were marked and staples removed. The amount of excess skin that could be comfortably removed in the vertical closure was thus determined. At this stage, the de-epithelialization of the skin around the areola and within the medial and lateral markings was completed. Vertical incisions were closed by using 3-0 Monocryl suture (Ethicon Inc., Somerville, NJ). A pocket was created for the transposition of the antenna flaps. For that purpose a 0.5-cm vertical incision was made at the 6 o'clock position at the base of the areola. A tunnel was dissected at and through the areola and extended to the base of the nipple. The tissue beneath the nipple was dissected and the fibrosis was released. The retracting lactiferous ducts were cut mainly from the central portion of the nipple. All the fibrosis and retracting ducts were released until the nipple could maintain its eversion by itself without any traction. Two legs of the antenna flap were inserted into the created pocket (Fig. 6). A satisfactory projection of the nipple was seen at the end of the procedure.

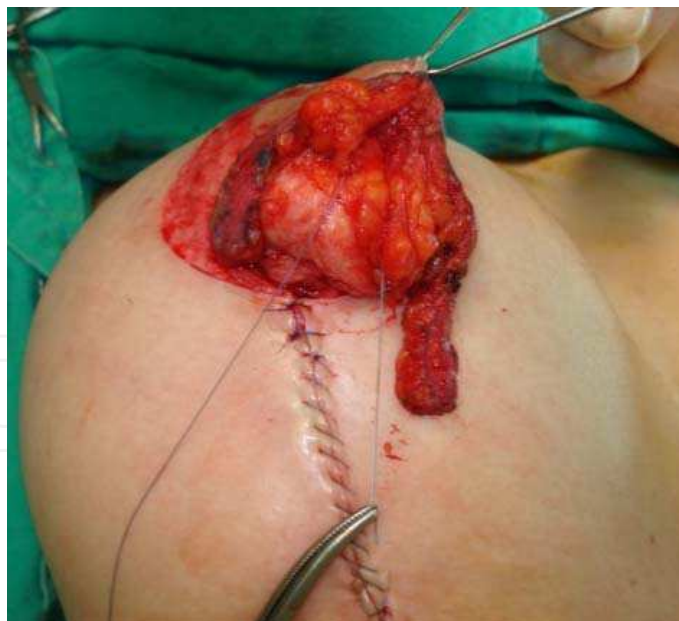

Fig. 6. A satisfactory projection of the nipple was seen at the end of the procedure.

Finally, the periareolar incisions were closed in layers. The periareolar portion was closed in a purse-string fashion by using 3-0 Gore-Tex suture (Gore & Assoc. Inc., Elkton, MD) (Fig. 7). After placement of Steri-strip dressing the newly everted nipple was maintained by a thermoplast splint. The patient was kept in a protective splint for 3 months after surgery.

It has been reported that the patients tolerated the procedure well. No major vital complications like major flap or nipple necrosis has been reported with this technique. In this technique, a high rate of success has been reported that no recurrence of nipple inversion after one and a half-year reported. As of patient satisfaction the technique seems promising that the shape and projection of the patient's nipple was deemed satisfactory (Fig. 8, 9).

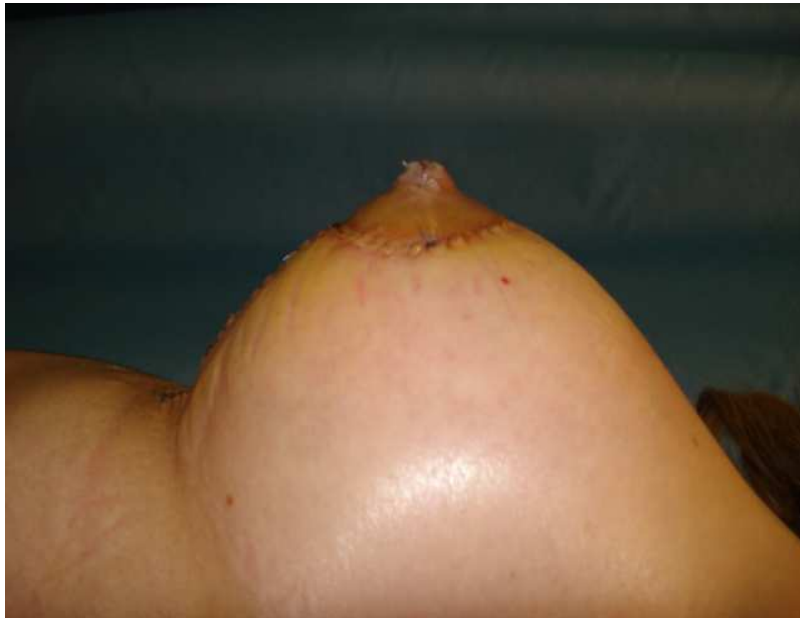

Fig. 7. Early postoperative result is seen.

The surgical approach presented in this chapter is even an option for correcting a recurrent, congenital inverted nipple. It also should be emphasized that even an alloplastic material could not have corrected the deformity in this particular case. As two other techniques had already been used to correct this deformity in previous surgeries, a new technique named the antenna flap was used. This technique entails transposition of bulky dermo-adipose flaps harvested from the de-epithelialized area of the mastopexy into the pocket created beneath the nipple.

In this technique the dead space was filled with autologous tissue where possible complications such as extrusion that is seen with alloplastic materials were avoided. One of the advantages of this technique was the lack of scar in the areola. The disadvantage of the technique is that it is limited to those patients who are candidates for mastopexy.

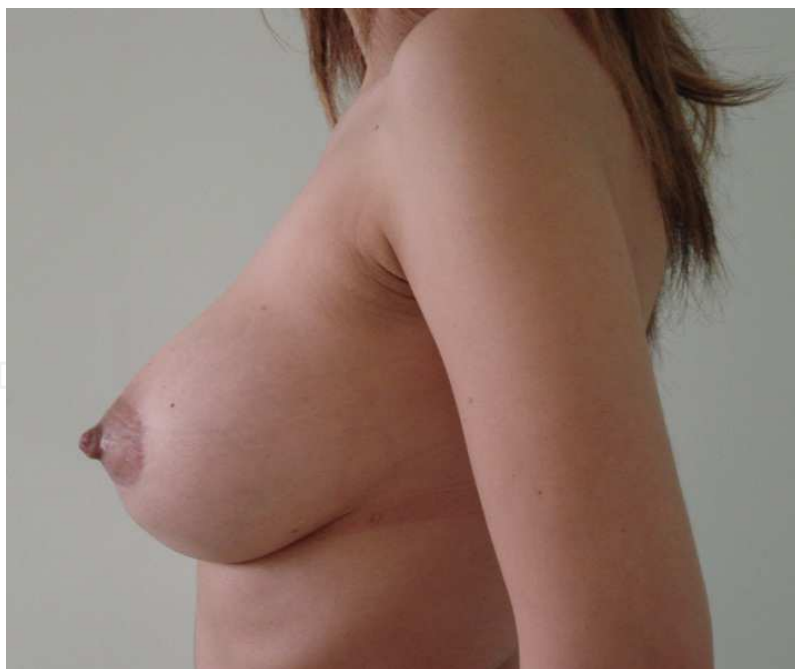
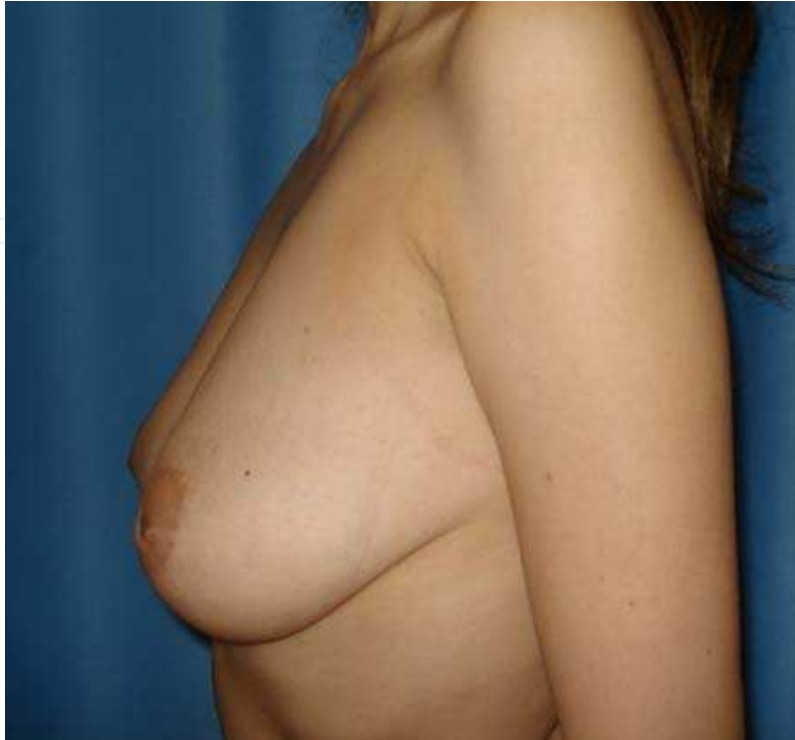

Fig. 8 and 9. As of patient satisfaction the technique seems promising that the shape and projection of the patient's nipple was deemed satisfactory. Patient's lateral view before and 3 years after surgery

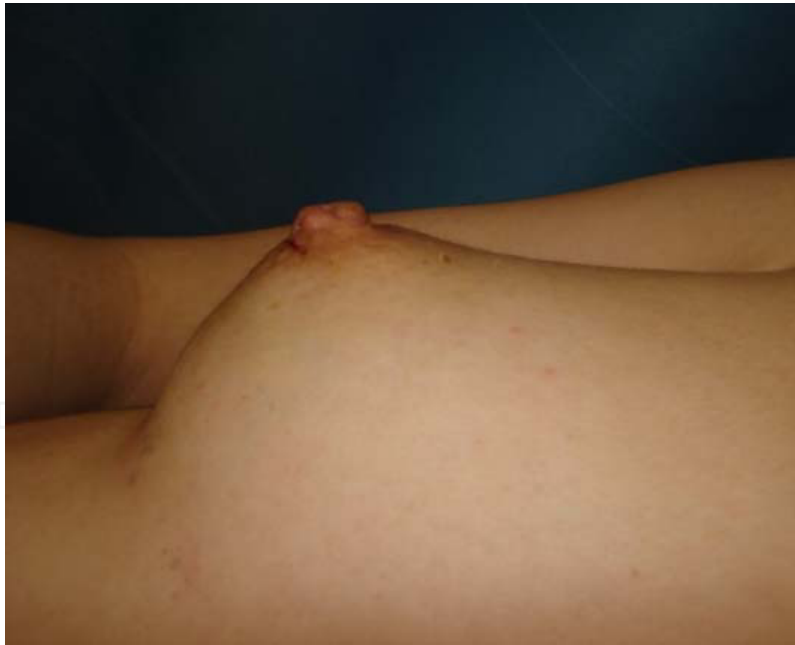
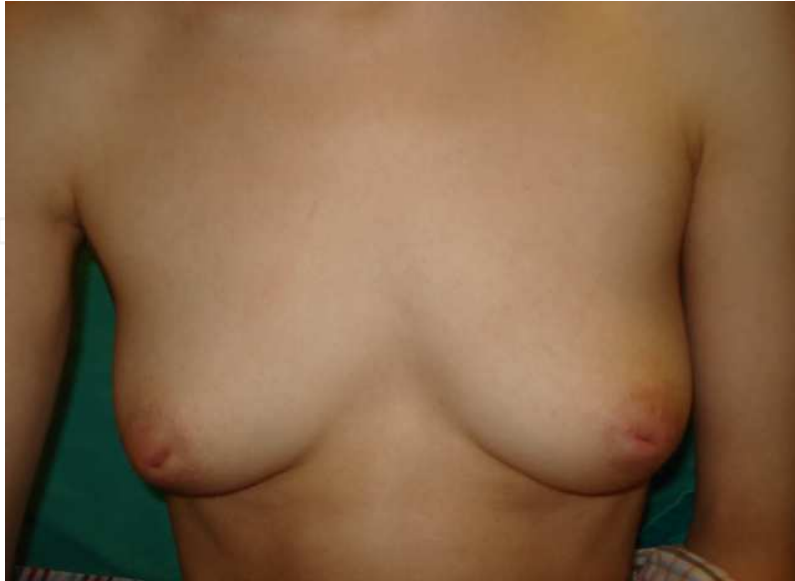
Fig. 10 and 11. A 24year-old nulliparous woman with a history of congenital inverted nipple is seen before and 4 years after surgery.

Author was used this technique in fourteen cases since its description. All patients were happy with the results. No major complications were reported. Only in two cases suture abscesses formation was reported.

As a conclusion, new vascularized tissue brought under the nipple-areola complex to correct recurrent inverted nipple yields a safe and better projection. This technique yields a satisfactory result without recurrence of inversion in fourteen cases. It is strongly recommended that the technique should be considered by the surgeon for any patient contemplating correction of inverted nipple and mastopexy.

4.2 Twisting and locking technique (Kim et al., 2006)

The corrective operation, based on twisting and locking principles, was described for various patterns of inverted nipple, ranging from the grade 1 to the grade 3 (Kim et al., 2006). One of the disadvantages of this technique is about the restriction for the color of the areola. Patients with a pale colored areola or an areola with smaller diameter are not considered appropriate for this technique as a quite a decent amount of areolar tissue is required for the operative technique.

Preoperative Marking: Three diamond-shaped patterns are marked on three concentric circles drawn at the areola, with intervals of 120 degrees.

Surgical Technique: The inner tip of each diamond design is expected to be a margin of the nipple tip, and its width could be controlled for primary closure after nipple protrusion. With closure of the diamond design, the lateral wall of the nipple is formed from the inner side of the design. Therefore, the height of the nipple is determined by the length of the inner side, and the degree of nipple protrusion depends on the inner acute angle of the design. The designed pattern is mostly diamond shaped, and the inner sides are shorter than the outer sides. The lengths of the inner sides should be designed to be equal to the outer sides to make a prominent nipple with a small areola. The exact measurements of the design depends on the size of the nipple and areola of each individual patient. Deepithelialization is performed on the designed area. Three triangular dermal flaps are created and elevated from each deepithelialized area with their bases attached to the nipple. In addition, with temporary traction of the nipple apex provided by a stay suture, the fibrotic bands underneath the nipple base are sufficiently but cautiously released to make a tunnel to minimize injury to the lactiferous ducts. The elevated dermal flaps are passed through the space released underneath the nipple base, pulled out, and sutured firmly with an absorbable suture to the opposite dermis of the neighboring deepithelialized defect.

With this key fixation suture, a twisting effect is created at the nipple base to keep the nipple protruded, and the omega shape of the nipple is finally formed. It is considered that each dermal flap acted as a locking barrier at the nipple base to prevent reinversion. Each deepithelialized defect is easily closed without tension by minimal undermining because of the twisting effect. In some cases, modification is available for easier closure of the defect with a small triangular skin flap that remained during the deepithelialization procedure. The twisting effect created by anchoring dermal fixation makes it possible to form the desirable omega-shaped nipple with a narrow nipple neck and also is expecting to prevent flattening of the nipple.

4.3 Triangular areolar dermal flaps technique (Kim et al, 2003)

Kim et al. introduce an alternative, simple method using 2 triangular areolar dermal flaps. Compared with other methods using triangular areolar dermal flaps, each triangle is approximately 1 mm shorter than the diameter of the nipple, and the deepithelialized areolar dermal flaps are lodged at the slit in the bundle of the lactiferous ducts in the grade 2 inverted nipple. Authors were treated 11 patients (16 nipples) where five patients had bilateral inverted nipples. Patient ages were reported as ranged from 18 to 31 years (mean age, 27 years). All nipples were congenital and they had no previous operation. Thirteen nipples were grade 2 and 3 were grade 3. The mean follow-up period was 8.7 months (range, 3-12 months). Follow-up examinations revealed no evidence of recurrence of inversion. There was no complication associated with surgery, such as infection, hematoma, permanent sensory disturbance, or nipple necrosis. The resulting scars were minimal. All patients were satisfied with their results. The authors conclude that their procedure is reliable, preserves the lactiferous ducts in grade 2 inverted nipple, requires no special postoperative care, and leaves minimal scars and no recurrence of inversion. This technique can be applied to any type of inverted nipple as a primary surgical procedure.

Preoperative marking: The width of the nipple is measured and the design is marked with methylene blue. A circle is drawn around the nipple neck and two triangular flaps- where the bases of which are located on the circle around the nipple neck, are designed at 3 o'clock and 9 o'clock. The marking is completed to assure the following key points: the base of the triangle is approximately 9 to 12 mm, depending on the diameter of the nipple. Each triangle is usually within the areolar margin, is approximately 1 mm shorter than the diameter of the nipple.

Surgical Technique: A traction suture is placed to the nipple strong enough to perform the procedure. The incisions are made at the triangles. On the side of the triangles, the incisions are deepened into the subcutaneous fatty tissue, but limited to the upper dermal layer on the bases of the triangles so the areolar dermal flap is based medially. The triangles are then deepithelialized, and the areolar dermal flaps are raised leaving the subcutaneous fat to the flaps. While traction is applied to the nipple the tethering fibrous tissue bands are identified and transected to free the nipple. A non-absorbable suture is put into the tip of each areolar dermal flap. Using a small pick up each suture is pulled out through the slit under the opposite areolar dermal flap. Pulling the absorbable sutures the areolar dermal flaps are turned down and pulled through the slit so that they cross each other within it. The sutures are stitched to the lower dermis of the nipple base just beside each of the opposite elevated triangular flaps. The donor areas are closed without undermining with the two layers and then the traction suture is removed from the nipple.

4.4 Internal 5-point star suture technique (Serra-Renom et al, 2004)

Some of the methods reported for the surgical treatment of the inverted nipple include insertion of autologous or heterologous material to provide volume and projection to the nipple, thereby avoiding recurrence. In this technique, the authors described the use of a surgical technique for grade III inverted nipple in which the nipple remains protruded when it is pulled out, and sectioning of the lactiferous ducts and an internal 'star' stitch to avoid both nipple collapse and introduction of heterologous filling material.

Surgical technique: In cases of severely inverted nipple with severe fibrosis and shortening of the lactiferous ducts, the authors' technique combines the pulling out of the nipple and the release of the fibrosis and retracting ducts with the introduction of a stitch of polyglactin as filling material, performing an internal star suture in only one surgical intervention, without the need for using graft material, or local flaps that introduce scars around the nipple. The technique is simple. The results are deemed satisfactory.

4.5 Other techniques

-Nipple aspirator (Jiang et al, 2008):

A self-designed instrument for inverted nipple was described by Jiamg et al.

-Correcting an inverted nipple with an artificial dermis (Yamada et al, 2004):

This report describes and incorporates a new concept of using artificial dermis for tissue augmentation and is performed without sacrificing any donor site and complex design. It was applied to four nipples in two nulliparous cases. For all four corrected inverted nipples, good results were reported with no complications. No deformities of the nipple or the areola were reported and as an advantage of the technique the surgical scars were reported as inconspicuous.

-Internal sidewall suturing technique: (Lee et al., 2003)

The authors described a simple technique for providing long-term correction for the grade III severely inverted nipple without the use of dermal flaps.

Surgical technique: An inferior periareolar incision extending from 5 o'clock to 7 o'clock was made, and a periareolar flap was raised to the nipple. A 3-0 nylon suture was placed through the nipple, after which the nipple was everted through complete release of all fibrous bands and tethering attachments. We accomplished long-term eversion of the nipple by suturing the internal sidewalls of the nipple together. This technique has been performed in 17 patients. No recurrence was reported even 1 year after surgery.

The technique for treatment of the inverted nipple is simple to perform and seems to provide reliable, long-term Correction (Lee et al., 2003).

-Three Periductal Dermofibrous Flaps (Huang, 2003)

The inverted nipple may be congenital or caused by repeated inflammation and breast surgery. The reported prevalence of congenital inverted nipple ranges from 1.77% (Sanghoo & Yoon, 1999) to 3.26%, and most of them are bilateral and umbilicated (Kim et al., 2003). The inversion has been linked to many aesthetic, functional, and psychological problems. Many methods have been proposed to correct this deformity since the first surgical correction by Kehrer in 1879. I propose a new method with three periductal dermofibrous flaps to add bulk to the nipple base and to form a hammock to prevent recurrence. The design also shortens the circumference of the root of the nipple without compromise of the neurovascular supply. We have corrected 46 nipples of 25 patients with this method successfully since 1996. This method can be applied to all types of inverted nipple without significant complications.

5. Conclusion

Various procedures have been proposed for the repair of inverted nipple since it was first described (Alexander & Campbell, 1997; Kim et al., 2006; Serra-Renom et al., 2004; Jiang et al., 2008; Yamada et al., 2004; Ritz et al., 2005; Huang, 2003; Crestinu, 2001; Pompei & Tedesco, 1999). No single technique is appropriate for correcting all the types of nipple deformities because different grades of inverted nipple have different levels of fibrosis, soft tissue bulk, and lactiferous ductus structure (Lee et al., 2003). Some of the techniques include construction at the base of the nipple by using areolar dermal flaps (Kim et al., 2003; Kim et al., 2006; Huang 2003) modified suturing "t" (Stevens et al., 2004; Serra-Renom, 2004) or a combination of these two (Pompei & Tedesco, 1999) to prevent the collapse of the nipple. Other techniques use alloplastic materials, i.e., silicone or PTFE, where extrusion is a potential complication; they have their own limitations (Serra-Renom, 2004).

The novel surgical approach of Karacaoglu, *antenna dermal flap Technique*, presented in this chapter is for correcting a recurrent, congenital inverted nipple. It also should be emphasized that even an alloplastic material could not have corrected the deformity in this particular case. The patient was also asking for breast augmentation and lifting in addition to correction of her recurrent inverted nipple. As two other techniques had already been used to correct this deformity in previous surgeries, a new technique named the antenna flap was used. This technique entails transposition of bulky dermo adipose flaps harvested from the de-epithelialized area of the mastopexy into the pocket created beneath the nipple. The shape and projection of the patient's nipple was deemed satisfactory. In this technique the dead space was filled with autologous tissue where possible complications such as extrusion that is seen with alloplastic materials were avoided. This technique allowed for correction of ptosis and breast augmentation in the same surgical procedure. Combining the three procedures did not adversely affect the results of each procedure. One of the other advantages of this technique was the lack of scar in the areola. The disadvantage of the technique is that it is limited to those patients who are candidates for mastopexy.

As a conclusion, new vascularized tissue brought under the nipple-areola complex to correct recurrent inverted nipple yields a safe and better projection. This technique yields a satisfactory result without recurrence of inversion and is encouraged to use by the surgeons for any patient contemplating correction of inverted nipple and mastopexy.

6. References

- Alexander JM, Campbell MJ. Prevalence of inverted and non-protractile nipples in antenatal women who intend to breastfeed. *Breast* Vol. 6, (1997), pp72-78.
- Crestinu JM The correction of inverted nipples without scars: 17 years' experience, 452 operations. *Aesthet Plast Surg*, Vol. 25, No. 3, (2001) p246-248.
- Huang WC A new method for correction of inverted nipple with three periductal dermofibrous flaps. *Aesthet Plast Surg*, Vol. 27, No. 4, (2003), pp 301-304.
- Hytten F.E. Clinical and chemical studies in human lactation; IX breast-feeding in hospital. *Br. Med. J*, Vol. 2, No. 2, (December 1954), pp. 1447-1452.
- Jiang HQ, Wei X, Yuan SM, Tang LM Nipple aspirator: a self-designed instrument for inverted nipple. *Plast Reconstr Surg* Vol. 121, No. 3, (2008), pp 141e-143e.

- Karacaoglu, E. Correction of Recurrent Grade III Inverted Nipple with Antenna Dermoadipose Flap: Case Report. *Aesth Plast Surg* (2009), Vol. 33, pp 843–848.
- Kim JT, Lim YS, Oh JG Correction of inverted nipples with twisting and locking principles. *Plast Reconstr Surg* Vol. 118, No. 7, (2006), pp 1526–1531.
- Kim DY, Jeong EC, Eo SR, Kim KS, Lee SY, Cho BH. Correction of inverted nipple: an alternative method using two triangular areolar dermal flaps. *Ann Plast Surg* Vol 51, No. 6, (2003) pp.636–640.
- Kopans D. (2007) Breast anatomy and basic histology, physiology, and pathology. In: *Breast Imaging*, Kopans D, ed.. 3rd ed. 7–43, Lippincott Williams & Wilkins, ISBN: 978-1-4419-1728-7, Philadelphia
- Lee MJ, DePolli PA, Casas LA Aesthetic and predictable correction of the inverted nipple. *Aesthet Surg J* Vol 23, (2003), pp 353–356.
- Love SM, Barsky SH. Anatomy of the nipple and breast ducts revisited. *Cancer* Vol. 101, (2004), pp1947–1957.
- Pompei S, Tedesco M A new surgical technique for the correction of the inverted nipple. *Aesthet Plast Surg*, Vol. 23, No. 5, (1999), pp 371– 374.
- Nicholson BT, Harvey JA, Cohen MA. Nipple-areolar complex: normal anatomy and benign and malignant processes. *Radiographics*. Vol.2, No 29, (March-April 2009), pp. 509-523. Doi10.1148/rg.292085128
- Osborne MP. (1991) Breast development and anatomy. In: *Breast Diseases*, Harris J, Hellman S, Henderson I, Kinne D, eds. 2nd ed. 1-13, Lippincott, ISBN: 978-0-7817-9117-5, Philadelphia
- Ritz M, Silfen R, Morgan D, Southwick G Simple technique for inverted nipple correction. *Aesthet Plast Surg*, Vol. 29, No. 1, (2005), pp 24–27.
- Sanghoo H, Yoon H. The inverted nipple: its grading and surgical correction. *Plast Reconstr Surg* Vol. 104, No. 2, (1999) pp.389–395.
- Seltzer V. The breast: embryology, development, and anatomy. *Clin Obstet Gynecol*, Vol. 37 (1994), pp879–880.
- Serra-Renom J, Fontdevila J, Monner J Correction of the inverted nipple with an internal 5-point star suture. *Ann Plast Surg*, Vol. 53, No. 3, (2004), pp 293–296.
- Stevens WG, Fellows DR, Vath SD, Stoker DA An integrated approach to the repair of inverted nipples. *Aesthet Surg J* Vol. 24, (2004), pp 211–215.
- Yamada N, Kakibuchi M, Kitaoshi H, Kurokawa M, Hosokawa K, Hashimoto K. A method for correcting an inverted nipple with an artificial dermis. *Aesthetic Plast Surg*. 2004 Jul-Aug;28(4):233-8.



Current Concepts in Plastic Surgery

Edited by Dr. Frank Agullo

ISBN 978-953-51-0398-1

Hard cover, 264 pages

Publisher InTech

Published online 23, March, 2012

Published in print edition March, 2012

Plastic surgery continues to be a rapidly growing field in medicine. There have been multiple recent advancements in the field. Specifically, there has been a continuously growing interest in fat grafting, body contouring, minimally invasive surgery, and plastic surgery education. At the same time, there have been continued advances and modifications in surgical techniques, which translate into better and improved results for our patients while increasing safety and efficacy. The title of the book is Current Concepts in Plastic Surgery and, as such, it highlights some of the "hot topics" in recent years. We have invited renowned specialists from around the world to share their valued expertise and experience. Most of the chapters will expose the reader to multiple techniques for achieving desired results, with emphasis on the author's preferred methodology.

How to reference

In order to correctly reference this scholarly work, feel free to copy and paste the following:

Ercan Karacaoglu (2012). Correction of Inverted Nipple: Comparison of Techniques with Novel Approaches, Current Concepts in Plastic Surgery, Dr. Frank Agullo (Ed.), ISBN: 978-953-51-0398-1, InTech, Available from: <http://www.intechopen.com/books/current-concepts-in-plastic-surgery/correction-of-inverted-nipple-comparison-of-techniques-with-novel-approaches>

INTECH
open science | open minds

InTech Europe

University Campus STeP Ri
Slavka Krautzeka 83/A
51000 Rijeka, Croatia
Phone: +385 (51) 770 447
Fax: +385 (51) 686 166
www.intechopen.com

InTech China

Unit 405, Office Block, Hotel Equatorial Shanghai
No.65, Yan An Road (West), Shanghai, 200040, China
中国上海市延安西路65号上海国际贵都大饭店办公楼405单元
Phone: +86-21-62489820
Fax: +86-21-62489821

© 2012 The Author(s). Licensee IntechOpen. This is an open access article distributed under the terms of the [Creative Commons Attribution 3.0 License](#), which permits unrestricted use, distribution, and reproduction in any medium, provided the original work is properly cited.

IntechOpen

IntechOpen