

We are IntechOpen, the world's leading publisher of Open Access books Built by scientists, for scientists

4,800

Open access books available

122,000

International authors and editors

135M

Downloads

Our authors are among the

154

Countries delivered to

TOP 1%

most cited scientists

12.2%

Contributors from top 500 universities



WEB OF SCIENCE™

Selection of our books indexed in the Book Citation Index
in Web of Science™ Core Collection (BKCI)

Interested in publishing with us?
Contact book.department@intechopen.com

Numbers displayed above are based on latest data collected.

For more information visit www.intechopen.com



Contralateral Breast Augmentation in Heterologous Breast Reconstruction

Paolo Persichetti, Barbara Cagli, Stefania Tenna, Luca Piombino,
Annalisa Cogliandro, Antonio Iodice and Achille Aveta
*Campus Bio-Medico University
Plastic Surgery Department, Rome
Italy*

1. Introduction

Breast cancer is the most frequent, after skin cancer, in women in industrialized countries, and is the leading cause of cancer morbidity and mortality. The latest epidemiological data in USA, updated in 2010, reported 207,090 new cases of breast cancer with a death toll of 39,840. (National Cancer Institute US). This disease is highly debilitating, even in the treatable forms, due to the emotional and psychological implications that come with it: even though it's not an organ essential to life, the breast is, in all cultures of the world, the deepest and purest expression of femininity, a pivotal aesthetic element, symbol of sexual and psychological identity and seduction. At the time of diagnosis the woman faces, on one hand a real threat to her survival and safety, and on the other the fear of witnessing her body image being irreversibly altered. Therefore in recent years, the need to provide the possibility for a breast reconstruction treatment after total mastectomy, in addition to specific treatment procedures for such tumors, has become increasingly pressing. The objective of post-cancer breast reconstruction is to restore the importance of the breast and maintain a good quality of life with no effect on the prognosis or the monitoring for tumor recurrence. Numerous studies confirm that breast reconstruction not only restores the body image, but it improves vitality, femininity and sexuality and has a positive effect on the sense of well being and quality of life of the patient. Modern breast reconstruction has seen many technical advances, which has provided valuable tools to the plastic surgeon for such procedures, including: improved models of silicone and saline breast implants, tissue expanders and the identification of several muscle-skin flaps that can provide well-vascularized tissue for breast reconstruction, as well as the tendency to perform modified total mastectomy as opposed to total mastectomy. Each surgical technique can be used both, for the delayed reconstruction (secondary), and for the immediate reconstruction, one that is performed at the same time as the mastectomy.

Nowadays acellular dermal matrices (ADMs) are being used for increasingly wider applications in breast reconstruction, both in primary and revision implant-based reconstructive procedures. ADM is helpful in subpectoral implant-based reconstruction, where it can be used as an interposition substrate between the released origin of the pectoralis major muscle and the inframammary fold (IMF).

Breast reconstruction with implants is the most frequently used technique after mastectomy. About 70% of breast reconstructions are performed using heterologous techniques that include the use of tissue expanders or breast implants.

Breast implants, in fact, allow the achievement of a good symmetry, in selected patients, with relative simplicity, and virtually no tissue transfer and scarring at the donor site. This supporting evidence makes breast reconstruction with implants seem to be the better accepted choice than flap reconstruction.

Patients who require radiation therapy for management of their breast cancer pose a unique set of challenges to the reconstructive surgeon. For the patient who has already received radiotherapy or will receive it after reconstructive surgery, implant-based procedures are often problematic. Tissue expansion is difficult in the previously irradiated tissues, and the risk of infection and the risk of subsequent extrusion of an implant are increased, but considering that some patients are not ideal candidates for flap based procedures it is crucial to individualize a specific surgical planning/timing.

For the last 20 years, the quality of breast implants has continued to evolve with the intent to improve the aesthetic results of this type of surgical procedure. The implant's shapes, surfaces, contents and materials typically used have been repeatedly modified to produce more reliable and resistant implants, with increased similarity to the natural breast, while maintaining a high degree of patient and surgeon satisfaction alike. However, in the case of unilateral breast reconstruction, the long term stability cannot account for variations which the contralateral breast may physiologically undergo. The achievement and preservation of symmetry is therefore the most important challenge for the surgeon especially in the case of unilateral reconstructions with heterologous materials. To achieve symmetry on the healthy breast the use of well known techniques such as breast reduction (procedure most frequently used), breast augmentation and ultimately mastopexy may be warranted. Whatever the technique used, good cosmetic result will depend on the stability over time, thus the choice of the procedure must take into account both functional and aesthetic results by allowing for possible minor corrections in the future. However, this data is poorly documented in the literature. There are only a few articles where the long-term aspect of breast reconstruction is analyzed and the most important series reveal that, despite a high percentage of good results during the first two years after surgery (approximately 84%), about 30% of surgeries worsen in a linear fashion over time and only 54% of patients retain a good result after five years. The deterioration of the aesthetic result is due to the appearance of breast asymmetry that worsens over time, due mainly to changes in the contralateral breast, weight fluctuations, the appearance of ptosis, and the aging of the patient. In the case of heterologous reconstruction, the breasts age differently (the implant on one side and autologous tissue on the other) and the development of tissue atrophy around the implant with the gradual appearance of folds and an increasingly spherical look of the reconstructed breast further contribute to the deterioration of the aesthetics results. If the use of a heterologous reconstruction technique has been selected, it becomes necessary to try to minimize the long-term issues associated with the implant.

In agreement with the data reported in the literature on long-term satisfaction of patients, our institute chooses implants for heterologous breast reconstruction when possible.

2. Heterologous breast reconstruction

2.1 History of implants and heterologous breast reconstruction

The first attempt at breast reconstruction with a material that did not present any rejection problems dates back to 1895 with Czerny, who used autologous adipose tissue. In 1899, Gersuny described a technique for breast augmentation achieved by percutaneous injection of paraffin wax. In 1930, Shwarzman implanted glass beads under the skin and in 1950 Polystan was introduced, a spongy material derived from polyethylene rarely recommended because it was invaded by connective tissue after the insertion. The research to use inert substances arrived to 1951 with Wallace and Pangmann who introduced the use di Ivalon, a sponge made of polyvinyl alcohol and formaldehyde. This substance was introduced under the breast tissue in a polyurethane casing. The implant was molded according to the patient's needs, soaked for 24 hours, sterilized and implanted. In 1960 the ethron was introduced, a polymethane derivative, which was used with some success because it induced low peripheral fibrosis and did not cause calcification. Since then many substances and methods have been tested, but the era of the current breast implants began only in 1963 when Cronin implanted prosthesis made of solid silicone casing with a smooth surface, filled with gel of the same polymer. On the back side, the mammary prosthesis were provided with dacron disks in order to adhere to tissues better. The casing did not stick to tissues and did not lead to phlogistic reactions. Since the introduction of Cronin's breast implants in 1963, the implants have always been composed in a similar manner. Over the years the manufacturers of breast implants have been trying to improve the quality by changing the thickness of the outer silicone casing, adding texture to the surface and introducing new filling substances as saline, hydrogel, soybean oil and silicone gel. In 1970, Ashley presented a model of breast implant made of a thin and soft silicone casing filled with low viscosity silicone gel, fully surrounded externally by a one-millimeter thick layer of polyurethane microfibers. In early 1989, textured surface implants have been introduced for clinical use; such implants would theoretically have the advantage of limiting the percentage of incidence of periprosthetic capsule retraction, thanks to their rough surface.

3. Classification and current status of breast implants

The heterologous reconstruction is based on the installation of prosthetic devices, whose morphological and structural features are constantly evolving. However, it's been shown in numerous studies that these materials do not increase the risk of developing cancer or autoimmune diseases.

Currently there are three types of commercially available implants: provisional tissue expanders, permanent tissue expanders and definitive implants. The definitive implants available on the market offer a wide variety in regards to the type of surface, the filling, the shape and the size that the consumer may choose. They are made of a silicone elastomer casing filled with silicone gel or saline.

The surface can be of three kinds: smooth, textured and polyurethane (Image 1,2,3). The smooth surface implants are now used very rarely. The polyurethane surface made it possible to reduce the phenomenon of capsular contracture by covering elastomers with an irregular surface and as a result it inspired further research for alternative solutions that will minimize capsular contracture even more. The texturized implants are the outcome of this

research; in fact, their rough surface limits the periprosthetic capsular contracture even more so than the polyurethane surface. In recent years, the shape of the implants was of great importance to the business aspect of plastic surgery. Primarily, there are two shapes that are available: round and anatomic.

The round implants were the first available and today are the most frequently used. They are available with any type of surface, filling and profile, pre-filled, inflatable, with single and double chamber.

The anatomic implants were designed to give the breast a more natural look. The upper pole is flattened and slopes down to a fuller lower pole, where generally the maximum implant projection is situated. The anatomical implants, especially those filled with cohesive silicone



Image 1. Smooth surface implants filled with silicon gel.



Image 2. Textured surface implants saline filled with saline solution.



Image 3. Textured surface implants saline filled with silicon gel.

gel, maintain their shape both in ortho and clinostatism and guarantee a more predictable result. The possibility to choose the implant height according to chest proportions and the absence of collapse effect, assure a stable upper pole. With regard to the size, the implants may vary according to three basic parameters: height (Height: full, moderate, low), projection (Variable projection: full, moderate, low), and base diameter. They should be evaluated according to the patient's body habitus and preferences.

The most used implants are:

- double-lumen implants with silicone gel-filled core and outer chamber with saline content.
- double-lumen implants with saline-filled inner chamber and outer chamber made of silicone gel.
- double-lumen implants with chambers filled with silicone gel in different density.
- single-lumen implants containing uniform or differentiated density silicone gel.
- single-lumen implants containing oil of various types (so far not sufficiently tested and safe).
- single-lumen implants containing saline solution.

The provisional tissue expanders are implants whose purpose is to stretch the breast tissue and to reconstruct the mammary relief by creating the necessary space to accommodate a definitive implant. This process, known as tissue expansion, is carried out by progressive fillings of saline through a valve that allows the expander to inflate until the desired volume is reached. The expander is then left inside the breast for a period of approximately 4 to 6 months, the time required for the breast tissue to adequately expand in order to accommodate the definitive implant at a later date. The valve of the expander can be integrated into the implant itself or placed at a distance, or rather be connected through a small silicone tube. The embedded valve reduces the risk of expander depletion. However, this implies that the progressive saline fillings are performed with the needle piercing the tissues (skin, subcutaneous tissue and muscle). Also, the tissue expanders can vary

according to some parameters: shape (round, oval to drop, crescent), base, height and projection (classically with a greater projection and wider bending to the inferior pole) (Image 4). The permanent tissue expanders, or Becker's expansion implants, are devices that have the dual function of tissue expanders and long term breast implants, and are designed to be left inside the breast permanently at the end of the expansion. The goal is to avoid a second surgery for the placement of the definitive implant and to maintain the possibility of volume manipulation through a remote valve usually located in the axillary region. There are several models differing by shape, dimension and volume. The disadvantage; however, is a higher rate of implant depletion compared to provisional tissue expanders.

3.1 Status of breast implants filled with silicone gel

On April 10, 1991, the FDA (Food and Drug Administration) asked manufacturers to have silicone gel breast implants to undergo a pre-market test for safety and effectiveness. Unfortunately, they were not able to provide this information to the FDA. Without sufficient data on the safety and effectiveness, the FDA determined that these implants could not be approved. Therefore, the silicone implants were withdrawn from the market. However, these implants were still available through the following studies approved by the FDA:

- an additional study.
- A study investigating patterns in installments (IDE).

In April 1992, after a careful consideration of the public's needs of the alternatives to silicone implants and of their risks, the FDA concluded that the implants should continue to be available for women who require breast reconstruction or revision of an existing implant. Consequently, the additional study was developed to make the implants available for reconstruction and revisions and to collect short-term data on complications. Women who wanted silicone implants to increase the volume, for aesthetic reasons, could not be included in the additional studies. According to the protocol of the additional study, every woman would be followed for a minimum of 5 years.




Image 4. Different profile of silicone implants.

The IDE study is a clinical study, reviewed and approved by the FDA in order to ascertain the significance of the data and check for any risks or complications associated with the use of silicone gel implants. Generally, IDE study data is used as the basis for a future application on the market. The women participating in an IDE study can receive their implants for the uses described by the study protocol. A detailed informed consent is mandatory for IDE study. In addition, an IRB (Institutional Review Board), composed of scientists and health professionals, must supervise the study.

On November 17th, 2006, the FDA approved the distribution in the U.S. market of silicone breast implants manufactured by companies Mentor Corp. and Allergan Corp. In addition to having allowed the distribution of silicone breast implants of only two manufacturers (Mentor and Allergan) that provided complete documentation for the approval, the FDA has limited the use of silicone implants to women aged 22 years and older when the surgery is performed for cosmetic reasons. There is no age limit, however, for the use of silicone implants in breast reconstruction.

3.2 Study of saline solution Implants

The manufacturers of saline implants have had notification from the FDA in January 1993 that the agency would require data on the safety and efficacy of their products. While the manufacturers were carrying out the required studies, the saline implants remained on the market. On May 10, 2000 the FDA approved the pre-market testing of Mentor and McGhan. Currently, saline implants of all other manufacturers are considered experimental.

4. Surgical technique

In the first breast reconstruction surgeries with heterologous material, implants were placed beneath the skin layer, but since the overlying skin appeared visibly irregular with this technique and the use of saline implants, surgeons progressively moved to the placement of implants under the musculofascial layer, between the pectoralis major and the pectoralis minor muscle, in continuity with the serratus anterior, providing better protection for the implant as well as a better aesthetic result. Breast reconstruction with heterologous material includes three different procedures using different prosthetic devices:

- expander-implant technique.
- insertion of immediate definitive implant.
- insertion of permanent expander implant.

4.1 Expander-implant technique

It's the most common technique used today for the immediate reconstruction, but it can also be used for delayed reconstruction. The first surgical stage involves the construction of a lodge under the muscle-fascial layer between the Pectoralis Major muscle and the Pectoralis Minor muscle which is in continuity with the Serratus Anterior muscle and the cephalic portion of the Rectus Abdominis muscle fascia with the disconnection of the Pectoralis Major muscle from distal costal and mid-distal sternal plane. Then, the placement of the expansion implant is performed, pre-injected with saline solution (about 20% of the total volume), and two suction drainages are placed in the axillary region and in the muscular

lodge. The expansion, carried out through a valve within the implant (sometimes remote), may begin nearly two weeks after surgery and continue for about 6-8 weeks to reach the desired volume and shape. Chemotherapy does not impair the expansion which can be performed in parallel to chemotherapy (except in cases of severe neutropenia in which it is preferable to suspend the expansion). Once the desired volume is reached, the surgeon then proceeds with the removal of the expansion implant and the insertion of the definitive implant (the second stage of breast reconstruction). However, this procedure must await the end of the chemotherapy treatment and must be preceded by careful assessment of the patient's general state of health. To insert the definitive implant, subject to scarstomy of the previous surgery (gesture oncologically important since surgical scars are a frequent site for local recurrence), a sub-muscular access is performed until the expander is located and removed. This is followed by capsulotomy or radial incisions for tissue relaxation, the creation of a breast neo-fold through prefascial upper abdominal dissection, the anchoring flap with underdermal points on the groove to the V and VI rib periosteum, the placement of suction drainage and of the definitive implant, previously soaked in saline. Accesses are sewed and elasto-compressive dressing is applied. Such reconstruction can be performed regardless of contralateral breasts volume or ptosis status.

The advantages of this technique are as follows:

- technique versatility;
- reconstruction adaptability to ancillary treatments;
- short duration of the first surgical stage (average time 35 minutes);
- immediate reconstruction contextual to mastectomy;
- same access path as used during the demolitive stage;
- possible even if the skin of the mastectomy flap is insufficient;
- achievement of a good level of symmetry of folds, volume and shape;
- adequate expansion of skin and muscles;
- scars confined to the breast area;
- lack of "sacrifice" of working muscles;
- absence of aftereffects on gait and posture as a consequence of the reconstruction method;
- neo-breast skin and sensitivity with typical characteristics of mammary region;
- low immediate and delayed surgical morbidity;

The disadvantages are:

- two surgical stages;
- outpatient procedures necessary for the expansion;
- final outcome can be obtained only after some time;
- three surgical stages to complete the reconstruction (following reconstruction of nipple-areola complex, when requested);
- presence of foreign body (implant);
- possible alterations of the implant due to time and interaction with biological tissues;
- need to use "standard" implants, not always adaptable to shapes and dimensions of biological tissues;
- need to adapt the contralateral breast to the reconstructed one;
- the method is not recommended if residual tissues present precarious conditions (in post-actinic or surgical cases);

Complications associated with the use of breast implants may occur either in the immediate post-operative period or at a later date. They include exposure, extrusion or infection of the implant, asymmetry, displacement or implant rupture and capsular contracture.

4.2 Immediate definitive implant

Patients with contralateral breast of medium or small volume, in the absence of ptosis or mild ptosis, can be treated with the placement of immediate permanent implants. The advantage of such technique is that the entire reconstruction can be performed in a single surgical stage, but several factors have to be considered for this procedure. To start with, this technique cannot be executed if the mastectomy skin flap turns out to be inadequate for the purpose of the mammary relief reconstruction. In addition, frequently the intra-operative result does not match with the surgical outcome later and additional surgeries are commonly needed to achieve satisfactory cosmetic, clinical and morphological outcomes. Therefore, it is extremely difficult to achieve symmetry in shape, volume and the submammary fold in a single surgical stage.

4.3 Permanent expander implants

The use of permanent expansion implants follows the same instructions with respect to immediate definitive implants (small or medium-volume breasts without ptosis or mild ptosis) with the only difference in the possibility of intra- and postoperative volume adjustments. Similarly to the definitive implant, their placement is limited by the precarious conditions of the mastectomy flap and by the difficulty in reaching symmetry in shape, volume and the submammary fold in a single surgery. Besides the obviously higher cost, the disadvantages are the presence of the remote valve which eventually requires an additional surgical procedure for its removal and the fact that the models on the market, compared to implants, are not always adaptable to the shapes and dimensions of the biological tissues.

5. The contralateral breast

Symmetry is one of the main purposes of breast reconstruction, with the need to perform a surgical procedure on the healthy contralateral breast in most cases. Obtaining symmetry represents a great challenge for plastic surgeons, especially in case of unilateral heterologous reconstruction rather than unilateral autologous reconstruction. In addition, surgical techniques should allow an adequate oncological follow-up. The choice of the surgical procedure depends on the oncological stage of the patient, the characteristics of the contralateral breast, the type of mastectomy, the surgeon and patient's preferences. As a matter of fact the evaluation of the contralateral breast during pre-operative planning is essential to achieve an aesthetically pleasing result. The patient should be adequately informed about the whole reconstructive procedure, especially about the need for further surgery and other possible adjustments. The timing for symmetrization procedures is highly controversial. Some surgeons argue that it's easier to re-shape the contralateral breast during the first stage of the reconstruction rather than during a secondary procedure: in these cases the contralateral breast may be a model for the reconstruction rather than a corollary and the symmetrization procedure may be an opportunity to explore the contralateral gland, since the risk of occult cancer. Others prefer to perform the symmetrization surgery after the adjuvant therapy on account of the possibility to further

reshape the reconstructed breast. In case of heterologous reconstruction the choice of the surgical technique for symmetrization depends on volume, shape and position of the healthy breasts and must necessarily refer to the reconstructed breast and to the type of prosthesis chosen after the expander. Depending on the above mentioned parameters, it's possible to perform breast reduction and/or mastopexy, or breast augmentation.

5.1 Breast reduction and mastopexy

Breast reduction is performed on the large healthy breast, to adapt it to the reconstructed breast. Several authors recommend the use of a less traumatic as possible technique for the breast parenchyma to facilitate the oncological monitoring of breast cancer. The most common techniques rely on a superior or an inferior pedicle and do not generally require significant mobilization of tissue or glandular flaps. Anyway, the excised tissue is sent for histologic examination due to the risk of developing contralateral breast cancer. The patterns of skin resection vary depending on the size and shape of the breast (inverted-T, J or vertical scar). The "Round block" technique is quite frequently used because it decreases the projection of the breast, allowing a better symmetry with the reconstructed breast over time. Breast mastopexy is preferred if adequate breast volume, with only skin excess and ptosis of the nipple areola complex exclusively, is present. Again, the pattern of resection must minimize scars.

5.2 Breast augmentation

Breast augmentation using implants is generally used to achieve symmetry in patients who underwent heterologous reconstruction, when the contralateral breast has small or medium volume (hypotrophic or normotrophic). The breast reconstructed with heterologous techniques looks less natural and it often presents a rounded appearance, especially in the upper pole; moreover, it doesn't vary in volume like the contralateral breast if the patient changes weight. Therefore, both breasts will have, over time, a different aging process with the onset of asymmetry and the need for surgical procedures to be performed. Consequently, the placement of a contralateral prosthesis can give better symmetry both immediately and over time. The symmetrization using breast implants is comparable to the traditional breast augmentation procedures, therefore the surgeon will have to realize an accurate pre-operative planning about the incision, the choice of the implant and its placement.

5.3 Choice of the implant

Generally, the implants commonly used in Italy and Europe consist of a hard silicone surface wall that encloses silicone gel. The surface can be textured, smooth or made of polyurethane. The shape of the prosthesis can vary essentially between round and anatomical. There are no general rules to make this choice, that is generally made according to the personal preference of the surgeon and the patient. One of the aims of this work is to try to obtain, retrospectively, a decision algorithm for the selection of the contralateral prosthesis in heterologous breast reconstruction.

5.4 Incision placement

Incision placement is a crucial choice, because it greatly affects the final result. Moreover, the placement of the scar is critical to achieve a good cosmetic result and for patients'

satisfaction. The choice surely depends on the preference of the surgeon, agreed with the patient, but it must also consider certain anatomical features. The most frequently used incisions are the hemiperiareolar, inframammary fold and axillar. Hemiperiareolar incision: this is the most versatile approach. It provides a central access to all quadrants and it is compatible with all types of breast implants and plans for dissection. It is preferable when the inframammary fold should be lowered of several centimeters, and it is the best choice when a round block technique is simultaneously performed. It is also the most appropriate approach for the remodelling the gland, as in cases of tuberous breast. A little areolar diameter may limit the viability of this access; anyway, it must be considered that an areolar diameter of 2.5 cm can still provide an access at least 4 cm. Caution should be taken with the nipples that lacks net color contrast, because the scar would be very visible. There is also evidence that this incision may cause alterations in the sensitivity of the nipple and areola.

Incision in the inframammary sulcus: this is undoubtedly the most simple approach in breast augmentation. It gives direct access to both the subglandular and submuscular plans, which can be reached without the need for a trans-glandular dissection. The scar can be hidden from the lower pole, but the quality of these scars is often worse than hemiperiareolar ones. The length of the incision can be considerable, allowing the placement of large implants. In patients with lower pole hypoplasia, after positioning the implant, the IMF may fall more than planned, thus resulting in an ugly scar in the lower pole of the breast. Incision in the armpit: This type of access is preferred when the patient does not want any scar on the breast. The scar is hidden well behind the anterior pillar of the axilla. The access to the surgical plans is more difficult than the two previously described approaches, but the use of an endoscope may facilitate the operation. However, the technique lacks precision in the dissection and placement of the implant, increasing the risk of asymmetry and malpositioning. Furthermore, it is impossible, if necessary, to manipulate the breast parenchyma to insert large silicone gel implants. Trans-umbilical incision: trans umbilical access is certainly the latest innovation in breast augmentation. Through an invisible incision inside the navel, a subcutaneous tunnel is created just above the fascia of the rectus muscles up to the breast. Although it has been described for positioning of the implant in both subglandular or submuscular pockets, the latter is very difficult. The risks and limitations are the same of the axillary approach as both the accesses are far from the mammary gland. In addition, it is impossible to insert a silicone-gel implant and it should be used with caution in patients with a very thin subcutaneous tissue.

5.5 Implant placement

The mainly used pockets created for implants placement breast augmentation are the retroglandular, partially submuscular, totally submuscular and dual-plane.

Subglandular: In the history of breast augmentation the subglandular pocket was the first to be described. It is generally viable with patients in whom there is enough tissue to cover the implant. In patients with poor adipo-glandular tissue the risk of implant visibility and palpability is very high. In addition the prosthesis becomes very visible in the upper quadrants of the breast, resulting in a typical deformation of the breast. Moreover, the

subglandular pocket is associated with an increased risk of capsular contracture compared to submuscular or partially submuscular ones. In addition, the subglandular implant interferes with mammography more than the submuscular.

Submuscular: The totally submuscular pocket was developed in order to reduce the visibility and palpability of the implant and the incidence of capsular contracture. Unfortunately, with this technique the definition of the lower pole is poor, often worse than with other techniques. In addition, there is a higher incidence of upper dislocation of the implant.

Subpectoral: Generally the term subpectoral refers to a pocket partially under the pectoralis major muscle, with the lower portion of the implant located under the gland. This localization seems to be associated to a lower incidence of capsular contracture; it also facilitates mammography. This pocket should be used with caution in women with postpartum atrophy or glandular ptosis, because in these cases the risk of creating a double-bubble deformity is very high.

Dual-Plane: This technique has been developed as an evolution of the subpectoral pocket to minimize the risk of double bubble. The technique, recently described by Tebbets, achieves a good shape of the breast using both the submuscular and subglandular plans. The main difference with the subpectoral technique is the subglandular dissection, which may extend to the upper edge of the areola. In patients with poor breast tissue, dissection proceeds to the lower edge of the areola. In patients with more soft tissue coverage and ptosis, the dissection extends until the top edge of the areola.

6. Aim of the study

The aim of this retrospective study was to critically analyze the outcome of breast reconstruction after mastectomy using tissue expander followed by permanent implant placement and contralateral symmetrization through augmentation mammoplasty with a follow up at least of three years.

The overall aesthetic results was analyzed on the base of grade of symmetry, shape, volume, implant position, patient and surgeon satisfactions, thus evaluated with objective method (physical examination with clinical measures) and with a subjective one through a questionnaire administered to patients. Thus a flow chart was developed based on the volume, contour, and position of the natural and reconstructed breast and on the base of the data collected through the study.

7. Materials and methods

A review of about 360 tissue/expander breast reconstructions performed at University Campus Bio-Medico of Rome from 2003 to 2009 was performed. Out of 360 288 reconstructions (80%) were heterologous with two stage technique. 35 patients operated with permanent implant placement and contralateral symmetrization through augmentation mammoplasty were included in the present study.

The exclusion criteria were contralateral symmetrisation with reduction mammoplasty or mastopexy.

Preliminarily, patients were classified according age, tumour stage (Table 1), chemotherapy (after either quadrantectomy or mastectomy), radiation therapy timing of reconstruction (immediate vs delay), expander volume, definitive implant (in both sides), numbers of reoperation.

IntechOpen

Grouping in stages

N°	stage0	stage1	stage 2A	stage 2B	stage 3A	stage 3 B
Pz	5	10	11	7	1	1

Table 1.

Tissue expander were choosen according to contralateral breast width, volume and shape and patients heighth. The follow up was completed in 17 patients (48%). The Authors evaluated in both breasts the following measures immediatly after nipple areola reconstruction (time 0) and after at least 3 years (time 1):

- emiclavear -nipple distance
- sternal notch-nipple distance
- nipple -IMF distance
- breast width
- grade of contracture

Patient and surgeon satisfaction were assesed trough a questionnaire with numerical score form 1 to 5 (poor, fair, good, very good, excellent) regarding breasts appearance in terms of:

- Shape
- Volume
- Projection
- Inframmary fold
- Ptosis
- Countour of the device
- Grade of contracture
- Symmetry
- Overall aesthetic result

Accurate photographic documentation was thus evaluated by surgeons.

8. Results

Of the 35 patients the mean age of patients identified was 54 years ranging from 38 to 74 years.

Immediate reconstruction was performed in 25 patients (71%), delay reconstruction in 10 patients (29%). Volume range of tissue expander was from 300cc to 850 cc with median volume of 500 cc.

Volume range of anatomical implants of the reconstructed breast was from 210cc to 640 cc with median volume of 427 cc. In all reconstructed breasts the implant was anatomical shape, style 410. The implant style was 410 (Table 2), Low Height-Full Projection (LF) in 8 cases (23%), Low Height - Extra projection in 4 cases (11%), Medium height- Full Projection (MF) in 14 cases (40%), Medium height-Extra Projection in 8 cases (23%) and Full Height-Full Projection in 1 case (3%).

Height	Projection			
	L	M	F	X
F	0	0	0	1
M	0	0	14	8
L	0	0	8	4

Table 2.

For the contralateral symmetrization the implant volume range was from 90cc to 440 cc with median volume of 220cc. In 23 cases (83%) a round implant style 110 was used while in only 6 cases (17%) anatomical implant was preferred , style 410 LL in 1 case, style 410 ML in 1 case, style 410 FL in 1 case, style 410 MM in 1 case and style 410 MF in 2 cases (33%) as showed in Table 3.

Height	Projection			
	L	M	F	X
F	0	1	0	0
M	1	1	2	0
L	1	0	0	0

Table 3.

23 patients underwent adjuvant chemotherapy, 2 patients underwent both chemotherapy and radiotherapy. Thirteen patients underwent re operation: 7 capsulotomies for capsular contracture grade III of the reconstructed breast, 6 lipofilling for breast contour irregularities. Follow up ranged from 1 to 5 years with median of 4 years. Seventeen patients patients after at least 3 years of follow-up were evaluated. A comparison between time 0 and time 1 of the reconstructed breast is shown on Table 4, of the contralateral breast is shown on Table 5.

Parameters	Medium value		Variation
	T0	T1	
distance midclavicular-nipple	19,8125	18,906	1 ↓
distance jugular-nipple	20,9375	19,94	1 ↓
distance nipple-furrow	7,7666	7,4063	0,5 ↓
mammary base	13,125	12,81	0,4 ↓

Table 4.

Parameters	Medium value		Variation (Δm)
	T0	T1	
distance midclavicular-nipple	19	20,58	1,58 ↑
distance jugular-nipple	21,53	22,02	0,5 ↑
distance nipple-furrow	8,12	8,11	↔
mammary base	14,03	13,61	0,4 ↓

Table 5.

Capsular contracture grades classified with modified Baker classification was higher on the reconstructed breast compared to the healthy one. (Table 6).

Breast	Medium value		Δ Avarage
	T0	T1	
Reconstructed	1,43	2,68	1,25
Controlateral	1,06	1,25	0,19

Table 6.

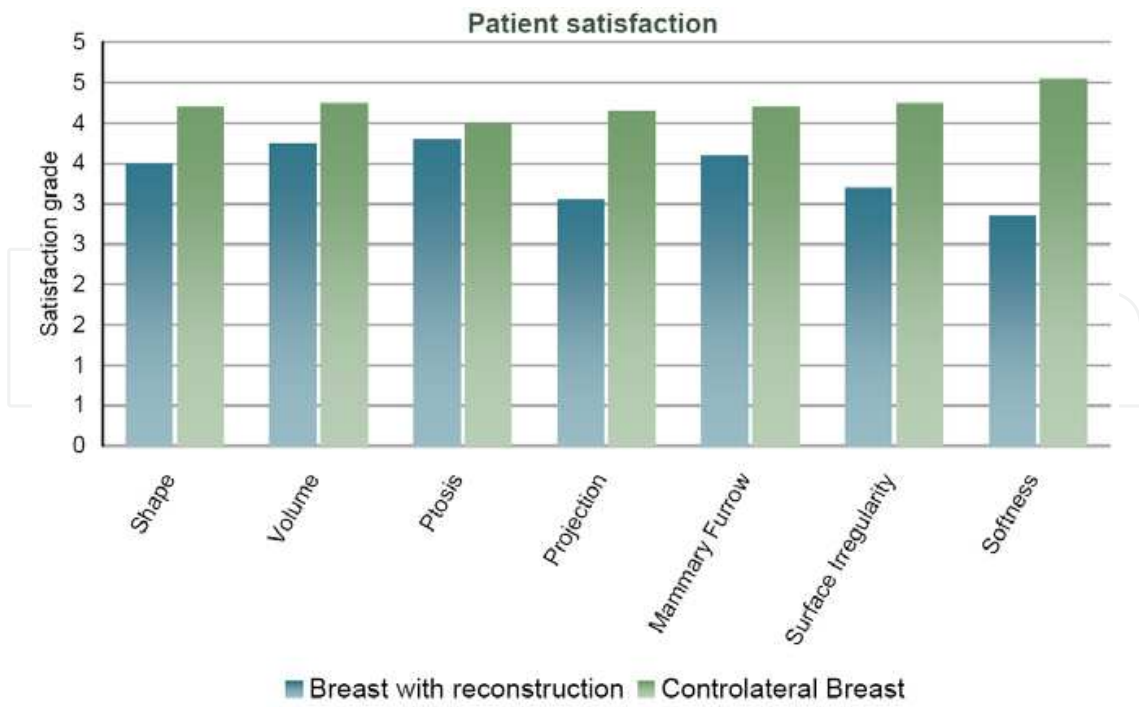


Image 5.

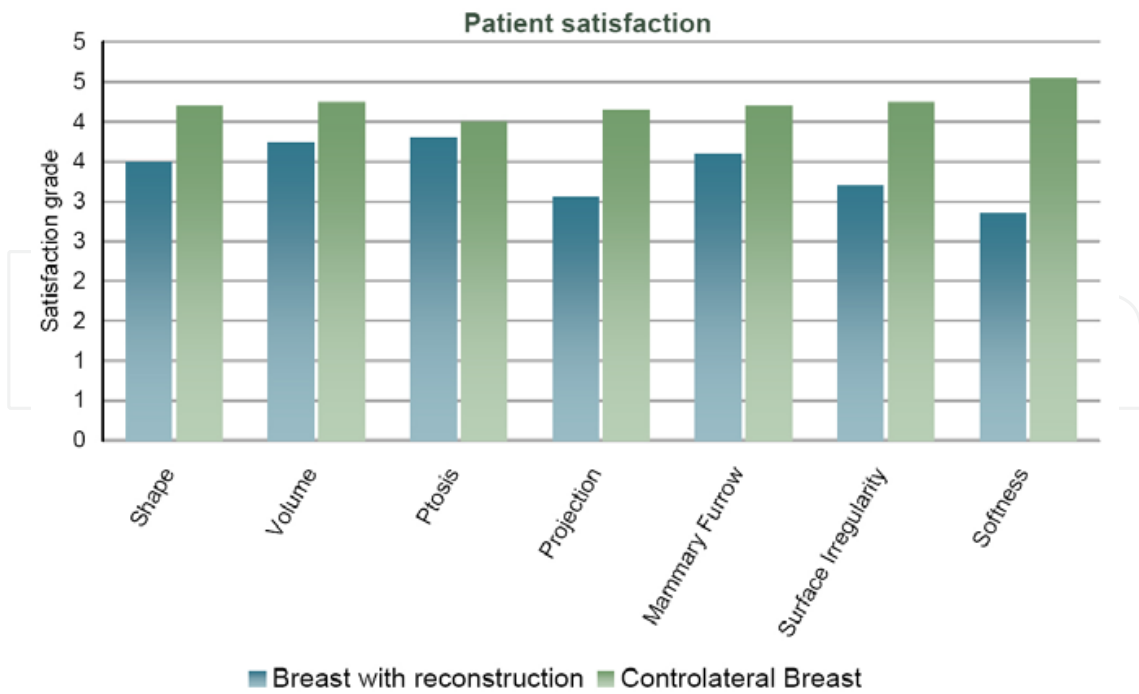


Image 6.

Patient and surgeon satisfaction were assessed through a questionnaire with numerical score from 1 to 5 (poor, fair, good, very good, excellent). Patient satisfaction was scored and showed in Image 5 while surgeon satisfaction was scored in Image 6. For the contralateral breast the score ranged in all patients between good and excellent. Symmetry was scored good in majority of case, while global satisfaction was scored good for surgeon, very good for patients in most cases

On the base of our results we developed a flow chart to guide the surgeon to preoperatively choice the right implant on the base of the shape of contralateral breast:

- Normal shape, glandular hypomastia: round implant
- Normotrophic, ptotic breast: round implant
- Normal shape, hypertrophic breast: round implant
- Normotrophic breast with hypoplasia of 1 or 2 quadrants: round implant
- Hypoplastic breast with mild deformity of 1 or 2 quadrants: anatomical or round implant
- Hypoplastic breast with severe deformity of 2 or more quadrants: anatomical implant

9. Discussion

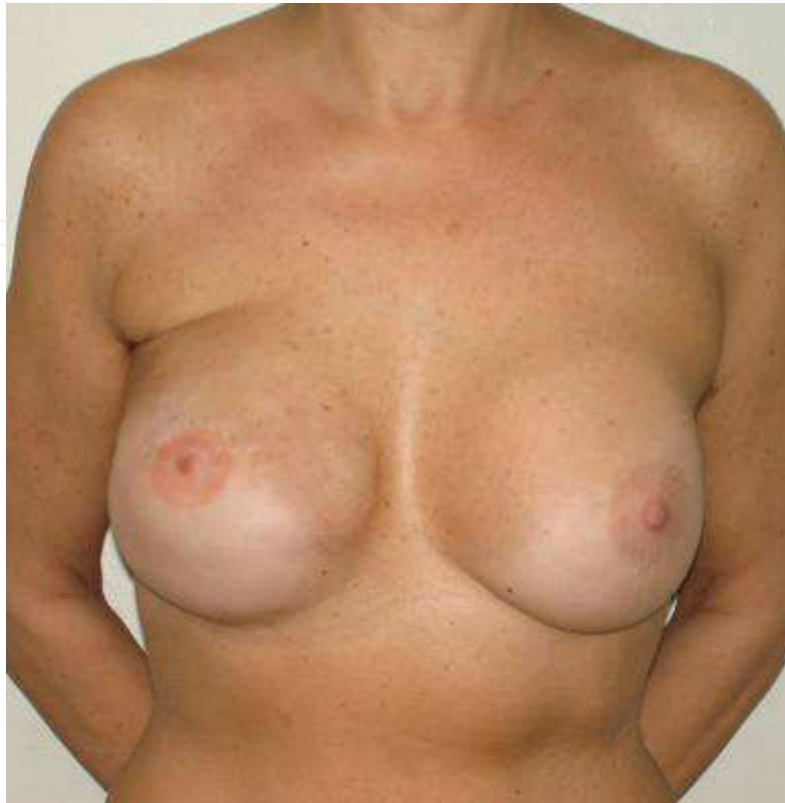In plastic surgery a good result is not influenced only by technical competence but also depends on other factors such as few surgical prestiges, short operating time, absence of pain, no touch up which of course highly increase patient's satisfaction. Patients undergoing breast reconstruction usually expected full recovery of the body image without further complications and they pay more attention to the oncological aspects than to the reconstructive ones, especially in immediate procedures. No interference with adjuvant therapies, very limited scars and perfect match with the contralateral breast are strongly considered in women's final evaluation. On the opposite, a technical opinion on the breast reconstruction mostly considers whether all anatomical features have been recovered and maintained for the longest. The goal is not "to fill the cup of a bra" but to "rebuild" an organ that has been mutilated. Shape, volume and projection of the breast are the main issues but many details need to be adequately restored such as fullness of the lower pole, definition of the inframammary fold (IMF) and nipple areola complex (NAC) position. In heterologous breast reconstruction the development of capsular contracture is probably the main cause for the loss of symmetry at 5 years follow up, which show a very high incidence in all studies (over 60 %) of revisions, so the challenge to maintain the result remains open. As other groups have already published our limited experience confirm some important considerations and suggest some refinements in implant based reconstruction that is still the major reconstructive procedure performed (80%, 288 out of 360 patients in our series). Symmetrization of contralateral breast is a key point. As Loske demonstrated and published, in fact, breast reduction, mastopexy and breast augmentation must be required to remodel the healthy breast (67%), and particularly contralateral breast augmentation seemed more used in implant based reconstruction (41%). Nahabedian et al. also introduced the necessity to revise surgical procedure along the years. In our experience symmetrization of contralateral breast has been done in almost 90% and breast augmentation revealed to be a precious tool to enhance long lasting symmetry in heterologous reconstruction. Shape and

position of the healthy breast unfortunately vary as time pass, breast reduction and mastopexy may age more rapidly while the presence of a submuscular implant improving upper pole fullness and volume symmetry may require minor revisions especially when a capsular contracture occurs on the reconstructed breast. The choice of which implant to use in these cases is crucial but represents just a step in the ongoing debate about round and anatomical in common cosmetic breast augmentation. Our review suggested that for normal shaped breast requiring just volume adjustment a round implant can be used, on the contrary in case of severe hypoplasia an anatomical implant is preferable. In our series 83% of patients had a round implant while the 17% need an anatomical one. Round implants have some advantages as they do not rotate, can be easily inserted even through small incisions and can be used also in mild to moderate hypertrophy combining implant position with a minor breast reduction. On the other hand round implants improve just volume and upper pole fullness but they do not correct asymmetry of breast diameters. According to our chart they must be chosen if the breast is normal shape or if the deficiency is limited to one quadrant. In case of more severe alterations involving 2 or more quadrants the anatomical implants are ideal. The vast sort of different width, height and projection, commonly available for anatomical implants, allowed an easy matching of the extra projected implant which is often chosen on the reconstructed side. Anyway, the long term analysis of 35 patients who have underwent breast augmentation on the contralateral side and completed the three years follow up, showed in the 49% the presence of asymmetry mainly due to capsular contracture. As well as in other studies also in our series most of the variations, such as implant dislocation, loss of lower pole projection and IMF definition occurred on the reconstructed breast. These modifications required in the 37% of cases a further surgical correction which has been achieved by means of lipostructure and lipofilling. Finally it is interesting to underline that patient's opinion, from the VAS questionnaire we have asked and registered, demonstrated a higher satisfaction when a contralateral implant is employed. This result was confirmed even in patients older than 65 years. The reason is probably a better symmetry with a upper pole fullness especially wearing the bra. All these patients, in fact, realized and described the development of modifications during the years but at the same time continued to positively judge the surgical procedure declaring an overall improvement of body image after the reconstruction with a full recovery of relationship and quality of life.

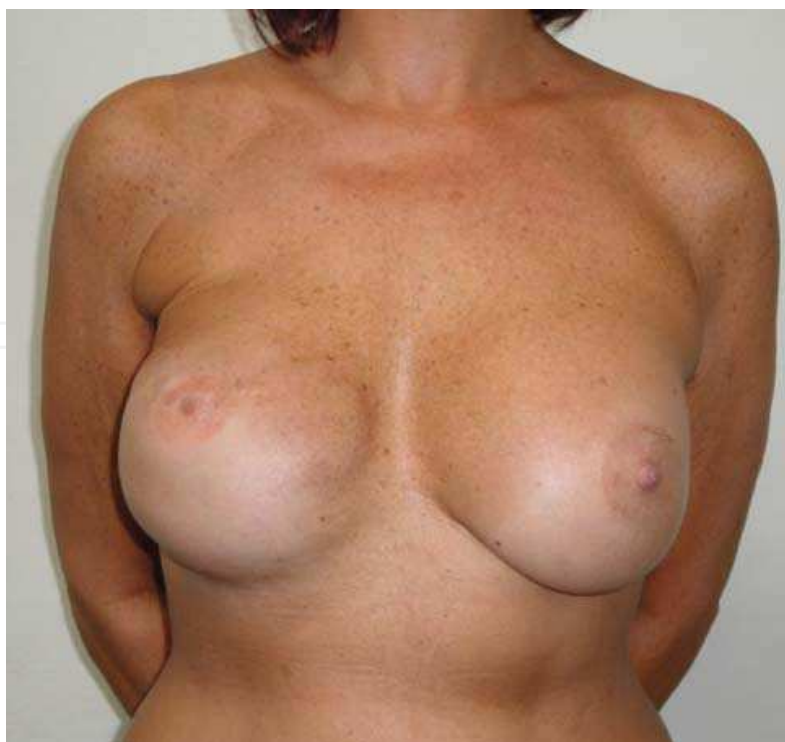10. Conclusions

Heterologous breast reconstruction still represents a first option in a great majority of patients due to easy and rapid technique, no donor site morbidity and technological improvement in implant industry. Contralateral breast symmetrization should be performed during the second stage of breast reconstruction. Nevertheless long term follow up confirm after 3 years a progressive loss of symmetry that may require further corrections. Lipostructure may be also useful in order to harmonize the volume and shape of both breasts, to acquire a better shape of the reconstructed breast or to manage the implant based breast contracture. In conclusion we underline that breast symmetrization with augmentation mammoplasty enhances long term satisfaction of patients and it should be considered as an important tool also in case of older patients or in case of mild to moderate breast hypertrophy.

11. Clinic cases

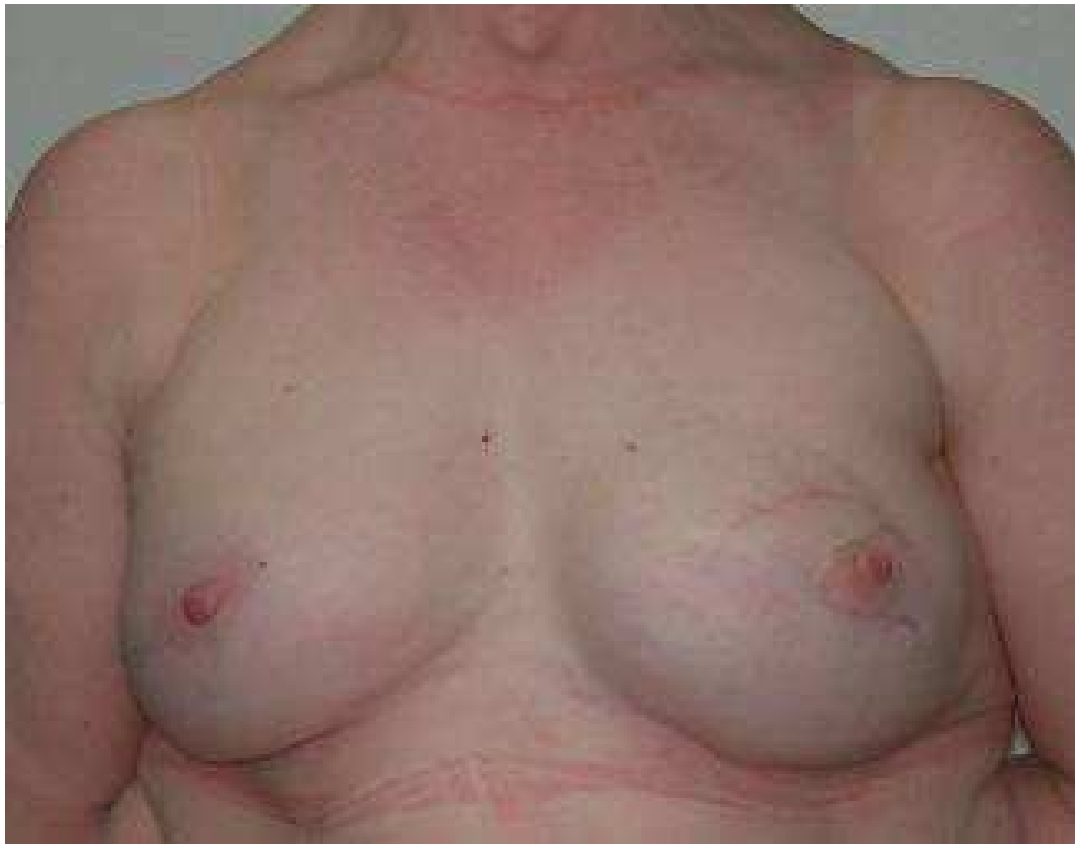

A

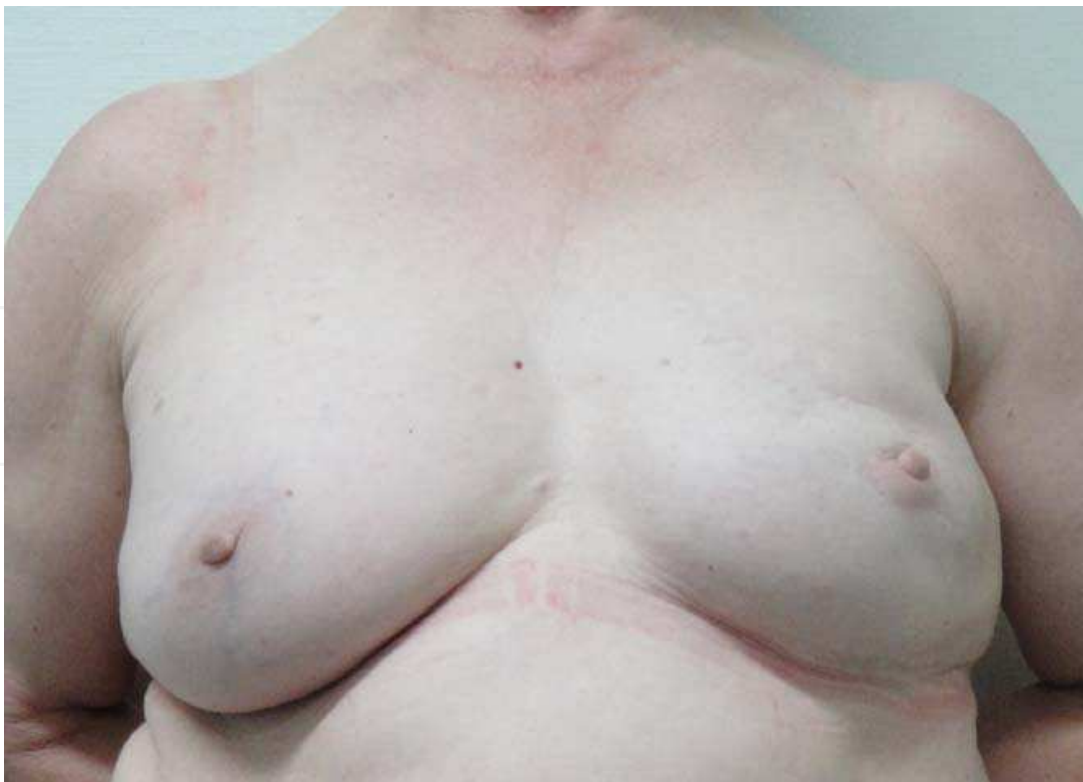

B

Fig. 1. Post-operation: (A) time T0; (B) time T1 follow-up 5 years

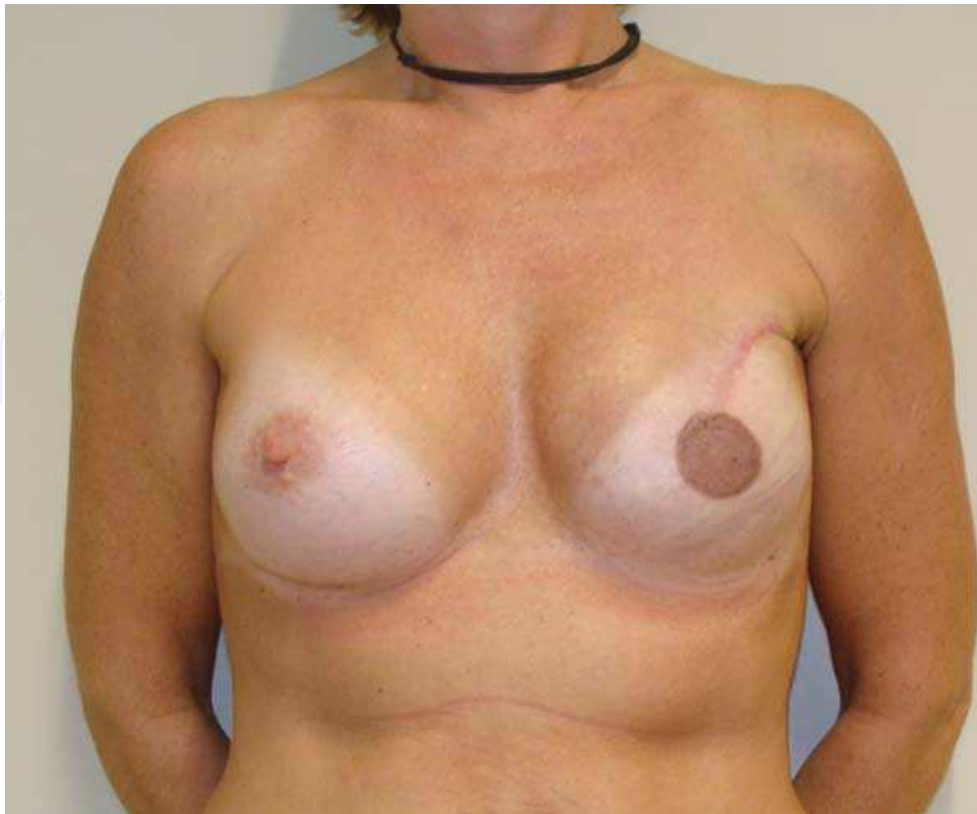

A

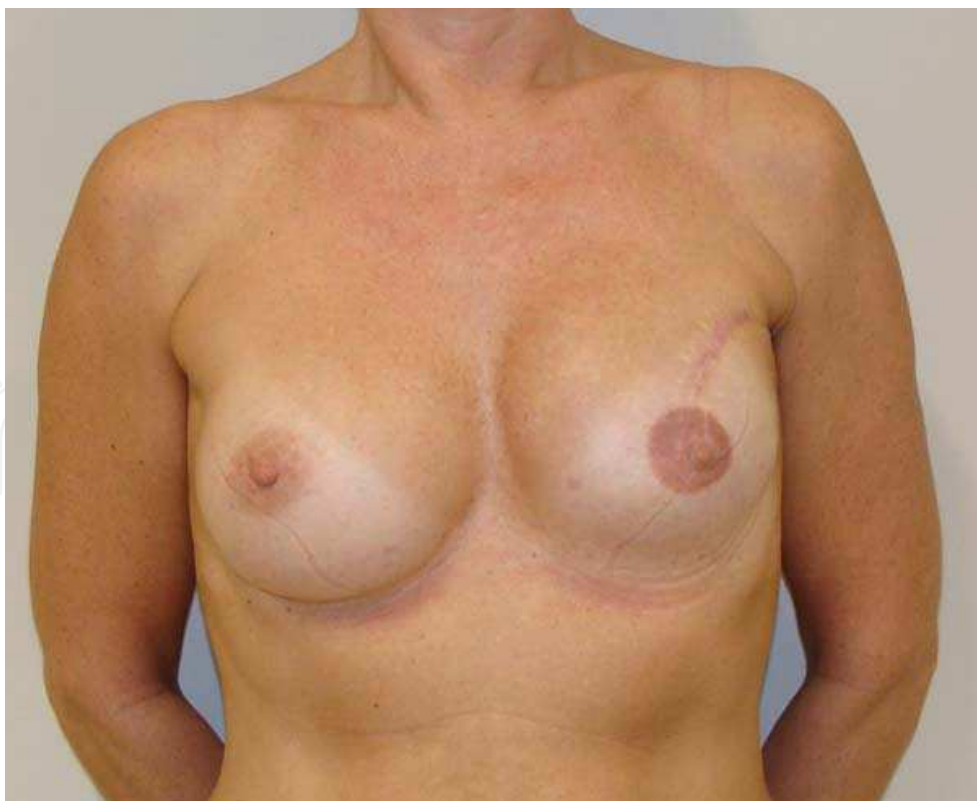


B

Fig. 2. Post-operation: (A) time T0; (B) time T1 follow-up 5 years

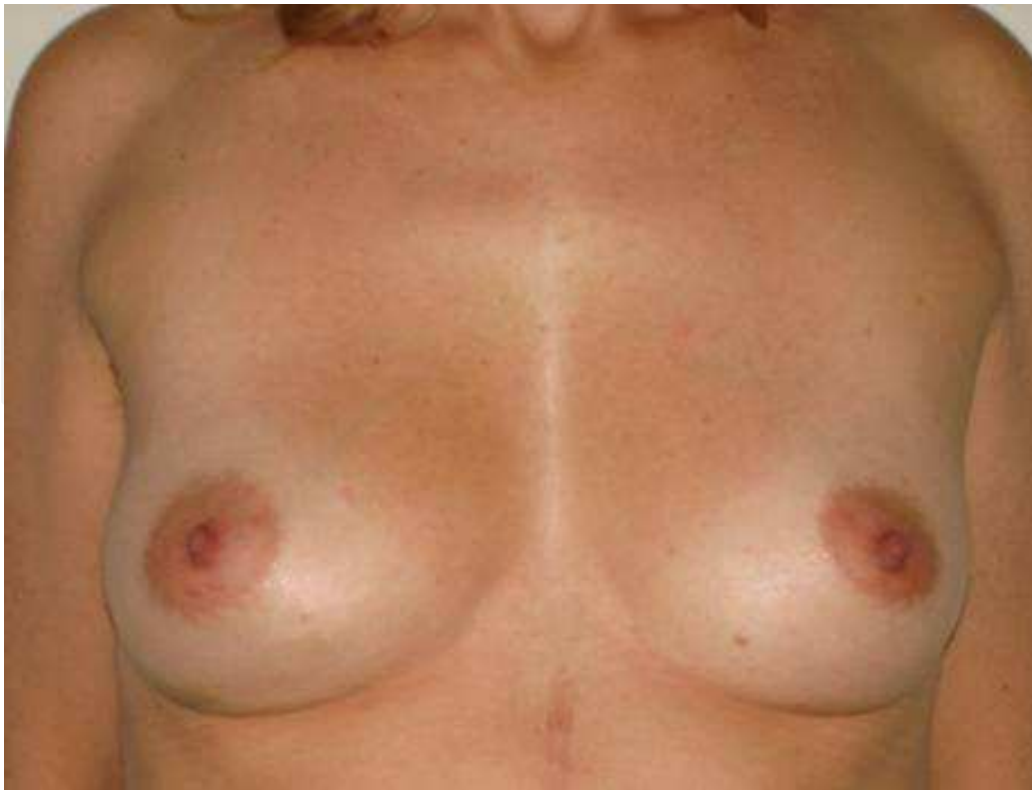

A

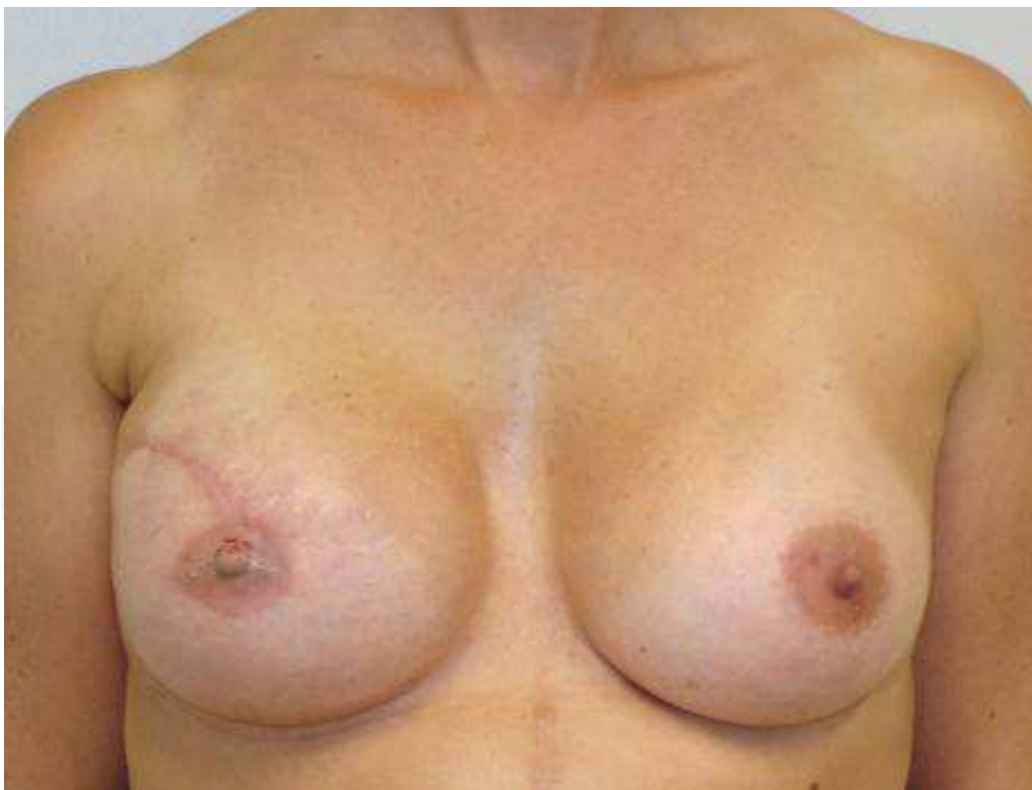

B

Fig. 3. Post-operation: (A) time T0; (B) time T1 follow-up 5 years



A



B

Fig. 4. (A) Pre-operation. (B) Post-operation: reconstruction right breast :anatomic implant H media /P extra; contralateral left breast : round implant P moderate

12. References

- A.D. Fitoussi, B. Couturaud. Evaluation of asymmetric implants in breast augmentation surgery. *Annales de chirurgie plastique esthétique* 50 (2005) 517-523.
- Albert Losken, M.D., Grant W. Carlson, M.D., John Bostwick, III, M.D.,† Glyn E. Jones, M.D., John H. Culbertson, M.D., and Mark Schoemann, B.A. Trends in Unilateral Breast Reconstruction and Management of the Contralateral Breast: The Emory Experience. *Plastic and reconstructive surgery*. July 2002; Vol. 110, No.
- Asplund O, Korlof B. Late results following mastectomy for cancer and breast reconstruction. *Scand J Plast Reconstr Surg* 1984;18:221-5
- Bogetti P, Boltri M, Balocco P, Spagnoli G. Augmentation mammoplasty with a new cohesive gel prosthesis. *Aesthetic Plast Surg* 2000;24(6):440-4
- Bostwick J Iii. Breast reconstruction following mastectomy. *CA Cancer J Clin* 1995; 45: 289-304.[
- Dean C, Chetty U, Forrest AP. Effects of immediate breast reconstruction on psychosocial morbidity after mastectomy. *Lancet* 1983;1:459-62.
- Elder EE, Brandberg Y, Björklund T, et al. Quality of life and patient satisfaction in breast cancer patients after immediate breast reconstruction: a prospective study. *Breast* 2005;14:201-8.
- Emily S. Hu e all. *Plast Reconstr Surg*.- July 2009-V. 124, Number 1.2
- Emily S. Hu, Andrea L. Pusic, Jennifer F. Waljee, Latoya Kuhn, Sarah T. Hawley, Edwin Wilkins, Amy K. Alderman. Patient-Reported Aesthetic Satisfaction with Breast Reconstruction during the Long-Term Survivorship Period. *Plastic and Reconstructive Surgery*, July 2009-Volume 124, Number 1.
- Garson S, Delay E, Sinna R, Carton S, Delaporte T, Chekaroua K. 3D evaluation and breast plastic surgery: preliminary study. *Ann Chir Plast Esthét* 2005;50(4):296-308.
- K.B.Clough, I.Sarfati, A. Fitoussi, P. Leblanc-Talent. Breast reconstruction: late cosmetic results of implant reconstruction. *Annales de chirurgie plastique esthétique* 50 (2005) 560-574.
- Kroll SS, Baldwin B. A comparison of outcomes using three different methods of breast reconstruction. *Plast Reconstr Surg* 1992;90:455. [4(1)
- Lagergren J, Jurell G, Sandelin K, et al. Technical aspects of immediate breast reconstruction with implants: Five year follow-up. *Scand J Plast Reconstr Surg Hand Surg* 2005;39:147-52
- Leis HP Jr. Managing the remaining breast. *Cancer*. 1980 Aug 15;46(4 Suppl):1026-30.
- Linell F, Ljungberg O, Andersson I. Breast carcinoma. Aspects of early stages, progression and related problems. *Acta Pathol Microbiol Scand Suppl*. 1980;(272):1-233.
- Metcalf KA, Semple JL, Narod SA. Satisfaction with breast reconstruction in women with bilateral prophylactic mastectomy: a descriptive study. *Plast Reconstr Surg* 2004;114:360-6.
- Nahabedian MY. Managing the opposite breast: contralateral symmetry procedures. *Cancer J* 2008 Jul-Aug;14(4):258-63.
- Niechajev I. Mammary augmentation by cohesive silicone gel implants with anatomic shape: technical considerations. *Aesthetic Plast Surg* 2001;25(6):397-403
- Olle Asplund and Gunilla Svane. Adjustment of the contralateral breast following breast reconstruction. *Scand J Plast Reconstr Surg* 17: 225-232, 1983. (

- P.Panettiere, L. Marchetti, D.Accorsi, G.A. Del Gaudio. Aesthetic Breast Reconstruction. *Aesthetic plast. surgery.* 26:429-435, 2002
- Parker PA, Youssef A, Walker S, et al. Short-term and long-term psychosocial adjustment and quality of life in women undergoing different surgical procedures for breast cancer. *Ann Surg Oncol* 2007; 14:3078-89.
- Peter G. Cordeiro, M.D. Breast Reconstruction after Surgery for Breast Cancer. *N.Engl.J.Med.* 359-15; October 9, 2008.
- Petit, J. Y., Rietjens, M., Contesso, G., Bertin, F., and Gilles, R. Contralateral mastoplasty for breast reconstruction: A good opportunity for glandular exploration and occult carcinomas diagnosis. *Ann. Surg. Oncol.* 4: 511, 1997.
- Ringberg A, Palmer B, Linell F. The contralateral breast at reconstructive surgery after breast cancer operation a histopathological study.. *Breast Cancer Res Treat.* 1982;2(2):151-61.
- Roldán, J. A. Lozano, J. Oroz. An. Sist. Sanit. Navar. Treatment of the contralateral breast in breast reconstruction. Nipple- areola reconstruction. P.. 2005; 28 (Supl. 2): 81-90.
- Rowland JH, Desmond KA, Meyerowitz, BE, Belin TR, Wyatt GE, Ganz PA. Role of breast reconstructive surgery in physical and emotional outcomes among breast cancer survivors. *J Natl Cancer Inst* 2000; 92:1422-9.
- Sigurdson L, Lalonde DH. MOC-PSSM CME article: Breast reconstruction. *Plast Reconstr Surg.* 2008 Jan;121(1 Suppl):1-12
- Tebbetts JB. Dual plane breast augmentation: optimizing implant-soft-tissue relationships in a wide range of breast types. *Plast Reconstr Surg.* 2006 Dec;118(7 Suppl):81S-98S; discussion 99S-102S.
- Vandeweyer E, Hertens D, Nogaret JM, Deraemaeker R. Immediate breast reconstruction with saline-filled implants: no interference with the oncologic outcome? *Plast Reconstr Surg* 2001;107: 1409-12.

IntechOpen



Current Concepts in Plastic Surgery

Edited by Dr. Frank Agullo

ISBN 978-953-51-0398-1

Hard cover, 264 pages

Publisher InTech

Published online 23, March, 2012

Published in print edition March, 2012

Plastic surgery continues to be a rapidly growing field in medicine. There have been multiple recent advancements in the field. Specifically, there has been a continuously growing interest in fat grafting, body contouring, minimally invasive surgery, and plastic surgery education. At the same time, there have been continued advances and modifications in surgical techniques, which translate into better and improved results for our patients while increasing safety and efficacy. The title of the book is Current Concepts in Plastic Surgery and, as such, it highlights some of the "hot topics" in recent years. We have invited renowned specialists from around the world to share their valued expertise and experience. Most of the chapters will expose the reader to multiple techniques for achieving desired results, with emphasis on the author's preferred methodology.

How to reference

In order to correctly reference this scholarly work, feel free to copy and paste the following:

Paolo Persichetti, Barbara Cagli, Stefania Tenna, Luca Piombino, Annalisa Cogliandro, Antonio Iodice and Achille Aveta (2012). Contralateral Breast Augmentation in Heterologous Breast Reconstruction, Current Concepts in Plastic Surgery, Dr. Frank Agullo (Ed.), ISBN: 978-953-51-0398-1, InTech, Available from: <http://www.intechopen.com/books/current-concepts-in-plastic-surgery/contralateral-breast-augmentation-in-heterologous-breast-reconstruction>

INTECH
open science | open minds

InTech Europe

University Campus STeP Ri
Slavka Krautzeka 83/A
51000 Rijeka, Croatia
Phone: +385 (51) 770 447
Fax: +385 (51) 686 166
www.intechopen.com

InTech China

Unit 405, Office Block, Hotel Equatorial Shanghai
No.65, Yan An Road (West), Shanghai, 200040, China
中国上海市延安西路65号上海国际贵都大饭店办公楼405单元
Phone: +86-21-62489820
Fax: +86-21-62489821

© 2012 The Author(s). Licensee IntechOpen. This is an open access article distributed under the terms of the [Creative Commons Attribution 3.0 License](#), which permits unrestricted use, distribution, and reproduction in any medium, provided the original work is properly cited.

IntechOpen

IntechOpen