

We are IntechOpen, the world's leading publisher of Open Access books Built by scientists, for scientists

4,800

Open access books available

122,000

International authors and editors

135M

Downloads

Our authors are among the

154

Countries delivered to

TOP 1%

most cited scientists

12.2%

Contributors from top 500 universities



WEB OF SCIENCE™

Selection of our books indexed in the Book Citation Index
in Web of Science™ Core Collection (BKCI)

Interested in publishing with us?
Contact book.department@intechopen.com

Numbers displayed above are based on latest data collected.

For more information visit www.intechopen.com



Challenges in Sacral Neuromodulation

Mai Banakhar¹, Tariq Al-Shaiji² and Magdy Hassouna³

¹*Clinical Fellow Toronto Western Hospital, King Abdul Aziz University*

²*Clinical Fellow Toronto Western Hospital*

³*Urology Toronto Western Hospital, Toronto University
Canada*

1. Introduction

Sacral neuromodulation (SNM) is an effective and increasingly used therapeutic option for refractory urge incontinence, chronic urinary retention and symptoms of urgency-frequency. The potential for neuromodulation has also been shown in patients with interstitial cystitis and neurogenic urge incontinence secondary to refractory detrusor hyperreflexia. With the increasing number of patients, obvious concerns and challenges raised. Young female patients who desire to conceive showed concerns pertaining to neuromodulation in pregnancy including possible teratogenic effect, symptom management during pregnancy & the effect of mode of delivery on the Sacral electrode. Another concern is the need for MRI follow up in neurogenic patients. Post operative troubleshooting raises another challenge in patient management. In our chapter, we will discuss these challenges in details.

2. Historical overview of neurostimulation

Knowledge of the neurological associations among spinal marrow, nerves, and the urinary bladder arose after the middle of the nineteenth century. In 1863 Giannuzzi stimulated the spinal cord in dogs and concluded that the hypogastric and pelvic nerves are involved in regulation of the bladder (Giannuzzi, 1863). The first attempt at bladder stimulation occurred in 1878, when Saxtorph treated patients with urinary retention by way of intravesical electrical stimulation (Madersbacher, 1999) After experimentations with various methods of stimulating the bladder such as the transurethral approach, direct detrusor stimulation (Boyce et al, 1964), pelvic nerve stimulation (Dees JE, 1965), pelvic floor stimulation (Caldwell KP, 1963), and spinal cord stimulation (Nashold et al, 1971) were carried out. Based on the work of Tanagho and Schmidt it was demonstrated that stimulation of sacral root S3 generally induces detrusor and sphincter action (Heine et al, 1977) (Schmidt et al, 1979) (Tanagho et al, 1982) (Tanagho, 1988). In 1988, Schmidt described the three stages of electrode placement (Schmidt, 1988). In 1988, a neuroprosthesis was first used for treatment of pelvic pain, and discomfort improved over 50% in 49% of patients (Schmidt, 1988). In 1990, Tanagho presented the results of Neurostimulation for incontinence, 70% of 31 patients with urge incontinence obtained subjective improvement of 50% or more, as did 40% of 25 patients with post prostatectomy incontinence (Tanagho, 1990). Two years latter, Tanagho published the results of neuromodulation in 27 children: five of seven children with meningomyelocele gained continence, as did four of six patients with voiding

dysfunction and one of two patients with neonatal hypoxia (Tanagho, 1992). In 1998, Shaker and Hassouna evaluated the efficacy and safety of sacral root neuromodulation. They concluded that, for non obstructive urinary retention, sacral root neuromodulation is an appealing, efficacious treatment. Implantation is relatively simple and carries a low complication rate (Shaker & Hassouna, 1998). Finally, in October 1997, after two decades of experimentation with various approaches to sacral root stimulation, Sacral Neurostimulation (SNS) was approved by the Food and Drug Administration (FDA) for the treatment of Urge incontinence (UI) and Urgency -frequency syndrome (U/F). In 1999, it was approved for the treatment of non-obstructive urinary retention (NOUR). Since the approval, a number of technical advances has been made. The introduction of tined lead had made a dramatic change in surgical approach. Spinelli et al reported that the success rate of this technique in selective patients for the permanent implant is significantly higher (70%) than what is reported in the literature (50%). Outcomes of the implanted patients confirmed better patient selection with minimal complication. This technique allows the possibility of more accurate patient selection by using the definitive lead for longer test period before proceeding with the neurostimulator (IPG) implant (Spinelli et al, 2003).

3. How does it work?

The Exact Mechanism of action is not well understood. A number of theories have been proposed to explain the effect of electrical neuromodulation which can be summarized as: somatic afferent inhibition of sensory processing in the spinal cord. Regardless of whether the lower urinary tract dysfunction involves storage versus emptying abnormalities, the pudendal afferent signaling serves as a common crossroads in the neurologic wiring of the system. Not only can pudendal afferent input turn on voiding reflexes by suppressing the guarding reflex pathways, pudendal afferent input to the sacral spinal cord also can turn off supraspinally mediated hyperactive voiding by blocking ascending sensory pathway inputs. (Kruse and Groat, 1993), (Thon et al, 1991), (Vadusek et al, 1986), (Groat et al, 1997), (Kruse et al, 1990), (Groat and Theobald, 1976)

Other possible mechanisms of sacral nerve stimulation include:

- Inhibits postganglionic neurons directly
- May inhibit primary afferents presynaptically
- Inhibits spinal tract neurons involved in the micturation reflex
- Inhibits interneurons involved in spinal segmental reflexes
- May suppress indirectly guarding reflexes by turning off bladder afferent input to internal sphincter sympathetic or external urethral sphincter interneurons
- Postganglionic stimulation can activate postganglionic neurons directly and induce bladder activity (induce voiding), but at the same time can turn off bladder-to- bladder reflex by inhibiting afferent- interneuronal transmission. (Wendy and Michael, 2005)

4. Indications for sacral nerve stimulation therapy

The US Food and Drug Administration (FDA) approved Sacral neuromodulation (SNM) for three main conditions: intractable urge incontinence in 1997, and for urgency- frequency and non obstructive urinary retention in 1999 (Shaker & Hassouna, 1998). Latter, the labeling was changed to include "overactive bladder" as an appropriate diagnostic category (Abrams

et al, 2009). Patients in this group are considered candidates for SNS if they have chronic symptoms, refractory to medical therapy. (Apostolicism, 2011) (Knupfer, 2011) The Urodynamics study may or may not demonstrate uninhibited bladder contractions. Their symptoms include urinary urgency-frequency and urge incontinence (Al-Shaiji et al, 2011) (Abrams et al, 2003) (Siegel et al, 2000). Since its inception, widespread use for approved conditions has led to incidental improvements in other areas. Research is ongoing to channel the potential of neuromodulation into other applications.

4.1 Neurogenic disorders

Patients who have defined neurologic abnormalities such as multiple sclerosis (MS) or partial cord injury also may benefit from SNS, but studies in this population of patients have been few (Bosch and Groen, 1996)(Hassouna et al,2000). In spinal cord injured patients, detrusor hyperreflexia develops after spinal shock period resolves. Vastenholt reported (Vastenholt et al, 2003) a series of 37 patients with spinal cord injury who underwent implantation of sacral anterior root stimulation. He reported his 7 year follow-up of the group in which 87% continued using the implant for micturition control, 60% used it for benefits with respect to defecation. Of the 32 male patients, 65% were able to achieve a stimulator- induced erection. (Everaert et al, 1997) reported the urodynamic changes in 27 neuromodulation implanted patients with spastic pelvic floor syndrome, bladder neck dysfunction, sphincter hypertonia, sphincter dysfunction, detrusor overdistention and hypercontractile detrusor.

Other demyelinating disease as Guillain-Barre syndrome with voiding dysfunction has been reported to respond to sacral neuromodulation therapy (Wosnitzer et al, 2009). A study on incomplete spinal cord injured patients suffering from lower urinary tract symptoms showed that SNM is effective (Lombardi and Del, 2009). Chaabane et al reported a mean follow up of 4.3+/- 3.7 years, SNM is still effective in neurogenic bladder dysfunction group, and failures depend on the progression of the underlying neurological disease which usually are reported in the first year of follow up (Chaabane et al, 2001).

4.2 Interstitial cystitis (IC) and pelvic pain

IC per se is not an FDA approved indication for SNM; these patients have a set of symptoms of frequency, urgency and pelvic pain which in combination considered as characteristic of IC. A lot of studies showed patient symptoms relieve with SNM (Lukban et al, 2002) (Everaert et al, 2001) improved patient quality of life & narcotic requirements in refractory IC (Siegel et al, 2001) (Comiter, 2003). Peters reported total of 18 out of 21 interstitial cystitis patients who used chronic narcotics before Interstim, with the remaining three using non-narcotic analgesics. The mean narcotic use dropped from 81.6 mg/day Morphine Dose Equivalent (before implantation) that decreased afterward to 52.0mg/day (36%, P=0.015). Four of 18 patients ceased using all narcotics after permanent Interstim implantation (Peters, 2003). Ghazwani et al reported long term follow up of 21 female patients with painful bladder syndrome in which 52% showed response to PNE and proceeded for permanent IPG implantation. They had a significant improvement in bladder pain and voiding parameters at 1- year follow-up which was maintained at 5 years, with improvement in urgency & average voided volume. (Ghazwani et al, 2011). Gajewski and Al-Zahrani

recommended SNM in these patients before any major invasive surgical interventions if the conservative measures have failed (Gajewski and Al-Zahrani, 2010).

4.3 Chronic genitourinary pain

SNM has been used to control a variety of forms of genitourinary pain. Chronic non bacterial prostatitis & chronic epididymo-orchalgia are a common challenge that had hope with SNM. Feler et al reported a 75% improvement in a 44y male diagnosed with chronic epididymitis and chronic non bacterial prostatitis (Feler et al, 2003). Vulvodynia consists of chronic vulvar discomfort including itching, burning and dyspareunia. Feler et al reported a 71y female who suffered of Vulvodynia for 9 years in which sacral neuromodulation provided excellent pain relief. (Feler et al, 2003).

4.4 Sexual function

There are few reported cases claiming improved sexual function in both male & females. Lombardi et al reported sacral neuromodulation for lower urinary tract function in male patients which showed impact on their erectile function. Total of 22 patients had their IEF-5 score shifted from 14.6 to 22.2 (Lombardi et al, 2008). In females, papers reported improvement in sexual function index of arousal and lubrication in voiding dysfunction female group (Lombardi et al, 2008). Pauls et al reported total female sexual function index improvement ($p=0.002$), and significant improvement domains of desire ($p=0.004$) and lubrication ($p=0.005$) in voiding dysfunction group (Pauls et al, 2006). However, all these reported papers were reported in voiding dysfunction group. No studies were constructed yet on any pure sexual dysfunction cases. Signorello et al claimed that the improvement in quality of sexual function in female patients with overactive bladder correlates with improvement in urinary symptoms (Signorello et al, 2011). In unpublished data from our center, female sexual function overall indices improved in voiding dysfunction female group $P=0.028$ (CI-23.14- -1.62), the parameters of satisfaction= 0.037 (CI -4.9- -0.0177) & lubrication $P=0.018$ (CI -6.082 - -0.687) showed significant improvement in comparison to the other parameters (Banakhar et al, 2011)

4.5 Children

Similar to adults, children are faced with various degrees of lower urinary tract dysfunction that often deteriorate upper tract function. Usual treatment modality of intermittent catheterization & Anticholinergics are not uniformly successful and major reconstructive procedures are needed. Humphreys et al reported SNM in 16 children with refractory voiding dysfunction with mean age of 11 years. His study group showed 75% improved or resolved urinary incontinence, 83% improved their nocturnal enuresis, urinary retention improved in 73% of patients (Humphreys et al, 2004)

4.6 Non urologic indications

Angina pectoris (Van at al,2011), chronic migraine (Magis and Schoenen, 2011), fecal incontinence (Pascuall et al, 2011). The overall published results for SNM include all etiologies of fecal incontinence. Melenhorst et al reported 132 patients who had temporary stimulation. 100 were implanted (75%), the mean age was 75 years (26 -75 years) and the

mean follow up was 25 months (2-63 months), the mean number of incontinence episodes decreased from 31 to 4.8 ($P < 0.0001$) as documented in a bowel diary (Melenhorst et al, 2007). SNM is also indicated for constipation (Van et al, 2011). Masin et al reported results in 34 patients with chronic idiopathic constipation with a median follow-up of 12 months (93-48). Cleveland Clinic Constipation score decreased significantly from (mean \pm SEM) 14 ± 8.3 to 7.5 ± 4.9 (Masin et al, 2005). Other indications include deep brain stimulation for Parkinson's (Hilker, 2010).

5. Contraindications

SNM is contraindicated in patients with anatomical bony abnormalities of the sacrum, in which transforaminal access may be difficult or impossible. Patients with mental incapacity or psychiatric illnesses rendering them incapable of operating the device. Patients who have undergone an unsuccessful SNS Trial (test stimulation). Others include coagulation disorders and local acute sacrum infection. SNM appears to be safe in the presence of a cardiac pacemaker without cardioversion/ defibrillation technology (Wallace et al, 2007) (Roth, 2010). Some conditions are considered challenging as MRI & pregnancy; however, more details are discussed upcoming in the chapter.

6. Surgical technique

After complete clinical evaluation by history, examination & Urodynamics assessment, all patients need to fill up a voiding diary for minimum of 3 days (baseline), which will assess the number of voids, the voided volumes, the degree of urgency and in patients who experience inefficient voiding or retention, the amount voided versus catheterized volumes per 24 hours and the patient's sense of completeness of evacuation. Associated symptoms such as pelvic pain and bowel symptoms are also assessed. Latter, this diary will be used to assess the patient objective response to the test stimulation trial. Patients are counseled for the option of sacral neuromodulation and procedure risk and benefits are discussed with the patient. The first crucial step in determining if the patient is a good candidate for definite implant is a test stimulation trial. Test stimulation can be either percutaneous nerve evaluation (PNE) also called one-stage implant, or two staged implant in which the first step in two staged implant is the test trial.

6.1 One – Stage implant

Patients will undergo stimulation test trial named percutaneous nerve evaluation (PNE), which will determine if the patient is a candidate for permanent SNM. PNE is done as an outpatient procedure. It involves placement of a thin insulated wire into the third sacral foramen. Usually fluoroscopy is needed to localize the foramen during the PNE insertion. In our center, we perform it without any fluoroscopy, rather than that, we depend on the landmarks & patient sensory and motor response for localization table 1. After describing the procedure for the patient, marking of the bony landmarks are done while patient is in the prone position. The greater sciatic notch is palpated & marked bilaterally. The level of the notch marks the Y axis. The Medline is marked; one fingerbreadth laterally on each side marks the X axis. The meeting point of the Y & X axis resembles the third sacral foramen see figure 1. After cleaning & draping, local anesthesia is used for the skin & subcutaneous

tissue. In our center, we use 1% plain Lidocaine, for both sides. Usually 10 cc will be enough but sometimes additional 10cc will be needed in some patients, however, the maximum total injected Lidocaine is 20 cc of 1% to avoid side effects.

Tips

*Be sure not to inject local anesthetic into the foramen, which will mask the desired response. To do so, we insert the needle until we hit bone before injecting which helps confirming that we are not passing through the halo of the foramen.

*If the needle is inserted at the sciatic nerve, it would elicit S3 stimulation response, to be sure that the needle is in the canal, use a second foramen needle and insert it just lateral to your target needle. If it hits bone, this confirms that your target needle is in the canal, but if not it means most probable you are not.

The procedure is done bilaterally, and the side giving better response will be chosen for wire insertion. Using the foramen needle, Long foramen needle is usually needed in obese patients, the third sacral canal is cannulated at the marked area. During insertion an angle of 60 degree should be maintained to access the canal. The sacral bone will be felt first; with minimal movement the canal can be cannulated. Then, the patient response is assessed by intermittent stimulation with external pulse generator (EPG). The target response of the thirds sacral foramen includes bellows contraction of the pelvic floor (e.g., rectum, vagina, scrotum and perineum) and planter flexion of the great toe, to some extent. S2 placement will result into planter flexion of the entire foot with lateral rotation, whereas S4 will reveal no lower extremity movement despite bellows response. Once the appropriate side and position is selected, the temporary unipolar lead is inserted through the needle and then connected to an external pulse generator and fixed with tape to the skin. At the end of the procedure the patient is given a voiding diary to fill up while the wire is in to assess her/his response for the stimulation. Patient is given instructions on how to manage the temporary lead during the test period to avoid any inadvertent migration or misuse. After a trial period of 3-5 days the patient will be assessed in the clinic for subjective and or, objective improvement by comparing the pre and post voiding diaries. If the patient developed 50% or more improvement (Subjectively or / and objectively), she/he will be considered as a candidate for permanent SNM implantation & removal of the temporary lead is done in the clinic. A baseline Sacrao-Coxygeal AP-Lateral X-rays are obtained to document lead position. If the patient claimed no benefit we question if they had intact sensation of the vibration at the target area, if not, a sacrao-coxygeal X-rays should be taken to rule out lead migration which is usually the cause of the false negative results. The maximum duration of this test is limited to 14 days to avoid bacterial contamination (Pannek et al, 2005). Antibiotic prophylaxis is not needed.

Limitations of this approach include lead migration, and potential discrepancy in clinical response with the permanent quadripolar lead implantation. Short term test stimulation period as well as lead migration probably explains the relatively low success rate of PNE, estimated at around 50% (Peter et.al, 2003)(Borawaski et.al , 2007).According to Everaert et.al false- positive PNE compose 33% of cases in home patients who have a beneficial test stimulation with a temporary lead do not continue to have a successful outcome after the permanent lead implantation (Everaert et al ,2004) . In our center, we adapted an algorithm

to minimize the false negative cases that can gain benefit from SNM but their test trials were negative see figure 2.

Nerve root	Motor response	Sensory response
S2	Anal sphincter contraction (A-P pinching of perineum/ coccyx), leg/heel rotation, planter flexion of foot, calf contraction.	Sensory alteration of the base of penis or vagina.
S3	Bellows (inwards contractions), plantar flexion of great toe.	Rectal sensation, extending into scrotum or labia.
S4	Bellows	Rectal sensation only

Table 1. Sacral roots, motor and sensory response (Bullock and Siegel, 2010).

6.2 Two – Stage implant

If the patient is not a candidate for office-based test stimulation (e.g. obese, difficult anatomy, previous sacral surgery or unable to tolerate the procedure under local anesthesia) or did not respond to the in-office test, test stimulation may be performed in the operating room. Furthermore, the immediate implantation of a permanent lead aims to avoid lead migration and allows prolonged patient screening. (Kessler et.al. 2005)(Kessler et al, 2007). The procedure involves using the quadripolar leads which fix the lead into the foramen & avoid migration.

The test response can be performed using intravenous sedation, local anesthesia or general anesthesia. In case of general anesthesia, the anesthetist is reminded to avoid any long-acting muscle relaxants which may impair sacral nerve stimulation or visualize their motor response. Note that the upper body nerves recover earlier than the sacral nerve, the anesthetist may claim recovery of the muscle relaxant in the absence of sacral response may imply delayed recovery and the surgeon may need to wait more time (about 10 minutes) to have a response. Fluoroscopy C-arm is used to facilitate placement of the quadripolar permanent lead. Once it is inserted into the foramen, using the foramen needle, followed by guide wire & foramen dilator, it is tested by bipolar stimulation (by EPG, PW210, Rate 14, Amplitude 10 volts) in all 4 positions 0,1,2,3, for response. After which, the dilator sheath is withdrawn under fluoroscopic guidance figure 3. Fluoroscopy views are important and taken as baseline pictures to locate the S3 foramen in correlation with the greater sciatic notch and the skin marking which we made. Then during the lead insertion to confirm being in proper position & the last electrode is at the lower surface level of the sacral foramen. Finally, the dilator sheath is removed under continuous fluoroscopy to avoid electrode movement from its proper position, and the last picture of the position will be considered as a baseline for future patient follow-up if developed any complications figure 4. The lead is then tunneled deeply through the subcutaneous fat to the right or left buttock depending on the patient dominant hand side where the permanent implantable pulse generator (IPG) will be placed in the second stage if the patient is considered as a candidate. The lead is attached to the temporary connector and then tunneled through the subcutaneous fat to an alternative exit site. This is particularly an important step because if the patient developed superficial skin infection, then the alternative exit site would help prevent the infection from spreading to the lead and future permanent IPG location (Kohli and Patterson, 2009). Finally, the lead is connected to an external pulse generator and taped to the skin surface. A test period of 14 days is used to determine which patient meets the criteria to have the permanent IPG implanted. At the end of the test period

the patient returns to the OR for either removal of the lead or implantation of the IPG, depending on the subjective and/ or objective responses, Figure 4D.

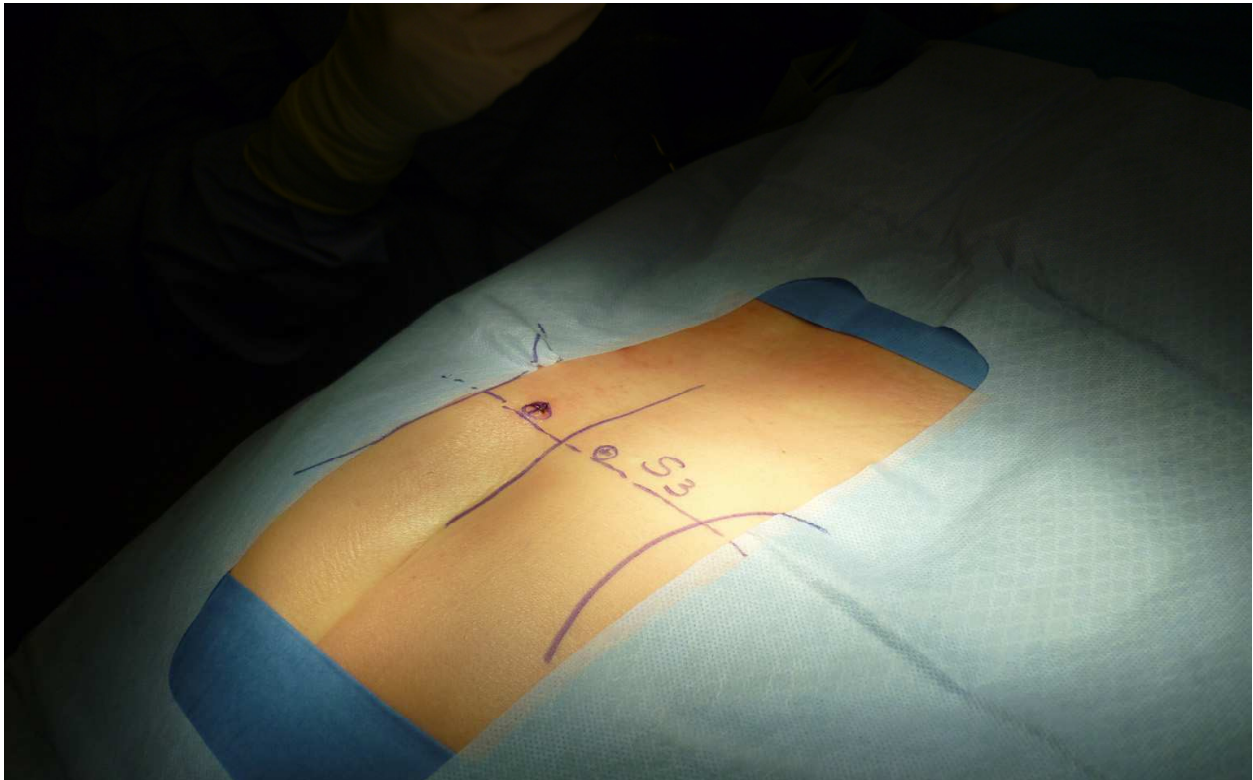


Fig. 1. Landmarks for S3. The curved line on each side resembles the greater sciatic notch which level corresponds for the Y axis, while one fingerbreadth from the marked midline is the X axis. S3 foramen is the joining point between the Y and X axis.

Tips

If no response can be demonstrated by the stimulation check the connection between the hook & the EPG, if it was well connected, check the battery of the EPG which can be expired. If all are working properly most probably the nerves are still under the effect of the muscle relaxant. Ask the anesthetist to reverse the effect of muscle relaxant if feasible & wait for the nerve to recover. Notice that the upper body nerves recover faster than the sacral nerves.

6.2.1 PNE versus staged testing

The PNE is a simple, safe, inexpensive, office- based procedure which is carried out under local anesthesia .A prospective randomized study showed that the two stage implant technique of SNM has a higher success rate compared to the one- stage method despite prior positive PNE in both short & long term (Everaet et al, 2004). Another important study by Borawaski et al reported significant positive results in the two stages procedures who proceeded with IPG implantation more that the PNE group in a randomized study (88% compared to 46%)(Borawaski et al, 2007).Other studies reported that the sensory response assessment at the time of implantation reduced the reoperation rate from 43% to 0% (Peters et al,2003) .The cost for the test protocol with the tined leads (two- stage procedure) are

much higher compared to the PNE . Currently, the use of either one of the two screening options is arbitrary. In our center, one –stage procedure is the trend unless the two stage is indicated with difficult PNE (technical, anatomical, not cooperative patient).In our hands, most of the PNE has high success rate in comparison to two- stage procedure see table 2.

6.2.2 Unilateral versus bilateral test stimulation

Unilateral sacral nerve stimulation is the most widely used method of testing for suitability for permanent sacral Neurostimulation implantation. It has been proposed that based on the bilateral innervations of the bladder, bilateral sacral nerve stimulation may improve the efficacy of this therapy. In a prospective randomized crossover trial comparing unilateral with bilateral stimulation using PNE screening, bilateral stimulation appeared to offer no definite advantage over unilateral stimulation. However, 2 of 13 patients voided only with bilateral stimulation and remained in retention with unilateral stimulation (Scheepens et al, 2002).The authors concluded that bilateral test stimulation should be considered when unilateral stimulation fails. Further studies are needed to evaluate the role of bilateral stimulation during test stimulation trials, as well as during post implantation chronic phase.

6.3 Implantation

6.3.1 Position

Buttock placement (figure 4D) of the IPG has an attractive alternative to the subcutaneous implantation in the lower part of the anterior abdominal wall because of shorter operation time, avoidance of repositioning the patient during the operation and lower incidence of complications (Scheepens et al, 2001) .

6.3.2 Technique

After successful test phase, the patient is brought to the OR for implantation of the permanent implantable pulse generator (IPG).If the first test was one stage, fluoroscopy is needed for permanent lead insertion. Broad spectrum preoperative antibiotics as Ampicillin and Gentamicin are given intravenously. (We usually perform 5 minutes scrubbing of the operative field with dilute Povidone-iodine in addition to prepping with chlorhexidine). The quadripolar tined lead is inserted in a similar fashion on the side where the patient had the best PNE test response. The lead is then tunneled in the subcutaneous fat to a pocket formed in the left or right buttock region according to the patient hand dominant site. It is attached to the connector & IPG which will be buried deep in the subcutaneous pocket. On the other hand, if the first phase was two- staged procedure the implantation is done as the 2nd stage, it does not require fluoroscopy, and can be done under local or general anesthesia. The previous incision where the temporary connector was placed in the buttock is opened and the permanent IPG is connected to the lead after removal of the temporary connection system. A pocket is formed & irrigated with antibiotic mixed with sterile water to minimize infection risk. Then, the IPG is buried deep in the subcutaneous tissue in the buttock. Post operatively, the IPG is switched on and programming is done.

Sterile water is used in irrigation and mixing with antibiotics, avoids electrical circuit formation & IPG erosion.

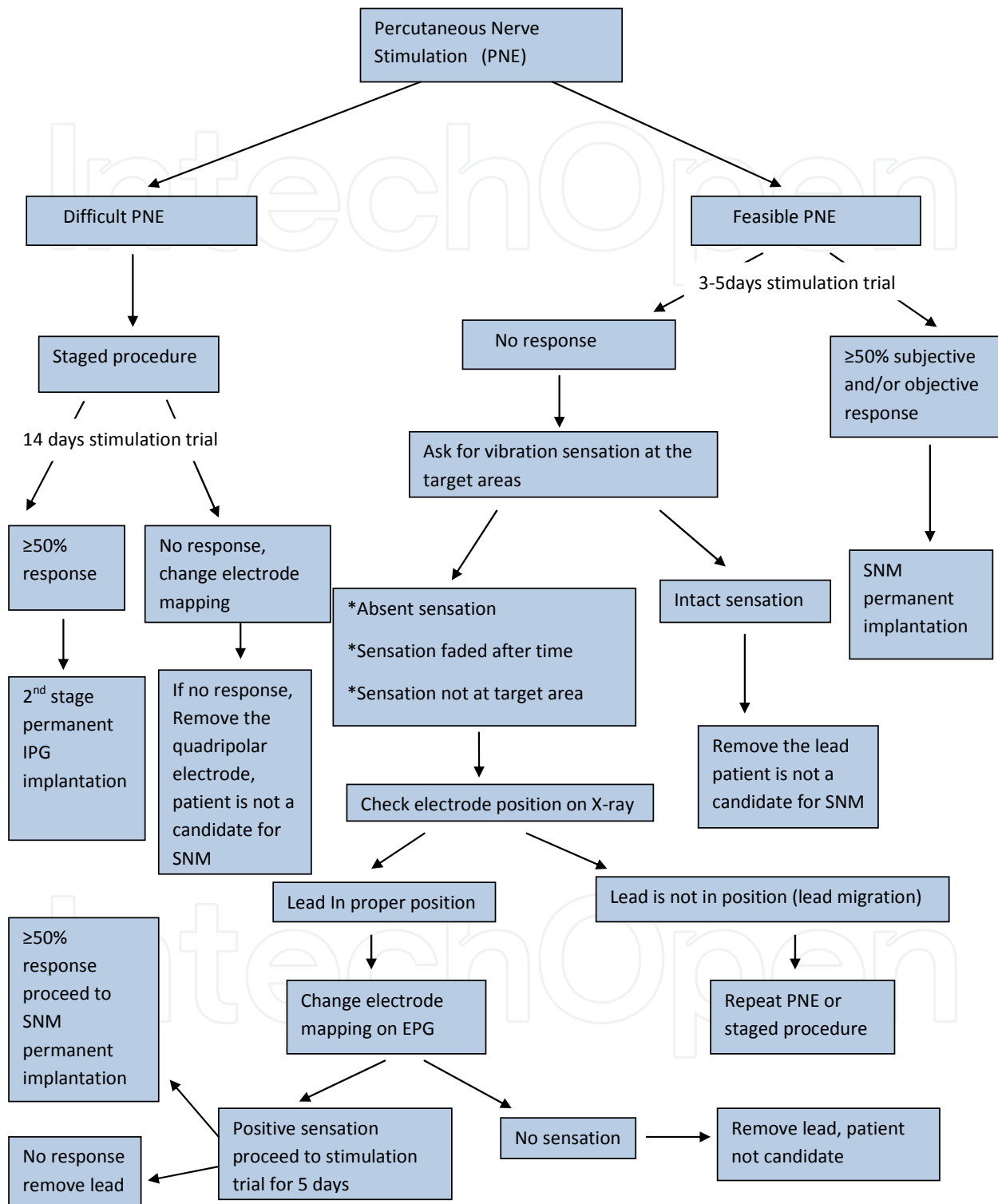


Fig. 2. Algorithm adapted by the Authors to minimize the false negative cases in Stimulation test trial

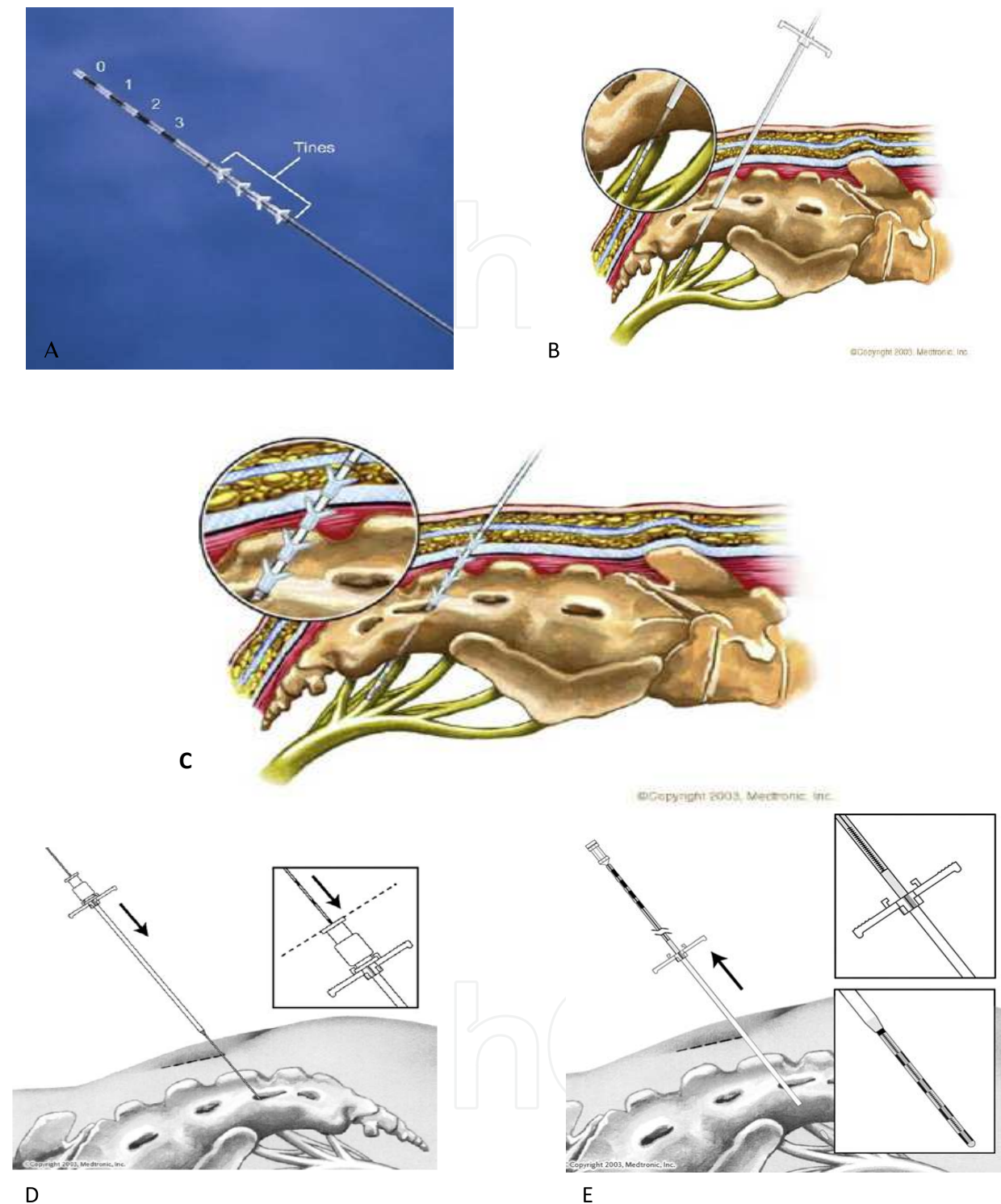


Fig. 3. A: Quadripolar tinned lead , the electrodes are shown, B: Sacral foramen needle is inserted and guided to the desired location, C: Location is verified by electrical stimulation to the needle, and fluoroscopy is used to confirm the position of the needle in the S3 foramen, D: The metal dilator is removed and plastic dilator is positioned, E: The quadripolar lead is introduced through the dilator plastic sheath into position which is confirmed by stimulation, the plastic dilator sheath is withdrawn carefully under fluoroscopic guidance Pictures adapted from Medtronic Inc, 2003.

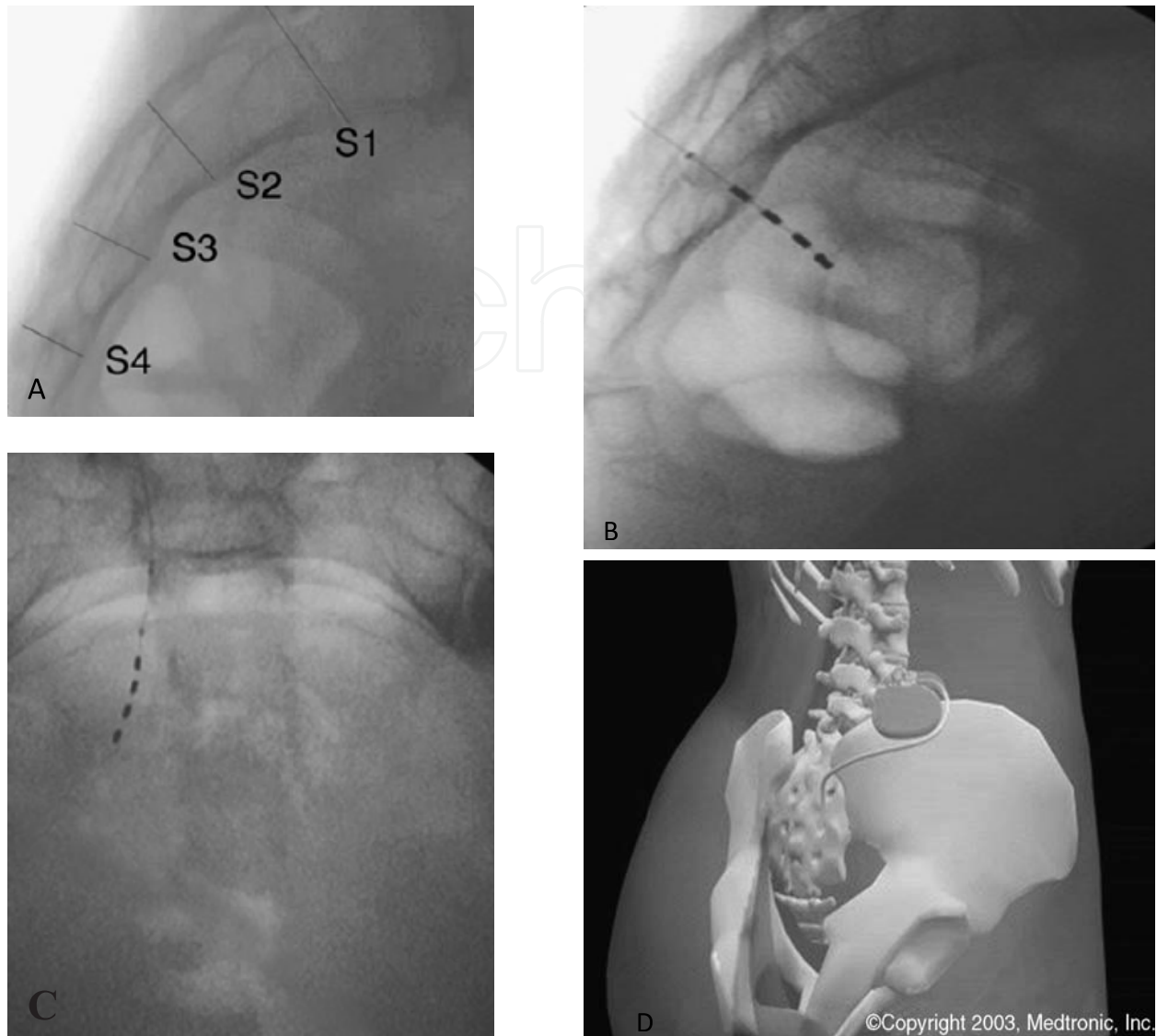


Fig. 4. A: Fluoroscopic view of the sacral foramina, B: Permanent electrode leads position; note that the last electrode is located at the lower surface of the sacral canal, C: A-P view of the electrode position, D: IPG position. Pictures adapted from Medtronic Inc, 2003.

7. Complications

The Sacral Nerve Stimulation study group has published several reports on the efficacy and safety of the procedure for individual indications. Siegel summarized the reported efficacy and complications in the total patient group who were included in the trials conducted by the neuromodulation study group. The complications were pooled from the different studies because the protocols, devices, efficacy results and safety profiles were identical. Of the 581 patients, 219 underwent implantation of the Interstim system (Medtronic, Minneapolis, Minnesota).

The complications were divided into percutaneous test stimulation-related and post implantation related problems. Of 914 test stimulation procedures done on the 581 patients, 181 adverse events occurred in 166 of these procedures (18.2% of the 914 procedures). Most

complications were related to lead migration (108 events, 11.8% of procedures). Technical problems and pain represented 2.6% and 2.1% of the adverse events. For the 219 patients who underwent implantation of the InterStim system (Lead and generator), pain at the neurostimulator site was the most commonly observed adverse effect at 12 months (15.3%) (Siegel et al, 2000) table 3.

Cleveland Clinic reported complication rate in 160 patients who proceeded to permanent IPG implantation from total of 214 lead implants. 17 patients (10.5%) had device completely removed for infection and failure of clinical response. 26 patients (16.1%) underwent device revision for attenuated response, infection, IPG site pain and lead migration. The majority of patients with revisions due to poor response had an abnormal impedance measurement. As a result, the author strongly advocate impedance measurement in patient evaluation in patients with response related dysfunction (Hijaz et al, 2006)

PNE (one- stage)	Tined lead (Two -stage)
<p>Advantages:</p> <ul style="list-style-type: none"> • In-office, under local anesthesia. • Greater patient acceptance(Minimal invasive) • Removal of leads in office , no need for experience • Accurate patient feedback during insertion (no interference from IV sedation) • Less costly, more favorable reimbursement. • Less risk of infection since permanent lead and IPG will be placed in one sitting after successful PNE. 	<p>Advantages:</p> <ul style="list-style-type: none"> • Less risk of lead migration during the test trial. • Greater comfort due to level of sedation for anxious or pain focused patients. • Quadripolar lead configuration allows for more precise placement and programming. • Symptom improvement remains unchanged when converted to chronic implant. • Longer trial period to assess for symptom improvement • Higher rate of true positives.
<p>Disadvantages:</p> <ul style="list-style-type: none"> • Higher rate of false negatives. Must do staged implant if equivocal. • Potential to place permanent lead in less favorable location, thus requiring re-operation. 	<p>Disadvantages:</p> <ul style="list-style-type: none"> • Requires two surgeries even if trial is unsuccessful • Greater potential for infection due to increased length of trial and potential contamination of permanent lead. • More expensive if trial is unsuccessful

Table 2. Comparison of the advantages and disadvantages of one- stage (PNE) and two - stage implant (with tined lead) (Elizabeth et al 2010)

7.1 Lead migration

Lead migration can be simply resolved by reprogramming, reinforcing the lead or insertion of a new lead contra-laterally (Deng et al, 2006) some patients lose benefit due to accommodation to the stimulation, but contralateral placement can be attempted to overcome this phenomenon (Wagg et al., 2007)

7.2 Infection

When infection is diagnosed, the best management is explantation of the IPG, debridement of the infected tissue & antibiotics. The lead can be left behind but keeping in consideration that the infection may spread through it & if needed, may be removed. The wound is left to heal by secondary intention & the patient is covered with antibiotic for two weeks. Another IPG implantation can be considered after 6-8 weeks if inflammatory signs has resolved.

Complication	Probability of occurrence (Siegel series)
Pain at the Neurostimulation site	15.3%
New pain	9%
Suspected lead migration	8.4%
Infection	6.1%
Transient electric shock	5.5%
Pain at lead site	5.4%
Adverse change in bowel function	3.0%
Technical problems	1.7%
Suspected device problems	1.6%
Change in menstrual cycle	1.0%
Adverse change in voiding function	0.6%
Persistent skin irritation	0.5%
Suspected nerve injury	0.5%
Device rejection	0.5%

Table 3. Reported complications with sacral neuromodulation therapy from the neuromodulation study group (Siegel et al, 2000)

7.3 Impedance related complications

Impedance describes the resistance to the flow of electrons through a circuit. Impedance or resistance is an integral part of any functioning circuit, but if there is too much resistance, no current will flow (Open). On the other hand, if there is too little resistance, an excessive current flow results in diminished battery longevity (Short). In the InterStim system, the circuit travels from the electrode through the patient tissue to another electrode (Bipolar) or through the patient tissue to the neurostimulator case (IPG) (Unipolar).

Impedance measurement is used as a troubleshooting tool to check the integrity of the system when the patient present with sudden or gradual disappearance of stimulation. Usually the normal measurement falls between 400 and 1500 Ω . High levels (>4000 Ω) identify open circuit, usually is caused by fractured lead or extension wires, loose connections. In open circuits, the patient feels no stimulation. In these cases, the programmer which measures the impedance can be used to know which electrode is broken. Managing these cases can be done by reprogramming .The new mapping should avoid the broken electrode. If reprogramming is exhausted in these cases with no benefit, then revision is done. The aim of the revision is to identify the source of the open circuit (the electrode or connection).

On the other hand, low levels (<50 Ω) identify short circuits which can be caused by body fluid intrusion into the connectors or crushed wires that are touching each other. Patients

may not feel stimulation, or may feel it away from the correct area as the IPG pocket. Again, reprogramming followed by revision are the options in these cases.

7.4 Pocket (IPG site) pain, discomfort

IPG site pain is caused by either pocket -related, or output- related causes, see figure 5. To determine which is the case in the patient; turn the IPG off, if pain or discomfort persist, it means that the patient is having a pocket- related cause. Revision of the IPG and relocation can resolve the problem.

If the pain disappears, that implies an output- related cause. In these cases, check the patient mapping. If the patient is having a monopolar one change it into a bipolar (some patients are sensitive to the unipolar because the positive pole is the IPG). Another possibility is current leak, try reprogramming (Mapping, Pulse width, and rate). If it did not show any benefit, ask the patient if that discomfort is tolerable (burning sensation usually at the pocket and perineum), if not revision is advocated

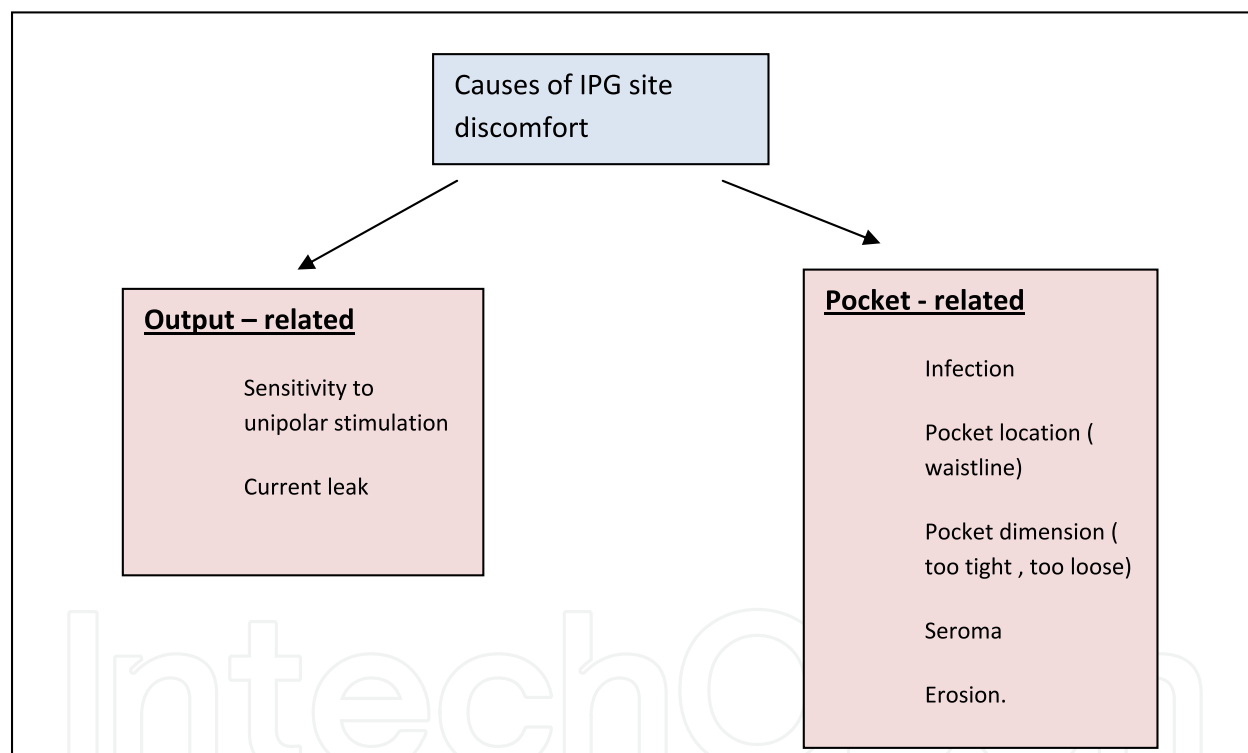


Fig. 5. Causes of IPG site discomfort (Hijaz et al, 2005)

7.5 Recurrent symptoms

When the patient presents with recurrent symptoms, we need to evaluate the impedance, battery, and stimulation perception. The impedance abnormalities were discussed previously. If the battery was low with decreased sensation, this warrants new IPG (battery) exchange (Anecdotally, the battery mean half life we have encountered ranged between 7 to 9 years, depending on the usage). The possibilities are that the patient perceives the stimulation in wrong area compared with the baseline, has no stimulation, or has intermittent stimulation, see management algorithm at figure 6

8. Contraindications for patients with implanted IPG

Contraindications for patients with implanted IPG include short wave diathermy, microwave diathermy or therapeutic ultrasound diathermy (Medtronic professional use manual, 2011). MRI & pregnancy are special conditions at which implanted Neurostimulation is contraindicated

8.1 Diathermy

The diathermy's energy anywhere in the body can be transferred through the implanted system and can cause tissue damage which could result in severe injury or death. Diathermy can also damage parts of the Interstim therapy system. This can result in loss of therapy from the Neurostimulation, and can require additional surgery to remove or place parts of the Interstim therapy system.

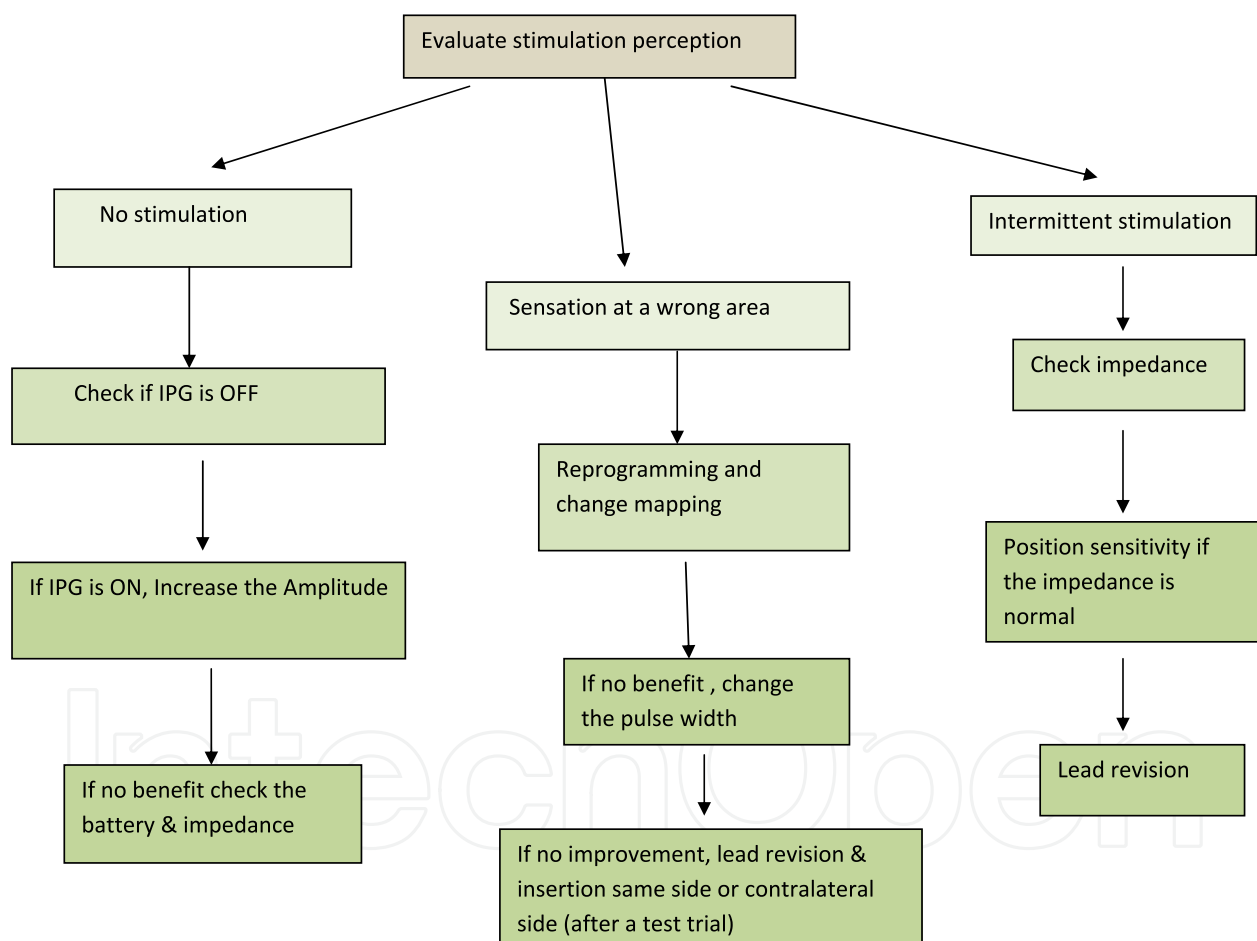


Fig. 6. Management algorithm for different stimulation perception (Hijaz et al, 2005).

8.2 Neuromodulation and MRI

MRI is a safe, non invasive and essential diagnostic tool. Currently the number of patients who have bladder Neurostimulation is growing rapidly. For many reasons, their conditions often need magnetic resonance (MRI) examination. However the current practice is to contraindicate patients with implantable devices (Shellock and Kanal, 1992) (Achenbach et

al, 1997). Medtronic product technical manual indicates that exposure to MRI can potentially injure the patient or damage the Neurostimulator (Medtronic professional use manual, 2011). The induced electrical current from the MRI to the Interstim therapy system can cause heating, especially at the lead electrode site, resulting in tissue damage. The induced electrical current can also stimulate or shock the patient. The precaution is applied even if only a lead or an extension is implanted; it does not only apply to the IPG alone. Few factors increase the risk of heating and injury, but are not limited to, as high MRI Specific Absorption Rate (SAR) Radio Frequency (RF) power levels, MRI transmit coil that is near or extends over the implanted lead, implanted leads with small surface area electrodes, and short distance between lead electrodes and tissue that is sensitive to heat (Medtronic professional use manual). An MRI may permanently damage the neurostimulator, requiring to be removed or replaced. It also can reset the neurostimulator to power - on- reset values requiring reprogramming again. The Neurostimulation can move within the implanted pocket and align with the MRI field, resulting in discomfort or reopening of a recent implanted incision. In addition, the image details from MRI may be degraded, destroyed or blocked from view by the implanted Interstim system (Shellock, 2001) (Ordidge et al, 2000) (Luechinger et al, 2002) (Shellock et al, 1993). In contrast, many studies conducted on patients who underwent MRI examinations with implantable devices showed no clinical adverse effects (Luechinger et al, 2001) (Martin et al, 2004) (Gimbel et al 1996) (Buendia et al, 2011). Other concerns are associated with heating of the electrodes. Achenbach et al reported that temperature increase occurred at the tip of the pacing electrode (Achenbach et al, 1997). However, Rezai et al reported that temperature elevations at the distal end of deep brain stimulation electrode of 25.3°C occurred after 15 minutes of MRI and noted that the use of clinically relevant positioning techniques for the Neurostimulation system and MRI parameters used for imaging the brain generated little heating (Rezai et al, 2002). Furthermore, Martin et al reported in 2004 that they found no evidence that increase in SAR increase the likelihood that the pacemaker lead would heat and cause subsequent threshold changes (Martin et al, 2004). In the case of sacral nerve Neurostimulator, a variety of symptoms could develop if the lead is heated (e.g. urgency with pelvic pain, urinary frequency, incontinence for stool or urine and possible sexual dysfunction in both men and women). Furthermore, Sommer et al have showed a significant decrease in temperature in leads of the pacemaker when the center of the region to be imaged was located 30 cm or farther from the center of the lead loop (Sommer, 2000).

Nevertheless, Elkelini and Hassouna reported six patients with implanted sacral nerve stimulation who underwent eight MRI examinations at 1.0 Tesla conducted in areas outside the pelvis (Elkelini and Hassouna, 2006). They examined the IPGs before and after the MRI procedure. All patients had their parameters recorded; then the IPGs were put to "nominal" status. Patients were monitored continuously during and after the procedure. During the MRI session, no patient showed symptoms that required stopping the examination. There was no change in the perception of the stimulation after reprogramming of the implanted sacral nerve stimulator, according to patients' feedback. Devices were functioning properly, and no change in bladder functions was reported after MRI examinations.

8.2.1 Concluding message

A lot of controversial issues arise in MRI safety in Neurostimulation implanted patients. There are no clear safety guidelines established yet. However, if a patient needs MRI it

would be preferred to postpone the Neurostimulation implantation till patient is done with it. Patients should be instructed about the potential injury of MRI, and to stop the MRI if they felt any heat at the IPG site. Those who will undergo MRI should have their IPG explanted. If the patient is having the electrode left behind or part of the electrode (ghost effect) it can act as an antenna and result into the heat injury to the nerve, when so the MRI procedure should be stopped.

8.3 Neuromodulation and pregnancy

Sacral nerve stimulation has been increasingly used in females of child bearing age with various voiding dysfunctions. Nevertheless, electrical stimulation has been considered a contraindication in pregnant women. Medtronic product technical manual indicates that safety and effectiveness have not been established for pregnancy, unborn fetus, and delivery (Medtronic professional use manual,2011). Although no firm evidence exists, concerns pertaining to neuromodulation during pregnancy include negative effects on the fetus, conceiving mother, and the InterStim device itself as shown in table 4. Few animal studies have attempted to address this issue. In addition, data on human subjects is scarce and available in the form of case reports and small cases series.

8.3.1 Animal data

Wang and Hassouna were first to examine the effect of electrical stimulation on pregnant rats and fetuses (Wang and Hassouna, 1999). The authors divided 20 Sprague-Dawley pregnant rats into either electrical stimulation group (n = 10) or sham controls (n = 10). Rats in the stimulation group were stimulated 7 hours every day from Day 4 to Day 20 of gestation. Stimulation was done bilaterally at the level of S1, bipolar of 3 volts and frequency 20 Hz. The stimulation was adjusted to 80% of the value that induced a visible tail tremor. All pregnant rats were sacrificed and fetuses were examined at near term (Day 20 of gestation). The results showed that all pregnant rats were healthy during the gestation period and no abortions were observed. There was no significant difference between the stimulation group (2.27 +/- 0.51 gm.) and the sham group (2.13 +/- 0.51 gm.; p = 0.91) in terms of fetal body weight.

Fetus	Conceiving mother	InterStim device
<ul style="list-style-type: none"> • Teratogenicity • Fetal malformation 	<ul style="list-style-type: none"> • Abortion • Premature labour • Irritation and ulceration of the stretched skin over the battery (depending on the site of the battery) • Obstetric and anaesthetic care difficulties / complications • Pain at the lead site 	<ul style="list-style-type: none"> • Lead migration • Battery failure • Stretching the lead extender by the expanding abdomen

Table 4. Neuromodulation potential concerns during pregnancy (Wiseman et al, 2002) (Gaynor et al, 2006) (Nartowicz et al 1980),(Smimova et al, 1982) (Bernardini et al ,2010) (Saxena et al, 2009)

No significant difference was seen in the number of resorptions between both groups. All fetuses were alive at the time of caesarean section. No fetal malformation was observed in gross appearance, viscera and skeleton of all rats.

Karsdon et al. carried out an experiment to examine if uterine contractility during parturition can be inhibited with an electrical current (Karsdon et al, 2006). Electrical inhibition of in vitro spontaneously contracting preterm or term gestational rat myometrium tissue and in vivo spontaneously contracting uterus either directly in the rabbit and rat or transvaginally in the rat was studied. There was a decreased rat in vitro myometrial tension by 50%, decreased in vivo rabbit intrauterine pressure by 48%, decreased in vivo rat intrauterine pressure by 80%, and increased birth intervals (latency) by factors of 50 and 20. In addition, all electromyographic activity parameters were reduced significantly. The authors suggested that electrical inhibition may be a novel method to apply tocolysis in the human. These results, of course, argue against the concern premature labour induced by neuromodulation. In the same vein, Fujii et al. found that applying sacral surface electrical stimulation (ssES) treatment markedly decreased the peak power of uterine peristalses in comparison with that measured before ssES on the day of embryo transfer (ET) (Fujii et al, 2008). Since the uterus at the time of ET is sensitive to ssES, the investigators speculated that electrical neuromodulation may be an effective method to induce uterine relaxation for ET.

8.3.2 Human data

Published data on human subjects is limited. It involves case reports and series of pregnant women undergoing a form of neuromodulation either for bladder or non-bladder related reasons. Saxena and Eljamel described 1 case report of young woman who had Spinal cord stimulation (SCS) implanted for chronic pain and then became pregnant (Saxena et al, 2009). In this case, the epidural SCS was high in the thoracic region with the epidural lead placed at T6 level. The IPG was implanted in the anterior abdominal wall being secured in a subcutaneous pocket. The patient had normal course of pregnancy and fetus development while the stimulation was on. However, she developed new severe pain at the side of the abdomen at the junction between the epidural lead and the lead extender, which became intolerable in the 25th week of gestation. Eventually, the lead extender wire was surgically cut in the 28th week of gestation under local anaesthesia. The rest of the pregnancy was uneventful. The authors suggested that if the IPG was implanted in a location that was unlikely to be affected by the enlarging gravid abdomen or if the lead extender was long enough, then she would have managed to continue her pregnancy without this mechanical related pain. Bernardini et al. also reported two female patients with complex regional pain syndrome I who were well managed with SCS and then became pregnant (Bernardini et al, 2010). In both cases, the leads were placed through the T12/L1 inter-space and the IPG was placed in the buttock region. In the first patient, the device was kept deactivated prior to pregnancy and maintained off for the entire duration of the pregnancy. The second patient became pregnant on two separate occasions, with active SCS for a portion of the first trimester (8 weeks) of her first pregnancy before turning it off. She went on to deliver a healthy full-term neonate via caesarean section under general anaesthesia. During her second pregnancy, she deactivated the device 5 weeks post conception, however the patient elected to use SCS at 30 weeks' gestation because the pain became intolerable. There were no

obstetric or anaesthetic care complications related to the physical presence of the device. Rechargeable SCS systems were not affected when turned off during the duration of the pregnancy in both cases. In addition, intrauterine exposure to SCS was followed out for a minimum of two years and the developing fetuses were developmentally normal. Further reviewing of the literature also found two older case reports of SCS in the cervical spine to manage complex regional pain syndrome with concomitant usage during pregnancy to avoid the utilization of potentially teratogenic painkillers. In the first patient, there was a full term safe vaginal delivery despite the stimulator being switched on throughout pregnancy, labour, and delivery (Segal, 1999). In the second patient, she had SCS in the cervical spine 30 months before the pregnancy and had normal delivery under epidural anesthesia with no effects on the fetus or mother (Hanson and Goodman, 2006). One note regarding these patients is that the IPG was implanted in the subclavicular fossa. In 1988, Nanninga et al. reported the first case of the effect of sacral nerve stimulation for bladder control during pregnancy in a patient with myelodysplasia (Nanning et al, 1988). The patient activated the device to inhibit the bladder and deactivated it to allow voiding. Its use during pregnancy did not seem to have any adverse effect. In another report, a 30-year-old woman diagnosed with interstitial cystitis received a paddle lead (two lamitrode 44 paddles were placed in the sacrum such that they overlay at S2, S3, and S4 roots). The patient became pregnant but never used her stimulator during pregnancy (Feler et al, 2003). When Dasgupta et al. reviewed the long-term results of sacral nerve stimulation in the treatment of women with Fowler's syndrome over a 6-year period at one referral center, they found that there were 20 patients still voiding spontaneously at the time of review (with two having deactivated their stimulator because of pregnancy) (Dasgupta et al, 2004). There was no further elaboration regarding outcomes during or after pregnancy.

Sutherland et al. reviewed their 11 years experience with SNS for the management of refractory voiding dysfunction (Sutherland et al, 2007). Two patients in this cohort became pregnant after successful initiation of SNS therapy. One patient was treated for urgency and frequency 2 years prior to pregnancy. Pregnancy was carefully planned and neuromodulation was gradually decreased until it was deactivated. Nevertheless, her symptoms remained controlled during pregnancy. Following a successful vaginal delivery of a full-term baby, a temporary period of lead reactivation was needed due to postpartum idiopathic urinary retention and pain. Thereafter, the patient was free of symptoms, and remained so without neuromodulation. In the second patient, the same satisfactory efficacy was never obtained following postpartum device reactivation, and the device was eventually explanted. Lead migration during pregnancy and/or vaginal delivery was assumed to be the cause of decreased effectiveness, but this assumption was never confirmed radiographically.

Siegel presented an abstract regarding an internet-based survey of InterStim implanters pertaining to their views and approaches to neuromodulation in pregnant patients (Siegal, 2009). The survey showed that 66% of implanters have implanted a device in a woman younger than 30 years old. In patients that became pregnant, 2/3 decided to deactivate during the first trimester. Thirty-eight percent had patients with active devices during pregnancy, and 19% noted a change in efficacy after delivery. The survey concluded that there is likely little morbidity from having an active neuromodulation during pregnancy, however most implanters choose to deactivate on discovery of pregnancy. Perhaps the largest and most cited case series pertaining to SNS and pregnancy was published by

Wiseman et al. in 2002 (Wiseman et al, 2002). The authors obtained data on 6 women on SNS who then achieved pregnancy. The information was gathered using a standard questionnaire from 4 physicians known to treat patients on sacral neuromodulation. Data on indication for SNS, pregnancy course, the mode of delivery, neonatal health, the timing of implant deactivation and reactivation were all recorded. The results showed that in 1 patient, stimulation was switched off 2 weeks before conception and was never reactivated in the post partum period. In 5 patients the stimulator was deactivated between weeks 3 and 9 of gestation, after which 2 with a history of urinary retention had urinary tract infection, in which one of them also had IPG site pain and developed premature delivery at 34/40 weeks. Normal vaginal delivery was observed in 3 patients, including 1 in whom subsequent implant reactivation did not resolve voiding dysfunction. Elective caesarean section was carried out in the other 3 cases; in which 1 with urinary retention had to have the device switched back on at 19/40 weeks due to difficult catheterization without any complications during pregnancy. All neonates in the series were healthy. Based on their small cohort, the authors suggested few recommendations: 1) the device should be deactivated if a patient on neuromodulation becomes pregnant, 2) reactivation should be considered when deactivation leads to urinary related complications that threaten the pregnancy, 3) elective caesarean section should be discussed with the patient since it is possible for sacral lead damage or displacement to occur during vaginal delivery. Finally, Govaert et al. described a pilot study to assess the influence of SNS on endometrial waves of the non-pregnant uterus by using diagnostic ultrasound to study various aspects of uterine activity (Govaert et al, 2010). Six patients with an implanted SNS for faecal incontinence were included (3 premenopausal and 3 postmenopausal). Ultrasound recordings were performed with the stimulator turned off and in three stimulation frequencies. All premenopausal patients showed some form of endometrial activity when the stimulator was turned off. This activity was maintained when the stimulator was turned on in two patients, but disappeared in one patient. On the other hand, all postmenopausal patients had no endometrial activity with the stimulator turned off. Only one postmenopausal woman showed endometrial activity when the pacemaker was set at a frequency of 21Hz. The investigators concluded that in premenopausal women SNS seems to exhibit no effect or an inhibitory effect rather than an excitatory effect on uterine activity. Nevertheless, they were unable to recommend any guidelines for SNS usage during conception and pregnancy.

8.3.3 Concluding message

Not much is known about the effects of SNS on uterocervical function, pregnancy, and the developing fetus. Few studies on pregnant animals do not suggest any issues, but data on pregnant and non-pregnant women is scarce precluding the issuing of any firm recommendations or guidelines. Therefore, until such clear evidence exists, it is advised to turn off the stimulator during pregnancy or to wait with permanent implantation of the device until after family completion has been achieved.

9. Summary

Sacral neuromodulation offers minimally invasive treatment for voiding dysfunction. Despite many advances in the techniques of neuromodulation, the mechanism of

neuromodulation remains undefined. Many technical challenges raised with the widespread use of this new therapy. Special attention is given for pregnant patients. Precautions should be followed to avoid complications in both pregnancy & MRI procedures in sacral neuromodulation patients.

10. References

- Abrams P, Blaivas J, Fowler C, et al , The role of neuromodulation in the management of urinary incontinence ,BJU Int (2003) 91(4):355-9. erve
- Achenbach S, Moshage W, Diem B, et al ,Effects of magnetic resonance imaging on cardiac pacemakers and electrodes, Am Heart: (1997), 134:467-73
- Apostolidis A, Neuromodulation for intractable OAB, Neurorol Urodynami, (2011) Jun:30(5):766- 70.doi:10.1002/nau.21123
- P. Abrams, K. E. Andersson, L. Birder et al., *4th International consultation on incontinence. Recommendations of the International Scientific committee: evaluation and treatment of Urinary Incontinence, Pelvic Organ Prolapse and fecal Incontinence, Health Publication Ltd, Paris, France, 4th edition, 2009*
- Adonis Hijaz, Sandip Vasavada, *Complications and troubleshooting of sacral neuromodulation Therapy, Urol Clin N Am 32 (2005) 65-69*
- Alshaiji Tariq , Banakhar Mai, Hassouna Magdy, Pelvic electrical neuromodulation for the treatment of overactive bladder symptoms, Adv Urol, 2011:2011:757454.Epub 2011 May 14
- Al-Zahrani AA, ElZayat EA, Gajewski JB, Long -term outcome and surgical interventions after sacral neuromodulation implant for lower urinary tract symptoms:14 years experience at 1 center, J Urol 2011 Mar:185 (3):981-6 Epib 2011 Jan 19
- Boyce WH, Lathem JE, Hunt LD, research related to the development of an artificial electrical stimulator for the paralyzed human bladder: a review; J Urol 1964; 91:41-51
- Banakhar Mai, Gazuani Yahya, Elkelini Mohamed, Al-Shaiji Tariq, Hassouna Magdy, Effect of sacral neuromodulation on female sexual function , abstract AUA 2011 May 14-19.
- Bosch J, Groen J. Treatment of refractory urge urinary incontinence with sacral spinal nerve stimulation in multiple sclerosis patients. Lancet, 1996;348 (9029):7:717-9
- Bernardini D.J, Pratt S.D, Takoudes T.C.and Simopoulos T.T ,Spinal cord stimulation and the pregnant patient specific considerations for management: A case series and review of the literature. Neuromodulation,Technology at the neural Interface, 2010:13,270-274
- Bullock TL, Siegel SW (2010) Sacral neuromodulation for voiding dysfunction in statskin D (ed) atlas of bladder disease.S pringer, Philadelphia, pp 1- 12
- K. M. Borawski, R. T. Foster, G. D. Webster, and C. L. Amundsen, "Predicting implantation with a neuromodulator using two different test implantation techniques: a prospective randomized study in urge incontinent women ,Neurourology and Urodynamics,2007,Vol 26,no 1, pp 14 -18
- Bernardini, D. J., Pratt, S. D., Takoudes, T. C. and Simopoulos, T. T. Spinal Cord Stimulation and the Pregnant Patient-Specific Considerations for Management: A Case Series and Review of the Literature. Neuromodulation: Technology at the Neural Interface, (2010), 13: 270-274

- Buendia F, Cano O, Sanchez-Gomez JM, Igual B, Osca J, Sancho-Tello MJ, Olague J, Salvador A. Cardiac magnetic resonance imaging at 1.5 T in patients with cardiac rhythm devices. *Europace*, 2011, Apr 13(4):533-8. Epub 2011 Jan 11
- Caldwell KP. The electrical control of sphincter incompetence. *Lancet* 1963; 2:174-5
- Chaabane W, Guillotreau J, Castel-Lacanal E, Abu-Anz S, De Boissezon X, Malavaud B, Margue P, Sarramon JP, Rischmann P, Game X. Sacral Neuromodulation for treating neurogenic bladder dysfunction: clinical and urodynamic study. *Neuro Urol and Urodyna*, 2011, Apr; 30(4):547-50. doi:10.1002/nau.21009
- Comiter C. Sacral neuromodulation for the symptomatic treatment of refractory interstitial cystitis: a prospective study. *J Urol* 2003; 169:1369-73
- Dees JE. 1965. Contraction of the urinary bladder produced by electric stimulation: Preliminary report. *Invest Urol* 2:539-47
- Dasgupta R, Wiseman OJ, Kitchen N, Fowler CJ. Long term results of sacral neuromodulation for women with urinary retention. *BJU Int*. 2004 Aug; 94(3):335-7
- De Groat WC, Kruse MN, Vizzard MA, et al. Modification of urinary bladder function after neural injury. *Neurology*, 1997; vol 72:347-64
- De Groat WC, Theobald RJ. Reflex activation of sympathetic pathways to vesical smooth muscle and parasympathetic ganglia by electrical stimulation of vesical afferents. *J Physiol*, 1976; 259:223
- Elizabeth R., William and Steven W. Siegel. Procedural techniques in sacral nerve modulation. *Int Urogynecol J*, 2010, 21 suppl 2: s453-s460
- Elkelini M S and Hassouna M.M. "Safety of MRI at 1.5 tesla in patients with implanted sacral nerve neurostimulator. *European Urology*, 2006, vol 50, no 2, pp.311-316
- Everaert K., Kerckhaert W., Caluwaerts H. et al., "A prospective randomized trial comparing the 1-stage implantation of a pulse generator in patients with pelvic floor dysfunction selected for sacral nerve stimulation. *European Urology*, 2004, vol 45, no 5, pp.649-654
- Everaert K, Devulder J, De Muynck M, et al. The pain cycle implications for the diagnosis and treatment of pelvic pain syndromes. *Int Urogynecol J Pelvic Floor Dysfunct*, 2001; 12:9-14
- Everaert K, Plancke H, Lefevre F, Oosterlinck W. The urodynamic evaluation of neuromodulation in patients with voiding dysfunction. *Br J Urol*. 1997; 79(5):702-7
- Feler CA, Whitworth LA, Fernandez J. Sacral neuromodulation for chronic pain conditions. *Anesthesiol Clin North America*. 2003 Dec; 21(4):785-95.
- Fujii O, Murakami T, Murakawa H, Terada Y, Ogura T, Yaegashi N. Uterine relaxation by sacral surface electrical stimulation on the day of embryo transfer. *Fertil Steril*. 2008 Oct; 90(4):1240-2
- Gimbel JR, Johnson D, Levine PA, Wilkoff BL. Safe performance of magnetic resonance imaging of five patients with permanent cardiac pacemakers. *Pacing Clin Electrophysiol*, 1996; 19:913-9
- Giannuzzi J. Recherches physiologiques sur les nerfs moteurs de la vessie. *Journal de la physiologie de l'Homme et des animaux* 1863, 6: 22-9
- Gaynor-Krupnick DM, Dwyer NT, Rittenmeyer H, Kreder KJ. Evaluation and management of malfunctioning sacral neuromodulator. *Urology*. 2006 Feb; 67(2):246-9

- Govaert B, Melenhorst J, Link G, Hoogland H, van Gemert W, Baeten C. The effect of sacral nerve stimulation on uterine activity: a pilot study. *Colorectal Dis.* 2010 May;12(5):448-51.
- Ghazwani YQ, Elkelini MS, Hassouna MM, Efficacy of sacral neuromodulation in treatment of bladder pain syndrome: long-term follow-up, *Neurourol and Urodynam*,2011 may 6.dio 10.1002/nau.21037
- Heine JP, Schmidt RA, Tanagho EA, intraspinal sacral root stimulation for controlled micturition. *Invest Urol*, 1977;15:78-82
- Hijaz A., Vasavada S.P., Daneshgari F., Frinjari F., Goldman H. and Rackley R., complications and troubleshooting of two stage sacral neuromodulation therapy: a single institution experience" *Urology*,2006, vol 68, no.3, pp 533-537
- Humphreys M, Smith C, Smith J, et al. Sacral neuromodulation in children: preliminary results in 16 patients (Abstract) ,*J Urol*, 2004;171 (4)(suppl):56-57
- Hassouna M, Siegel S, Nyeholt A, et al. Sacral neuromodulation in the treatment of urgency-frequency symptoms: a multicenter study on efficacy and safety.*J Urol* 2000;163;1849-54
- Hilker R, Functional imaging of deep brain stimulation in idiopathic Parkinson's disease, *Nervenarzt*, 2010,Oct;81 (10):1204-7
- Hanson JL, Goodman EJ. Labor epidural placement in a woman with a cervical spinal cord stimulator. *Int J Obstet Anesth* 2006;15:246-249.
- Kohli N. and Patterson D., "InterStim therapy: a contemporary approach to overactive bladder" *Reviews in Obstetrics and Gynecology*, 2009,Vol 2, no 1 .pp.18-27
- Kessler T.M., Madersbacher H., and Kiss G., "Prolonged sacral neuromodulation testing using permanent leads: a more reliable patient selection method? *European Urology*,2005 ,Vol.47, no.5,pp.660-665
- Kessler T.M. , Buchser E., Meyer S. et al., "Sacral neuromodulation for refractory lower urinary tract dysfunction:results of a nationwide registry in switzerland, *European Urology*,2007,vol 51, no.5,pp.1357-1363
- Knupfer S., Hamann M., Naumann CM, Melchior D, Junemann KP, Therapy- refractory overactive bladder: Alternative treatment approaches, *Urologe A*, 2011, Jul:50 (7):806-809
- Kruse MN, Noto H, Roppolo JR, et al, Pontine control of the urinary bladder and external urethral sphincter in the rat,*Brain in Res*1990;532:182
- Kruse MN, de Groat WC., Spinal pathways mediate coordinated bladder/urethral sphincter activity during reflex micturition in normal and spinal cord injured neonatal rats, *Neurosci let*1993,152:141
- Karsdon J, Garfield RE, Shi SQ, Maner W, Saade G. Electrical inhibition of preterm birth: inhibition of uterine contractility in the rabbit and pup births in the rat. *Am J Obstet Gynecol.* 2005 Dec;193(6):1986-93. Erratum in: *Am J Obstet Gynecol.* 2006 Feb;194(2):595.
- Luechinger R, Duru F, Scheidegger MB, et al. Force and torque effects of a 1.5 telsa MRI scanner on cardiac pacemakers and ICDs. *Pacing Clin Electrophysiol* 2002;24:2

- Luechinger R, Duru F, Zeijlemaker VA, et al. Pacemaker reed switched behavior in 0.5, 1.5 and 3 Tesla magnetic resonance imaging units: are reed switched always closed in strong magnetic fields? *Pacing Clin Electrophysiol* 2002;25:10
- Lukban J, Whitmore K, Sant G. Current management of interstitial cystitis: *Urol Clin North Am*, 2002; 29:649-60
- Lombardi G, Mondaini N, Macchiarella A., Cilotti A, Del Popolo G: Clinical female sexual outcome after neuromodulation implanted for lower urinary tract symptom (LUTS), *J Sex Med*, 2008, Jun;5 (6):1411-7.Epub 2008 Mar 26
- Lombardi G, Mondaini N, Giubilei G, Macchiarella A, Lecconi F, Del popolo G, Sacral neuromodulation for lower urinary tract dysfunction and impact on erectile function, *J Sex Med*, 2008 Sep;5(9):2135-40.Epub 2008 Jul 15
- Lombardi G, Del Popolo G, Clinical outcome of sacral neuromodulation in incomplete spinal cord injured patients suffering from neurogenic lower urinary tract symptoms, *Spinal cord*,2009.Jun;47(6):486-91.Epub 2009 Feb 24
- Madersbacher H .Konservative Therapie der neurogenen Blasendysfunktion, *Urologe A* 1999.:38:24-9
- Magis D, Schoenen J., treatment of migraine: update on new therapies, *Curr Opin Neurol*, 2011 Jun;24 (3):203-10
- Martin ET, Coman JA, Shellock FG, et al. Magnetic resonance imaging and cardiac pacemaker safety at 1.5 telsa, *J Am Coll Cardiol* 2004;43:7
- Masin A, Ratto C, Ganio E, et al. Effect of sacral nerve modulation in chronic constipation. *Ital J Public Health* 2005;2:30
- Melenhorst J, Koch SM, Uludag O, van Gemert WG, Baeten CG ,Sacral neuromodulation in patients with faecal incontinence: results of the first 100 permanent implantations. *Colorectal (2007) Dis* 9:725-730
- Nashold BS JR, Friedman H, Boyarsky S.: electrical activation of micturition by spinal cord stimulation *J Surg Res*,1971; 11:144-7
- Nartowicz, E., Burduk, P., Skowron, A., et al.: Pacemaker implantation in a pregnant woman. *Pol. Tyg. Lek.* 1980. 35: 541,
- Nanninga JB, Einhorn C, Deppe F. The effect of sacral nerve stimulation for bladder control during pregnancy: a case report. *J Urol.* 1988 Jan;139(1):121-2.
- Ordidge RJ, Shellock FG, Kanal E. A Y2000 update of current safety issues related to MRI. *J Magn Reson Imaging* 2000;12:1
- Pauls RN, Marinkovic SP ,Silva WA, Rooney CM, Kleeman SD, Karram MM, Effects of sacral neuromodulation on female sexual function *Int Urogynecol J Pelvic Floor Dysfunction* 2007 Apr,18 (4):391-5.Epub 2006 Jul 26
- Pascual I, Gonzalez, Gomez CC, Ortega R, Jimenez Toscano M, Marijuan JL, Lomas Espadas M, Fernandez Cebrian JM, Garcia Olmo, Pascual Montero JA, Sacral nerve stimulation for fecal incontinence, *Rev Esp Enferm Dig*, 2011 Jul, 103(7):355-359
- Product technical manual. <http://professional.medtronic.com/therapies/sacral-nerve-stimulation-interstim-therapy/indications-safety-and-warnings/index.htm>
- Peters K.M , Carey J.M., and KonstandtD.B. , "Sacral neuromodulation for the treatment of refractory interstitial cystitis:outcomes based on technique" *international Urogynecology Journal andpelvic Floor Dysfunction*,2003, vol.14, no.4, pp.223-228

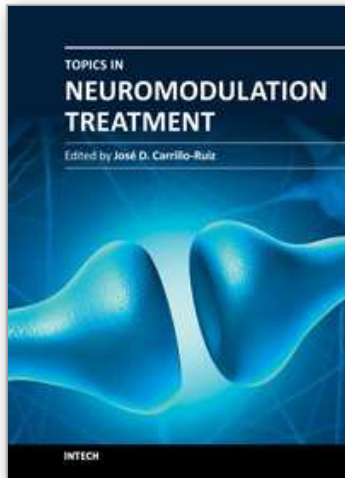
- Peters K. Sacral neuromodulation decreases narcotic requirement in refractory interstitial cystitis, *BJU Int*, 2004;93 (6):777-9
- J. Pannek, U. Grigoleit, and A. Hinkel, "Bacterial contamination of test stimulation leads during percutaneous nerve stimulation' *Urology*, 2005, Vol,65, no6, pp.1096-1098
- Rezai AR, Finelli D, Nyenhuis JA, et al. Neurostimulation systems for deep brain stimulation: in vitro evaluation of magnetic resonance imaging-related heating at 1.5 Tesla, *J Magn Reson Imaging* 2002;15:241-5-
- Roth TM, Sacral neuromodulation and cardiac pacemakers, *Int Urogynecol J Pelvic Floor Dysfunct*, 2010, Aug;21 (8):1035-7. Epub 2010 Jan 30
- Schmidt RA, Bruschini H, Tanagho EA, Urinary bladder and sphincter responses to stimulation of dorsal and ventral sacral roots. *Invest Urol*, 1979,,16:300-4
- Saxena, A. and Eljamel, M. S. ,Spinal Cord Stimulation in the First Two Trimesters of Pregnancy: Case Report and Review of the Literature. *Neuromodulation: Technology at the Neural Interface*, (2009), 12: 281-283.
- Scheepens W.A., Weil E.H.J., Van Koevinge G.A. et al, Buttock placement of the implantable pulse generator: a new implantation technique for sacral neuromodulation a multicenter study, *European Urology*, 2001, vol.40,no.4, pp.434-438
- Schmidt R , Application of Neurostimulation in Urology, *Neurourol Urodyn*1988 :7:585-92
- Schmidit RA, Treatment of pelvic pain with neuroprosthesis, *J Urol Abstract* .1988,458:139:277A
- Shaker HS, Hassouna M, sacral root neuromodulation in idiopathic nonobstructive chronic urinary retention *J Urol* 1998,:159:1476-8
- Segal R. Spinal cord stimulation, conception, pregnancy, and labor: case study in a complex regional pain syndrome patient. *Neuromodulation* 1999; 1: 41-45.
- Signorello D., Seitz CC, Berner L, Trenti E, Martini T, Galantini A, Lusuardi L, Lodde M., Pycha A, Impact of sacral neuromodulation on female sexual function and his correlation with clinical outcome and quality of life indexes: a monocentric experience, *J Sex Med*, 2011, apr 8(4) :1147-55.dio:10.1111/j.1743-6109.2010.02189.x.Epub 2011 Jan 26
- Shellock FG, Kanal E. SMRI Report: policies, guidelines and recommendations for MR imaging safety and patients management *J Magn Reson Imaging* 1992;2:247-8
- Shellock FG, Morisoli S, Kanal E. MR procedures and Biomedical implants material and devices 1993: update. *Radiology* 1993: 189:587-99
- Shellock FG. Pocket guide to metallic implants and MR procedures: update 2001. New York: Lippincott-Raven Healthcare.
- Siegel SW, Catanzaro F, Dijkema H, et al. Longterm results of multicenter study on sacral nerve stimulation for treatment of urinary urge incontinence, urgency- frequency and retention. *Urology*, 2000;4(56 Suppl,1):87-91
- Siegel S, Paszkiewicz E, Kirkpatrick C, et al. Sacral nerve stimulation in patients with chronic intractable pelvic pain. *J Urol* 2001;166(5):1742-5
- Steven Siegal, SUFU 2009 - Use and Management of InterStim® Sacral Neuromodulation in Pregnant Patients: A Survey of Active Implanters - Session Highlights. *Urodynamics & Female Urology (SUFU) 2009 Winter Meeting, February 25 - 28, 2009 - Las Vegas, NV, USA*. SUFU 2009 - Use and Management of InterStim®

- Sacral Neuromodulation in Pregnant Patients: A Survey of Active Implanters - Session Highlights.
- Sutherland SE, Lavers A, Carlson A, Holtz C, Kesha J, Siegel SW. Sacral nerve stimulation for voiding dysfunction: One institution's 11-year experience. *Neurourol Urodyn*. 2007;26(1):19-28; discussion 36.
- Scheepens WA, de Bie RA, Weil E, et al.: Unilateral versus bilateral sacral neuromodulation in patients with chronic voiding dysfunction, *J Urol* 2002;168:2046-2050
- Smimova, L. M., Glukhova, P. A., Pavlova, S. S., et al.: Pregnancy and labour in patients with electric cardiac pacemaker. *Akush. Ginekol. (Mosk)* 1982. 5: 31,
- Saxena, A. and Eljamel, M. S. , Spinal Cord Stimulation in the First Two Trimesters of Pregnancy: Case Report and Review of the Literature. *Neuromodulation: Technology at the Neural Interface*, 2009, 12: 281-283.
- Thon WF, Baskin LS, Jonas U, et al, Surgical principles of sacral foramen electrode implantation, *World J Urol*,1991;9:133
- Tanagho EA, Schmidit RA, Bladder pacemaker:scientific basis and clinical future. *Urology*1982;20:614-9
- Tanagho EA, Neural stimulation for bladder control, *semin Neurol*1988 :8:170-3
- Tanagho EA, Electrical stimulation.*J Am Geriatr Soc*, 1990, 38:352-5
- Tanagho EA,Neuromodulation in the management of voiding dysfunction in children,*J Urol*1992 :14802 pt2):655-7
- Torsten Sommer, Vahlhaus C, Lauck G, et al. MR imaging and cardiac pacemaker: in vitro evaluation and in vivo studies in 51 patients at 0.5 T1 *Radiology*, 2000:215;869-79
- Vadusek DB, Light JK, Liddy JM, Detrusor inhibition induced by stimulation of pudendal nerve afferents, *Neurourol urodyn*1986,:5:381
- Vastenholt JM, Snoek GJ, Buschman HP, et al.A 7 year follow- up of sacral anterior root stimulation for bladder control in patients with spinal cord injury: Quality of life and users experiences, *Spinal cord* @003:41;397-402
- Van Kleef M, Staats P, Mekhail N, Huygen F, Chronic refractory Angina Pectoris, *Pain Pract*, 2011, Mar 16 . doi: 10.1111/j.1533-2500.2010.00444.x.
- Van Wunnik BP, Baeten CG, Southwell BR, Neuromodulation for constipation: sacral and transcutaneous stimulation, *Best pract res Clin Gastroenterol*, 2011 Feb;25(1):181-91.
- Wang Y, Hassouna MM. Electrical stimulation has no adverse effect on pregnant rats and fetuses. *J Urol*. 1999 Nov;162(5):1785-7
- Wiseman OJ, v d Hombergh U, Koldewijn EL, Spinelli M, Siegel SW, Fowler CJ. Sacral neuromodulation and pregnancy. *J Urol*. 2002 Jan;167(1):165-8.).
- Wagg A., Majumdar A., Toozs-Hobson P., Patel A. K. , Chapple C. R., and Hill S., Current and future trends in the management of overactive bladder, *International urogynecology Journal and pelvic Floor Dysfunction* 2007, vol.18,.no.1,pp.81-94
- Wallace PA, Lane FL, Noblett KL, Sacral Nerve veuromodulation in patients with cardiac pacemakers, *Am J Obstet Gynecol*, 2007, Jul,197 (1):94.e 1-3
- Wendy W.Leg, Michael B. Chancellor, How Sacral Nerve stimulation Works,*Urol Clin N Am*, 2005, 32:11-18

Wosnitzer MS, Walsh R, Rutman MP, The use of sacral neuromodulation for the treatment of non-obstructive urinary retention secondary to Guillain- Barre syndrome, Int Urogynecol J Pelvic floor Dysfunction, 2009, Sep:20(9);1145-7.Epub2009 Mar 11.

IntechOpen

IntechOpen



Topics in Neuromodulation Treatment

Edited by Dr. José Carrillo-Ruiz

ISBN 978-953-51-0395-0

Hard cover, 190 pages

Publisher InTech

Published online 23, March, 2012

Published in print edition March, 2012

"Topics in Neuromodulation Treatment" is a book that invites to the reader to make an update in this important and well-defined area involved in the Neuroscience world. The book pays attention in some aspects of the electrical therapy and also in the drug delivery management of several neurological illnesses including the classic ones like epilepsy, Parkinson's disease, pain, and other indications more recently incorporated to this important tool like bladder incontinency, heart ischemia and stroke. The manuscript is dedicated not only to the expert, but also to the scientist that begins in this amazing field. The authors are physicians of different specialties and they guarantee the clinical expertise to provide to the reader the best guide to treat the patient.

How to reference

In order to correctly reference this scholarly work, feel free to copy and paste the following:

Mai Banakhar, Tariq Al-Shaiji and Magdy Hassouna (2012). Challenges in Sacral Neuromodulation, Topics in Neuromodulation Treatment, Dr. José Carrillo-Ruiz (Ed.), ISBN: 978-953-51-0395-0, InTech, Available from: <http://www.intechopen.com/books/topics-in-neuromodulation-treatment/challenges-in-sacral-neuromodulation>

INTECH
open science | open minds

InTech Europe

University Campus STeP Ri
Slavka Krautzeka 83/A
51000 Rijeka, Croatia
Phone: +385 (51) 770 447
Fax: +385 (51) 686 166
www.intechopen.com

InTech China

Unit 405, Office Block, Hotel Equatorial Shanghai
No.65, Yan An Road (West), Shanghai, 200040, China
中国上海市延安西路65号上海国际贵都大饭店办公楼405单元
Phone: +86-21-62489820
Fax: +86-21-62489821

© 2012 The Author(s). Licensee IntechOpen. This is an open access article distributed under the terms of the [Creative Commons Attribution 3.0 License](#), which permits unrestricted use, distribution, and reproduction in any medium, provided the original work is properly cited.

IntechOpen

IntechOpen