

# We are IntechOpen, the world's leading publisher of Open Access books Built by scientists, for scientists

**4,800**

Open access books available

**122,000**

International authors and editors

**135M**

Downloads

Our authors are among the

**154**

Countries delivered to

**TOP 1%**

most cited scientists

**12.2%**

Contributors from top 500 universities



**WEB OF SCIENCE™**

Selection of our books indexed in the Book Citation Index  
in Web of Science™ Core Collection (BKCI)

Interested in publishing with us?  
Contact [book.department@intechopen.com](mailto:book.department@intechopen.com)

Numbers displayed above are based on latest data collected.

For more information visit [www.intechopen.com](http://www.intechopen.com)



# Reconstruction of Post-Traumatic Bone Defect of the Upper-Limb with Vascularized Fibular Graft

R. Adani<sup>1</sup>, L. Tarallo<sup>2</sup> and R. Mugnai<sup>2</sup>

<sup>1</sup>Hand and Microsurgery Department, Policlinico GB Rossi, Azienda Ospedaliera Universitaria Verona, Verona,

<sup>2</sup>Department of Orthopaedic Surgery, University of Modena and Reggio Emilia, Policlinico di Modena, Modena, Italy

## 1. Introduction

Fracture non-union or delayed union frequently occur after high-energy traumas associated to significant bony tissue loss, in open fractures with infections, and after an inappropriate use of internal fixation.<sup>1,2,3,4,5,6,7</sup> Obesity, smoking, abuse of alcohol or drugs, osteoporosis and immunodepression are additional factors that prevent bone healing.<sup>1,4,6</sup> Based on characteristic of the bone ends, non-unions may be atrophic, oligotrophic, and hypertrophic.<sup>8,9,10</sup> Atrophic non-unions have little or no callus formation and are often characterized by bone resorption with normal healing, being limited by inadequate biological response at the fracture site. In turn, in oligotrophic and hypertrophic non-unions the blood supplies are adequate and abundant calluses are seen. In this case, the main reason for the non-union is an insufficient mechanical stability. Generally, the majority of non-unions are atrophic.<sup>11,12,13</sup>

A number of surgical options for the treatment of upper limb bony non-union, including intramedullary nailing,<sup>2,14,15</sup> distraction with an Ilizarov fixator,<sup>4,16,17,18,19</sup> and plate compression with or without conventional bone grafting,<sup>6,20</sup> have been described over the years. The use of these therapeutic options achieves bony union in 82% to 95% of patients.<sup>4</sup> Causes of unsuccessful outcomes can be the result of inadequate techniques of osteosynthesis with unsatisfactory stabilization or with persistence of infection, but failure mostly occur in bony defects greater than 6 cm.<sup>21,22</sup> Bone grafts and bone graft substitutes have a number of inherent properties that allow them to initiate, stimulate, and facilitate bony healing.<sup>23,24</sup> (Table 1) Osteoconduction refers to the process by which the graft provides a scaffold for the ordered 3-D ingrowth of capillaries, perivascular tissue, and osteoprogenitor cells. Osteoinduction refers to the recruitment of osteoprogenitor cells from surrounding tissue. Osteogenesis refers to the formation of new bone from either the host or graft tissue. In addition to these three properties, it is important to consider the mechanical strength and vascularity of the bone graft material. Autogenous and allogenic cortical and cancellous bone grafts are all, to varying degrees, osteoconductive, osteoinductive, and

osteogenic. For these reasons, non-vascularized bone grafts are effective in facilitating bony healing. When properly utilized, non-vascularized bone grafts may be incorporated into the adjacent host bone through the process of “creeping substitution”. The bone graft material, through the invasion of capillaries, perivascular tissue, and inflammatory cells, is gradually revascularized and ultimately resorbed, allowing for the formation of new living bone which is incorporated and remodeled into the host skeleton. However, this process takes time, during which the structural integrity and mechanical strength of the bone graft and host bone may be impaired.<sup>23</sup> Autograft is the most commonly used type of bone graft.<sup>25</sup> It can come from a variety of areas, including the iliac crest, distal femur, proximal tibia, fibula, distal radius, and olecranon. Nonvascularized iliac crest bone grafts are effective in the management of defects smaller than 5 to 6 cm in length in the presence of well-perfused soft tissue with no active infection.<sup>26</sup> The use of nonvascularized fibular grafts has provided interesting results;<sup>8,27</sup> however, this technique requires a prolonged immobilization and a consolidation time ranging between 6-11 months.<sup>28</sup> In addition, bone allografts do not yield satisfactory results if the recipient site is not well vascularized or if infection is present.<sup>29</sup> Vascularized bone grafts, by definition, are placed with their vascularity intact, and thus are immediately viable. As a result, vascularized bone grafts obviate the need for incorporation by creeping substitution and may instead incorporate into the adjacent host bone via primary (or secondary) bone healing. This process allows for the mechanical strength and structural integrity of the vascularized graft to be preserved, which may provide greater strength and more immediate stability to the recipient site. Vascularized bone transfer are more efficient than conventional corticocancellous interposition grafting for the management of massive bone loss (>6 cm).<sup>30,31</sup> Vascularized bone grafting has several advantages in the treatment of non-union,<sup>32</sup> in particular the living bone graft can provide osteogenic cells, improve vascularity at the bone junction, eliminate infection and enhance the intrinsic stability at the site of non-union, thereby permitting simpler and more rapid fracture healing.<sup>33</sup>

| Type of Graft        | Osteoconduction | Osteoinduction | Osteogenesis | Mechanical strength | Vascularity |
|----------------------|-----------------|----------------|--------------|---------------------|-------------|
| Bone Marrow          | +/-             | +              | ++           | -                   | -           |
| Cancellous autograft | ++              | +              | ++           | +                   | -           |
| Cortical autograft   | +               | +/-            | +            | ++                  | -           |
| Vascularized         | ++              | +              | ++           | ++                  | ++          |

Table 1. Properties of bone grafts

## 2. Vascularized fibular graft

Almost 30 years have elapsed since the vascularized fibula graft was first mentioned in the literature,<sup>34</sup> and this technique is now commonly used in clinical practice. Biomechanically, the fibula bears only 15 percent of the axial load across the ankle, allowing for its use as an

autogenous bone graft with minimal biomechanical consequences on the weight-bearing status of the lower limb.<sup>35</sup> As also the distal fibula plays an important role in conferring rotational stability and restraint against lateral translation of the talus, efforts are made to preserve the distal fibula during graft harvest to avoid subsequent ankle deformity or instability.<sup>36,37,38</sup> The vascular supply to the fibula has been well established.<sup>34,38</sup> The endosteal blood supply to the fibula is provided by a nutrient artery which typically enters the posterior fibular cortex at the junction of the proximal one-third and distal two-thirds. This nutrient artery is a branch of the peroneal artery, which runs along the posterior aspect of the fibular diaphysis. The peroneal artery arises from the posterior tibial artery approximately 2 to 3 cm below the lower border of the popliteus muscle, it passes towards the fibula and descends along its medial border, between tibialis posterior and flexor hallucis longus and divides into calcaneal branches which ramify on the lateral and posterior surfaces of the calcaneum. These vessels anastomose with the anterior and posterior tibial. The peroneal artery supplies the nutrient vessels to the fibula which enter on the posteromedial surface of the bone. At approximately 2 to 5 cm intervals throughout its length, septocutaneous vessels arise, which pass laterally, sometimes through the edge of soleus, onto the posterior surface of the lateral intermuscular septum.<sup>39</sup> The fibula free flap based on the peroneal artery and its venae comitantes lies medial to the fibula and posterior to the interosseous membrane. Based upon this understanding of the vascularity of the fibula, techniques of vascularized fibula graft harvest, which preserve both the nutrient artery and the rich periosteal blood supply, have been developed. The use of vascularized fibular graft in reconstructive surgery of the upper extremity was introduced at the end of the 1970s,<sup>40</sup> and for a long time its application in posttraumatic reconstruction of the forearm was limited to a small number of isolated clinical cases.<sup>31,41,42,43,44,45</sup> In 1984, Dell and Sheppard described its use in the treatment of infected pseudoarthrosis of the forearm, and reported on 4 cases.<sup>46</sup> It was not until 1991 that a significant series was reported in the literature;<sup>47</sup> some other papers were recently published on this subject.<sup>29,48,49,50,51,52,53</sup> With advancements in microsurgical techniques, vascularized bone grafts have become well-established technical resources capable of providing solutions to difficult reconstructive challenges.<sup>32</sup> The use of free fibula flap in the treatment of upper limb diaphyseal non-unions has also gained increased popularity over the last few decades. The reason for this are (1) increased vascularity at the fracture site is essential in promoting a faster bone healing and fighting infection and (2) vascularized bone provides higher biomechanical strength than nonvascularized bone.<sup>29</sup> Vascularized fibular grafting also has a number of additional theoretical advantages over conventional, non-vascularized bone grafting techniques. Given the length of fibular diaphysis that may be harvested, free fibular grafts are well suited for the reconstruction of segmental defects of the long bones, providing both mechanical strength and biological stimulus for healing. Furthermore, based upon the fasciocutaneous arterial branches of the peroneal artery, skin, fascia, and muscle may be harvested concomitantly with the fibula to allow for more complex soft tissue reconstruction. Moreover, given the ability to transfer the proximal fibular epiphysis with the diaphysis during free vascularized fibular grafting, there is potential for preserving continued skeletal growth of the fibular graft.<sup>54</sup> Finally, the fibula is a long and straight tubular bone, which is not difficult to harvest, while donor site morbidity is minimal up to a graft length of 20 cm.<sup>55,56</sup> The anatomy is predictable, and its size and shape allows a satisfactory fixation of femoral, tibial, and humeral defects.<sup>55,56</sup> Free fibula flap in long bones reconstruction is an useful and versatile procedure for defects greater than 6-8 cm.<sup>29,32,57,58</sup> It

has been demonstrated that, when appropriate blood perfusion is restored to the flap, the proximal and distal fracture sites have the same healing potential of a bifocal fracture with no bone tissue loss, and with no vascular impairment to the central segment. Despite its many theoretical advantages and applications, however, free vascularized fibula grafting is technically challenging and confers its own set of inherent risks and potential complications. Sound microsurgical technique is essential in performing the required arterial and venous anastomoses and ensuring long-term graft viability. Furthermore, donor site morbidity has been well documented, and up to 10% of patients may subsequently develop ankle pain, instability, and/or progressive valgus deformity if fibula harvest is not performed with a proper technique.<sup>59,60</sup> Given these considerations, free vascularized fibula grafting should be employed in specific clinical situations. Presently, the indications for free vascularized fibula grafting fall into two categories.<sup>61</sup> (Table 2) The former is for segmental bony defects greater than 6 to 8 cm, such as those seen in post-traumatic or post-infectious bone loss and tumor resection. The latter is for smaller bony defects in which a biological failure of bony healing, such as those seen in recalcitrant fracture non unions, congenital pseudarthroses, and osteonecrosis, has occurred. Accurate patient selection with a careful clinical evaluation is essential in order to reduce the complication rate. Chronic infections, diabetes, immunosuppression, alcohol, tobacco, drug abuse and obesity are relative contraindications to the procedure. Furthermore, the local wound conditions, the trauma etiology and the outcome of previous surgeries should also be carefully considered.<sup>55</sup> The fibula may be used as graft material in the cervical spine, clavicle, humerus, radius, ulna, lumbar spine, femur (including knee arthrodesis), tibia, and ankle. In the shoulder, the free fibula graft may be used to augment arthrodesis or to treat the patient with prosthesis failure and massive bone loss.<sup>62</sup> In the humerus, fibula graft can be used to manage non-union, infection, and epiphyseal fracture. Fibula graft can be used to manage radius and ulna defects or in creating a one-bone forearm. The overall success rate of the procedure, estimated from the literature, varies from 76% to 100%, with a healing time ranging from 3.7 to 8.9 months.<sup>63</sup> In a large Mayo cohort, the primary and secondary union rates in vascularized fibular grafts performed for non-osteomyelitis indications were 69% and 84%, respectively, but in series of defects with infections, the union rates fall to 49% and 77%.<sup>64</sup> From a meta-analysis of 13 different series involving 317 reconstructions for atrophic non-unions, the mean time for fracture consolidation appeared to be 5.5 months in the 87% of patients.<sup>22</sup> In cases of severely injured limb complicated by infection and large bony defects, the success rate of reconstruction was lowered to 71.5%.<sup>65</sup> In a research we performed on forearm non-union with a bony defect ranging from 6 cm to 13 cm, treated with vascularized fibular graft, the complete healing was obtained in 11/12 cases, with a mean period for radiographic bony union of 4.8 months.<sup>52</sup> A review of the available literature shows only a few reports of vascularized bone grafting for non-union of the humeral shaft. Jupiter reported 4 patients, and 3 of them went to primary bony union within 4 months.<sup>1</sup> Muramatsu et al. reported 9 patients with recalcitrant non-union of the humerus reconstructed by a vascularized fibular graft, and the mean time for union was 6 months (range, 4-10 months).<sup>4</sup> The results of our previous research did not differ very much from these reports: our mean healing time was 6 months (range, 3-13 months) in a series of 13 cases with bony defect ranging from 6 to 16 cm.<sup>53</sup> Among different possible complications, stress fractures of the graft represent a possible event. Vascularized bone grafts have decreased the incidence of stress fractures with respect to conventional bone grafts;<sup>64</sup> their incidence is reported in 15% to 20% of cases.<sup>2,52,58,65,66</sup> Most fracture occurs within the first year of surgery, when the bone has

insufficient time to hypertrophy.<sup>64,67</sup> Therefore, de Boer et al. recommend that a vascularized graft should be protected against stress fracture during the first year, allowing for a gradual increase in mechanical loading that enhances remodeling and hypertrophy.<sup>68</sup> Other complications associated with the procedure are secondary infection, delayed union, recurrent non-union, transient palsy of the radial nerve, and vascular impairment to the pedicle flap. These complications occur in 7% to 10% of cases.<sup>65</sup> Complications to the donor site are rare, however they may include peroneal palsy, contracture of the long flexor tendon of the great toe, compartment syndrome in the lower limb, valgus deformity of the ankle, or even a spontaneous fracture of the ipsilateral tibia.<sup>69,70</sup>

|   |                           |
|---|---------------------------|
| <b>Segmental bone defects greater than 6 - 8 cm</b> | Traumatic bone loss       |
|   | Tumor resection           |
|   | Osteonecrosis             |
|   | Osteomyelitis             |
| <b>Biological failure of bony healing</b>           | Persistent non-union      |
|   | Infected non-union        |
|   | Congenital pseudarthrosis |

Table 2. Indications for free vascularized fibula grafting

### 3. Surgical technique

A brief description of the technique of free vascularized fibula graft harvest is provided to give the reader some insight on related surgical considerations and applications. Preoperative planning for vascularized fibula transfer involves coordination of recipient vessels, bone length, and internal fixation. Recipient vessels must be large enough in diameter to accept the peroneal artery, which can be quite large in adults.<sup>71</sup> One artery and two veins are preferred as recipient vessels. For vascular access, the brachial artery or distal branching into the radial artery can be used for inflow, particularly around the humerus. An existing end artery from previous trauma resection in the upper extremity should be used as an end-to-end anastomosis. When the fibula is to be harvested without accompanying skin or soft-tissue, a longitudinal incision is made over the lateral aspect of the fibula. Superficial dissection is performed in the interval between the peroneus longus muscle anteriorly and the soleus posteriorly. The diaphysis of the fibula is then circumferentially exposed with care being made to preserve the periosteum and periosteal blood supply; this results in the typical “marbled” appearance to the fibular graft. Circumferential dissection of the fibula is continued anteriorly and posteriorly, reflecting the peroneal and flexor hallucis longus muscles, respectively. The peroneal artery and vein are identified along the posterior aspect of the fibula and carefully protected as the intermuscular septum is divided along the length of the proposed graft. The fibula is osteotomized proximally and distally, with preservation of the peroneal vessels. Once the recipient site is prepared, the vascular pedicle may be divided and the fibula transferred to the desired location. If an osteomyocutaneous flap is required, dissection starts with a linear lateral incision over the fibula paralleling to its border. The skin paddle is centered over the distal one third of the flap as most cutaneous perforators will arise in the distal half of the lower leg. The skin paddle is incised and elevated in a subfascial plane over the peroneus longus and brevis muscles anteriorly and

the soleus and gastrocnemius muscles posteriorly. Dissection is continued until the posterior intermuscular septum is reached. At this point, septocutaneous perforators passing into the skin paddle are identified. Only one perforator is required, but as many as possible of them are included in the dissection. If no such perforators are identified, another reconstructive modality is chosen for the cutaneous portion of the defect, and a bone only fibula flap is harvested. The peroneus longus and brevis muscles are freed from the anterolateral part of the fibula allowing the access to the interosseous membrane, which is next released. Proximal and distal osteotomies are made in the fibula. The pedicle is then traced proximally to its origin. Once flap harvest has been completed, closure of the leg is accomplished by careful muscle reapproximation and split thickness skin graft application to the donor site. After the stabilization of the fibula to the recipient site, typically done with rigid internal screw fixation, microvascular anastomoses are performed, reconstituting both arterial inflow and venous outflow to the fibular graft. In the figures are briefly reported two cases in which we used the vascularized fibular graft for the treatment of respectively distal humerus (Case 1) and radial diaphysis (Case 2) non-unions.

#### Case 1. Non-union of the distal humerus

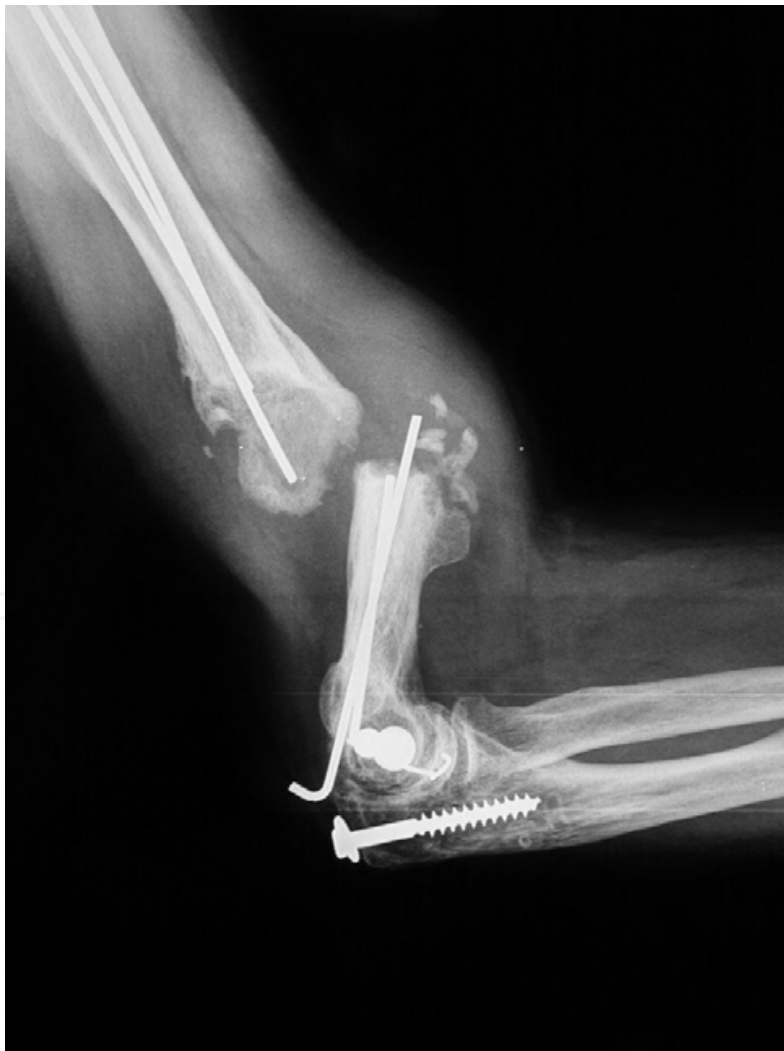

Fig. 1A. Non-union of the distal humerus treated with 2 K.wires

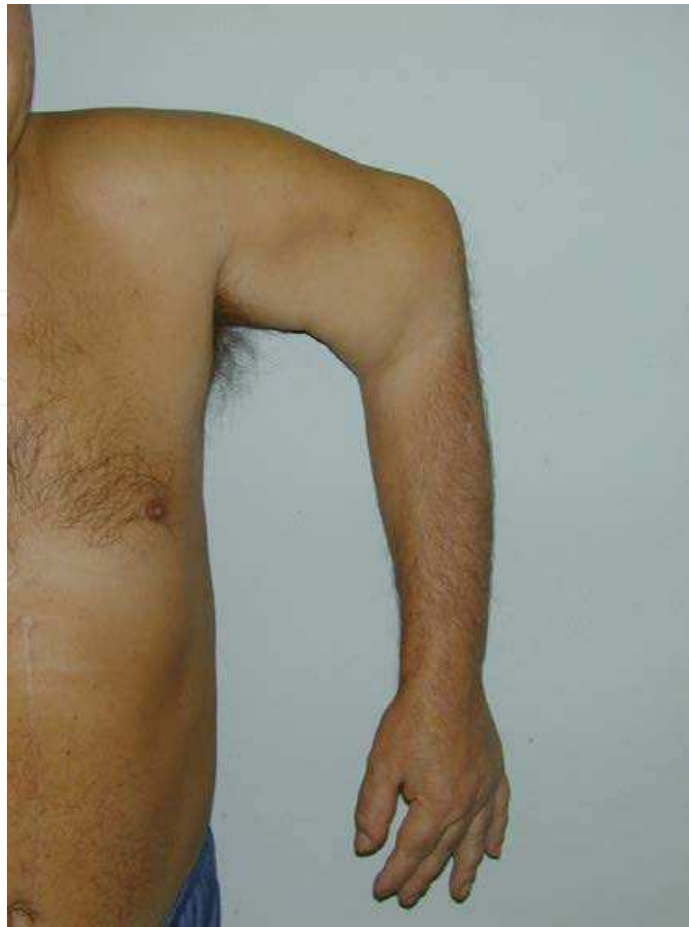

Fig. 1B. Clinic view with a new joint (non-union) upper the elbow

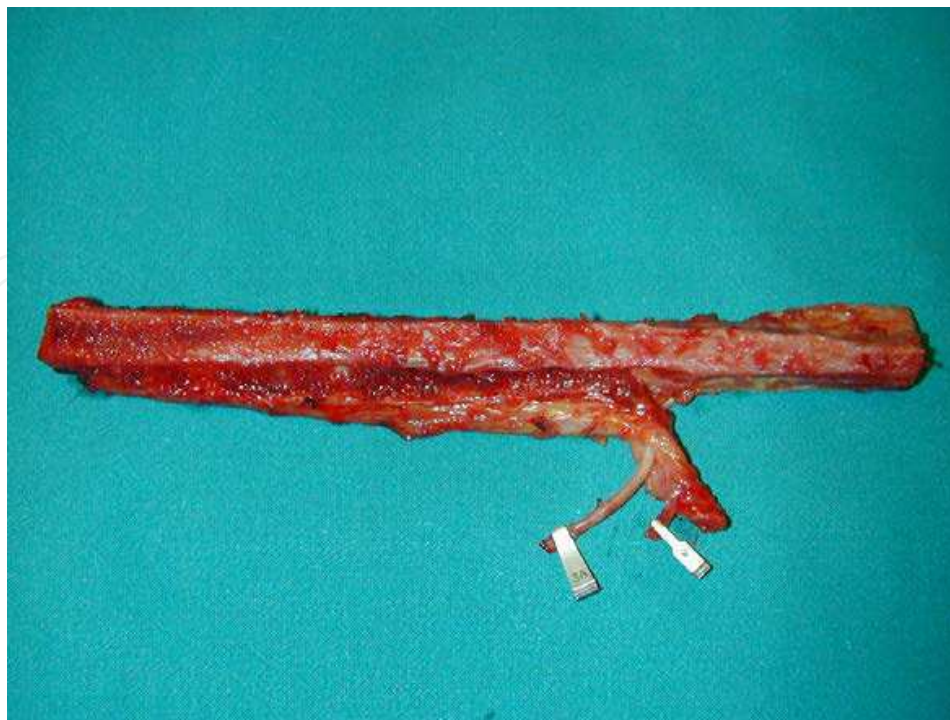


Fig. 1C. Free vascularized fibular bone graft with the pedicle of the peroneal vessels



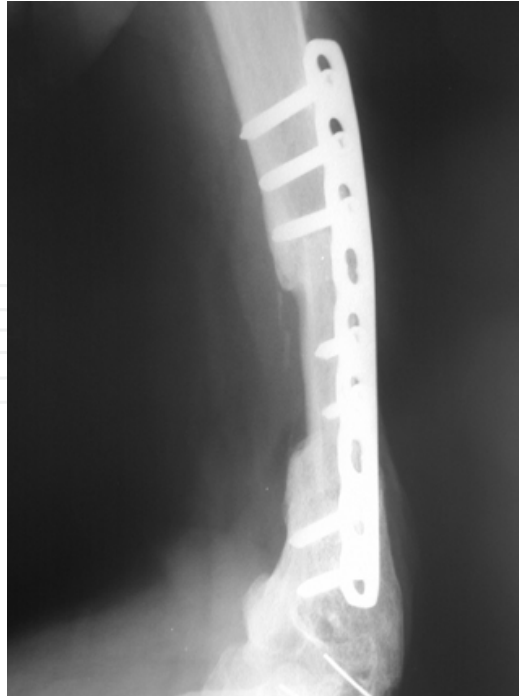

Fig. 1D. Rx after 6 months with the completely healing of the graft

**Case 2. Non-union of the radial diaphysis**

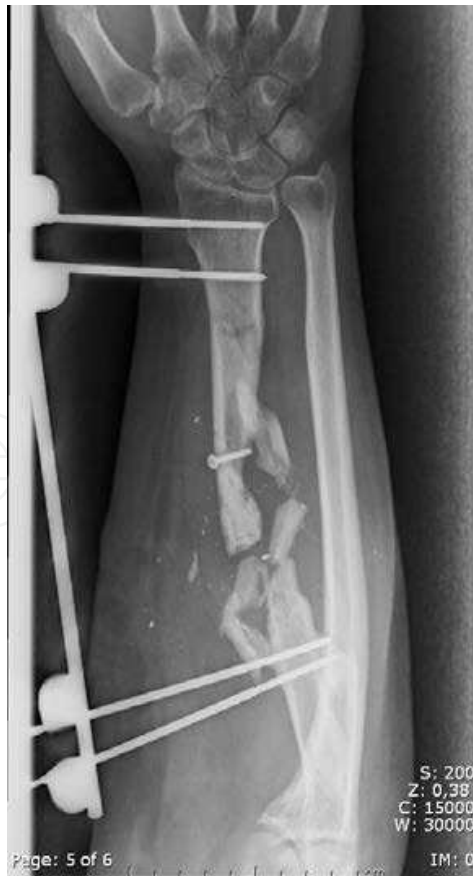

Fig. 2A. Non-union of the radial diaphysis treated with external fixation

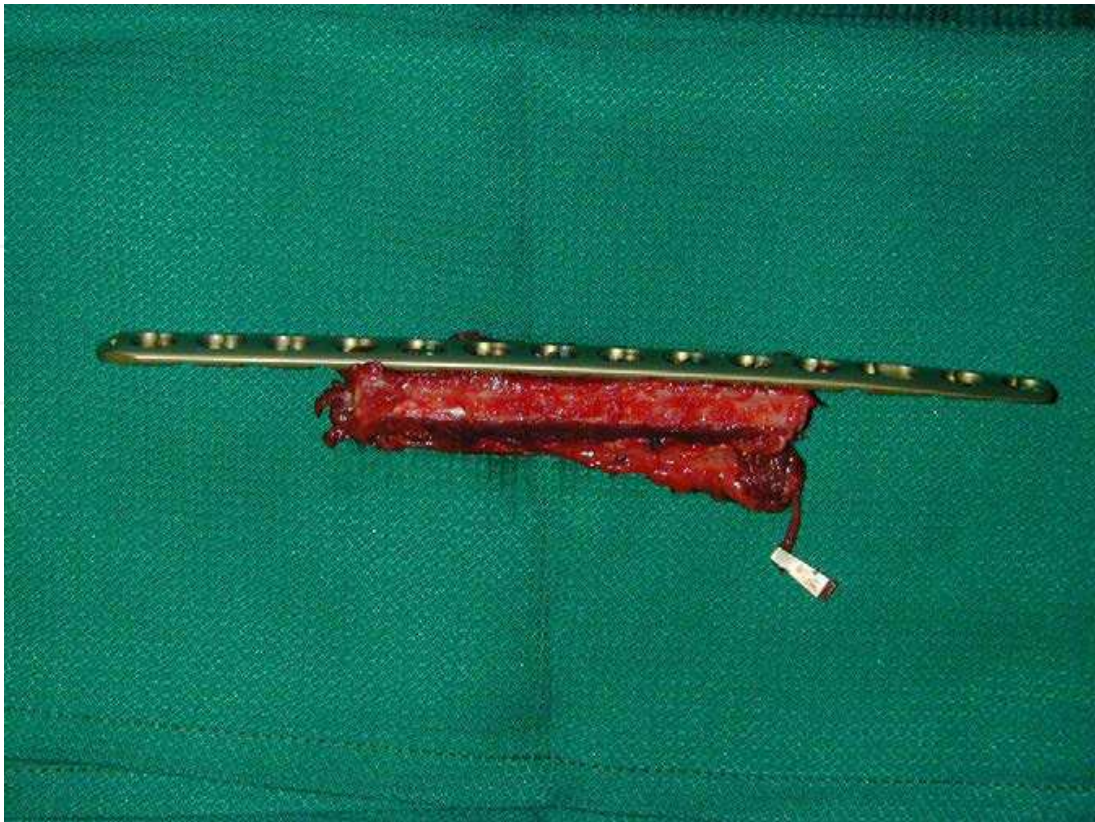


Fig. 2B. Free vascularized fibular bone graft with the pedicle of the peroneal vessels

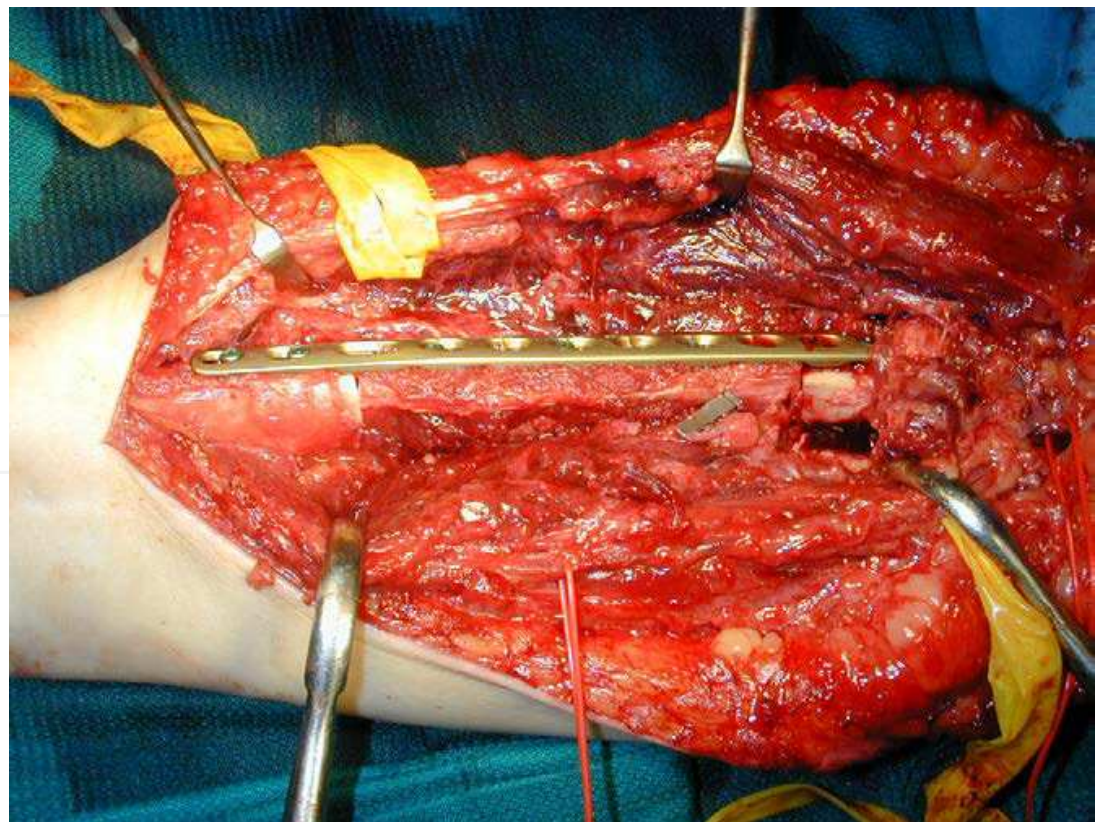


Fig. 2C. Intraoperative view of the fibular graft into the bone defect, fixed with a L.C.P. plate

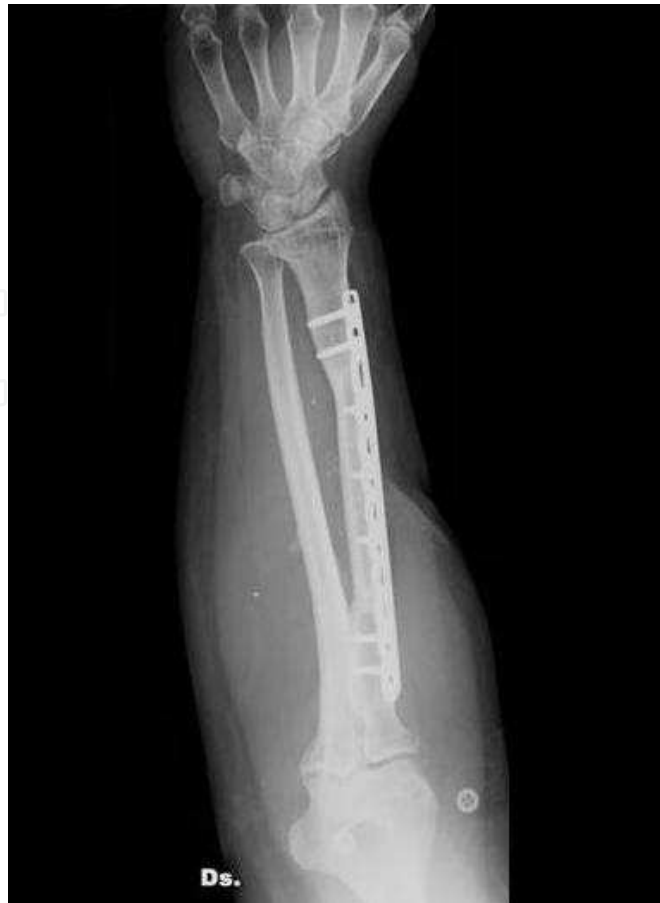

Fig. 2D. Rx after 12 months with the completely healing of the graft

#### 4. References

- [1] Jupiter JB. Complex non-union of the humeral diaphysis. Treatment with a medial approach, an anterior plate, and a vascularized fibular graft. *J Bone Joint Surg Am* 1990;72:701-7.
- [2] de Boer HH, Wood MB, Hemans J. Reconstruction of the large skeletal defects by vascularized fibula transfer. *Int Orthop* 1990;14:121-8.
- [3] McKee MD, Miranda MA, Riemer BL, Blasler RB, Redmond BJ, Sims SH, Waddell JP, Jupiter JB. Management of humeral non-union after the failure of locking intramedullary nails. *J Orthop Trauma* 1996;10:492-9.
- [4] Muramatsu K, Doi K, Ihara K, Shigetomi M, Kawai S. Recalcitrant posttraumatic non-union of the humerus. *Acta Orthop Scand* 2003;74:95-7.
- [5] Patel VR, Menon DK, Pool RD, Simonis RB. Non-union of the humerus after failure of surgical treatment. Management using the Ilizarov circular fixation. *J Bone Joint Surg Br* 2000;82:977-83.
- [6] Ring D, Jupiter JB, Quintero J, Sanders RA, Marti RK. Atrophic ununited diaphyseal fractures of the humerus with a bony defect. *J Bone Joint Surg Br* 2000;82: 867-71.


- [7] Volgas DA, Stannard JP, Alonso JE. Non-unions of the humerus. *Clin Orthop* 2004;419:46-50.
- [8] Moroni A, Rollo G, Guzzardella M, Zinghi G. Surgical treatment of isolated forearm non-union with segmental bone loss. *Injury* 1997;28(8):497-504.
- [9] Moroni A, Caja VL, Sbato C, Rollo G, Zinghi G. Composite bone grafting and plate fixation for the treatment of non-unions of the forearm with segmental bone loss: a report of eight cases. *J Orthop Trauma* 1995;9:419-426.
- [10] Naimark A, Miller K, Segal D, Kossoff J. Non-union. *Skeletal Radiol* 1981;6(1):21-25.
- [11] Grace TG, Eversmann WW Jr. The management of segmental bone loss associated with forearm fractures. *J Bone Joint Surg Am* 1980;62(7):1150-5.
- [12] Miller RC, Phalen GS. The repair of defects of the radius with fibular bone grafts. *J Bone Joint Surg Am* 1947;29:629-36.
- [13] Spira E. Bridging of bone defects in the forearm with iliac graft combined with intramedullary nailing. *J Bone Joint Surg Br* 1954;36:642-6.
- [14] Paramasivan ON, Younge DA, Pant R. Treatment of non-union around the olecranon fossa of the humerus by intramedullary locked nail. *J Bone Joint Surg Br* 2000;82:332-5.
- [15] Wu CC. Humeral shaft non-union treated by a Seidel interlocking nail with a supplementary staple. *Clin Orthop* 1996;326:203-8.
- [16] Catagni MA, Guerreschi F, Probe RA. Treatment of humeral non-unions with the Ilizarov technique. *Bull Hosp Jt Dis* 1991;51:74-83.
- [17] Cattaneo R, Catagni MA, Guerreschi F. Applications of the Ilizarov method in the humerus: lengthenings and non-unions. *Hand Clin* 1993;9:729-39.
- [18] Ciuccarelli C, Cervellati C, Montanari G, Masetti G, Galli G, Carpanelli F. The Ilizarov method for the treatment of non-union in the humerus. *Chir Organi Mov* 1990;75:115-20.
- [19] Lammens J, Bauduin G, Dreisen R, Moens P, Stuyck J, De Smet L, Fabry G. Treatment of non-union of the humerus using the Ilizarov external fixator. *Clin Orthop* 1998;353:223-30.
- [20] Trotter DH, Dobozi W. Non-union of the humerus: rigid fixation, bone grafting, and adjunctive bone cement. *Clin Orthop* 1986;204:62-8.
- [21] Heitmann C, Erdmann D, Levin LS. Treatment of segmental defects of the humerus with an osteoseptocutaneous fibular transplant. *J Bone Joint Surg Am* 2002;84:2216-23.
- [22] Tu YK, Yen CH, Yeh WL, Wang IC, Wang KC, Ueng SWN. Reconstruction of posttraumatic long bone defect with free vascularized bone graft: good outcome in 48 patients with 6 years' follow-up. *Acta Orthop Scand* 2001;72:359-64.
- [23] Buckwalter JA, Einhorn TA, Simon SR, eds. *Orthopaedic Basic Science*. Chicago: American Academy of Orthopaedic Surgeons, 2000.
- [24] Khan SN, Cammisa FP, Sandhu HS, Diwan AD, Firardi FP, Lane JM. The biology of bone grafting. *J Am Acad Orthop Surg* 2005;13:77-86.
- [25] Lieberman JR, Daluiski A, Einhorn TA. The role of growth factors in the repair of bone. Biology and clinical applications. *J Bone Joint Surg Am* 2002;84:1032-1044.

- [26] Brunelli GA, Vigasio A, Brunelli GR. Microvascular fibular grafts in skeleton reconstruction. *Clin Orthop* 1995;314:241-6.
- [27] Al Zahrani S, Harding MG, Kremli M, Khan FA, Ikram A, Takroni T. Free fibular graft still has a place in the treatment of bone defects. *Injury* 1993;24:551-554.
- [28] Stevanovic M, Gutow AP, Sharpe F. The management of bone defects of the forearm after trauma. *Hand Clin* 1999;15:299-318.
- [29] Mattar R Jr, Azze RJ, Castro Ferreira M, Starck R, Canedo AC. Vascularized fibular graft for management of severe osteomyelitis of the upper extremity. *Microsurgery* 1994;15:22-7.
- [30] Ruch DS, Weiland AJ, Wolfe SW, Geissler WB, Cohen MS, Jupiter JB. Current concepts in the treatment of distal radial fractures. *Instr Course Lect.* 2004;53:389-401. Review.
- [31] Wood MB. Upper extremity reconstruction by vascularized bone transfers: results and complications. *J Hand Surg Am.* 1987;12(3):422-7.
- [32] Moran CG, Wood MB. Vascularized bone autografts. *Orthop Rev* 1993;22(2):187-97.
- [33] Duffy GP, Wood MB, Rock MG, Sim FH. Vascularized free fibular transfer combined with autografting for the management of fracture non-unions associated with radiation therapy. *J Bone Joint Surg Am.* 2000;82(4):544-54.
- [34] Taylor GI, Miller GDH, Ham FJ. The free vascularized bone graft: a clinical extension of microvascular techniques. *Plast Reconstr Surg* 1975;55:533-544.
- [35] Lambert KL. The weight-bearing function of the fibula. A strain gauge study. *J Bone Joint Surg Am* 1971;53:507-513.
- [36] Pacelli LL, Gillard J, McLoughlin SW, Buehler MJ. A biomechanical analysis of donor-site ankle instability following free fibular graft harvest. *J Bone Joint Surg Am* 2006;85:597-603.
- [37] Vail TP, Urbaniak JR. Donor-site morbidity with the use of vascularized autogenous fibular grafts. *J Bone Joint Surg Am* 1996;78:204-211.
- [38] Malizos KN, Zalavras CG, Soucacos PN, Beris AE, Urbaniak JR. Free vascularized fibular grafts for reconstruction of skeletal defects. *J Am Acad Orthop Surg* 2004;12:360-369.
- [39] Carr AJ, Macdonald DA, Waterhouse N. The blood supply of the osteocutaneous free fibular graft. *J Bone Joint Surg Br* 1988;70(2):319-21.
- [40] Weiland AJ, Kleinert HE, Kutz JE, Daniel RK. Free vascularized bone grafts in surgery of the upper extremity. *J Hand Surg Am* 1979;4:129-143.
- [41] Chuang DC-C, Chen H-C, Wei FC. Compound functioning free muscle flap transplantation (lateral half of soleus, fibula, and skin flap). *Plast Reconstr Surg* 1992;89:335-339.
- [42] Hurst LC, Mirza MA, Spellman W. Vascularized fibular graft for infected loss of the ulna: case report. *J Hand Surg Am* 1982;7:498-501.
- [43] Jones NF, Swartz WM, Mears DC, Jupiter JB, Grossman A. The "double barrel" free vascularized bone graft. *Plast Reconstr Surg* 1988;81:378-385.
- [44] Koshima I, Higaki H, Soeda S. Combined vascularized fibula and peroneal composite-flap transfer for severe heat-press injury of the forearm. *Plast Reconstr Surg* 1991;88:338-341.

- [45] Santanelli F, Latini C, Leanza L, Scuderi N. Combined radius and ulna reconstruction with a free fibula transfer. *Br J Plast Surg* 1996;49:178-182.
- [46] Dell PC, Sheppard JE. Vascularized bone grafts in the treatment of infected forearm non-unions. *J Hand Surg Am* 1984;9:653-658.
- [47] Olekas J, Guobys A. Vascularized bone transfer for defects and pseudoarthrosis of forearm bones. *J Hand Surg Br* 1991;16:406-408.
- [48] Jupiter JB, Gerhard HJ, Guerrero JA, Nunley J, Levin LS. Treatment segmental defects of the radius with use of the vascularized osteoseptocutaneous fibular autogenous graft. *J Bone Joint Surg Am* 1997;79:542-550.
- [49] Tang C-H. Reconstruction of the bones and joints of the upper extremity by vascularized free fibular graft: report of 46 cases. *J Reconstr Microsurg* 1992;8:285-292.
- [50] Yajima H, Tamai S, Ono H, Kizaki K. Vascularized bone grafts to the upper extremities. *Plast Reconstr Surg* 1998;101:727-735.
- [51] Yajima H, Tamai S, Ono H, Kizaki K, Yamauchi T. Free vascularized fibula grafts in surgery of the upper limb. *J Reconstr Microsurg* 1999;15:515-521.
- [52] Adani R, Delcroix L, Innocenti M, Marcoccio I, Tarallo L, Celli A, Ceruso M. Reconstruction of large posttraumatic skeletal defects of the forearm by vascularized free fibular graft. *Microsurgery* 2004;6:423-9.
- [53] Adani R, Delcroix L, Tarallo L, Baccarani A, Innocenti M. Reconstruction of posttraumatic bone defects of the humerus with vascularized fibular graft. *J Shoulder Elbow Surg* 2008;17(4):578-84.
- [54] Tsai TM, Ludwig L, Tonkin M. Vascularized fibular epiphyseal transfer. A clinical study. *Clin Orthop Relat Res* 1986;210:228-234.
- [55] Harrison DH. The osteocutaneous free fibular graft. *J Bone Joint Surg Br.* 1986;68(5):804-7.
- [56] Shalaby S, Shalaby H, Bassiony A. Limb salvage for osteosarcoma of the distal tibia with resection arthrodesis, autogenous fibular graft and Ilizarov external fixator. *J Bone Joint Surg Br.* 2006;88(12):1642-6.
- [57] González del Pino J, Bartolomé del Valle E, Graña GL, Villanova JF. Free vascularized fibula grafts have a high union rate in atrophic non-unions. *Clin Orthop* 2004;419:38-45.
- [58] Minami A, Kasashima T, Iwasaki N, Kato H, Kaneda K. Vascularized fibular grafts: an experience of 102 patients. *J Bone Joint Surg Br* 2000;82:1022-5.
- [59] Vail TP, Urbaniak JR. Donor-site morbidity with the use of vascularized autogenous fibular grafts. *J Bone Joint Surg Am* 1996;78:204-211.
- [60] Kanaya K, Wada T, Kura H, Yamashita T, Usui M, Ishii S. Valgus deformity of the ankle following harvesting of a vascularized fibular graft in children. *J Reconstr Microsurg* 2002;18:91-96.
- [61] Green DP, Hotchkiss RN, Pederson WC, Wolfe S, eds. *Green's Operative Hand Surgery*, 5th ed. Philadelphia: Churchill Livingstone, 2005.
- [62] Levin LS: The use of the osteoseptocutaneous free fibula transfer in the upper extremity, in *Reconstructive Microsurgery [DVD]*. Rosemont, IL: American Society for Surgery of the Hand, 1996.

- [63] Lee KS, Park JW. Free vascularized osteocutaneous fibular graft to the tibia. *Microsurgery* 1999;19:141-7.
- [64] Han CS, Wood MB, Bishop AT, Cooney WP. Vascularized bone transfer. *J Bone Joint Surg Am* 1992;74:1441-1449.
- [65] Arai K, Toh S, Tsubo K, Nishikawa S, Narita S, Miura H. Complications of vascularized fibula graft for reconstruction of long bones. *Plast Rec Surg* 2002;7:2301-6.
- [66] Belt PJ, Dickinson IC, Theile DRB. Vascularised free fibular flap in bone resection and reconstruction. *Br J Plast Surg* 2005;58:425-30.
- [67] Minami A, Kaneda K, Itoga H, Usui M. free vascularized fibular grafts. *J Reconstr Microsurg* 1989; 5:37-43.
- [68] De Boer HH, Wood MB. Bone changes in the vascularized fibular grafts. *J Bone Joint Surg Br* 1989;71(3)374-378.
- [69] Shpitzer T, Neligan P, Boyd B, Gullane P, Gur E, Freeman J. Leg morbidity and function following fibular free flap harvest. *Ann Plast Surg* 1997;38(5):460-4.
- [70] Garrett A, Ducic Y, Athre RS, Motley T, Carpenter B. Evaluation of fibula free flap donor site morbidity. *Am J Otolaryngol.* 2006;27(1):29-32.
- [71] Levin LS. Tumor reconstruction: The use of the vascularized osteoseptocutaneous fibula transplant for extremity reconstruction. *Oper Tech Orthop* 1998;9: 84-91.

IntechOpen



## **Bone Grafting**

Edited by Dr Alessandro Zorzi

ISBN 978-953-51-0324-0

Hard cover, 214 pages

**Publisher** InTech

**Published online** 21, March, 2012

**Published in print edition** March, 2012

Bone grafting is the surgical procedure in which new bone (bone graft) or a replacement material (graft substitute), is placed into bone fractures or bone defects to aid in healing. Bone grafting is in the field of interest of many surgical specialties, such as: orthopedics, neurosurgery, dentistry, plastic surgery, head and neck surgery, otolaryngology and others. In common, all these specialties have to handle problems concerning the lack of bone tissue or impaired fracture healing. There is a myriad of surgical techniques nowadays involving some kind of bone graft or bone graft substitute. This book gathers authors from different continents, with different points of view and different experiences with bone grafting. Leading researchers of Asia, America and Europe have contributed as authors. In this book, the reader can find chapters from the ones on basic principles, devoted to students, to the ones on research results and description of new techniques, experts will find very beneficial.

### **How to reference**

In order to correctly reference this scholarly work, feel free to copy and paste the following:

R. Adani, L. Tarallo and R. Mugnai (2012). Reconstruction of Post-Traumatic Bone Defect of the Upper-Limb with Vascularized Fibular Graft, Bone Grafting, Dr Alessandro Zorzi (Ed.), ISBN: 978-953-51-0324-0, InTech, Available from: <http://www.intechopen.com/books/bone-grafting/reconstruction-of-post-traumatic-bone-defect-of-the-upper-limb-with-vascularized-fibular-graft>

**INTECH**  
open science | open minds

#### **InTech Europe**

University Campus STeP Ri  
Slavka Krautzeka 83/A  
51000 Rijeka, Croatia  
Phone: +385 (51) 770 447  
Fax: +385 (51) 686 166  
[www.intechopen.com](http://www.intechopen.com)

#### **InTech China**

Unit 405, Office Block, Hotel Equatorial Shanghai  
No.65, Yan An Road (West), Shanghai, 200040, China  
中国上海市延安西路65号上海国际贵都大饭店办公楼405单元  
Phone: +86-21-62489820  
Fax: +86-21-62489821



© 2012 The Author(s). Licensee IntechOpen. This is an open access article distributed under the terms of the [Creative Commons Attribution 3.0 License](#), which permits unrestricted use, distribution, and reproduction in any medium, provided the original work is properly cited.

IntechOpen

IntechOpen