

# We are IntechOpen, the world's leading publisher of Open Access books Built by scientists, for scientists

4,800

Open access books available

122,000

International authors and editors

135M

Downloads

Our authors are among the

154

Countries delivered to

TOP 1%

most cited scientists

12.2%

Contributors from top 500 universities



WEB OF SCIENCE™

Selection of our books indexed in the Book Citation Index  
in Web of Science™ Core Collection (BKCI)

Interested in publishing with us?  
Contact [book.department@intechopen.com](mailto:book.department@intechopen.com)

Numbers displayed above are based on latest data collected.

For more information visit [www.intechopen.com](http://www.intechopen.com)



## Bone Grafting in Malunited Fractures

Fernando Baldy dos Reis<sup>1</sup> and Jean Klay Santos Machado<sup>2</sup>

<sup>1</sup>*Orthopedics and Traumatology Department,  
Universidade Federal de São Paulo (Unifesp), São Paulo,*

<sup>2</sup>*Porto Dias and Adventista de Belém Hospitals, Pará,  
Brazil*

### 1. Introduction

Pseudarthrosis and delayed union are two types of malunion events that can occur during fracture healing, and it is necessary to define and recognize the differences between them. Pseudarthrosis is defined as a case of consolidation failure in which a false joint is formed, including the presence of synovial fluid. Delayed union, or a delay in the fracture consolidation, is a condition where consolidation is not present and there is no evidence that it might occur, but there are no signs of movements in the focus of the lesion or of a "false joint": the bones simply do not unite (Jupiter & Rüedi, 1992; Miller & Phalen, 1947; Muller et al. 1990; Müller, 1965; Weber & Cech, 1976).

In 1986, the Food and Drug Administration (FDA) bureau defined diaphysis malunion as a situation identified at least nine months after the injury, provided the fracture shows no visible progressive signs of consolidation in the last three months. This concept applies only to diaphyses and is not a definition in cases of femoral neck or scaphoid fractures, in which the maximum periods considered for consolidation are three and four months respectively. In other cases, such as severe bone loss or active infections, the cut-off periods for a diagnosis of malunion are usually much shorter (Campbell & Boyd, 1941; Scaglietti et al. 1965; Schemitsch & Richards, 1992).

In cases of union delay, the healing process that is expected for the fracture is not interrupted; it does occur, but too slowly, unlike pseudarthrosis, in which there is an interruption in the bone healing. The process of evolution of the bone healing can be clinically and radiographically evidenced and followed up (Boyd, 1943; Ring et al. 1997).

### 2. Epidemiology

The incidence of malunions reported in the literature varies from 1% to 12% (Miller & Phalen, 1947, Moroni et al. 1997; Müller, 1965; Rasmussen et al. 1993) according to the severity of the primary lesion and the treatment initially used. The phenomenon is more common in men (over 80% of cases) in the third and fourth decades of life, probably due to the fact that these men are more frequently involved in risky activities (Scaglietti et al., 1965). The dominant limb is the one most affected (Weber & Cech, 1976; Wei et al. 1986; Weiland et al. 1979), probably due to intensified use of the limb in the postoperative period.

When this is associated with an inadequate surgical procedure, the risk of malunion is higher (Weber & Cech, 1976; Wei et al. 1986).

### 3. Etiology

Pseudarthrosis may be caused by mechanical and/or biological factors (Weber & Cech, 1976).

- a. Mechanical factors involved in pseudarthrosis
- Lack of stabilization in unstable fractures;
  - Deficient stabilization of the fracture, as in cases of fixation with plate and screws, with insufficient number of cortical elements involved in each side, fractures treated with unlocked intramedullary devices, and the use of inappropriate plates, such as the one-third tubular plate in forearm fractures
  - Fractures treated conservatively, with an insufficient immobilization period.

According to the Perren and Cordey theory (cited by Perren & Ito, 2009), osteoblasts need stability between the bone fragments in order to develop. Therefore, spaces between fragments larger than 4 mm cannot be filled by new bone tissue. In situations of high strain, the gap is filled by chondroblasts and fibroblasts, instead of bone formation cells, particularly in surgically treated cases.

- b. Biological factors involved in pseudarthrosis

b1- Local:

- Bone defects
- Open (exposed) fractures
- Injury to soft tissue structures close to the fractured bone, such as in direct trauma cases
- Intensive comminution
- Segmental fractures
- Pathological fractures
- Diastatic fractures
- Soft-tissue interposition.

b2- Systemic:

- Neuropathies
- Diabetes mellitus
- Malnutrition
- Chronic smoking
- Chronic alcoholism
- Use of anticoagulants
- Use of corticosteroids

### 4. Classification

The most commonly used classification is still the one proposed by Müller, Weber and Cech in 1976 (Weber & Cech, 1976), which divides malunited fractures into two groups: those that are vascularized and those that are avascular or unviable.

Vascularized malunions may be hypertrophic (known as "elephant's foot"), with a large callous formation, normotrophic ("horse hoof") or oligotrophic, as shown in Figure 1. Hypertrophic consolidation may be the result of mechanical problems, such as poor fixation, inadequate immobilization, and premature weight bearing on the affected limb, with reduced fractures with viable fragments. Normotrophic healing occurs after moderate fixation with plates and screws. Oligotrophic consolidation, despite being vascularized, does not present a callous formation, and occurs after an accentuated deviation, or diastasis of the fragment due to internal fixation without precise positioning of the fragments.

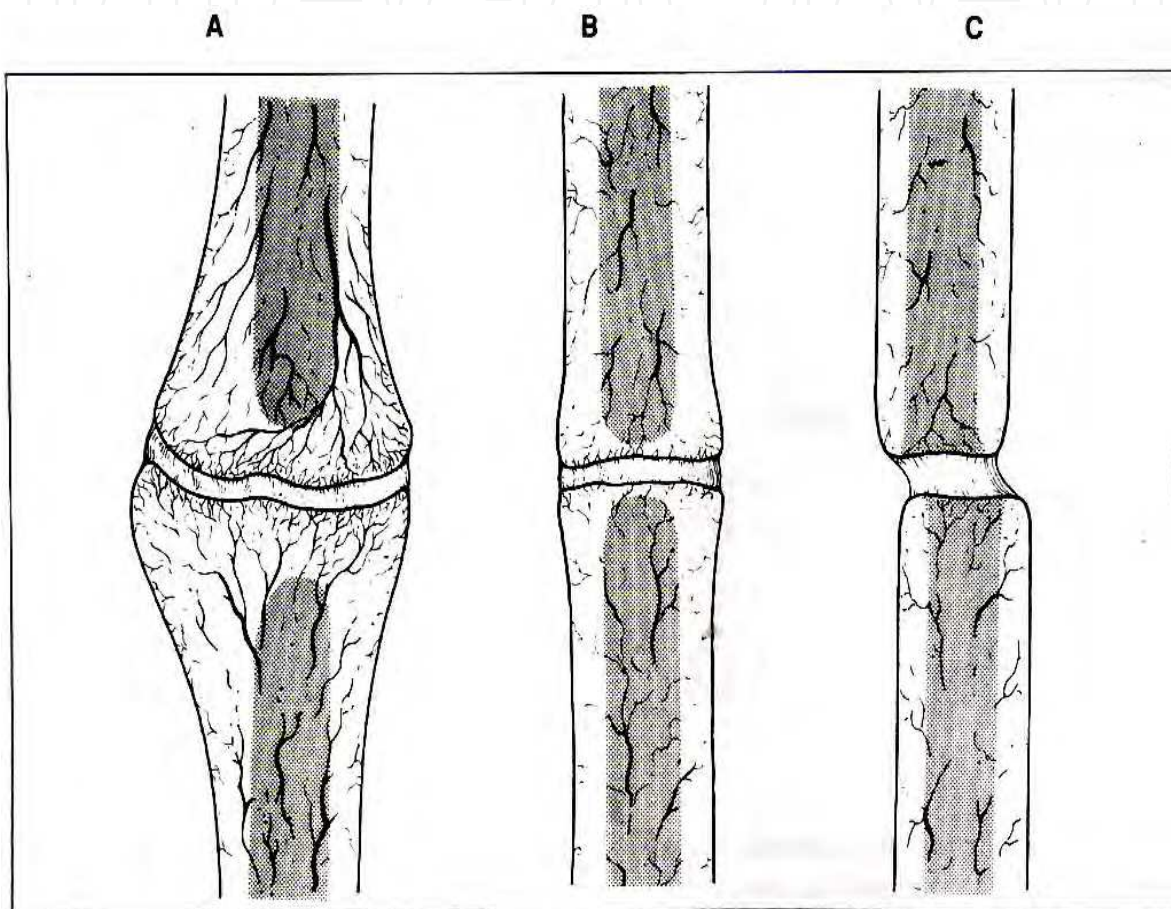


Fig. 1. Illustration of vascularized malunited fractures: "elephant's foot" (A), "horse hoof" (B) and oligotrophic (C).

Avascular malunions are classified as wedge, twisted; comminuted; by bone defects (gaps) and atrophic. As shown in Figure 2, in the case of the wedge, twisted malunion, there is an intermediate bone fragment, and the consolidation takes place only in one of the main fragments. In the case of the comminutive malunion, one or more intermediate bone fragments are necrotic, and these generally result in breaking of the plate. In consolidation failure by bone defects, there is a loss of one of the fragments. The bone extremities are viable. These cases occur after open fractures with bone loss, tumor resections or osteotomies. In the atrophic cases, osteoporotic and atrophic extremities are present, and there is an interpositioning of healing tissue, but without osteogenic potential (Weber & Cech, 1976).

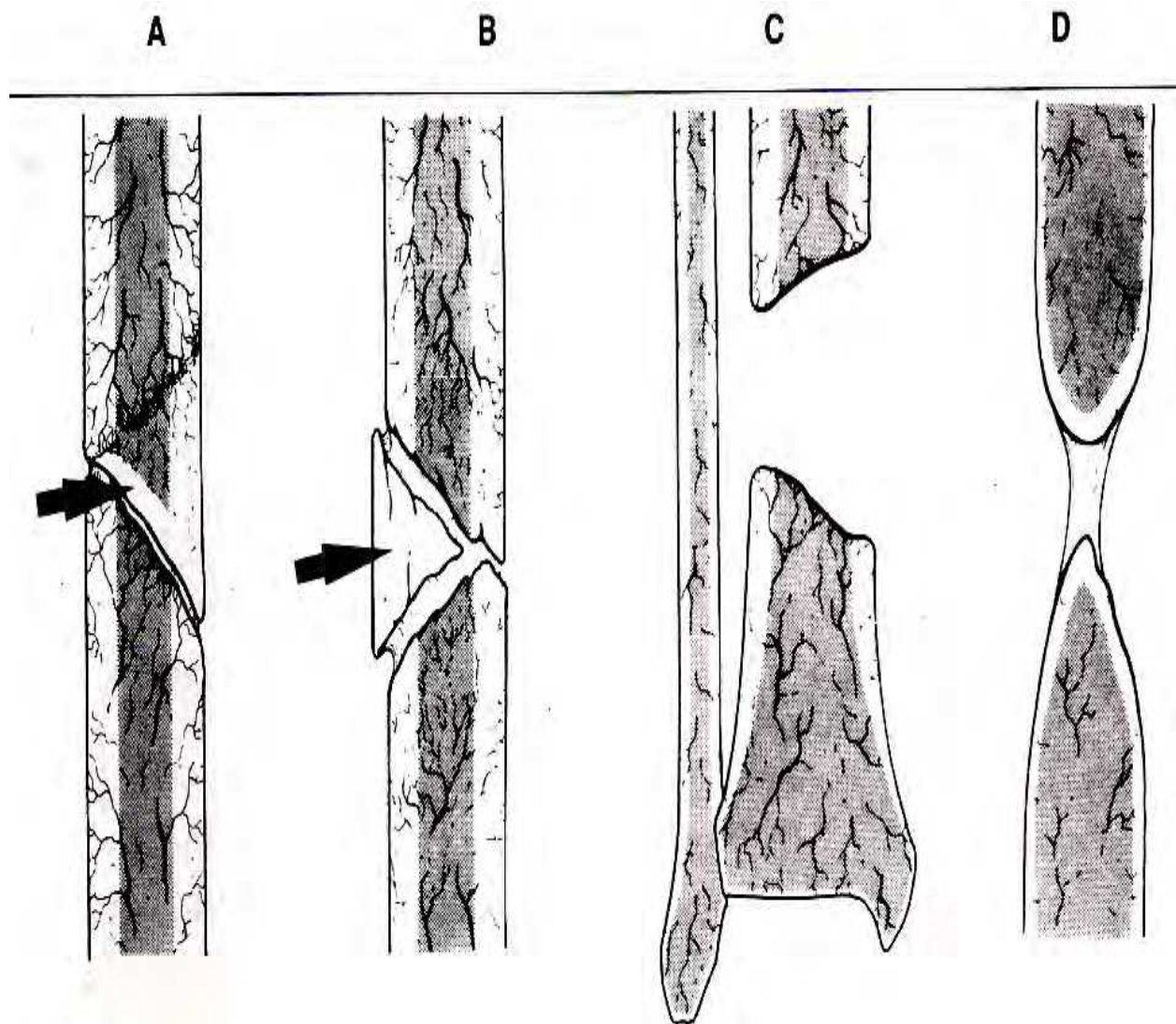


Fig. 2. Illustration of avascular malunions: wedge, twisted (A), comminutive (B), bone gap (C) and atrophic (D).

## 5. Signs and symptoms

Basically, patients with malunited fractures present pain when moving the limb, and when manual pressure is applied to the lesion. The presence of deformity (Figure 3) or visible mobility depends on the type of malunion (Schemitsch & Richards, 1992; Segmüller et al. 1969).

## 6. Imaging exams

The diagnosis of consolidation failure is, in most cases, clinical and radiographical. For the radiographic study, two incidences are enough: antero-posterior and lateral, including necessarily the satellites joints for a correct evaluation of the lesion. In situations where the diagnosis is not evident in the initial X ray, additional exams can be obtained:

- Planigraphy, in which one of the sections may show a radiotransparent line corresponding to the focus of the lesion

- Bone scintigraphy, in which the increase in captation may indicate the presence of mobility in the focus of the lesion
- Computed tomography, with 2-mm sections, which can definitely show the presence of the lesion (Figure 4).

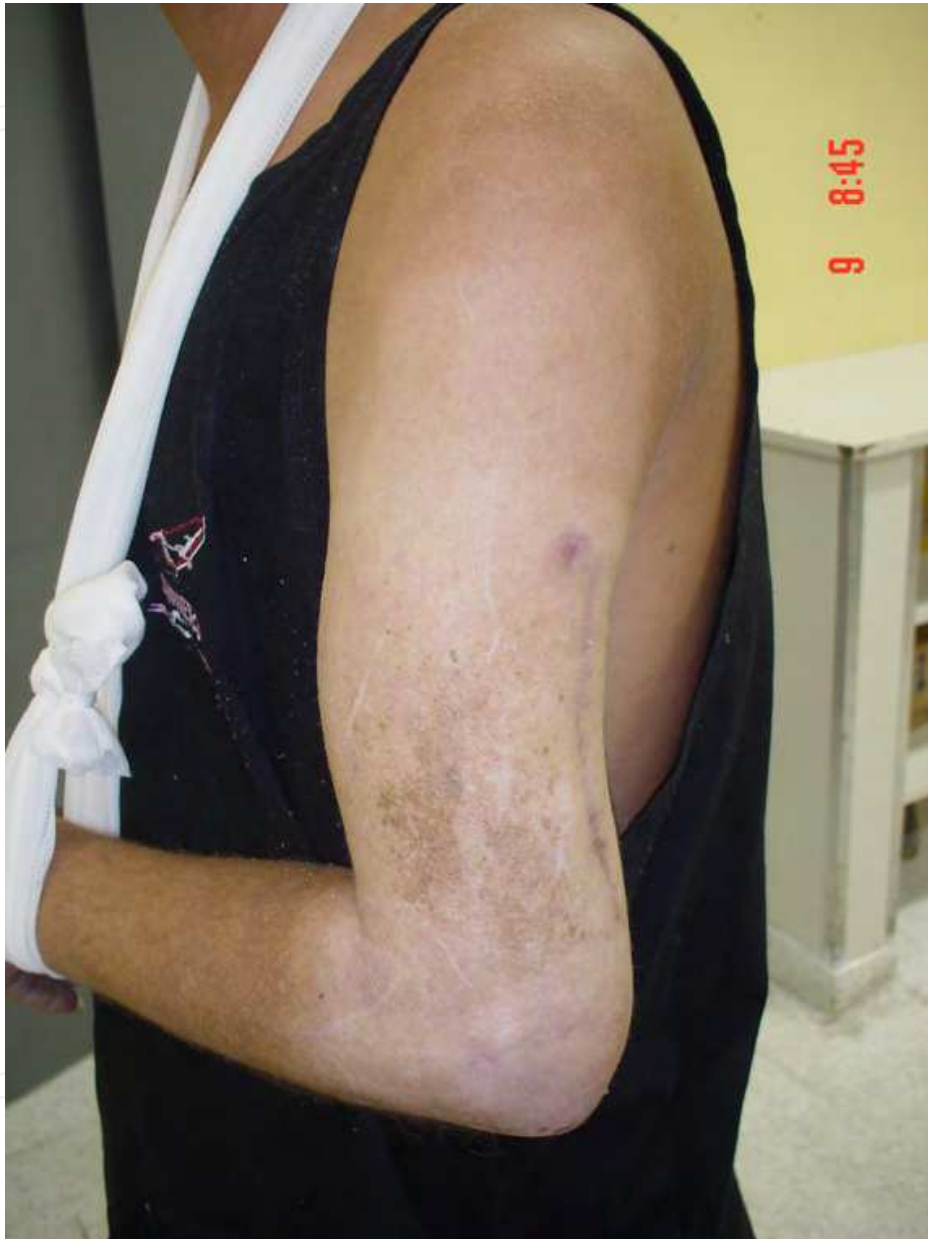

Fig. 3. Picture of a patient with a malunited fracture of the left humerus, with an evident deformity of the limb.

In patients with previous surgical treatments and in those with signs of infection, it is advisable to perform laboratory exams (blood sedimentation, c-reactive protein, complete blood count), in order to identify active infection, since latent infections do not appear in the usual laboratory exams. In imaging exams, the presence of a periosteal reaction, or signs of implant loosening, are suggestive of local infection (Barbieri et al. 1997; Muller et al. 1990; Scuderi, 1948; Spira, 1954).

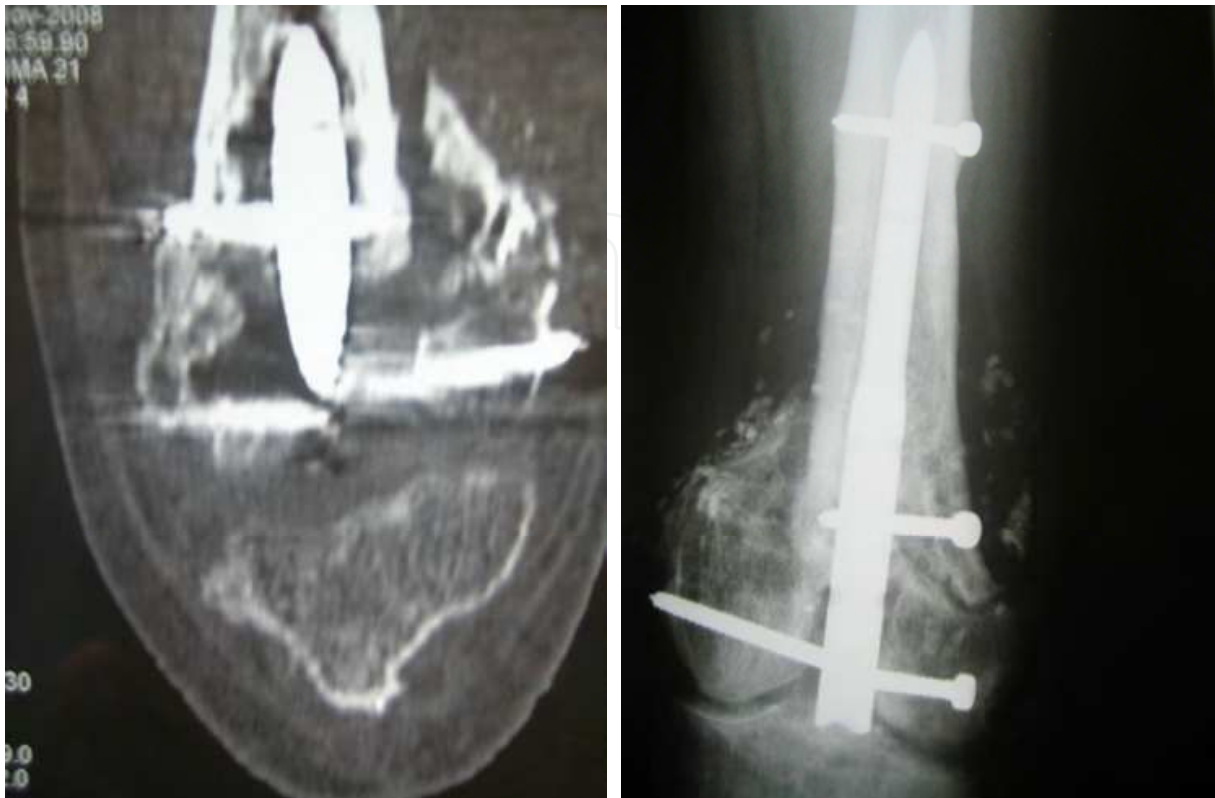

Fig. 4. Frontal section computed tomography (left) showing nonunion of the distal femur, without any evident radiographic signs (right).

## 7. Treatment

The treatment of malunited fractures is surgical, because the lesion results in severe anatomic and functional disorders. The method is chosen according to the type of lesion, as well as its cause: therefore, it is important to define whether the origin is mechanical or biological. In general, bone grafts are indicated in cases where the cause is either purely biological, or biological associated with a mechanical cause. Thus, vascularized and sometimes oligothrophic malunited fractures have formal indication for bone grafting (dos Reis et al. 2009; Gibson & Loadman, 1948; Haddad & Drez, 1974, Nicoll, 1956).

The bone grafts used in these cases are basically (dos Reis et al. 2009; Nilsson et al. 1986; Piotrowski et al., 2005; Reis, 2001):

- a. Autologous: grafted from the same patient
  1. Cancellous (spongy): used in most cases
  2. Tricortical: indicated when there is a segmental gap
  3. Segmental, which can be free or vascularized
- b. Synthetic: usually made of hydroxyapatite, whether associated or not with any calcium derivative, such as tricalcium phosphate
  4. Granulated
  5. En bloc.

### 7.1 Surgical techniques

#### a. Malunited fracture without a bone gap

Treatment consists in inserting a cancellous bone graft (best results) or synthetic, granulated graft over the lesion site. Where necessary, this may be associated with a synthesis material review (Figure 5) (Ring et al. 1997; Schemitsch & Richards, 1992; Segmüller et al. 1969; Tydings et al. 1986).

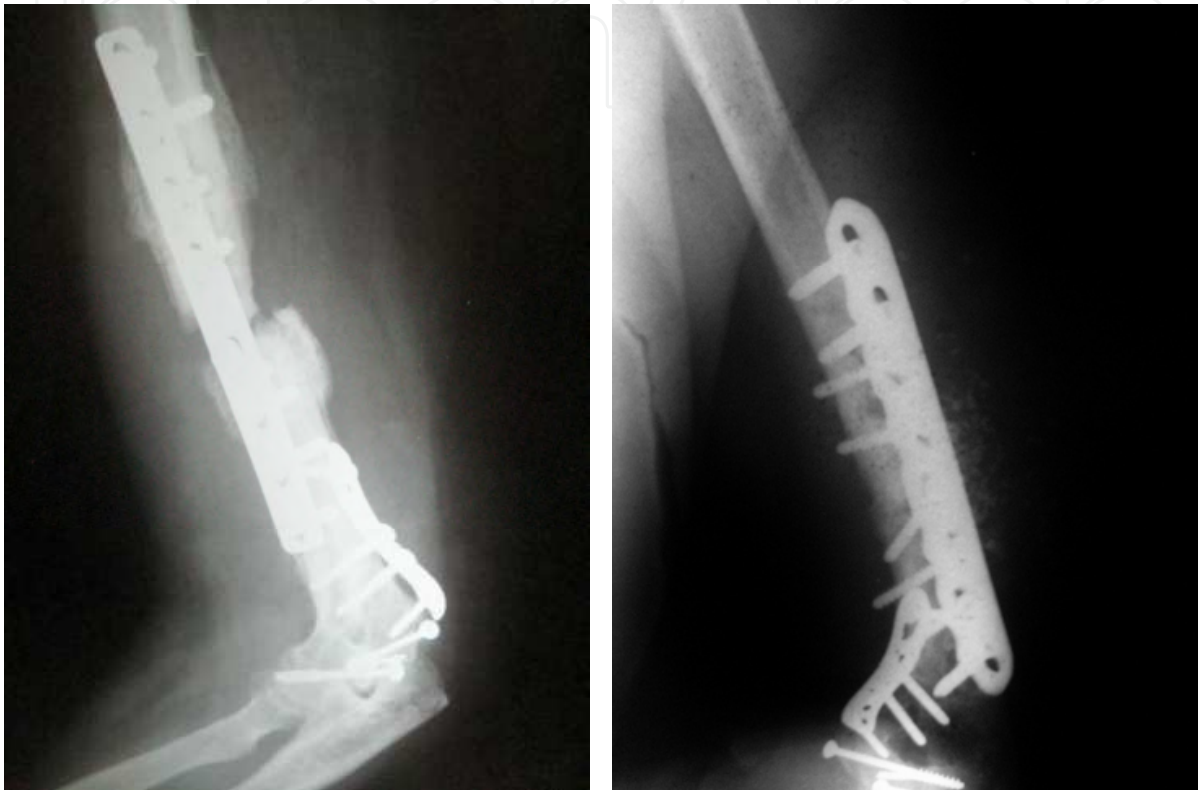


Fig. 5. Radiograph of a malunited fracture (left) of the humerus, treated with a new synthesis material and with synthetic bone grafting

#### b. Malunited fracture with a partial bone gap

In this case, there are two treatment options:

b1) Using the abovementioned technique, with the bone graft filling the gap. For this, the remaining cortical bone must have viable tissue at the edges. The advantage of this method is that it preserves the bone length. The disadvantage is its dependence on the synthesis material, since the lower contact between the bone extremities requires the synthesis to be larger (Barbieri et al., 1997; dos Reis et al., 2009; Orzechowski et al., 2007; Reis, 2001).

b2) Resecting the bone extremities, in order to regularize the main fragments, followed by autologous or granulated, synthetic bone grafting. The advantage is that the procedure is less dependent on synthesis, and the disadvantage is that it shortens the bone length, which should not be less than 2 cm in the upper limbs and 5 cm in the lower limbs, to avoid functional problems (Figure 6) (Haddadr & Drez, 1974; Ilizarov, 1988; Muller et al., 1990; Müller, 1965).



c. Malunited fracture with a segmental bone loss

In this case there are three treatment options:

c1) Treatment with an external fixation: bone transfer, especially for larger bone gaps, or in cases of acute shortening associated with lengthening outside the malunion lesion. The advantage of this method is the possibility of treating cases with infection; and the disadvantage is the morbidity associated with the technique, like pain, stiffness joint, superficial infections and many scars (Aronson, 1997; Ilizarov, 1991; Ilizarov et al., 1972; Ilizarov, 1988, Paley et al., 1989).

c2) The use of an antibiotic-impregnated cement spacer to treat the infection, over a period of six weeks. After this period, a pseudocapsule (induced membrane) is formed and used as a container for the cancellous bone graft that is inserted in the second stage. This technique was described by Masquelet and colleagues (Masquelet & Begue, 2010; Masquelet et al., 2000), and is an alternative in cases of bone loss with infection. However, its drawback is synthesis overload, since the cancellous bone graft adds little stability to the lesion site.

c3) Treatment with segmental bone graft, usually the fibula, which may be vascularized or not. This technique is indicated mainly in cases where there is major bone loss, and the graft must be included in the synthesis. Its advantage is that it preserves limb length, and its disadvantage is the complexity of the method, especially when a vascularized graft is used (Figure 7) (Miller & Phalen, 1947; Reis, 2001).

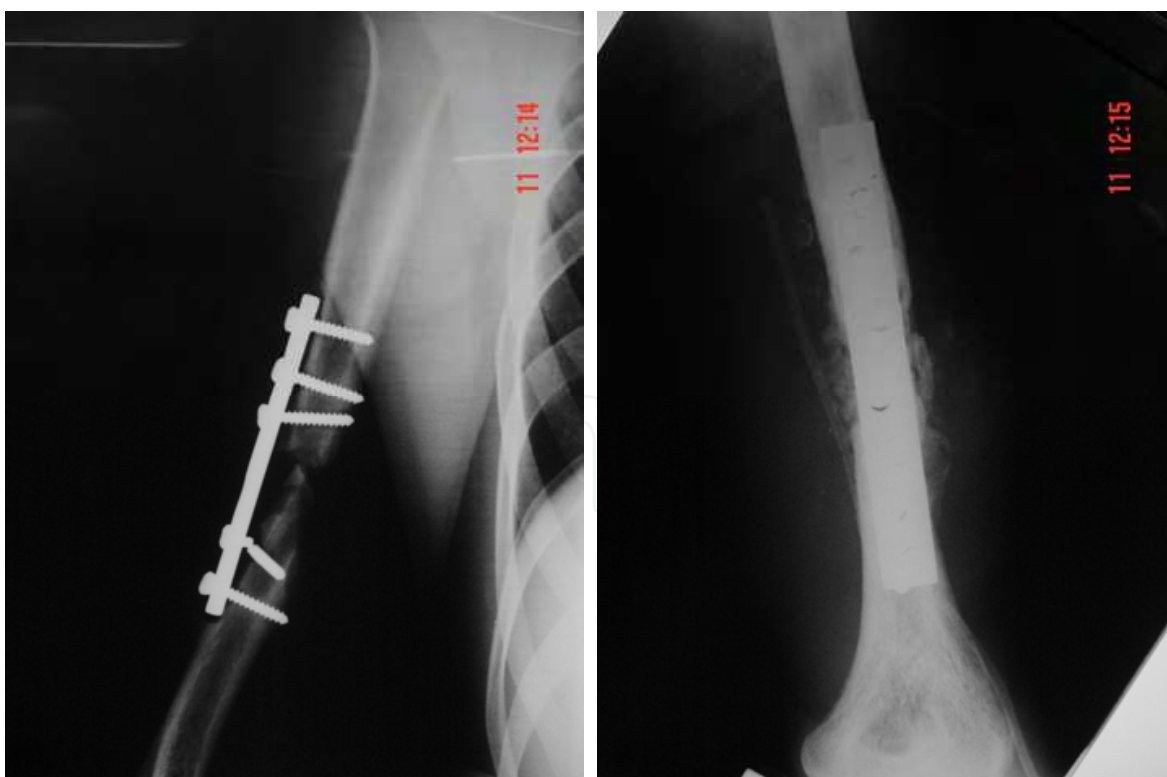


Fig. 6. Radiograph showing a nonunion of the humerus with a partial bone defect (left), treated with resection of the edges, bone shortening of 3 cm, and change of the synthesis material associated with bone grafting.

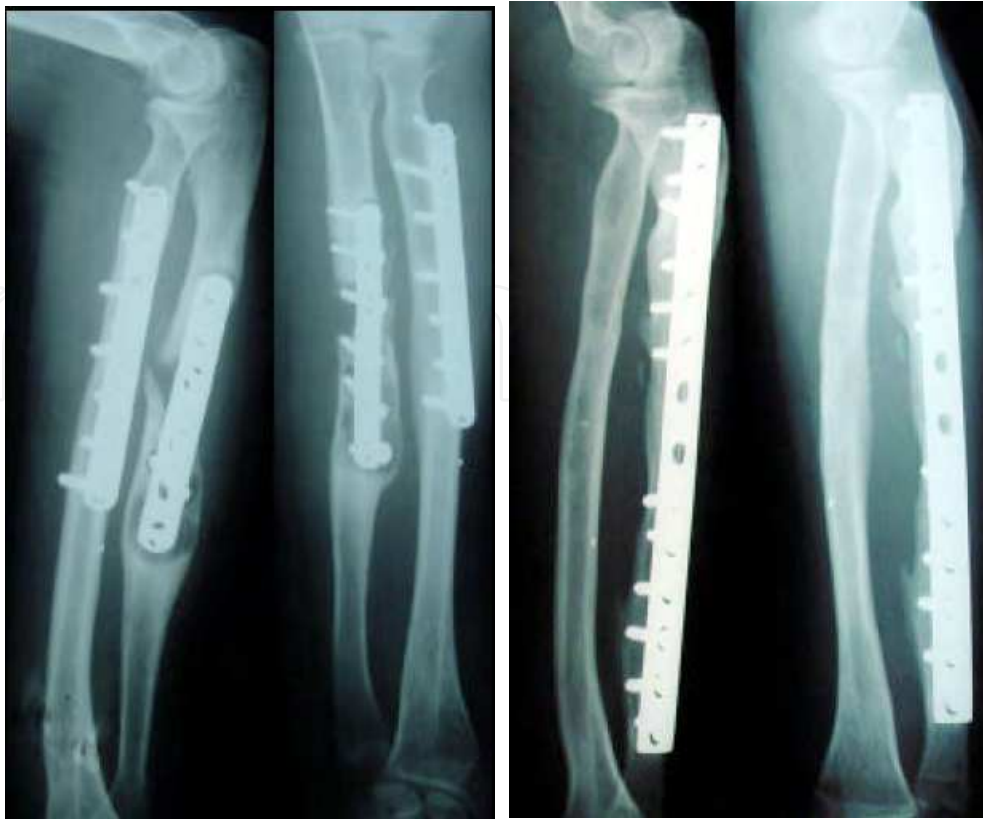

Fig. 7. Malunited ulna fracture with segmental bone loss, treated with osteosynthesis with long a dynamic compression plate (DCP) associated with bone grafting (non-vascularized fibula)

#### d. Special situations

##### d1) Malunited fracture with a bone loss in one of the forearm bones.

Because the forearm is a well-established morphofunctional unit, it is necessary to preserve compatibility of the length between the two long bones. Therefore, we may use a tricortical or a vascularized graft (mainly in gaps larger than 6 cm) in the bone that presents bone tissue loss and/or to associate this procedure with shortening of the other bone (Figure 8) (Barbieri et al., 1997; dos Reis, 2009; Reis, 2001).

##### d2) Nonunion with a bone loss in lower limbs

The classical indication for this kind of lesion is bone transfer with external fixation. However, particularly in cases where there are large gaps, and depending on the patient's tolerability, we usually choose the shortening-elongation method. In this case, it is left to the patient's discretion to determine whether the elongation is complete or not, but without compromising the consolidation of the malunited fracture. The lesion is submitted to compression from the start of the treatment, except in the case of bone transfer (Aronson, 1997; Ilizarov, 1991; Ilizarov et al., 1972; Ilizarov, 1988; Paley et al., 1989).

##### d3) Pseudoarthrosis after intramedullary nail insertion

Due to the increasingly frequent use of intramedullary nails, the occurrence of this type of nonunion has become fairly common. In these cases, the indication is usually substitution

with a reamed, blocked, intramedullary nail, making the use of an autologous graft unnecessary: studies show that the effect of reaming is comparable to open cancellous bone grafting, provided the reaming is at least 2 mm larger than that of the first surgery (Spira, 1954; Tydings et al., 1986).

IntechOpen

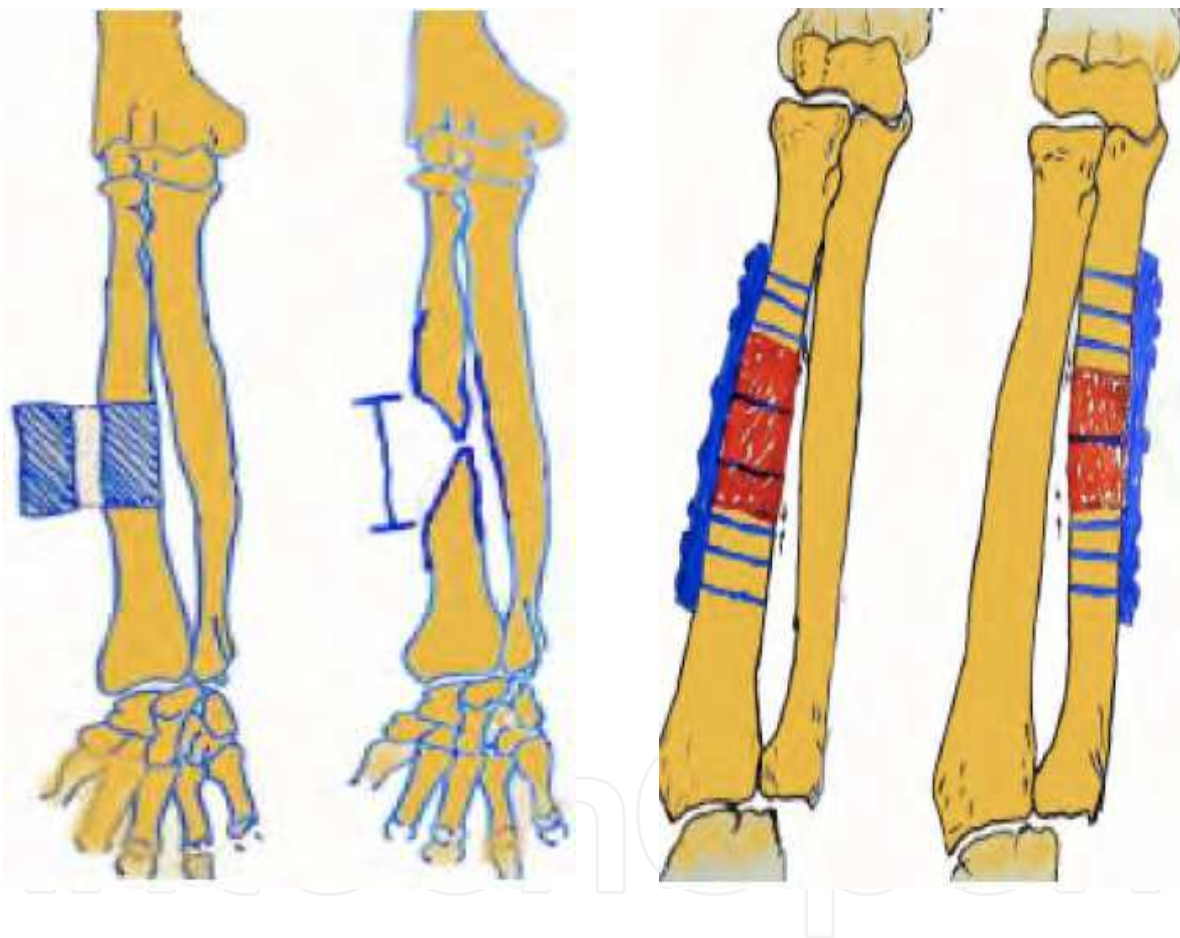


Fig. 8. Illustration showing the pre-operative surgical planning in the case of an atrophic nonunion of the radius with adjustment of the borders, grafting and osteosynthesis with plate and screw

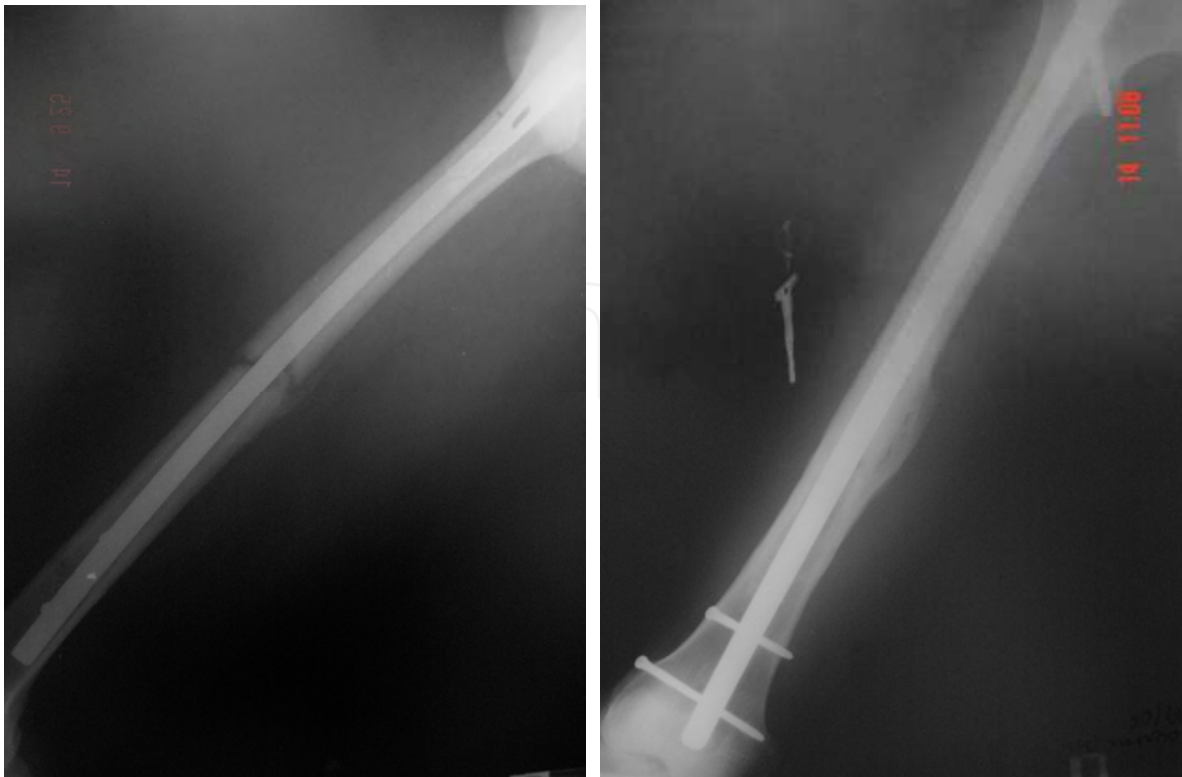

Fig. 9. Radiograph of a diaphyseal femoral nonunion (left), in a patient using a blocked intramedullary nail, treated with the substitution of the nail for a longer one with a larger caliber, resulting in consolidation (right).

## 8. References

- Aronson, J. (1997). Limb-lengthening, skeletal reconstruction, and bone transport with the Ilizarov method. *The Journal of Bone and Joint Surgery. American Volume*, Vol.79, No.8, (August 1997), pp. 1243-58, ISSN 0021-9355.
- Barbieri, CH, Mazzer, N, Aranda, CA & Pinto, MM. (1997). Use of a bone block graft from the iliac crest with rigid fixation to correct diaphyseal defects of the radius and ulna. *The Journal of Hand Surgery: Journal of the British Society for Surgery of the Hand*, Vol.22, No.3, (June 1997), pp. 395-401, ISSN 0266-7681.
- Boyd, HB. (1943). The treatment of difficult and unusual non-unions. *Journal of Bone and Joint Surgery*, 25:535-52. Accessed in 2011 (May 3), Available from: <<http://www.ejbs.org/cgi/content/abstract/25/3/535>>
- Campbell, WC & Boyd, HB. (1941). Fixation of onlay bone grafts by means of vitallium screws in the treatment of ununited fractures. *American Journal of Surgery*, Vol.51, (March 1941), pp. 748-56, ISSN 0002-9610.
- dos Reis, FB, Faloppa, F, Fernandes, HJ, Albertoni, WM & Stahel, PF. (2009). Outcome of diaphyseal forearm fracture-nonunions treated by autologous bone grafting and compression plating. *Annals of Surgical Innovation and Research*, Vol.3, No.5, (May 2009), ISSN 1750-1164.
- Gibson, A & Loadman, B. (1948). The bridging of bone defects. *The Journal of Bone and Joint Surgery. American Volume*, Vol.30A, No.2, (April 1948), pp. 381-96, ISSN 0021-9355.


- Haddad, RJ Jr & Drez, D. (1974). Salvage procedures for defects in the forearm bones. *Clinical Orthopaedics and Related Research*, No.104, (October 1974), pp. 183-90, ISSN 0009-921X.
- Ilizarov, GA, Kaplunov, AG, Degtiarev, VE & Lediaev, V. (1972). Lechenie lozhnykh sustavov i nesrosshikhsia perelomov, oslozhnennykh gnoinoi infektsiei, metodom kompressionno-distraktsionnogo osteosinteza [Treatment of pseudarthroses and ununited fractures, complicated by purulent infection, by the method of compression-distraction osteosynthesis]. *Ortopediia Traumatologia i Protezirovaniie*, Vol.33, No.11, (November 1972), pp. 10-4, ISSN 0030-5987.
- Ilizarov, GA. (1988). The principles of the Ilizarov method. *Bulletin of the Hospital for Joint Diseases Orthopaedic Institute*, Vol.48, No.1, (Spring 1988), pp. 1-11, ISSN 0883-9344.
- Ilizarov, GA. (1991). Asami Group- Classification and treatment of nonunion. In: *Operative principles of Ilizarov: fracture, treatment, nonunion, osteomyelitis, lengthening deformity correction*. Bianchi-Maiocchi, A, Aronson, J, Eds, pp. 190-8, Williams & Wilkins, ISBN 978-0683007503, Baltimore.
- Jupiter, JB & Rüedi, T. (1992). Intraoperative distraction in the treatment of complex nonunions of the radius. *The Journal of Hand Surgery*, Vol.17, No.3, (May 1992), pp. 416-22, ISSN 0363-5023.
- Masquelet, AC & Begue, T. (2010). The concept of induced membrane for reconstruction of long bone defects. *The Orthopedic Clinics of North America*, Vol.41, No.1, (January 2010), pp. 27-37, ISSN 0030-5898.
- Masquelet, AC, Fitoussi, F, Begue, T & Muller, GP. (2000). Reconstruction des os longs par membrane induite et autogreffe spongieuse [Reconstruction of the long bones by the induced membrane and spongy autograft]. *Annales de Chirurgie Plastique et Esthétique*, Vol.45, No.3, (June 2000), pp. 346-53, ISSN 0294-1260.
- Miller, RC & Phalen, GS. (1947). The repair of defects of the radius with fibular bone grafts. *The Journal of Bone Joint Surgery. American volume*, Vol.29, No.3, (July 1947), pp. 629-36, ISSN 0021-9355.
- Moroni, A, Rollo, G, Guzzardella, M & Zinghi, G. (1997) Surgical treatment of isolated forearm non-union with segmental bone loss. *Injury*, Vol.28, No.8, (October 1997), pp. 497-504, ISSN 0020-1383.
- Muller, ME, Allgöwer, M & Schneider, R. (1991). *Manual of internal fixation of fractures*, Springer-Verlag, ISBN 4-431-52523-8, New York.
- Müller, ME. (1965). Treatment of nonunions by compression. *Clinical Orthopaedics and Related Research*, Vol.43, (November-December 1965), pp. 83-92, ISSN 0009-921X.
- Nicoll, EA. (1956). Treatment of gaps in long bones by cancellous insert grafts. *The Journal of Bone and Joint Surgery. British volume*, Vol.38-B, No.1, (February 1956), pp. 70-82, ISSN 0301-620X.
- Nilsson, OS, Urist, MR, Dawson, EG, Schmalzried, TP & Finerman, GA. (1986). Bone repair induced by bone morphogenetic protein in ulnar defects in dogs. *The Journal of Bone and Joint Surgery. British volume*, Vol.68, No.4, (August 1986), pp. 635-42, ISSN 0301-620X.
- Orzechowski W, Morasiewicz L, Dragan S, Krawczyk A, Kulej M & Mazur T (2007). Treatment of non-union of the forearm using distraction-compression osteogenesis. *Ortopedia, Traumatologia, Rehabilitacja*, Vol.9, No.4, (July-August 2007), pp. 357-65, ISSN 1509-3492.

- Paley, D, Catagni, MA, Argnani, F, Villa, A, Benedetti, GB & Cattaneo, R. (1989). Ilizarov treatment of tibial nonunions with bone loss. *Clinical Orthopaedics and Related Research*, No.241, (April 1989), pp. 146-65, ISSN 0009-921X.
- Perren, SM, & Ito, K. (2009). Biologia e biomecânica na consolidação óssea. In: *Princípios AO do tratamento das fraturas*. Ruedi, TP, Buckley, RE, Moran, CG, Eds. PP. 33-56, Artmed, ISBN 9788536317502, São Paulo.
- Piotrowski, M, Baczkowski, B & Luczkiewicz, P. (2005). Zastosowanie litego przeszczepu korowo-gabczastego w leczeniu stawów rzekomych trzonu kości przedramienia [Application of block of corticocancellous graft in the treatment of forearm shaft nonunions]. *Chirurgia Narządów Ruchu i Ortopedia Polska*, Vol.70, No.1, pp. 45-7, ISSN 0009-479X.
- Rasmussen, SW, Bak, K & Tøholm, C. (1993). External compression of forearm nonunion. A report on 6 cases. *Acta Orthopaedica Scandinavica*, Vol.64, No.6, (December 1993), pp. 669-70, ISSN 0001-6470.
- Reis, FB. (2001). *Tratamento da pseudoartrose da diáfise dos ossos do antebraço com placa de compressão e enxertia óssea autóloga [Pseudoarthrosis treatment of the forearm shaft with compression plate and autogenous bone graft]* [Tese]. São Paulo: Universidade Federal de São Paulo. Escola Paulista de Medicina.
- Ring, D, Jupiter, JB, Sanders, RA, Quintero, J, Santoro, VM, Ganz, R & Marti, RK. (1997). Complex nonunion of fractures of the femoral shaft treated by wave-plate osteosynthesis. *The Journal of Bone Joint Surgery. British volume*, Vol.79, No.2, (March 1997), pp. 289-94, ISSN 0301-620X.
- Scaglietti, O, Stringa, G & Mizzau, M. (1965). Bone grafting in nonunion of the forearm. *Clinical Orthopaedics and Related Research*, Vol.43, (November-December 1965), pp. 65-76, ISSN 0009-921X.
- Schemitsch, EH & Richards, RR. (1992). The effect of malunion on functional outcome after plate fixation of fractures of both bones of the forearm in adults. *The Journal of Bone and Joint Surgery. American volume*, Vol.74, No.7, (August 1992), pp. 1068-78, ISSN 0021-9355.
- Scuderi, C. (1948). Restoration of long bone defects with massive bone grafts. *Journal of the American Medical Association*, Vol.137, No.13, (July 1948), pp. 1116-21, ISSN 0002-9955.
- Segmüller, G, Cech, O & Bekier, A. (1969). Die osteogene Aktivität im Bereich der Pseudarthrose langer Röhrenknochen [Osteogenic activity in the area of pseudoarthrosis of the long tubular bones]. *Zeitschrift für Orthopädie und Ihre Grenzgebiete*, Vol.106, No.3, (July 1969), pp. 599-609, ISSN 0044-3220.
- Spira, E. (1954). Bridging of bone defects in the forearm with iliac graft combined with intramedullary nailing. *The Journal of Bone and Joint Surgery. British volume*, Vol.36-B, No.4, (November 1954):642-6, ISSN 0301-620X.
- Tydings, JD, Martino, LJ, Kircher, M, Alfred, R & Lozman, J. (1986). The osteoinductive potential of intramedullary canal bone reamings. *Current Surgery*, Vol.43, No.2, (March-April, 1986), pp. 121-4, ISSN 0149-7944.
- Weber, BG & Cech, O. (1976). *Pseudoarthrosis*. Bern, ISBN 9783456801957, Hans Huber Publishers.

- Wei, FC, Chen, HC, Chuang, CC & Noordhoff, MS. (1986) Fibular osteoseptocutaneous flap: anatomic study and clinical application. *Plastic and Reconstructive Surgery*, Vol.78, No.2, (August 1986), pp. 191-200, ISSN 0032-1052.
- Weiland, AJ, Kleinert, HE, Kutz, JE & Daniel, RK. (1979). Free vascularized bone grafts in surgery of the upper extremity. *The Journal of Hand Surgery*, Vol.4, No.2, (March 1979), pp. 129-44, ISSN 0363-5023.

IntechOpen

IntechOpen



## **Bone Grafting**

Edited by Dr Alessandro Zorzi

ISBN 978-953-51-0324-0

Hard cover, 214 pages

**Publisher** InTech

**Published online** 21, March, 2012

**Published in print edition** March, 2012

Bone grafting is the surgical procedure in which new bone (bone graft) or a replacement material (graft substitute), is placed into bone fractures or bone defects to aid in healing. Bone grafting is in the field of interest of many surgical specialties, such as: orthopedics, neurosurgery, dentistry, plastic surgery, head and neck surgery, otolaryngology and others. In common, all these specialties have to handle problems concerning the lack of bone tissue or impaired fracture healing. There is a myriad of surgical techniques nowadays involving some kind of bone graft or bone graft substitute. This book gathers authors from different continents, with different points of view and different experiences with bone grafting. Leading researchers of Asia, America and Europe have contributed as authors. In this book, the reader can find chapters from the ones on basic principles, devoted to students, to the ones on research results and description of new techniques, experts will find very beneficial.

### **How to reference**

In order to correctly reference this scholarly work, feel free to copy and paste the following:

Fernando Baldy dos Reis and Jean Klay Santos Machado (2012). Bone Grafting in Malunited Fractures, Bone Grafting, Dr Alessandro Zorzi (Ed.), ISBN: 978-953-51-0324-0, InTech, Available from:  
<http://www.intechopen.com/books/bone-grafting/bone-grafting-in-malunited-fractures>

**INTECH**  
open science | open minds

### **InTech Europe**

University Campus STeP Ri  
Slavka Krautzeka 83/A  
51000 Rijeka, Croatia  
Phone: +385 (51) 770 447  
Fax: +385 (51) 686 166  
[www.intechopen.com](http://www.intechopen.com)

### **InTech China**

Unit 405, Office Block, Hotel Equatorial Shanghai  
No.65, Yan An Road (West), Shanghai, 200040, China  
中国上海市延安西路65号上海国际贵都大饭店办公楼405单元  
Phone: +86-21-62489820  
Fax: +86-21-62489821



© 2012 The Author(s). Licensee IntechOpen. This is an open access article distributed under the terms of the [Creative Commons Attribution 3.0 License](#), which permits unrestricted use, distribution, and reproduction in any medium, provided the original work is properly cited.

IntechOpen

IntechOpen