

We are IntechOpen, the world's leading publisher of Open Access books Built by scientists, for scientists

4,800

Open access books available

122,000

International authors and editors

135M

Downloads

Our authors are among the

154

Countries delivered to

TOP 1%

most cited scientists

12.2%

Contributors from top 500 universities



WEB OF SCIENCE™

Selection of our books indexed in the Book Citation Index
in Web of Science™ Core Collection (BKCI)

Interested in publishing with us?
Contact book.department@intechopen.com

Numbers displayed above are based on latest data collected.
For more information visit www.intechopen.com



Neonatal Lupus Erythematosus (NLE)

Hanan Al-Osaimi and Suvarnaraju Yelamanchili

King Fahd Armed Forces Hospital, Jeddah

Saudi Arabia

1. Introduction

Neonatal lupus erythematosus (NLE) or neonatal lupus syndrome (NLS) is a rare syndrome seen in 1-2% of neonates with auto-antibodies to SSA/Ro, SSB/La and or U1 RNP, passively transferred transplacentally from the mother who is either asymptomatic or having manifestations of Sjogren's syndrome, SLE or other systemic rheumatic disease, characterized by cutaneous, cardiac or rarely both clinical manifestations.

The skin manifestations are seen at least in 30% of these patients, in the form of periorbital annular erythematous plaques later spreading to other areas of face, scalp, trunk and extremities which is non-scarring and non-atrophic. This is usually transient lasting for days to months. But, the cardiac manifestations are seen in up to 60% of the patients is mainly in the form of complete congenital heart block (CHB) which is irreversible and is associate with cardiomyopathy in at least 10% of the cases. Cardiomyopathy is associated with increased morbidity and mortality. Almost all the patients having cardiac lupus require permanent pacemaker. The recurrence rate of neonatal lupus is as much as 25% in the subsequent pregnancies. There has been better understanding of aetiopathogenesis of the disease which is due to the rapid advances in field of medicine [Buyon, 2001, 2007].

2. Historical aspects

The first case reported by Aylward in 1928, who described two siblings with CHB born to a mother who had Sjogren's syndrome. Plant & Stevens described CHB as a manifestation of NLE in 1945 [Plant, 1945]. But the first report linking autoimmune disease in mother with cutaneous lupus was McCuiston and Schoch in 1954. In 1957 Hogg noted the possible relation between autoimmune disease of the mother and congenital heart block in her child. Finally in 1980 Weston reported the association of neonatal lupus (NLE) with maternal anti-Ro auto- antibodies [Lee LA, 1997].

The term, neonatal lupus erythematosus (NLE) has been challenged, because although cutaneous lupus resembles subacute cutaneous adult lupus, the cardiac manifestation of CHB is not seen in the adult lupus. So a better term could have been "Neonatal anti-Ro antibody associated disease", but the disease has become so popular with the name of neonatal lupus erythematosus (NLE). It is also called as Neonatal lupus syndrome (NLS) due to protean clinical manifestations of the disease.

3. Epidemiology

The prevalence of Anti-SSA antibodies in women is 1:200 while the incidence of neonatal lupus is only 1 in 20,000 live births [Neiman, 2000]. And less than 1:50 of women with anti-SSA antibodies will have child with CHB. Only 1-2% of the infants of mothers with anti-SSA/Ro with or without anti-SSB/La antibodies develop neonatal lupus, although it ranges from 0.6% to 25% with an average of 7.2% by various studies. The incidence increases to 3% if the mother has anti-La antibodies in addition to anti-Ra antibodies.

If the mother has also SLE along with anti-SSA antibodies the incidence of NLE may be up to 6-13%. This is much higher and reaches up to 25% if the mother already had a child with NLE. 15-20% present as CHB and 6% present as cutaneous lupus. A recent study reported that the overall recurrence rate for any manifestation of NLE was 49% out of which 18.2% were complicated by cardiac NLE, 29.9% by cutaneous NLE, and 1.3% by hematologic/hepatic NLE. On follow up studies it was found that there were no significant differences in the maternal risk factors for having a subsequent child with either cardiac or cutaneous NLE [Izmirly, 2010].

The incidence of CHB is seen in 50-60% while the cutaneous lupus is seen in 25-30% and the combination of cutaneous and cardiac manifestations seen only in 4-10% of the patients with NLE [Eronen, 2000]. The incidence of cutaneous lupus may be higher but under reported as the rash is transient and may not be noticed at times and these neonates are usually asymptomatic. The antibody titers are three fold higher for cardiac lupus as compared to cutaneous lupus.

Race: No racial predilection has been observed. However, NLE appears to be more common in African Americans, Latin Americans, and Asian children. So it is more common in non-white than white population (3:1).

Sex: Girls are affected more often than boys (2:1) and the cutaneous lupus is much more common in girls (3:1), whereas cardiac lupus is seen in equal ratio in males and females while anti-RNP neonatal cutaneous lupus is seen mainly in males [Jaeggie, 2010].

During a 20 year follow-up study of asymptomatic mothers with NLE, 50-60% of them have developed rheumatologic disease in the form of SLE, Sjogren's or undifferentiated connective tissue disease approximately in the ratio of 1:2:2. The incidence of rheumatologic disease is more in cutaneous lupus (up to 70%) and the incidence of Sjogren's disease is more common in mothers having infants with CHB than cutaneous lupus [Waltuck, 1994]. The overall risk of a woman with SLE having a child with CHB is 1:60 and it increases to 1:20 in presence of anti-SSA/Ra antibodies [Watson, 1986].

The prevalence of anti-SSA/Ro antibodies in general population (pregnant & non-pregnant) ranges from 1-10% and its average prevalence in SLE patients is up to 50%. The prevalence of anti-SSB/La antibodies in SLE is less than anti-SSA/Ro (15-20%) and usually associated with anti-SSA/Ro in 90% of cases. Rarely anti-SSB/La or anti-U1 RNP can be present without anti-SSA/Ro which may rarely cause cutaneous lupus [Singsen, 1986; Goldsmith, 1989].

4. Pathophysiology

NLE is presumed to result from trans-placental passage of maternal anti-SSA/Ro and/or anti-SSB/La auto-antibodies. The precise mechanism of injury to specific tissues, such as the skin and heart, is not known. The pathogenesis of disease probably involves more than simple trans-placental passage of antibodies because:

- The disease itself is very rare.
- The mothers who have these auto antibodies, half of them are asymptomatic.
- There is discordance of disease even in monozygotic twins.
- And finally the anti-Ro/SSA and anti-La/SSB are associated with a variety of clinical syndromes in adults.

4.1 Pathogenesis of CHB in NLE

The trans-placental passive transfer of IgG auto antibodies is the initiating factor. The auto antibodies are usually anti-SSA/Ro against usually 52kD or 60kD protein or anti-SSB/La against 48kD protein or rarely anti-U1RNP antibodies and the incidence for these antibodies in the mother for CHB and CNL (cutaneous neonatal lupus) is 100 and 91% for anti-SSA and 91 and 73% for anti-SSB and the incidence in the mother without NLE is only 47 and 15% respectively, strengthening the role of these antibodies in the pathogenesis. Anti-52 kD component of anti-SSA/Ro for a particular peptide fragment p200-239 has greatest risk for CHB than to p177-196, the later seen in unaffected children [Clansy, 2005].

Other autoantibody specificities reported to be associated with neonatal lupus include antibodies to calreticulin, a 57 kD protein, a 75-kD phosphoprotein, α -fodrin, the neonatal heart M1 muscarinic acetylcholine receptor, and the serotonergic 5-HT₄ receptor [Sontheimer,1996; Maddison 1995; Wang,1999; Miyagawa,1998; Borda, 2001; Eftekhari,2001]. Ro- and La-specific IgA and IgM antibodies were detected in the serum from a subset of mothers. However, Ro- and La-specific IgA and IgM antibody levels were low or non-detectable in children raised with or without breastfeeding [Klauinger, 2009]. This supports the role of transplacental passively transferred maternal antibodies than fetal antibodies in pathogenesis.

These auto antibodies later enter the myocardial cell causing exaggerated apoptosis which leads to expression of the antibodies on the surface of the cardiocyte. These results suggest that resident cardiocyte participate in physiologic clearance of apoptotic cardiocyte, but that clearance is inhibited by opsonization via maternal auto- antibodies, resulting in accumulation of apoptotic cells promoting inflammation, stimulating macrophages which secretes cytokines mainly, transforming growth factor-beta (TGF- β), that stimulates fibroblast proliferation later on leading to fibrosis of the conduction system (causing CHB) or myocardium (leading to cardiomyopathy or Endocardial fibroelastosis) or both as shown in Fig.1.

Histopathology of the affected heart shows fibrosis and calcification of the atrioventricular nodal region and replacement of that region with fibrous tissue explaining the irreversibility of the heart block in most patients [Lee LA, 1997]. Infants exposed to low titers of anti-SSB/La or anti-U1 RNP were more likely to have non-cardiac manifestations of neonatal lupus or only cutaneous lupus while the antibody titers are at least three-fold higher in cardiac than cutaneous lupus [Jaeggie, 2010].

In addition to inducing tissue damage, anti-SSA/Ro and/or anti-SSB/La antibodies inhibit calcium channel activation or the cardiac L- and T-type calcium channels themselves. L-type channels are crucial to action potential propagation and conduction in the AV node [Xiao GQ, 2001; Silverman, 1995].

Very few neonates who have maternal antibodies develop neonatal lupus. Therefore factors other than attachment of the antibodies to the target antigens to be considered like fetal, uterine, viral and genetic factors.

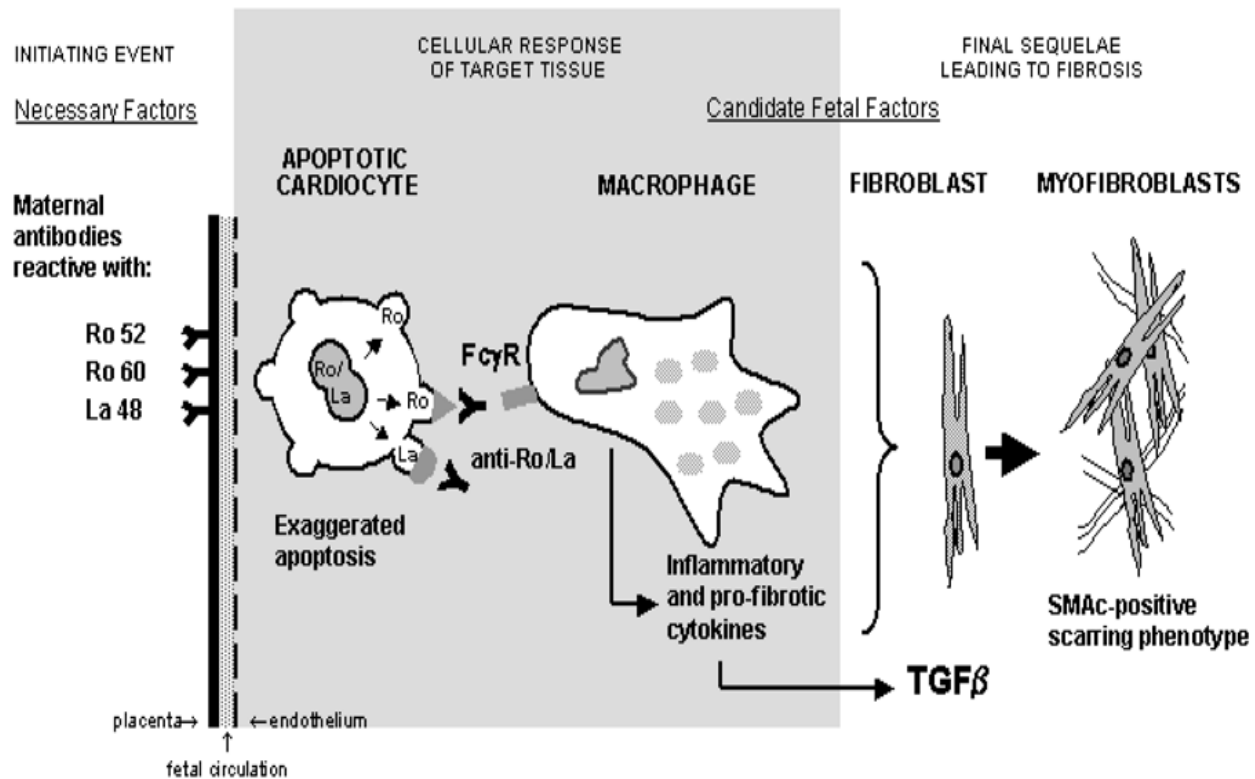


Fig. 1. Proposed pathologic cascade (Buyon, 2004)

(This leads from inflammation to fibrosis whereby maternal antibodies initiate events that lead to a persistent myofibroblasts, a phenotype associated with scarring. Apoptosis of cardiocyte results in the surface expression of SSA/Ro and SSB/La components, subsequent opsonization by cognate antibodies, and the secretion by macrophages of cytokines (e.g., TGF- β) which modulate fibroblasts into scar promoting myofibroblasts)

Genetic factors in particular the HLA alleles DR3, B8, DQw2 and DRw52 and a polymorphism in the promoter region of the gene for tumor necrosis factor alpha (-308A, associated with higher TNF- α production) may play a role at least in cutaneous lupus.

There are many questions that still remain. Why only few develop the disease while many do not develop? Why do some babies develop skin disease, others develop heart disease, and very few develop both? Studies from the laboratory failed to show differences between auto-antibodies from mothers who had babies with skin disease and auto-antibodies from mothers who had babies with cardiac disease. The sera were not different with regard to IgG antibody subclass, immunoblotting patterns against skin and heart extracts, and immuno-precipitation of Ro-associated hY RNAs. The only significant difference noted was, the lower titers of maternal anti-Ro60 in the skin disease subset, but the reason for that difference is also not clear [Lee LA, 1994, 1996; Bennion, 1990].

Again the discordance in the homozygotic twins goes against the genetic factors playing a major role in NLE. Post mortem studies in the neonates revealed deposition of IgG1 & IgG3 along with complement (including C1q, C4, C3d, C6, and C9), and fibrin [6. Silverman, 1995; Salomonsson 2002] leading initially to pancarditis and later on to fibroelastosis of the heart. Thus it can involve almost all the structures of the heart. So fibrosis starts near the AV nodal region and extends to the other regions of the heart. As the process of inflammation starts

mainly in the second trimester, when the organogenesis is complete, structural defects in the heart are rare.

It was also noticed that there is reduction of the protective molecules like the complement regulatory proteins (decay accelerating factor (DAF, CD55), protectin (CD59), and membrane cofactor protein (MCP, CD46) which predispose complement-mediated damage to the heart [Clancy, 2006; Miranda, 2000].

Some observational studies in monozygotic twins and triplets need clarification. Some neonates are affected while others are not affected. Even in the affected neonates each one will have different type of manifestations, regardless of them sharing a common placenta or not [Botard, 2000; Shimosegawa, 1997; Yazici, 2000]. Many studies revealed that type 1 interferon pathway is not involved in NLE pathogenesis [Niewold, 2002, 2008].

All the above indicate that the maternal antibodies to SSA/Ro and SSB/La recognize their respective antigens in the immature cardiac conduction system and the fetal myocardium, gain access perhaps through apoptosis, causing in utero an inflammatory reaction of the conduction system and endo-myocardium, resulting in fibrosis of the conduction system with heart block and myocarditis.

4.2 Pathogenesis of cutaneous lupus

The same maternal antibodies recognize the antigens present in the neonatal skin exposed to UV light and high estradiol concentrations and cause the cutaneous manifestations of NLE. And the cutaneous lupus is due to deposition of anti-Ro IgG auto-antibodies throughout the epidermis and not the epidermo-dermal junction or dermis, which is seen even in the unaffected areas of skin. Probably deposition of antibodies in the affected organ is not leaving enough antibodies to be deposited in other organs to cause disease manifestations. And it is not known whether this could be the reason why usually only one organ is involved in one patient and other in another patient in neonatal lupus.

At this time, although there is compelling evidence that maternal auto-antibodies are a major factor in the genesis of disease, the factors that determine which child will be affected and which organs will be affected are largely unknown. These factors should be predictable so that one day it may be possible to identify the fetus at high risk, particularly for heart blocks, and target that particular fetus for prevention or effective treatment [Izmirly, 2007].

5. Patient history

The mother usually discovers her affected child either has skin rash shortly after birth or that her infant is highly sensitive to sunlight (intense photosensitivity). Mothers may be asymptomatic or have symptoms of lupus erythematosus, Sjogren's syndrome or undifferentiated CTD. When carefully questioned, they may report dry eyes, arthralgias, myalgias, or arthritis. A recent report linked the presence of hypothyroidism in mothers with anti-SSA/Ro with an increased risk of CHB. Cardiac involvement can be revealed in ultrasound exam of fetus from routine antenatal check-up from 20-24 weeks gestation in the form of bradycardia which may suggest cardiac lupus (CHB) or by physical exam at birth.

6. Clinical manifestations

A fetus/newborn can have either cutaneous or cardiac or both as the major manifestations of NLE. Cardiac manifestations usually occur at 18 to 24 weeks gestation. The rash is often present at birth, but can appear up to four months of age.

The commonest manifestation, CHB, is seen in 61%, cutaneous manifestations in 26.9% both cardiac & cutaneous manifestations in 8.7% and hepatic or hematological involvement in 3.2% but the recent literature shows that cutaneous, cardiac, hepatobiliary, and hematological involvement was found in 70.6%, 64.7%, 52.9%, and 35.3% of infants respectively with a mortality of 11.8% in 64.7% of asymptomatic mothers in recent literature [Wisuthsarewong, 2011]. NLE can also involve liver (6.2%), blood (5.2%), CNS (0.8%), lung (0.8%) and kidney (0.4%). It is usually common to see NLE with affection of one organ, although involvement of multiple organs can occur [Buyon, 2001].

6.1 Neonatal cutaneous lupus

This is seen in 15-30% of neonatal lupus and the incidence may be higher than this as it may be under reported because the skin rash is transient and majority of their mothers are usually asymptomatic. It is more common in female (3:1) than male neonates.

Cutaneous findings in neonatal lupus erythematosus [Wisuthsarewong, 2011]

- Annular erythematous plaques with a small scales characterize neonatal lupus erythematosus. Atrophic lesions may develop; however, over time, even these lesions leave little residual change. These lesions are usually not present at birth but may become evident shortly afterward, particularly in infants exposed to light therapy [Figure 2].

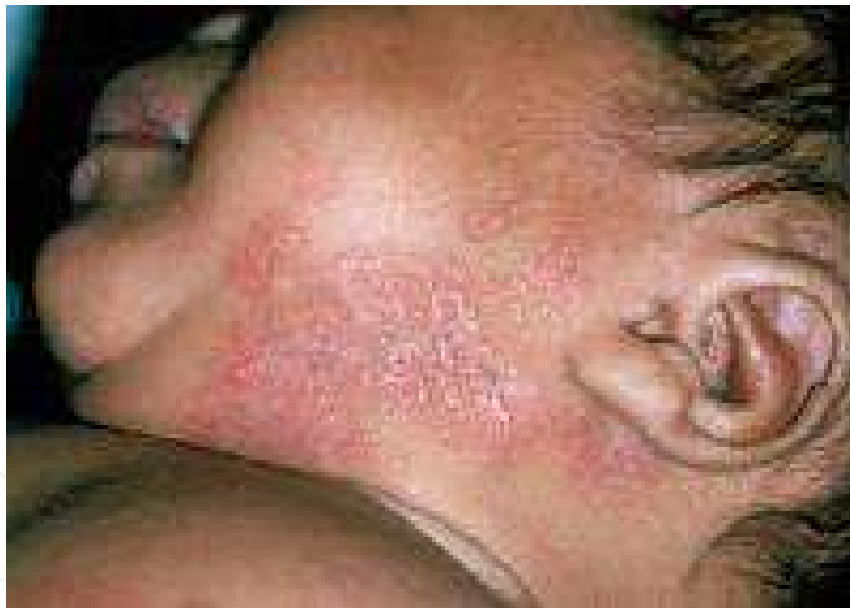

Fig. 2. Neonatal cutaneous lupus erythematosus

- These skin lesions are usually non-scarring and non-atrophic.
- The lesions are mainly seen on the face, scalp, trunk and extremities. The lesions are very dense in the periorbital area which gives an “eye-mask” or “owl-eye appearance” (with ice-pick lesions located to the superior aspect of face, lateral edges of eyes, spreading into the temple regions bilaterally). Mild erythema on the face was observed at birth.
- An erythematosus raccoon-like patch began to develop on the face following sun exposure.

- It becomes plaque like and develop scaling and desquamation
- Intense photosensitivity is another striking feature in neonatal cutaneous lupus.
- Telangiectasia is often prominent and is the sole cutaneous manifestation reported in some patients, sometimes to the extent of forming muco-cutaneous and visceral hemangiomas [Spalding, 2007].
- Dyspigmentation is frequent, but, with time, this change spontaneously resolves. It may last as long as one year.
- Although histology is typical but it is not needed in most cases due to characteristic appearance of rash in the presence of auto-antibodies [Lee LA, 1993].

The lesional histology supports the clinical descriptions of sub acute cutaneous lupus with basal cell damage in the epidermis and a superficial mononuclear cell infiltrate in the upper dermis. As observed in sub acute cutaneous lupus, immunofluorescence is positive with the finding of a particulate pattern of IgG in the epidermis. The histopathology of the erythematous-desquamative lesions more closely resembles that of sub acute cutaneous lupus erythematosus (SCLÉ) than discoid lupus. Typical findings are vacuolar alterations at the dermo-epidermal interface and adnexal structures.

Some patients present with urticaria-like lesions that have superficial and deep perivascular and periadnexal lymphocytic infiltrates [Silverman, 2010, Penate, 2009]. The identification of cutaneous NL in an anti-SSA/Ro antibody-exposed infant is particularly important, since it predicts a 6-10-fold risk of a subsequent child developing cardiac NL [Izmirly, 2010].

6.2 Neonatal cardiac lupus

The commonest cardiac manifestation of neonatal lupus is congenital complete heart block and the next one is cardiomyopathy with or without heart failure. There are other rare cardiac manifestations that may be seen [Table 1).

6.2.1 Congenital complete heart block (CHB)

The most dangerous and life threatening cardiac manifestation of NLE is complete heart block (CHB) which is more common in female neonates (3:1) and usually appear in fetus from 20-24 weeks of gestation by fetal ultrasound exam and in 90% of cases it is seen by birth. It is mainly due to the anti-SSA/Ro with or without anti-SSB/La antibodies. Anti-SSB/La and anti-U1 RNP alone are not associated with cardiac lupus. It is seen in 62% cases of NLE as against 31% of cases with cutaneous lupus and together with cutaneous lupus it is seen only in 4% of cases. CHB is usually detected by fetal US exam as fetal bradycardia (40-80 beats/min) [Brucato, 1995, 2007; Agarwala, 1996]. NLE is responsible for 90-95% of CHB presenting in utero and only 5% of cases of CHB after birth. The incidence of CHB in the general population varies between 1 in 15,000 to 1 in 22,000 live-born infants [Michaëlsson, 1972].

Presentation in the neonate:

- Bradycardia
- Intermittent cannon waves in the neck,
- First heart sound that varies in intensity,
- Intermittent gallops and murmurs.
- The newborn at greatest risk has a rapid atrial rate, often 150 beats/min or faster, and a ventricular rate less than 50 beats/min. With junctional or atrioventricular (AV) nodal escape or ectopic rhythm

- First or second degree heart block found in infants at birth can progress to complete heart block [Jaggie, 2002].

It may take just one week for a neonate to develop CHB from a normal PR interval, so weekly fetal echo is very important between 16-24wks.

Presentation in the childhood:

Only 60% present before six years as the ventricular rate is adequate from the junctional release rhythm so they become symptomatic later in their life and the CHB is usually intermittent initially before becoming persistent. They are usually picked up for slow pulse which is not symptomatic. Some patients present with bradycardia-related symptoms like

- Reduced exercise tolerance and
- Pre-syncope or syncope (Stokes-Adams attacks) -26%
- Sudden death has also been described -6%

The sinoatrial (SA) node also may be involved and sinus bradycardia has been described in 3.8 percent of fetuses but is usually not permanent.

Other types of electrical disturbances can be there as reported in the table 1. There are host of other cardiac manifestations which are not that common.

Electrical	Mechanical	Structural
CHB II° Heart block I° Heart block RBBB Sinus bradycardia Stokes-Adams attacks Prolonged QT interval (sudden death)	Cardiomyopathy CHF Hydrops fetalis CHB with structural heart disease Libman-Sack's verrucous endocarditis Myopericarditis. Endocardial fibroelastosis (EFE) Valvular lesions (rare) Intramyocardial Vasculopathy 2° to APS	ASD PDA VSD Patent foramen ovale Pulmonary stenosis Pulmonary regurgitation Coarctation of Aorta Tetrology of Fallot Hypoplastic RV Anomalous Pulmonary Venous Drainage PV dysplasia, Fusion of chordae tendineae of the valves, causing MR & TR

Table 1. Cardiac disorders reported in neonatal cardiac lupus (Data adopted from Buyon et al, 1998, 2007, Hornberger, 2010].

6.2.2 Cardiomyopathy/ CHF/ hydrops fetalis

This is the second most common cardiac abnormality commonly in the presence of CHB but can occur rarely in the absence of CHB. It may be due to various reasons. It may be due to the extension of fibrotic process into the myocardium causing myocardial fibrosis and CHF or it may be due to compensatory ventricular dilatation to increase the stroke volume due to bradyarrhythmia or it can also be due to the ventricular asynchrony due to right ventricular pacing alone. It is seen in 10% of cases and the mortality is higher in the neonates presented early with CHB than presenting after birth. CHF is rarely seen in CHB presenting after birth.

Structural heart disease has been reported occasionally in association with NLE. However, caution is needed in interpreting such reports because the inflammatory fibrosis of conduction system occurs usually after the organogenesis is complete (after first trimester) and some structural abnormalities may cause heart block per se (e.g., L-transposition of the great vessels with a single ventricle, ostium primum type atrial septal defect, and rarely ventricular septal defects). Out of all these anomalies, only VSD has been reported in association with NLE. The commonest among these are ASD, PDA and VSD [Buyon, 1998; Falcini, 1998; Houssiau, 1986].

Other congenital structural cardiac anomalies have also been observed in association with NLE (persistent patent ductus arteriosus, patent foramen ovale, pulmonary stenosis, pulmonary regurgitation, coarctation of aorta, tetralogy of Fallot, hypoplastic right ventricle, anomalous pulmonary venous drainage, pulmonary valvular dysplasia, fusion of chordae tendinae of the tricuspid valve, TR, MR, and ostium secundum type atrial septal defects [Table 1].

NLE with CHB has been associated with endocardial fibroelastosis (EFE). In a report of 13 affected children, seven had EFE at presentation (four fetal and three postnatal), and six developed EFE weeks to as long as five years after the diagnosis of complete heart block. Eleven either died or underwent cardiac transplantation because of the EFE. EFE has also been reported in the absence of a conduction defect in infants with maternal anti-Ro and anti-La antibodies [Nield, 2002].

6.3 Hematological manifestations

They are commonly asymptomatic in the form of thrombocytopenia (frequently associated with splenomegaly), anemia (Coombs-positive hemolytic anemia or microangiopathic hemolytic anemia), leucopenia, neutropenia (in up to 25% of NLE) and rarely aplastic anemia. The thrombocytopenia and anemia very rarely can be so severe requiring blood transfusions and steroid therapy. Lymphopenia, which is commonly seen in adult lupus, is not usually seen in neonatal lupus [Wolach, 1993].

6.4 Hepatic and gastrointestinal manifestations

They are seen in 10-25%. Three types of liver manifestations were observed. Liver failure, with histological features of neonatal iron storage disease, occurring in utero or shortly after birth and resulting in fatality; cholestasis with conjugated hyperbilirubinemia and minimal transaminase elevations occurring a few weeks after birth and eventually resolving; and mild or moderate transaminase elevations occurring a few weeks or months after birth and resolving. Rarely patients can have cirrhosis and gastrointestinal hemorrhage. The pathology resembles idiopathic neonatal giant cell hepatitis [Silverman, 2010; Izmirlly, 2010].

6.5 Neurological manifestations

They are seen in less than 1% of patients in the form of myelopathy, aseptic meningitis, seizures with or without hypocalcaemia, myasthenia gravis (transient) [Kaye, 1987], hydrocephalus, microcephaly, macrocephaly, non-specific white matter changes, calcification of basal ganglia, vasculopathy and neuropsychiatric dysfunction/attention deficient disorders [Boros, 2007].

6.6 Other rare manifestations

They can be in the form of pulmonary (Pneumonia), renal (nephritis or nephritic syndrome), bony (chondrodysplasia punctata) [Silverman, 2010] or multiple thrombosis due to maternal cardiolipin antibodies [Tabbut, 1994].

The NLE occurring in the subsequent pregnancies after a lupus child is up to 36%, out of which 12.8% were complicated by cardiac NL and 23.1% by cutaneous NLE. There were no significant differences in the following maternal risk factors for having a subsequent child with cardiac or cutaneous NLE: age, race, ethnicity, anti-SSB/La status, diagnosis, use of non-fluorinated steroids, or breastfeeding. The sex of the subsequent fetus did not influence the development of cardiac or cutaneous NL [Izmirly, 2010].

The manifestation of anti-RNP positive is a rare occurrence. It was noted that infants affected with NLE from anti-RNP antibodies developed only cutaneous lesions and were all male [Boh, 2004].

The transient hematologic abnormalities and skin disease of the neonate reflect the effect of passively acquired auto- antibodies on those organ systems that have the capacity of continual regeneration, in contrast to the heart, which apparently lacks this capability, because, to date, third-degree heart block is irreversible [Buyon, 2007].

7. Diagnosis

The diagnosis of NLE is made when a fetus or newborn of a mother with anti-SSA/Ro and/or anti-SSB/La, or anti-RNP, antibodies develops heart block and/or the typical rash, hepatic or hematologic manifestations, in the absence of other causes. The following recommendations for prenatal screening and postnatal diagnosis are based upon the potential cardiac manifestations of neonatal lupus (NLE) and their associated morbidity and mortality.

7.1 Prenatal screening (antibodies)

Prenatal screening for anti-SSA/Ro and anti-SSB/La antibodies is warranted for women who are known to be at risk of having a pregnancy complicated by NLE. Women who are more likely to have anti-SSA/Ro and anti-SSB/La antibodies include those with lupus, Sjogren's syndrome, an undifferentiated autoimmune disease, or NLE in a previous pregnancy. Women with these identifiable risk factors should be tested before conception or early pregnancy as soon as possible.

7.2 Intra-natal diagnosis

CHB in an offspring can be the first sign in the mother that has anti-SSA/Ro and anti-SSB/La antibodies. These antibodies are not part of routine prenatal testing in asymptomatic women.

7.2.1 Fetal echocardiography

Women who test positive for SSA/Ro and SSB/La auto antibodies may benefit from more intense assessment for fetal heart block with frequent fetal echocardiographic testing during pregnancy. There are no formal guidelines for the type or the frequency of testing to detect fetal heart block, but performing weekly pulsed Doppler fetal echocardiography from the 16th through the 26th week of pregnancy and then every other week until 32 weeks should

be strongly considered. The most vulnerable period for the fetus is during the period from 18 to 24 weeks gestation. Normal sinus rhythm can progress to complete block in seven days during this high-risk period. New onset of heart block is less likely from 26 to 30 weeks, and it rarely develops after 30 weeks of pregnancy.

7.2.2 Pulsed Doppler echocardiography

Less-advanced degrees of heart block can be detected in utero by this technique [Glickstein, 2000]. And it depends upon measurement of the mechanical PR interval as determined from the onset of atrial contraction (initiation of mitral valve movement) to ventricular contraction (aortic pulsation). It is generally accepted that women with low titer antibodies are less likely to have offspring with cardiac NLE than women with high titers. The problem is that laboratories have different cutoff values and most women with these antibodies have high titers.

7.2.3 Fetal auscultation (fetoscope) / fetal ultrasound

Complete heart block (and usually second-degree block) results in fetal bradycardia that can be detected by even routine fetal auscultation or ultrasonography (sonogram). The use of echocardiographic monitoring may present a way to more selective use interventions to prevent or reverse the development of more advanced heart block. Fetal monitoring may include a biophysical profile and non-stress test [Vesel, 2004; Sonesson, 2004].

7.2.4 Biophysical profile

A biophysical profile (BPP) score is calculated to assess the fetus' health. It consists of five components which include non-stress testing and ultrasound measurement of four fetal parameters: fetal body movements, breathing movements, fetal tone (flexion and extension of an arm, leg, or the spine) and measurement of the amniotic fluid levels. Each component is scored individually, with two points given for a normal result and zero points given for an abnormal result. The maximum possible score is 10. The amniotic fluid level is an important variable in the BPP because a low volume (called oligohydramnios) may increase the risk of umbilical cord compression and may be a sign of changes in the blood flow between the baby and mother. Amniotic fluid levels can become reduced within a short time period, even a few days.

7.2.5 Non-stress testing

Non-stress testing is done by monitoring the baby's heart rate with a small device that is placed on the mother's abdomen. The device uses sound waves (ultrasound) to measure the baby's heart rate over time, usually for 20 to 30 minutes. Normally, the baby's baseline heart rate should be between 110 and 160 beats per minute and should increase above its baseline by at least 15 beats per minute for 15 seconds when the baby moves. The test is considered reassuring (called "reactive") if two or more fetal heart rate increases are seen within a 20 minute period. Further testing may be needed if these increases are not observed after monitoring for 40 minutes.

7.3 Postnatal diagnosis

Testing for maternal anti-SSA/Ro antibodies should be performed in any neonate with heart block, because these antibodies account for 80 to 95 percent of reported cases of CHB in the

fetus and neonate. Infants up to eight months of age with an annular or polycyclic rash and/or any degree of heart block should be tested for anti-SSA/Ro and anti-SSB/La antibodies. A positive test in the child or mother fulfills the diagnostic criteria for NLE [Buyon, 2001, Jaeggi, 2002, Johansen, 1998].

An infant diagnosed with NLE who has compatible clinical manifestations and detectable auto antibodies (i.e., anti-SSA/Ro and/or anti-SSB/La in the mother or infant), but no electrocardiographic evidence of heart block of any degree at birth, is at very low risk of subsequently developing conducting system disease. However, there have been rare cases of isolated cardiomyopathy reported.

8. Differential diagnosis

8.1 Differential diagnosis of cutaneous neonatal lupus

Polycyclic Skin Lesions	Isolated Annular Erythematosus
Urticaria Erythema marginatum Tinea Seborrheic dermatitis Ichthyosiform genodermatosis	Erythema annulare centrifugum Familial annular erythema Erythema multiforme Infantile epidermodysplastic erythema Pityrosporum (Malassezia species) dermal infection Annular erythema of infancy Erythema gyratum atrophicans

Table 2. Differential diagnosis of cutaneous neonatal lupus
(Data adopted from Lee LA, 1997)

The differential diagnosis includes various rashes seen in the newborn period. These other rashes are not associated with maternal anti-SSA/Ro, anti-SSB/La, or anti-RNP antibodies or with congenital heart block [Table 2].

8.2 Differential diagnosis of cardiac neonatal lupus

Differential diagnosis of congenital CHB [Jaeggi et al, 2002]

Although neonatal lupus is responsible for 95% of congenital CHB in neonate but it is a cause for CHB after birth in only 5% of the children. The other causes of CHB are:

- Myocarditis
- Various structural cardiac defects
- Congenitally corrected transposition of the great arteries,
- Atrioventricular discordance,
- Polysplenia with atrioventricular canal defect.
- Several hereditary disorders

In complicated congenital lesions such as transposition of great vessels it is difficult to say whether it is due to NLE or due to the cardiac defect itself.

The patients who present with congenital CHB can be differentiated from other causes of CHB by early presentation (20-24wks of gestation) as fetal bradycardia and/or fetal PR interval and may have additional structural cardiac abnormalities commonest being VSD & endocardial fibroelastosis along with presence of antibodies to SSA/SSB. They may also

have complications due to CHB like hydrops fetalis, endocardial fibroelastosis, pericardial effusion, and spontaneous intrauterine fetal death.

9. Treatment

9.1 Treatment of congenital heart block

Prenatal testing for anti-SSA/Ro and anti-SSB/La antibodies is being done only in high risk women, like women with SLE, Sjogren's syndrome, or other systemic rheumatic diseases (UCTD or UAS) and previous child with NLE where the risk is up to 25%. Careful monitoring during gestation with fetal ultrasound and echocardiography from 16th week of pregnancy is to be done. The best treatment for CHB is prevention as once CHB is diagnosed medical treatment seems to be unsuccessful. Testing for candidate antibodies is important prior to initiating therapy for a presumed case of neonatal cardiac lupus, because there are cases of heart block not associated with anti-SSA/Ro and SSB/La antibodies.

9.1.1 Preventive therapy

As the incidence of congenital heart block is only 2% in the offspring of unselected anti-Ro antibody positive mothers the preventative therapy cannot be advocated for this group.

However, in women with a previous child with congenital heart block the risk is greater, in the region of 17–19%. Graham Hughes has proposed that in this group of patients, maternal administration of intravenous immunoglobulins (IVIG) may reduce the risk of recurrences.

A multinational open label study is currently underway based at The Lupus Unit, St. Thomas' Hospital, London, UK [Gordon, 2007] to confirm or refute the efficacy of IVIG in preventing congenital heart block.

Another potential strategy to prevent recurrence in subsequent pregnancies was immune-suppression with fluorinated steroids, which cross the placenta. However, the toxicity of these agents precludes their use as a preventative therapy. Serious effects on the fetus such as spontaneous abortions, stillbirth, IUGR, low birth weight, mild adrenal insufficiency, left ventricular myocardial hypertrophy and delayed psychomotor development were noticed with these drugs apart from the adverse effects on the mother [Gordon, 2007]. A case control study suggests that hydroxychloroquine, a Toll-like receptor (TLR) inhibitor the usage of which carries minimal risk to the mother and fetus, may decrease the risk of neonatal cardiac lupus related to anti-SSA/SSB antibodies. But prospective studies are needed for its confirmation [Izmirly, 2010].

9.1.2 Care of neonates at risk for complete heart block

Careful observation of infants whose second-degree atrioventricular block has been reversed in utero is necessary in the postnatal period, as there is still a risk of progression to a higher degree heart block, even with clearance of maternal auto antibodies. If prenatal screening or fetal monitoring has detected any degree of heart block in utero, consultation with a pediatric cardiologist should be obtained. Some infants with complete heart block will require insertion of a cardiac pacemaker, especially if the heart rate at delivery is less than 55 beats per minute [Izmirly, 2010].

An electrocardiogram (ECG) should be performed in all neonates born to mothers with anti-SSA/Ro and/or anti-SSB/La antibodies to detect first-degree heart block; infants with first-degree heart block are at risk of postnatal progression to higher degree block [Lawrence,

2000]. A normal ECG is reassuring. However, even a normal EKG at birth cannot exclude the subsequent development of second degree heart block. There are reports of anti-Ro antibody associated cardiomyopathy also, in the absence of heart block [Gordon, 2007].

9.1.3 Treating of fetal heart block

Complete heart block is irreversible even with glucocorticoid therapy [Saleeb, 1999]. Second-degree heart block may be reversible, but it also may progress to complete heart block despite therapy [Yamada, 1999]. The clinical relevance of first-degree heart block is unclear, since progression from first-degree block to more advanced heart block in untreated fetuses has not been reported.

Fluorinated glucocorticoids such as dexamethasone and betamethasone, which are not inactivated by placental 11-beta hydroxysteroid dehydrogenase, may suppress the associated pleuro-pericardial effusion or hydrops and may improve outcomes. Fluorinated glucocorticoids are also considered for signs of a more global cardiomyopathy. However, the effectiveness of these agents in the treatment of endocardial fibroelastosis is unknown. Maternal dexamethasone in conjunction with transplacental β -adrenergic stimulation for bradycardia in fetus with HR of <55 beats/mt was reported to be effective in CHB [Jaeggi et al, 2010].

Many children with congenital heart block (33–53%) require pacing as newborns. Due to the long-term risk of sudden death the vast majority of patients are paced by the time they reach adult life. Data from several studies suggest that right ventricular apex pacing may cause left ventricular dysfunction secondary to asynchronous right and left ventricular contraction and relaxation. Thus, late onset cardiomyopathy, in at least some congenital heart block patients, may be due to right ventricular apex pacing rather than the underlying disease process. Pacing at earlier age and higher rate of pacing may accentuate this problem [Lawrence, 2000].

A prolonged QTc is a recognized feature of congenital heart block and occurs in 15–22% of patients. Due to the risk of torsades de pointes these patients should be paced and treated with a beta-blocker. A prolonged QTc has been reported to occur in isolation in children born to anti-Ro positive mothers, although prospective studies do not suggest this as a common occurrence [Gordon, 2007].

Prolonged in-utero exposure to fluorinated glucocorticoids (e.g., betamethasone or dexamethasone) can lead to adrenal hypoplasia and result in neonatal adrenal insufficiency [Costedoat-Chalumeau, 2003]. This is a rare complication that can be anticipated and tested for. Neonatal hypotension that potentially results from adrenal insufficiency should be treated empirically with hydrocortisone in addition to standard supportive care.

9.1.4 Laboratory evaluation and management (Buyon, 2001)

1. ELISA- If this initial screening test is negative for anti-SSA/Ro and anti-SSB/La antibodies the pregnancy has no known risk for CHB. If positive,
2. Immunoblot testing to be done to stratify the risk into low, moderate and high.
 - a. Negative immunoblot defines low risk pregnancy (<2% probability of CHB)
 - b. Positive 52kD and 60kD Ro and La antibodies is moderate risk (2-5% probability of CHB)
 - c. Positive 52kD and 60kD Ro and La antibodies with previous NLE child is high risk pregnancy (15-20% probability of CHB)

Monitoring

Low risk- Fetal echo alternate weeks from 16-36wks & continuous auscultation

Moderate risk- Fetal echo every week from 16-26 wks and then alternate weeks from 26-36 Wks & Continued auscultation

High risk- Fetal echo weekly from 16-36 wks & continued auscultation

If echo shows prolonged mechanical PR interval or advanced degree block then follow the therapeutic approach which depends on degree of block and fetal morbidity at presentation [Jaeggi et al, 2004].

1a. III° AVB >2wks from detection=serial echo, fetal US, no therapy initiated

1b. III° AVB <2wks from detection=start oral dexamethasone-4mg/day for 6wks

If no change taper the dose

If reversed to II° AVB or less continue till delivery, and then taper

1c. Alternating III° AVB with II° AVB = start oral dexamethasone-4mg/day for 6wks

If it progress to III° AVB taper the dose

If reversed to II° AVB or less continue till delivery, and then taper

1d. II° or I° AVB =start oral dexamethasone-4mg/day till delivery, and then taper

If it progress to III° AVB give for 6 wks, and then taper

2. Heart block with signs of myocarditis, CHF, and/of hydropic changes

Start oral Dexamethasone until improvement, and then taper

3. Severe hydrops fetalis= start oral dexamethasone-4mg/day +

+Plasmapheresis (to remove the antibodies rapidly)

+Deliver if the lungs are mature

Fluorinated steroids cross the placental barrier, therefore dexamethasone or betamethasone is chosen for treatment. However, data during the same period at Guy's Hospital, London, has not supported the hypothesis that the improved survival can be attributed to dexamethasone therapy. As such a prospective study is needed to establish the role of routine dexamethasone therapy in congenital heart block.

At present, given the potential toxicity of dexamethasone to the fetus it is perhaps advisable to take a conservative approach and reserve the use of fluorinated steroids for cases where there is evidence of hydrops, poor ventricular function, or both. In compromised fetuses with a heart rate below 55 bpm maternal administration of β -sympathomimetic agents may be considered. New ultrasound methods allow measurement of the fetal atrioventricular time interval which provides a 'mechanical' PR interval and therefore it is now possible to detect first-degree heart block *in utero*.

If the natural history of congenital heart block involves the development of lesser degrees of heart block progressing to complete congenital heart block, detection of first-degree congenital heart block could theoretically provide a window of opportunity where therapeutic intervention is beneficial, either reversing the heart block or preventing progression to complete congenital heart block. The PRIDE (PR interval and dexamethasone evaluation) study is assessing this possibility by frequent measurement of the mechanical PR interval, weekly from 16 to 26 weeks gestation and then biweekly until 34 weeks, in pregnancies where the mother is anti-Ro antibody positive [Gordon,2007].

Thus even with intense monitoring lesser degrees of heart block are frequently not detected prior to the development of complete congenital heart block, providing little opportunity for

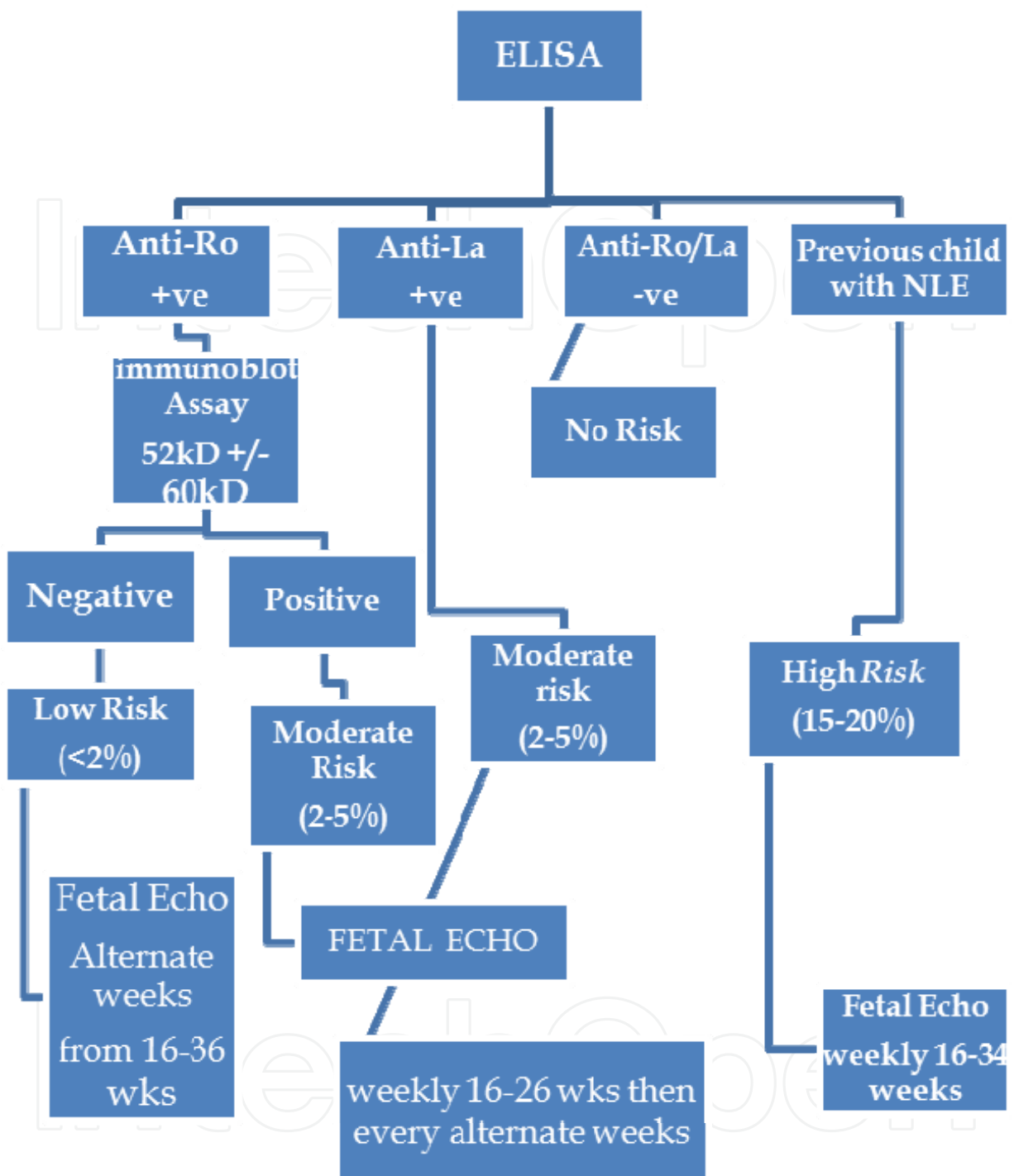


Fig. 3. Decision tree for diagnosis & management of CHB [Buyon, 2000]

intervention. Second-degree heart block detected *in utero* responds to treatment with fluorinated steroids. Whilst first-degree heart block detected *in utero* resolves following fluorinated steroid therapy, however its natural history is unclear with many cases resolving spontaneously.

Management of congenital heart block in utero and in the perinatal period can include

- steroid therapy if associated with anti-Ro/SSA and anti-La/SSB antibodies, and
- isoproterenol (β -sympathomimetic stimulation)

- And/or pacemaker insertion immediately postpartum.

The principal therapeutic decision after the immediate perinatal period involves the need for pacemaker placement. Most patients ultimately have a pacemaker inserted, regardless of the time of onset of the syndrome. Even patients who are free of symptoms at age 15 remain at risk for syncope or sudden cardiac death. And pacemaker is usually inserted in at least 90 percent by age 60 [Michaëlsson M, 1995].

Pacemaker: The type of pacemaker implanted is often based upon physician preference; either a ventricular (with rate responsiveness) or dual chamber pacemaker can be used. However, most physicians prefer physiologic dual chamber pacing in young patients as right ventricular pacing alone can cause ventricular asynchrony, which over long period of time can itself lead to cardiomyopathy. In addition if patient is not paced the bradyarrhythmia itself try to compensate with ventricular dilatation to increase the stroke volume which also can lead to heart failure.

In general implantation of permanent pacemaker in advanced second or third degree heart block which is either intermittent or permanent is in one of any of the following:

- Symptomatic bradycardia (syncope or presyncope)
- Ventricular dysfunction or low cardiac output
- A wide QRS escape rhythm
- Complex ventricular ectopy
- In an infant, ventricular rates <55 beats per minute or <70 beats per minute when associated with congenital heart disease

However any patient with CHB is at the risk of syncope or presyncope with stokes- Adam attacks and sudden death, therefore they need a pacemaker.

9.2 Treatment of neonatal cutaneous lupus

It does not require much therapy beyond avoidance of sun exposure and use of sun block and hydrocortisone cream. Systemic steroids are usually not required and systemic antimalarials are not advised due to slow onset of action in a transient illness and because of its potential toxicity in infants [Lee La, 1997].

10. Course

10.1 Early outcome

The rash of neonatal lupus (NLE) generally does not cause scarring or atrophy and disappears within six to eight months. Appearance of NLE skin lesions postnatally is independent of breastfeeding [Klauninger, 2009]. Thus, breastfeeding is not contraindicated in mothers with anti-SSA/Ro and/or anti-SSB/La antibodies.

There is little risk of later cardiac involvement in patients who had no evidence of heart block of any degree at birth or who had non-cardiac manifestations of NLE (rash or hematologic/liver abnormalities) at the time of diagnosis. However, infants with non-cardiac manifestations of NLE should at least have an ECG, and possibly an echocardiogram, since first-degree block is clinically silent and can progress postnatally. There have been no reported cases, nor has the Research Registry for Neonatal Lupus recorded the occurrence, of subsequent development of heart block following a normal electrocardiogram. As noted previously, second-degree block detected in utero and first or second degree heart block found at birth, can progress to complete heart block [Askanase, 2010].

10.2 Childhood mortality

The early outcome in infants with congenital complete heart block had a mortality of 43% if diagnosed in utero but only 6% for cases diagnosed at birth and among survivors 89% were paced [Jaeggi, 2010]. Therefore the mortality is higher for CHB diagnosed in utero than at birth. Late mortality may occur from arrhythmias, pacemaker failure or CHF. Mortality due to refractory heart failure is about 10% while the average mortality due to CHB is up to 20%.

The majority of the deaths occur in utero and first three months of life. And one year mortality is up to 41% (12%-41%) out of which 27% die within the first week of birth and 9% in the first three month but the mortality is only 3% for cases diagnosed after birth. Predictors of early mortality include a fetal heart rate <55 beats/min, delivery prior to 34 weeks and hydrops. The mortality is 3% in the 2nd year and another 3% in the 3rd year and no deaths related to cardiac lupus after three years in a study by Buyon and his colleagues. The main cause of early death is cardiac failure secondary to cardiomyopathy particularly in children between 2 and 4 years.

These children developed late onset cardiomyopathy despite early pacing. Survival also depends on the gestational age of birth. The earlier they are born the more the mortality is. The children born before 34 weeks the mortality is 52% than children born later in whom the mortality is only 9% [Buyon, 1998].

10.3 Long-term prognosis of the child

Infants and young children with complete heart block who are asymptomatic usually remain well until later childhood, adolescence, or adulthood. However, exercise limitation and even death are possible in the absence of pacing. The prognosis following pacemaker implantation is excellent for most children, although development of heart failure may occur.

Children who have had NLE may be at increased risk of developing an autoimmune and/or rheumatic disease, although it is rare. They are usually SLE, Juvenile RA, Sjogren's syndrome, undifferentiated connective tissue disease (UCTD), Hashimoto thyroiditis, Psoriasis, Iritis, type 1 DM, Raynaud's phenomenon or nephritic syndrome. Probably the longer the follow up period the higher the incidence of autoimmune disease in the child with NLE but, it is usually around 10% [Martin, 2007].

10.4 Maternal health & long-term outcome of mothers

At least 50% of the mothers with NLE had rheumatologic disease at presentation. Out of which 10% have SLE, 20% Sjogren's syndrome and 20% undifferentiated (UCTD). And 50% of the remaining asymptomatic patients developed disease in 20 year follow-up period mainly Sjogren's syndrome, SLE, UCTD, and others. Greater proportion of mothers has rheumatologic disease whose children have cutaneous NLE than CHB.

The development of lupus nephritis in mothers of children with NLE is relatively uncommon. In a review of the database of the Research Registry for Neonatal Lupus, 50 percent of mothers had some progression of their health status toward development of autoimmune (rheumatologic) symptoms. These asymptomatic mothers had a 19 percent risk of developing SLE and a 28 percent chance of developing probable or definite Sjogren's syndrome within 10 years. The NLE manifestations were not predictive of maternal disease progression.

The incidence of hypothyroidism is increased in women with anti-SSA/Ro antibodies, which is about 10% and the incidence of CHB in these mothers with hypothyroidism is higher than those without (56% Vs 13%). Therefore evaluation of thyroid disorders is warranted in any mother of an infant with neonatal lupus who complains of hair loss or fatigue [Askanase et al, 2006].

11. Conclusion

Neonatal lupus is due to passive transplacental transfer of maternal IgG auto-antibodies to SSA/Ro, SSB/La or U1RNP. It is seen in 1-2% of these neonates. The incidence is higher if the mother also has autoimmune disease. The incidence increases 5-10 folds in mothers who already have a child with neonatal lupus. The pathogenesis is mainly due to fibrosis of the atrioventricular node with or without cardiomyopathy caused by auto antibodies.

It can cause cutaneous lupus which is transient and self-limiting which usually do not require treatment. It can also present with complete heart block which is usually permanent requiring permanent pacemaker in most of the patients. They are prone for cardiomyopathy either as a result of the disease or due to right ventricular pacing which also contributes to mortality at least by 10%. The diagnosis is made by detecting auto-antibodies to SSA or SSB or U1 RNP and the CHB is made mainly in utero by periodic fetal echocardiography from 16 weeks onwards.

Fluorinated glucocorticoids (oral dexamethasone 4 mg per day or betamethasone 3 mg per day) are given for mothers of fetuses with second-degree heart block, cardiomyopathy or hydrops. It is not effective in CHB and not recommended in first degree heart block as they do not progress to advanced heart block and the adverse side effects of the drugs also limit its use.

The mortality is high in children who were detected of having CHB in utero than that detected after birth and it is mainly high in the first year and more so in the first three months of life. Many aspects of its pathogenic mechanisms are revealed but still research is needed as many questions are unanswered which could help in the preventive and therapeutic aspects of these patients.

12. Acknowledgment

The work to produce this chapter was supported by Alzaidi's Chair of research in rheumatic diseases- Umm Alqura University.

13. References

- Agarwala B, Sheikh Z, Cibils LA. (1996). Congenital complete heart block. *J Natl Med Asso*, 88:725-729.
- Askanase AD et al. (2006). Hypothyroidism and antithyroglobulin and antithyropoxidase antibodies in the pathogenesis of autoimmune associated congenital heart block. *J Rheumatol*, 33:2099.
- (2010). Frequency of neuro-psychiatric dysfunction in anti-SSA/SSB exposed children with and without neonatal lupus. *Lupus*, 19:300.


- Bennion SD, Ferris et al. (1990). IgG subclasses in the serum and skin in sub acute cutaneous lupus erythematosus and neonatal lupus erythematosus. *J Invest Dermatol*, 95: 643-646.
- Boh, E. (2004). Neonatal lupus erythematosus due to anti-RNP. *Clin Dermatol*, 22: 125-128.
- Borda E, Sterin-Borda L. (2001). Auto-antibodies against neonatal heart M1 muscarinic acetylcholine receptor in children with congenital heart block. *J Autoimmun*, 16: 143-150.
- Boros, Christina et al. (2007). Hydrocephalus and macrocephaly: New manifestations of neonatal lupus erythematosus. *Arthritis & Rheumatism*, 57(2) *Arthritis Care & Research*, 261-266.
- Botard N, Sainte-Marie D et al. (2000). Cutaneous neonatal lupus erythematosus: discordant expression in identical twins. *Ann Dermatol venereal*, 127(10):814-817.
- Brucato A et al. (1995) Isolated congenital complete heart block: long-term outcome of children and immunogenetic study. *J Rheumatol*, 5;22:541-543.
- (2010). Ghidoni S. Arrhythmias presenting in neonatal Lupud. [Review] *Scandinavian Journal of Immunology*, 72(3):198-204.
- Buyon JP et al. (1998). Autoimmune-associated congenital heart block: demographics, mortality, morbidity and recurrence rates obtained from a national neonatal lupus registry. *J Am Coll Cardiol*, 31:1658.
- (2001). Anti-Ro/SSA antibodies and congenital heart block: necessary but not sufficient. *Arthritis Rheum*, 44:1723.
- (2005). Neonatal Lupus: Basic research and Clinical perspectives *Rheum Dis Clin N Am*, 31:299-313
- (2007). Neonatal Lupus, In: *Dubois' Lupus Erythematosus* (7th Edition).
- Wallace, Daniel J Hahn et al. Lippincott Williams & Wilkins Clancy RM et al. (2005). Maternal antibody responses to the 52-kd SSA/RO p200 peptide and the development of fetal conduction defects. *Arthritis Rheum*, 52:3079.
- (2006). Impaired clearance of apoptotic cardiocytes is linked to anti-SSA/Ro and -SSB/La antibodies in the pathogenesis of congenital heart block. *J Clin Invest*, 116: 2413.
- Costedoat-Chalumeau N, Amoura et al. (2003). Questions about dexamethasone use for the prevention of anti-SSA related congenital heart block. *Ann Rheum Dis*, 62: 1010.
- Eftekhari P, Roegel JC, et al. (2001). Induction of neonatal lupus in pups of Mice immunized with synthetic peptides derived from amino acid sequences of the serotonergic 5-HT₄ receptor. *Eur J Immunol*, 31:573-579.
- Eronen M, Siren et al. (2000). Short and long- term outcome of children with congenital complete heart block diagnosed in utero or as a newborn. *Pediatrics*, 106:86-91.
- Falcini F, De Simone et al. (1998). Congenital conduction defects in children born to asymptomatic mothers with anti-SSA/SSB antibodies: report of two cases. *Ann Ital Med Int*, 13:169.

- Friedman DM, Llanos, et al. (2010) Evaluation of fetuses in a study of Intravenous immunoglobulin as preventive therapy for congenital heart block: Results of a multicenter, prospective, open-label clinical trial. *Arthritis Rheum*, 62:1138.
- Garcia S, Nascimento et al. (1994). Cellular mechanism of the conduction Abnormalities induced by serum from anti-Ro/SSA-positive patients in rabbit hearts. *J Clin Invest*, 93:718.
- Glickstein JS, Buyon et al. (2000). Pulsed Doppler echocardiographic assessment of the fetal PR interval. *Am J Cardiol*, 86:236.
- Goldsmith DP. (1989) Neonatal rheumatic disorders. View of the pediatricians. *Rheum Dis Clin North Am*, 15:287-305.
- Gordon PA. (2007). Congenital heart block: Clinical features and therapeutic approaches. *Lupus*, 16:642-646.
- Hornberger LK. Al Rajaa . (2010). Spectrum of cardiac involvement in neonatal lupus. [Review] *Scandinavian Journal of Immunology*, 72(3):189-97.
- Houssiau FA, Lebacqz. (1986). Neonatal lupus erythematosus with congenital heart block associated with maternal systemic lupus erythematosus. *Clin Rheumatol*, 5:505.
- Izmirly PM et al. (2002). Outcome of children with fetal, neonatal or childhood diagnosis of isolated congenital atrioventricular block. A single institution's experience of 30 years. *J Am Coll Cardiol*, 39:130.
- (2007). Neonatal Lupus Syndromes. *Rheum Dis Clin N Am*, 33:267-285
- Jaeggi E et al. (2010). Evaluation of the risk of anti-SSA/Ro-SSB/La antibody-associated cardiac manifestations of neonatal lupus in fetuses of mothers exposed to hydroxychloroquine. *Ann Rheum Dis*, 69:1827.
- (2010). Cutaneous manifestations of neonatal lupus and risk of subsequent congenital heart block. *Arthritis & Rheumatism*, 62(4):1153-1157
- (2010). The importance of the level of maternal anti-Ro/SSA antibodies as a prognostic marker of the development of cardiac neonatal lupus erythematosus. *J Am Coll Cardiol*, 55:2778
- Johansen AS, Herlin T. (1998). Neonatal lupus syndrome. Association with Complete congenital atrioventricular block. *Ugeskr Laeger*, 160:2521.
- Kaye EM, Butler IJ, Conley S. (1987). Myelopathy in neonatal and infantile lupus erythematosus. *J Neurol Neurosurg Psychiatry*, 50:923.
- Klauninger R, Skog A, Horvath et al. (2009). Serologic follow-up of children born to mothers with Ro/SSA autoantibodies. *Lupus*, 18:792
- Lee LA et al. (1993). Neonatal lupus liver disease. *Lupus*, 2:333-338.
- (1994). The autoantibodies of neonatal lupus erythematosus. *J Invest Dermatol*, 102:963-966.
- (1996). The recognition of human 60-kDa Ro ribonucleoprotein particles by antibodies associated with cutaneous lupus and neonatal lupus. *J Invest Dermatol*, 107:225-228.
- (1996). Special considerations concerning the cutaneous manifestations of rheumatic diseases in children. In: Sontheimer, RD, Provost, TT, (eds), *Cutaneous manifestations of rheumatic diseases*, 2nd ed. P. 323-344. Baltimore, Maryland: Williams & Wilkins;

- (1997). Cutaneous Lupus erythematosus during the neonatal and childhood periods. *Lupus*, 6:132-138.
- (2009). The clinical spectrum of neonatal lupus. *Archives of Dermatological Research*. 301(1):107-110.
- (2010). Cutaneous lupus in infancy. *Lupus*, 19, 1112-1117.
- Lawrence S, Luy et al. (2000). The health of mothers of children with cutaneous neonatal lupus erythematosus differs from that of mothers of children with congenital heart block. *Am J Med*, 108:705-9.
- Maddison PJ, Lee L, Reichlin M, et al. (1995). Anti-p57: a novel association with neonatal lupus. *Clin Exp Immunol*, 99: 42-48.
- Martin V, Lee LA, Askanase AD, et al. (2002). Long-term followup of children with neonatal Lupus and their unaffected siblings. *Arthritis Rheum*, 46:2377.
- McCuiston, C, Schoch, E Jr. (1954). Possible discoid lupus erythematosus in newborn infant; report of a case with subsequent development of acute systemic lupus erythematosus in mother. *AMA Arch Derm Syphilol*, 70: 782-785.
- Miranda-Carús ME, Askanase AD, et al. (2000). Anti-SSA/Ro and anti-SSB/La Autoantibodies bind the surface of apoptotic fetal cardiocytes and promote secretion of TNF-alpha by macrophages. *J Immunol*, 165:5345.
- Michaëlsson M, Engle MA. (1972). Congenital complete heart block: an international study of the natural history. *Cardiovasc Clin*, 1972;4:85
- Michaëlsson M, Jonzon A, Riesenfeld T. (1995). Isolated congenital complete atrioventricular block in adult life. A prospective study. *Circulation* 1995; 92:442.
- Miyagawa S, Yanagi K, et al. (1998). Neonatal lupus erythematosus: maternal IgG antibodies bind to a recombinant NH2-terminal fusion protein encoded by human alpha-fodrin cDNA. *J Invest Dermatol*, 111:1189-1192.
- Neiman, A, Lee, L, Weston, W, Buyon, J. (2000). Cutaneous manifestations of neonatal lupus without heart block: characteristics of mothers and children enrolled in a national registry. *J Pediatr*, 137: 674-680.
- Nield LE, Silverman ED, Taylor GP, et al. (2002). Maternal anti-Ro and anti-La antibody-associated endocardial fibroelastosis. *Circulation*, 105:843.
- Niewold, Timothy B, Rivera et al. (2002). Interferon in neonatal lupus. *Arthritis & Rheumatism*, 58(2):541-546.
- Niewold, Timothy B ; Rivera, et al. (2008). Serum type I interferon activity is dependent on maternal diagnosis in anti-SSA/Ro-positive mothers of children with neonatal lupus. *Arthritis & Rheumatism*, 58(2):541-546.
- Peñate Y, Guillermo et al. (2009). Histopathologic characteristics of neonatal cutaneous lupus erythematosus: description of five cases and literature review. *J Cutan Pathol*, 36:660.
- Pisoni CN, Brucato A, Ruffatti A, et al. (2010). Failure of intravenous immunoglobulin to prevent congenital heart block: Findings of a multicenter, prospective, observational study. *Arthritis Rheum*, 62:1147.
- Plant RK Steven RA. (1945). Complete AV block in fetus. Case report. *Am Heart J*, 30:615-618.

- Saleeb S, Copel J, Friedman D et al. (1999). Comparison of treatment with fluorinated glucocorticoids to the natural history of autoantibody-associated congenital heart block: *Arthritis Rheum*, 42:2335.
- Salomonsson S, Dörner T, Theander E, et al. (2002). A serologic marker for fetal risk of congenital heart block. *Arthritis Rheum*, 46:1233.
- Shimosegawa M, Alaska T, Matsuta M. (1997). Neonatal lupus erythematosus occurring in identical twins. *J Dermatol*, 24: 578-582.
- Silverman ED et al. (1995). Autoantibody response to the Ro/La particle may predict outcome in neonatal lupus erythematosus. *Clin Exp Immunol*, 100:499.
- (2010). Non-cardiac manifestations of Neonatal Lupus Erythematosus. *Scandinavian Journal of Immunology*, 72(3):223-225.
- Singsen BH, Nevon P, Wang G, et al. (1986). Anti-SSA and other anti-nuclear antibodies (ANA) in healthy pregnant women and in newborn cord blood (Abstract) *J Rheumatol*, 13:984
- Spalding, T Hennon, J Dohar and T Arkachaisri. (2007). A case report-Neonatal lupus erythematosus complicated by mucocutaneous and visceral hemangiomas. *Lupus*, 16, 904-907
- Sonesson SE, Salomonsson et al. (2004). Signs of first-degree heart block occur in one-third of fetuses of pregnant women with anti-SSA/Ro 52-kd antibodies. *Arthritis Rheum*, 50:1253.
- Sontheimer RD, Nguyen TQ, Buyon JP, et al. (1996). Clinical correlations of autoantibodies to a recombinant, hYRNA-binding form of human calreticulin. *J Invest Dermatol*, 106: 938
- Spence D, Hornberger et al. (2006). Increased risk of complete congenital heart block in infants born to women with hypothyroidism and anti-Ro and/or anti-La antibodies. *J Rheumatol*, 33:167.
- Tabbut S, Griswold WR, Ogino MT, et al. (1994). Multiple thromboses in a premature infant associated with maternal antiphospholipid syndrome. *J perinatol*, 14:66-70.
- Vesel S, Mazić U, Blejec T, Podnar T. (2004). First-degree heart block in the fetus of an anti-SSA/Ro-positive mother: reversal after a short course of dexamethasone treatment. *Arthritis Rheum*, 50:2223.
- Waltuck J, Buyon JP. (1994). Autoantibody-associated congenital heart block: outcome in mothers and children. *Ann Internal Med*, 120:544.
- Wang D, Buyon JP, Zhu W, Chan EK. (1999) Defining a novel 75-kD a Phosphoprotein associated with SS-A/Ro and identification of distinct human autoantibodies. *J Clin Invest*, 104: 1265-1275.
- Watson RM, Braunstein BL, Watson AJ, et al. (1986). Fetal wastage in women with anti-Ro/SSA antibody. *J Rheumatol*, 13:90-94.
- White, P, Eustis, R. (1921). Congenital heart block. *Am J Dis Child*, 22:299.
- Wisuthsarewong, Wanee M.D. et al. (2011). Neonatal Lupus Erythematosus: Clinical character, investigation, and Outcome. *Pediatric Dermatology*, 28(2):115-121
- Wolach B, Choc L, Pomeranz A, et al. (1993). Aplastic anemia in neonatal lupus erythematosus. *Am J Dis Child*, 147:941.

- Xiao GQ, Hu K, Boutjdir M. (2001). Direct inhibition of expressed cardiac l-and t-type calcium channels by igg from mothers whose children have congenital heart block. *Circulation*, 103:159
- Yamada H, Kato EH, Ebina Y, et al. (1999). Fetal treatment of congenital heart block ascribed to anti-SSA antibody: case reports with observation of cardiohemodynamics and review of the literature. *Am J Reprod Immunol*, 42:226.
- Yazici Y, Onel K, Sammaritano L. (2000). Neonatal lupus erythematosus in triplets. *J Rheumatol*, 27(3):807-809.



Systemic Lupus Erythematosus

Edited by Dr Hani Almoallim

ISBN 978-953-51-0266-3

Hard cover, 554 pages

Publisher InTech

Published online 21, March, 2012

Published in print edition March, 2012

This book provides a comprehensive overview of the basic and clinical sciences of Systemic Lupus Erythematosus. It is suitable for basic scientists looking for detailed coverage of their areas of interest. It describes how advances in molecular biology have increased our understanding of this disease. It is a valuable clinical resource for practicing clinicians from different disciplines including rheumatologists, rheumatology fellows and residents. This book provides convenient access to information you need about cytokines, genetics, Fas pathway, toll like receptors and atherogenesis in SLE. Animal models have been reviewed as well. How to avoid delay in SLE diagnosis and management, in addition to various clinical manifestations including pregnancy and SLE have all been explained thoroughly in this book.

How to reference

In order to correctly reference this scholarly work, feel free to copy and paste the following:

Hanan Al-Osaimi and Suvarnaraju Yelamanchili (2012). Neonatal Lupus Erythematosus (NLE), Systemic Lupus Erythematosus, Dr Hani Almoallim (Ed.), ISBN: 978-953-51-0266-3, InTech, Available from: <http://www.intechopen.com/books/systemic-lupus-erythematosus/neonatal-lupus-erythematosus>

INTECH

open science | open minds

InTech Europe

University Campus STeP Ri
Slavka Krautzeka 83/A
51000 Rijeka, Croatia
Phone: +385 (51) 770 447
Fax: +385 (51) 686 166
www.intechopen.com

InTech China

Unit 405, Office Block, Hotel Equatorial Shanghai
No.65, Yan An Road (West), Shanghai, 200040, China
中国上海市延安西路65号上海国际贵都大饭店办公楼405单元
Phone: +86-21-62489820
Fax: +86-21-62489821

© 2012 The Author(s). Licensee IntechOpen. This is an open access article distributed under the terms of the [Creative Commons Attribution 3.0 License](#), which permits unrestricted use, distribution, and reproduction in any medium, provided the original work is properly cited.

IntechOpen

IntechOpen