

# We are IntechOpen, the world's leading publisher of Open Access books Built by scientists, for scientists

**4,800**

Open access books available

**122,000**

International authors and editors

**135M**

Downloads

Our authors are among the

**154**

Countries delivered to

**TOP 1%**

most cited scientists

**12.2%**

Contributors from top 500 universities



**WEB OF SCIENCE™**

Selection of our books indexed in the Book Citation Index  
in Web of Science™ Core Collection (BKCI)

Interested in publishing with us?  
Contact [book.department@intechopen.com](mailto:book.department@intechopen.com)

Numbers displayed above are based on latest data collected.

For more information visit [www.intechopen.com](http://www.intechopen.com)



## Recent Development and Trends in Molecular Imaging Probes for Prostate Cancer

Wenbin Zeng<sup>1,2</sup>, Zhiguo Liu<sup>1,2</sup> and Wei Wang<sup>2,3</sup>

<sup>1</sup> School of Pharmaceutical Sciences, Central South University, Tongzipo Road, Changsha,

<sup>2</sup> Molecular Imaging Research Center, Central South University, Changsha,

<sup>3</sup> Cell Transplantation & Gene Therapy Institute,  
The Third Xiangya Hospital of Central South University, Changsha,  
China

### 1. Introduction

In 1853, a surgeon at the London Hospital, Adams J, discovered the first case of prostate cancer by histological examination [1]. In the report, he noted that the condition was “a very rare disease”. Remarkably, 150 years later, prostate cancer has become a significant health problem and disease. Prostate cancer continues to have the highest incidence rate of any other type of cancer in male, and it is the second leading cause of cancer deaths in male (in the United States), with about 220k new cases diagnosed each year only in US [2-4]. Detection rates of prostate cancers vary widely across through the world, with less frequently detecting in East and South Asia than in Europe, and especially in the United States. Prostate cancer tends to develop in men over the age of fifty, and although it is one of the most prevalent types of cancer in men. However, many of those patients never have symptoms, while undergo no therapy, and eventually die of other causes. The increased incidence of prostate cancer patients has led to remarkable changes in diagnosis and treatment over the past decades. Fifty years ago the typical patient was a man in his early seventies who was diagnosed with metastases to the bone and/or soft tissues [5]. Characteristically, these lesions were bulky and histologically poorly differentiated. Diagnosis at such an advanced disease status was a death sentence, with patients dying within less than two years. Prostate cancer is currently diagnosed by sector biopsy in men presenting with an elevated serum prostate-specific antigen level. As for all biopsies, sector biopsy for prostate cancer is invasive and limited by sampling error [6]. Now there is a genetic and biochemical framework for understanding the process of both sporadic and inherited forms of prostate cancer, especially with the development of the new discipline, molecular imaging, a valuable tool for the diagnosis for prostate cancer [7]. At present, owing to the use of molecular imaging modality, together with the traditional serum PSA screening and improved biopsy techniques, most patients could be diagnosed with prostate cancer at a stage when it is potentially curable by surgical and/or radiological approaches. As a result, the good news is that the diagnosis of prostate cancer is no longer automatically a death sentence [8].

Molecular imaging is a newly emerging field, but has become an indispensable tool in cancer research, medical practice and clinical trials, with aims at noninvasive, real-time, quantitative visualization of *in vivo* molecular processes occurring at cellular and subcellular levels. Molecular imaging allows physicians and clinicians not only to see where a tumor is located in the body, but also to visualize the expression and activity of specific molecules (small molecular, or large molecular such as protein, antibody, and etc) and biological processes (e.g., apoptosis, metastasis, and angiogenesis) which influence tumor behavior and/or its response to therapy. At present, advancement in the molecular imaging field is promoted by the development of improved imaging hardware for use in preclinical and clinical settings, the identification and validation of new, biologically relevant imaging targets, and the development of improved imaging probes derived from novel chemicals. Of these three essential factors, which comprise the majority of current molecular imaging research, hardware developments and novel target discoveries significantly outpace the development and clinical advancement of new molecular imaging probes, particularly with respect to cancer imaging [9-12]. Hence, molecular imaging, or diagnostic imaging, could provide a full prospect of prostate tumor burden by uncovering recurrent and metastatic lesions.

Herein, we will focus on the discovery of molecular imaging probes that exist for the use of molecular imaging as a platform for prostate cancer, rather than specific details of hardware and instrumentation. Since molecular imaging probes may also help to guide oncologists, physicians and clinicians to identify those patients that could best benefit from a given therapeutic regimen, dose, or duration of drug, we will also outline the existing molecular imaging probes and modalities that are currently undergoing preclinical and clinical tests and those, which have been described based on the different receptor of prostate cancer, that could be rapidly translated into humans. Meanwhile, we will also discuss possible future directions and specific application of these and other potential new imaging strategies designed to both diagnosis and treatment for prostate cancer.

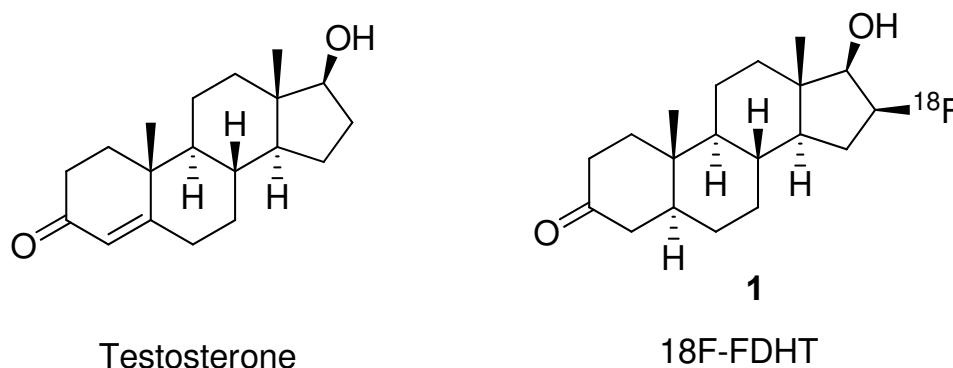
## **2. Imaging probes for prostate cancer based on androgen receptor (AR)**

Androgens are fundamental for the growth, development and maintenance of the prostate. Its effects are exerted via the nuclear androgen receptor (AR) which is a ligand-dependent transcription activator involved in cellular proliferation and differentiation and is founded in all histologic types of prostate tumors. Pathologic and molecular analyses of AR would afford the evidence of the gene expression and increased protein mutation, which contributes to a change of function, and ligand-independent activation [13, 14]. Since it is particularly imperative to find approaches for assessing prostate cancer comprehensively, molecular imaging of AR might provide an unprecedented opportunity for deciphering the molecular mechanisms involved in the development and natural progression of prostate cancer from a localized process to the hormone-refractory metastatic disease. Such understanding will be the key for targeted imaging and therapy, as well as for predicting and evaluating treatment response and prognosis [15]. An alternative approach to radiolabeled antibodies, such as <sup>111</sup>In-labeled prostate-specific membrane antigen (PSMA) monoclonal antibody (also named as ProstaScint) was reported, with a focus on the development of AR radioligands for positron emission tomography (PET), single photon emission computerized tomography (SPECT), and magnetic resonance imaging (MRI)-based

imaging of the prostate. Generally speaking, AR radiolabeled ligands can be divided into two main structural classes, steroidal (such as  $^{18}\text{F}$ -FDHT) and nonsteroidal (such as flutamide and bicalutamide), or into two different functional classes, androgenic and antiandrogenic [16, 17].

### 2.1 Steroidal AR radioligands for imaging prostate cancer

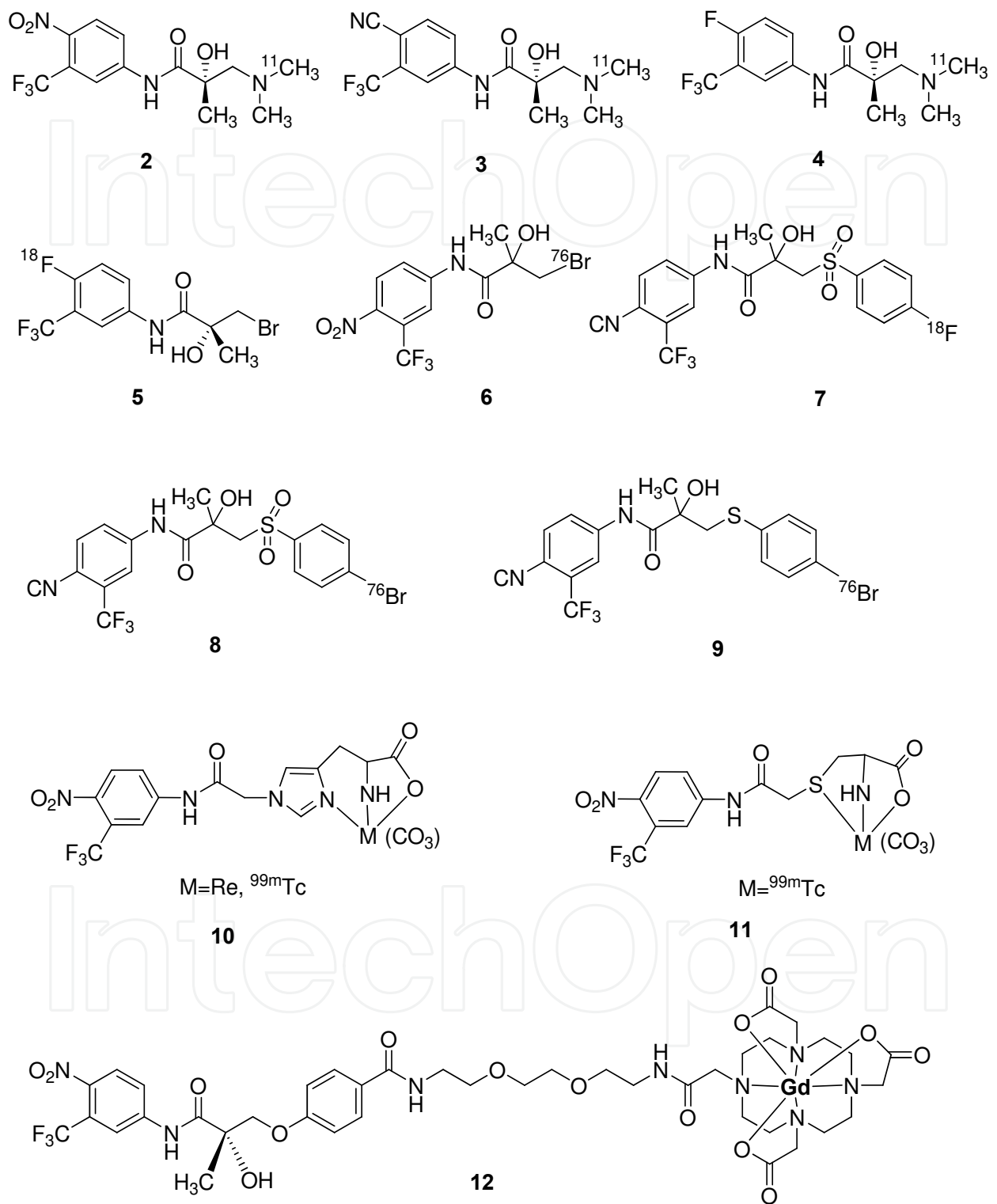
Zanzonico P and co-workers discovered a steroidal AR radioligand,  $^{18}\text{F}$ -FDHT (16 $\beta$ -[ $^{18}\text{F}$ ]fluoro-5 $\alpha$ -dihydrotestosterone), and carried out some basic research to evaluate it [18, 19]. FDHT is of a structural analog of 5 $\alpha$ -dihydrotestosterone, a principal intraprostatic form of androgen. A study of progressive androgen-independent prostate cancer on seven patients indicated that  $^{18}\text{F}$ -FDHT may be a promising new radiotracer compare with  $^{18}\text{F}$ -FDG. In the relevant study of fluorinated androgen analogs in baboon, performed by Welch group, the uptake of FDHT in the prostate was blocked by coadministration of cold testosterone (reduced about 10-fold) [20]. To date, FDHT appears to bind specifically to androgen receptors in vivo and to be of the most favorable targeting properties for noninvasive imaging among all receptor-binding radiotracers studied before. In other researches,  $^{18}\text{F}$ -FDHT present some advantages such as fast tumor uptake and prolonged retention of radioactivity observed in human studies. However, limitations such as metabolic rate of this labeled compound rapid have been observed [21-23].



Scheme 1. The chemical structure of Testosterone and  $^{18}\text{F}$ -FDHT.

### 2.2 Nonsteroidal AR radioligands for imaging prostate cancer

Nonsteroidal AR radioligands, (R)-[ $^{11}\text{C}$ ]-dimethylaminehydroxy-flutamide derivatives (Scheme 2, probe **2**, **3**, and **4**), were designed, synthesized and radiosynthesized by Jacobson O et al in 2006 [24]. The preliminary biological evaluations of three novel nonsteroidal flutamide derivative androgen ligands demonstrated some significant benefits compared with the currently used commercial drugs. These compounds have higher or similar affinities to the AR when compared with 3-bromo-hydroxyflutamide and hydroxyflutamide. However, unlike other reported nonsteroidal radiolabeled AR ligands, these compounds have an electron-rich group (dimethylamine) located on the methyl moiety, which may confer a better stability to the molecule. Additionally, they serve as an anchor for carbon-11 labeling in a more straightforward approach than labeling with fluorine-18 or bromine-76. Furthermore, some other nonsteroidal agents are being evaluated for prostate cancer imaging, based on hydroxyflutamide and bicalutamide pharmacophores, for example, as shown in Scheme 2, (R)-[ $^{18}\text{F}$ ]-hydroxyflutamide (**5**), 3-[ $^{76}\text{Br}$ ]-bromo-hydroxyflutamide (**6**), [ $^{18}\text{F}$ ]- bicalutamide (**7**),

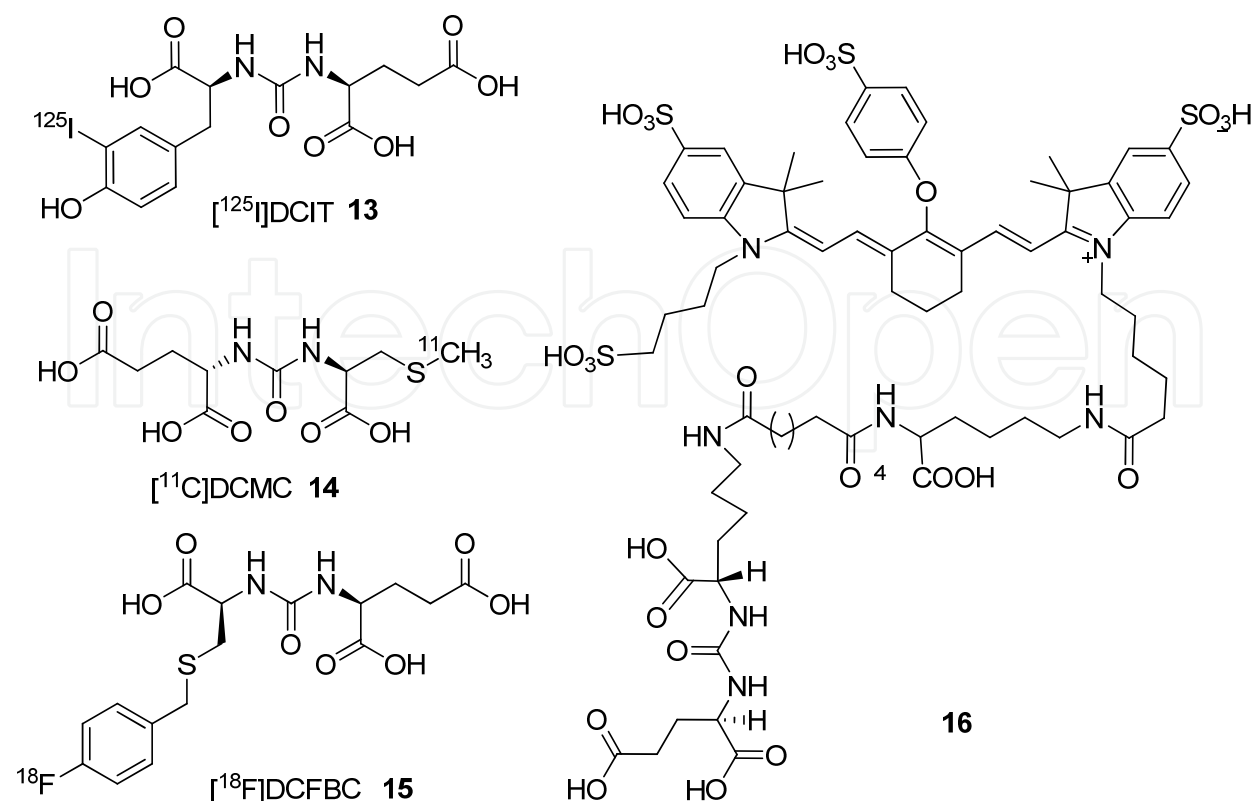


Scheme 2. Chemical structures of some nonsteroidal AR radioligands for imaging prostate cancer.

[<sup>76</sup>Br]-bromo-bicalutamide (**8**), and [<sup>76</sup>Br]-bromo-thiobicalutamide (**9**) [25, 26]. Additionally, [<sup>76</sup>Br]-bromo-bicalutamide compound has been found to have an order of magnitude higher affinity for AR than that of bicalutamide (K<sub>d</sub> of 0.113 μM for [<sup>76</sup>Br]-bromobicalutamide versus to K<sub>d</sub> of 1.276 μM for bicalutamide). Also, a series of novel prospective SPECT imaging agents has been reported very recently. These <sup>99m</sup>Tc-containing flutamide derivatives (**10**, **11**) were synthesized, characterized, and evaluated, with a significant selective uptake by a prostate [27]. Furthermore, Marom H et al reported a new nonsteroidal antiandrogen-lanthanoid metal complexes (**12**) as a potential MRI contrast agent for prostate cancer diagnostics [28]. These interesting results demonstrate that AR provides a more sensitive imaging-based biologic target for imaging and early assessment of treatment response.

### 3. Imaging probes for prostate cancer based on PSMA

Serum prostate-specific antigen (PSA) has long been used as an organ-specific biomarker and is currently the most commonly used one for prostate cancer. PSA is a 33 kDa androgen-regulated serine protease produced by the prostate gland. However, PSA and other related parameters have limited sensitivity and limited specificity to prostate cancer. Therefore, it may be affected by a manner unrelated to the effect of the therapy on tumor, and is the cause of the patients' great anxiety or overstated diagnostic expectations [29, 30]. The prostate-specific membrane antigen (PSMA) is expressed in both the benign and the neoplastic prostatic epithelial cells and in other tissues, such as kidney, liver, and brain [31]. It is upregulated in hormone-resistant states and in metastatic disease. It is a transmembrane, 750 amino acid, type II glycoprotein primarily expressed in normal human prostate epithelium but overexpressed in prostate cancer, including metastatic disease. Because PSMA is expressed by virtually all prostate cancers and its expression is further increased in poorly differentiated, metastatic and hormone-refractory carcinomas, it is a very attractive target for prostate cancer imaging and therapy [32, 33]. Recently, researchers from Johns Hopkins University presented the preparation of radiolabeled small-molecule ligands for PSMA ([<sup>125</sup>I]DCIT, [<sup>11</sup>C]DCMC, [<sup>18</sup>F]DCFBC), as well as seven technetium <sup>99m</sup>- or rhenium-labeled chelating agents attached to an amino-functionalized PSMA inhibitor with or without a variable length linker moiety [34-36]. These probes were based on potential capitalization on PSMA as a relevant biologic target for imaging and therapy of prostate cancer. Other works indicated that biotinylated anti-PSMA antibody conjugated to streptavidin-labeled iron oxide nanoparticles could be used as the MRI probe for detection of prostate cancer cells [37]. T1-weighted signal was greater for cells with magnetic particles bound to cell surface than for cells that internalized the particles, whereas no such effect was noted with T2-weighted images. Besides, a low molecular weight PSMA-based fluorescent imaging agent have been relatively extensively studied in prostate cancer. 2-(3-(5-[7-(5-amino-1-carboxy-pentyl-carbamoyl)-heptanoy-amino]-1-carboxy-pentyl)-ureido) entanedioic acid was conjugated with a commercially available near-infrared light-emitting dye (IRDye 800CW) to afford **16** in good yield. It has a PSMA inhibitory activity of 0.37 nM, which is capable of generating target-to-nontarget ratios of at least 10 fold in PSMA-expressing PC3-PIP vs PSMA-negative PC3-flu tumors in vivo. It is useful for the study of PSMA-expressing tissue in preclinical models or for intraoperative guidance [38].



Scheme 3. Probes for imaging prostate cancer based on PSMA.

#### 4. Other probes for imaging prostate cancer based on EGF receptor, GRP receptor, and integrin $\alpha\beta 3$

[<sup>18</sup>F]-fluorodeoxyglucose (FDG) (17) is a well known molecular imaging probe for monitoring tissue glucose metabolism in clinical trial [39, 40]. Because of the advantages of the known mechanism that most tumors are hypermetabolic with increased glucose metabolism (Warburg effect), this probe is more suitable for assessing the glucose metabolism for prostate cancer. The upregulation of glucose transporter (GLUT) proteins (such as GLUT1 and/or GLUT3) and/or increased enzymatic level of hexokinase (HK) and activity (primarily HK-II) have been observed in many cancers. GLUT, which affects the rate-limiting step, is very important for glucose metabolism. The whole procedure needs energy-independent glucose transport across the cell membrane down the concentration gradient. Then, glucose is phosphorylated to glucose-6-phosphate by efficiently using HK-II. FDG, with a similar structure to glucose, is phosphorylated to FDG-6-phosphate, but when compared with glucose-6-phosphate, it cannot be further metabolized in the glycolytic pathway and finally trapped and accumulated in the cell owing to its negative charge [41, 42]. The GLUT1 mRNA expression was observed by Northern blot analysis in both androgen-independent cell lines and the androgen-sensitive prostate cancer cell line [43]. A related study from Australia demonstrated that the expression of GLUT12 in human prostate cancer cell lines potentially enhanced glucose metabolism in prostate tumor [44]. These findings may explain the phenomenon of higher FDG accumulation in prostate cancer, especially in malignancy grade. However, there are some limitations: the role of <sup>18</sup>F-FDG PET in prostate cancer is controversial, and the results are heavily influenced by the

patient selection; The uptake of  $^{18}\text{F}$ -FDG is low in tumour tissue. The 60%–70% sensitivity of  $^{18}\text{F}$ -FDG PET for prostate cancer is not high enough to justify its routine clinical use for staging or restaging of this disease [45]. The poor performance of  $^{18}\text{F}$ -FDG PET is likely related to the low glucose metabolic rate that results from the relatively slow growth of most prostate cancers as well as to other factors.

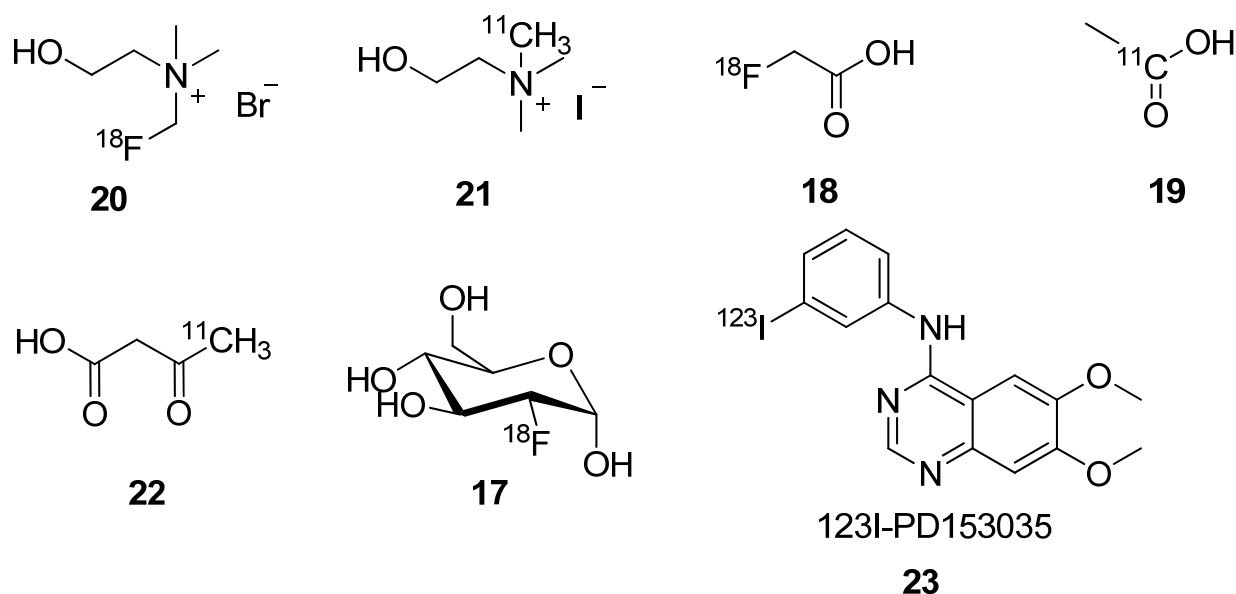
Another PET tracers, such as  $^{11}\text{C}$ - or  $^{18}\text{F}$ -labeled acetate (**18**, **19**) and choline (**20**, **21**), have been extensively studied in prostate cancer [46, 47]. However,  $^{11}\text{C}$  acetate is primarily retained in prostate cancer cell lines, due to incorporation of the radiocarbon into phosphatidylcholine and neutral lipids of the cells [48]. Meanwhile, because of the alteration in several enzymes involved in the metabolism of fatty acids and enhanced beta-oxidation pathway, it has been observed that fatty acid metabolism rather than glycolysis may be dominant in prostate cancer [49]. Recent studies also confirmed that the involvement of the fatty acid synthesis pathway in  $^{11}\text{C}$  acetate uptake in prostate tumors is an imaging marker for fatty acid synthesis expression [50]. Previous clinical studies with  $^{11}\text{C}$ - labeled acetate ( $^{11}\text{C}$ -ACE) have reported improved sensitivity, up to 100%, for detection of primary tumors in patients with untreated prostate cancer [51, 52]. However, the potential for widespread use of  $^{11}\text{C}$ -ACE is limited by the short radioactive half-life (20.4 min) of  $^{11}\text{C}$ . Accordingly, there is considerable interest in identifying positron-emitting radiopharmaceuticals labeled with isotopes with longer half-lives that are suitable for imaging of prostate cancer. One such radiopharmaceutical that has been studied is  $^{18}\text{F}$ -fluoroethylcholine, which also appears to be a cell membrane precursor compound [53, 54]. Another potential agent is the acetate analog  $^{18}\text{F}$ -fluoroacetate ( $^{18}\text{F}$ -FAC). Fatty acid synthesis is an important pathway in cancer cell, which requires major enzyme for converting carbohydrates to fatty acids, and the upregulation of the relevant enzyme plays a key role in tumorigenesis of the prostate in the transgenic adenocarcinoma of mouse prostate (TRAMP) model [55]. Recently, [ $^{11}\text{C}$ ]acetoacetate (**22**) has also been evaluated as a potential PET probe of ketone body use by prostate tumors [56]. It was found that PC-3 androgen-independent prostate tumors display moderated uptake of [ $^{11}\text{C}$ ] acetoacetate with rapidly decreasing background activity. Further research would be needed to determine the exact biologic relevance of imaging ketone body use to the natural history of prostate cancer and how it may be useful in a specific clinical setting.

The epidermal growth factor receptor (EGFR) is over-expressed in a variety of human cancers, including in hormone-refractory prostate carcinomas, in which the EGFR has been associated with advanced disease stage, resistance to standard treatment and poor prognosis. Therefore, the EGFR is considered to be a promising molecular target for molecular imaging and therapy for hormone-refractory prostate cancer. Fozing T reported a synthesis an EGF receptor tyrosine kinase (EGFR-TK) inhibitor,  $^{123}\text{I}$ -PD153035 (**23**) as potential imaging probes. In vitro studies of  $^{123}\text{I}$ -PD153035 was found that it accumulates highly in human PC-3 and DU-145 prostate cancer cells cooperating with  $^{123}\text{I}$ -mAb425, the  $^{123}\text{I}$  radiolabelled IgG2a antibody [57]. In vivo studies of the human prostate cancer xenografts in mouse was accurately visualized after i.v. administration of  $^{123}\text{I}$ -PD153035 by a gamma camera. These data suggest that  $^{123}\text{I}$ -PD153035 are promising candidates as an imaging probe for EGFR- positive prostate cancer and warrant further in vivo validations to ascertain their potential as imaging agents for clinical used. Another radiolabeled bombesin (a target molecular with high affinity for GRP receptors) analogues was synthesized and



assessed for SPECT ( $^{111}\text{In}$  label) and PET ( $^{64}\text{Cu}$  or  $^{18}\text{F}$  label) visualization of prostate cancer [58, 59]. However, imaging of the GRP receptor is being under the further investigation to determine whether it is useful or not in clinical trial for prostate cancer.

In relation to tumor angiogenesis, the vascular endothelial growth factor (VEGF) signaling pathway and the integrin  $\alpha\text{v}\beta3$  (a cell adhesion molecule) have been identified to play key roles. Molecular imaging of these targets in the tumor vasculature may help tailor targeted antiangiogenic therapy [60]. Some of PET probes suitable for integrin receptor imaging have been reported, and have shown high specificity in various types of tumors, including prostate cancer models [61]. Active research continues in identifying more specific biologic markers for interrogating the tumor vessels. These investigations will not only shed more light on the biologic basis of the complex signals involved in malignancy-induced angiogenesis, but may also help facilitate the design and image-based testing of drugs targeted to tumor-specific angiogenesis.



Scheme 4. Other small molecular imaging probes for prostate cancer.

## 5. Conclusion

Molecular imaging probes represent an important, growing class of chemical compounds for biology, pharmaceutical sciences, preclinic and clinic studies and further application. In conjunction with the imaging modality (such as PET, SPECT, MRI and etc), the identification of molecular imaging targets and the development of new labeled molecular probes for those targets are crucial for expanding the capability of in vivo molecular imaging for biological research, molecular diagnostics and drug discovery. In the post genomics era, there is the opportunity to advance probes to the point where they can target specific biochemical signatures associated with disease, including prostate cancer. Because changes in biochemistry occur before diseases reach an advanced stage, molecular imaging probes will foster earlier and more personalized diagnosis of disease. Herein, the abilities of various probes to assess different functional and molecular characteristics for prostate

cancer are being explored and reviewed. The advantages and limitations of imaging agents for prostate cancer were outlined in Table 1.

Table 1. Advantages and limitations of probes used in clinical and preclinical trials for prostate cancer.

Probes for prostate cancer	Advantages	Limitations	Reference
1	fast tumor uptake, prolonged retention of radioactivity	rapid metabolic rate, not sensitive enough	21, 22, 23
2, 3, 4	stability, easy for <sup>11</sup> C label, high affinity	instability of the <sup>11</sup> C labeled precursor, low radiolabeled yield	24
13, 14, 15	easy for synthesization, specificity, multi-labeled methods	not specific enough (mouse kidneys, also express PSMA)	31, 33, 34, 35, 36,
17	clinical use, safety	not sensitive enough, low cellular uptake	39, 40, 41
18, 19	clinical use, high uptake	short physical half-life of positron-emitting radionuclide (19)	51, 52
20, 21	clinical use, high sensitivity and specificity, suitable for PET (20)	short physical half-life of positron-emitting radionuclide (21)	53, 54

## 6. Perspective

Currently, imaging probes for prostate cancer are focused on the construction that yield an increased selectivity and sensitiveness of measurements per examination, thus higher resolution and quantification accuracy is required. Due to the complication of case difference and personalized conditions, more accurate and more efficient forward and inversion problems for improving the quantification accuracy will be speed up. The design, synthesis and application of dual- and multi-modality probe will be a hot research area, which may be the next generation of probe. The combination of different functional modality undoubtedly will improve the accuracy of diagnosis and analysis to prostate cancer. On the other hand, a targeted gene-therapy approach is also being developed to activate the immune system to recognize prostate cancer cells. To discovery probes based on labeled gene and related macromolecule and these types of approaches might provide a new direction of prostate cancer therapies. We believe that such imaging probes will play a vital role in our further understanding of prostate cancer, in early detection and in the design of effective treatments.

## 7. Acknowledgement

We thank the financial supports from National Natural Foundation Science of China (30900377), Program of New Century Excellent Talents in University (NCET-09-0800), and the Fundamental Research Funds for the Central Universities.

## 8. References

- [1] Adams J. The case of scirrhus of the prostate gland with corresponding affliction of the lymphatic glands in the lumbar region and in the pelvis. *Lancet*, 1853, 1, 393.
- [2] Greenlee RT, Hill-Harmon MB, Murray T, and Thun M. Cancer statistics, 2001. *CA Cancer J. Clin.*, 2001, 51, 15-36.
- [3] Denmeade SR, and Isaacs JT. A history of prostate cancer treatment. *Nat. Rev. Cancer*, 2002, 2, 389-396.
- [4] Leach F. Targeting prostate-specific membrane antigen in cancer therapy: can molecular medicine be brought to the surface? *Cancer Biol. Ther.*, 2004, 3, 559-560.
- [5] Jemal A, Bray F, Center MM, Ferlay J, Ward E, and Forman D. Global cancer statistics. *CA Cancer J. Clin.*, 2011, 61, 69-90.
- [6] Djulbegovic M, Beyth RJ, Neuberger MM, Stoffs TL, Vieweg J, Djulbegovic B, and Dahm P. Screening for prostate cancer: systematic review and meta-analysis of randomised controlled trials. *Bri. Med. J.*, 2010, 341, c4543.
- [7] Isaacs WB, Xu J, and Walsh PC. Prostate cancer: biology, genetics and the new therapeutics (eds Chung L, Isaacs W, and Simons J), Humana, Totowa, New Jersey, 2001, 13-28.
- [8] Denmeade SR, and Isaacs JT. Development of prostate cancer treatment: the good news. *The Prostate*, 2004, 58, 211-224.
- [9] Weissleder R. Molecular imaging in cancer. *Science*, 2006, 312, 1168-1171.
- [10] Herschman HR. Molecular imaging: looking at problems seeing solutions. *Science*, 2003, 302, 605-608.
- [11] Zeng W, and Miao W. Development of small molecular probes for the molecular imaging of apoptosis. *Anti-Cancer Agents in Med. Chem.*, 2009, 9, 986-995.
- [12] Huang J, Zeng W, Zhou M, and Gao F. Progress of the dual-modality probes for molecular imaging. *Acta Biophys. Sinica*, 2011, 27, 301-311.
- [13] Fenton MA, Shuster TD, Fertig AM, Taplin ME, Kolvenbag G, Bubley GJ, and Balk SP. Functional characterization of mutant androgen receptors from androgen-independent prostate cancer. *Clin. Cancer Res.*, 1997, 3, 1383-1388.
- [14] Craft N, and Sawyers CL. Mechanistic concepts in androgen-dependence of prostate cancer. *Cancer Met. Rev.*, 1998, 17, 421-427.
- [15] Jadvar H. Molecular imaging of prostate cancer: a concise synopsis. *Mol. Imaging*, 2009, 8, 56-64.
- [16] He Y, Yin DG, Perera MA, Kirkovsky L, Stourman N, and Li W. Novel ligands with high binding affinity and potent functional activity for the androgen receptor. *Eur. J. Med. Chem.*, 2002, 37, 619-634.
- [17] Dalton JT, Mukherjee A, Zhu Z, Kirkovsky L, and Miller DD. Discovery of nonsteroidal androgens. *Biochem. Biophys. Res. Commun.*, 1998, 244, 1-4.

- [18] Zanzonico P, Finn R, Pentlow KS, Erdi Y, Beattie B, Akhurst T, Squire O, Morris M, Scher H, McCarthy T, Welch M, Larson SM, and Humm JL. PET-based radiation dosimetry in man of 18F-fluorodihydrotestosterone, a new radiotracer for imaging prostate cancer. *J. Nucl. Med.*, 2004, 45, 1966-1971.
- [19] Zanzonico P. Prostate cancer: 16 $\beta$ -[18F] fluoro-5 $\alpha$ -dihydrotestosterone (FDHT) whole-body positron emission tomography. *Methods of Cancer Diagnosis, Therapy and Prognosis*, 2008, Volume 2, III, 521-530.
- [20] Bonasera TA, O'Neil JP, Xu M, Dobkin JA, Cutler PD, Lich LL, Choe YS, Katzenellenbogen JA, and Welch MJ. Preclinical evaluation of fluorine-18-labeled androgen receptor ligands in baboons. *J. Nucl. Med.*, 1996, 37, 1009 -1015.
- [21] Larson SM, Morris M, Gunther I, Beattie B, Humm JL, and Akhurst TA. Tumor localization of 16h-18F-fluoro-5 $\alpha$ -dihydrotestosterone versus 18F-FDG in patients with progressive, metastatic prostate cancer. *J. Nucl. Med.*, 2004, 45, 366-373.
- [22] Zanzonico PB, Finn R, Pentlow KS, Erdi Y, Beattie B, and Akhurst T. PET-based radiation dosimetry in man of 18F-fluorodihydrotestosterone, a new radiotracer for imaging prostate cancer. *J. Nucl. Med.*, 2004, 45, 1966- 1971.
- [23] Dehdashti F, Joel P, Michalski JM, Dence CS, Siegel BA, and Katzenellenbogen JA. Positron tomographic assessment of androgen receptors in prostatic carcinoma. *Eur. J. Nucl. Med. Mol. Imag.*, 2005, 32, 344-350.
- [24] Jacobson O, Laky D, Carlson KE, Elgavish S, Gozin M, Even-Sapir E, Leibovitch I, Gutman M, Chisin R, Katzenellenbogen JA, and Mishani E. Chiral dimethylamine flutamide derivatives--modeling, synthesis, androgen receptor affinities and carbon-11 labeling. *Nucl. Med. Biol.*, 2006, 33, 695-704.
- [25] Jacobson O, Bechor Y, Icar A, Novak N, Birman A, Marom H, Fadeeva L, Golan E, Leibovitch I, Gutman M, Even-Sapir E, Chisin R, Gozin M, and Mishani E. Prostate cancer PET bioprobes: synthesis of [18F]-radiolabeled hydroxyflutamide derivatives. *Bioorg. Med. Chem.*, 2005, 13, 6195-6205.
- [26] Parent EE, Dence CS, Jenks C, Sharp TL, Welch M, and Katzenellenbogen JA. Synthesis and biological evaluation of [18F]bicalutamide, 4-[76Br]bromobicalutamide, and 4-[76Br]-bromo-thiobicalutamide as nonsteroidal androgens for prostate cancer imaging. *J. Med. Chem.*, 2007, 50, 1028-1040.
- [27] He H, Morely JE, Silva-Lopez E, Bottenus B, Montajano M, Fugate GA, Twamley B, and Benny PD. Synthesis and characterization of nonsteroidal-linked M(CO)<sub>3</sub><sup>+</sup> (M = <sup>99m</sup>Tc, Re) compounds based on the androgen receptor targeting molecule flutamide. *Bioconjugate Chem.*, 2009, 20, 78-86.
- [28] Marom H, Miller K, Bechor-Bar Y, Tsarfaty G, Satchi-Fainaro R, and Gozin M. Toward development of targeted nonsteroidal antiandrogen-1,4,7,10-tetraazacyclododecane-1,4,7,10-tetraacetic acid-gadolinium complex for prostate cancer diagnostics. *J. Med. Chem.*, 2010, 53, 6316-6325.
- [29] Lofters A, Juffs HG, Pond GR, and Tannock IF. "PSA-itis": knowledge of serum prostate specific antigen and other causes of anxiety in men with metastatic prostate cancer. *J. Urol.*, 2002, 168, 2516-2520.
- [30] Dreicer R. Metastatic prostate cancer: assessment of response to systemic therapy. *Semin. Urol. Oncol.*, 1997, 15, 28-32.


- [31] Gregor PD, Wolchok JD, Turaga V. Induction of autoantibodies to syngeneic prostate-specific membrane antigen by xenogeneic vaccination. *Int. J. Cancer.*, 2005, 116, 415–421.
- [32] O'Keefe DS, Bacich DJ, and Heston WD. Comparative analysis of prostate-specific membrane antigen (PSMA) versus a prostate-specific membrane antigen-like gene. *The Prostate*, 2004, 58, 200–210.
- [33] Fair WR, Israeli RS, and Heston WD. Prostate-specific membrane antigen. *The Prostate*, 1997, 32, 140–148.
- [34] Foss CA, Mease RC, Fan H, Wang Y, Ravert HT, Dannals RF, Olszewski RT, Heston WD, Kozikowski AP, and Pomper MG. Radiolabeled small-molecule ligands for prostate-specific membrane antigen: in vivo imaging in experimental models of prostate cancer. *Clin. Cancer Res.*, 2005, 11, 4022–4028.
- [35] Banerjee SR, Foss CA, Castanares M, Mease RC, Byun Y, Fox JJ, Hilton J, Lupold SE, Kozikowski AP, and Pomper MG. Synthesis and evaluation of technetium-99m- and rhenium-labeled inhibitors of the prostate-specific membrane antigen (PSMA). *J. Med. Chem.*, 2008, 51, 4504–4517.
- [36] Mease RC, Dusich CL, Foss CA, Ravert HT, Dannals RF, Seidel J, Prideaux A, Fox JJ, Sgouros G, Kozikowski AP, and Pomper MG. N-[N-[(S)-1,3-Dicarboxypropyl]carbamoyl]-4-[18F]fluorobenzyl-L-cysteine, [18F]DCFBC: a new imaging probe for prostate cancer. *Clin. Cancer Res.*, 2008, 14, 3036–3043.
- [37] Serda RE, Adolphi NL, Bisoffi M, and Sillerud LO. Targeting and cellular trafficking of magnetic nanoparticles for prostate cancer imaging. *Mol. Imaging*, 2007, 6, 277–288.
- [38] Chen Y, Dhara S, Banerjee SR, Byun Y, Pullambhatla M, Mease RC, and Pomper MG. A low molecular weight PSMA-based fluorescent imaging agent for cancer. *Biochem. Biophys. Res. Commun.*, 2009, 390, 624–629.
- [39] Effert PJ, Bares R, Handt S, Wolff JM, Bull D, and Jakes G. Metabolic imaging of untreated prostate cancer by positron emission tomography with 18-fluorinelabeled deoxyglucose. *J. Urol.*, 1996, 155, 994–998.
- [40] Oyama N, Akino H, Suzuki Y, Kanamaru H, Ishida H, Tanase K, Sadato N, Yonekura Y, and Okada K. FDG PET for evaluating the change of glucose metabolism in prostate cancer after androgen ablation. *Nucl. Med. Commun.*, 2001, 22, 963–969.
- [41] Shreve PD, Grossmann HB, Gross MD, and Wahl RL. Metastatic prostate cancer: initial findings of PET with 2-deoxy-2-[F-18]-fluoro-D-glucose. *Radiology*, 1996, 199, 751–756.
- [42] Mathupala SP, Ko YH, and Pederson PL. Hexokinase II: cancer's double-edged sword acting as both facilitator and gatekeeper of malignancy when bound to mitochondria. *Oncogene*, 2006, 25, 4777–4786.
- [43] Smith TA. Mammalian hexokinases and their abnormal expression in cancer. *Br. J. Biomed. Sci.*, 2000, 57, 170–178.
- [44] Effert P, Beniers AJ, Tamimi Y, Handt S, and Jakse G. Expression of glucose transporter 1 (GLUT-1) in cell lines and clinical specimen from human prostate adenocarcinoma. *Anticancer Res.*, 2004, 24, 3057–3063.
- [45] Chandler JD, Williams ED, Slavin JL, Best JD, and Rogers S. Expression and localization of GLUT1 and GLUT12 in prostate carcinoma. *Cancer*, 2003, 97, 2035–2042.

- [46] Ponde DE, Dence CS, Oyama N, Kim J, Tai YC, Laforest R, Siegel BA, and Welch MJ. 18F-Fluoroacetate: a potential acetate analog for prostate tumors imaging-in vivo evaluation of 18F-fluoroacetate versus 11C-acetate. *J. Nucl. Med.*, 2007, 48, 420–428.
- [47] DeGrado TR, Coleman RE, Wang S, Baldwin SW, Orr MD, Robertson CN, Polascik TJ, and Price DT. Synthesis and evaluation of 18F-labeled choline as an oncologic tracer for positron emission tomography: initial findings in prostate cancer. *Cancer Res.*, 2001, 61, 110–117.
- [48] Shreve PD, Lannone P, and Weinhold P. Cellular metabolism of [1-C14]-acetate in prostate cancer cells in vitro. *J. Nucl. Med.*, 2002, 43, S272.
- [49] Liu Y. Fatty acid oxidation is a dominant bioenergetic pathway in prostate cancer. *Prostate Cancer Prostatic Dis.*, 2006, 9, 230–234.
- [50] Vavere AL, Kridel SJ, Wheeler FB, and Lewis JS. 1-11C-Acetate as a PET radiopharmaceutical for imaging fatty acid synthase expression in prostate cancer. *J. Nucl. Med.*, 2008, 49, 327–334.
- [51] Oyama N, Akino H, and Kanamaru H. 11C-Acetate PET imaging of prostate cancer. *J. Nucl. Med.*, 2002, 43, 181–186.
- [52] Kotzerke J, Volkmer BG, Neumaier B, Gschwend JE, Hautmann RE, and Reske SN. Carbon-11 acetate positron emission tomography can detect local recurrence of prostate cancer. *Eur. J. Nucl. Med. Mol. Imaging.*, 2002, 29, 1380–1384.
- [53] DeGrado TR, Baldwin SW, Wang S, Orr MD, Liao RP, Friedman HS, Reiman R, Price DT, and Coleman RE. Synthesis and evaluation of 18F-labeled ncholine analogs as oncologic PET tracers. *J. Nucl. Med.*, 2001, 42, 1805–1814.
- [54] Hara T, Kosaka N, and Kishi H. PET imaging of prostate cancer using carbon-11-choline. *J. Nucl. Med.*, 1998, 39, 990–995.
- [55] Pflug BR, Pecher SM, Brink AW, Nelson JB, and Foster BA. Increased fatty acid synthase expression and activity during progression of prostate cancer in the TRAMP model. *The Prostate*, 2003, 57, 245–254.
- [56] Authier S, Tremblay S, Dumulon V, et al Authier S, Tremblay S, Dumulon V, Dubuc C, Ouellet R, Lecomte R, Cunnane SC, and Benard F. [11C]Acetoacetate utilization by breast and prostate tumors: a PET and biodistribution study in mice. *Mol. Imaging Biol.*, 2008, 10, 217–223.
- [57] Fozing T, Scheuer C, and Samnick S. Synthesis and initial tumor affinity testing of iodine-123 labelled EGFR-affine agents as potential imaging probes for hormone-refractory prostate cancer. *Eur. J. Med. Chem.*, 2010, 45, 3780–3786.
- [58] De Visser M, Bernard HF, Erion JL, Schmidt MA, Srinivasan A, Waser B, Reubi JC, Krenning EP, and de Jong M. Novel 111In-labeled bombesin analogues for molecular imaging of prostate tumors. *Eur. J. Nucl. Med. Mol. Imaging*, 2007, 34, 1228–1238.
- [59] Zhang X, Cai W, Cao F, Schreibmann E, Wu Y, Wu JC, Xing L, and Chen X. 18F-Labeled bombesin analogs for targeting GRP receptorexpressing prostate cancer. *J. Nucl. Med.*, 2006, 47, 492–501.
- [60] Cai W, and Chen X. Multimodality molecular imaging of tumor angiogenesis. *J. Nucl. Med.*, 2008, 49, 113S–128S.

- [61] Zhang X, Xiong Z, Wu Y, Cai W, Tseng JR, Gambhir SS, and Chen X. Quantitative PET imaging of tumor integrin  $\alpha v \beta 3$  expression with  $^{18}\text{F}$ -FRGD2. *J. Nucl. Med.*, 2006, 47, 113-121.

IntechOpen

IntechOpen



### **Molecular Imaging**

Edited by Prof. Bernhard Schaller

ISBN 978-953-51-0359-2

Hard cover, 390 pages

**Publisher** InTech

**Published online** 16, March, 2012

**Published in print edition** March, 2012

The present book gives an exceptional overview of molecular imaging. Practical approach represents the red thread through the whole book, covering at the same time detailed background information that goes very deep into molecular as well as cellular level. Ideas how molecular imaging will develop in the near future present a special delicacy. This should be of special interest as the contributors are members of leading research groups from all over the world.

#### **How to reference**

In order to correctly reference this scholarly work, feel free to copy and paste the following:

Wenbin Zeng, Zhiguo Liu and Wei Wang (2012). Recent Development and Trends in Molecular Imaging Probes for Prostate Cancer, Molecular Imaging, Prof. Bernhard Schaller (Ed.), ISBN: 978-953-51-0359-2, InTech, Available from: <http://www.intechopen.com/books/molecular-imaging/recent-development-and-trends-in-molecular-imaging-probes-for-prostate-cancer>

**INTECH**  
open science | open minds

#### **InTech Europe**

University Campus STeP Ri  
Slavka Krautzeka 83/A  
51000 Rijeka, Croatia  
Phone: +385 (51) 770 447  
Fax: +385 (51) 686 166  
[www.intechopen.com](http://www.intechopen.com)

#### **InTech China**

Unit 405, Office Block, Hotel Equatorial Shanghai  
No.65, Yan An Road (West), Shanghai, 200040, China  
中国上海市延安西路65号上海国际贵都大饭店办公楼405单元  
Phone: +86-21-62489820  
Fax: +86-21-62489821



© 2012 The Author(s). Licensee IntechOpen. This is an open access article distributed under the terms of the [Creative Commons Attribution 3.0 License](#), which permits unrestricted use, distribution, and reproduction in any medium, provided the original work is properly cited.

IntechOpen

IntechOpen