

We are IntechOpen, the world's leading publisher of Open Access books Built by scientists, for scientists

4,800

Open access books available

122,000

International authors and editors

135M

Downloads

Our authors are among the

154

Countries delivered to

TOP 1%

most cited scientists

12.2%

Contributors from top 500 universities



WEB OF SCIENCE™

Selection of our books indexed in the Book Citation Index
in Web of Science™ Core Collection (BKCI)

Interested in publishing with us?
Contact book.department@intechopen.com

Numbers displayed above are based on latest data collected.

For more information visit www.intechopen.com



Transmissible Spongiform Encephalopathies

Glaucia N. M. Hajj, Tiago G. Santos,
Michele C. Landemberger and Marilene H. Lopes
*International Center for Research and Education,
A.C. Camargo Hospital, Antonio Prudente Foundation, São Paulo
Brazil*

This chapter is dedicated to the loving memory of Prof. Ricardo Renzo Brentani, a brilliant scientist, a source of inspiration for younger generations and a wonderful man.

1. Introduction

1.1 Neurodegenerative disorders and transmissible spongiform encephalopathies

Neuronal death represents the primary pathology of neurodegenerative diseases such as Alzheimer's and Parkinson's disease and Amyotrophic Lateral Sclerosis. These diseases usually present with a slow onset and a chronic progression. Various regions of the brain, spinal cord, or peripheral nerves may be affected, leading to functional impairment and neuron loss. Neurodegenerative diseases are often categorized by symptoms that may include impairment in cognition, movement, strength, coordination, sensation, or autonomic control. However, the diagnosis of a specific neurodegenerative disease may be misleading, as there is both clinical and neuropathologic overlap among diseases and existing diagnostic tools are not always accurate. For most neurodegenerative diseases, neuronal dysfunction, such as synaptic loss, may occur long before neuronal death takes place (Soto, 2003;Shastry, 2003;Aguzzi and O'Connor, 2010).

A group of neurodegenerative diseases called protein conformational disorders includes relatively common diseases as well as some rare inherited disorders that involve the deposition of protein aggregates in the brain, leading to the selective loss of neurons in an age-dependent manner. The protein conformational disorders include Alzheimer's disease (AD), Parkinson's disease (PD), Huntington's disease (HD), as well as polyglutamine disorders that include several forms of spinocerebellar ataxia, amyotrophic lateral sclerosis, and the transmissible spongiform encephalopathies (TSEs), also referred to as prion diseases (Table 1). These disorders affect a diverse neuronal population in discrete regions of the brain. Until recently, there were no molecular mechanisms known to be shared by all these diseases. However, accumulating evidence implicates protein misfolding and aggregation as a likely common underlying cause (Soto, 2003;Shastry, 2003;Aguzzi and O'Connor, 2010).

Correct cell maintenance depends upon the activity of proteins, whose function relies upon their three-dimensional structure. However, some proteins can also fold into stable alternative conformations that result in their aggregation and accumulation as fibrillar deposits. Although these deposits have similar morphological, structural, and staining/immunoreactivity characteristics, protein deposits found on different diseases may

also have distinct biochemical or biological features. The precise causes of abnormal folding and accumulation of proteins are not understood. There is currently considerable debate regarding the toxic versus neuroprotective effect of aggregates, and whether small soluble oligomers of the same proteins, may represent the toxic entities (Aguzzi and O'Connor, 2010;Shastry, 2003;Soto, 2003).

The rarest, yet the most intriguing, of these protein conformational disorders are the TSEs or prion diseases. This group of diseases includes Creutzfeldt-Jakob disease (CJD), kuru, fatal familial insomnia (FFI), and Gerstmann-Straussler-Scheinker syndrome (GSS) in humans, scrapie in sheep, bovine spongiform encephalopathy (BSE) in cattle, and chronic wasting disease in cervids (Soto, 2003;Shastry, 2003;Aguzzi and O'Connor, 2010;Aguzzi et al., 2001;Aguzzi and Polymenidou, 2004;Gibbs, Jr. et al., 1968;Masters et al., 1981;Medori et al., 1992a;Medori et al., 1992b).

Diseases	Clinical Features	Structures affected	Likely cause
Alzheimer's disease	Progressive dementia	Hippocampus, cerebral cortex	Amyloid deposits
Amyotrophic lateral sclerosis	Movement disorder	Motor cortex, brainstem	Superoxide dismutase/ TDP-43 deposits
Charcot Marie Tooth	Muscular weakness	PNS	Axonal degeneration / demyelination
Corticobasal degeneration	Impairment on cognition and movement	cerebral cortex and the basal ganglia	Unknown
Dementia with Lewy bodies	Impairment on cognition and movement	Cerebral cortex	Lewy bodies - deposits of synuclein and ubiquitin
Friedreich's ataxia	Coordination problems	Spinal cord and peripheral nerves	Mutation in Frataxin gene
Huntington's disease	Dementia, motor and psychiatric problems	Striatum, cerebral cortex	Huntingtin deposits
Multiple Sclerosis	sensory disturbance, visual loss, motor dysfunction	spinal cord and optic nerves	Demyelination
Parkinson's disease	Movement disorder	Substantia nigra, hypothalamus	Synuclein deposits
Pick's disease	behavior changes, speech difficulty, and impaired thinking	frontal lobes	Pick bodies, accumulation of Tau
Prion disorders	Dementia, ataxia, or psychiatric or insomnia problems	Various regions depending on the disease	Prion protein deposits
Progressive supranuclear palsy	Impairment on cognition and movement	most areas of the brain and in some parts of the spinal cord	unknown
Polyglutamine Diseases/ Spinocerebellar ataxia	Coordination Problems	Cerebellum/ spinal cord	Accumulation of proteins (ataxins) presenting poly-Q repeats

Table 1. Brief list of well characterized neurodegenerative diseases (not inclusive, and diseases can present in ways in which they have not been listed). Protein conformational disorders are highlighted in bold. PNS = peripheral nervous system.

The most unique feature of the prion diseases is that they present both hereditary and transmissible forms and, as we will present further in this chapter, the identification of proteins as transmissible disease agents represents a breakthrough in the concepts of modern biology. Prion diseases are generally characterized by the aggregation of prions, also referred to PrP^{Sc}, into large plaques that are associated with the rapid loss of neurons in specific areas of the brain and corresponds to the onset of neurological and behavioral symptoms. The PrP^{Sc} protein is the abnormal isoform of the cellular prion protein (PrP^C) that is normally present in all tissues of the body and whose expression is particularly high in neurons. A change in the three-dimensional structure of PrP^C renders it into the highly insoluble PrP^{Sc}, which is resistant to degradation and proteinase digestion. The presence of PrP^{Sc} can alter the conformation of PrP^C in the cell, thus making it a productive infection. The unusual properties of prion propagation have presented challenges to researchers seeking to understand the pathogenic mechanisms of these diseases and have slowed the development of effective diagnostic tools and therapeutic strategies (Soto, 2003; Shastry, 2003; Aguzzi and O'Connor, 2010).

This chapter will focus on human prion disorders, their history, etiology, symptoms, and the therapeutic strategies tried so far. Instead of a comprehensive review of the abundant prion literature, our goal here is to present a general view of the mechanism of these diseases for the lay public, complemented by a list of references that will enable additional study for those who wish to further explore the mysteries of prions.

2. A historic overview

This section will present a historic view of the TSEs, from the early descriptions of scrapie, the prototypic prion disease that affects sheep and goats and which has been a concern since the 18th century, to kuru, an endemic form of human TSE that was transmitted via cannibalistic rituals among the aborigines of Papua New Guinea throughout the 1950s and 1960s. We will also discuss the transmission of prions via contaminated meat that resulted in patients who contracted a new variant of Creutzfeldt-Jakob disease and led to one of the largest catastrophes in the history of medicine.

2.1 From scrapie to kuru – The discovery of infectious prions

The disease named scrapie affects sheep and has been a matter of concern since the 18th century, mystifying farmers and negatively impacting local economies (Aguzzi, 2006). The name “scrapie” originates from the behavior of compulsive rubbing and scraping against fixed objects observed in affected sheep. Scrapie could be found in many countries of Europe, such as France, in which is called tremblante (trembling), Spain (Basquilla disease), Germany (traberkrankheit – trotting disease), and Iceland (rida – tremor) amongst others, in addition to regions in Asia such as India and the Himalayas (Khujali or Mokoo) (Schneider et al., 2008; Prusiner, 1999).

Early descriptions of scrapie date back to the 17th century (Adams, 1975) or earlier, possibly including explicit references by agricultural writers at the time of the Romans (Schneider et al., 2008). The symptoms of scrapie are characterized by progressive ataxia, particularly in the hind limbs, and collapse. The disease typically affects sheep around

four years of age and progresses rapidly, within weeks to months, to death of the animal (Adams, 1975). Naturally infected sheep may have an asymptomatic incubation period that varies from three to five years, during which there is no febrile phase or alterations in cerebrospinal fluid composition. The lesions of scrapie are limited to the central nervous system (CNS) and are concentrated in the cerebellum, where widespread neuronal degeneration and the prominent hypertrophy and proliferation of astrocytes are typical features (Adams, 1975).

Different theories have emerged during the 20th century regarding the nature of the etiological agent of scrapie, and a “slow-virus” hypothesis was predominant until the revolutionary “protein-only” proposal that suggested that scrapie could spread in the absence of DNA (Schneider et al., 2008; Prusiner, 1999; Griffith, 1967). Experiments in sheep demonstrating a lengthy incubation period enabled the proposal of the “slow-virus” hypothesis. The unknown agent presented some viral features, such as the ability to spread and cause disease in other sheep indefinitely. In addition, the infectious agent could be filtered and appeared to be self-replicating. Moreover, this agent had been detected in most tissues including brain, spinal cord, pituitary gland, adrenal gland, salivary glands, spleen, liver, and lymphatic glands (Schneider et al., 2008).

However, the initial experimental studies did not show evidence of the agent being present and active in tissue culture models or detectable via serology or electron microscopy (Adams, 1975). In these studies, the scrapie agent puzzled investigators with properties that challenged the current knowledge regarding viruses, such as its remarkable resistance to a number of physical and chemical treatments that destroy conventional viruses.

The possibility that the scrapie agent did not contain nucleic acids suggested that a hitherto unrecognized agent could be involved in this disease (Adams, 1975). In agreement with these findings, early evidence of an unconventional transmission of scrapie arose accidentally in 1930's in Scotland. In an attempt to vaccinate sheep against infectious encephalomyelitis caused by a virus (looping-ill virus), the animals received inoculums derived from the brain and spleen of affected animals that had been treated with formalin. The tissues used to produce the “inactivated virus” were, in fact, contaminated with scrapie, which caused the disease in a fraction of the animals that received the inoculum, suggesting that the agent involved in this disease was resistant to formalin treatment (Prusiner, 1999; Gordon, 1946).

Following the findings of experimental transmission of scrapie in sheep, little progress in the field was made until Carleton Gajdusek demonstrated that kuru, a human disease responsible for a high mortality in the Fore people from Papua, New Guinea, was a transmissible spongiform encephalopathy.

This story begins in 1955, after an invitation made by Vincent Zigas, a physician of the Fore region, to his colleague Carleton Gajdusek, who had a strong background in microbiology, to help understanding the increasing incidence of a strange disease the aborigines called kuru. At that time, approximately 10% of the Fore people were dying of kuru each year, and women and children were particularly affected (Zetterstrom, 2010) (Figure 1).

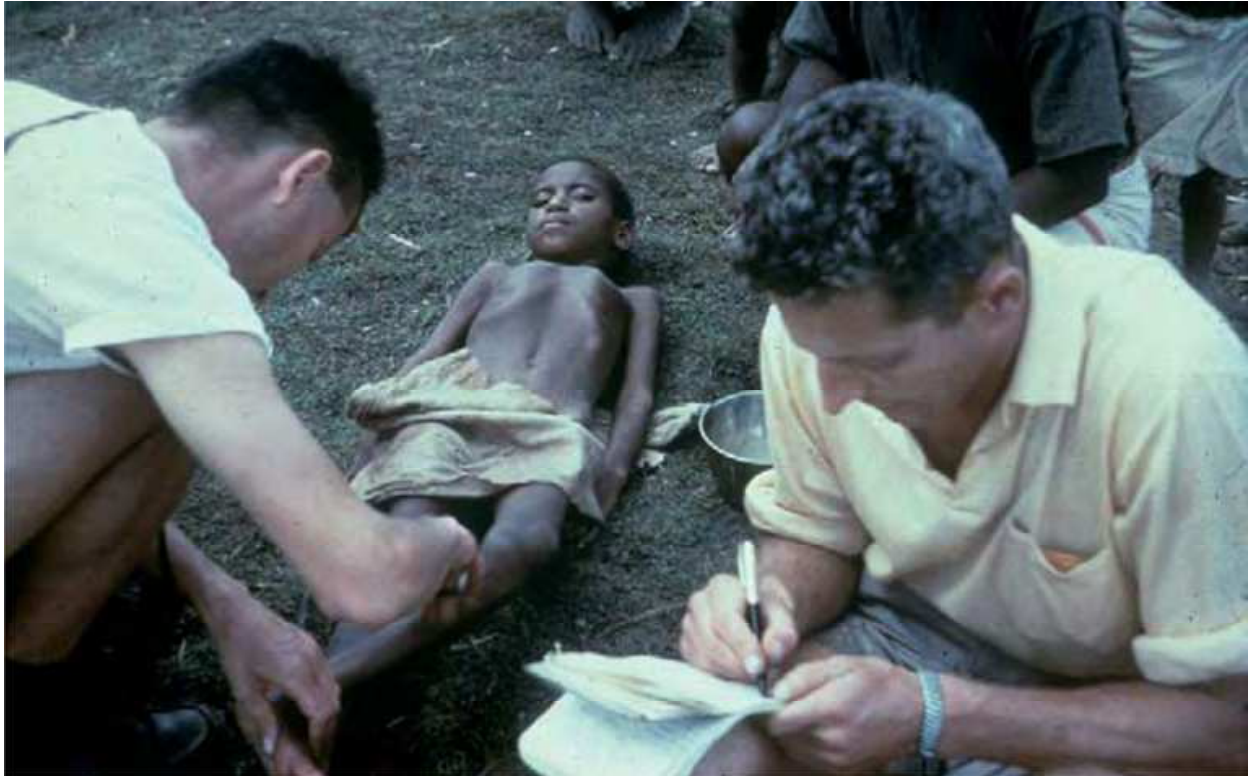

Fig. 1. Dr Carleton Gajdusek (left) and Dr Vincent Zigas study a child patient with kuru at Okapa in 1957. Reproduced with permission from Gajdusek in: *Phil. Trans. R. Soc. B* (2008) 363, 3636–3643 (Gajdusek, 2008).

Gajdusek and Zigas first described the clinical symptoms of kuru (the name means shivering or trembling in the Fore language) in 1957 (Zetterstrom, 2010). They described the disease as subacute and characterized by progressive cerebellar ataxia manifesting as athetoid movements that progresses to complete motor incapacity and, although cognition was generally unaffected, kuru was invariably fatal, patients typically died within 3–9 months after disease onset (Gajdusek and Zigas, 1957). However, the clinical and epidemiological profiles suggested that this was indeed a peculiar disease, as brains autopsies showed spongiform encephalopathy, suggesting that, like scrapie, kuru was an infectious disease (Gajdusek and Zigas, 1959; Zetterstrom, 2010; Harper, 1977).

A genetic explanation was initially proposed based in the apparent restriction of the disease to a particular tribal group and the remarkable familial clustering, with vertical transmission from generation to another (Harper, 1977). The elucidation of the causative factors of kuru came from the elegant experimental approaches and epidemiological studies carried out by Gajdusek and others (Harper, 1977; Zetterstrom, 2010). They demonstrated that ritual cannibalism of the brain and other parts of deceased relatives, practiced by the family, particularly by women and children, as an act of mourning and respect, provided the clue to the discovery that consumption of kuru-contaminated tissue was the means of transmitting the disease (Gajdusek, 1977). These findings led to the successful transmission of the disease to chimpanzees by the intracerebral inoculation of brain tissue from kuru patients (Harper, 1977; Gajdusek et al., 1966).

As in scrapie, the infectious agent of kuru accumulated in great quantities in the brain and did not have the features of a typical viral pathogen. These observations led Gajdusek to speculate that an unconventional type of virus might be the etiological agent of kuru, and this view was supported by the experimental transmission of kuru, scrapie and also Creutzfeldt-Jakob disease to chimpanzees during the 1960s and 1970s (Gajdusek et al., 1966).

These findings led to a new vision of the etiology of various neurodegenerative diseases, which garnered Gajdusek the Nobel Prize in 1976 (Zetterstrom, 2010). However, the “protein only” hypothesis came from the mind of J. S. Griffith, a mathematician (Griffith, 1967). He presented different models of transmission solely by protein particles with the ability to modify native proteins. The term “prion” was introduced in 1982 by Stanley Prusiner to describe an infectious proteinaceous particle (Prusiner, 1982).

The elucidation of the true chemical nature of prions occurred in the 1980s, following the isolation of infectious material from affected brains of Syrian hamsters (Bolton et al., 1982). This material was highly insoluble, with characteristics typical of amyloid aggregates (Prusiner et al., 1983), and was resistant to treatments that inactivate nucleic acid activity. Conversely, the infectious ability of prions was completely abrogated by moieties that modify protein activity and structure, such as proteases and detergents, strengthening the concept of the prion being an infectious “protein-only” agent. The isolation of prions permitted the characterization of a native protein synthesized by the host genome, termed the cellular prion protein (Oesch et al., 1985; Meyer et al., 1986). To characterize the infectious agent of transmissible spongiform encephalopathies, the prion protein gene was cloned from host cells by Dr. Prusiner, who went on to discover that changes in the three-dimensional structure of the native prion protein was the cause of these disorders. For this work, Dr. Prusiner was awarded the Nobel Prize in 1998 (Schneider et al., 2008).

The importance of these findings extended far beyond simply elucidating the means of transmission of a disease; they have broken a biology dogma that stated that information passing from one organism to another must be mediated by nucleic acids. From the discovery of prions, scientists knew that proteins were also able to transmit information from one organism to another.

2.2 The BSE epidemic and transmission to humans

Coincident with the period in which the elucidation prion biology was the focus of TSE studies came the “mad-cow disease.” In the mid-1980s, an epidemic of bovine spongiform encephalopathy (BSE; commonly known as mad-cow disease) had a major impact on the human health policies as well as the economies of Europe, particularly the United Kingdom (UK), and Canada (Tyrrell and Taylor, 1996; Prusiner, 1999). In the UK, the incidence of BSE in cattle peaked at 370,000 cases in 1992, and has steadily diminished since (Zetterstrom, 2010). The incubation period of BSE varies from 2 to 8 years and thus affects adult cattle. Importantly, all breeds of cattle are equally susceptible to the infection (Chesebro, 2003).

Several pieces of evidence suggested that BSE was transmitted from sheep to cows via contaminated feed in the 1980’s (Stack et al., 2006; Wells and Wilesmith, 1995). The epidemic

began simultaneously at many geographic locations in England and was traced to the contamination of meat and bone meal derived from scrapie-infected sheep that was used in cattle feed. The spread of BSE was likely accelerated by the recycling of infected bovine tissues to manufacture feed, a practice halted following the recognition of BSE (Nathanson et al., 1997). The onset of the BSE epidemic was coincident with modifications in the process of extracting fat from meat and bone meal that unknowingly allowed prion particles to remain active (Wilesmith et al., 1991).

The BSE epidemic provoked much alarm in societies worldwide, as it had been associated with a new human disease, known as variant CJD (vCJD), that had been observed in individuals who had eaten infected cattle meat (Aguzzi, 2006; Aguzzi and Weissmann, 1996; Hill et al., 1997a). Despite concerns about a potential epidemic of vCJD, the total number of victims was relatively small (Valleron et al., 2001; Aguzzi, 2006). However, the risk of acquiring CJD is not limited to consumption of BSE-contaminated meat, as the transmission of prions has also been documented to occur during clinical procedures (iatrogenic transmission) (Aguzzi, 2006; Brown et al., 1992). Cases of CJD have been attributed to the transplantation of tissues or from pituitary hormone derived from deceased individuals that had unrecognized or asymptomatic TSE at the time of death. The contamination of medical instruments during neurosurgical interventions was also of concern, as patients with CJD were documented to have undergone invasive procedures, including brain biopsies (Will et al., 1999). Moreover, transmission of CJD was observed in patients submitted to depth electroencephalogram (EEG) recordings using electrodes that had previously been used in a CJD patient (Bernoulli et al., 1977). Evidence was also presented for prion transmission via human blood and derivatives; however, controversy still exists regarding the presence of CJD infectivity in human blood (Brown, 1995; Will et al., 1999).

3. Human forms of TSE

In humans, TSE has been classified into three subtypes: infectious (kuru, iatrogenic (i) CJD and variant (v) CJD), in which transmission has occurred because of human intervention, heritable familial (fCJD, GSS, and FFI) forms, and sporadic (sCJD) in which the disease cannot be linked to any of the previous forms of infection. In all three subgroups, the TSE can be transmitted to primates via ingestion or inoculation (Brown et al., 1994), thus fulfilling one of the main characteristics of TSE diseases, transmissibility.

Kuru was the first human neurodegenerative disease to be transmitted to laboratory primates (Gajdusek et al., 1966) and classified as a TSE. The most striking sign of the disease is a fine tremor of the head, trunk, and limbs that is associated with the insidious onset of ataxia. Both the ataxia and tremor become more pronounced as the disease progresses, and these signs are joined by other indicators of cerebellar pathology, as well as behavioral abnormalities (Gajdusek and Reid, 1961). Following the cessation of ritual cannibalism in the Fore people of Papua New Guinea, the incidence of kuru has steadily decreased to its current low levels (Collinge et al., 2006). The incubation period of this disease can be as long as 56 years, according to reports. Analysis of the PrP^C gene showed that most kuru patients were heterozygous for a polymorphism at codon 129 (presenting both a methionine and a valine at this position - M129V), a genotype associated with extended incubation periods and resistance to prion disease (Collinge et al., 2006).

Pathologically, kuru is characterized by a mild to moderate degree of neuronal vacuolation, an intense astrocytic gliosis, cerebellar degeneration, and the presence of numerous amyloid plaques that tend to be most common in the cerebellum, but can also be widely distributed in the brain.

CJD is the most common human TSE (the name Creutzfeldt-Jakob disease was coined by Spielmeyer in 1922), which has been shown to have familial (fCJD), infectious (iatrogenic/iCJD and variant/vCJD), and sporadic (sCJD) etiologies. Approximately 85% of all human prion diseases are sporadic forms of CJD, with incidences of 0.6-1.2 cases per million people per year distributed equally between men and women (Ladogana et al., 2005). The cause of sCJD is still unclear, although the spontaneous misfolding of PrP^C to PrP^{Sc} is a plausible hypothesis (Prusiner, 1989; Hsiao et al., 1991a). Alternate explanations include somatic mutations in the PrP^C gene that could lead to abnormal protein folding, even though no case of somatic mutations has been reported. However, the M129V polymorphism in the PrP^C gene appears to be associated with a lower risk (Palmer et al., 1991) and/or prolonged incubation time (Collinge et al., 2006). It remains possible that sCJD could be an acquired illness, as two case-control studies have reported prior surgery as a risk factor (Ward et al., 2002; Collins et al., 1999). However, evidence that these factors directly contribute to the etiology of sCJD is still lacking.

Unlike other diseases with dementia, such as Alzheimer's and Parkinson's diseases, in which incidence rises with age, the incidence of sCJD is primarily between 55 and 60 years of age, although patients as young as 14 (Murray et al., 2008) and as old as 86 (de et al., 1997) years of age have been reported. sCJD is a rapidly progressing dementia, and usually leads to death within a few weeks of the first symptoms. Initial symptoms include very rapid cognitive decline and dementia, sleep disturbances, and behavioral abnormalities consistent with prominent cerebral atrophy (Figure 2). Cerebellar symptoms including ataxia and myoclonus are often present. Visual disturbances and ocular movement disorders, as well as extrapyramidal signs and hallucinations may also occur with sCJD. The final stages are characterized by an akinetic mute state (Murray, 2011). The rapidity of deterioration in sCJD usually allows the clinician to distinguish it from other dementias and neurodegenerative conditions. Pathological findings consist primarily of astrocytosis and spongiform changes associated with loss of neurons. The abnormal protease-resistant PrP^{Sc} can frequently be detected directly by immunohistochemistry in properly treated brain sections. Amyloid plaques containing PrP^{Sc} are also present in 5% of cases (Brown et al., 1994).

While variant CJD (vCJD) is associated with the consumption of BSE-infected meat, another CJD acquired by infection is iatrogenic CJD (iCJD), which is believed to result from the patient's exposure to prions by contact with contaminated human tissues. iCJD can be inadvertently transmitted during the course of medical or surgical procedures, either by the transplantation of tissues from patients with TSE or by neurosurgery using instruments incompletely sterilized following use on TSE patient (Aguzzi and Polymenidou, 2004). The first reported case of iCJD occurred in 1974 and was caused by the corneal transplantation of a graft derived from a patient suffering from sCJD (Duffy et al., 1974). Iatrogenic CJD is rare and is most often observed in individuals that have received cadaveric *dura mater* implants, human growth hormone, or were placed contaminated brain electrodes (Will, 2003).

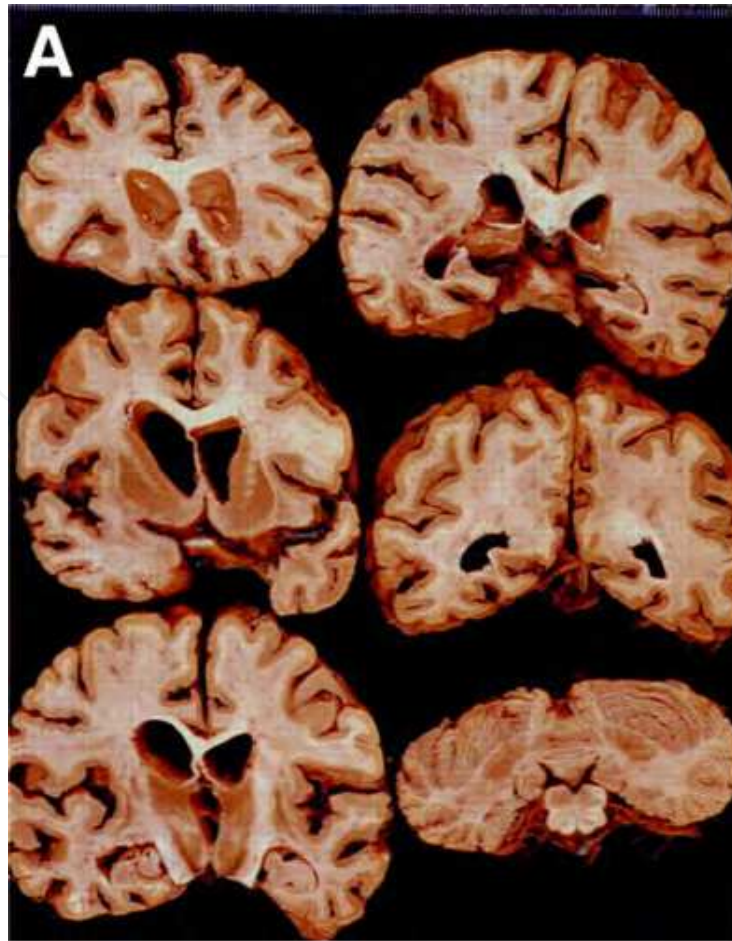


Fig. 2. Macroscopical aspect of a sporadic CJD brain with prominent cerebral, but not cerebellar, atrophy. Reproduced with permission from Budka, *British Medical Bulletin* 2003; 66: 121–130 (Budka, 2003).

The incubation period for iCJD is long, ranging from two to more than ten years. Additional evidence indicates that the route of prion exposure influences the clinical manifestation of CJD. For example, a predominantly ataxic phenotype is observed for *dura mater* or growth hormone-related cases, whereas cases in which prions were directly introduced into the CNS present with dementia as the initial symptom (Glatzel et al., 2005).

The newest version of human TSE, vCJD, was first reported in 1996 (Will et al., 1996) and was linked to the consumption of food contaminated with the BSE agent. In recent years, several studies regarding the biochemical, neuropathologic, and transmission characteristics of vCJD confirms that this disease represents the transmission of BSE prions to humans (Aguzzi, 1996; Aguzzi and Weissmann, 1996; Bruce et al., 1997; Hill et al., 1997a). In contrast to traditional forms of CJD, vCJD has affected younger patients (average age 19–39 years, as opposed to 65 years), has a relatively long duration of illness (median of 14 months as opposed to 4.5 months), and is strongly linked to exposure, probably through consumption, to cattle BSE (Will et al., 2000). The young age range of these patients and their distinctive pathology indicated that they represented a novel clinical TSE disease, combined with the initial occurrence of these patients in the UK, suggested an association with bovine BSE (Will et al., 1996). Subsequent laboratory

experiments suggested that a strong similarity existed between BSE and vCJD on the basis of the lesion distribution in these disorders. Approximately 200 people have been diagnosed with vCJD world-wide, with most affected individuals being from the UK and France. Since 2001, the incidence vCJD in the UK appears to have stabilized (<http://www.cjd.ed.ac.uk>). The predominant clinical presentation for vCJD involves psychiatric symptoms, including behavioral changes, anxiety, and depression. These symptoms are followed, within weeks to months, by a cerebellar syndrome with ataxia and subsequent myoclonus. Later in the course of the disease, memory disturbances are evident, which progress to severe cognitive impairment and, finally, akinetic mutism. Neuropathological analyses have shown spongiform changes, neuronal loss, and astrogliosis, most prominently in the basal ganglia and thalamus. In addition, striking amyloid plaques containing PrP^{Sc} may be present throughout the cerebrum and cerebellum, and are often surrounded by vacuoles (Will et al., 1996).

The familial/inherited human prion diseases can be subdivided into three phenotypes, including fCJD, GSS, and FFI, according to the clinical symptoms presented. Familial prion diseases are far more rare than sCJD, and account for 10 to 20% of all TSE cases with an incidence of approximately 1 per 10 million. Familial TSEs are associated with an autosomal dominant alteration in the gene that encodes the PrP^C protein (Hsiao et al., 1989). To date, over 40 different mutations in this gene have been described to segregate with TSEs (Table 2).

Diseases	Mutations	
GSS	P102L-129M	
	P105L-129V	
	A117V-129V	
	G131V-129M	
	Y145*-129M	
	H187R-129V	
	F189S-129V	
	D202N-129V	
	Q212P	
	Q217R-129M	
	fCJD	D178N-129V
		V180I
		T188K
		T188R-129V
E196K		
E200K		
V203I		
E208H		
V210I		
E211Q		
M232R		
FFI	D178N-129M	

Table 2. Summarizes known mutations that cause human TSEs. Point mutations found in patients with prion disease in the gene that codes for PrP^C. In some cases, the mutations are found in association with a polymorphism in codon 129, where methionine (M) or valine (V) are indicated. Amino acids are given in single-letter code. The asterisk indicates a stop codon; consequently, this mutation results in a truncated protein.

Several different mutations in the gene encoding PrP^C have been implicated in fCJD (Goldfarb et al., 1990;Hsiao et al., 1991b;Hsiao et al., 1991a;Bertoni et al., 1992). The clinicopathological phenotype of fCJD varies depending upon the mutation, as well as on the presence of a polymorphism at amino acid 129 (methionine (M) or valine(V)) (Kovacs et al., 2002). Highly variable symptoms may present even in affected members of the same family. The pattern of symptoms is sometimes similar to that observed for sCJD. Early symptoms may include depression, memory lapses, social withdrawal, and a lack of interest. However, the rapid progression to dementia and neurological symptoms are diagnostic. Within weeks, the patient may become unsteady on their feet, lack coordination, experience blurred vision or even blindness, rigidity in the limbs, and difficulty in speaking. In fCJD, the average age of onset symptoms is 52 years of age, compared to 65 years for sCJD.

A mutation in the gene encoding for PrP^C that results in an aspartate (D) to asparagine (N) substitution at amino acid 178 (D178N) can underlie either fCJD or FFI, depending on the polymorphism present at amino acid 129 (M or V). D178N coupled with V129 produces fCJD, in which patients present dementia and a widespread deposition of prion protein in the brain (Goldfarb et al., 1991a;Goldfarb et al., 1991b). When D178N is coupled with M129, the result is FFI.

The FFI diagnosis was first used in 1986 to describe an illness affecting five members of a large Italian family (Lugaresi et al., 1986). Over 20 kindred and seven nonfamilial (sporadic) cases of this unusual variety of prion disease have since been identified throughout the world. In the most characteristic presentation, the patient with FFI develops untreatable insomnia, sometimes for a prolonged period of weeks or months. Insomnia is followed by dysautonomia, ataxia, and variable pyramidal and extrapyramidal signs and symptoms, with a relative sparing of cognitive function until late in the disease course. The dysautonomias may include episodic alterations in blood pressure, heart rate, temperature, respiratory rate, and secretions. Electroencephalogram (EEG) recordings performed on these patients shows diffuse slowing, rather than periodic, discharges. Positron emission tomography (PET) reveals a reduction in metabolic activity in, or blood flow to, the thalamus relatively early in the disease (Padovani et al., 1998). The average age of onset for FFI is 50 years of age, with an average disease duration of 12 months.

The neuropathologic features of FFI include neuronal loss and astrogliosis within the thalamus and inferior olives and, to a lesser degree, the cerebellum. Vacuolation is minimal or absent in typical cases. Protease-resistant PrP^{Sc} is detectable in the brains of affected patients; however, it is usually present only in small amounts and is often restricted to specific regions such as the thalamus and temporal lobe (http://www.medscape.com/viewarticle/410863_4).

A specific mutation in the gene encoding PrP^C, which results in a proline (P) to leucine (L) substitution at amino acid 102 (P102L), was found to be present in patients with GSS. This was first detected in the original Austrian family described by Gerstmann, and was later observed in other cases (Hainfellner et al., 1996). This finding led to the unprecedented conclusion that prion diseases can have both genetic and infectious etiologies (Hsiao et al., 1989;Prusiner, 1989). This mutation has been found in unrelated families from several countries (Goldgaber et al., 1989;Kretzschmar et al., 1991) and other mutations causing GSS have also been identified. GSS is characterized by a slowly progressive cerebellar ataxia accompanied by cognitive decline (Ghetti et al., 1995). In contrast to other inherited human

prion diseases, GSS has unique neuropathologic features that consist of widespread, multicentric PrP^{Sc} plaques in the cerebellar cortex. In families with GSS, symptoms usually begin in the fifth or sixth decade of life, but disease onset may occur as young as 25 years of age, with illness durations ranging from three months to 13 years (mean five to six years) (Chabry et al., 1999; Masters et al., 1981; Gajdusek, 1977; Hill et al., 1997a). Variation in the age of onset is associated with the presence of the P102L mutation (Deslys et al., 1996).

4. Transmission of prions

The most notorious means of prion transmission is via the ingestion of contaminated meat, although transmission by this route is actually highly inefficient. The concept of prion infectivity was presented to the general population during the rise of the mad-cow disease epidemic and the recognition of vCJD. vCJD was reported for the first time in 1996 as a disease having a clinical and pathological phenotype distinct from sCJD. Following many years of investigation, it became clear that vCJD is caused by consumption of BSE-contaminated meat products. Since 1996, 223 cases of vCJD have been reported, most occurring in the UK and France, although other countries have also reported cases (Table 3) (Ironside, 2010). The most likely period for transmission of BSE to humans was from 1984-89 and 1995-96 during the outbreak of BSE in cattle. Although a major portion of the UK population was likely exposed to BSE infectivity, a relatively small number of individuals have died from vCJD (Knight, 2010). Reasons for this low incidence may include a significant inter-species barrier, inefficiency of oral ingestion as a route of transmission, as well as difference in individual susceptibility.

Iatrogenic transmission of CJD is relatively rare. To date, iCJD has been reported in more than 400 patients who were exposed to prion transmission via contaminated neurosurgical instruments, intracerebral electroencephalographic electrodes, human pituitary hormone, corneal transplant, or *dura mater* graft. iCJD was first suggested in the case of a woman who died of CJD in 1974. She had received a corneal transplant 18 months before disease onset, derived from a patient who also died of CJD (Duffy et al., 1974). In 1997, a 45-year-old German woman developed CJD 30 years after corneal graft from a donor with confirmed CJD. Another eight cases of suspected contamination through corneal transplant have been reported, but the status of the donor in these cases has not been confirmed (Hamaguchi et al., 2009).

Country	Number of cases (October 2011)
United Kingdom	176
France	25
Spain	5
Ireland	4
Netherlands	3
United States of America	3
Portugal	2
Italy	2
Canada	1
Saudi Arabia	1
Japan	1

Table 3. Variant CJD cases worldwide.

The first case of *dura mater* graft-associated CJD (dCJD) was reported in the US in 1987(1987). Since then, 196 dCJD cases have been described, more than 50% of which occurred in Japan (Hamaguchi et al., 2009).

Another iatrogenic means of prion transmission resulted from the treatment of children with short stature with human growth hormone (hGH) that was derived from pituitary glands from the corpses of CJD-affected individuals. The process of purifying hGH did not eliminate prion infectivity causing this kind of contamination. To date, more than 190 patients worldwide have presented with iCJD following hGH treatment. More than 100 cases occurred in France (Hamaguchi et al., 2009), and others have been described in the UK, US, New Zealand, Brazil, and others (Brown et al., 2006). Although the use of recombinant GH began in 1985, cases of hGH-associated iCJD are still being observed due to the prolonged incubation period, up to 20 years, observed for these iCJD cases.

Thus, the length of the incubation period for the CJDs appears to be related to the means by which the prion particles were transmitted. Direct intracerebral exposure to prions via contaminated surgical material and the implantation of prion-contaminated *dura mater*, for example, have been associated with relatively short incubation periods (16-28 months). Peripheral exposure to prions, through the consumption of contaminated meat or exposure to contaminated hGH, results in longer incubation times that range from 5 to 30 years (Glatzel et al., 2005).

The occurrence of secondary transmission of CJD via blood transfusion has been reported. This route of human to human iCJD transmission has particularly important implications for public health, as relatively high infectivity has been observed in the lymphoid tissues of CJD patients. The existence of subclinical infected donors, combined with the high CJD infectivity of blood and the efficiency of blood as a route of transmissions, are key factors influencing the likelihood of acquiring iCJD via transfusion. To date, there are four confirmed cases of iCJD associated with the transfusion of non-leukoreduced red blood cells from an asymptomatic donor who subsequently died from vCJD (McCutcheon et al., 2011). The incubation time in the recipients was approximately 7 years after the contaminated transfusions (Ironsides, 2010).

5. Diagnosis

Although a rapidly progressive dementia, myoclonus, and other neurological signs may lead the clinician to suspect a TSE, the definitive diagnostics in humans can only be confirmed by brain biopsy or necropsy followed by the histopathological and immunohistochemical examination of brain tissue. Cerebral biopsy in living patients is discouraged, unless its purpose is to achieve an alternative diagnosis of a treatable disorder.

The misfolded prion protein, PrP^{Sc}, is the single most significant marker for the TSE diseases, but its detection using standard serological methods is complicated by its antigenic similarity to the normal prion protein, PrP^C. Many research groups have tried to detect PrP^{Sc} outside of the brain in order to develop more accurate and less invasive diagnostic tools, but these attempts have so far been unsuccessful or are still in clinical trials. Electrophysiological examinations using EEG, or imaging exams using magnetic resonance imaging (MRI), combined with biochemical analysis, are among the methods currently used to probe for prion diseases, as discussed below (Venneti, 2010). In the following section we will present the main features of the diagnostic tools that have, to date, been in use.

5.1 Genetic investigations

DNA sequencing of the gene that encodes PrP^C can detect the inherited forms of prion diseases that are caused by point mutations. There have been 55 pathogenic mutations described in the gene that encodes PrP^C (Table 2) which include 24 missense point mutations, 27 insertion mutations, 2 deletions, and 2 nonsense mutation that result in the premature termination of the PrP^C protein. If DNA sequencing detects a mutation in a patient, the diagnosis of TSE can be confirmed (Figure 3). However, the absence of detectable mutations does not exclude the sporadic or iatrogenic forms of the disease (Gambetti et al., 1999).

Twelve polymorphisms that do not result in amino acid substitution have been described in the gene encoding for PrP^C (Gambetti et al., 1999). Four additional polymorphisms that do alter the amino acid sequence of PrP^C have also been reported. The polymorphism at amino acid 129 of PrP^C is of particular importance; compelling evidence from studies in genetically modified mice as well as from clinical studies indicate that homozygosity for the less common methionine at position 129 constitutes a risk factor for the development of prion disease. Notably, methionine homozygotes are overrepresented among patients with sCJD, and all individuals affected by vCJD are codon 129 methionine homozygotes. Besides constituting a risk factor for the development of prion diseases, this polymorphism has a considerable effect on the clinical, biochemical, and neuropathologic presentation of individuals with prion diseases (Glatzel et al., 2005). As described in previous sections, a mutation in PrP^C at amino acid 178, when combined with the presence of methionine at position 129, results in the development of CJD or FFI.

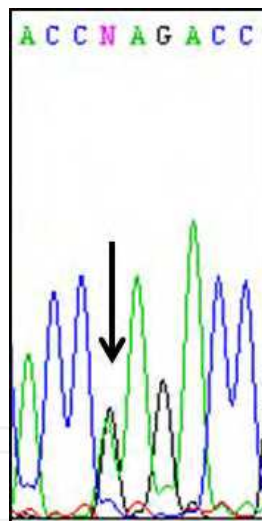


Fig. 3. Genomic sequencing of PrP^C encoding gene. This particular test shows a mutation (AAG to GAG) in heterozygosis that would code for amino acid 200, replacing a glutamate for a lysine (E200K).

5.2 EEG

EEG recording show periodic or pseudoperiodic paroxysms of triphasic or sharp waves of 0.5 to 2.0 Hz against a slow background in about two-thirds of sCJD patients. However, this EEG pattern is not specific to sCJD, and occurs in other conditions, such as metabolic diseases. In addition, at least 30% of cases may not demonstrate the typical features. There appears to be a temporal window of opportunity for the detection of abnormal EEG patterns

in sCJD, as these patterns may not be evident either early or late in the disease course. Thus, a serial course of weekly or bi-weekly EEGs may be necessary to capture the characteristic periodic discharges (Will et al., 1999).

In iCJD, the EEG shows a slow wave pattern and, in FFI, the EEG displays diffuse slowing, rather than the periodic triphasic discharges typical of sCJD (Will et al., 1999).

5.3 MRI

Although the use of MRI is not included in the exams recommended by the World Health Organization (WHO) (<http://www.who.int/entity/zoonoses/diseases/Creutzfeldt.pdf>), it can be useful for CJD diagnosis. In sCJD almost all cases present gray matter hyperintensities in the neocortical, limbic and subcortical areas. In 70% to 90% of patients, cortical ribboning is evident that may be accompanied by increased intensities in the putamen and caudate nuclei detectable with fluid-attenuated inversion-recovery sequences and diffusion-weighted imaging (DWI) MRI (Geschwind et al., 2008). In vCJD, a characteristic MRI pulvinar sign is evident as hyperintensity in the pulvinar - posterior thalamus relative to the anterior putamen in about 80% of patients (Glatzel et al., 2005). In prolonged courses of sCJD (more than one year), brain MRIs show significant atrophy with loss of DWI hyperintensity, particularly in areas that previously displayed restricted diffusion (Vitali et al., 2011).

In prion disorders associated with a high degree of amyloid deposition, such as GSS and other genetic variants, PET ligands that bind to prion-containing amyloid deposits, such as 2-(1-{6-[(2-[F-18]fluoroethyl) (methyl)amino]-2-naphthyl]ethylidene)malononitrile (FDDNP), may offer additional diagnostic opportunities (http://www.medscape.com/viewarticle/582032_7). As with EEG results, these signs can also be found in other diseases, complicating the definitive diagnosis of a prion disease.

5.4 14.3.3 detection

The 14.3.3 proteins are a group of cytosolic polypeptides whose abnormal presence in the cerebrospinal fluid (CSF) can be detected in many conditions including stroke, infection, inflammatory processes, epileptic seizures, and toxic metabolic conditions, and is a reliable marker of the rapid destruction of neurons characteristic of a number of progressive neurological disorders (Zanusso et al., 2011).

The use of 14.3.3 as a diagnosis for prion disease was suggested for the first time in 1996 (Hsich et al., 1996). Despite controversy regarding the specificity of this diagnostic tool, in 1999, 14.3.3 detection was included by the WHO in their guidelines for CJD diagnosis. The 14.3.3 protein can be detected in many clinical laboratories; however, this is considered to be an expensive and time-consuming test that generates often inconclusive data due to the difficulty with which the protein band patterns can be discerned (Sato et al., 2010). In spite of these limitations, 14.3.3 tests are considered to be reliable diagnostic markers for CJD and present an approximately 90% specificity and sensitivity in the diagnosis of sCJD. In addition, the presence of 14.3.3 in the CSF occurs in around 90% of fCJD cases. However, the presence of 14.3.3 has not been reported in the CSF of patients suffering from FFI or GSS (Glatzel et al., 2005).

Other biochemical analyses of the CSF useful for CJD diagnosis are the presence of neuron-specific enolase (NSE) and S100 proteins, which have been shown to be increased in the CSF of patients with CJD. The presence of Tau proteins in the CSF has also been described to be

diagnostic for CJD, but only in a small group of patients. Although the test for the presence of Tau is highly sensitive, it is not a differential diagnostic that can be used to distinguish CJD from other diseases (Otto et al., 2002).

5.5 Neuropathological analysis

The neuropathological hallmark of prion disease is the presence of the classical triad of spongiform changes, neuronal loss, and gliosis. As neuronal loss and gliosis are found in other neurodegenerative conditions, the spongiform changes in the brain are the most specific characteristic of prion disease. The spongiform changes may be mild, moderate, or severe, and are characterized by diffuse or clustered, small, round, or oval vacuoles in the neuropil (Budka, 2003) (Figure 4).

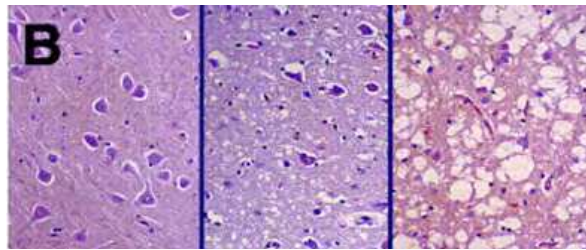


Fig. 4. Spongiform degeneration: In sporadic CJD, some brain areas may have no (hippocampal end plate, at left), mild (subiculum, at middle) or severe (temporal cortex, at right) spongiform change. Haematoxylin and eosin (H & E) stain. Reproduced with permission from Budka, *British Medical Bulletin* 2003; 66: 121–130 (Budka, 2003).

Other routine neuropathologic investigations include sampling from different regions of the CNS and the immunohistochemical detection of aggregated PrP^{Sc}. The type of PrP^{Sc} plaque deposition varies with the disease; synaptic-type deposits and unicentric PrP^{Sc} plaques occur in both CJD and GSS, while abundant multicentric plaques are peculiar to GSS. Plaque-like deposits are the only type of PrP^{Sc} deposits that extend to the subcortical white matter. Kuru plaques are present in a minority of sCJD cases and are most frequent in the cerebellar cortex (Budka, 2003) (Figure 5). GSS presents multicentric PrP^{Sc} plaques and thalamic degeneration, and also variable spongiform changes in cerebrum.

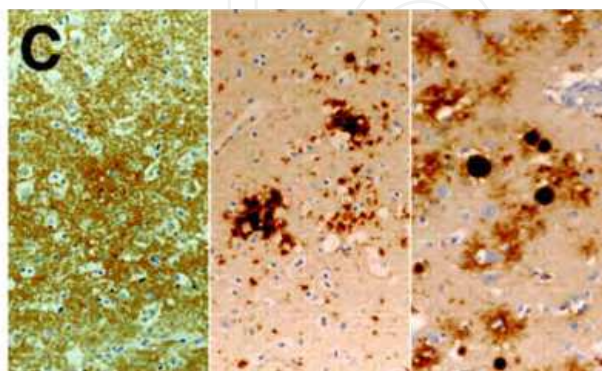


Fig. 5. Patterns of PrP^{Sc} deposition: Cortical sections immunostained for PrP^{Sc} in sporadic CJD: synaptic (at left), patchy/perivacuolar (at middle) or plaque type (at right) patterns of PrP^{Sc} deposition. Reproduced with permission from Budka, *British Medical Bulletin* 2003; 66: 121–130 (Budka, 2003).

In vCJD, a very particular pattern of PrP^{Sc} deposition is found. These depositions are composed of abundant multiple fibrillary PrP^{Sc} plaques surrounded by a halo of spongiform vacuoles called "florid" plaques or "daisy-like" plaques (Figure 6). Also present are amorphous pericellular and perivascular PrP^{Sc} deposits that are particularly prominent in the molecular layer of the cerebellum (Minor et al., 2004;Will et al., 1999;1997).

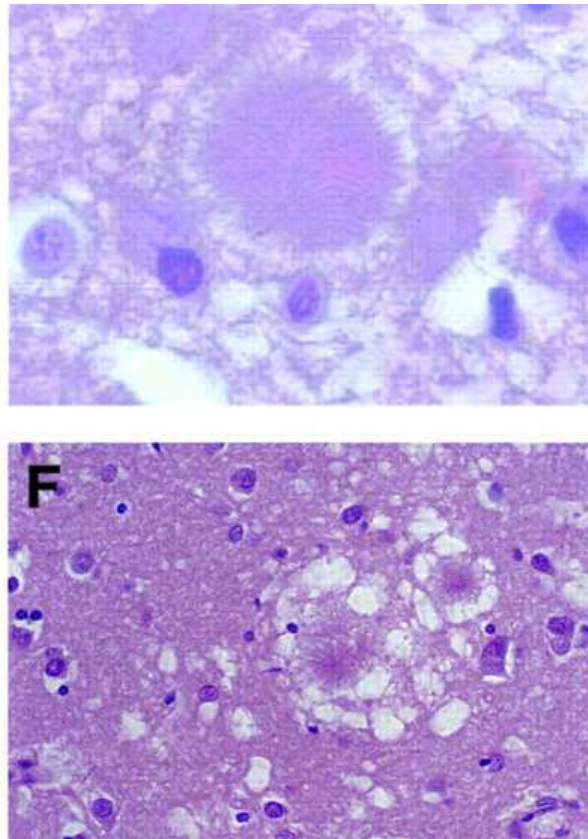


Fig. 6. Amyloid plaques in prion diseases. Upper panel - Large Kuru-type plaque, Hematoxylin and Eosin stain. Lower panel - Typical 'florid' plaques in vCJD, H & E stain. Reproduced with permission from Budka, British Medical Bulletin 2003; 66: 121-130 (Budka, 2003).

5.6 Tonsil biopsy

The presence of PrP^{Sc} in postmortem tonsillar tissue was first described in a 35 year old woman in 1997. The immunohistochemical and western blot findings in this suspected vCJD case showed an abnormal PrP^{Sc} immunoreactivity within tonsillar germinal centers that are not observed in sCJD, suggesting that tonsil biopsy may be applicable as a differential diagnostic tool (Hill et al., 1997b). The WHO does not recommend tonsil biopsy routinely in cases in which EEG findings are typical of sCJD, but the biopsy may be useful in cases where the clinical features are compatible with vCJD and the MRI does not show a high bilateral pulvinar signal.

5.7 Classification of sCJD and vCJD

According to all the above clinical signs and symptoms, and the use of the before mentioned diagnostic exams, the WHO classifies sCJD and vCJD according to the following criteria:

Possible sCJD

- Duration < two years
- Progressive dementia
- At least two of the following clinical features: myoclonus, visual or cerebellar disturbance, pyramidal, extrapyramidal dysfunction, akinetic mutism

Probable sCJD

- Duration < two years
- Progressive dementia
- At least two out of the following clinical features: myoclonus, visual or cerebellar disturbance, pyramidal, extrapyramidal dysfunction, akinetic mutism
- The presence of 14.3.3 immunoreactivity in the CSF, or typical EEG patterns of periodic triphasic sharp waves

Confirmed sCJD

- Spongiform changes in cerebral and/or cerebellar cortex and/or subcortical grey matter
- PrP^{Sc} immunoreactivity of the plaque and/or diffuse synaptic and/or patchy/perivacuolar type

Although the clinical criteria for CJD are fairly comprehensive, neuropathological analysis is important in every suspected case. The above criteria do not cover all CJD cases, and approximately 17% of all confirmed CJD cases do not fulfill clinical criteria for probable or possible CJD (Hainfellner et al., 1996; Radbauer et al., 1998).

5.8 Variant CJD

vCJD cannot be diagnosed with certainty using clinical criteria alone; the diagnosis requires neuropathological confirmation. The following combinations of signs, symptoms, and clinical investigations serve to define possible, probable, and definite vCJD (Table 4):

(I)
Progressive psychiatric disorder
Clinical duration >6 months
Routine investigations do not suggest an alternative diagnosis
No history of potential iatrogenic exposure
No evidence of a familial form of TSE (transmissible spongiform encephalopathies).
(II)
Early psychiatric symptoms (depression, anxiety, apathy, withdrawal, delusions)
Persistent painful sensory symptoms (pain and/or dysaesthesia)
Ataxia
Chorea / dystonia or myoclonus
Dementia.

Possible vCJD

- A patient with the items in (I) and at least four items in (II)
- EEG is not typical of sCJD

Probable vCJD

- A patient with the items in (I) and at least four items in (II)
- High bilateral pulvinar signal on MRI brain scan
- EEG in not typical of sCJD, although generalized periodic complexes may occasionally be seen at the later stages of the disease.
- Or, a patient with the items in (I) and a positive tonsil biopsy.

Definite vCJD

- A patient with the items in (I)
- Neuropathological confirmation of vCJD

HUMAN PRION DISEASE	SPORADIC CJD	VARIANT CJD
Age at onset (range)	60-70y	26y (12-74)
Disease Duration (range)	6 mo (1-35)	14 mo (6-24)
Clinical Symptoms	Progressive dementia, myoclonus, cerebellar ataxia, visual problems, extrapyramidal symptoms	Early psychiatric symptoms, dysesthesia, later neurologic deficits and cognitive decline
CSF 14.3.3	Positive > 90%	Positive in 50%
EEG	PSWC 60-70%	Nonspecific alterations
MRI	Brain atrophy hyperintensities in basal ganglia and/or cortical in 67%	Hyperintensities in the posterior thalamus (pulvinar sign), 78%
Histopathologic Features	Spongiform changes, neuronal loss, astrogliosis, PrP deposition - various patterns	Spongiform changes, neuronal loss, astrogliosis, PrP deposition - florid plaques

Adapted from Glatzel et al, 2009.

Table 4. Clinical, Diagnostic and Neuropathologic Features in Sporadic CJD and Variant CJD.

Because of their potential infectious properties, the incidence of prion disease should be followed worldwide. The global surveillance of vCJD and other forms of CJD will lead to a better understanding of these diseases, including the potential causes of iCJD as well as the distribution of the various familial forms. Such epidemiology should also provide information useful for the protection of individuals against the risks of these diseases. The surveillance of CJD is recommended by the WHO and has been implemented in many countries including the UK, the US, Canada, Japan, Brazil, and many countries in Europe.

6. Therapies and perspectives

There are currently no effective means of curing or even ameliorating the symptoms of prion disease. There is currently a multitude of studies using different strategies aimed at finding effective treatments for these diseases (Rigter et al., 2010). The many attempts to achieve this goal are discussed in this section (Table 5).

Four types of studies have been conducted. These include the 1) *in vitro* observation of abnormal prions in a test tube, 2) the observation of cultured cells infected with prions, 3) studies involving prion-infected animals or 4) actual patients affected by the disease. No drug has shown efficacy in the treatment of animal models after the onset of symptoms, although several compounds have been shown to delay the onset of disease if given before symptoms are evident.

The physiological functions of PrP^C, as well as the exact molecular processes underlying its conversion into PrP^{Sc}, are not completely understood. Nevertheless, a number of compounds and techniques have been investigated for their therapeutic potential against prion disease. Current therapeutic strategies are focused upon preventing the accumulation of PrP^{Sc} in the nervous system. This can be accomplished by lowering PrP^C availability, thus preventing PrP^{Sc} spread in the CNS, or by increasing PrP^{Sc} clearance. Additional non-specific therapeutic strategies, such as stem cell therapy or the use of neurotrophic factors to prevent neuronal death, which have been tried in other protein conformational diseases such as AD, are emerging amongst prion researchers.

The most direct strategy of inhibiting PrP^{Sc} conversion is to render PrP^C unavailable. This may be accomplished by lowering the cellular amounts of PrP^C. In mice, genetic deletion of PrP^C confers resistance to prion diseases (Bueler et al., 1993). In humans, the ablation of PrP^C may be possible via the recently-developed technology of interference RNA (RNAi). The transcription of DNA constructs that contain an antisense sequence to PrP^C would produce an RNA molecule complementary to PrP^C mRNA. This results in the annealing of both strands and the formation of a double-stranded RNA molecule, which activates a cellular mechanism of RNA degradation, thus preventing the translation and expression of PrP^C. In cells, this technique was successful in inhibiting normal amounts of PrP^C and its conversion to PrP^{Sc} (Daude et al., 2003). In mice inoculated with prions and allowed to incubate the disease until early neuropathology was established, a single injection of viral particles containing RNAi to PrP^C prevented the onset of early behavioral and cognitive deficits, reduced PrP^{Sc} deposition and spongiosis, and resulted in the significantly increased survival of the animals (White and Mallucci, 2009).

A potential drawback to the use of therapeutic RNAi in neurodegenerative diseases is the need to overcome the blood-brain-barrier (BBB); this would require either the transient disruption of the BBB's impermeability or direct injection into the brain. However, in animal studies the efficacy of the viral delivery was restricted to the sites of injection. Therefore, protection against the formation of PrP^{Sc} in multiple areas of the brain would depend on several brain injections (White et al., 2008). Another caveat to the use of RNAi *in vivo* is the need to avoid silencing of unintended genes, cytotoxicity, activation of interferon responses, and interference with the processing of endogenous micro RNAs due to an over-loading of the RNAi pathway.

In the treatment of prion disease, even a partial reduction of PrP^C expression would likely be beneficial; thus low doses of RNAi should be sufficient, minimizing the potential for unintended side effects. An additional caveat of this strategy is that, since PrP^C has many described functions, there may be undesirable side effects from its ablation. However, if a reversible process for gene silencing is developed, the physiological functions of PrP^C could be restored following treatment.

Therapeutic Strategy	<i>In vitro</i>	<i>In vivo</i>	Human trials
PrP ^c depletion by interference RNA	Yes	Yes	n.d.
Heterologous PrP	Yes	Yes	n.d.
Amiloydogenic motif peptide	Yes	n.d.	n.d.
Dendritic Follicular Cell inhibition of differentiation	Yes	Yes	n.d.
Branched Polyamines	Yes	Yes	n.d.
β-breaker peptides	Yes	Yes	n.d.
Quinacrine	Yes	Limited efficacy	Underway
Active immunization	n.d.	Yes	n.d.
Passive immunization	n.d.	Yes	n.d.
Dextran Sulfate	n.d.	Yes	n.d.
Pentosan Polysulfate	Yes	Yes	Not conclusive
Heparin mimetic	Yes	Not conclusive	n.d.
Congo red analogues	Yes	Yes	n.d.
Suramin analogues	Yes	Yes	n.d.
Poryphyrines/phtalocyanines	Yes	Yes	n.d.
Quinine/biquinoline	Yes	Some	n.d.
Tetracycline	Yes	Yes	Underway

n.d. - not determined. Adapted from: Vaccine 28 (2010) 7810–7823.

Table 5. Overview of therapeutic strategies designed so far.

A different strategy for reduction of PrP^{Sc} conversion is based upon the need for compatibility between the host PrP^C and infectious PrP^{Sc} proteins for efficient conversion. Incompatibilities in PrP^C between species, or from amino acid substitutions, may even block the conversion of compatible PrP^C (Horiuchi et al., 2000). For example, treatment of prion-infected mice with viral particles expressing PrP^C containing specific mutations increased survival time, even when treatment was started at a late stage of infection (Toupet et al., 2008). In this manner, the expression of incompatible PrP^C may be a viable therapeutic strategy in prion disease, without the drawback of impairing normal PrP^C functions. This approach has been applied to sheep in the Netherlands, where the preferential breeding of resistant phenotypes has been widely and effectively implemented. The difficulties of this treatment rely on the need of a continuous means of delivery for the resistant PrP^C forms that would also efficiently spread this molecule throughout the brain.

In addition to conversion-resistant PrP^C proteins, the introduction of peptides from a conserved region of PrP^C are also able to block conversion (Chabry et al., 1999). Even though peptides are easily synthesized, they have the disadvantage of being sensitive to proteolytic degradation and, like the PrP^C protein, the difficulties in crossing the BBB requires intracranial injections.

Alternatively, the prevention of PrP^{Sc} migration to the CNS can block the progression of the disease without the need of bypassing the BBB. In cases where infection is acquired, PrP^{Sc} must spread to the nervous system. Studies suggest that PrP^{Sc} first accumulates on follicular dendritic cells, from where neuronal invasion occurs. The experimental impairment of dendritic cell maturation was shown to inhibit prion neuroinvasion. However, this approach was most successful when treatment was administered prior to scrapie inoculation (Mabbott et al., 2003; Montrasio et al., 2000), and would not be effective against the familial prion diseases.

The study of the mechanisms by which PrP^{Sc} induces neurodegeneration also promises new therapeutic strategies. For example, the calcium-dependent phosphatase calcineurin (CaN) was shown to be hyperactivated as a result of PrP^{Sc} formation. Prion-infected mice treated with the CaN inhibitor FK506 at the clinical phase of the disease exhibited reduced severity of the clinical abnormalities and increased survival times. These animals also displayed a reduced degree of neurodegeneration that was independent of the amount of PrP^{Sc}, suggesting that inhibition of PrP^{Sc} formation may not be necessary for therapeutic effects with FK506 (Mukherjee et al., 2010).

At the current time, no protein conformational disorder has a highly effective therapy. Many studies using AD animal models have shown that immunotherapeutic approaches can reduce both amyloid and tau-related pathology, leading to cognitive rescue. Partly because of success observed in AD models, similar experiments with anti-PrP antibodies were initiated. In tissue culture studies, anti-PrP antibodies and antigen-binding fragments directed against PrP have been shown to inhibit prion replication. Administering specific anti-PrP monoclonal antibodies directly following the inoculation of mice with prions, resulted in prolonged survival in treated animals (Sigurdsson et al., 2003) and continuous treatment with antibodies delayed the incubation period (White et al., 2003). Passive immunization of extra-cerebrally infected mice with an anti-PrP antibody resulted in the effective suppression of PrP^{Sc} replication in the lymphoreticular system, effectively preventing prion invasion into the CNS (Sadowski et al., 2009). In a different approach, the artificial expression of the anti-PrP antibody 6H4 protected mice from prion disease following prion inoculation (Heppner et al., 2001).

Potential complications of this immunotherapy approach can arise from the fact that *in vivo* cross-linking with PrP^C-specific antibodies has been shown to trigger rapid and extensive apoptosis in neurons (Solfrosi et al., 2004). Additionally, passive immunization has not been found to be effective when administered close to the clinically symptomatic stages of prion infection. Additionally, this approach would be too costly for the treatment of prion diseases in animals.

Active immunization (vaccination) was also shown to prolong the survival of infected mice, especially when vaccination occurred prior to prion exposure (Sigurdsson et al., 2002; Schwarz et al., 2003). Full-length PrP^C, or a peptide sequence of PrP^C, were expressed in mice using viral particles resulting in the production of high-affinity antibodies able to inhibit PrP^{Sc} formation in prion-infected cells (Nikles et al., 2005; Handisurya et al., 2007). Trials using this methodology to prevent Chronic Wasting Disease in mule deer are ongoing.

A drawback of active immunization is that endogenous PrP^C functionality would be indefinitely impaired in the treated animal. Additionally, immunomodulation to target prions must overcome the body's natural tolerance to endogenous PrP^C at the same time that humoral or cellular autoimmune cytotoxic effects should be avoided or minimized (Wisniewski and Goni, 2010).

Preventing the accumulation of PrP^{Sc} is also a viable therapeutic strategy, and a number of compounds have been examined for this purpose. Branched polyamines were shown to disaggregate prion aggregates, rendering PrP^{Sc} susceptible to proteolysis. Although the mechanisms are not clear, these compounds appear to interact with PrP^{Sc}, resulting in the

blockade of de novo PrP^{Sc} formation and increased PrP^{Sc} clearance. However, the *in vitro* susceptibility of PrP^{Sc} to polyamine treatment was strain-dependent, limiting its application (Supattapone et al., 2001; Solassol et al., 2004). Peptides that disrupt protein β -sheets also can increase the susceptibility of PrP^{Sc} to protease degradation. A peptide capable of disrupting β -sheet structure was shown to reverse the inherent protease resistance of PrP^{Sc}, preventing prion formation in infected cultured cells and increasing the survival of mice inoculated with PrP^{Sc} (Soto et al., 2000). In this case, the same drawbacks described for other peptide treatments, namely BBB penetrability and protease susceptibility, still apply.

A number of other classes of compounds have also been tested for the ability to inhibit PrP^{Sc} accumulation. Polyanionic glycans, such as sulphated glycans, are known to non-specifically and indirectly inhibit the entry of viruses in cells and were first tested when prions were thought to be an unconventional virus. Pentosan polysulfate (PPS) showed promise as a therapeutic when administered directly into the cerebral ventricular system of a vCJD patient (Todd et al., 2005); however, these results were not replicated in other patients (Whittle et al., 2006). A recent monitoring study of seven British patients treated with PPS showed that, in spite of complications related to the administration itself, some of the patients treated with PPS appear to have survived for long periods (Bone et al., 2008) (<http://www.prion.ucl.ac.uk/clinic-services/research/drug-treatments>). It cannot be concluded, however, that the PPS treatment itself had a beneficial effect, as it was impossible to make direct comparisons with similar, but untreated, patients. It is also very difficult to determine exactly the time of disease onset, and this obviously affects the estimation of survival time. An drawback of polyanions is that their penetration of the BBB is minimal, again requiring direct brain administration.

Heparan mimetics (Congo Red, porphyrins and phtalocyanins) are among the first compounds identified as capable of binding to PrP^C and preventing PrP^{Sc} production (Caughey and Race, 1992). Congo Red displayed an ability to inhibit PrP^{Sc}, but is also limited in its ability to pass the BBB. Additionally, Congo Red can be cleaved in the mammalian gut and intestines to release highly carcinogenic benzidine. Curcumin shares many properties of Congo Red without its toxicity, and was demonstrated to share its properties as an effective inhibitor of PrP^{Sc} formation (Caughey et al., 2003). Curcumin treatment in mice was shown to result in a significantly prolonged survival time (Riemer et al., 2008).

Porphyrins and phtalocyanines are classes of compounds that were shown to prophylactically inhibit PrP^{Sc} formation and prolong survival in hamsters. Nevertheless, treatment at the onset of clinical symptoms did not result in significantly prolonged survival rates (Priola et al., 2000). Recently, poly-L-lysine polymers were also shown to strongly inhibit PrP^{Sc} propagation *in vitro*, in cell culture, and in mouse models of prion disease (Ryou et al., 2011).

Acridine and phenothiazine derivatives, which include the antimalarial and antipsychotic drug quinacrine, can pass the BBB and are effective inhibitors of PrP^{Sc} formation both *in vitro* and in cultured cells (Barret et al., 2003; Doh-ura et al., 2004). Even though quinacrine did not show anti-prion effects in infected rodents, this drug has been used extensively as an experimental treatment in CJD patients (Nakajima et al., 2004; Martinez-Lage et al., 2005). Although treatment sometimes resulted in slight improvement in patients' condition, this

improvement was temporary and quinacrine treatment did not significantly delay disease progression. Following reports of improvement after quinacrine administration, two clinical trials were initiated. PRION-1 was led by Drs. Collinge and Darbyshire at the National Prion Clinic in the UK (<http://www.prion.ucl.ac.uk/clinic-services/research/drug-treatments>). The headline-making results of PRION-1 were published in 2009 and unfortunately showed no survival benefit of quinacrine (Collinge et al., 2009). A separate trial based in San Francisco, US, is currently active, led by Dr. Michael Geshwind (<http://clinicaltrials.gov/ct2/show/NCT00183092?term=prion&rank=2>). In addition, newer compounds with structures similar to quinacrine, trimipramine, and fluphenazine, have been shown to prolong the asymptomatic incubation period of prion infection, as well as to significantly reduce the degree of spongiosis, astrocytosis, and PrP^{Sc} levels in the brains of treated mice (Chung et al., 2011).

Tetracyclines also have been tested in prion therapy. Tetracycline efficiently crosses the BBB and can interact with amyloid fibrils that mimic the central features of the proteinase-resistant core of PrP^{Sc}. Incubation of tetracycline with purified PrP^{Sc} results in diminished proteinase resistance. Doxycycline administration leads to prolonged survival when administered 30 days after prion inoculation in mice. Preliminary data from observational studies in humans, in which doxycycline is administered for compassionate reasons, show to significantly prolong the survival of CJD patients, confirming the anti-prion activity of tetracyclines in humans. A drug vs. placebo clinical study is currently underway (Rigter et al., 2010) (<http://www.prion.ucl.ac.uk/clinic-services/research/drug-treatments>).

Interestingly, compounds that block amyloid aggregation may reach the clinic for the treatment of systemic amyloidoses long before amyloid-targeted drugs for neurodegenerative disorders, as these systemic disorders do not require compounds that cross the BBB. For example, transthyretin amyloidosis (ATTR) is caused by the deposition of transthyretin (TTR) amyloid fibrils in various tissues. The hereditary form of ATTR is caused by amyloidogenic mutations leading to abnormally folded monomers that self-assemble to amyloid fibrils. These TTR amyloid fibrils are then deposited extracellularly in various tissues. Two such compounds for the treatment of ATTR amyloidosis (Tafamidis from Pfizer and Scyllo-inositol from Elan) are currently in Phase III clinical trials (Aguzzi and O'Connor, 2010).

Alternative to the strategies aimed at reducing PrP^{Sc} accumulation, tentative therapies involving regeneration of the damaged tissues are also in progress. Cell therapy, which has been in trials for other neurodegenerative disorders, such as AD, is beginning to emerge as a viable option for prion diseases. In prion disease, intracerebral transplantation of fetal neural stem cells significantly extended both the incubation and survival time in mice, suggesting that stem cell therapy may be an effective possibility for human prion diseases (Relano-Gines et al., 2011).

The above mentioned therapeutic strategies all focus on impairing neurodegeneration engendered by these conditions. Nonetheless, for some neurodegenerative diseases, it has been proposed that compromised synaptic function is one of the earliest symptoms. Synaptic connectivity between neurons is critical for their survival and thus loss of synapses, spines, and dendrites precedes the loss of neuronal cell bodies. On the other hand, while synapses have an intrinsic plasticity and can be potentially replaced, neuronal loss is

thus far irreversible. This knowledge means that the early stages of disease represent a highly attractive target for treatment. In prion diseases, it was recently demonstrated that mice experimentally infected with prions show changes in motivational behaviors long before the emergence of motor signs, and that these behavioral changes correlate with synaptic loss. Further, preventing neuronal death, but not synaptic dysfunction, does not halt the development of clinical disease in mice (Moreno et al., 2003; White and Mallucci, 2009; Verity and Mallucci, 2011). Many of the proposed therapies, therefore, may prove effective if administered at the time of synapse loss, rather than at the later stage of neuronal death. Thus, the identification of early dysfunction would help to direct therapies towards the earlier stages of disease, when rescue may still be possible. This may reflect a critical window for neuronal rescue that depends upon the kinetics of prion spread. The pre-clinical diagnosis of TSE is therefore of importance in the improvement and development of new therapies.

Ideally, a successful prion disease therapy should be able to cross the BBB or be delivered to the CNS, be non-toxic and effective at physiological concentrations, be efficient even after PrP^{Sc} accumulation, and would either not compromise PrP^C functionality or would allow for its restoration. Unfortunately, current therapeutic strategies are either only useful as a prophylactic or their applicability *in vivo* remains to be determined.

There are currently only a small number of clinical trials for treatment of CJD patients. Most reports include a single patient, and very few studies have been conducted under strict conditions. Due to the rarity of these diseases, studies usually contain a mixture of patients with different prion diseases with the assumption that the treatment may be effective for all of them. This is not necessarily true, as different prion strains may exhibit different sensitivities to drug treatments.

In the future, a combination of therapies aimed lowering the amount of PrP^C available for conversion with other strategies may prove the most effective. For example, the combination of RNAi against the PrP^C mRNA with a drug to increase endogenous clearance of PrP^{Sc} may be likely to delay disease progression. Hence, potential therapies need not aim for the total ablation of aberrant protein expression, but instead could have the lowering levels of expression below the cellular threshold for clearance as their goal. Of course, from a public health perspective, the elimination of neurotoxicity without abolishing prion replication maintains infectivity, leaving open the possibility of prion transmission.

While the ablation of PrP^C expression in adult mice is well tolerated, the consequences of reducing PrP^C in humans remain unknown. It may be that the risk-benefit ratio of the possible adverse effects of PrP^C loss against the potential for improved survival and protection against neuronal loss will determine future therapies for prion and other neurodegenerative disorders.

7. Concluding remarks

Prion diseases have represented a challenge to researchers and clinicians since the discovery of scrapie and kuru. The determination that scrapie, kuru, and CJD are related diseases and that they are both hereditary and transmissible, was a task that took many decades to resolve.

The discovery of the nature of the etiological agent responsible for these diseases also represented a breakthrough in the traditional concepts of molecular biology, and modified the paradigm that stated that flow of genetic information was mediated only by nucleic acids. A small number of proteins, particularly in yeast, are now known to have prion properties and are able to transmit information to their offspring (Uptain and Lindquist, 2002). Even more impressive, other neurodegenerative diseases, such as tauopathies, have recently been demonstrated to be transmissible in transgenic mouse models (Clavaguera et al., 2009).

Although much progress has been made in the understanding of prion disease, many unanswered questions remain. For example, the exact molecular mechanism by which the PrP^C alteration leads to neurodegeneration is unknown. As a consequence, no effective therapy against these diseases has been developed. Also lacking is a precise, low-cost, high-throughput diagnostic tool, and an advance in this aspect could contribute to the chances of a successful therapy, due to the possibility of detecting the illness before the onset of clinical symptoms.

The realization that diseases characterized by protein conformational disorders have many aspects in common is also a recent development. The presence of soluble oligomeric forms of the proteins responsible for these different diseases is currently recognized as the most likely entities to induce neuronal damage, and plaques and proteinaceous aggregates are now thought to play potentially protective roles in sequestering toxic oligomeric proteins. Thus, successful diagnostic or therapeutic strategies directed at one of these diseases will likely open new fields for all the others.

8. References

- (1987) Rapidly progressive dementia in a patient who received a cadaveric dura mater graft. *MMWR Morb Mortal Wkly Rep* 36:49-50, 55.
- (1997) Medicinal and other products and human and animal transmissible spongiform encephalopathies: memorandum from a WHO meeting. *Bull World Health Organ* 75:505-513.
- Adams JM (1975) Persistent or slow viral infections and related diseases. *West J Med* 122:380-393.
- Aguzzi A (1996) Pathogenesis of spongiform encephalopathies: an update. *Int Arch Allergy Immunol* 110:99-106.
- Aguzzi A (2006) Prion diseases of humans and farm animals: epidemiology, genetics, and pathogenesis. *J Neurochem* 97:1726-1739.
- Aguzzi A, Montrasio F, Kaeser PS (2001) Prions: health scare and biological challenge. *Nat Rev Mol Cell Biol* 2:118-126.
- Aguzzi A, O'Connor T (2010) Protein aggregation diseases: pathogenicity and therapeutic perspectives. *Nat Rev Drug Discov* 9:237-248.
- Aguzzi A, Polymenidou M (2004) Mammalian prion biology: one century of evolving concepts. *Cell* 116:313-327.
- Aguzzi A, Weissmann C (1996) Spongiform encephalopathies: a suspicious signature. *Nature* 383:666-667.
- Barret A, Tagliavini F, Forloni G, Bate C, Salmona M, Colombo L, De LA, Limido L, Suardi S, Rossi G, Auvre F, Adjou KT, Sales N, Williams A, Lasmezas C, Deslys JP (2003) Evaluation of quinacrine treatment for prion diseases. *J Virol* 77:8462-8469.

- Bernoulli C, Siegfried J, Baumgartner G, Regli F, Rabinowicz T, Gajdusek DC, Gibbs CJ, Jr. (1977) Danger of accidental person-to-person transmission of Creutzfeldt-Jakob disease by surgery. *Lancet* 1:478-479.
- Bertoni JM, Brown P, Goldfarb LG, Rubenstein R, Gajdusek DC (1992) Familial Creutzfeldt-Jakob disease (codon 200 mutation) with supranuclear palsy. *JAMA* 268:2413-2415.
- Bolton DC, McKinley MP, Prusiner SB (1982) Identification of a protein that purifies with the scrapie prion. *Science* 218:1309-1311.
- Bone I, Belton L, Walker AS, Darbyshire J (2008) Intraventricular pentosan polysulphate in human prion diseases: an observational study in the UK. *Eur J Neurol* 15:458-464.
- Brown P (1995) Can Creutzfeldt-Jakob disease be transmitted by transfusion? *Curr Opin Hematol* 2:472-477.
- Brown P, Brandel JP, Preece M, Sato T (2006) Iatrogenic Creutzfeldt-Jakob disease: the waning of an era. *Neurology* 67:389-393.
- Brown P, Gibbs CJ, Jr., Rodgers-Johnson P, Asher DM, Sulima MP, Bacote A, Goldfarb LG, Gajdusek DC (1994) Human spongiform encephalopathy: the National Institutes of Health series of 300 cases of experimentally transmitted disease. *Ann Neurol* 35:513-529.
- Brown P, Preece MA, Will RG (1992) "Friendly fire" in medicine: hormones, homografts, and Creutzfeldt-Jakob disease. *Lancet* 340:24-27.
- Bruce ME, Will RG, Ironside JW, McConnell I, Drummond D, Suttie A, McCardle L, Chree A, Hope J, Birkett C, Cousens S, Fraser H, Bostock CJ (1997) Transmissions to mice indicate that 'new variant' CJD is caused by the BSE agent. *Nature* 389:498-501.
- Budka H (2003) Neuropathology of prion diseases. *Br Med Bull* 66:121-130.
- Bueler H, Aguzzi A, Sailer A, Greiner RA, Autenried P, Aguet M, Weissmann C (1993) Mice devoid of PrP are resistant to scrapie. *Cell* 73:1339-1347.
- Caughey B, Race RE (1992) Potent inhibition of scrapie-associated PrP accumulation by congo red. *J Neurochem* 59:768-771.
- Caughey B, Raymond LD, Raymond GJ, Maxson L, Silveira J, Baron GS (2003) Inhibition of protease-resistant prion protein accumulation in vitro by curcumin. *J Virol* 77:5499-5502.
- Chabry J, Priola SA, Wehrly K, Nishio J, Hope J, Chesebro B (1999) Species-independent inhibition of abnormal prion protein (PrP) formation by a peptide containing a conserved PrP sequence. *J Virol* 73:6245-6250.
- Chesebro B (2003) Introduction to the transmissible spongiform encephalopathies or prion diseases. *Br Med Bull* 66:1-20.
- Chung E, Prelli F, Dealler S, Lee WS, Chang YT, Wisniewski T (2011) Styryl-based and tricyclic compounds as potential anti-prion agents. *PLoS One* 6:e24844.
- Clavaguera F, Bolmont T, Crowther RA, Abramowski D, Frank S, Probst A, Fraser G, Stalder AK, Beibel M, Staufenbiel M, Jucker M, Goedert M, Tolnay M (2009) Transmission and spreading of tauopathy in transgenic mouse brain. *Nat Cell Biol* 11:909-913.
- Collinge J, Gorham M, Hudson F, Kennedy A, Keogh G, Pal S, Rossor M, Rudge P, Siddique D, Spyer M, Thomas D, Walker S, Webb T, Wroe S, Darbyshire J (2009) Safety and efficacy of quinacrine in human prion disease (PRION-1 study): a patient-preference trial. *Lancet Neurol* 8:334-344.

- Collinge J, Whitfield J, McKintosh E, Beck J, Mead S, Thomas DJ, Alpers MP (2006) Kuru in the 21st century--an acquired human prion disease with very long incubation periods. *Lancet* 367:2068-2074.
- Collins S, Law MG, Fletcher A, Boyd A, Kaldor J, Masters CL (1999) Surgical treatment and risk of sporadic Creutzfeldt-Jakob disease: a case-control study. *Lancet* 353:693-697.
- Collins SJ, Lawson VA, Masters CL (2004) Transmissible spongiform encephalopathies. *Lancet* 363:51-61.
- Daude N, Marella M, Chabry J (2003) Specific inhibition of pathological prion protein accumulation by small interfering RNAs. *J Cell Sci* 116:2775-2779.
- de SR, Findlay C, Awad I, Harries-Jones R, Knight R, Will R (1997) Creutzfeldt-Jakob disease in the elderly. *Postgrad Med J* 73:557-559.
- Deslys JP, Lasmezias CI, Billette d, V, Jaegly A, Dormont D (1996) Creutzfeldt-Jakob disease. *Lancet* 347:1332.
- Doh-ura K, Ishikawa K, Murakami-Kubo I, Sasaki K, Mohri S, Race R, Iwaki T (2004) Treatment of transmissible spongiform encephalopathy by intraventricular drug infusion in animal models. *J Virol* 78:4999-5006.
- Duffy P, Wolf J, Collins G, DeVoe AG, Streeten B, Cowen D (1974) Letter: Possible person-to-person transmission of Creutzfeldt-Jakob disease. *N Engl J Med* 290:692-693.
- Gajdusek DC (1977) Unconventional viruses and the origin and disappearance of kuru. *Science* 197:943-960.
- Gajdusek DC (2008) Early images of kuru and the people of Okapa. *Philos Trans R Soc Lond B Biol Sci* 363:3636-3643.
- Gajdusek DC, Gibbs CJ, Alpers M (1966) Experimental transmission of a Kuru-like syndrome to chimpanzees. *Nature* 209:794-796.
- Gajdusek DC, REID LH (1961) Studies on kuru. IV. The kuru pattern in Moke, a representative Fore village. *Am J Trop Med Hyg* 10:628-638.
- Gajdusek DC, ZIGAS V (1957) Degenerative disease of the central nervous system in New Guinea; the endemic occurrence of kuru in the native population. *N Engl J Med* 257:974-978.
- Gajdusek DC, ZIGAS V (1959) Kuru; clinical, pathological and epidemiological study of an acute progressive degenerative disease of the central nervous system among natives of the Eastern Highlands of New Guinea. *Am J Med* 26:442-469.
- Gambetti P, Petersen RB, Parchi P, Chen SG, Capellari S, Goldfarb L, Gabizon R, Montagna P, Lugaresi E, Piccardo P, Ghetti B (1999) Inherited Prion Diseases. In: *Prion Biology and Diseases* (Prusiner S, ed), pp 509-583. Cold Spring Harbor Laboratory Press.
- Geschwind MD, Shu H, Haman A, Sejvar JJ, Miller BL (2008) Rapidly progressive dementia. *Ann Neurol* 64:97-108.
- Ghetti B, Dlouhy SR, Giaccone G, Bugiani O, Frangione B, Farlow MR, Tagliavini F (1995) Gerstmann-Straussler-Scheinker disease and the Indiana kindred. *Brain Pathol* 5:61-75.
- Gibbs CJ, Jr., Gajdusek DC, Asher DM, Alpers MP, Beck E, Daniel PM, Matthews WB (1968) Creutzfeldt-Jakob disease (spongiform encephalopathy): transmission to the chimpanzee. *Science* 161:388-389.
- Glatzel M, Stoeck K, Seeger H, Luhrs T, Aguzzi A (2005) Human prion diseases: molecular and clinical aspects. *Arch Neurol* 62:545-552.

- Goldfarb LG, Brown P, McCombie WR, Goldgaber D, Swergold GD, Wills PR, Cervenakova L, Baron H, Gibbs CJ, Jr., Gajdusek DC (1991a) Transmissible familial Creutzfeldt-Jakob disease associated with five, seven, and eight extra octapeptide coding repeats in the PRNP gene. *Proc Natl Acad Sci U S A* 88:10926-10930.
- Goldfarb LG, Brown P, Mitrova E, Cervenakova L, Goldin L, Korczyn AD, Chapman J, Galvez S, Cartier L, Rubenstein R, . (1991b) Creutzfeldt-Jacob disease associated with the PRNP codon 200Lys mutation: an analysis of 45 families. *Eur J Epidemiol* 7:477-486.
- Goldfarb LG, Mitrova E, Brown P, Toh BK, Gajdusek DC (1990) Mutation in codon 200 of scrapie amyloid protein gene in two clusters of Creutzfeldt-Jakob disease in Slovakia. *Lancet* 336:514-515.
- Goldgaber D, Goldfarb LG, Brown P, Asher DM, Brown WT, Lin S, Teener JW, Feinstone SM, Rubenstein R, Kascsak RJ, . (1989) Mutations in familial Creutzfeldt-Jakob disease and Gerstmann-Straussler-Scheinker's syndrome. *Exp Neurol* 106:204-206.
- Gordon WS (1946) Advances in veterinary research. *Vet Rec* 58:516-525.
- Griffith JS (1967) Self-replication and scrapie. *Nature* 215:1043-1044.
- Hainfellner JA, Jellinger K, Diringer H, Guentchev M, Kleinert R, Pilz P, Maier H, Budka H (1996) Creutzfeldt-Jakob disease in Austria. *J Neurol Neurosurg Psychiatry* 61:139-142.
- Hamaguchi T, Noguchi-Shinohara M, Nozaki I, Nakamura Y, Sato T, Kitamoto T, Mizusawa H, Yamada M (2009) The risk of iatrogenic Creutzfeldt-Jakob disease through medical and surgical procedures. *Neuropathology* 29:625-631.
- Handisurya A, Gilch S, Winter D, Shafti-Keramat S, Maurer D, Schatzl HM, Kirnbauer R (2007) Vaccination with prion peptide-displaying papillomavirus-like particles induces autoantibodies to normal prion protein that interfere with pathologic prion protein production in infected cells. *FEBS J* 274:1747-1758.
- Harper PS (1977) Mendelian inheritance or transmissible agent? The lesson Kuru and the Australia antigen. *J Med Genet* 14:389-398.
- Heppner FL, Musahl C, Arrighi I, Klein MA, Rulicke T, Oesch B, Zinkernagel RM, Kalinke U, Aguzzi A (2001) Prevention of scrapie pathogenesis by transgenic expression of anti-prion protein antibodies. *Science* 294:178-182.
- Hill AF, Desbruslais M, Joiner S, Sidle KC, Gowland I, Collinge J, Doey LJ, Lantos P (1997a) The same prion strain causes vCJD and BSE. *Nature* 389:448-50, 526.
- Hill AF, Zeidler M, Ironside J, Collinge J (1997b) Diagnosis of new variant Creutzfeldt-Jakob disease by tonsil biopsy. *Lancet* 349:99-100.
- Horiuchi M, Priola SA, Chabry J, Caughey B (2000) Interactions between heterologous forms of prion protein: binding, inhibition of conversion, and species barriers. *Proc Natl Acad Sci U S A* 97:5836-5841.
- Hsiao K, Baker HF, Crow TJ, Poulter M, Owen F, Terwilliger JD, Westaway D, Ott J, Prusiner SB (1989) Linkage of a prion protein missense variant to Gerstmann-Straussler syndrome. *Nature* 338:342-345.
- Hsiao K, Meiner Z, Kahana E, Cass C, Kahana I, Avrahami D, Scarlato G, Abramsky O, Prusiner SB, Gabizon R (1991a) Mutation of the prion protein in Libyan Jews with Creutzfeldt-Jakob disease. *N Engl J Med* 324:1091-1097.

- Hsiao KK, Cass C, Schellenberg GD, Bird T, Devine-Gage E, Wisniewski H, Prusiner SB (1991b) A prion protein variant in a family with the telencephalic form of Gerstmann-Straussler-Scheinker syndrome. *Neurology* 41:681-684.
- Hsich G, Kenney K, Gibbs CJ, Lee KH, Harrington MG (1996) The 14-3-3 brain protein in cerebrospinal fluid as a marker for transmissible spongiform encephalopathies. *N Engl J Med* 335:924-930.
- Ironside JW (2010) Variant Creutzfeldt-Jakob disease. *Haemophilia* 16 Suppl 5:175-180.
- Knight R (2010) The risk of transmitting prion disease by blood or plasma products. *Transfus Apher Sci* 43:387-391.
- Kovacs GG, Zerbi P, Voigtlander T, Strohschneider M, Trabattoni G, Hainfellner JA, Budka H (2002) The prion protein in human neurodegenerative disorders. *Neurosci Lett* 329:269-272.
- Kretzschmar HA, Honold G, Seitelberger F, Feucht M, Wessely P, Mehraein P, Budka H (1991) Prion protein mutation in family first reported by Gerstmann, Straussler, and Scheinker. *Lancet* 337:1160.
- Ladogana A, Puopolo M, Poleggi A, Almonti S, Mellina V, Equestre M, Pocchiari M (2005) High incidence of genetic human transmissible spongiform encephalopathies in Italy. *Neurology* 64:1592-1597.
- Llewelyn CA, Hewitt PE, Knight RS, Amar K, Cousens S, Mackenzie J, Will RG (2004) Possible transmission of variant Creutzfeldt-Jakob disease by blood transfusion. *Lancet* 363:417-421.
- Lugaresi E, Medori R, Montagna P, Baruzzi A, Cortelli P, Lugaresi A, Tinuper P, Zucconi M, Gambetti P (1986) Fatal familial insomnia and dysautonomia with selective degeneration of thalamic nuclei. *N Engl J Med* 315:997-1003.
- Mabbott NA, Young J, McConnell I, Bruce ME (2003) Follicular dendritic cell dedifferentiation by treatment with an inhibitor of the lymphotoxin pathway dramatically reduces scrapie susceptibility. *J Virol* 77:6845-6854.
- Martinez-Lage JF, Rabano A, Bermejo J, Martinez PM, Guerrero MC, Contreras MA, Lunar A (2005) Creutzfeldt-Jakob disease acquired via a dural graft: failure of therapy with quinacrine and chlorpromazine. *Surg Neurol* 64:542-5, discussion.
- Masters CL, Gajdusek DC, Gibbs CJ, Jr. (1981) Creutzfeldt-Jakob disease virus isolations from the Gerstmann-Straussler syndrome with an analysis of the various forms of amyloid plaque deposition in the virus-induced spongiform encephalopathies. *Brain* 104:559-588.
- McCutcheon S, Alejo Blanco AR, Houston EF, de WC, Tan BC, Smith A, Groschup MH, Hunter N, Hornsey VS, MacGregor IR, Prowse CV, Turner M, Manson JC (2011) All clinically-relevant blood components transmit prion disease following a single blood transfusion: a sheep model of vCJD. *PLoS One* 6:e23169.
- Medori R, Montagna P, Tritschler HJ, LeBlanc A, Cortelli P, Tinuper P, Lugaresi E, Gambetti P (1992a) Fatal familial insomnia: a second kindred with mutation of prion protein gene at codon 178. *Neurology* 42:669-670.
- Medori R, Tritschler HJ, LeBlanc A, Villare F, Manetto V, Chen HY, Xue R, Leal S, Montagna P, Cortelli P, . (1992b) Fatal familial insomnia, a prion disease with a mutation at codon 178 of the prion protein gene. *N Engl J Med* 326:444-449.


- Meyer RK, McKinley MP, Bowman KA, Braunfeld MB, Barry RA, Prusiner SB (1986) Separation and properties of cellular and scrapie prion proteins. *Proc Natl Acad Sci U S A* 83:2310-2314.
- Minor P, Newham J, Jones N, Bergeron C, Gregori L, Asher D, van EF, Stroebel T, Vey M, Barnard G, Head M (2004) Standards for the assay of Creutzfeldt-Jakob disease specimens. *J Gen Virol* 85:1777-1784.
- Montrasio F, Frigg R, Glatzel M, Klein MA, Mackay F, Aguzzi A, Weissmann C (2000) Impaired prion replication in spleens of mice lacking functional follicular dendritic cells. *Science* 288:1257-1259.
- Moreno CR, Lantier F, Lantier I, Sarradin P, Elsen JM (2003) Detection of new quantitative trait Loci for susceptibility to transmissible spongiform encephalopathies in mice. *Genetics* 165:2085-2091.
- Mukherjee A, Morales-Scheihing D, Gonzalez-Romero D, Green K, Tagliatela G, Soto C (2010) Calcineurin inhibition at the clinical phase of prion disease reduces neurodegeneration, improves behavioral alterations and increases animal survival. *PLoS Pathog* 6:e1001138.
- Murray K (2011) Creutzfeldt-Jacob disease mimics, or how to sort out the subacute encephalopathy patient. *Pract Neurol* 11:19-28.
- Murray K, Ritchie DL, Bruce M, Young CA, Doran M, Ironside JW, Will RG (2008) Sporadic Creutzfeldt-Jakob disease in two adolescents. *J Neurol Neurosurg Psychiatry* 79:14-18.
- Nakajima M, Yamada T, Kusuhara T, Furukawa H, Takahashi M, Yamauchi A, Kataoka Y (2004) Results of quinacrine administration to patients with Creutzfeldt-Jakob disease. *Dement Geriatr Cogn Disord* 17:158-163.
- Nathanson N, Wilesmith J, Griot C (1997) Bovine spongiform encephalopathy (BSE): causes and consequences of a common source epidemic. *Am J Epidemiol* 145:959-969.
- Nikles D, Bach P, Boller K, Merten CA, Montrasio F, Heppner FL, Aguzzi A, Cichutek K, Kalinke U, Buchholz CJ (2005) Circumventing tolerance to the prion protein (PrP): vaccination with PrP-displaying retrovirus particles induces humoral immune responses against the native form of cellular PrP. *J Virol* 79:4033-4042.
- Oesch B, Westaway D, Walchli M, McKinley MP, Kent SB, Aebersold R, Barry RA, Tempst P, Teplow DB, Hood LE, . (1985) A cellular gene encodes scrapie PrP 27-30 protein. *Cell* 40:735-746.
- Otto M, Wiltfang J, Cepek L, Neumann M, Mollenhauer B, Steinacker P, Ciesielczyk B, Schulz-Schaeffer W, Kretschmar HA, Poser S (2002) Tau protein and 14-3-3 protein in the differential diagnosis of Creutzfeldt-Jakob disease. *Neurology* 58:192-197.
- Padovani A, D'Alessandro M, Parchi P, Cortelli P, Anzola GP, Montagna P, Vignolo LA, Petraroli R, Pocchiari M, Lugaresi E, Gambetti P (1998) Fatal familial insomnia in a new Italian kindred. *Neurology* 51:1491-1494.
- Palmer MS, Dryden AJ, Hughes JT, Collinge J (1991) Homozygous prion protein genotype predisposes to sporadic Creutzfeldt-Jakob disease. *Nature* 352:340-342.
- Priola SA, Raines A, Caughey WS (2000) Porphyrin and phthalocyanine antiscrapie compounds. *Science* 287:1503-1506.
- Prusiner S (1999) An Introduction to Prion Biology and Diseases. In: *Prion Biology and Disease* (Prusiner S, ed), pp 1-66. Cold Spring Harbor Laboratory Press.

- Prusiner SB (1982) Novel proteinaceous infectious particles cause scrapie. *Science* 216:136-144.
- Prusiner SB (1989) Creutzfeldt-Jakob disease and scrapie prions. *Alzheimer Dis Assoc Disord* 3:52-78.
- Prusiner SB, McKinley MP, Bowman KA, Bolton DC, Bendheim PE, Groth DF, Glenner GG (1983) Scrapie prions aggregate to form amyloid-like birefringent rods. *Cell* 35:349-358.
- Radbauer C, Hainfellner JA, Jellinger K, Pilz P, Maier H, Kleinert R, Budka H (1998) [Epidemiology of transmissible spongiform encephalopathies (prion diseases) in Austria]. *Wien Med Wochenschr* 148:101-106.
- Relano-Gines A, Lehmann S, Bencsik A, Herva ME, Torres JM, Crozet CA (2011) Stem cell therapy extends incubation and survival time in prion-infected mice in a time window-dependant manner. *J Infect Dis* 204:1038-1045.
- Riemer C, Burwinkel M, Schwarz A, Gultner S, Mok SW, Heise I, Holtkamp N, Baier M (2008) Evaluation of drugs for treatment of prion infections of the central nervous system. *J Gen Virol* 89:594-597.
- Rigter A, Langeveld JP, van Zijderveld FG, Bossers A (2010) Prion protein self-interactions: a gateway to novel therapeutic strategies? *Vaccine* 28:7810-7823.
- Ryou C, Titlow WB, Mays CE, Bae Y, Kim S (2011) The suppression of prion propagation using poly-L-lysine by targeting plasminogen that stimulates prion protein conversion. *Biomaterials* 32:3141-3149.
- Sadowski MJ, Pankiewicz J, Prelli F, Scholtzova H, Spinner DS, Kascsak RB, Kascsak RJ, Wisniewski T (2009) Anti-PrP Mab 6D11 suppresses PrP(Sc) replication in prion infected myeloid precursor line FDC-P1/22L and in the lymphoreticular system in vivo. *Neurobiol Dis* 34:267-278.
- Satoh K, Tobiume M, Matsui Y, Mutsukura K, Nishida N, Shiga Y, Eguchi K, Shirabe S, Sata T (2010) Establishment of a standard 14-3-3 protein assay of cerebrospinal fluid as a diagnostic tool for Creutzfeldt-Jakob disease. *Lab Invest* 90:1637-1644.
- Schneider K, Fangerau H, Michaelsen B, Raab WH (2008) The early history of the transmissible spongiform encephalopathies exemplified by scrapie. *Brain Res Bull* 77:343-355.
- Schwarz A, Kratke O, Burwinkel M, Riemer C, Schultz J, Henklein P, Bamme T, Baier M (2003) Immunisation with a synthetic prion protein-derived peptide prolongs survival times of mice orally exposed to the scrapie agent. *Neurosci Lett* 350:187-189.
- Shastry BS (2003) Neurodegenerative disorders of protein aggregation. *Neurochem Int* 43:1-7.
- Sigurdsson EM, Brown DR, Daniels M, Kascsak RJ, Kascsak R, Carp R, Meeker HC, Frangione B, Wisniewski T (2002) Immunization delays the onset of prion disease in mice. *Am J Pathol* 161:13-17.
- Sigurdsson EM, Sy MS, Li R, Scholtzova H, Kascsak RJ, Kascsak R, Carp R, Meeker HC, Frangione B, Wisniewski T (2003) Anti-prion antibodies for prophylaxis following prion exposure in mice. *Neurosci Lett* 336:185-187.
- Solassol J, Crozet C, Perrier V, Leclaire J, Beranger F, Caminade AM, Meunier B, Dormont D, Majoral JP, Lehmann S (2004) Cationic phosphorus-containing dendrimers reduce

- prion replication both in cell culture and in mice infected with scrapie. *J Gen Virol* 85:1791-1799.
- Solforosi L, Criado JR, McGavern DB, Wirz S, Sanchez-Alavez M, Sugama S, DeGiorgio LA, Volpe BT, Wiseman E, Abalos G, Masliah E, Gilden D, Oldstone MB, Conti B, Williamson RA (2004) Cross-linking cellular prion protein triggers neuronal apoptosis in vivo. *Science* 303:1514-1516.
- Soto C (2003) Unfolding the role of protein misfolding in neurodegenerative diseases. *Nat Rev Neurosci* 4:49-60.
- Soto C, Kascsak RJ, Saborio GP, Aucouturier P, Wisniewski T, Prelli F, Kascsak R, Mendez E, Harris DA, Ironside J, Tagliavini F, Carp RI, Frangione B (2000) Reversion of prion protein conformational changes by synthetic beta-sheet breaker peptides. *Lancet* 355:192-197.
- Stack M, Jeffrey M, Gubbins S, Grimmer S, Gonzalez L, Martin S, Chaplin M, Webb P, Simmons M, Spencer Y, Bellerby P, Hope J, Wilesmith J, Matthews D (2006) Monitoring for bovine spongiform encephalopathy in sheep in Great Britain, 1998-2004. *J Gen Virol* 87:2099-2107.
- Supattapone S, Wille H, Uyechi L, Safar J, Tremblay P, Szoka FC, Cohen FE, Prusiner SB, Scott MR (2001) Branched polyamines cure prion-infected neuroblastoma cells. *J Virol* 75:3453-3461.
- Todd NV, Morrow J, Doh-ura K, Dealler S, O'Hare S, Farling P, Duddy M, Rainov NG (2005) Cerebroventricular infusion of pentosan polysulphate in human variant Creutzfeldt-Jakob disease. *J Infect* 50:394-396.
- Toupet K, Compan V, Crozet C, Mourton-Gilles C, Mestre-Frances N, Ibos F, Corbeau P, Verdier JM, Perrier V (2008) Effective gene therapy in a mouse model of prion diseases. *PLoS One* 3:e2773.
- Tyrrell DAJ, Taylor K (1996) Handling the BSE Epidemic in Great Britain. In: *Prion Diseases* (Baker HF, Ridley RM, eds), pp 175-198. Humana Press.
- Uptain SM, Lindquist S (2002) Prions as protein-based genetic elements. *Annu Rev Microbiol* 56:703-741.
- Valleron AJ, Boelle PY, Will R, Cesbron JY (2001) Estimation of epidemic size and incubation time based on age characteristics of vCJD in the United Kingdom. *Science* 294:1726-1728.
- Venneti S (2010) Prion diseases. *Clin Lab Med* 30:293-309.
- Verity NC, Mallucci GR (2011) Rescuing neurons in prion disease. *Biochem J* 433:19-29.
- Vitali P, Maccagnano E, Caverzasi E, Henry RG, Haman A, Torres-Chae C, Johnson DY, Miller BL, Geschwind MD (2011) Diffusion-weighted MRI hyperintensity patterns differentiate CJD from other rapid dementias. *Neurology* 76:1711-1719.
- Ward HJ, Everington D, Croes EA, Alperovitch A, Delasnerie-Laupretre N, Zerr I, Poser S, van Duijn CM (2002) Sporadic Creutzfeldt-Jakob disease and surgery: a case-control study using community controls. *Neurology* 59:543-548.
- Wells GA, Wilesmith JW (1995) The neuropathology and epidemiology of bovine spongiform encephalopathy. *Brain Pathol* 5:91-103.
- White AR, Enever P, Tayebi M, Mushens R, Linehan J, Brandner S, Anstee D, Collinge J, Hawke S (2003) Monoclonal antibodies inhibit prion replication and delay the development of prion disease. *Nature* 422:80-83.

- White MD, Farmer M, Mirabile I, Brandner S, Collinge J, Mallucci GR (2008) Single treatment with RNAi against prion protein rescues early neuronal dysfunction and prolongs survival in mice with prion disease. *Proc Natl Acad Sci U S A* 105:10238-10243.
- White MD, Mallucci GR (2009) RNAi for the treatment of prion disease: a window for intervention in neurodegeneration? *CNS Neurol Disord Drug Targets* 8:342-352.
- Whittle IR, Knight RS, Will RG (2006) Unsuccessful intraventricular pentosan polysulphate treatment of variant Creutzfeldt-Jakob disease. *Acta Neurochir (Wien)* 148:677-679.
- Wilesmith JW, Ryan JB, Atkinson MJ (1991) Bovine spongiform encephalopathy: epidemiological studies on the origin. *Vet Rec* 128:199-203.
- Will RG (2003) Acquired prion disease: iatrogenic CJD, variant CJD, kuru. *Br Med Bull* 66:255-265.
- Will RG, Alpers MP, Dormont D, Schonberger LB, Tateishi J (1999) Infectious and Sporadic Prion Diseases. In: *Prion Biology and Diseases* (Prusiner S, ed), pp 465-507. Cold Spring Harbor Laboratory Press.
- Will RG, Ironside JW, Zeidler M, Cousens SN, Estibeiro K, Alperovitch A, Poser S, Pocchiari M, Hofman A, Smith PG (1996) A new variant of Creutzfeldt-Jakob disease in the UK. *Lancet* 347:921-925.
- Will RG, Zeidler M, Stewart GE, Macleod MA, Ironside JW, Cousens SN, Mackenzie J, Estibeiro K, Green AJ, Knight RS (2000) Diagnosis of new variant Creutzfeldt-Jakob disease. *Ann Neurol* 47:575-582.
- Wisniewski T, Goni F (2010) Immunomodulation for prion and prion-related diseases. *Expert Rev Vaccines* 9:1441-1452.
- Zanusso G, Fiorini M, Ferrari S, Gajofatto A, Cagnin A, Galassi A, Richelli S, Monaco S (2011) Cerebrospinal fluid markers in sporadic creutzfeldt-jakob disease. *Int J Mol Sci* 12:6281-6292.
- Zetterstrom R (2010) The discovery of misfolded prions as an infectious agent. *Acta Paediatr* 99:1910-1913.

IntechOpen



Brain Damage - Bridging Between Basic Research and Clinics

Edited by Dr. Alina Gonzalez-Quevedo

ISBN 978-953-51-0375-2

Hard cover, 282 pages

Publisher InTech

Published online 16, March, 2012

Published in print edition March, 2012

"Brain Damage - Bridging Between Basic Research and Clinics" represents a collection of papers in an attempt to provide an up-to-date approach to the fascinating topic of brain damage in different pathological situations, combining the authors' personal experiences with current knowledge in this field. In general, the necessary link between basic and clinical neurosciences is highlighted, as it is through this interaction that the theoretical understanding of the pathophysiological mechanisms can be successfully translated into better ways to diagnose, treat and prevent the catastrophic events that occur when the brain suffers from external or internal noxious events. The book spans different aspects of brain injury, starting from damage occurring in the fetal and child brain, followed by different neurodegenerative processes. Attention is also focused on the negative effects of drug addictions and sleep deprivation on the brain, as well as on the early assessment of brain injury for preventive strategies employing sensitive biomarkers.

How to reference

In order to correctly reference this scholarly work, feel free to copy and paste the following:

Glauca N. M. Hajj, Tiago G. Santos, Michele C. Landemberger and Marilene H. Lopes (2012). Transmissible Spongiform Encephalopathies, *Brain Damage - Bridging Between Basic Research and Clinics*, Dr. Alina Gonzalez-Quevedo (Ed.), ISBN: 978-953-51-0375-2, InTech, Available from:
<http://www.intechopen.com/books/brain-damage-bridging-between-basic-research-and-clinics/transmissible-spongiform-encephalopathies-tses-pathophysiology-and-molecular-aspects>

INTECH
open science | open minds

InTech Europe

University Campus STeP Ri
Slavka Krautzeka 83/A
51000 Rijeka, Croatia
Phone: +385 (51) 770 447
Fax: +385 (51) 686 166
www.intechopen.com

InTech China

Unit 405, Office Block, Hotel Equatorial Shanghai
No.65, Yan An Road (West), Shanghai, 200040, China
中国上海市延安西路65号上海国际贵都大饭店办公楼405单元
Phone: +86-21-62489820
Fax: +86-21-62489821

© 2012 The Author(s). Licensee IntechOpen. This is an open access article distributed under the terms of the [Creative Commons Attribution 3.0 License](#), which permits unrestricted use, distribution, and reproduction in any medium, provided the original work is properly cited.

IntechOpen

IntechOpen