

# We are IntechOpen, the world's leading publisher of Open Access books Built by scientists, for scientists

**4,800**

Open access books available

**122,000**

International authors and editors

**135M**

Downloads

Our authors are among the

**154**

Countries delivered to

**TOP 1%**

most cited scientists

**12.2%**

Contributors from top 500 universities



**WEB OF SCIENCE™**

Selection of our books indexed in the Book Citation Index  
in Web of Science™ Core Collection (BKCI)

Interested in publishing with us?  
Contact [book.department@intechopen.com](mailto:book.department@intechopen.com)

Numbers displayed above are based on latest data collected.

For more information visit [www.intechopen.com](http://www.intechopen.com)



## Echinococcosis/Hydatidosis

Antoni Soriano Arandes and Frederic Gómez Bertomeu  
University Hospital Joan XXIII of Tarragona  
Spain

### 1. Introduction

Echinococcosis is a zoonotic infection caused by adult or larval (metacestode) stages of cestodes belonging to the genus *Echinococcus* and the family *Taeniidae*. Life cycles imply two mammal hosts. Definitive hosts are carnivores containing adult forms in the gut. The infection is acquired by the intermediate hosts and humans after the ingestion of eggs from the feces of carnivorous definitive hosts, which harbour the adult egg-producing stage in the intestine. Eggs ingested by infected human develop into the infective metacestode stage causing various forms of Echinococcosis. The disease in humans and intermediate hosts is called Hydatidosis and is characterized according to the morphologic features of the larval stages: cystic echinococcosis (CE) caused by *Echinococcus granulosus* and related organisms, alveolar echinococcosis (AE) caused by *Echinococcus multilocularis*, and polycystic echinococcosis (PE) caused by *Echinococcus vogeli* or *Echinococcus oligarthrus*.

This disease is becoming an important public health problem in many parts of the world where dogs are used for cattle breeding. Control measures are unable to be implemented everywhere, and where control programs were initiated the success of them have been incomplete generating a re-emergence of the disease. This has also led to the interruption of control measures excluding Echinococcosis from the list of notifiable diseases. As a consequence of this the incidence and prevalence of CE in Mediterranean countries in humans and animals are not known (Dakkak, 2010). Also, there are a number of factors that contribute to the increase of prevalence and to the spreading of CE in the Mediterranean Region. Cyprus is the only country where an eradication programme has been successfully implemented. However, CE has obtained important developments in the last decade, in the epidemiology, in the diagnosis of canine infection, in strain characterisation and in immune strategies against CE in animals. This scientific progress, together with effective health education programmes, will likely improve control programmes and reduce the time required to achieve significant decreases in prevalence or eradication. Thus, European authorities recognized, through the directive 2003/99/CE, Echinococcosis as a disease to be reported to the European Food Safety Authority (EFSA).

The "WHO/OIE Manual on Echinococcosis in Humans and Animals: a Public Health Problem of Global Concern", published in 2001, has been used as a fundamental issue for the redaction of this chapter.

### 2. Echinococcosis

The first part of this chapter is dedicated to explain the etiology to know the taxonomy and the life transmission cycles which perpetuate the agent in nature. The biology of the

causative agents of various forms of Echinococcosis is faced because it can help to understand the maintaining of these parasites in different geographic areas. Following to this part the epidemiology and clinical presentation forms are assessed. Finally, diagnosis, treatment and prevention are developed and emphasis is given to the identification of species and strains within the genus as an essential prerequisite to the establishment of local control programmes.

## 2.1 Etiology and life cycles

*Echinococcus* presents certain unique characteristics that set it apart from the other major genus in the family, *Taenia*. The adult form is only few millimetres long, has no gut and all metabolic interchange takes place across the syncytial outer covering, the tegument. Scolex is the anterior part of the *Echinococcus* becoming an attachment organ with four muscular suckers and two rows of hooks. The body is the strobila and is segmented in a different number of reproductive units called proglottids. The adult worm is hermaphrodite with reproductive ducts opening at a common, lateral, genital pore, the position of which may vary depending on species and strain. The uterus dilates after fertilisation, eventually occupying most of the terminal segment when the eggs are fully developed. The eggs are ovoid, consisting of a hexacanth embryo surrounded by several envelopes and are morphologically indistinguishable to those of other tapeworms of the genus *Taenia*. The metacestode is the second larval stage and consists of a bladder with an outer acellular laminated layer and an inner nucleated germinal layer. Protoscoleces arise from the inner wall of the brood capsules (figure 1). The structure and development of the metacestode differs between the four species of *Echinococcus*.

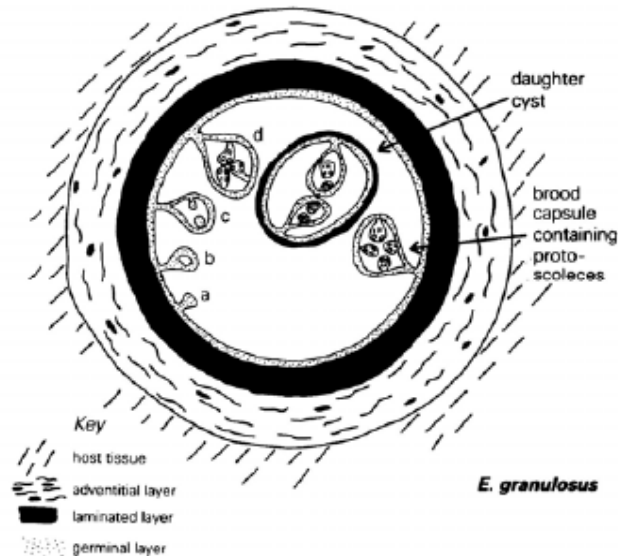


Fig. 1. Representation of the metacestode of *Echinococcus granulosus* (WHO/OIE publication: *Manual on echinococcosis in humans and animals*)

The life cycle of *Echinococcus spp.* requires two mammalian hosts for its completion. Gravid proglottids containing eggs or free eggs are passed in the faeces of the definitive host, a carnivore. These eggs are ingested by an intermediate host, in which the metacestode stage and protoscoleces develop. The cycle is completed if such an intermediate host is eaten by a suitable carnivore. Eggs are highly resistant to the environmental factors being infective for

months at lower ranges of temperatures (from +4°C to +15°C). However, they are very sensitive to desiccation and to high temperatures as 60-80°C.

Intermediate hosts are represented by a wide range of mammals which acquire the infection by the ingestion of eggs. The oncosphere is released from the keratinised embryophore in the stomach and small intestine. Bile activates the oncosphere which penetrates the wall due to the hook movements and secretions and arrives to the liver where some of them are retained (figure 2). All mammals (including man) in which metacestodes of *Echinococcus* species develop after infection with eggs may be referred to as 'intermediate hosts'. However, man is an aberrant host because metacestode stages do not become fertile in this host or because does not interact in the transmission cycle. Once the oncosphere has reached its final location, it develops into the metacestode stage. Time of development is variable and it may take several months before protoscoleces are produced (fertile metacestode). There may be several thousand protoscoleces within a single cyst of *E. granulosus* or an aggregation of vesicles of *E. multilocularis*. Each single protoscolex is capable of developing into a sexually mature adult worm. Not all metacestodes produce protoscoleces (sterile metacestode).

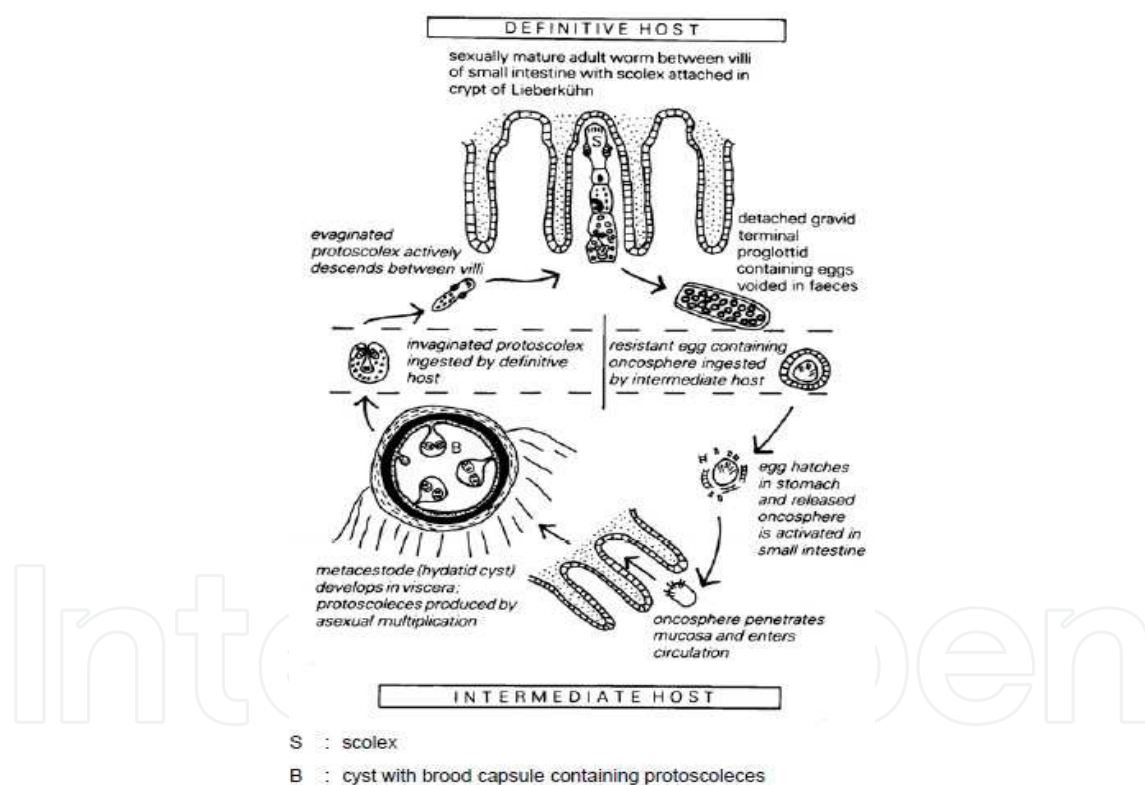


Fig. 2. Life-cycle of *Echinococcus* (WHO/OIE publication: Manual on echinococcosis in humans and animals)

Strain identification is possible for all four species of *Echinococcus* using morphological and biological features and/or molecular techniques, such as sequence comparison of a 366 bp-fragment of the mitochondrial cytochrome oxidase subunit 1 DNA (CO1) and a 471 bp-region in the mitochondrial NADH dehydrogenase gene 1 (ND1), by analysis of a ribosomal (r) DNA fragment (18S) or by the random amplified polymorphic DNA-PCR (RAPD-PCR). Recent genetic studies have principally confirmed the concept of strain diversity within the

species *E. granulosus*, previously based on morphological and biological features. Several molecular techniques are now available which would quite easily allow the identification of certain *E. granulosus* strains using genetic markers. To prepare the identification of the strain using molecular techniques protoscoleces are collected from *E. granulosus* cysts being washed several times in physiological saline solution and preserved in 70% ethanol. The material needs to be examined by an experienced laboratory. The rDNA ITS1 (internal transcribed spacer) region has been shown to be a potentially very useful genetic marker for distinguishing strains and species of *Echinococcus* and small quantities of *Echinococcus* material can be characterised using a PCR-RFLP 'fingerprinting' technique (Bowles & McManus, 1993). Other method is the single strand conformation polymorphism (SSCP) which is technically simple and has high resolution capacity under optimised conditions. The utility of SSCP has been demonstrated for the categorisation of different *Echinococcus* genotypes (Gasser et al., 1998). The different strains of *Echinococcus* have an epidemiological significance for the prognosis in infected patients. Epidemiological studies have evidenced that the sylvatic strain of *E. granulosus* in northern North America is causing a benign infection with low pathogenicity, and affecting the lungs. Also, these epidemiological observations have been demonstrated in the People's Republic of China. In contrast, in parts of Kenya and Libya, it has been suggested that there are local virulent strains of *E. granulosus* (Thompson, 1995). Isoenzyme and molecular studies have confirmed that sheep strain is infective to humans (Bowles & McManus, 1993). Developmental differences between species and strains of *Echinococcus* are likely to be a limiting factor in control programmes which employ regular adult cestocidal treatment of definitive hosts for breaking the cycle of transmission (Thompson, 1995).

## 2.2 Clinical forms of Echinococcosis

The metacestodes of all four recognised *Echinococcus* species can infect humans and cause various forms of echinococcosis (Table 1). Among these forms cystic and alveolar echinococcosis are of special medical importance.

Forms of Echinococcosis	Causative agent	Disease synonyms
Cystic Echinococcosis	<i>Echinococcus granulosus</i>	Hydatid disease, Hydatidosis, <i>E. granulosus</i> echinococcosis
Alveolar Echinococcosis	<i>Echinococcus multilocularis</i>	Alveolar hydatid disease, <i>E. multilocularis</i> echinococcosis
Polycystic Echinococcosis	<i>Echinococcus vogeli</i>	<i>E. vogeli</i> echinococcosis
Polycystic Echinococcosis	<i>Echinococcus oligarthrus</i>	<i>E. oligarthrus</i> echinococcosis

Table 1. Forms of Echinococcosis

Primary echinococcosis is established when metacestodes develop in various sites of the human body from oncospheres liberated from ingested eggs of *Echinococcus* spp. In CE liver and lung are the most frequently affected organs.

Secondary echinococcosis occurs when metacestode material spreads from primary site to adjacent or distant organs and proliferates. Regarding CE this form occurs after release of viable parasite material during invasive treatment procedures.

### 2.2.1 Cystic echinococcosis (CE)

The causative agent of CE is the metacestode of *Echinococcus granulosus*, becoming a cystic structure filled with a clear fluid. Most of the cysts grow slowly in size and become surrounded by host tissue (pericyst) encompassing the endocyst of metacestode origin. The endocyst consists of the outer laminated layer and the inner cellular germinal layer, which may form brood capsules and protoscoleces. The minimum time required for the development of protoscoleces in cysts in humans is not exactly known, but it is expected to be 10 months or longer after infection (Pawlowski, 1997). Fertile (with protoscoleces) and sterile (without protoscoleces) cysts may coexist in the same patient. Frequently, smaller daughter cysts are formed within a larger mother cyst. If these smaller cysts are growing in close proximity to each other forming clusters the appearance of “polycystic” needs to be distinguished from AE or PE.

The initial phase of primary infection is always asymptomatic remaining as this for many years or permanently. However, the infection may become symptomatic when cysts press adjacent tissues or induce other pathological events. When symptoms appear suddenly a spontaneous or traumatic cyst rupture has to be suspected. Spontaneous cure is possible but improbable, and is due to the collapse and resolution of cysts or due to the cyst rupture into the bile duct or the bronchial tree. The fatality rate is highly dependent on the severity of the infection and on facilities for treatment.

The age of the symptomatic infected patients can vary from below 1 year of age to over 75 years old. In a study from Madrid (Spain), over 1,473 patients admitted to a children’s hospital, 2% were <1 year old, 21% between 1 and 4 years and 77% between 5 and 14 years (Utrilla et al., 1991). Many patients (about 40% up to 80%) with CE have a single organ involved and harbour a solitary cyst.

#### 2.2.1.1 Clinical presentation of CE

Clinical symptoms of CE are variable and depend on the organ involved, the size of the cysts, the interaction between the expanding cysts and the adjacent organ structures, and the complications related to the cyst rupture and bacterial infection. CE involving the liver can remain asymptomatic for more than ten years (Frider et al., 1999). Liver and lungs are the two more frequent organ sites involved. Complications affecting the biliary tract are the most common and include the cystic rupture into bile ducts. Other complications are bacterial infection of the cyst, intraperitoneal rupture, and lung involvement.

#### 2.2.1.2 Diagnosis of CE

Diagnosis of CE is done through different steps as follows:

- a. Clinical suspect or screening
- b. Confirmation by imaging and identification of suspicious cyst structures
- c. Confirmation by detection of specific antibodies with immunodiagnostic tests
- d. If doubt diagnostic puncture may be considered
- e. Material obtained by biopsy puncture or surgery is examined.

Ultrasonography (US) is used for the diagnosis of the cystic structure and portable units are suitable to take into account in field situations. Immunodiagnostic tests for detecting specific antibodies are commonly used for the aetiological confirmation of the findings of imaging examinations.

Protoscoleces or hooks of *E. granulosus* are found in aspirated fluid samples. This technique is not performed frequently because the material can only be available after a surgical intervention, therapeutic puncture (PAIR) or diagnostic puncture. Direct diagnosis can also

be made by macroscopic identification of the *E. granulosus* obtained by surgery or biopsy. Other methods include the identification of specific *E. granulosus* antigen (antigen 5) in the fluid from sterile cysts or DNA markers in the cysts fluid or parasite tissue (e.g. by PCR).

Imaging techniques for diagnosis:

- Standard radiology: chest radiography detects uncomplicated cyst structures displaying a homogeneous shadow that indicates a fluid-filled space. Calcification in lung imaging is rare and cysts may be located anywhere as solitary or multiple. For differential diagnosis, cysts filled with clear fluid, with an air shadow or with water-lily sign are pathognomonic. If a rounded parenchymatous opacity is seen, it is necessary to consider tuberculoma, a tumour or pulmonary sequestration. A fluid and air shadow will lead to consideration of a bacterial, fungal or amoebic abscess.
- Ultrasonography (US): an expert committee of the WHO Working Group on echinococcosis presented an internationally agreed classification of US images in hepatic CE in 2001 (WHO, 2001), according to the use of PAIR (Puncture, Aspiration, Injection, Re-aspiration). This technique was proposed in 1986 by the Tunisian team that first used it in a prospective study. PAIR is a minimally invasive therapeutic option for percutaneous drainage of echinococcal cysts located in the abdomen, complementing or replacing surgery in most of the settings. PAIR also helps the use of benzimidazoles (albendazole and mebendazole) for the treatment of CE. The drainage is performed with a fine needle or a catheter, followed by the killing of the protoscolices remaining in the cyst cavity by a protoscolicide agent. If numerous and large daughter cysts are present, an alternative percutaneous technique "Percutaneous Puncture with Drainage and Curettage" (PPDC) may be used.

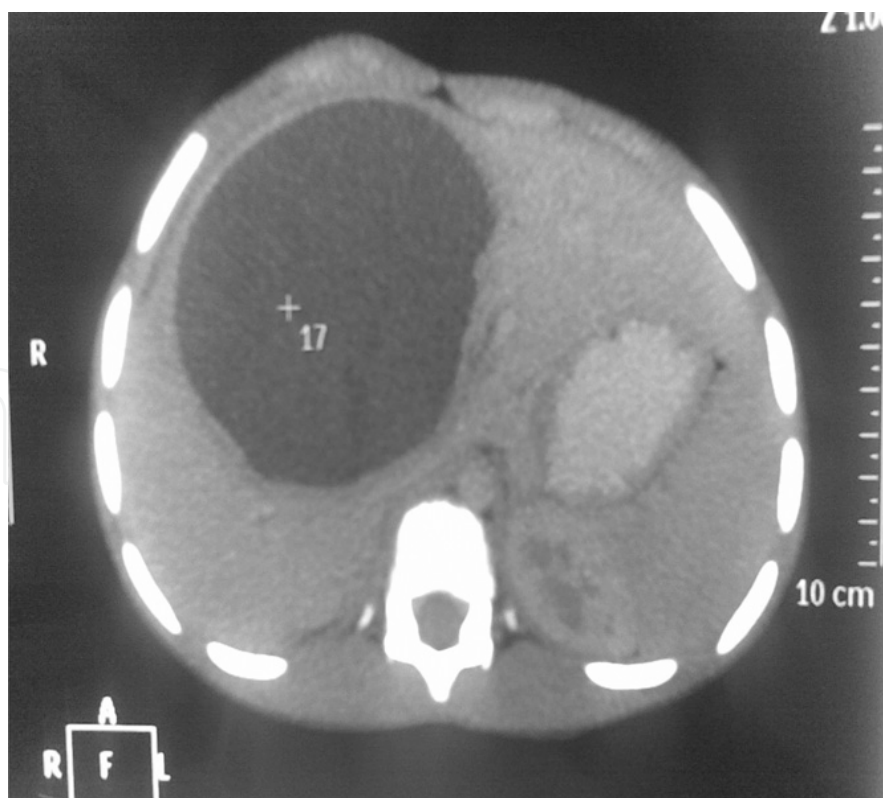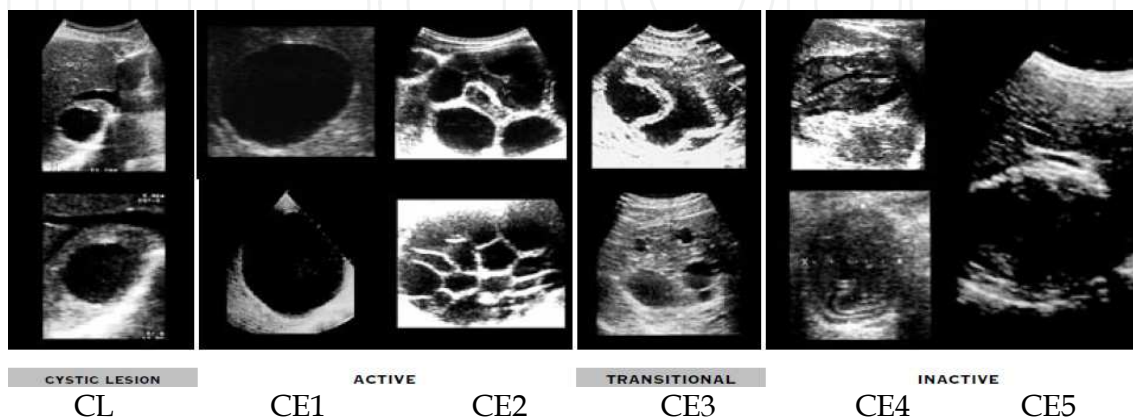


Fig. 3. Image from a computed tomography study of the abdomen of a patient (Soriano Arandes et al., 2010).

- Computed tomography (CT) can detect small cysts, and it also facilitates differential diagnosis of lesions caused by *Echinococcus* metacestodes from non-parasitic lesions (figure 3) (Soriano Arandes et al., 2010). CT is only indicated when US diagnosis is uncertain, mainly in cysts CE4 or CE5. However, CT is the principal method for diagnosis of cerebral cysts showing a spherical cyst with a thin wall, not enhanced after injection of contrast medium, without perilesional oedema the adjacent structures.

### 2.2.1.3 WHO classification of CE

The WHO classification of CE cysts (WHO, 2001) is done according to the US images:



**Cystic lesion (CL):** Unilocular, cystic lesion (s) (CL) with uniform anechoic content, not clearly delimited by a hyperechoic rim (= cyst wall not visible).

- Normally round but may be oval.
- Size: variable but usually small. CLs (< 5.0 cm), CLm (5 - 10 cm), CLl (> 10cm).
- Status: If CE - active. If these cystic lesions are caused by CE at an early stage of development then usually these cysts are not fertile.
- Ultrasound does not detect any pathognomonic signs.
- Differential diagnosis of these cystic lesions requires further diagnostic techniques.

**CE1:** Unilocular, simple cyst with uniform anechoic content. Cyst may exhibit fine echoes due to shifting of brood capsules which is often called hydatid sand ("snow flake sign") (figure 4).

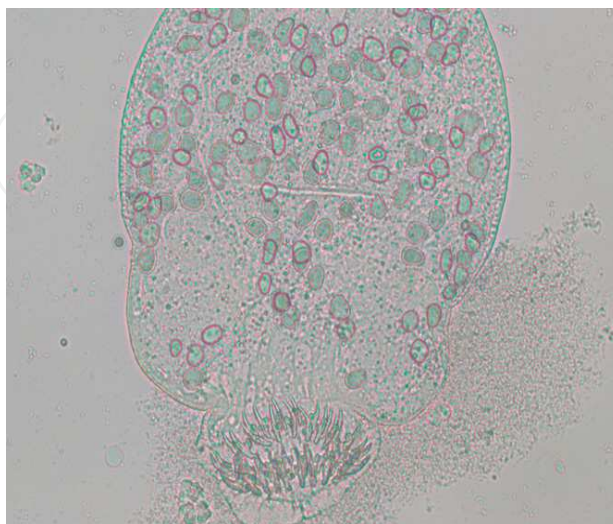

Fig. 4. Hydatid sand containing a protoscolex of *Echinococcus granulosus* seen by light microscopy (Soriano Arandes et al., 2010).



- Cyst wall is visible.
- Normally round or oval.
- Size variable: CE1s (< 5.0 cm), CE1m (5 - 10 cm), CE1l (> 10cm)
- Status: active.
- Usually fertile.
- Pathognomonic signs include visible cyst wall and snow flake sign.

**CE2:** Multivesicular, multiseptated cysts; cysts septations produce “wheel-like” structures, and presence of daughter cysts is indicated by “rosette-like” or “honeycomb-like” structures. Daughter cysts may partly or completely fill the unilocular mother cyst.

- Cyst wall normally visible.
- Normally round or oval.
- Size variable: CE2s (< 5.0 cm), CE2m (5 - 10 cm), CE2l (> 10cm).
- Status: active.
- Usually fertile.
- Ultrasound features are pathognomonic.

**CE3:** Unilocular cyst which may contain daughter cysts. Anechoic content with detachment of laminated membrane from the cyst wall is visible as floating membrane or as “water-lily sign” which is indicative of wavy membranes floating on top of remaining cyst fluid.

- Cyst form may be less rounded because of decrease of intra-cystic fluid pressure.
- Size variable: CE3s (< 5.0 cm), CE3m (5 - 10 cm), CE3l (> 10cm).
- Status: transitional.
- Transitional stage. Cyst which may degenerate further or may give rise to daughter cysts.
- Ultrasound features are pathognomonic.

**CE4:** Heterogenous hypoechoic or hyperechoic degenerative contents. No daughter cysts.

- May show a “ball of wool” sign which is indicative of degenerating membranes.
- Size variable: CE4s (< 5.0 cm), CE4m (5 - 10 cm), CE4l (> 10cm).
- Status: inactive.
- Most cysts of this type are not fertile.
- US features are not pathognomonic and further diagnostic tests are required to ascertain a diagnosis.

**CE5:** Cysts characterized by thick calcified wall that is arch shaped, producing a cone shaped shadow.

- Degree of calcification varies from partial to complete.
- Size variable: CE5s (< 5.0 cm), CE5m (5 - 10 cm), CE5l (> 10cm).
- Status: inactive.
- Cyst not fertile in most cases.
- Diagnosis is uncertain. Features are not pathognomonic but highly suggestive for *E. granulosus*.

#### 2.2.1.4 Laboratory findings of CE

Routine laboratory tests show non-specific results. Patients with rupture of a cyst into the biliary tree can show transient elevations of GGT or alkaline phosphatase concentrations, often associated with hyperamylasaemia and eosinophilia (>500/ $\mu$ l). When cyst is ruptured eosinophilia achieves higher concentrations.

### 2.2.1.5 Immunodiagnosis of CE

Immunodiagnosis procedures for serum antibody detection are used for the aetiological confirmation of imaging structures suggestive for CE. Certain proportion of patients with echinococcosis is unable to be diagnosed with highly sensitive diagnostic tests such as IgG-ELISA and false-negative results are obtained. Cysts in the brain or eye and calcified cysts often induce low or no antibody titres. Antibody response may also be low in certain human population groups and in young children. False positive results may also occur, especially in patients with other helminthic diseases. Approaches to the diagnosis of CE using immune methods are specified in table 2.

<b>First step: Primary antibody test</b>		
Test for serum antibody detection: IgG-ELISA or IgE-ELISA with <i>E. Granulosus</i> antigen		
A combination of two or more primary tests may increase sensitivity		
<b>Subsequent steps</b>		
<b>Seronegative samples</b>	<b>Seronegative samples</b>	<b>Seropositive samples</b>
+	+	+
<b>No suggestive images for CE</b>	<b>Suggestive images for CE</b>	<b>With or without suggestive images for CE</b>
	<b>Asymptomatic cases</b> Extended and/or advanced imaging and repeated serological examinations, including differential diagnosis for AE*	<b>Asymptomatic and symptomatic cases</b> Secondary antibody test: Arc 5 test IgG4-ELISA Immunoblot for antibodies reactive with subunits of <i>E. granulosus</i> antigens Serological differential diagnosis for AE (ELISA-Em2plus, immunoblot)
No further serological follow-up or further steps for differential diagnosis	‘Wait and observe’ approach with repeated serological examinations	
	<b>Symptomatic cases</b> Consideration of cyst puncture Consideration of surgical intervention and/or chemotherapy without further serological examinations	

Table 2. Approaches for immunodiagnosis of CE

IgG-ELISA is the preferable test used as a primary test for detecting anti-*Echinococcus* serum antibodies. Most of the routine laboratory test systems or commercialized test kits are based on crude or semi-purified preparations of *E. granulosus* antigens. The use of the two major hydatid cyst fluid antigens, antigen 5 (thermolabile) and antigen B (thermostable), is predominantly restricted to scientific applications, and these antigens are not generally

available. Secondary tests for antibody detection are used to increase specificity and these are: arc 5, identification of IgG subclasses, and immunoblotting which demonstrates the reactivity of serum antibodies with subunits of *E. granulosus* antigens (Craig, 1997; Di Felice, 1986; Ioppolo, 1996; Leggatt & McManus, 1994; Leggatt, 1992; Ligthowlers & Gottstein, 1995; Profumo, 1994; Sheperd & McManus, 1987; Siracusano & Vuitton, 1997; Wen & Craig, 1994). Generally, these tests are less sensitive, but more specific than primary test systems. Putative hydatid cyst fluid samples obtained by puncture or after surgical intervention can be tested for the presence or absence of *Echinococcus* antigen through binding of enzyme-labelled anti-*Echinococcus* (hydatid cyst fluid) antibodies in an ELISA with a monoclonal antibody against antigen 5 (Ag5) that may be useful in confirmation of the *Echinococcus* nature of the fluid (Paul & Stefaniak, 1997).

#### 2.2.1.6 Treatment of CE

Surgery is still the treatment that has the potential to remove *E. granulosus* cysts and lead to complete cure (WHO, 1996). Up to 90% of the patients can be treated surgically if a cyst does not have a risky localisation or if the disease is not too far advanced. However, surgery may be impractical in patients with multiple cysts localised in several organs and if surgical facilities are inadequate. Chemotherapy and PAIR offer an attractive option for treatment, especially in inoperable patients and for cases with a high surgical risk.

##### 2.2.1.6.1 Surgery

Surgery is indicated for large liver cysts with multiple daughter cysts; single liver cysts, situated superficially that may rupture spontaneously or as a result of trauma; cysts that are infected; cysts communicating with biliary tree and/or exerting pressure on adjacent vital organs; cysts in the lung, brain and kidney, bones and other organs.

Surgery of CE is contraindicated as defined for surgical procedures in general, i.e. patients refusing surgery, patients at the extremes of age, pregnant women, and patients with concomitant severe diseases (i.e. cardiac, renal or hepatic diseases, diabetes and hypertension). Also, surgery is contraindicated in patients with multiple cysts or cysts difficult to access, dead cysts either partly or totally calcified, and in patients with very small cysts.

The protoscolicides apparently effective are: 70-95% ethanol, 15-20% hypertonic saline solution, and 0.5% cetrimide solution. These substances should be left in the cyst cavity for at least 15 minutes to obtain an optimal efficacy.

The risks of surgical intervention include secondary echinococcosis owing to spillage of viable parasite material during the intervention. Recurrence can be due to incomplete cyst removal or to previously undetected cysts. Anaphylactic reactions represent a further risk on rare occasions. Postoperative fatality is about 2% or less, but may be higher in the second or further operations or if medical facilities are inadequate.

##### 2.2.1.6.2 Puncture, aspiration, injection, re-aspiration (PAIR)

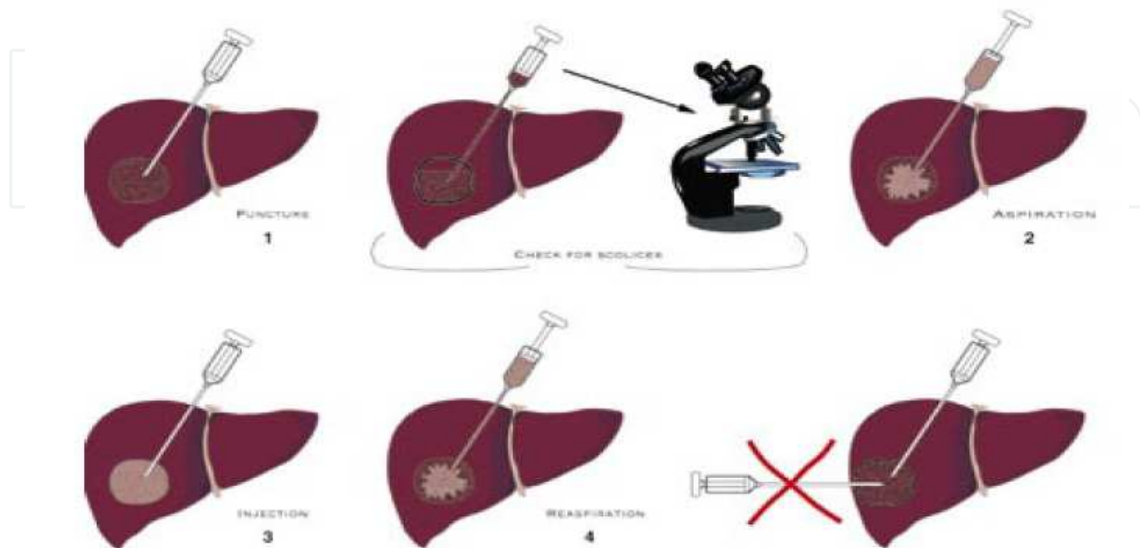
This technique includes the following steps (WHO, 2001):

- percutaneous puncture of cysts under ultrasonic guidance
- aspiration of a substantial amount of cyst fluid
- injection of protoscolicidal substance (preferably 95% ethanol)
- re-aspiration of the fluid cyst content after 15 min to 20 min.

PAIR should be accompanied by a chemotherapeutic coverage to minimise risks of secondary echinococcosis and should be reserved for use by skilled and well experienced physicians with a surgical and intensive care back-up team well prepared to deal

immediately with complications. Aspirates of liver cysts must be analysed immediately for traces of bilirubin and protoscolecemes or hooks. PAIR should only be performed under chemotherapeutic coverage, except in early pregnant patients (Filice & Brunetti, 1997).

The PAIR sequence is (WHO, 2001):



There are some critical points to take into account when proceeding with the PAIR protocol:

- Prophylaxis pre- and post-procedure: albendazole is administered 24 to 4 hours before intervention and 15 days to 30 days after intervention according to the cystic size. No treatment for pregnant women.
- Communication with biliary tree: the minimum requirements are to search for bile in the fluid with fast test.
- Scolicidal agent to be used: hypertonic saline (at least 15% final concentration in cyst) or 95% alcohol.
- Quantity of scolicide injected: at least 1/3 of the aspirated quantity.
- Evaluation of viability: microscopic examination.
- Needle vs. catheter: needle for cysts <5 cm. or in multiloculated cysts. Catheter for cysts >5 cm. (PAIRD)
- Follow-up: every week for the 1<sup>st</sup> month, then every month for the 1<sup>st</sup> year, the every year for 10 years.

Indications for PAIR: we use this technique for patients with:

- Non-echoic lesion  $\geq 5$  cm in diameter (CE1m and I)
- Cysts with daughter cysts (CE2), and/or with detachment of membranes (CE3)
- Multiple cysts if accessible to puncture
- Infected cysts
- Also for pregnant women, children >3 years old, patients who fail to respond to chemotherapy alone, patients in whom surgery is contraindicated, patient who refuse surgery, and patients who relapse after surgery.

Contraindications for PAIR:

- Non-cooperative patients and inaccessible or risky location of the cyst in the liver
- Cyst in spine, brain and/or heart
- Inactive or calcified lesion

- Cysts communicating with the biliary tree
- Cysts open into the abdominal cavity, bronchi and urinary tract.

#### 2.2.1.6.3 Chemotherapy

The documentation of the experience about chemotherapy with benzimidazoles in CE is now extensive. Third part of the patients treated with benzimidazoles is achieving the cure with a complete and definitive disappearing of the cysts, and higher proportion (30-50%) has obtained a considerable reduction of the cyst size and also relieve of their symptoms. However, 20-40% of the cases don't respond as expected. Smaller and isolated cysts (less than 7mm.), surrounded by a minimal adventitial membrane respond better than complicated with multiple separations or with son cysts, or surrounded by a thick or calcified adventitial membrane which are refractory to the treatment. There are two main drugs for chemotherapy: albendazole (10-15 mg/kg/day twice per day; 3- to more than 6 monthly courses with free intervals of 14 days) for treating patients with single or multiple cysts (Gemmell & Roberts, 1995), and mebendazole (40-50 mg/kg/day; everyday in three doses per day during 3-6 months). Albendazole continuous courses have shown equal or improved efficacy for 3 to 6 months or longer without an increase of adverse effects (Franchi et al., 1999). When comparing both drugs, albendazole and mebendazole, some researchers concluded that albendazole was better regarding complete cure rates and relieve of the symptoms (Franchi et al., 1999). Albendazole has a better pharmacokinetic profile than mebendazole facilitating higher intestinal absorption and penetration into the cysts. There are described some adverse reactions (neutropenia, hepatic toxicity, alopecia, and others) in a few number of patients which are reversible when treatment is interrupted. Doses, duration, and follow-up of treatment must be taken individually for each patient. However, it seems that minimum duration has to be for three months. It is difficult to predict the long-term prognosis for every patient; therefore it's necessary to do a long-term follow-up, with US or other imaging methods to be able to evaluate the result of the treatment.

Chemotherapy is also useful as a surgical complement and albendazole has been used as a pre-surgical treatment to facilitate the surgical manipulation of the cysts inactivating the protoscolices previously, modifying the integrity of the cyst membranes and reducing the consistency of the cysts. Treatment with benzimidazoles is recommended to prevent the relapse of the disease, which is the secondary echinococcosis when the content of the cysts is spread after its spontaneous or accidental rupture. When it occur the best option is to treat with three cycles of albendazole or the continuous administration of mebendazole during 1-3 months.

Praziquantel at doses of 40 mg/kg is a potent protoscolicide and could be used as a preventive drug after the cyst content spillage when the rupture of the cyst or as a protoscolicide when PAIR is applied.

Other drugs as nitazoxamide (at doses of 500mg/12h for 3-24 months) has been evaluated in the effectiveness in disseminated cystic echinococcosis (DCE) that failed to respond to surgical and antiparasitic therapy. Three patients improved: one with muscle involvement (clinico-radiological response), one with lung involvement (radiological response), and another with soft tissue and bony involvement (clinico-radiological response of soft tissue cysts) (Pérez-Molina et al., 2011).

Benzimidazoles are contraindicated in pregnancy because they are teratogenic.

Monitoring of the patients is needed and medical and laboratory examinations for adverse reactions are necessary initially every 2 weeks then monthly (WHO, 1996). Leukocyte counts

should be checked at 2-week intervals during the first 3 months because in rare instances severe and not always reversible leukopaenia has been observed in early phases of chemotherapy. Serum drug concentrations (ABZ-sulfoxide or MBZ parent compound) should be monitored after 2 and 4 weeks of chemotherapy, respectively, in order to identify levels too high (possibly toxic) or too low (ineffective). For MBZ, it has been recommended to determine serum or plasma levels 4 h after the morning dose. Oral drug doses can be adapted to individual patients in order to achieve adequate serum levels, but such attempts are not always effective. Unfortunately, only few laboratories have the capability to measure ABZ-sulfoxide or MBZ serum drug levels (see also section on AE). Follow-up examinations, including imaging if needed, should be carried out at intervals of about 3 to 6 months for 1 to 3 years after termination of chemotherapy because of the relatively high rate of relapses.

#### 2.2.1.6.4 Vaccines

A new vaccine against echinococcosis would be highly desirable in order to provide long-term prevention of the disease and to complement control programs. Vaccines against ovine hydatidosis have demonstrated its efficacy when targeting the larval stage of the parasite (Lightowers, 2001). However, if used in the field we would need to vaccinate all the animals in a herd to achieve good results and this would be very costly to control programs. Otherwise, a vaccine protecting dogs against the adult worm would have to be given to only a few animals to protect the environment, because dogs are less numerous than other animals in the herd. Also, domestic dogs are the key in the transmission to livestock and humans. Therefore, some authors have proposed a recombinant oral vaccine given to the small number of dogs keeping the herd would decrease the number of *E. granulosus* adult worms and, consequently, the number of infective eggs. This measure would help reduce the contamination risk factors for humans and livestock, would be cost-effective for the owners of the dogs, and could help increase the overall efficacy of control programs in endemic countries (Petavy, 2008).

Some candidates have been used to induce immune response with vaccination. One of those is Eg-95 encoding gene that is expressed in the oncosphere, protoscoleces, and immature and mature adult worms of *E. granulosus*. EG95 vaccine antigen is a secreted glycosylphosphatidylinositol (GPI)-anchored protein containing a fibronectin type III domain, which is ubiquitous in modular proteins involved in cell adhesion. EG95 protein represents one of the targets of immunity induced by the vaccine because there is a high degree of sequence gene conservation between different isolates (Zhang, 2003). A mixture of different EG95 isoforms increases the ability of *E. granulosus* to invade different hosts and could possibly maximize vaccine efficacy (Haag, 2009). Other candidates for vaccine are the homologous sequences of two of the S3Pvac peptides, GK1 and KETc1, identified and further characterized in *Taenia crassiceps* WFU, *Taenia solium*, *Taenia saginata*, *E. granulosus* and *E. multilocularis*. Comparisons of the nucleotide and amino acid sequences coding for KETc1 and GK1 revealed significant homologies in these species and the results of a study indicate that GK1 and KETc1 may be considered candidates to be included in the formulation of a multivalent and multistage vaccine against these cestodiasis because of their enhancing effects on other available vaccine candidates (Rassy, 2010).

### 2.2.2 Alveolar echinococcosis (AE)

Alveolar echinococcosis (AE) is an infection caused by the metacestode stage of *E. multilocularis*, which is characterised by a tumour-like, infiltrative and destructive growth

with the potential to induce serious disease with a high fatality rate. Metacestodes develop primarily almost exclusively in the liver varying from small foci of a few millimetres in size to large areas of infiltration (15-20 cm.). From the liver, the metacestode tends to spread to both the adjacent and distant organs by infiltration or metastasis formation (Eckert, 1998). Cases of AE are characterized by an initial asymptomatic incubation period of 5-15 years duration and a subsequent chronic course. Fatality rate in untreated or inadequately treated persons is high.

High burden of AE is known to be common in certain rural communities in China whilst it is generally rare and sporadic elsewhere. Recently, a study was carried out to estimate the global incidence of this disease by country (Torgerson, 2010). They undertook a detailed review of published literature and data from other sources suggesting that there are approximately 18,235 (CI 11,900–28,200) new cases of AE per annum globally with 16,629 (91%) occurring in China and 1,606 outside China. Most of these cases are in regions where there is little treatment available and therefore will be fatal cases. They were able to calculate that AE results in a median of 666,434 DALYs per annum (CI 331,000-1.3 million).

### 2.2.2.1 Clinical presentation of AE

Age at the time of diagnosis of AE is significantly higher than for CE. The primary site of metacestode development is almost exclusively in the liver. The right lobe is predominantly infected, but the liver hilus together with one or two lobes may also be involved. Extra hepatic primarily locations are rare. During the infection, secondary echinococcosis may occur in variety of adjacent or distant organs. Symptoms of AE are primarily cholestatic jaundice (1/3 of cases) and/or epigastric pain (1/3 of the cases). In the remaining third of patients, AE is detected incidentally during medical examination for symptoms such as fatigue, weight loss, hepatomegaly, or abnormal routine laboratory findings.

### 2.2.2.2 Classification and staging of AE

#### PNM system for classification of human alveolar echinococcosis

##### Classification of findings

##### **P: Hepatic localisation of the parasite**

PX: Primary lesion cannot be assessed

P0: No detectable lesion in the liver

P1: Peripheral lesions without proximal vascular and/or biliar involvement

P2: Central lesions with proximal vascular and/or biliar involvement of one lobe (a)

P3: Central lesions with hilar vascular and biliar involvement of both lobes and/or with involvement of two hepatic veins

P4: Any liver lesion with extension along the vessels (b) and the biliary tree

##### **N: Extrahepatic involvement of neighbouring organs**

Diaphragm, lung, pleura, pericardium, heart, gastric and duodenal wall, adrenal glands, peritoneum, retroperitoneum, parietal wall (muscles, skin, bone), pancreas, regional lymph nodes, liver ligaments, kidney

NX: Not evaluable

N0: No regional involvement (see above)

N1: Regional involvement of contiguous organs or tissues

##### **M: Absence or presence of distant metastases**

Lung, distant lymph nodes, spleen, CNS, orbital, bone, skin, muscle, distant peritoneum and retroperitoneum]

MX: Not completely evaluated

M0: No metastasis(c)

M1: Metastasis

- a. For classification, the plane projecting between the bed of the gallbladder and the inferior vena cava divides the liver in two lobes
- b. Vessels means inferior vena cava, portal vein and arteries
- c. Chest X-ray and cerebral CT negative

Source: European Network for Concerted Surveillance of AE: PNM system for the classification of human cases of AE.

<b>Staging of alveolar echinococcosis cases based on PNM classification</b>	
<b>Stage of alveolar echinococcosis</b>	<b>PNM classification</b>
Stage I	P1 N0 M0
Stage II	P2 N0 M0
Stage IIIa	P3 N0 M0
Stage IIIb	P1-3 N1 M0
	P4 N0 M0
Stage IV	P4 N1 M0
	Any P Any N M1

Source: European Network for Concerted Surveillance of Alveolar Echinococcosis: PNM system for the classification of human cases of alveolar echinococcosis.

### 2.2.2.3 Diagnosis of AE

Diagnosis of AE is based on similar findings and criteria as in CE.

Hepatic lesions are characterised in US and CT by heterogenous hypodense masses, often associated with necrotic cavities. The lesion contours are irregular and there is lack of a welldefined wall. Calcifications are often found and exhibit a typical pattern in regard to shape and distribution: clusters of microcalcifications or irregular plaque-like calcified foci are located in the central or peripheral parts of the lesions. Discrepancies between US and CT patterns can be found. Hyperechoic haemangioma-like nodules could represent early forms of AE lesions. Quite frequently an extension of the lesions beyond the liver is found toward diaphragm, lungs, pericardium, retroperitoneum, hepatoduodenal ligament and pancreas.

Magnetic resonance imaging is used to observe compression or obstruction of inferior vena cava, the hepatic veins or the portal branches. Pathognomonic aspects are represented by multicystic honeycomb-like images.

### 2.2.2.4 Laboratory findings of AE

The routine laboratory tests do not yield specific findings. The blood sedimentation rate is elevated in most of the cases. The numbers of leucocytes and platelets may be depressed in patients with splenomegaly. Lymphopaenia is frequent in advanced cases, and eosinophilia is usually absent. Cholestasis with or without jaundice is observed in patients with intrahepatic bile duct compression or obstruction. Cholangitis and/or liver abscesses, which usually result from bile duct obstruction, are associated with typical alterations of the laboratory parameters. Hypergammaglobulinaemia is present in most of the patients and reflects the specific and polyclonal antibody response. In about one-half of the patients, the presence of specific anti-*E. multilocularis* - IgE can be demonstrated.



### 2.2.2.5 Immunodiagnosis of AE (table 3)

<b>First step: Primary antibody test</b>		
Tests with high sensitivity and less specific value		
<b>Subsequent steps</b>		
<b>Seronegative samples +</b>	<b>Seronegative samples +</b>	<b>Seropositive samples +</b>
<b>No suggestive images for AE</b>	<b>Suggestive images for AE</b>	<b>With or without suggestive images for AE</b>
<p>No further serological follow-up. Persons with suspected infection risk may require repeated serological examinations after 3-6 months, and US imaging.</p>	<p><b>Asymptomatic cases</b> Extended and/or advanced imaging and repeated serological examinations. Fine needle biopsy for PCR or immunohistology may be considered in rare cases. If lesions are fully calcified, serological and imaging follow-up after 6 months to confirm parasite abortion.</p> <p><b>Symptomatic cases</b> Consideration of surgical intervention and/or chemotherapy without further serological examinations</p>	<p><b>Asymptomatic and symptomatic cases</b> Secondary antibody test: Em2Plus-ELISA (Gottstein et al., 1993) Em alkaline phosphatase-antigen-ELISA (Sarciron et al., 1997) Immunoblot for specific bands or similar test Serological differential diagnosis for CE</p>

Table 3. Approaches for immunodiagnosis of AE

### 2.2.2.6 Pathological and histological examination of AE

Metacestode of *E. multilocularis* typically exhibits an alveolar structure composed of numerous irregular cysts with diameters between less than 1 mm and 30 mm. when is examined in a macroscopic section of the liver. Due to necrosis of the lesion, cavities filled with liquid and necrotic material may be formed in the central parts of the parasite (Eckert, 1998). Microscopically, the cysts consist of a relatively thin PAS-positive laminated layer and a delicate germinal layer often with only a few nuclei. Brood capsules and protoscoleces are rarely formed in the human host (Eckert, 1998). The cysts are surrounded by an inner zone of necrotic tissue and outer layers of histiocytes and lymphocytes. In later phases, tissue reactions of chronic inflammation, often with giant cell foreign body reaction, fibrous tissue and calcifications are seen around cysts.

### 2.2.2.7 Treatment of AE

There are a variety of options to select the adequate treatment for each individual patient. Clinical experience is crucial for AE; therefore patients should be referred to a recognised national or regional reference centre. Early diagnosis of AE is of special importance for successful treatment because the lesion is acting as a malignant tumour. Screening programmes in Japan and Europe have shown that early diagnosis reduces mortality and morbidity due to AE. Some considerations for treatment of AE are generally accepted: the first choice treatment in all operable cases is radical surgical resection of the entire parasitic lesion from the liver and other affected organs, chemotherapy is indicated after radical surgery for a limited period of time, and long-term chemotherapy is mandatory after incomplete resection of the lesions, in inoperable patients and in AE patients after liver transplantation.

Chemotherapy has several indications, as follows:

- Applicable for limited period of time after radical surgery. Since residual parasite tissue may remain undetected at radical surgery, post-operative chemotherapy for at least 2 years should be carried out and patients should be monitored for a minimum of 10 years for possible recurrence
- Long-term chemotherapy for several years is mandatory in inoperable AE patients, in cases following incomplete surgical resection of the parasite lesions and after liver transplantation
- Pre-surgical chemotherapy is not indicated in cases of AE. However, in rare cases that surgery was contraindicated at the time of diagnosis of AE, surgery can be carried out after a prolonged course of chemotherapy.

Benzimidazoles are preferentially used for AE:

Mebendazole (MBZ) is given as 500-mg tablets in daily doses of 40-50 mg/kg bw in three divided doses postprandially. After an initial continuous treatment of 4 weeks, it is advisable to adjust the oral doses in order to obtain plasma drug levels of >250 nmol/l (= 74 ng/ml). The duration of treatment is at least 2 years after radical surgery or continuously for many years in inoperable cases, as well as for patients who have undergone incomplete resection or liver transplantation.

Albendazole (ABZ) is given as 400-mg tablet or as a 4% suspension at daily doses of 10 -15 mg/kg bw (in two divided doses). In practice, a daily dose of 800 mg is given to adults, divided into two doses of 400 mg. Repeated cycles of 28 days treatment should be followed by a 'wash out' phase without chemotherapy of 14 days. However, data from the People's Republic of China (Liu, 1997) and Italy indicate that a continuous ABZ treatment of AE is at least equally or more effective and well tolerated. The duration of necessary chemotherapy has not yet been determined but might well be life-long for most of the patients without complete resection of the AE lesions.

Adverse effects of the chemotherapy with benzimidazoles are neutropaenia, alopecia and liver dysfunction. They are contraindicated in pregnancy due to its potential embryotoxicity and teratogenicity. Monitoring of the AE patients is similar to that in CE patients. A long-term follow-up of more than 10 years is recommended.

Interventional procedures are indicated for AE patients for whom surgery is contraindicated. Some of them are dilation and stent implantation in vessels or bile ducts, and endoscopic sclerosing of oesophageal varices.

Liver transplantation should only be considered in patients with very severe hilar extension, leading to uncontrolled biliary infections, symptomatic secondary biliary cirrhosis with ascites or severe variceal bleeding owing to portal hypertension (Bresson-Hadni, 1997). It requires long-term and continuous postoperative chemotherapy.

### 2.2.3 Polycystic echinococcosis (PE)

Forms of human polycystic echinococcosis (PE) are caused by *E. vogeli* and *E. oligarthrus*, which are confined in their distribution to Latin American countries.

Metacestode of *E. vogeli* is characterized by its polycystic form filled with liquid with a tendency to form conglomerates with multiples small spaces inside. The most affected organ in the intermediate host is the liver. Metacestode of *E. oligarthrus* is similar to *E. vogeli* but the division in secondary spaces is less frequent and the laminar membrane is significantly thinner.

Wild and domestic dogs as definitive hosts and paca (*Cuniculus paca*) as intermediate host participate in the life-cycle of *E. vogeli*. Polycystic echinococcosis due to *E. vogeli* has been communicated in the majority of the countries belonging to the neotropical region of America; including Panama, Colombia, Argentina, Ecuador, Brasil, Bolivia and Venezuela.

*E. oligarthrus* is the unique *Echinococcus* specie that uses felids as definitive hosts. Infections naturally acquired have been demonstrated affecting pumas, jaguars, and other wild felids.

#### 2.2.3.1 Polycystic echinococcosis due to *E. vogeli*

Clinical and radiological presentation is very similar to infection with multiple cysts of *E. granulosus*, and differential diagnosis depends on isolation of protoscolexes and morphological hook characteristics (D'Alessandro, 1997). Immunodiagnosis using a purified antigen of *E. vogeli* allowed discrimination between cases of PE and CE, but differentiation between PE and AE was not always possible (Gottstein, 1995). Albendazole with doses of 10 mg/kg/day has been used for chemotherapy in six cases with success of treatment in four and improvement in two (D'Alessandro, 1997).

#### 2.2.3.2 Polycystic echinococcosis due to *E. oligarthrus*

Only three human cases have been reported to date, two orbital in Venezuela and Surinam and one cardiac in Brazil with 2 cysts (1.5 cm diameter) (D'Alessandro, 1997). The diagnosis was based on morphology of protoscolex hooks.

## 3. Conclusion

Human echinococcosis is a zoonotic larval cestode disease usually caused by *Echinococcus granulosus* or *E. multilocularis*. Infection is chronic taking years for symptoms to develop. The medical impact of the late stages of human cystic or alveolar echinococcosis may be significant though morbidity and mortality are usually grossly under-reported in endemic areas. Because of diagnosis and treatment are difficult and reservoirs of infection are maintained in domestic livestock, dogs or wildlife, the disease is difficult to assess in terms of public health and requires long-term control interventions. Globally, 3.6 million disability-adjusted life-years (DALYs) could be lost due to echinococcosis, and this disease is included in an important group of neglected non vector-borne zoonotic infections that are currently not sufficiently prioritised (WHO/DFID-AHP, 2006).

Echinococcosis is therefore a neglected disease which is under-reported and requires urgent attention in common with a number of other zoonoses in order to reduce morbidity and to help alleviate poverty in poor pastoral areas of the sub-tropics and temperate zones. It's also difficult to formulate interventions and to apply cost-effective control programmes in this disease.

Human behaviour is crucial in facilitating transmission of this infection between domestic animal hosts as a result of traditional pastoral and husbandry practices (Mcpherson, 2005; Craig, 2007). Dogs are also susceptible to infection with *E. multilocularis* and *E. vogeli* (whose intermediate hosts are principally rodents) and therefore dogs may constitute a greater zoonotic reservoir of infection compared to natural wild canid hosts. Peri-domestic transmission may occur and could for example sustain a level of transmission of *E. multilocularis* in highly endemic communities (Li, 2005), but is probably not responsible for long-term maintenance of these Echinococcus species adapted to small mammals. Therefore, echinococcosis is a disease where humans may acquire infection from wild or domestic animal hosts but the parasite cannot be directly transmitted between humans (Wolfe, 2007), and due to all of these concepts treatment of human echinococcosis cases will have no effect on pathogen transmission. We will need to apply interventions to reduce human exposure or break transmission cycles in order to control the disease. This places echinococcosis in a 'difficult-to-deal-with' category; firstly, unlike the other neglected parasitic diseases humans can not act as a definitive host, and secondly, echinococcosis in livestock (or dogs) is not perceived as an animal health problem.

Clinical symptoms and subsequent diagnosis occur in adults (20-60 years) but infections in children may also become symptomatic (Soriano Arandes et al., 2010), and imaging techniques are the basis for diagnosis preferably accompanied by a specific serological test (Craig et al., 2003). Surgical removal of cysts/cystic masses, cyst drainage or organ resection, are the main form of treatment, often supported by high dose albendazole cover; the latter also has a benefit in medically-only treated cases (WHO, 2001).

The key factors of echinococcosis as a neglected disease are best described in a recent paper (Craig et al., 2007):

- Human echinococcosis is a zoonosis, non vector-borne zoonosis, that is not transmitted between humans. Therefore, it's a disease that is not amenable to vector-based control nor to direct human-treatment-approaches for case prevention.
- Human CE and AE are chronic diseases with very long asymptomatic periods so that endemic communities and health authorities fail to properly recognise the negative health impacts. Prevalence values represent infection events some years previously. CE remains an important health problem in many regions of the world, both where no control measures have been implemented, and where control programs have been incompletely successful with ensuing re-emergence of the disease. In Spain, official data on CE show an increase in the proportion of intermediate hosts with CE during the last few years, and autochthonous pediatric patients have been reported, a sign of active local transmission of disease. However, several crucial aspects related to CE that would help better understand and control the disease have not been tackled appropriately, in particular the emergence of infection in specific geographical areas. The introduction of national registries for CE with online data entry, following the example set by the European Registry for Alveolar Echinococcosis, would help streamline data collection on CE by eliminating the need for evaluating and

integrating data from multiple regions, by avoiding duplication of data from patients who access several different health facilities over time, and by providing much needed clinical and epidemiological data that are currently accessible only to clinicians (Rojo-Vazquez et al., 2011).

- Echinococcosis is difficult to detect or diagnose in humans without access to imaging tools (eg. ultrasound, CT scan), furthermore the basis for confirmatory laboratory diagnosis is usually expensive serological tests.
- Treatment is very difficult and not always very effective, relying largely on costly major surgical or percutaneous hospital-based interventions to remove or sterilise cystic lesions. Furthermore, anthelmintic therapy is not as highly effective as for other helminthic diseases (eg. gastro-intestinal helminthiasis, schistosomiasis or onchocerciasis), and is based on long-term high dose albendazole usually requiring a minimum 6 months daily course, for which follow-up is very difficult especially in poor-resource areas. In this regard echinococcosis treatment more closely resembles tumour treatments or TB therapy, than that for a parasitic disease.
- Medical records are usually not very explicit/specific, may involve complex follow-up notes, and may be dispersed across several specialities within/between hospitals/clinics and therefore data is not usually properly collated.
- In under-developed regions, human echinococcosis generally occurs in poor, often remote marginalised pastoral societies that may be ethnically/socio-culturally isolated from the general population. Consequently they are not usually very well prioritised by the predominant agricultural-based community district health authorities, and so access to affordable health care is also poor and/or difficult.
- The burden of echinococcosis disease is therefore difficult to quantify, and official hospital or district records often inaccurate, and in any case represent gross underestimates of the real burden in an endemic area.
- CE is a chronic, asymptomatic infection in domestic animals and is therefore also not recognised by livestock owners as an animal health or economic problem.
- Dogs are the main carrier and spreader of the parasite, but are asymptomatic. In contrast to livestock numbers, official accurate estimates of dog population sizes (owned and stray) are almost never kept/known by municipal, veterinary or agricultural authorities. Canine echinococcosis is treatable with the anthelmintic praziquantel but requires frequent dosing. Unlike for rabies, there is currently no dog vaccine against canine echinococcosis.
- Control of echinococcosis is difficult and exacerbated by the requirement of cooperation between agricultural/veterinary services and medical authorities.

#### 4. Acknowledgment

To my family, and especially to my wife Marta and my sons Marc and Toni for their support everywhere and every moment of my life.

#### 5. References

- Bowles, J. & McManus, D.P. (1993). Molecular variation in *Echinococcus*. *Acta trop.*, 53, 291-305.

- Bowles, J. & McManus, D.P. (1993). Rapid discrimination of *Echinococcus* species and strains using a polymerase chain reaction-based RFLP method. *Molec. biochem. Parasitol.*, 57, 231-239.
- Bresson-Hadni, S., Koch, S., Beutron, L., Vuitton, DA., Bartholomot, B., Hrusovsky, S., Heyd, B., Lenys, D., Minello, A., Becker, MC., Vanlemmens, C., Manton, GA. & Miguet, JP. (1997). Primary disease recurrence after liver transplantation for alveolar echinococcosis: long-term evaluation in 15 patients. *Hepatology*, 30, 857-863.
- Craig, PS. (1997). Immunodiagnosis of *Echinococcus granulosus* and a comparison of techniques for diagnosis of canine echinococcosis, *In: Compendium on cystic echinococcosis in Africa and Middle Eastern Countries with special reference to Morocco* (F.L. Andersen, H. Ouhelli & M. Kachani, eds). Brigham Young University, Print Services, Provo, 85-118.
- Craig, PS., Budke, CM., Schantz, PM., Li, T., Qiu, J., Yang, Y., Zeyhle, E., Rogan, MT., and Ito, A. (2007). Human echinococcosis: a neglected disease?, *Trop. Med. Int. Health*, 35(4), 283-292.
- Craig, PS., McManus, DP., Lightowlers, MW., Chabalgoity, JA., Garcia, HH., Gavidia, CM., Gilman, RH., Gonzalez, AE., Lorca, M., Naquira, C., Schantz, PM. (2007). Prevention and control of cystic echinococcosis. *Lancet Inf Dis.*, 7, 385-394.
- Craig, PS., Rogan, MT., Campos-Ponce, M. (2003). Echinococcosis: disease, detection and transmission. *Parasitology*, 127, S5-S20.
- Dakkak, A. (2010). Echinococcosis/hydatidosis: a severe threat in Mediterranean countries. *Vet Parasitol.* 174(1-2), 2-11.
- D'Alessandro, A. (1997). Polycystic echinococcosis in tropical America: *Echinococcus vogeli* and *E. oligarthrus*. *Acta trop.*, 67 (1-2), 43-65.
- Di Felice, G., Pini, C., Afferni, C. & Vicari, G. (1986). Purification and partial characterization of the major antigen of *E. granulosus* (antigen 5) with monoclonal antibodies. *Molec. biochem. Parasitol.*, 20, 133-142.
- Eckert, J. (1998). Alveolar echinococcosis (*Echinococcus multilocularis*) and other forms of echinococcosis (*Echinococcus oligarthrus* and *Echinococcus vogeli*), *In: Zoonoses* (S.R. Palmer, E.J.L. Soulsby & D.I.H. Simpson, eds). Oxford University Press, Oxford, 689-716.
- Filice, C. & Brunetti, E. (1997). Use of PAIR in human cystic echinococcosis. *Acta trop.*, 64, 95-107.
- Franchi, C., Di Vico, B. & Teggi, A. (1999). Long-term evaluation of patients with hydatidosis treated with benzimidazole carbamates. *Clin. infect Dis.*, 29, 304-309.
- Frider, B., Larrieu, E. & Odriozola, M. (1999). Long-term outcome of asymptomatic liver hydatidosis. *J. Hepatol.*, 30, 228-231.
- Gasser, RB., Zhu, XQ. & McManus, DP. (1998). Display of sequence variation in PCR-amplified mitochondrial DNA regions of *Echinococcus* by single-strand conformation polymorphism. *Acta trop.*, 71, 107-115.
- Gemmell, M.A. & Roberts, M.G. (1995). Modelling *Echinococcus* life cycles, *In: Echinococcus and hydatid disease* (R.C.A. Thompson & A.L. Lymbery, eds). CAB International, Wallingford, Oxon, 333-354.

- Gottstein, B., D'Alessandro, A. & Rausch, R.L. (1995). Immunodiagnosis of polycystic hydatid disease/polycystic echinococcosis due to *Echinococcus vogeli*. *Am. J. trop. Med. Hyg.*, 53, 558-563.
- Gottstein, B., Jacquier, P., Bresson-Hadni, S. & Eckert, J. (1993). Improved primary immunodiagnosis of alveolar echinococcosis in humans by an enzyme-linked immunosorbent assay using the Em2plus-antigen. *J. clin. Microbiol.*, 31, 373-376.
- Haag, KL., Gottstein, B., Ayala, FJ. (2009). The EG95 Antigen of *Echinococcus* spp. Contains Positively Selected Amino Acids, which May Influence Host Specificity and Vaccine Efficacy. *PLoS ONE* 4(4): e5362. doi:10.1371/journal.pone.0005362.
- Ioppolo, S., Notargiacomo, S., Profumo, E., Franchi, C., Ortona, E., Rigano, R. & Siracusano, A. (1996). Immunological responses to antigen B from *Echinococcus granulosus* cyst fluid in hydatid patients. *Parasite Immunol.*, 18, 571-578.
- Leggatt, GR. & McManus, DP. (1994). Identification and diagnostic value of a major antibody epitope on the 12 kDa antigen from *Echinococcus granulosus* (hydatid disease) cyst fluid. *Parasite Immunol.*, 16, 87-96.
- Leggatt, GR., Yang, W. & McManus, DP. (1992). Serological evaluation of the 12 kDa subunit of antigen B in *Echinococcus granulosus* cyst fluid by immunoblot analysis. *Trans. roy. Soc. trop. Med. Hyg.*, 86, 189-192.
- Li, T., Qiu, J., Yang, W., Craig, PS., Chen, X., Xiao, N., Ito, A., Giraudoux, P., Wulamu, M., Yu, W., Schantz, PM. (2005). Echinococcosis in Tibetan populations, western Sichuan Province, China. *Emerg Inf Dis.*, 11, 1866-1873.
- Lightowlers MW & Gauci CG (2001). Vaccines against cysticercosis and hydatidosis. *Vet Parasitol* 101: 337-352.
- Lighthowlers, MW. & Gottstein, B. (1995). Echinococcosis/hydatidosis: antigens, immunological and molecular diagnosis, *In: Echinococcus and hydatid disease* (R.C.A. Thompson & A.J. Lymbery, eds). CAB International, Oxon, 355-410.
- Liu, YH. (1997). Continuous or intermittent treatment with albendazole? *Arch. int. Hidatid.*, 32, 171-173.
- Macpherson, CNL. (2005). Human behaviour and the epidemiology of parasitic zoonoses. *Int J Parasitol.*, 35, 1319-1331.
- Paul, M. & Stefaniak, J. (1997). Detection of specific *Echinococcus granulosus* antigen 5 in liver cyst bioplate from human patients. *Acta trop.*, 64, 65-77.
- Pawłowski, ZS. (1997). Critical points in the clinical management of cystic echinococcosis: a revised review, *In: Compendium on cystic echinococcosis in Africa and in Middle Eastern Countries with special reference to Morocco* (F.L. Andersen, H. Ouhelli & M. Kachani, eds). Brigham Young University, Print Services, Provo, Utah, 119-135.
- Pérez-Molina, JA., Díaz-Menéndez, M, Gallego, JI, et al. (2011). Evaluation of nitazoxanide for the treatment of disseminated cystic echinococcosis: report of five cases and literature review. *Am. J. Trop. Med. Hyg.*, 84(2), 351-6.
- Petavy A-F, Hormaeche C, Lahmar S, Ouhelli H, Chabalgoity A, et al. (2008). An Oral Recombinant Vaccine in Dogs against *Echinococcus granulosus*, the Causative Agent of Human Hydatid Disease: A Pilot Study. *PLoS Negl Trop Dis* 2(1): e125.

- Profumo, E., Ortona, E., Rigano, R., Gioia, I., Notargiacomo, S., Ioppolo, S. & Siracusano, A. (1994). Cellular and humoral responses to antigenic subunits of *Echinococcus granulosus* cyst fluid in hydatid patients. *Parasite Immunol.*, 16, 393-398.
- Rassy, D., Bobes, RJ., Rosas, G., Anaya, VH., Brehm, K., et al. (2010). Characterization of S3Pvac Anti-Cysticercosis Vaccine Components: Implications for the Development of an Anti-Cestodiasis Vaccine. *PLoS ONE* 5(6): e11287.
- Rojo-Vazquez, FA., Pardo-Lledias, J., Francos-Von Hunefeld, M., et al. (2011). Cystic echinococcosis in Spain: current situation and relevance for other endemic areas in Europe. *PLoS neglected tropical diseases.*, 5 (1): e893.
- Sarciron, EM., Bresson-Hadni, S., Mercier, M., Lawton, P., Duranton, C., Lenys, D., Petavy, AF. & Vuitton, DA. (1997). Antibodies against *Echinococcus multilocularis* alkaline phosphatase as markers for the specific diagnosis and the serological monitoring of alveolar echinococcosis. *Parasite Immunol.*, 19, 61-68.
- Sheperd, A. & McManus, D.P. (1987). Specific and cross reactive antigens of *Echinococcus granulosus* cyst fluid. *Molec. biochem. Parasitol.*, 25, 143-154.
- Siracusano, A. & Vuitton, D. (1997). Immunology and immunopathology of *Echinococcus granulosus* and *Echinococcus multilocularis* infections. *Arch. int. Hidatid.*, 32, 132-135.
- Soriano Arandes, A., Gómez Bertomeu, F., and Maldonado Artero, J. (2010). Microscopic Image of the Protoscolex of *Echinococcus granulosus* on the "Hydatid Sand". *Am. J. Trop. Med. Hyg.*, 82(6), 980.
- Thompson, RCA. (1995). Biology and systematics of *Echinococcus*, In: *Echinococcus and hydatid disease* (R.C.A. Thompson & A.J. Lymbery, eds). CAB International, Wallingford, 1-50.
- Torgerson, PR., Keller, K., Magnotta, M., Ragland, N. (2010). The Global Burden of Alveolar Echinococcosis. *PLoS Negl Trop Dis* 4(6): e722.
- Utrilla, JG., Eyre, FP., Muguerza, R., Alami, H. & Bueno, J. (1991). Hidatidosis en la infancia. *Arch. Hidatid.*, 30, 721-730.
- Wen, H. & Craig, PS. (1994). Immunoglobulin G subclass responses in human cystic and alveolar echinococcosis. *Am. J. trop. Med. Hyg.*, 51, 741-748.
- Wolfe, ND., Dunavan, CP., Diamond, J. (2007). Origins of major human infectious diseases. *Nature.*, 447, 279-283.
- World Health Organization (WHO) (1996). Guidelines for treatment of cystic and alveolar echinococcosis. WHO Informal Working Group on Echinococcosis. *Bull. WHO*, 74, 231-242.
- World Health Organization (WHO) (2001). International classification of ultrasound images in cystic echinococcosis for application in clinical and field epidemiological settings., In: PAIR, an option for the treatment of cystic echinococcosis. WHO, Geneva.
- World Health Organization (WHO) (2001). WHO/OIE Manual on Echinococcosis in Humans and Animals: a Public Health Problem of Global Concern. WHO, Geneva.
- WHO/DFID-AHP (2006). The Control of Neglected Zoonotic Diseases-A Route to Poverty Alleviation. World Health Organization, Dept of Food Safety, Zoonoses, and Food-borne Diseases, Geneva.



Zhang, W., Li, J., You, H., Zhang, Z., Turson, G., Loukas, A. & McManus, DP. (2003). Short report: *Echinococcus granulosus* from Xinjiang, PR China: CDNAs encoding the EG95 vaccine antigen are expressed in different cycle stages and are conserved in the oncosphere. *Am. J. Trop. Med. Hyg.*, 68, 40–43.

IntechOpen

IntechOpen



## **Current Topics in Tropical Medicine**

Edited by Dr. Alfonso Rodriguez-Morales

ISBN 978-953-51-0274-8

Hard cover, 564 pages

**Publisher** InTech

**Published online** 16, March, 2012

**Published in print edition** March, 2012

Tropical Medicine has emerged and remained as an important discipline for the study of diseases endemic in the tropic, particularly those of infectious etiology. Emergence and reemergence of many tropical pathologies have recently aroused the interest of many fields of the study of tropical medicine, even including new infectious agents. Then evidence-based information in the field and regular updates are necessary. Current Topics in Tropical Medicine presents an updated information on multiple diseases and conditions of interest in the field. It includes pathologies caused by bacteria, viruses and parasites, protozoans and helminths, as well as tropical non-infectious conditions. Many of them are considering not only epidemiological aspects, but also diagnostic, therapeutic, preventive, social, genetic, bioinformatic and molecular ones. With participation of authors from various countries, many from proper endemic areas, this book has a wide geographical perspective. Finally, all of these characteristics, make an excellent update on many aspects of tropical medicine in the world.

### **How to reference**

In order to correctly reference this scholarly work, feel free to copy and paste the following:

Antoni Soriano Arandes and Frederic Gómez Bertomeu (2012). Echinococcosis/Hydatidosis, Current Topics in Tropical Medicine, Dr. Alfonso Rodriguez-Morales (Ed.), ISBN: 978-953-51-0274-8, InTech, Available from: <http://www.intechopen.com/books/current-topics-in-tropical-medicine/echinococcosis-hydatidosis>

**INTECH**  
open science | open minds

### **InTech Europe**

University Campus STeP Ri  
Slavka Krautzeka 83/A  
51000 Rijeka, Croatia  
Phone: +385 (51) 770 447  
Fax: +385 (51) 686 166  
[www.intechopen.com](http://www.intechopen.com)

### **InTech China**

Unit 405, Office Block, Hotel Equatorial Shanghai  
No.65, Yan An Road (West), Shanghai, 200040, China  
中国上海市延安西路65号上海国际贵都大饭店办公楼405单元  
Phone: +86-21-62489820  
Fax: +86-21-62489821

© 2012 The Author(s). Licensee IntechOpen. This is an open access article distributed under the terms of the [Creative Commons Attribution 3.0 License](#), which permits unrestricted use, distribution, and reproduction in any medium, provided the original work is properly cited.

IntechOpen

IntechOpen