

# We are IntechOpen, the world's leading publisher of Open Access books Built by scientists, for scientists

**4,800**

Open access books available

**122,000**

International authors and editors

**135M**

Downloads

Our authors are among the

**154**

Countries delivered to

**TOP 1%**

most cited scientists

**12.2%**

Contributors from top 500 universities



**WEB OF SCIENCE™**

Selection of our books indexed in the Book Citation Index  
in Web of Science™ Core Collection (BKCI)

Interested in publishing with us?  
Contact [book.department@intechopen.com](mailto:book.department@intechopen.com)

Numbers displayed above are based on latest data collected.

For more information visit [www.intechopen.com](http://www.intechopen.com)



## Dystonias of the Neck: Clinico-Radiologic Correlations

Gerhard Reichel

*Department of Movement Disorders, Paracelsus Clinic, Zwickau,  
Germany*

### 1. Introduction

Idiopathic cervical dystonias (CD), the most prevalent form of defined dystonias in adults, are characterized by involuntary, abnormal movements of the head, and/or by the involuntary adoption of various head postures. With the exception of a few patients, the course of the condition is not progressive<sup>1,2</sup>.

Since the clinical description of the four basic dystonic head/neck movements in 1953 by Hassler<sup>3</sup> there have been no publications concerning the further differentiation of these forms of CD. Also, it has not been attempted to define muscles affected by dystonia with the help of imaging procedures. A new book called "Imaging of Movement Disorders" does not contain a single image of dystonic muscles in its eleven chapters<sup>4</sup>.

Since botulinum toxin has become available for the symptomatic treatment of CD, an exact differentiation between dystonic and non-dystonic muscles is very important.

Botulinum toxin is an established treatment for CD<sup>5</sup> and has gained widespread acceptance since its first use in 1985<sup>6</sup>, based on a large body of evidence<sup>7,8</sup>. Response rates of approximately 80% have been achieved in patients with CD in open and double-blind studies<sup>9-11</sup>. Furthermore, treatment is generally well tolerated even following long-term administration<sup>12, 13</sup> and the risk of adverse events may also be minimized using well-defined injection procedures.

Nevertheless, unsatisfactory treatment outcomes have been observed in patients with CD<sup>14</sup>. These may generally be attributed to incorrect muscles selected for treatment administration and suboptimal dosing and distribution to the affected muscles. Moreover, in some cases, poor treatment outcomes may reflect failure to treat all the affected muscles or the influence of toxins on healthy muscles. Although imaging<sup>15</sup>, electromyography<sup>16</sup> and modifications of injection technique<sup>17</sup> have all been used to improve treatment outcomes, the influence of these methods on treatment outcome requires further clarification<sup>17</sup>.

In patients with CD, dystonic nodding movements, rotatory movements and lateral flexion can originate from the head joints and from the cervical spine. The combination of nodding movements of the upper head joint with rotatory movements of the lower head joint can result in movements in all three spatial planes. Dystonic movement disorders occur in the

majority of patients in two planes (50%), less commonly in one plane (approximately 35%) and, rarely, in three planes (11%)<sup>18</sup>.

The localization of dystonic movements is dependent on the origin and insertion of the muscles involved in dystonia. As not all potentially affected muscles are dystonic in each form of CD, clinical decisions must be based on findings from the clinical examination, including palpation, electromyographic analysis and, in cases of ambiguity, imaging (computed tomography [CT] and magnetic resonance imaging [MRI]). Although dystonic head postures are traditionally classified according to four different movement planes (rotation, lateral flexion, forward/backward flexion and sagittal shift), our clinical experience suggests that this system of classification is not sufficient for the accurate identification of muscles that should be targeted for botulinum toxin treatment. Thus, we conducted a large, non-intervention study using clinical examination, CT and MRI, with the overall aim of elucidating a more precise method of differentiating forms of head and neck postures in patients with CD. Initial results of the MRI analyses have been published previously<sup>19</sup>.

## **2. Methodology**

### **2.1 Setting and study population**

Patients treated in our specialist movement disorders clinic with documented primary CD – established by clinical examination, electromyography, MRI of the neurocranium, laboratory tests and data relating to the patient's medical history – were eligible for inclusion. Patients were enrolled from 2007 to 2009. This sample represents all the patients in our clinic in this time period, with the exception of pregnant patients (n=1) or those who refused to participate (n=1). Written informed consent was given by all included patients and the study was approved by the local ethics committee.

### **2.2 Study assessments**

Characterization of the different forms of the abnormal head (-caput) and neck (-collis) postures in patients with CD was conducted by clinical evaluation and radiological examination. For complicated or unclear cases, CT and/or MRI was also used.

Radiological examinations involved: 1) CT scanning of the soft tissues of the neck as single layers at the section level of cervical vertebrae 3 and 7; and 2) MRI of the cervical spine and the soft parts of the neck (with T1- and T2-weighting in 2 mm slices), and the deep neck muscles (examined at an angle with T1 weighting). During the examination, patients were requested to assume a relaxed head or neck posture. For patients with lateral flexion, electronic 'straightening' of the tomograph was performed to enable muscles to be visualized at the same height on both sides of the image (Figure 1). For evaluation of MRI data, images from 50 patients who did not suffer from CD (prior condition documented as mild trauma or suspected radicular disorder) were used as retrospective controls.

### **2.3 Statistical analyses**

Following CT and MRI, the relationships of the skull to the cervical spine and of the cervical spine to the thoracic spine were analyzed. CT images were also used to obtain measurements

and shapes of muscles in the neck region, as clinically appropriate. Results of analyses for CT and MRI data for patients with CD are presented descriptively as percentages.

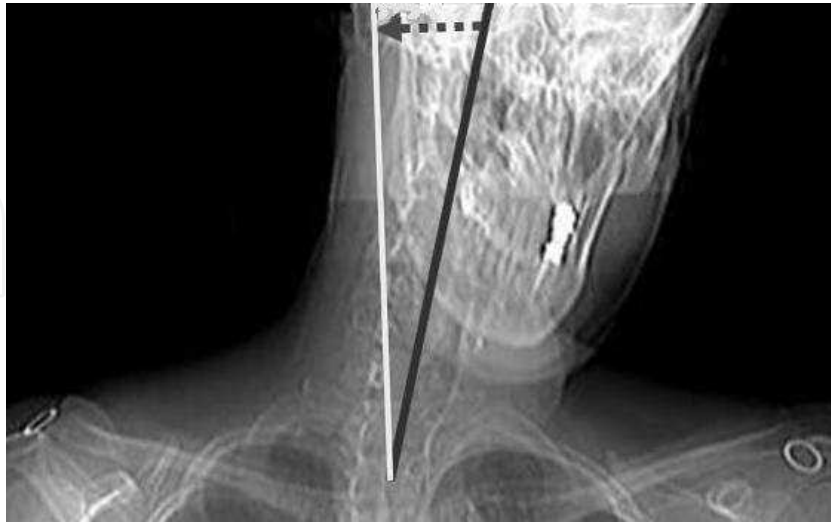

Fig. 1. 'Straightening' by computer tomography in the case of lateral flexion.

### 3. Results

Overall, 95 patients (55 female, 40 male) with established primary CD were included in the study. The patient population had a mean age of 48.5 years, with a mean age at disease onset of 41.6 years.

The incidences of abnormal head posture, categorized according to the traditional classification of four different movement planes (rotation, lateral flexion, forward/backward flexion and sagittal shift), are presented in Table 1. The most frequent form of CD presented as lateral flexion and rotation (34%). The incidence of pure backward flexion was rare (5%), and there were no cases of pure forward flexion.

Abnormal head posture	n (%)
Lateral flexion alone	13 (14)
Rotation alone	10 (11)
Lateral flexion + rotation	32 (34)
Lateral flexion + lateral shift	2 (2)
Lateral flexion + backward flexion	9 (10)
Lateral flexion + forward flexion	2 (2)
Lateral flexion + forward flexion + lateral shift	2 (2)
Lateral flexion + rotation + forward flexion	12 (13)
Lateral flexion + rotation + forward flexion + lateral shift	1 (1)
Backward flexion alone	5 (5)
Rotation + forward flexion	2 (2)
Forward sagittal shift	4 (4)
Backward sagittal shift	1 (1)

Table 1. Incidence of differing abnormal head postures in patients with cervical dystonia (N=95)

The majority of patients (78%; n=73) experienced lateral flexion followed by rotation (61%; n=57), forward flexion (20%; n=19), backward flexion (15%; n=14), and, less frequently, lateral shift (9%; n=8) and sagittal shift (5%; n=5).

The four types of abnormal head posture were characterized further using clinical findings and MRI and CT imaging, and are summarized in Tables 2 and 3.

	<b>-Caput</b>	<b>-Collis</b>	<b>Both</b>	<b>Total (n [%])*</b>
Lateral flexion	14 (19.2)	16 (21.9)	43 (58.9)	73 (44.8)
Rotation	11 (19.3)	10 (17.5)	36 (63.2)	57 (35.0)
Forward flexion	3 (15.8)	5 (26.3)	11 (57.9)	19 (11.7)
Backward flexion	3 (21.4)	2 (14.3)	9 (64.3)	14 (8.6)
<b>Total (n [%])</b>	<b>31 (19)</b>	<b>33 (20)</b>	<b>99 (61)</b>	<b>163 (100)</b>

\*Patients were included more than once in any subgroup.

Table 2. Patient subgroups by flexion or rotation type (latero/ antero/ retro/ torticaput or - collis; n [%])

Clinical manifestation	Dystonic muscles acting on the skull or head joints	Dystonic Muscles acting on C2-7
Lateral flexion	Laterocaput	Laterocollis
Rotation	Torticaput	Torticollis
Forward flexion	Anterocaput	Anterocollis
Backward flexion	Retrocaput	Retrocollis
Combination of laterocollis and contralateral laterocaput	Lateral shift	
Combination of anterocollis and retrocaput	Forward sagittal shift	
Combination of anterocaput and retrocollis	Backward sagittal shift	

Table 3. Proposed subdivisions of cervical dystonia forms

### 3.1 Flexion

Clinical examination alone was sufficient to determine the variant of lateral flexion that was present in the majority of patients (Figure 2a and b). In a few cases, imaging was used to confirm the clinical decision (Figure 2c).

Clinical and imaging observations revealed that 19% of patients had lateral flexion that was located in the head joints, whereas flexion in the cervical spine or between the cervical spine and the thoracic spine was present in 22% of patients (Table 2). Most (59%) patients exhibited simultaneous lateral flexion of the head and of the cervical spine (Table 2).

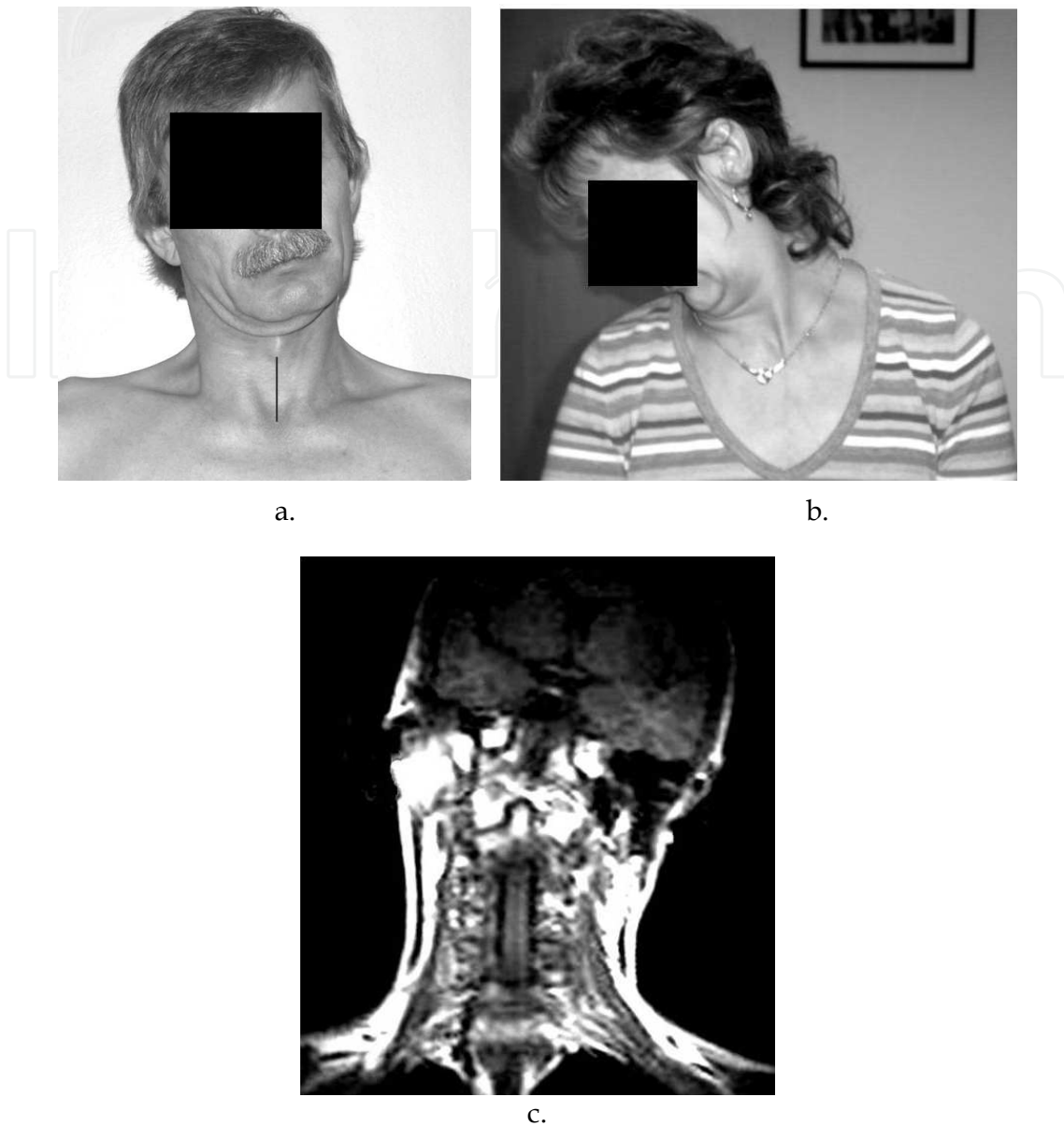


Fig. 2. a.-c. Lateral flexion: a) Laterocaput; b) Laterocollis; c) Computer tomograph-reconstruction in the case of laterocaput.

As observed for lateral flexion, clinical impression was accurate in the majority of patients with backward and forward flexion (Figure 3). The incidence of backward and forward flexion was similar to observations for lateral flexion, with approximately 16 (forward) and 21 (backward) % of cases caused by flexion in the head joints and 14 (forward) and 26 (backward) % by flexion of the cervical spine. Both forms of these posture disorders were present in 58 (forward) and 64 (backward) % of the patients (Table 2).

### 3.2 Rotation

In analyses of head rotation, clinical differentiation between rotation in the head joints and the cervical spine region was frequently inaccurate (Figures 4 and 5). Guidance was provided by the position of the readily palpable incisura jugularis sterni with respect to the

incisura thyroidea superior (for example, in the case of rotation in the head joints, the notches are positioned directly above each other; Figure 4d).

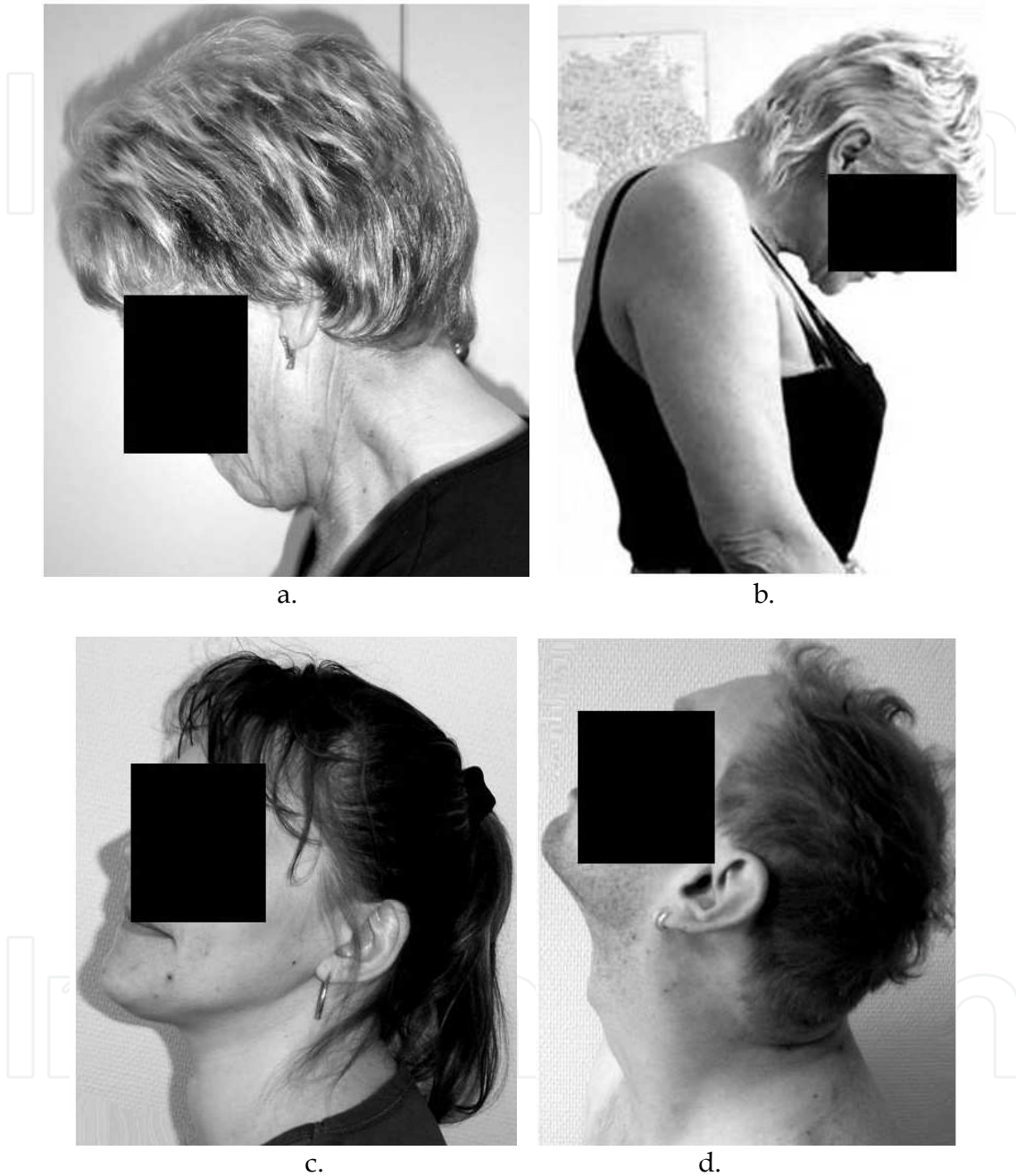

Fig. 3. a.–d. Patients with forward and backward flexion forms of cervical dystonia: a) Forward flexion, anterocaput; b) Forward flexion, anterocollis; c) Backward flexion, retrocaput; d) Backward flexion, retrocollis.

Results using CT-slices to compare the position of the vertebrae in both planes (C3 and C7) allowed more reliable differentiation between torticollis and torticaput. In the case of torticaput, rotation was observed only in the lower head joint (articulatio atlantoaxialis).

Thus, in the C3 image, only the skull (easy to recognize by the lower jaw) is positioned in the rotated direction, whereas cervical vertebrae 3 and 7 are not rotated towards each other (Figure 4b and c). By contrast, the upper cervical vertebrae are rotated towards the lower cervical vertebrae in the presence of torticollis, and the third cervical vertebra points in the direction of the lower jaw (Figure 5b and c). Correspondingly, CT images demonstrated differences between the diameters of the muscles on each side, and therefore the muscles affected by dystonia.

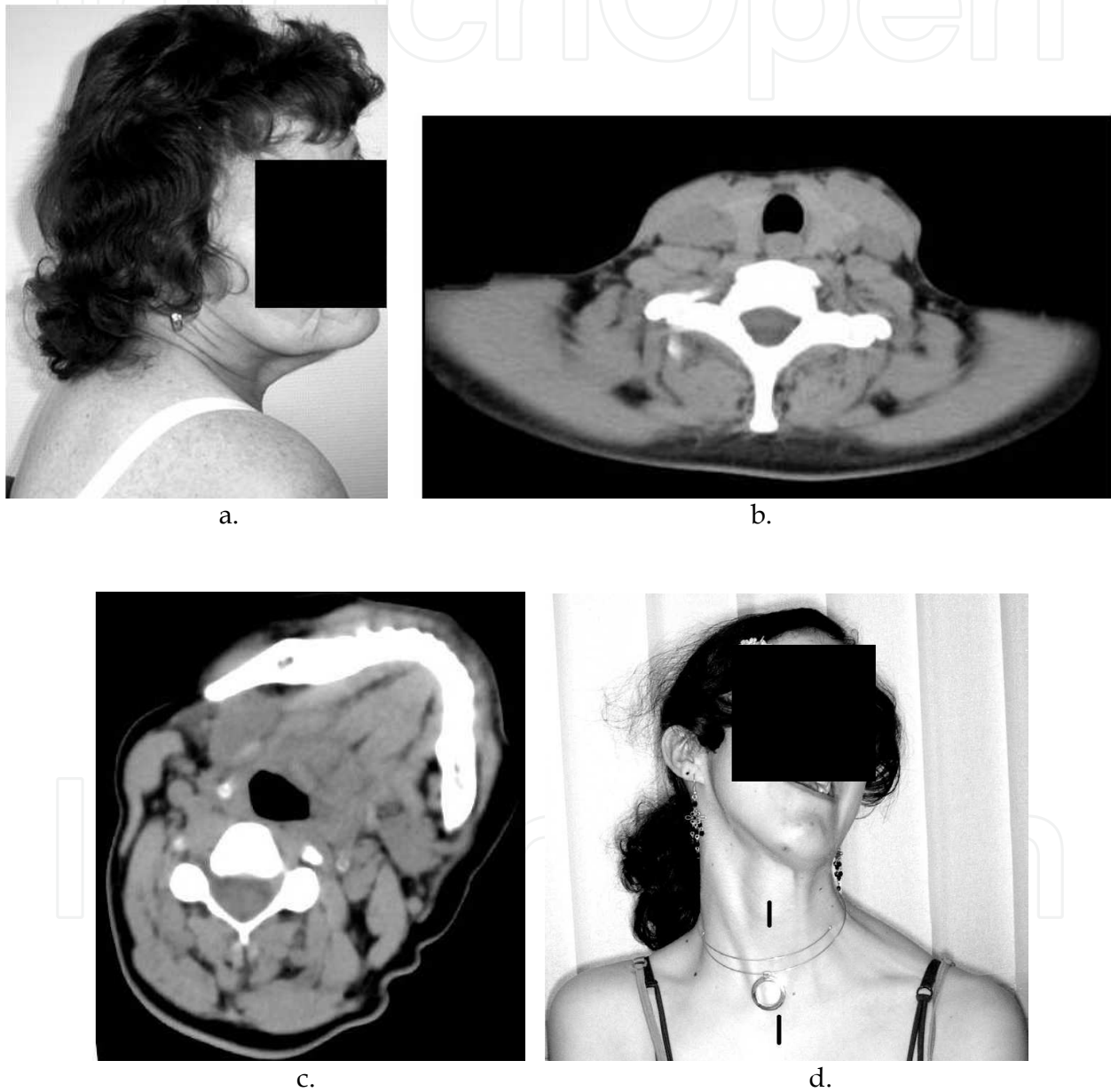


Fig. 4. a.-d. Clinical and imaging evaluations of torticaput: a) Patient with torticaput; b) Computer tomograph at section C7; c) Computer tomograph at C3 (the cervical vertebra is not rotated towards C7 but towards the skull); d) Torticaput (laterocaput and retrocaput, the larynx is positioned above the sternum).



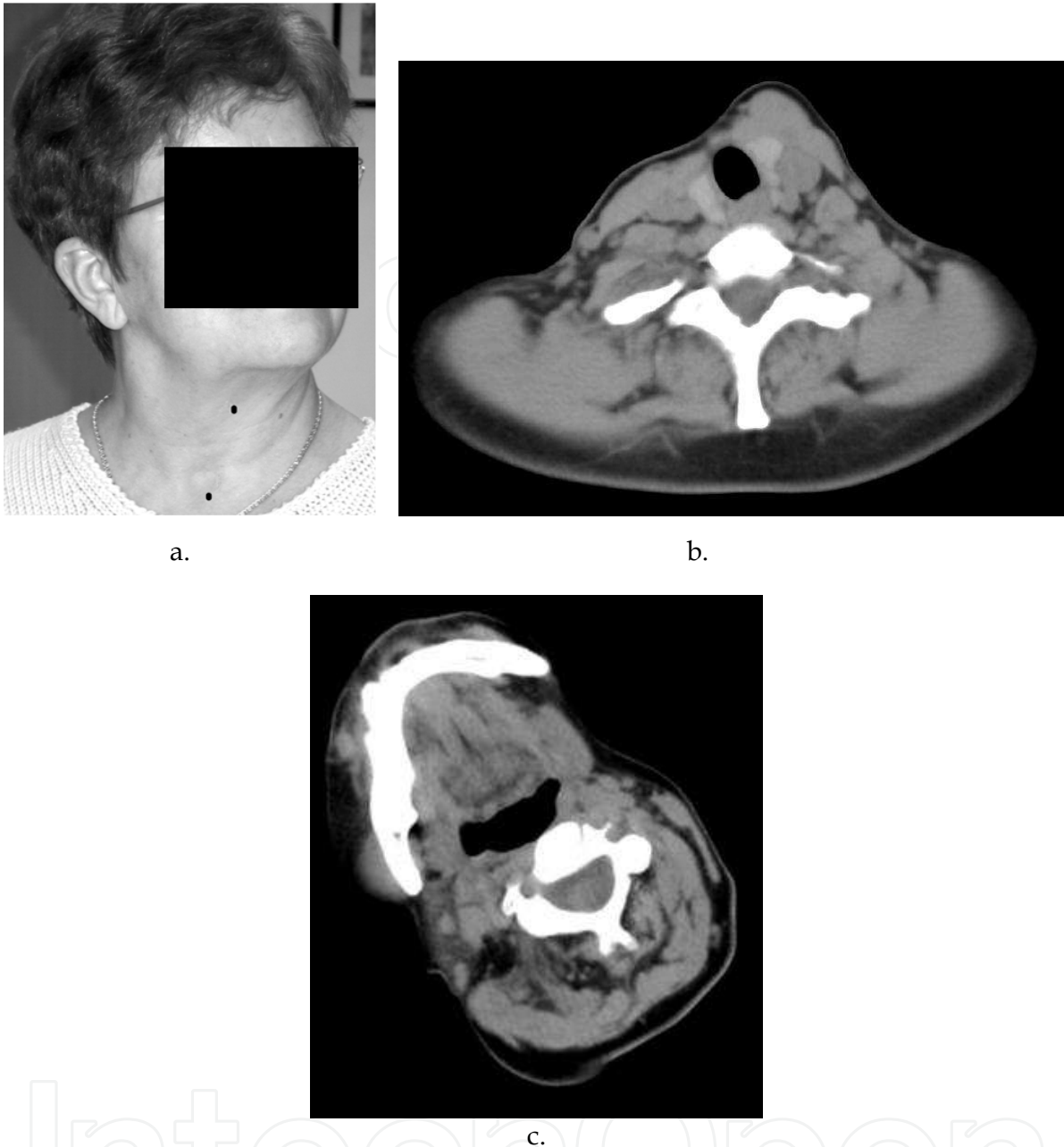


Fig. 5. a.-c. Clinical and imaging evaluations of torticollis: a) Patient with torticollis (the larynx is not positioned above the sternum); b) Computer tomograph at section C7; c) Computer tomograph at C3 (the cervical vertebra is rotated towards C7 but not towards the skull).

### 3.3 Shift

Lateral shift was evident as a combination of lateral flexion of the cervical spine with flexion in the head joints to the opposite side (Figure 6a), whereas sagittal shift presented as a combination of forward flexion of the cervical spine with backward flexion in the head joints (Figure 6b). In contrast, backward shift developed from a combination of retrocollis and anterocaput (Figure 6c).

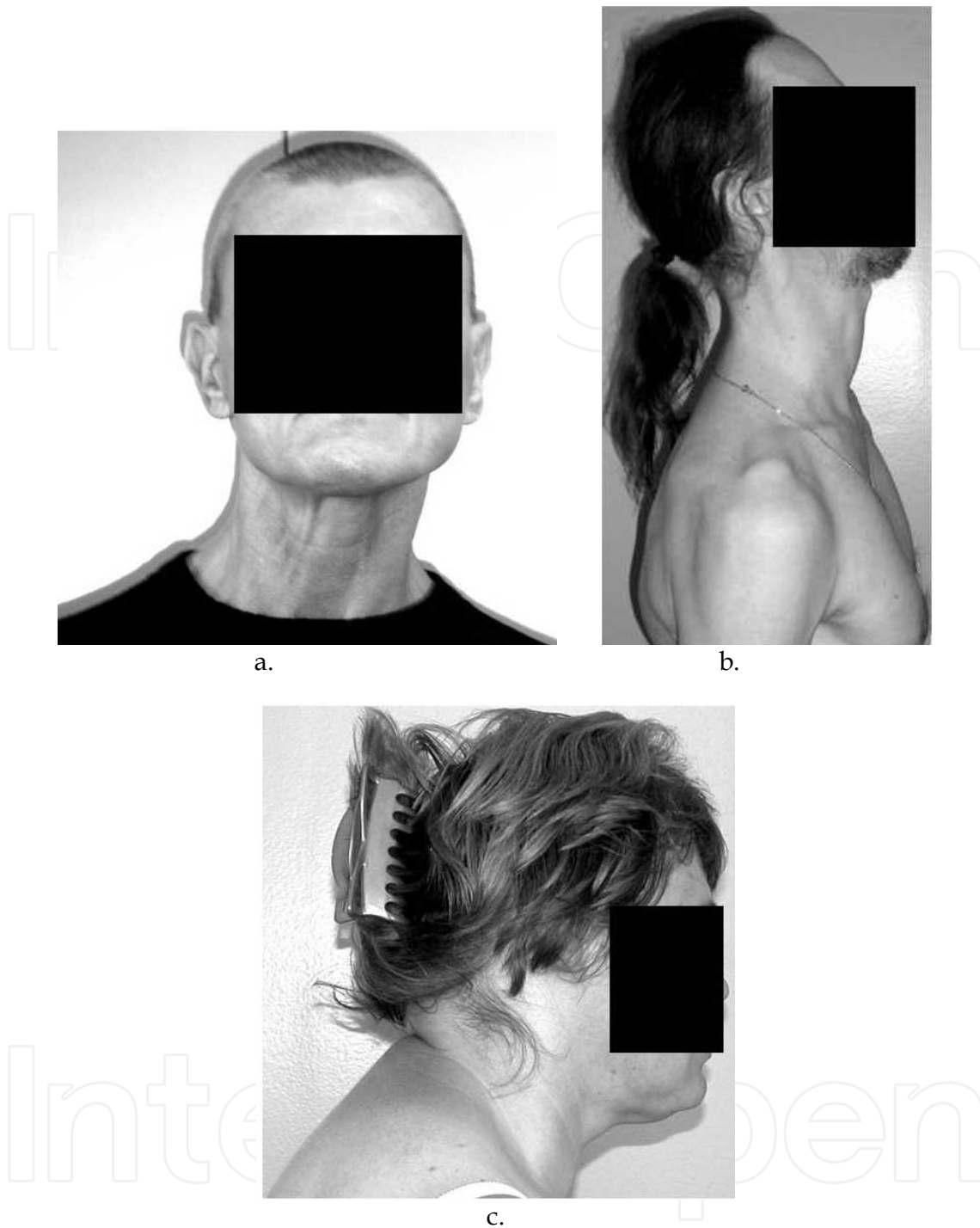

Fig. 6. a.-c. Patients with cervical dystonia characterized by lateral or sagittal shift: a) Lateral shift; b) Backward sagittal shift; c) Forward sagittal shift.

### 3.4 Muscle size

Measurement of maximum muscle diameters using MRI<sup>15</sup> revealed that, in addition to the large neck muscles, musculus obliquus capitis inferior was the only small muscle that was asymmetrical in the majority of patients (73%; Figure 7a). This muscle, when dystonic, induced rotation and backward flexion in the head joints. Therefore, separate analysis of this

muscle is advised given the difficulty of localized treatment with botulinum toxin. For reasons of safety, treatment should only be performed if administration is monitored by CT (Figure 7b).

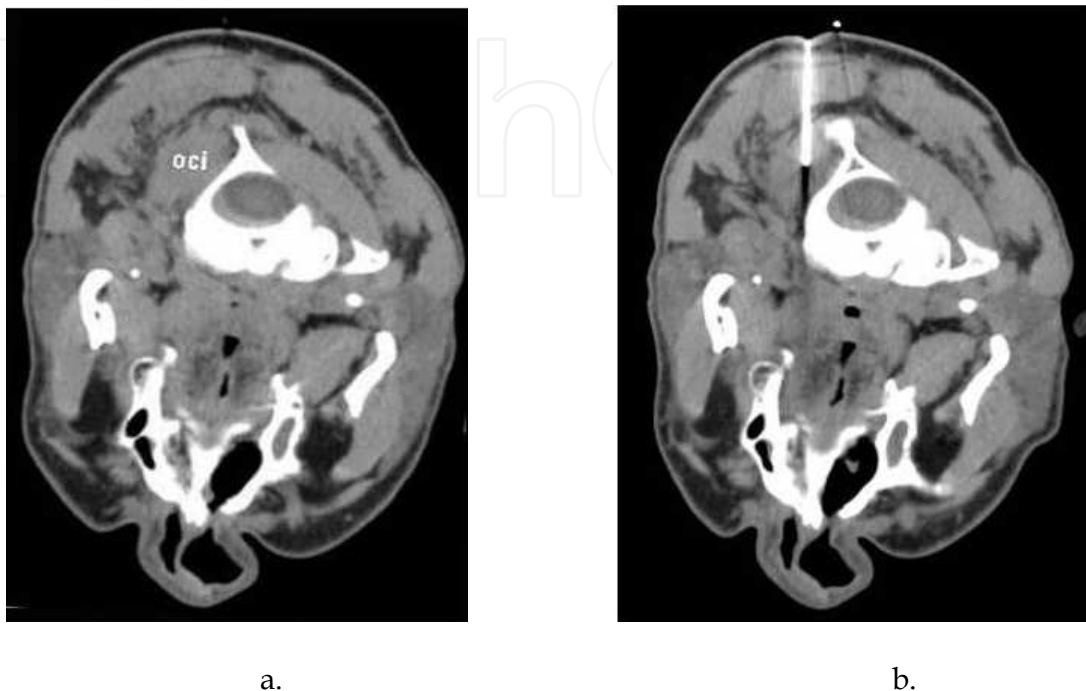
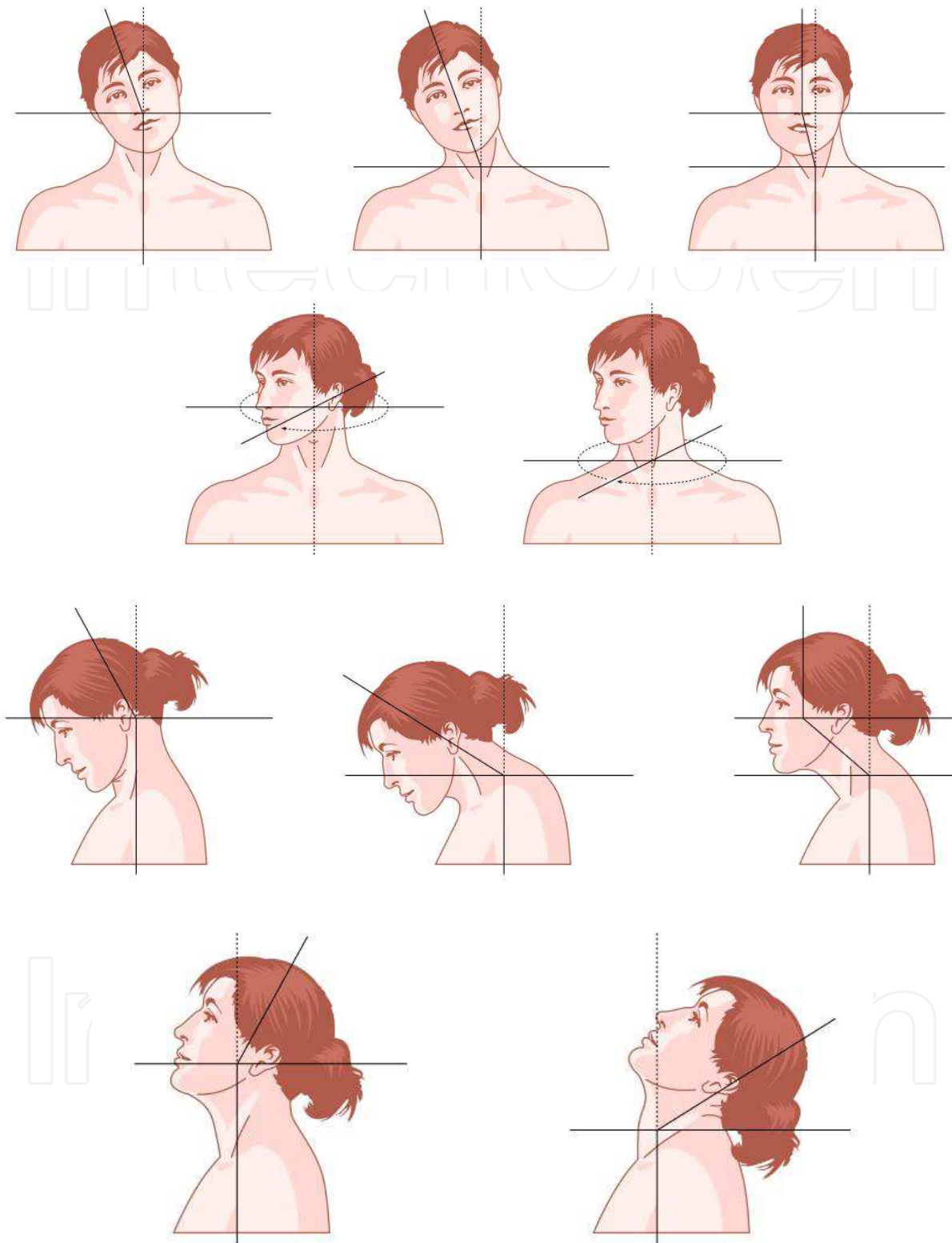


Fig. 7. a.-b. Computertomographic evaluations of dystonic small neck muscle: a) Hypertrophy of the musculus obliquus capitis inferior (oci); b) Botulinum toxin therapy of the musculus obliquus capitis inferior monitored by CT.

#### 4. Botulinum toxin targeting in CD based on clinic-radiologic correlates

This was a large study that was conducted to elucidate the characteristics of abnormal head and neck postures among patients with CD in order to maximize treatment outcomes with botulinum toxin. In contrast to the previously accepted classification of CD (four basic forms), our clinical and imaging findings support the differentiation of the disorder into 10 variations of posture and/or movement (Figure 8), which allows better delineation of the muscles involved in the particular form of CD (Table 4).

Analyses of the prevalence of the characterized forms of CD in our study population revealed that, in the case of lateral flexion and rotation, the abnormal movement and/or posture involved only the head joints (latero- and/or torticaput) in approximately 20% of patients and only the region of the cervical spine (latero- and/or torticollis) in approximately a further 20% of patients. The remaining patients, approximately 60%, had both disorders, albeit with varying degrees of involvement of -caput and -collis. Thus, the incidence of these three forms represented a ratio of 1:1:3. A similar ratio of incidence was observed for forward and backward flexion forms involving the head joints (antero- and/or retrocaput) or the cervical spine (antero- and/or retrocollis) or both in our study population.



[Copyright owned by G Reichel].

Fig. 8. Schematic representation of all forms of cervical dystonia: From the left: upper row – laterocaput, laterocollis, lateral shift; second row – torticaput, torticollis; third row – anterocaput, anterocollis, forward sagittal shift; bottom row – retrocaput, retrocollis.

Form	Muscle	Origin	Insertion
Laterocollis	Levator scapulae	Proc. transv. CV 1-4	Angulus superior scapulae
	<b>Scalenus anterior</b>	Proc. transv. CV 4-6	Rib 1
	<b>Scalenus medius</b>	Proc. transv. CV 2-7	Rib 1
	Semispinalis cervicis	Proc. transv. upper TV	Proc. spin. lower 4 CV
	Longissimus cervicis	Proc. transv. 6 upper TV	Proc. transv. CV 2-5
Laterocaput	<b>Sternocleidomastoideus</b>	Sternum, clavicula	Proc. mastoideus + linea nuchae superior
	<b>Splenius capitis</b>	Proc. spinosus CV 4-7	Proc. mastoideus
	Splenius cervicis	Proc. spinosus TV 4-6	Proc. transv. CV 1 + 2
	Trapezius pars descendens	Linea nuchae	Lateral third of clavicula
	Semispinalis capitis	Proc. transv. CV 4-7	Linea nuchae
	Longissimus capitis	Proc. transv. CV 5-7 and TV 1-4	Proc. mastoideus
	Levator scapulae	Proc. transv. CV 1-4	Angulus superior scap
Torticollis	Longissimus cervicis	Proc. transv. 6 upper TV	Proc. transv. CV 2-5
	Semispinalis cervicis	Proc. transv. upper TV	Proc. spin. lower 4 CV
Torticaput	<b>Sternocleidomastoideus</b>	Sternum, clavicula	Proc. mast. + linea nuchae superior
	<b>Trapezius pars descendens</b>	Linea nuchae	Lateral third of clavicula
	Semispinalis capitis	Proc. transv. CV 4-7	Linea nuchae
	Splenius capitis	Proc. spinosus CV 4-7	Proc. mastoideus
	Splenius cervicis	Proc. spinosus TV 4-6	Proc. transv. CV 1 + 2
	Longissimus capitis	Proc. transv. TV 5-7 and TV 1-4	Proc. mastoideus
	<b>Obliquus capitis inferior</b>	Proc. spinosus axis	Proc. transv. atlantis
Anterocollis bilateral	Scalenus anterior	Proc. transv. CV 4-6	Rib 1
	Scalenus medius	Proc. transv. CV 2-7	Rib 1
	Levator scapulae	Proc. transv. CV 1-4	Angulus superior scapulae
	Longus colli	Proc. transv. CV 2-7	Rib 1
Anterocaput bilateral	<b>Longus capitis</b>	Proc. CV 3-6	Pars basilaris ossis occipitalis

Form	Muscle	Origin	Insertion
Retrocollis bilateral	Longissimus cervicis	Proc. transv. 6 upper TV	Proc. transv. CV 2-5
	<b>Semispinalis cervicis</b>	Proc. transv. upper BW	Proc. spin. lower 4 CV
Retrocaput bilateral	<b>Sternocleidomastoideus</b>	Sternum, clavicula	Proc. mast. + linea nuchae superior
	Trapezius pars descendens	Linea nuchae	Lateral third of clavicula
	Semispinalis capitis	Proc. transv. CV 4-7	Linea nuchae
	Splenius capitis	Proc. spinosus CV 4-7	Proc. mastoideus
	Splenius cervicis	Proc. spinosus TV 4-6	Proc. transv. CV 1 + 2
	<b>Obliquus capitis inferior</b>	Proc. spinosus axis	Proc. transv. atlantis

Table 4. Muscles involved in the different head posture variants (bold: most frequently affected; from MRI measurements<sup>15</sup>).

Treatment strategies for the individual abnormal dystonic postures will differ according to the function of the muscles in the neck region. For example, in the event of lateral bending, dystonia of the muscles originating from, or inserted in, the head or the first cervical vertebra causes abnormal head posture only when normal alignment of the cervical spine is present (Figure 2). With the involvement of muscles that originate from, or are inserted in, the cervical spine, 'genuine' laterocollis occurs if the relationship of the head to the cervical spine is normal. If both muscle groups are dystonic in the same direction, both muscle groups must be treated. However, dosage must be evaluated for both groups, and final dose is dependent on which of the two groups is most affected. If both muscle groups are affected in opposite directions (i.e. laterocollis and laterocaput), this presents clinically as lateral shift (Figure 6). In this study, sagittal backward shift, a rare presentation, was shown to be a complex cervical dystonia with involvement of the muscles for retrocollis and anterocaput. In contrast, forward sagittal shift, in most cases, was solely caused by bilateral dystonia of the musculus sternocleidomastoidei. Contrary to many earlier reports, bilateral tonus of the musculus sternocleidomastoidei does not cause anterocaput; the head is turned backwards in the sagittal plane and the upper cervical spine is pulled downwards, representing a forward shift (Figure 6c). This was first described in 1895<sup>20</sup>, and has been confirmed more recently<sup>21</sup>.

The results of this study are intended to provide a more precise differentiation of the variants of CD and thus to maximize the effectiveness of treatment with botulinum toxin. For purposes of treatment, it is necessary to decide which of the muscle groups are primarily dystonic; it is often sufficient to treat only severely affected muscles<sup>22</sup>.

It is important to treat the most involved dystonic muscles, but it is just as important not to treat muscles that are not affected; a healthy muscle injected accidentally causes a significant change in the pattern of movement and posture and thus renders it difficult to select strategies for further treatment. If an injection plan is prepared on the basis of the clinical examination and consequently optimum treatment results are achieved (i.e. no complaints for several weeks), further diagnostic procedures are not required. If treatment results are inadequate, imaging procedures should also be used to modify the injection plan.

## 5. Recommendations for the differentiation and treatment of CD with botulinum toxin and conclusion

Based on our classification of CD, we propose the following recommendations for the treatment of CD with botulinum toxin:

1. To confirm *lateral bending*, it is usually possible to differentiate clinically between laterocollis and laterocaput. In addition, an analysis of the position of the incisura jugularis sterni towards the incisura thyroidea superior (Figure 4d) is helpful. Should the diagnosis remain unclear, a simple anterior-posterior X-ray is normally sufficient to resolve the problem. In the event of a combination of laterocaput and laterocollis, the relationship of the angles between the thoracic spine and the cervical spine and/or between the cervical spine and the skull is adequate to determine the distribution of botulinum toxin dose between the two different muscle groups.
2. *Lateral shift* inevitably occurs when laterocollis occurs on one side and laterocaput on the other side. Thus, muscles attached to the cervical spine on the side of the shift, and the muscles attached to the skull on the opposing side, require treatment.
3. In the case of *rotation*, reliable clinical differentiation between torticollis and torticaput is difficult. The position of the larynx may be helpful. In the case of torticaput, it tends to remain in the middle, whereas in the presentation of torticollis it tends to be turned to the side. To confirm this form of CD, CT sections at planes C3 and C7 should always be obtained. By comparing the position of the vertebra in both planes, torticollis and torticaput can be reliably differentiated. Additionally, measurements of muscle diameters and shapes on both sides can be extracted from the CT images at C3 and C7, enabling capture of almost all of the muscles involved in CD.
4. An analysis of *forward flexion* (i.e. differentiation between anterocollis and anterocaput) can be performed by lateral examination of the angles between the cervical spine and the thoracic spine and/or between the cervical spine and the base of the skull. This also applies to the analysis of *backward movement* (the differentiation between retrocollis and retrocaput).
5. A *forward sagittal shift* (a combination of anterocollis and retrocaput) is generally caused by bilateral dystonic activity of the musculus sternocleidomastoidei. Conversely, a *backward sagittal shift* is a combination of anterocaput and retrocollis.

In considering our findings, a potential methodological limitation of note was that this study constituted neither a prospective nor a controlled design. However, by recruiting patients without using strict inclusion and exclusion criteria (with the exception of pregnancy and lack of consent), the observed results can be considered to be more representative of the real-life treatment population.

Botulinum toxin administration to the affected muscles is the treatment of choice for primary CD. In order to differentiate between the dystonia affecting muscles inserted in, or originating from, the cervical spine and/or muscles inserted in, or originating from, the skull, supplementation of the clinical examination with CT or MRI is advised. Given the involvement of different muscle groups, it is essential to differentiate between -collis and -caput forms of CD. We have proposed a classification system of 10 basic subtypes of abnormal dystonic positions and postures that we envisage will aid the selection of optimal treatment strategies with botulinum toxin.

## 6. Acknowledgments

Grateful thanks to Andrea Stenner, MD, Director of the Neurological Specialist Department of the MVZ<sup>1</sup> of the Paracelsus clinic, Zwickau, and Anke Jahn, MD, Member of staff of the Radiological group practice at the Paracelsus clinic, Zwickau, for their expert support and kind help. Thank you also to David Caird, PhD, Ipsen Pharma GmbH, Ettlingen, for help in preparation of the manuscript. Editorial assistance for the preparation of this manuscript was provided by Ogilvy Healthworld Medical Education; funding was provided by Ipsen Pharma GmbH.

## 7. References

- [1] Stacy M, ed. Handbook of dystonia. 2007, Informa: New York.
- [2] Jankovic J. Treatment of cervical dystonia. In: Dystonia. M Brin, C Comella, and J Jankovic (eds). Lippincott Williams & Wilkins: Philadelphia, 2004. pp. 159-166.
- [3] Hassler R. Torticollis spasticus. In: Begmann G, Frey W, Schwieglk H, editors. Handbuch der Inneren Medizin. Part 3 Neurologie, vol. 5. Berlin: Springer; 1953. p. 774-9.
- [4] Yousry T, A. Leews. Imaging of Movement Disorders. An Issue of Neuroimaging Clinics of North America. 2010 Saunders W B Co
- [5] Simpson DM, Blitzer A, Brashear A, Comella C, Dubinsky R, Hallett M, et al. Assessment: Botulinum neurotoxin for the treatment of movement disorders (an evidence-based review): Report of the therapeutics and technology assessment subcommittee of the american academy of neurology. *Neurology* 2008;70(19):1699-706.
- [6] Tsui JK, Eisen A, Mak E, Carruthers J, Scott A, Calne DB. A pilot study on the use of botulinum toxin in spasmodic torticollis. *Can J Neurol Sci* 1985;12(4):314-6.
- [7] Costa J, Espirito-Santo C, Borges A, Ferreira JJ, Coelho M, Moore P, et al. Botulinum toxin type a therapy for cervical dystonia. *Cochrane Database Syst Rev* 2005(1):CD003633.
- [8] Swope D, Barbano R. Treatment recommendations and practical applications of botulinum toxin treatment of cervical dystonia. *Neurol Clin* 2008;26 Suppl 1:54-65.
- [9] Jost WH. [clinical use of botulinum toxin]. *Nervenarzt* 2008;79 Suppl 1:9-14.
- [10] Vogt T, Lussi F, Paul A, Urban P. [Long-term therapy of focal dystonia and facial hemispasm with botulinum toxin a]. *Nervenarzt* 2008;79(8):912-7.
- [11] Jankovic J, Schwartz K. Botulinum toxin injections for cervical dystonia. *Neurology* 1990;40(2):277-80.
- [12] Truong D, Brodsky M, Lew M, Brashear A, Jankovic J, Molho E, et al. Long-term efficacy and safety of botulinum toxin type a (Dysport) in cervical dystonia. *Parkinsonism Relat Disord* 2010;16(5):316-23.
- [13] Mohammadi B, Buhr N, Bigalke H, Krampfl K, Dengler R, Kollwe K. A long-term follow-up of botulinum toxin a in cervical dystonia. *Neurol Res* 2009;31(5):463-6.
- [14] Comella CL. The treatment of cervical dystonia with botulinum toxins. *J Neural Transm* 2008;115(4):579-83.
- [15] Reichel G. Therapy guide spasticity - dystonia. 2nd revised & expanded ed: Uni-Med Verlag Bremen 2011.


---

<sup>1</sup> Medizinisches Versorgungszentrum – AHCC (ambulatory health care center)



- [16] Lee LH, Chang WN, Chang CS. The finding and evaluation of emg-guided botox injection in cervical dystonia. *Acta Neurol Taiwan* 2004;13(2):71-6.
- [17] Jost W. Pictorial atlas of botulinum toxin injection: Dosage, localization, application. Berlin: Quintessence Pub Co, 2008.
- [18] Camargo CH, Teive HA, Becker N, Baran MH, Scola RH, Werneck LC. Cervical dystonia: Clinical and therapeutic features in 85 patients. *Arq Neuropsiquiatr* 2008;66(1):15-21.
- [19] Reichel G, Stenner A, Jahn A. Zur Phänomenologie der zervikalen Dystonien [the phenomenology of cervical dystonia]. *Fortschr Neurol Psychiatr* 2009;77(5):272-7.
- [20] Mikulicz J. Über die Exstirpation des Kopfnickers beim muskulären Schiefhals, nebst Bemerkungen zur Pathologie dieses Leidens. *Centralblatt für Chirurgie* 1895;22:1-10.
- [21] Platzer W. Color atlas of human anatomy 1. Locomotor system. Vol 1. New York: Thieme Stuttgart, 2003.
- [22] Hefter H. [Aspects of the complexity of cervical dystonia]. *Nervenarzt* 2008;79 Suppl 1:15-8.

IntechOpen



## **Dystonia - The Many Facets**

Edited by Prof. Raymond Rosales

ISBN 978-953-51-0329-5

Hard cover, 220 pages

**Publisher** InTech

**Published online** 14, March, 2012

**Published in print edition** March, 2012

Dystonia has many facets, and among those, this book commences with the increasingly associated genes identified, including a construct on how biology interacts with the dystonia genesis. The clinical phenomenology of dystonia as approached in the book is interesting because, not only were the cervical, oromandibular/lingual/laryngeal, task-specific and secondary dystonias dealt with individually, but that the associated features such as parkinsonism, tremors and spasticity were also separately presented. Advances in dystonia management followed, and they ranged from dopaminergic therapy, chemodeneration, surgical approaches and rehabilitation, effectively complementing the approach in dystonia at the clinics. A timely critical pathophysiologic review, including the muscle spindle involvement in dystonia, is highlighted at the book's end.

### **How to reference**

In order to correctly reference this scholarly work, feel free to copy and paste the following:

Gerhard Reichel (2012). Dystonias of the Neck: Clinico-Radiologic Correlations, *Dystonia - The Many Facets*, Prof. Raymond Rosales (Ed.), ISBN: 978-953-51-0329-5, InTech, Available from:  
<http://www.intechopen.com/books/dystonia-the-many-facets/dystonias-of-the-neck-clinico-radiologic-correlations>

**INTECH**  
open science | open minds

### **InTech Europe**

University Campus STeP Ri  
Slavka Krautzeka 83/A  
51000 Rijeka, Croatia  
Phone: +385 (51) 770 447  
Fax: +385 (51) 686 166  
[www.intechopen.com](http://www.intechopen.com)

### **InTech China**

Unit 405, Office Block, Hotel Equatorial Shanghai  
No.65, Yan An Road (West), Shanghai, 200040, China  
中国上海市延安西路65号上海国际贵都大饭店办公楼405单元  
Phone: +86-21-62489820  
Fax: +86-21-62489821

© 2012 The Author(s). Licensee IntechOpen. This is an open access article distributed under the terms of the [Creative Commons Attribution 3.0 License](#), which permits unrestricted use, distribution, and reproduction in any medium, provided the original work is properly cited.

IntechOpen

IntechOpen