

We are IntechOpen, the world's leading publisher of Open Access books Built by scientists, for scientists

4,800

Open access books available

122,000

International authors and editors

135M

Downloads

Our authors are among the

154

Countries delivered to

TOP 1%

most cited scientists

12.2%

Contributors from top 500 universities



WEB OF SCIENCE™

Selection of our books indexed in the Book Citation Index
in Web of Science™ Core Collection (BKCI)

Interested in publishing with us?
Contact book.department@intechopen.com

Numbers displayed above are based on latest data collected.

For more information visit www.intechopen.com



Ventilation Perfusion Single Photon Emission Tomography (V/Q SPECT) in the Diagnosis of Pulmonary Embolism

Michel Leblanc

*Chief of Staff, Nuclear Medicine Department
Centre Hospitalier Régional de Trois-Rivières
Clinical professor, University of Montreal
Clinical professor, University of Sherbrooke
Canada*

1. Introduction

Pulmonary embolism (PE) is a frequent and potentially lethal disease caused by the migration of a thrombus to the pulmonary circulation, typically from the venous system of the lower limbs. Unfortunately, there are no specific sets of symptoms which accurately predict or exclude the diagnosis. Therefore, in clinical practice, the diagnosis always strongly relies on imaging. On the other hand, clinical evaluation can predict the probability of embolism in a specific patient. This information can be used to select which patient can benefit most from imaging studies.

Historically, pulmonary angiography and planar ventilation perfusion (V/Q) scintigraphy were the main techniques available for identification of PE. Although traditionally viewed as the gold standard, pulmonary angiography is an invasive technique that suffers from significant limitations. It is not considered anymore as a suitable gold standard (Baile, King et al. 2000). V/Q scintigraphy was used extensively as a non-invasive alternative. It has a high sensitivity and a high negative predictive value. Unfortunately, the technique suffers from a large number of indeterminate studies in which the diagnosis of PE cannot be reliably confirmed or excluded. Indeed, in the PIOPED study, as much as 72% of cases were in that category. Although later studies substantially improved those numbers, the level of indeterminate findings remains high.

It is in that context that computed tomography pulmonary angiography (CTPA) emerged as an alternative non-invasive technique. CTPA carries the advantages of a much lower rate of indeterminate study and the ability to diagnose alternate conditions for the patient's symptoms. Also, the binary interpretation ("positive" vs "negative") was much more acceptable to physicians than the rather complex probabilistic system of V/Q scintigraphy. As such, it has become the principal imaging technique worldwide for the diagnosis of PE. In most centers, conventional planar V/Q scintigraphy is now a secondary technique used mainly when there are contraindications to CTPA or when CTPA is non-diagnostic or not available.

Nonetheless, CTPA also suffers from significant limitations. There are contraindications such as impaired renal function and allergies. The radiation dose is very high, especially to

the female breast. Also, the performance of CTPA in terms of sensitivity and specificity is far from optimal, especially when judged according to the results of the PIOPED II study, which showed significant inaccuracies when the CTPA result was not in line with the clinical probability.

Therefore, there is still a need for other techniques. In that context, Ventilation Perfusion Single Photon Emission Computed Tomography (V/Q SPECT) is rapidly emerging as an interesting alternative. V/Q SPECT is a natural 3D tomographic extension of the conventional V/Q planar technique. It is used in many centers in Europe, Australia and Canada as well as in Asia. Its use in the United States has unfortunately been limited by the absence of FDA approval of Technegas, a superior ventilation imaging agent which is essential for the implementation of V/Q SPECT.

2. Basis of emboli detection by nuclear techniques

The major physiological consequence of PE is occlusion of a part of the pulmonary circulation. Usually, ventilation is preserved, resulting in increased dead space. Therefore, altered perfusion with normal ventilation is the usual consequence of PE. There are situations in which ventilation can be altered such as secondary lung infarct or atelectasis. In those cases, the chest x-ray is usually abnormal.

Nuclear techniques for the evaluation of regional ventilation and perfusion have existed for several decades. Ventilation is usually studied by inhalation of a radioactive gas or radioactive nebulised particles. Perfusion is studied by intravenous injection of radioactive particles (typically macroaggregates of albumin) which are trapped in the pulmonary circulation. In both cases, the distribution of radioactivity on the images is absolutely proportional to ventilation and perfusion. By comparing regional perfusion and ventilation, PE can be diagnosed as areas of absent perfusion with normal ventilation.

3. Technical aspects of V/Q SPECT

SPECT technique requires a ventilation agent which will distribute proportionately to true ventilation in the lungs. Also, once distributed, the agent has to remain fixed for the full period of the acquisition. Therefore, SPECT technique with a gas (xenon-133 or Krypton-81m) is not feasible with current technology, except if a steady state method is used which is complex and not practical in disease situations since it requires a high degree of patient collaboration with ventilation during the whole acquisition period. Therefore, evaluation of ventilation with gaseous agents is always done with a very limited number of planar views (often 1 or 2) and modern tomographic techniques (SPECT) are not clinically available.

SPECT is possible with radio-aerosols, such as DTPA-Tc99m, since these particles become impacted in the lung and their position remains relatively stable during the acquisition time. However, these aerosols, created by nebulisation, produce particles that are rather large (0,5 to 2,0 μm), that tend to deposit in the central airways to a certain degree, especially in chronic obstructive pulmonary disease (COPD). This leads to artefacts in the SPECT reconstruction and poor peripheral lung penetration. Images of suboptimal quality are produced, particularly in diseased lungs, in which mismatches can be missed or underestimated using these conventional aerosols.

Therefore, the use of newer generation ventilation agents such as Technegas is highly preferable. Technegas is an aerosol with very small technetium labelled solid graphite

particles that are generated at high temperature using a specialized oven. The particle sizes are typically 0,005 to 0,2 μm and have a high alveolar penetration index. Ventilation distribution is highly related to those obtained with Krypton 81m (Peltier, De Faucal et al. 1990; Cook and Clarke 1992). The term pseudogas has been used to describe the agent, a reflection of the fact that its behaviour during inspiration is close to that of a true gas. The superiority of Technegas to conventional DTPA aerosols has been demonstrated in COPD (Jögi et al 2010). There is limited central deposition except in severe COPD. Underestimation of true ventilation is not a problem. The particles are cleared from the lungs with a biological half-life of about 5 1/2 days. The agent is thus ideal for SPECT evaluation of true ventilation.

The perfusion technique has not changed significantly in last decades. It is accomplished by micro-embolization with radio-labelled particles injected into a peripheral vein. The particles are labelled with technetium-99m. Particle size is about 15 to 100 μm . For a typical exam, about 400,000 labelled particles are injected. However, since there are about 300 million pre-capillary arterioles and 280 billion pulmonary capillaries, a very small percentage of the pulmonary circulation will be occluded. SPECT technique for perfusion is readily accomplished without artefacts.

In a clinical setting, ventilation is usually performed first with a smaller dose of radioactivity. Typically, the patient is asked to inhale Technegas through a tube set until the desired quantity of radioactivity is present in the lungs, typically 20-50 mega Becquerels (MBq). Usually, 2 to 5 breaths are required. The activity can be standardized in each department either through counting directly under the scintillation camera or with a portable Geiger counter. Patients are then positioned under the camera for image acquisition.

The perfusion study is then performed with a higher dose of radioactivity. In most centers, a ratio of perfusion to ventilation activity of 4 to 1 is considered adequate. The injected dose should be tailored to insure such a ratio. Administered intravenous dose of labelled particles will typically be in the range of 100 to 250 MBq for most patients. Both ventilation and perfusion should be performed in the supine position to minimize regional gradients.

4. SPECT acquisition protocol

The protocol can be tailored to a certain point to the preference of the different centers. The number of tomographic steps should be at least 64 while 128 are considered optimal. Higher radiation doses will permit either higher-quality images or faster acquisition times. If a lower dose range is preferred, a general-purpose collimator which has a higher sensitivity (but a lower resolution) can be used. With such a collimator, using a 64 X 64 matrix, acquisition time can be as low as 5 second per step with perfusion and 10 seconds per step in ventilation in a 128 step protocol with 20-25 MBq in ventilation and 100-120 MBq in perfusion (Palmer, Bitzen et al. 2001). Using a high-resolution collimator and a matrix of 128 X 128 will produce higher-quality images at the expense of a higher radiation dose and longer acquisition times. Depending on the number of steps, the activity will be more in the range of 35-40 MBq in ventilation and 180-200 MBq in perfusion and the time per step will be 15-20 seconds in ventilation and 7-10 seconds in perfusion. Reconstruction of the data should be iterative using OSEM (ordered subset expectation maximization). Eight subsets and two iterations are recommended. Using a higher number of subsets and iterations may produce sharper images but noise will also be increased. However, every center can optimize their protocol.

Image display should strive to match precisely each ventilation slice with the corresponding perfusion slice in all three planes (transverse, coronal, sagittal). This can be easily done either by not moving the patient or bed position between ventilation and perfusion or, alternatively, by using commercially available software which will co-register each set of images.

5. Image interpretation

In a normal patient, perfusion and ventilation are both homogeneous (figure 1). There is usually a ventilation and perfusion gradient which increases from the anterosuperior to the posteroinferior region of the lungs. There is often a thin band of hyperventilation located in the lower two thirds of the posterior aspect of both lungs. The normal indentations of the mediastinum should be recognized.

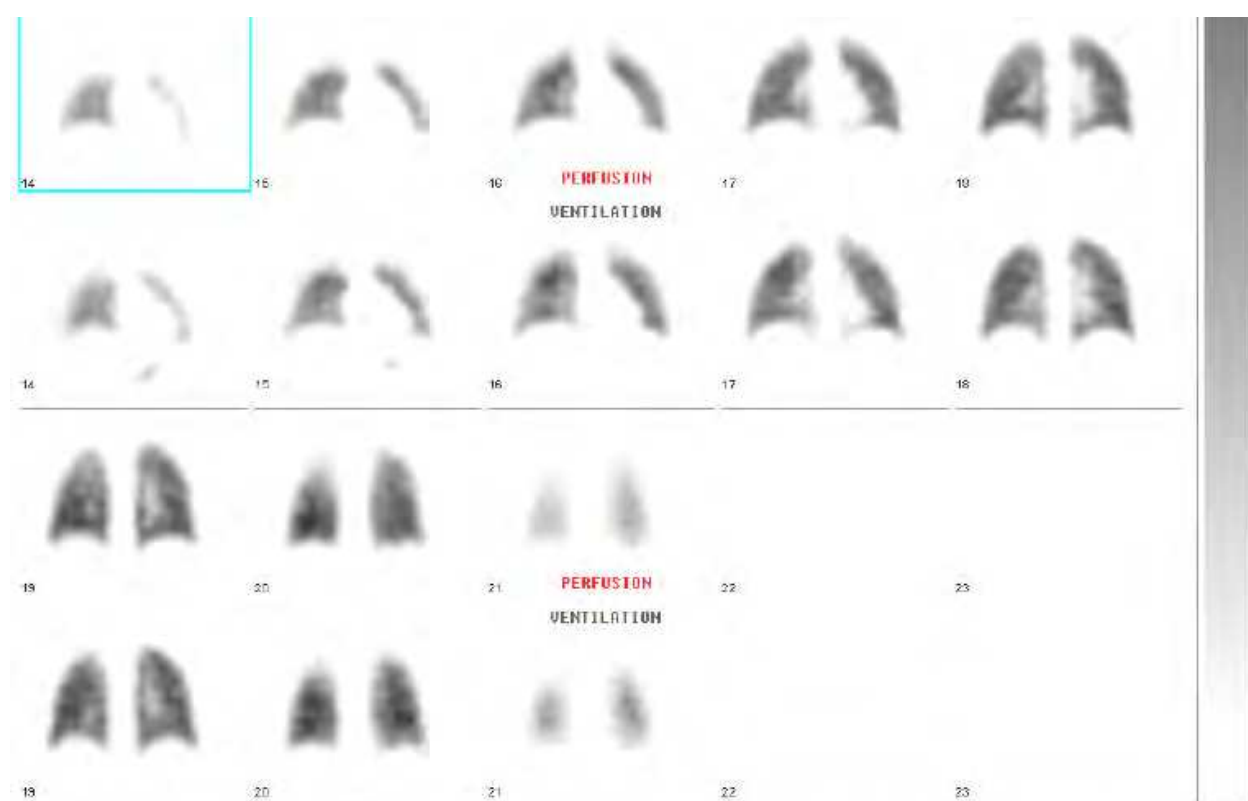

Fig. 1. Normal perfusion and ventilation coronal SPECT slices.

Non-segmental partial mismatches (preserved ventilation with abnormal perfusion) can occur in normal subjects. Physiologically, they are explained by the fact that ventilation with Technegas is usually evaluated with deep breathing. Such deep breathing can temporarily overcome partially compressed lung and result in hyperventilation. Those lung sections are usually poorly ventilated with tidal breathing. Since perfusion will be physiologically matched to tidal breathing, this explains the potential for partial mismatches. Perfusion is usually maintained to some degree (figure 2). The most common areas are the medial postero-inferior regions of both lungs because of compression by the mediastinum in the supine position. Both the inferior and posterior costal phrenic angles are also often subject to this phenomenon (figure 3). Also, the superior portion of the large fissure may be the site of a small mismatch. None of these anomalies follow the topography of normal lung vessels.



Fig. 2. Passive atelectasis (coronal and sagittal slice triangulation). Note non-segmental partial mismatch.



Fig. 3. Sagittal SPECT slices showing non-embolic mismatch at posterior costophrenic angle caused by lung compression.

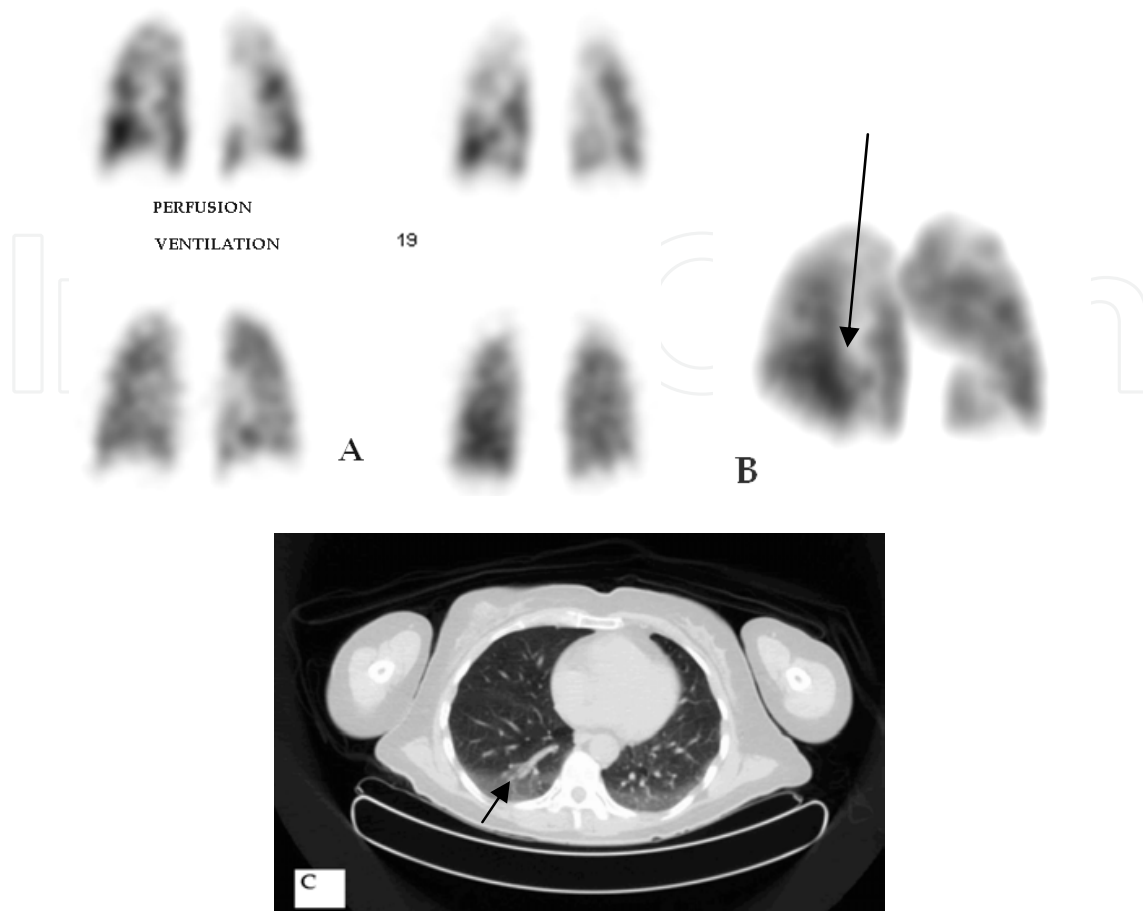


Fig. 4. Gravity dependant atelectasis. (A) Coronal slices centered on posterior surface of the lungs show diffuse shallow non segmental partial mismatches. (B) Excerpt from a 3D reconstruction of perfusion in oblique view showing a topography totally incompatible with a vascular origin. (C) CT of another patient showing the typical pattern of gravity dependent atelectasis on posterior surfaces.

In some patients, gravity dependent atelectasis can result in widespread partial mismatches on the posterior surface of both lungs. This pattern is usually easily recognized by the occurrence of multiple shallow perfusion defects which are often in a linear pattern (figure 4). A 3D display will often best demonstrate the topography.

PE is diagnosed when there is a severe and well demarcated perfusion defect which is pleural-based and clearly larger at the periphery (typically wedge-shaped, triangular or half-oval). Small size partial defects that are not well defined are much less specific and should be ignored in most acute settings, even if they are partially mismatched. The defect should clearly follow an orientation compatible with known pulmonary vascular anatomy. Ventilation should be normal or at least much better preserved than perfusion. One such large sub-segmental defect is sufficient for the diagnosis (figure 5 & 6). There are however multiple mismatched regions in most cases (figures 7, 8 & 12). For smaller sub-segmental defects, at least two are required for a confident diagnosis (figure 9 & 11). Distal PE is usually totally occlusive. However, more proximal PE (i.e.: lobar) can be partially occlusive and the perfusion defect may at times be moderate. It should be remembered that an isolated whole lung mismatch is usually not caused by PE but rather by compression of the main pulmonary artery by a mediastinal or hilar lesion.

The preceding discussion applies only to acute pulmonary embolism. In the sub-acute or chronic phases, when partial reperfusion has occurred, the aspect can vary considerably and interpretation can be less straightforward because strange shaped partial mismatches can occasionally be seen in this setting.

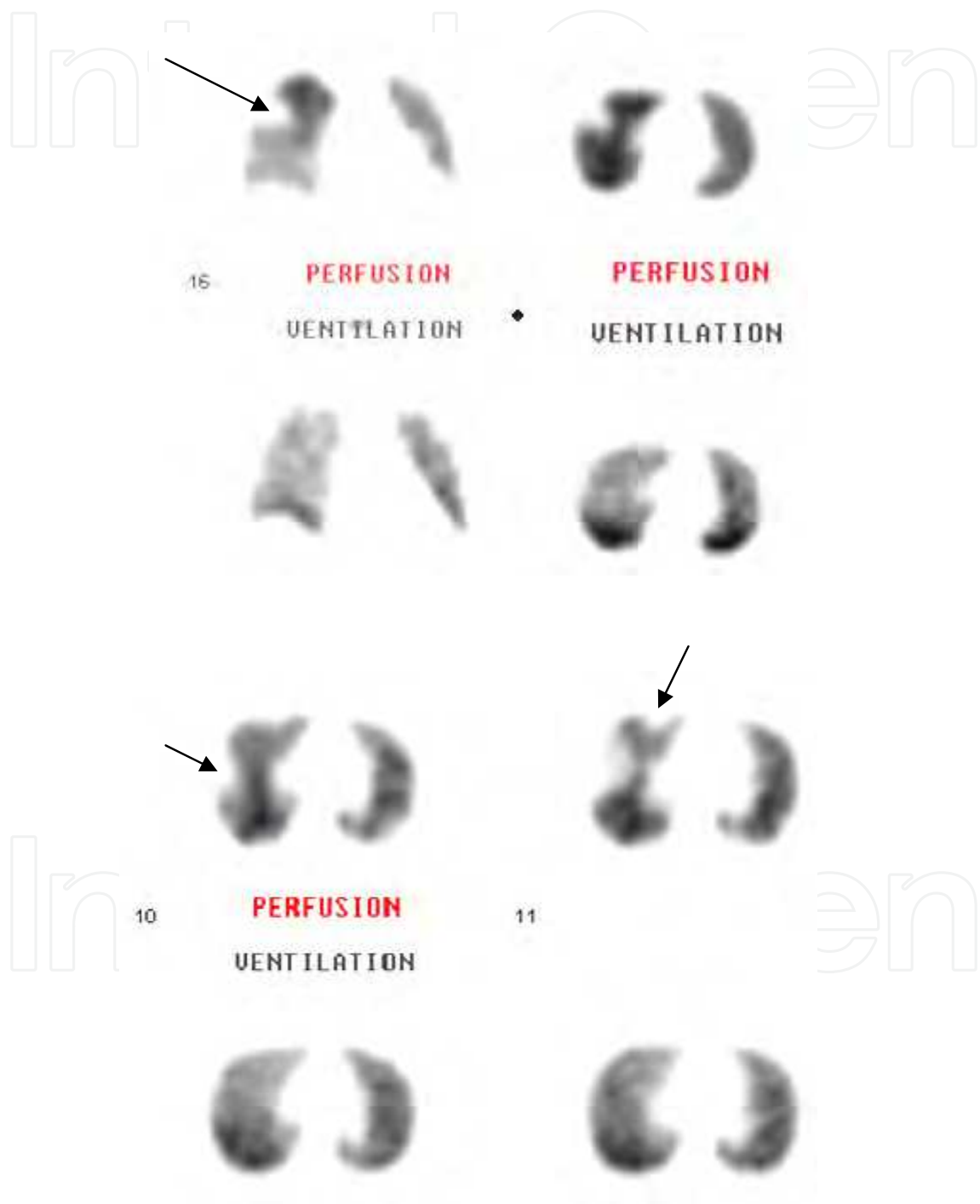


Fig. 5. Typical wedge-shaped emboli in two different patients (coronal and transverse slices)




Fig. 6. Typical embolus, coronal, sagittal and transverse slice triangulation.

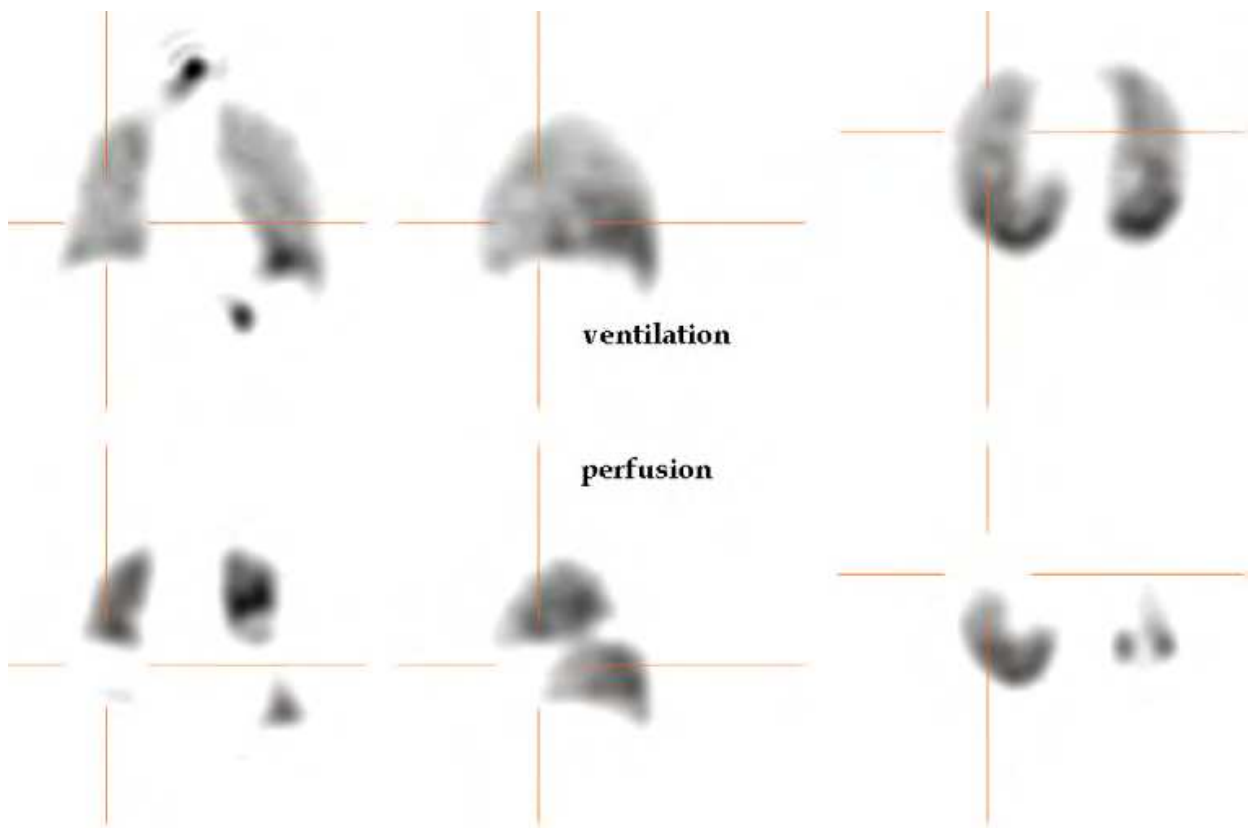


Fig. 7. Multiple emboli.

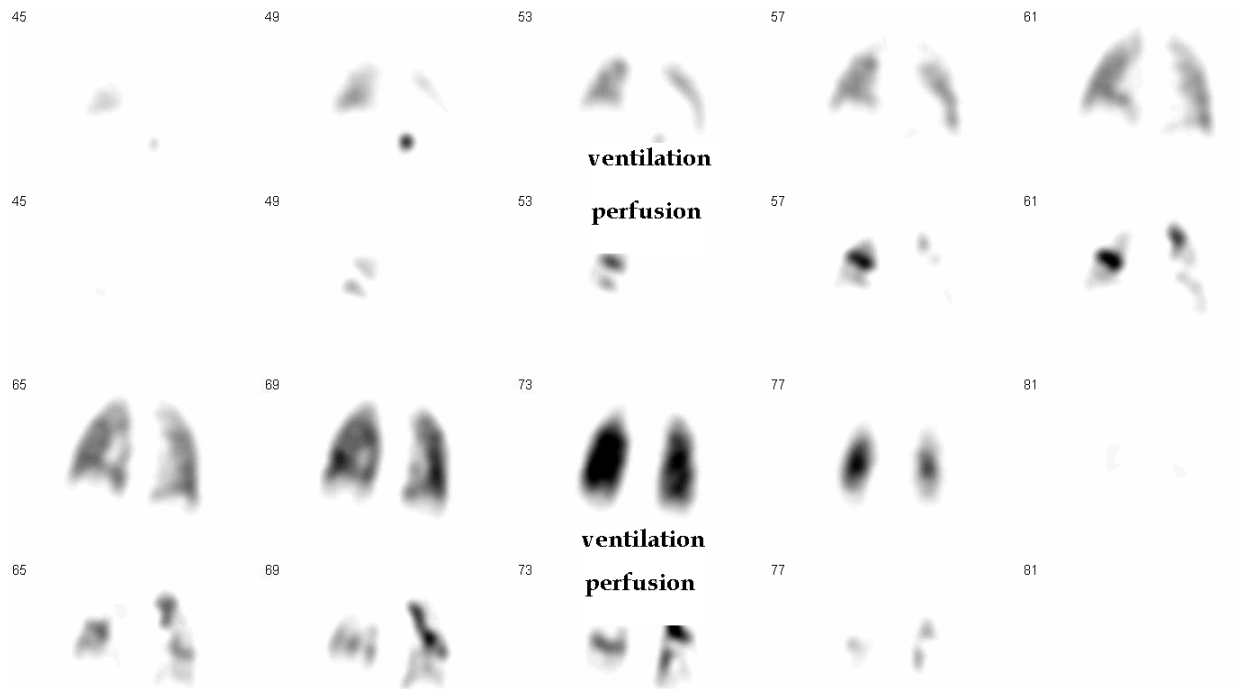


Fig. 8. Massive embolism (co-registered coronal slices). Ventilation slices are on 1st and 3rd row. Corresponding perfusion slices on 2nd and 4th row show massive areas of vascular amputation with preserved ventilation.

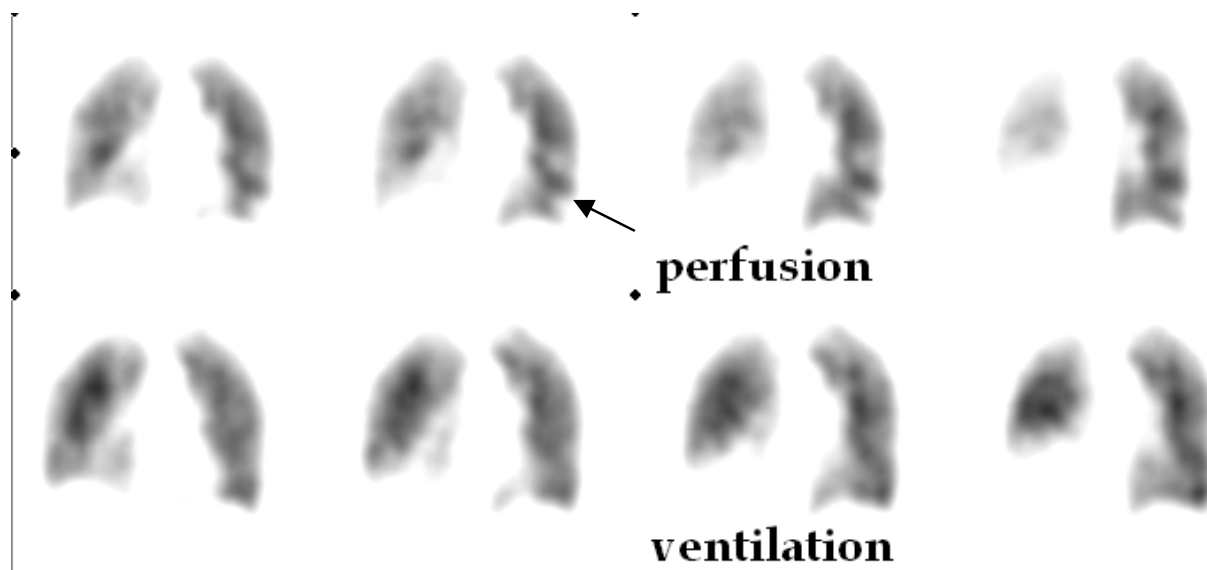


Fig. 9. Small left sub-segmental embolus. Pleural effusion is noted on the right side (co-registered coronal slices)




Fig. 10. Typical wedge-shaped embolus.

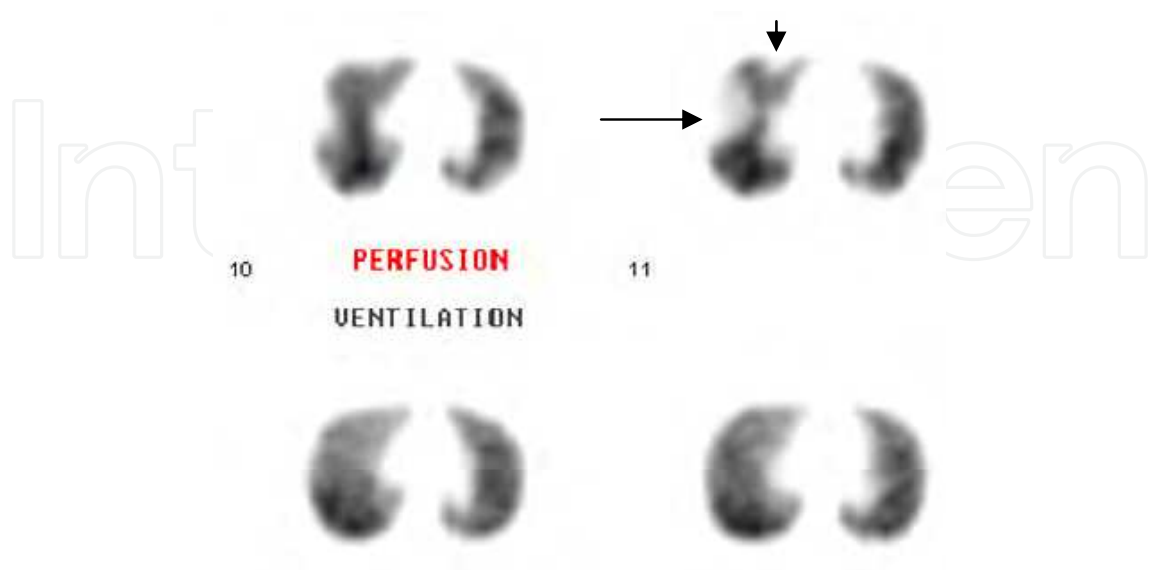


Fig. 11. Example of segmental (long arrow) and subsegmental (short arrow) emboli.

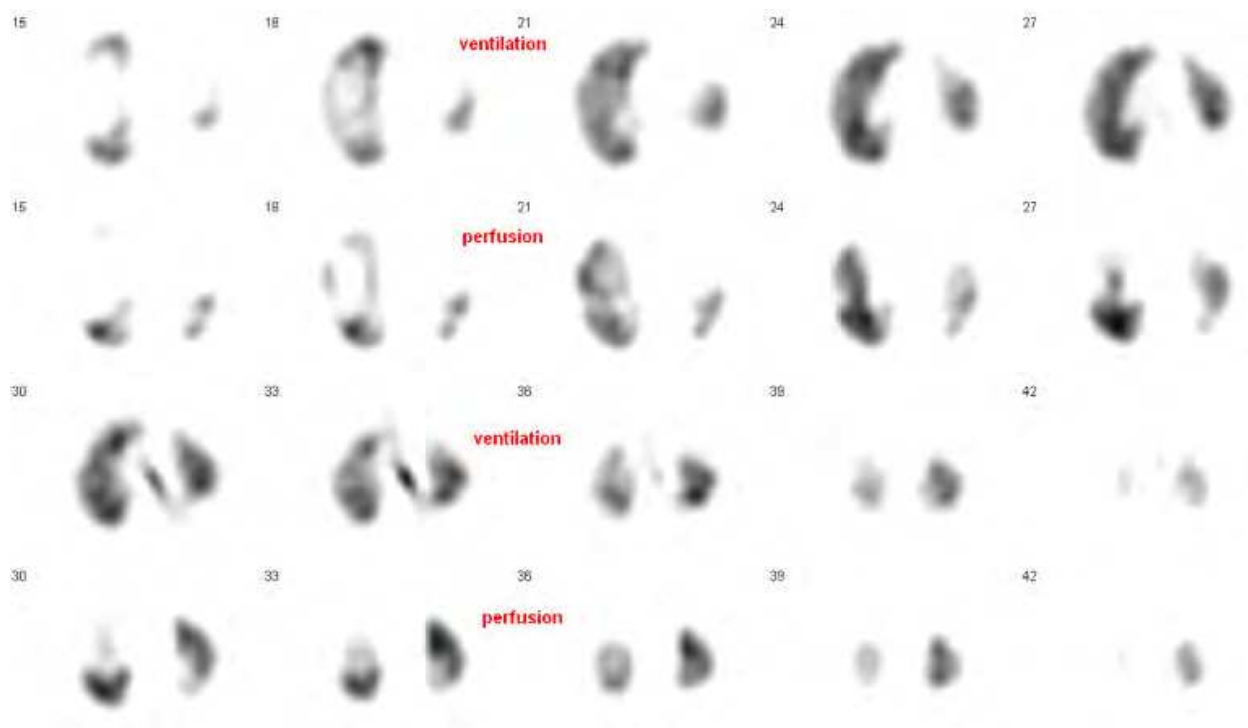


Fig. 12. Transverse slices showing multiple right sided emboli. Pleural effusion on left.

Probabilistic interpretation with classification of cases into “normal”, “low”, “indeterminate” or “high” probability which is still in use with planar scintigraphy is absolutely not warranted with V/Q SPECT. Indeed, there has been no study to specifically address the validity of probabilistic interpretation with V/Q SPECT. Therefore, using a probabilistic interpretation in that context has no scientific basis. All authors that have published on the subject have used a straightforward positive-negative approach and it is the only one that is acceptable. It makes no sense to use a mode of interpretation that has been motivated by the use of an inferior ventilation agent (xenon-133) in a single planar view, associated with planar perfusion imaging. As for any other type of imaging, a very narrow indeterminate category can be acceptable for highly atypical cases.

Causes of non-embolic pathological mismatches are well known and are essentially the same with V/Q SPECT as they are with the conventional planar V/Q scintigraphy. They may be the source of false-positive readings. Septic, fat or amniotic fluid embolization may occasionally occur in specific settings. The mismatches are usually small. Intravenous illicit drug use may occasionally result in small sized mismatches, although larger mismatches may occur. Vasculitis can be considered when clinically appropriate. A compression of a segmental or sub-segmental branch of the pulmonary artery by a lung nodule can be rarely seen. Much more frequent is a very large mismatch caused by a compression of hilar or mediastinal origin. Small partial mismatches can also occur in emphysematous bullae (Figure 13) because of occasional penetration of Technegas. However, the mismatch does not usually have a vascular pattern and is typically located at the apex. Lung scarring or fibrosis can also cause small or partial mismatches. Rarely, asthma can present with some strange looking small but multiple partial mismatches, presumably because there can be a lag time between restoration of regional ventilation and adjustment of the physiologically matched perfusion anomaly (figure 14). In such cases, V/Q SPECT will normalise after 24 hours of aerosol therapy.

It is therefore highly recommended that image interpretation is made with full knowledge of the clinical data and that correlation should be made with a recent chest x-ray. Correlation with existing anterior thoracic CT may be helpful in selected pathological cases. In this manner, high specificity can be achieved. Also, equivocal cases should be interpreted in light of the pre-test probability and knowledge of prior pulmonary pathology. Evidently, knowledge of prior PE or venous thrombotic disease is essential for the correct interpretation of positive cases. This type of interpretation (“holistic” or “Gestalt”) is now considered as standard in most parts of the world and has been officially endorsed by the guidelines of the European Association of nuclear medicine (Bajc, Neilly et al. 2009).




Fig. 13. Small apical mismatch caused by a bullae. This should be suspected in all non-segmental apical mismatch, although scarring may also cause a similar image.

6. Some non-embolic pathological patterns that can be recognized on V/Q SPECT

Although other pulmonary pathologies are not an indication for V/Q SPECT, diagnostic patterns have been described and validated for several situations and their recognition can provide useful information to the referring physician.

6.1 COPD

In COPD, ventilation is usually diffusely more affected than perfusion. The exact configuration depends on the severity of the process as well as the relative contribution of emphysema and bronchitis (figures 15 to 17). With a relatively pure bronchitis, the changes

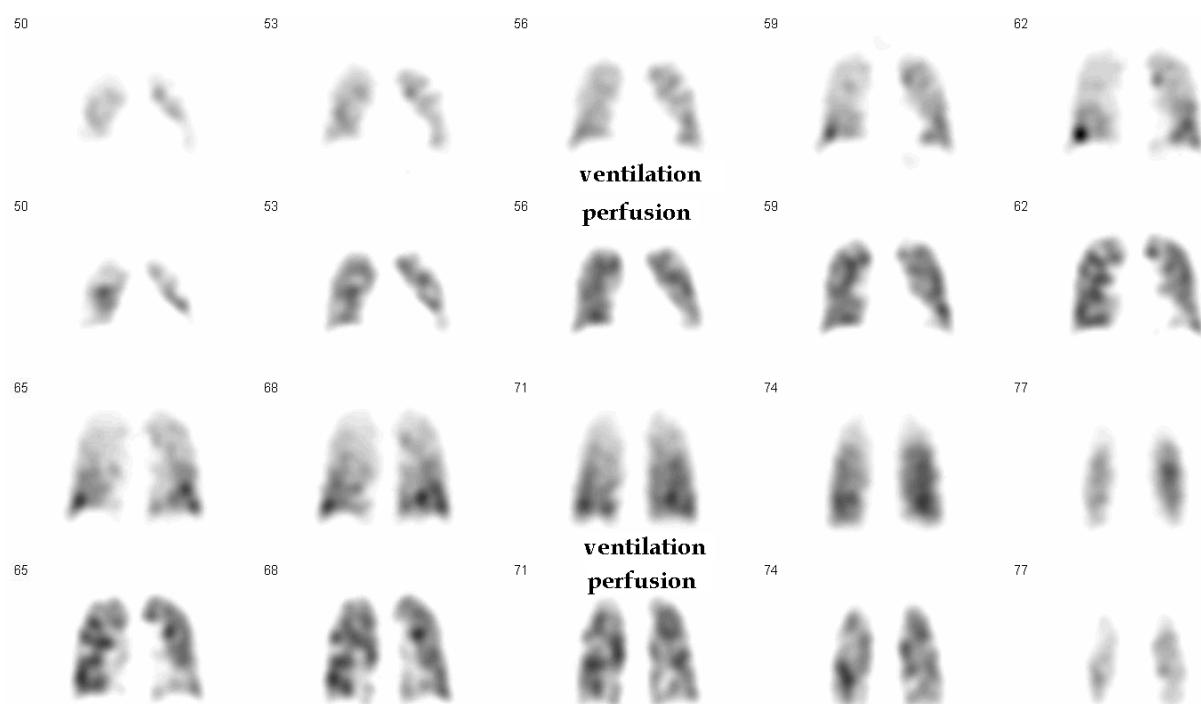


Fig. 14. Asthma, acute attack (retrospective diagnosis). Aerosol therapy was begun before V/Q SPECT. Notice multiple non-vascular looking partial mismatches.

are mainly seen on the ventilation part of this study. Distribution is heterogeneous and, in the more severe cases, there may be focal deposition of Technegas in Airways. With advanced disease, there may be widespread focal deposition. On the other hand, perfusion is usually better preserved. With a pattern of relatively pure and advanced emphysema, perfusion and ventilation are more matched, reflecting mainly focal architectural pulmonary changes. It has been demonstrated that the degree of heterogeneity on the ventilation study, as well as the degree of heterogeneity of perfusion and ventilation matching, are both proportional to the severity of COPD. In fact, these measures appear to be more sensitive to the presence of COPD than high-resolution CT which, despite its higher resolution, has a limited capacity for the detection of airway closure. However, heterogeneous distribution of ventilation and perfusion can also be found in pulmonary oedema, lung fibrosis and infectious or non-infectious diffuse lung inflammation.

6.2 Cardiac failure and volume overload

Although pulmonary oedema is usually well demonstrated on a chest x-ray, in the early stages of volume overload the only sign will be vascular redistribution to the upper lung zone. On a V/Q SPECT study, this is very easily appreciated. Typically, the examination being performed in a supine position, redistribution will be most marked anteriorly and superiorly and will usually be much more apparent on perfusion than on ventilation (figure 18). In the earliest stages, the ventilation gradient will be totally preserved which produces a rather large scale partial mismatch. It is important that this pattern be recognized and not confused with bilateral partially occluding inferior lobar PE. It should be noted that cardiac failure is not the only cause of vascular redistribution. Volume overload, whether iatrogenic or caused by hepatic or renal failure may produce the same images.

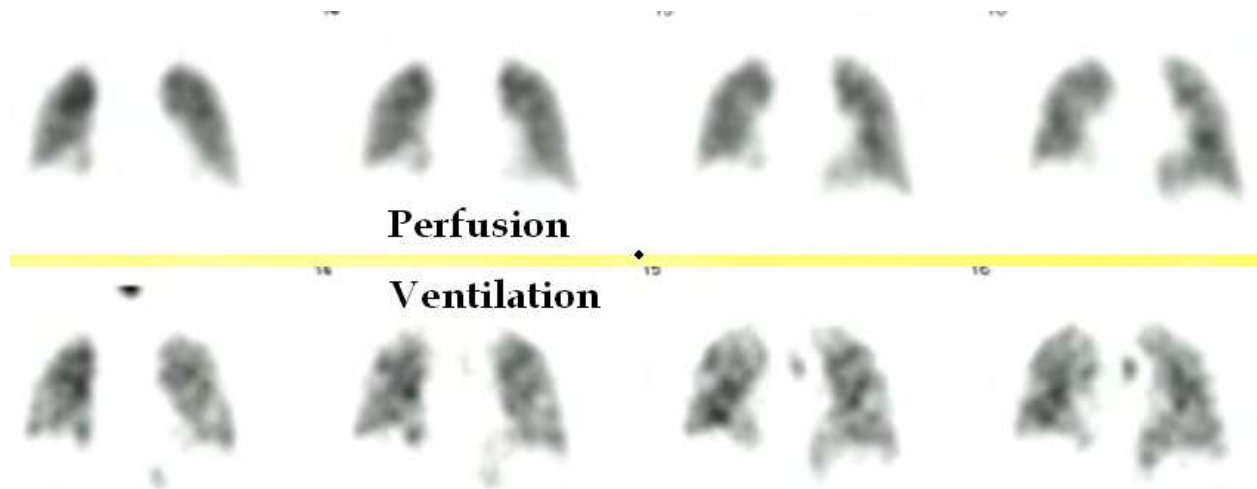


Fig. 15. Mild to moderate COPD (selected coronal slices). Diffusely mottled ventilation with better preservation of perfusion.

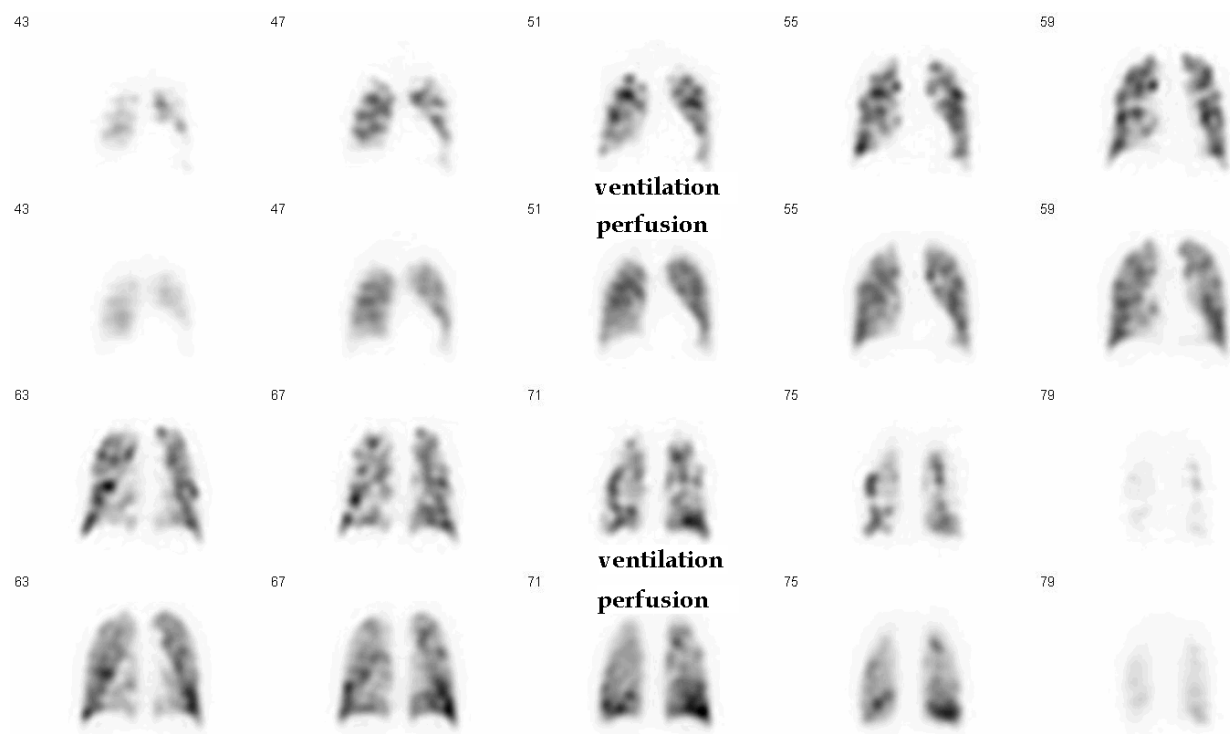


Fig. 16. Moderate COPD. Focal deposition of Technegas with heterogeneous ventilation. Perfusion is also mottled but to a lesser degree.

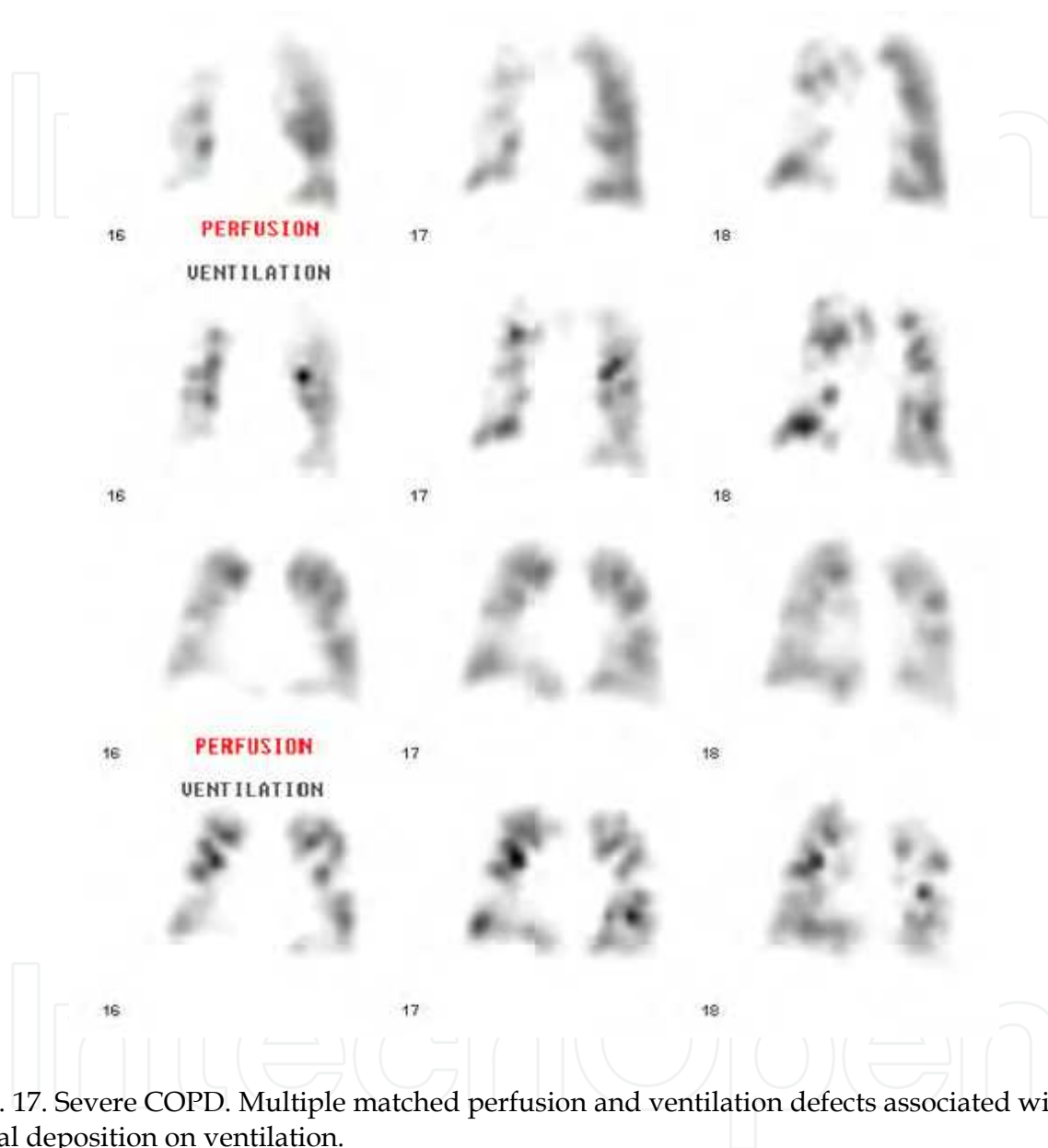


Fig. 17. Severe COPD. Multiple matched perfusion and ventilation defects associated with focal deposition on ventilation.

6.3 Pneumonia and atelectasis

In most cases, ventilation will be totally absent while perfusion will be partially preserved at least to some extent. Sometimes, a pattern of total reverse mismatch will be observed (absent ventilation with normal perfusion). It is unusual for PE to present with absent ventilation and some degree of residual perfusion. Also, in many cases of pneumonia, the distribution of the defect will not be compatible with a vascular anomaly (not pleural based, trans-segmental or orientation not compatible with vascular anatomy). Preservation of some perfusion in the presence of an x-ray anomaly favours a non-embolic cause (figure 19).

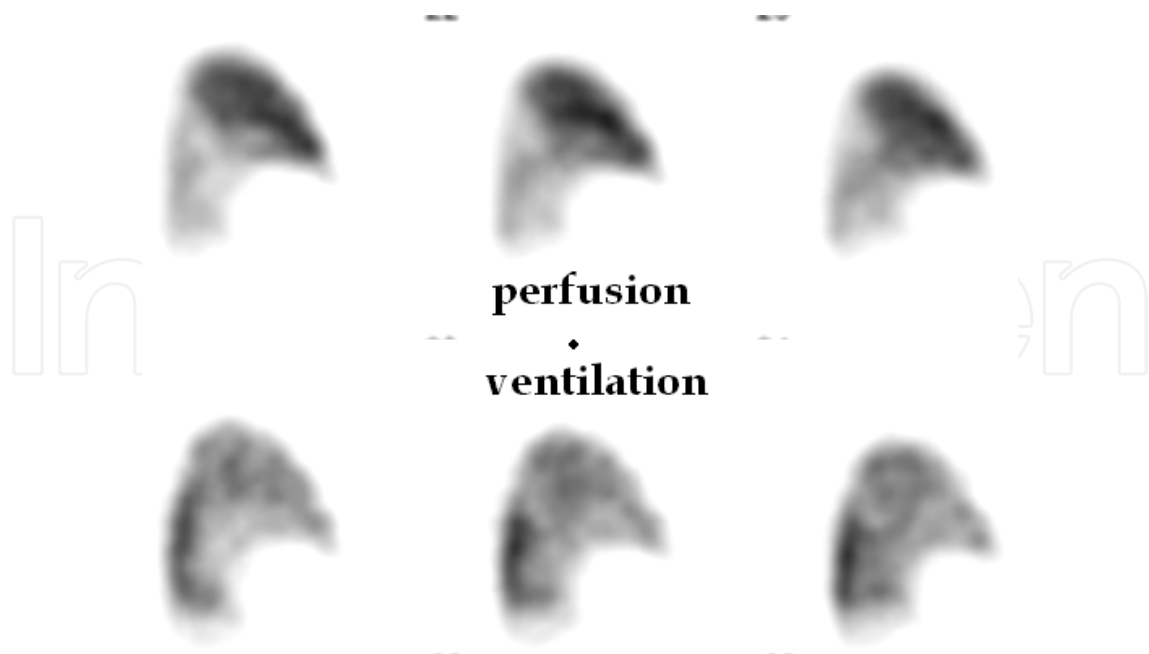


Fig. 18. Cardiac failure (volume overload). Note vascular redistribution to the super-anterior regions while normal gradient is preserved in ventilation.

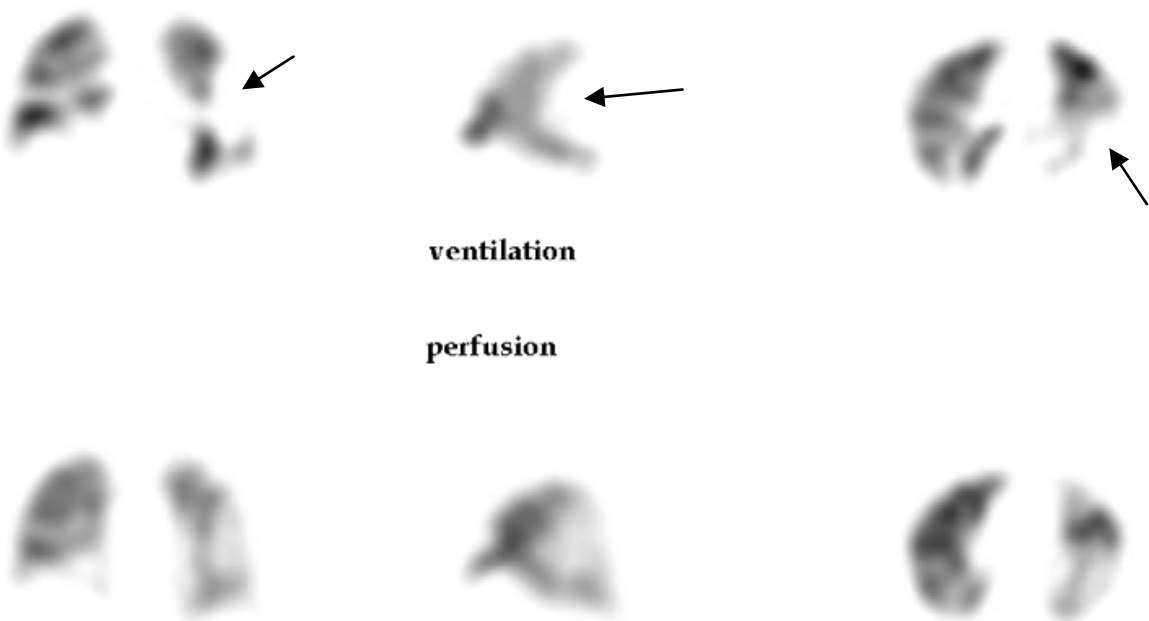


Fig. 19. Pneumonia (triangulation in coronal, sagittal and tranverse slices). Note the large trans-segmental defect. Absent ventilation with some partial residual perfusion.

6.4 Interstitial pneumonitis

Some recent work suggests that usual interstitial pneumonitis (UIP) can give rise to a rather specific pattern of sub pleural mismatch of crescent shape (Suga, Kawakami et al. 2009). The posterior surfaces of the lungs have to be excluded from the analysis however because in a supine position, this phenomenon is frequently observed because of gravity dependent atelectasis.

6.5 Pleural effusion

Pleural effusions of significant size are usually well recognized on V/Q SPECT. On transverse sections, the patient being in a supine position, the lung is displaced in the anterior direction as the effusion occupies the posterior region. On sagittal slices, there is loss of posterior angle. The perfusion and ventilation are typically matched although a thin band of hyperventilation is common at the lung-effusion interface because of compressed lung tissue. It is not uncommon however that the perfusion is better preserved. In that case, there is failure of the vasoconstriction reflex combined with lung compression which cannot be overcome by deep inspiration. For confident interpretation of a non-embolic effusion, there should not be any mismatches elsewhere and there should not be any hint of a wedge-shaped perfusion defect underlying the effusion (mismatched or not) (figures 20 and 21).

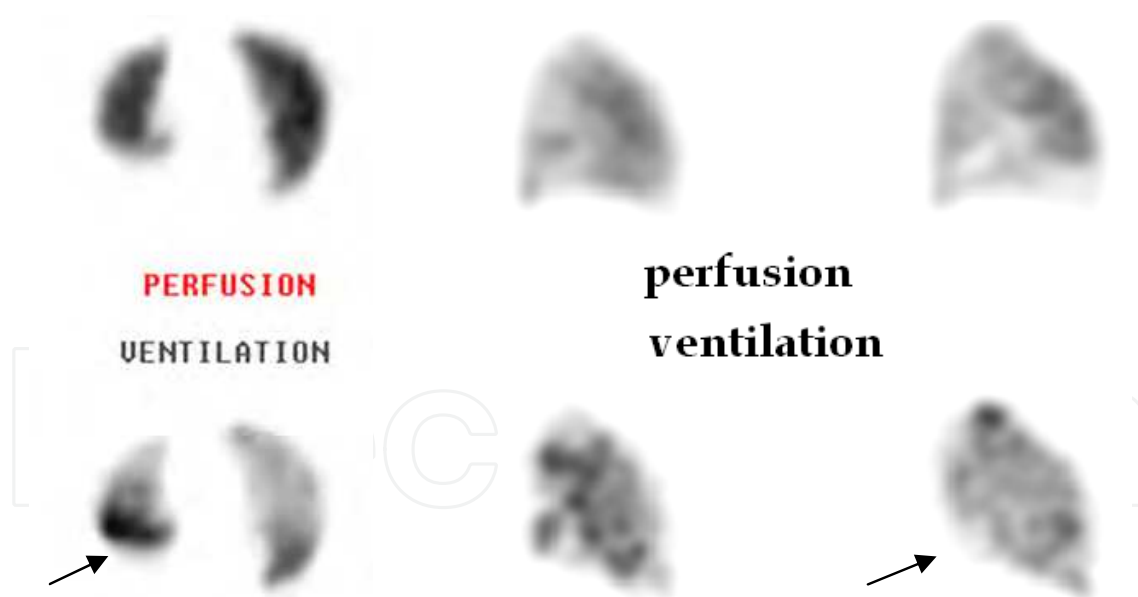


Fig. 20. Pleural effusion. Left: transverse slices show upward displacement of lung on both ventilation and perfusion, creating a non-segmental defect. Note band of hyperventilation indicating partially compressed lung. Right: sagittal slices in another patient show relatively preserved perfusion but absent ventilation. In this case, the effusion does not permit lung expansion.




Fig. 21. Pleural effusion caused by embolism (sagittal and transverse slices). Note upward displacement of right lung by the effusion with an underlying wedge shaped sub-segmental mismatched defect.

6.6 Reverse mismatches

In most physiological and pathological conditions, ventilation and perfusion are matched. This is accomplished by the pulmonary vasoconstriction reflex which diverts blood away from poorly ventilated areas to prevent a right to left shunt equivalent. Indeed, perfusion of non-ventilated areas causes non-oxygenated blood to return to the arterial circulation and this has a profound impact on the arterial oxygen pressure (figure 22). Failure of the vasoconstriction reflex is not an uncommon finding on V/Q SPECT imaging. It is often seen in the context of pneumonia (established or pre-radiological), atelectasis or bronchial mucous plug in COPD patients. It is important to report this finding as it represents an obvious cause to the patient's oxygen saturation problems. Reverse mismatch in the context of emboli is extremely uncommon as it requires causation of a ventilation anomaly which persists with reperfusion, without any other mismatches elsewhere. It is theoretically possible in the sub acute phase.

7. Validation of V/Q SPECT

7.1 Theoretical basis

SPECT has proven advantageous in just about every field in nuclear medicine. It is now standard procedure either as the sole examination (myocardial perfusion imaging and brain imaging) or a very useful adjunct to just about every other organ imaging (bone, gallium, white blood cell, liver, hemangioma, somatostatin). The theoretical advantages in lung imaging are the same as they are in every other organ: suppression of overlapping structures, better imaging contrast and 3-D representation of the data. Better depiction of sub-segmental and even some segmental defects is expected, resulting in better sensitivity.

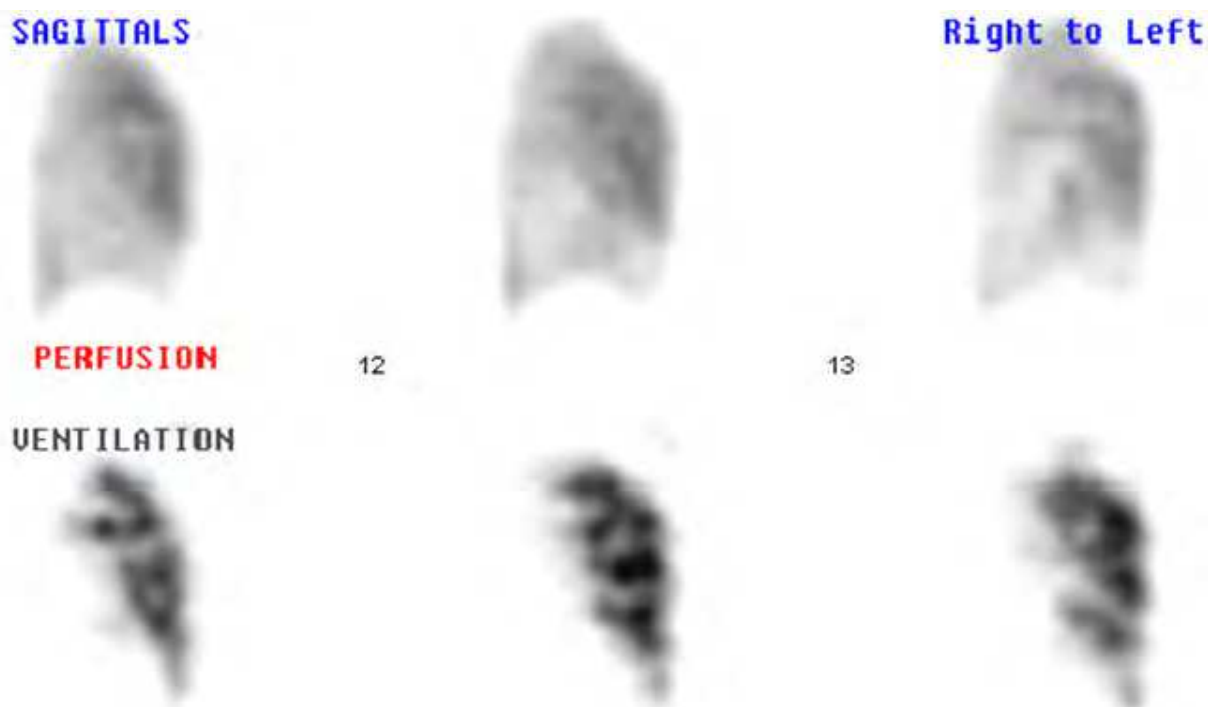

Fig. 22. Reverse mismatch. Sagittal slices show absent ventilation to inferior lobe with relative preservation of perfusion. In such a case, there is a huge amount of un-oxygenated blood returned to the arterial circulation, causing hypoxemia. In this case, a mucous plug in a COPD patient was the culprit.

Also, with 3-D data, the assignment of a defect to a vascular or non-vascular origin is much easier which will result in both better specificity and a much lower rate of indeterminate study.

7.2 Computer modeling

The superiority of V/Q SPECT (sensitivity 97%) to planar imaging (sensitivity 77%) was tested in a computer model which clearly predicted much better accuracy with V/Q SPECT (Magnussen, Chicco et al. 1999). It is very interesting to note that this model accurately predicted the results of clinical studies which would appear several years later.

7.3 Animal studies

The technique was also tested in a pig model with artificially produced small size emboli (Bajc, Bitzen et al. 2002). Again, the superiority of V/Q SPECT to planar imaging was clearly demonstrated, as sensitivity for V/Q SPECT was 91% while it was 64% for planar imaging for the same emboli. Specificity was also better for SPECT (87% vs 79%). It should be mentioned that a similar model had been employed earlier for validation of invasive pulmonary angiography and that the performance numbers in terms of

sensitivity and specificity were no better than that obtained with V/Q SPECT (Baile, King et al. 2000).

7.4 Validation with alternative perfusion techniques

New generation techniques to measure regional perfusion independently (by opposition to simply visualizing the artery and the thrombus) by means of perfusion thoracic CT (Wildberger, Klotz et al. 2005) or nuclear magnetic resonance (NMR) (Kluge, Gerriets et al. 2006) have correlated very well with V/Q SPECT measures of regional perfusion. Indeed, work with those techniques suggests that embolism is almost always totally occlusive and that inclusion of perfusion data enhances sensitivity over an approach based purely on luminology.

7.5 Clinical studies

It is beyond the scope of this chapter to review individually all studies. However, even if proof of superiority of V/Q SPECT to planar imaging seems redundant, it has been proven clinically, with V/Q SPECT having an edge in sensitivity of more than 20% while still maintaining better specificity (Gutte, Mortensen et al. 2010; Bajc, Olsson et al. 2004). The negative predictive value of V/Q SPECT (the ability to reliably exclude PE) has been validated and is excellent, in the order of 98-99%, even in the presence of abnormal perfusion with a nonvascular pattern (Leblanc, Leveillee et al. 2007). Sensitivity is in the range of 96-99% and specificity hovers between 85% and 98%, depending on the study. The rate of non-diagnostic studies is 1-3%. Comparison to CTPA is unfortunately limited because of the lack of a large-scale prospective study comparing both techniques. A detailed discussion on each of the available studies can be found elsewhere (Leblanc and Paul 2010). However, all published studies have demonstrated that V/Q SPECT performs at least as well as CTPA for the diagnosis of pulmonary embolism (Reinartz, Wildberger et al. 2004; Suga, Yasuhiko et al. 2008; Gutte, Mortensen et al. 2009; Miles, Rogers et al. 2009).

8. V/Q SPECT and CTPA: Relative advantages and limitations

8.1 Diagnostic performance

Although a large randomized prospective study comparing the two techniques is not available, the pooled published results suggest at this point that V/Q SPECT may have an edge in sensitivity while CTPA may have an edge on specificity. Better sensitivity of V/Q SPECT can be attributed essentially to sub-segmental embolism. Indeed, to visualize directly a thrombus in a sub-segmental vessel is difficult even with the latest CTPA technology. Also, existing literature suggest that inter-observer agreement is very low for sub-segmental embolism with CTPA (Ghanima, Nielsen et al. 2007). Since V/Q SPECT visualizes the resulting perfusion defect, it has a clear advantage. Indeed, even for a small sub-segmental defect implicating 25% of a segment, the pleural base of the defect will have at least 3 cm, a dimension easily resolved by the SPECT technique. On the other hand, since CTPA directly visualizes a filling defect, it is less prone to false positive studies since most (but not all) filling defects will represent embolus. This may not be true of sub-segmental emboli because the poor inter-observer agreement in this setting suggests limited specificity. Causes of false-positive mismatches on V/Q SPECT have

been discussed earlier. Causes of false-positive filling defect on CTPA do exist and have been discussed elsewhere (Kuriakose and Patel 2010). Indeterminate interpretation is usually low for CTPA and is generally related to technical factors. It is also very low for V/Q SPECT, occurring in less than 5% of cases in all published studies. Finally, different studies have proven that both techniques have a high negative predictive value (capacity to exclude) for PE (Leblanc, Leveillee et al. 2007).

8.2 Radiation dose

Estimated radiation dose is a complex subject and a detailed discussion is beyond the scope of this chapter and can be found elsewhere (Schembri, Miller et al. 2010). However, there is little doubt that when comparing state-of-the-art technology for both modalities, incurred radiation dose is much higher with CTPA and this is particularly true of the female breast. Depending on the exact protocol that is employed, total radiation dose for CTPA is in the range of 8-20 milliSievert (mSv) while it is 2,0 - 3,5 mSv for V/Q SPECT. The dose to the female breast varies between 10 and 70 mSv for CTPA (equivalent to 10-25 mammograms or 100-400 chest x-rays) while the corresponding breast dose for V/Q SPECT is less than 1,5 mSv.

8.3 Contraindications and technical success rate

There are no contraindications to V/Q SPECT imaging. Some degree of prudence is required in cases of severe pulmonary hypertension (the number of particle injected should be limited) and reasonable efforts should be made to limit the dose during pregnancy, but any patient may undergo V/Q SPECT as long as he can tolerate a supine position for 20 min. Allergies are virtually nonexistent. There are no known deleterious effects on any organ system.

On the other hand, CTPA has specific contraindications. Allergies are relatively frequent and, depending on the severity, constitute an absolute or relative contraindication. If the decision is made to proceed with the study, patients must be prepared appropriately. Also, because of the injection of contrast, renal failure is a possible complication especially in patients with established underlying renal disease. In some subgroups, the risk of renal failure requiring dialysis is extremely high.

Performance in pregnancy has also been reviewed (Ridge, McDermott et al. 2009). The radiation dose to the foetus is very low for both techniques (< 1mSv) although it is significantly lower for CTPA. However, at this level, there is no increased risk for either technique. On the other hand, it is clear that the technical performance of CTPA in pregnancy is poor, with as many as one third of the studies being technically inadequate. This is probably due to increased pressure in the inferior vena cava during pregnancy with aspiration of large amounts of non-opacified blood during inspiration that interferes with optimal mixing of contrast coming from the superior vena cava. There are no technical limits to V/Q SPECT during pregnancy. Therefore, V/Q SPECT should be the preferred modality in this situation, especially considering the very high breast radiation dose given with CTPA in young patients with actively proliferating breasts.

High-quality imaging with CTPA requires accurate timing for contrast injection. In most studies, the technical failure rate hovers between 5 and 10%. The technical success rate for

V/Q SPECT is extremely high, with failure occurring in less than 1% of cases in all studies. Using Technegas as a ventilation agent, it is possible to ventilate patients on mechanical ventilation.

8.4 Performance in difficult patients: COPD and abnormal x-ray

The presence of COPD is generally thought to decrease the usefulness of V/Q scanning. However, this stems from the use of a planar technique using an inferior ventilation agent (xenon-133) interpreted in probabilistic terms according to the PLOPED scheme. This is much less true with V/Q SPECT in which a superior ventilation agent is used (technegas) and determination of the nature of a vascular defect is much easier. In COPD, ventilation is often much more affected than perfusion and it is generally possible to distinguish vascular from nonvascular type defects following the definition outlined above for PE. Also, in COPD, emboli will always follow vascular flow which, by definition, always corresponds to residual ventilated areas, thus permitting the identification of a mismatch. However, in cases of very severe COPD where there are very few residual normally ventilated regions, interpretation may be more difficult and theoretically, sensitivity may be decreased. There are however no studies to prove this point.

There are no data suggesting that the performance of CTPA is altered by the presence of severe COPD. Therefore, in severe COPD, with a high pre-test likelihood of PE and with a V/Q SPECT difficult to interpret, CTPA may be warranted.

The presence of an abnormal lung x-ray causes special problems in nuclear imaging. Embolism detection is based on a mismatch between ventilation and perfusion. Ventilation is rarely possible in the presence of atelectasis, consolidations or marked infiltrate. Since embolism may create secondary atelectasis or lung infarcts, detection of PE on the basis of a mismatch may not be possible in that specific scenario. It must be stressed however that an x-ray anomaly does not preclude exclusion of PE by V/Q SPECT. Significant residual perfusion at the site of the chest x-ray anomaly or the presence of a nonvascular or non-pleural-based defect associated with the anomaly are reliable signs for the absence of PE. Also, PE is generally thought to be much more often multiple than single. Therefore, in most cases, you would expect identification of a mismatch away from the x-ray anomaly. Indeed, with the published data, using mismatching as the sole criteria for the presence of PE, the sensitivity of V/Q SPECT has been excellent. Nevertheless, there are no data on the incidence of solitary PE associated with a radiological anomaly. Therefore, if the anomaly has a vascular pattern on the perfusion study and the perfusion defect is complete, CTPA should be performed if the pre-test probability is significant. For lower pre-test probabilities, lower limb Doppler studies are probably sufficient. The presence of an x-ray anomaly is not thought to alter the capacity of CTPA to diagnose PE accurately. Altered sensitivity is unlikely since there are several studies confirming a high negative predictive value for CTPA. However, in the absence of a suitable gold standard, there is no data to evaluate the specificity of CTPA in that setting.

8.5 Chronic PE and follow-up studies

The sensitivity of CTPA for the detection of chronic pulmonary embolism has been proven to be poor, with a sensitivity of probably not much more than 50%. The sensitivity of V/Q SPECT for the detection of chronic PE is excellent, probably on the

order of 95% (Tunariu, Gibbs et al. 2007). Specificity is in the same range. Therefore, chronic PE cannot be reliably excluded by CTPA and V/Q SPECT should always be performed if this diagnosis is suspected. It is to be noted that in chronic PE, mismatches may not have the typical vascular shape it usually has in acute PE because of partial reperfusion.

From the previous discussion, it is obvious that follow-up studies using CTPA may be of limited value. Conversely, the evolution of the perfusion defects on serial V/Q SPECT is very easy to follow and resolution or persistence of perfusion anomalies is easily identified. Follow-up studies are very important in PE, especially for the larger embolic processes which are at risk for later pulmonary hypertension. Also, since there is a risk of relapse, follow-up studies need to be done to have a baseline to evaluate this dynamic process. Therefore, even if the initial diagnosis has been made by CTPA, an initial V/Q SPECT study is very valuable. Also, it should be pointed out that it seems difficult to justify the higher radiation dose and contrast agent of CTPA solely for follow-up purposes. There are of course some signs that permit distinction by CTPA of acute and chronic embolism but differentiation between the two conditions is far from being always easy (Castaner, Gallardo et al. 2009).

8.6 Alternate diagnosis

The capacity to provide an alternate explanation for the patient's symptoms is certainly one of CTPA's strong points. This subject has been recently reviewed extensively (Hall, Truitt et al. 2009). An alternate diagnosis for the symptoms (not previously known) can be expected in approximately 1/3 of patients undergoing CTPA for the exclusion of PE. However, a substantial number of those anomalies are also visualized on a chest x-ray and there is some concern that those that are not visualized on a standard x-ray may be of limited clinical consequence. However, for some alternate diagnosis (aortic dissection) CTPA is essential. Also, some tumours will obviously be visualized only on chest CT. As mentioned above, some diagnostic patterns other than PE can be recognized on V/Q SPECT. Early cardiac failure, identification of a large area of reverse mismatch and underestimation of the severity of COPD constitute the most frequent alternative explanations for the symptoms that are not apparent on a standard chest x-ray. Such alternate findings are frequent, occurring in nearly 40% of patients in one study (Bajc, Olsson et al. 2004). However, COPD is often known beforehand and the scope of potential diagnosis is narrower than with CTPA. It is to be noted that approximately 1/4 of patients undergoing CTPA will have incidental findings not related to the acute symptomatic episode that will require follow-up. Most of these findings are pulmonary nodules or thoracic adenopathy. The vast majority will prove benign on follow-up and thus, there is a potential for the generation of multiple follow-up studies with extra costs, extra radiation dose and significant concern for patients. Such incidental findings are inexistent for V/Q SPECT.

9. Future directions

Technical enhancements which are under study at this point for V/Q SPECT include respiratory gating, SPECT-CT technique and quantitative evaluation of ventilation perfusion ratio.

Respiratory gating takes advantage of the fact that image acquisition can be timed electronically with a device that identifies the patient's respiratory movements. This has the potential to create images of better quality, especially for the lung regions closer to the diaphragm where movement during acquisition causes some blurring. Better images have been confirmed in at least one study. Since the majority of emboli are in the lower lung fields, this enhancement may be significant for some patients (Suga, Yasuhiko et al. 2008).

In recent years, hybrid machines, called SPECT-CT, that combine a nuclear camera with a standard CT have become available. Those machines permit acquisition of physiological nuclear medicine data and anatomical CT images that can be perfectly registered. Therefore, physiological anomalies (in the case of lung imaging, ventilation or perfusion anomalies) can be mapped directly on the anatomical images. The potential of this technique is mainly to enhance the specificity of V/Q SPECT, as potential causes of false-positive imaging can be readily identified with this technique (Roach, Gradinscak et al. 2010). There is however the drawback of the higher radiation dose although most protocols will use a low-dose CT.

Quantitative evaluation of the ventilation and perfusion ratios has been the subject of physiological evaluation in normal patients but also in different pathological settings including embolism (Palmer, Bitzen et al. 2001). This type of evaluation has the potential to enhance reading accuracy in embolism, accurately quantify the volume of lung affected by the embolic process and to pinpoint patterns which may be indicative of other types of lung pathology (Suga, Kawakami et al.) (figures 23 to 25). Basically, relative matching of perfusion is illustrated by a color display to show areas of normal matching, mismatches (altered perfusion with preserved ventilation) and reverse mismatches (altered ventilation with preserved perfusion).

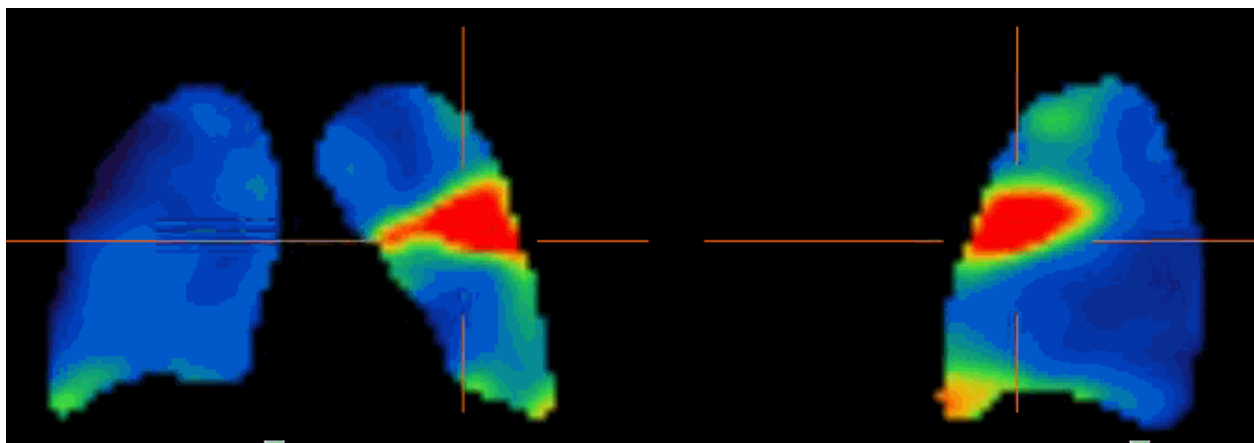


Fig. 23. V/Q quotient of embolism, coronal (left) and sagittal (right) slices. Red indicates the area of complete mismatch, while blue shows normally matched regions.

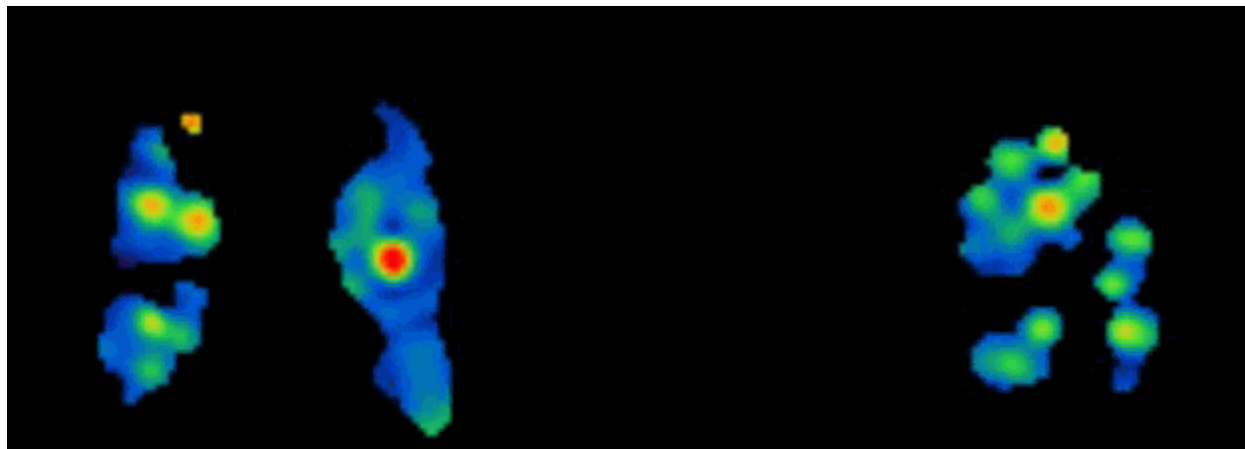


Fig. 24. V/Q quotient of severe COPD, coronal (left) and sagittal (right) slices. Black indicates reverse mismatched areas, green indicates partial mismatches while blue indicates normally matched areas. Widespread areas of non-matched perfusion and ventilation are typical of established COPD.

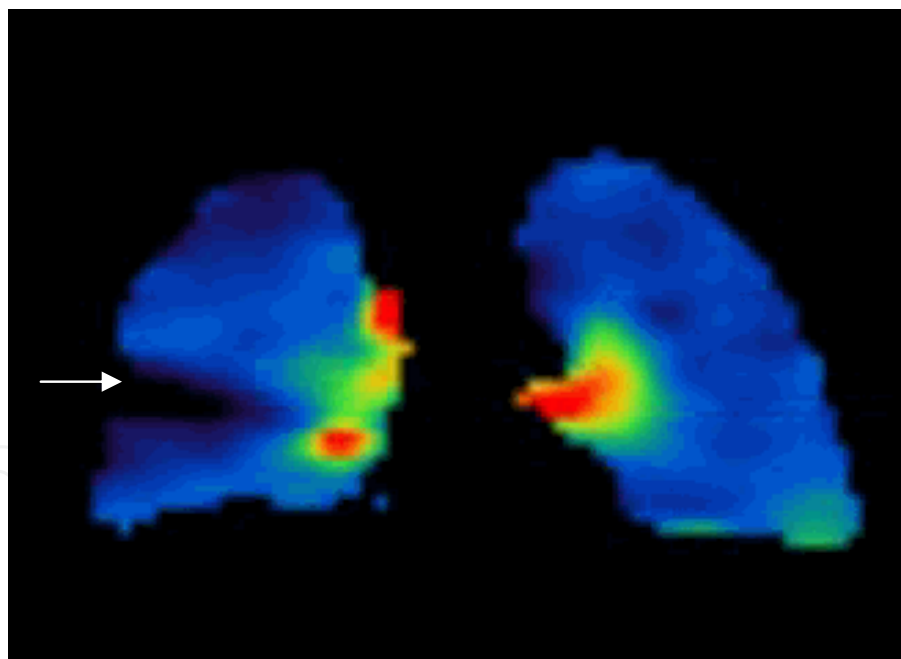


Fig. 25. V/Q quotient of pneumonia, coronal slice. Note wedge shaped area in black indicating reverse mismatch.

10. Role of V/Q SPECT in PE

Given the high sensitivity associated with a low indeterminate rate, absence of contraindications and low radiation dose, V/Q SPECT seems ideally suited to be the initial

screening test for PE in most clinical settings. It should be the test of choice in all cases with a clear chest x-ray (or minor alterations), and most probably in cases of X-rays with a single anomaly. It should be the test of choice in cases associated with pregnancy.

Consideration for CTPA as an initial test should be in cases of severe radiological anomalies or cases for which it is clear from the clinical presentation that a chest CT will be mandatory anyway (to exclude a non-embolic aetiology, when a chest X-ray is deemed insufficient). Cross over to the alternate technique (whether V/Q SPECT or CTPA was used first) should be considered for all equivocal cases and for cases with very strong disagreement between the imaging result and the clinical data. In those cases, lower limb Doppler studies may also be useful. For patients with moderate chest x-ray anomalies there is insufficient data for recommendations at this point but the performance of V/Q SPECT in that setting has been encouraging.

11. Conclusion

V/Q SPECT has proven its value in the setting of PE. It should totally replace planar V/Q scintigraphy in all settings, except in rare cases when a patient cannot tolerate supine imaging. It has significant advantages over CTPA in several common situations and its excellent sensitivity associated with a better safety profile and lower radiation dose makes it the ideal routine screening technique for PE.

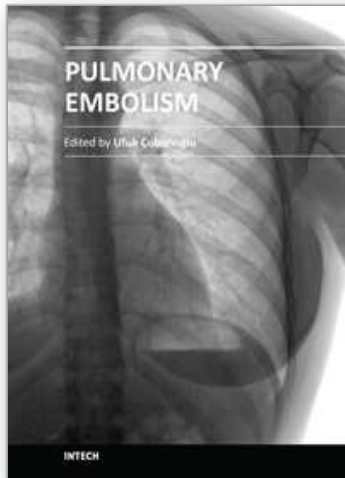
12. References

- Baile, E. M., King, G.G. et al. (2000). Spiral computed tomography is comparable to angiography for the diagnosis of pulmonary embolism. *American Journal of Respiratory and critical care medicine* 161(3 Pt 1): 1010-5
- Bajc, M., Bitzen, U. et al. (2002). Lung ventilation/perfusion SPECT in the artificially embolized pig. *Journal of Nuclear Medicine* 43(5): 640-7.
- Bajc, M., Neilly, J.B. et al. (2009). EANM guidelines for ventilation/perfusion scintigraphy : Part 1. Pulmonary imaging with ventilation/perfusion single photon emission tomography. *European Journal of Nuclear Medicine and Molecular Imaging* 36(8): 1356-70.
- Bajc, M., Olsson, C.G. et al. (2004). Diagnostic evaluation of planar and tomographic ventilation/perfusion lung images in patients with suspected pulmonary emboli. *Clinical Physiology and functional Imaging* 24(5): 249-56.
- Castaner, E., Gallardo, X. et al. (2009). CT diagnosis of chronic pulmonary thromboembolism. *Radiographics* 29(1): 31-50; discussion 50-3.
- Cook, G. and Clarke S.E. (1992). An evaluation of Technegas as a ventilation agent compared with krypton-81 m in the scintigraphic diagnosis of pulmonary embolism. *European Journal of Nuclear Medicine* 19(9): 770-4.
- Ghanima, W., Nielssen B.E., et al. (2007). Multidetector computed tomography (MDCT) in the diagnosis of pulmonary embolism: interobserver agreement among radiologists with varied levels of experience. *Acta Radiologica* 48(2): 165-70.
- Gutte, H., Mortensen, J. et al. (2009). Detection of pulmonary embolism with combined ventilation-perfusion SPECT and low-dose CT: head-to-head comparison with multidetector CT angiography. *Journal of Nuclear Medicine* 50(12): 1987-92.

- Gutte, H., Mortensen, J. et al. (2010). Comparison of V/Q SPECT and planar V/Q lung scintigraphy in diagnosing acute pulmonary embolism. *Nuclear Medicine Communications* 31(1): 82-6.
- Hall, W. B., Truitt, S.G. et al. (2009). The prevalence of clinically relevant incidental findings on chest computed tomographic angiograms ordered to diagnose pulmonary embolism. *Archives of Internal Medicine* 169(21): 1961-5.
- Kluge, A., Gerriets, T. et al. (2006). Pulmonary perfusion in acute pulmonary embolism: agreement of MRI and SPECT for lobar, segmental and subsegmental perfusion defects. *Acta Radiologica* 47(9): 933-40.
- Kuriakose, J. and Patel, S. (2010). Acute pulmonary embolism. *Radiologic Clinics of North America* 48(1): 31-50.
- Leblanc, M., Leveillee, F. et al. (2007). Prospective evaluation of the negative predictive value of V/Q SPECT using 99mTc-Technegas. *Nuclear Medicine Communications* 28(8): 667-72.
- Leblanc, M. and Paul, N. (2010). V/Q SPECT and computed tomographic pulmonary angiography. *Seminar of Nuclear Medicine* 40(6): 426-41.
- Magnussen, J. S., Chicco, P. et al. (1999). Single-photon emission tomography of a computerised model of pulmonary embolism. *European Journal of Nuclear Medicine* 26(11): 1430-8.
- Miles, S., Rogers, K.M. et al. (2009). A comparison of single-photon emission CT lung scintigraphy and CT pulmonary angiography for the diagnosis of pulmonary embolism. *Chest* 136(6): 1546-53.
- Palmer, J., Bitzen, U. et al. (2001). Comprehensive ventilation/perfusion SPECT. *Journal of Nuclear Medicine* 42(8): 1288-94.
- Peltier, P., De Faucal, P. et al. (1990). Comparison of technetium-99m aerosol and krypton-81m in ventilation studies for the diagnosis of pulmonary embolism. *Nuclear Medicine Communications* 11(9): 631-8.
- Reinartz, P., Wildberger, J.E. et al. (2004). Tomographic imaging in the diagnosis of pulmonary embolism: a comparison between V/Q lung scintigraphy in SPECT technique and multislice spiral CT. *Journal of Nuclear Medicine* 45(9): 1501-8.
- Ridge, C. A., McDermott, S. et al. (2009). Pulmonary embolism in pregnancy: comparison of pulmonary CT angiography and lung scintigraphy. *American Journal of Roentgenology* 193(5): 1223-7.
- Roach, P. J., Gradinscak, D.J. et al. (2010). SPECT/CT in V/Q scanning. *Seminar of Nuclear Medicine* 40(6): 455-66.
- Schembri, G. P., Miller, A. E. et al. (2010). Radiation dosimetry and safety issues in the investigation of pulmonary embolism. *Seminar of Nuclear Medicine* 40(6): 442-54.
- Suga, K., Kawakami, Y. et al. (2010). Lung ventilation-perfusion imbalance in pulmonary emphysema: assessment with automated V/Q quotient SPECT. *Annals of Nuclear Medicine* 24(4): 269-77.
- Suga, K., Kawakami, Y. et al. (2009). Characteristic crescentic subpleural lung zones with high ventilation (V)/perfusion (Q) ratios in interstitial pneumonia on V/Q quotient SPECT. *Nuclear Medicine Communications* 30(11): 881-9.

- Suga, K., Yasuhiko, K. et al. (2008). Relation between lung perfusion defects and intravascular clots in acute pulmonary thromboembolism: assessment with breath-hold SPECT-CT pulmonary angiography fusion images. *European Journal of Radiology* 67(3): 472-80.
- Tunariu, N., Gibbs, S.J. et al. (2007). Ventilation-perfusion scintigraphy is more sensitive than multidetector CTPA in detecting chronic thromboembolic pulmonary disease as a treatable cause of pulmonary hypertension. *Journal of Nuclear Medicine* 48(5): 680-4.
- Wildberger, J. E., Klotz, E. et al. (2005). Multislice computed tomography perfusion imaging for visualization of acute pulmonary embolism: animal experience. *European Radiology* 15(7): 1378-86.
- Jögi, J., Jonson B., et al. (2010). Ventilation-perfusion SPECT with ^{99m}Tc-DTPA versus Technegas: a head-to-head study in obstructive and nonobstructive disease. *Journal of Nuclear Medicine* 51(5): 735-741

IntechOpen



Pulmonary Embolism

Edited by Dr. Ufuk Çobanoğlu

ISBN 978-953-51-0233-5

Hard cover, 236 pages

Publisher InTech

Published online 14, March, 2012

Published in print edition March, 2012

Pulmonary embolism is a serious, potentially life-threatening cardiopulmonary disease that occurs due to partial or total obstruction of the pulmonary arterial bed. Recently, new improvement occurred in the diagnosis and treatment of the disease. The aim of this disease is to re-review pulmonary embolism in the light of new developments. In this book, in addition to risk factors causing pulmonary embolus, a guide for systematic approaches to lead the risk stratification for decision making is also presented. In order to provide a maximum length of active life and continuation of functional abilities as the aim of new interventional gerontology, the risk factors causing pulmonary embolus in elderly individuals are evaluated, and the approach to prevention and treatment are defined. The risk of the development of deep vein thrombosis and pulmonary embolism, combined with obesity due to immobility, the disease of this era, irregular and excessive eating, and treatment management are highlighted. Non-thrombotic pulmonary emboli are also covered and an attempt is made to constitute an awareness of this picture that can change the treatment and prognosis of the disease to a considerable extent. In addition to the pathophysiological definition of pulmonary embolus, the priority goal of quick and definitive diagnosis is emphasized, and diagnostic strategies are discussed in the book. A numerical analysis of the vena cava filters, which is a current approach to prevent pulmonary emboli recurrences, is presented in the last chapter.

How to reference

In order to correctly reference this scholarly work, feel free to copy and paste the following:

Michel Leblanc (2012). Ventilation Perfusion Single Photon Emission Tomography (V/Q SPECT) in the Diagnosis of Pulmonary Embolism, *Pulmonary Embolism*, Dr. Ufuk Çobanoğlu (Ed.), ISBN: 978-953-51-0233-5, InTech, Available from: <http://www.intechopen.com/books/pulmonary-embolism/v-q-spect-in-the-diagnosis-of-pulmonary-embolism>

INTECH
open science | open minds

InTech Europe

University Campus STeP Ri
Slavka Krautzeka 83/A
51000 Rijeka, Croatia
Phone: +385 (51) 770 447
Fax: +385 (51) 686 166

InTech China

Unit 405, Office Block, Hotel Equatorial Shanghai
No.65, Yan An Road (West), Shanghai, 200040, China
中国上海市延安西路65号上海国际贵都大饭店办公楼405单元
Phone: +86-21-62489820
Fax: +86-21-62489821

www.intechopen.com

www.intechopen.com

IntechOpen

IntechOpen

© 2012 The Author(s). Licensee IntechOpen. This is an open access article distributed under the terms of the [Creative Commons Attribution 3.0 License](#), which permits unrestricted use, distribution, and reproduction in any medium, provided the original work is properly cited.

IntechOpen

IntechOpen