

We are IntechOpen, the world's leading publisher of Open Access books Built by scientists, for scientists

4,800

Open access books available

122,000

International authors and editors

135M

Downloads

Our authors are among the

154

Countries delivered to

TOP 1%

most cited scientists

12.2%

Contributors from top 500 universities



WEB OF SCIENCE™

Selection of our books indexed in the Book Citation Index
in Web of Science™ Core Collection (BKCI)

Interested in publishing with us?
Contact book.department@intechopen.com

Numbers displayed above are based on latest data collected.

For more information visit www.intechopen.com



Secondary Caries

Guang-yun Lai¹ and Ming-yu Li²

¹*Department of Restorative Dentistry and Periodontology,
Ludwig-Maximilians-University, Munich,*

²*Shanghai Key Laboratory of Stomatology, Shanghai Research Institute of Stomatology,
Ninth People's Hospital, Medical College, Shanghai Jiao Tong University, Shanghai,*

¹*Germany*

²*P.R. China*

1. Introduction

Secondary caries, the lesion at the margin of a restoration, has been widely considered as the most important and common reason for restoration replacement, regardless of the restorative material type [Collins et al., 1998; Dahl and Eriksen, 1978; Deligeorgi et al., 2001; Friedl et al., 1995; Mjör, 2005; Mjör and Toffenetti, 2000;]. As it develops after the initial caries has been removed and replaced by a restoration, 'secondary caries', which is often referred to as 'recurrent caries' by practitioners in North America, is used more commonly in Europe [Mjör, 2005]. The Fédération Dentaire Internationale defined secondary caries as a 'positively diagnosed carious lesion, which occurs at the margins of an existing restoration' [Fédération Dentaire Internationale, 1962]. Then two kinds of lesion may exist adjacent to the restorations: secondary caries and residual caries (remaining caries). The latter one is residual demineralized tissue left, due to the failure of eliminating all infected dentine or/and enamel during the cavity preparation. Therefore it is very difficult for clinicians to make an accurate diagnosis of secondary caries and provide a clear terminology. Nowadays it is generally acknowledged that secondary caries or recurrent caries is a primary carious lesion of tooth at the margin of an existing restoration, which occurs after the restoration has been used for some time [Mjör and Toffenetti, 2000].

Due to its importance to the longevity of the restorations and human oral health, over the past few decades, multiple of studies have been conducted both in vivo and in vitro to understand and prevent secondary caries, including the etiology and histopathology of secondary caries, the detective and diagnostic methods of secondary caries, the relationship between microleakage and secondary caries, as well as the cariostatic effects of various restorative materials. The purpose of this chapter is to present a systematic and brief review of secondary caries in order to draw people's attention to this common but also complicated dental disease.

2. Diagnosis of secondary caries

2.1 Histology of secondary caries

In the 1970s, Hals et al. did a comprehensive investigation of the secondary caries lesions around various restorative materials both in vitro and in vivo, and natural secondary caries

on the extracted restored human teeth [Hals, 1975a, 1975b; Hals et al., 1974; Hals and Nernaes, 1971; Hals and Norderval, 1973; Hals and Simonsen1972]. According to their studies, whatever the restorative material type is, the secondary carious lesion displayed histologically the same basic pattern (Fig. 1): 1) an outer lesion, which is caused by the a new primary attack on the outer surface of the tooth; 2) a wall lesion, might be the consequence of the diffusion of bacteria, fluids or hydrogen ions between the restorations and the cavity wall. It is also supposed in their study that the fluoride released from the silicate material would be taken by both the cavity wall and the tooth surface around the restoration, which might reduce glycolysis and induce the remineralization [Hals, 1975a]. Thus, the individual caries patterns between the teeth with silicate materials and amalgam are different more or less. However, this described pattern of secondary caries including the outer lesion and wall lesion has been confirmed in later experiments [Diercke et al., 2009; Thomas et al., 2007; Totiam et al., 2007].

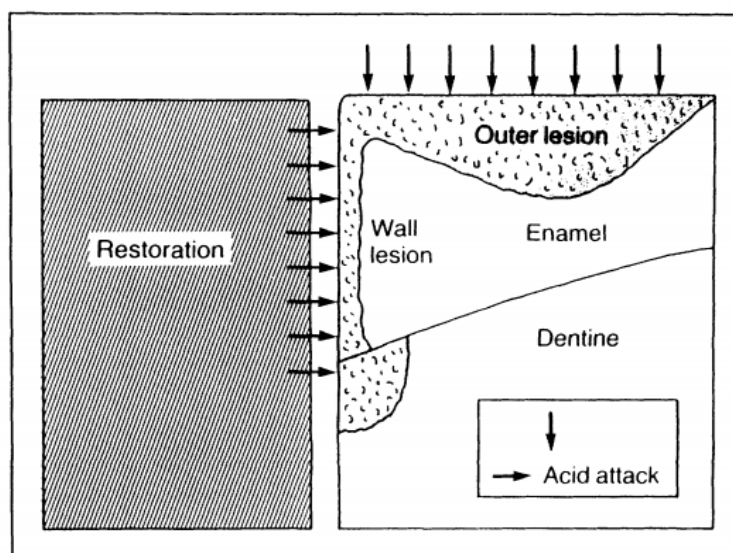


Fig. 1. A diagrammatic representation of secondary caries

The secondary caries lesion may occur in two parts: an outer lesion, formed on the surface of the tooth as a result of primary attack and a wall lesion formed as a result of diffusion of bacteria, fluids or hydrogen ions between the restorations and the cavity wall (From Kidd, 1990).

2.2 Frequency and location of diagnosed secondary caries

Since the early days of restorative dentistry, the phenomenon of secondary caries has been known and considered as the basis for the extension-for-prevention concept, the well-known principles of cavity preparation established by G.V. Black in the last century [Black, 1908]. The clinical diagnosed secondary caries has been shown to be principal cause for the replacement of all types of restorations both in permanent and primary teeth, 50%-60% of restorations are replaced as a result of the diagnosis of secondary caries [Mjör and Toffenetti, 2000]. As the development of restorative materials, some literatures regarding secondary caries indicated that the prevalence of secondary caries is associated with the restorative material type, although it may occur with all restorative materials [Burke et al.,

1999b; Forss and Widström E, 2004; Mjör, 1997; Mjör and Jokstadt, 1993]. Some published researches showed that compared to amalgam restorations, resin-based composite restorations represented a higher percentage of replacement because of the diagnosed secondary caries [Mjör and Jokstadt, 1993; Bernardo et al., 2007]. On the contrary, others reported that the amalgam was replaced because of the secondary caries more often than composite resin [Wilson et al., 1997; Burke et al., 1999a]. Compared with those studies, which acclaimed that a large proportion of restorations replaced as a result of diagnosis of secondary caries in general dental practice, one controlled clinical trials showed secondary caries represented in less than 1 percent of the restoration failures [Letzel et al., 1989], inversely, another controlled clinical trials by Bernardo et al. reported that secondary caries accounted for 66.7 percent and 87.6 percent of the failures that occurred in amalgam and composite restorations, respectively [Bernardo et al., 2007]. These controversies might be explained that the statistic results could be influenced by many factors, including the age of the population, the status of patients' oral health and dental care, examiner calibration and the duration of the experiment, etc.

Secondary caries, like other dental caries, is initially caused by the activities of microorganisms in dental plaque, so it is possible for any site on the restored teeth where is prone to the bacterial stagnation to develop secondary caries. General practitioners indicated that secondary caries was detected predominately on the gingival margins of Class II and Class I restorations, while seldom on the Class I restorations and the occlusal part of Class II restorations [Mjör, 1998; Mjör and Qvist, 1997]. A number of factors contribute to the more frequent occurrence of secondary caries on the gingival surface. First of all, the gingival aspect of any restorations is more difficult for patient to keep plaque free than any other parts, especially if it is located interproximally, while the occlusal surface is not a generally a plaque stagnation area and toothbrushing can easily reach this area to clean the plaque [Kidd, 2001; Mjör, 2005]. Secondly, during the restorative operation, the gingival surface is prone to contamination by gingival fluid and saliva, which causes the impossible visual inspection of the gingival floor and the deficiencies of insertion of restorative materials. And these deficiencies may lead to secondary caries more easily [Mjör, 2005]. Meanwhile, the less effective bonding of resin composite and the polymerization shrinkage at the gingival cavosurface may also influence the integrity of restoration at the gingival section and result in the development of secondary caries [Mjör, 2005].

2.3 The specific diagnostic problem and the diagnostic methods

As it was described above, while secondary caries accounts for more than half of replacing restorations regardless of the different materials in the general practice, around 50 percent, this high prevalence is not found in one controlled clinical trial in which only 2 among 2660 Class I or II restorations were replaced due to secondary caries [Letzel et al., 1989]. On the contrary, in another randomized controlled clinical trial 66.7% and 87.6% of the failures that occurred in amalgam and composite restorations because of the diagnosed secondary caries, respectively [Bernardo et al., 2007]. Are they correct or wrong? Why are there are huge differences between these studies? Are the practitioners involved in these studies poorly trained or ignorant about the criteria of secondary caries diagnosis? Indeed, until now it is very difficult to explain the above questions reasonably, however, except the variation between those studies themselves, it should be acknowledged that there are some specific

diagnostic problems for secondary caries and it is very crucial to understand secondary caries correctly in order to make an accurate diagnosis.

In 1990 Kidd pointed out that there are several main specific diagnostic problems for secondary caries, including the difficulty of detecting the wall lesion; the relevance of a defective margin (e.g. ditched margin) to the longevity of a restoration and the difficulty of distinguishing secondary from residual caries [Kidd, 1990]. It is suggested that only frankly caries lesion at the margin of the restoration constitutes a dependable diagnosis of secondary caries [Kidd and Bieghton, 1996], whereas it is impossible to detect or see the wall lesion until it is so advanced that the overlying tissue collapses to reveal a large hole or the tooth tissue over it becomes grossly discoloured [Kidd, 1990]. Consequently, dentists often cannot detect or diagnose a secondary caries when a wall lesion is in progress under a sound surface.

Traditionally, the presence of clinically detectable defects in restoration margins has been associated with an increased risk of secondary caries occurring beneath such restorations [Hewlett et al., 1993]. Besides, marginal defects present between a restoration and the cavity wall, such as those occur in occlusal pits and fissures, may act as gathering points for bacterial plaque [Pimenta et al., 1995]. Surveys in which dental practitioners determine reasons for replacing restoration indicate that clinical evidence of defective margins is a commonly used criterion for replacing restorations [Boyd and Richardson, 1985; Qvist et al., 1986]. On the other hand, other studies showed the low relevance of defective margin to restoration replacement and secondary caries which supported the conclusion that the defective margin only can not be the reason to replace a restoration. Söderholm et al. suggested that the use of defected margin as the criterion for restoration replacement would have resulted in the unnecessary treatment of 34% of the teeth examined [Söderholm, 1989]. Kidd and O'Hara reported that caries incidence on the cavity wall adjacent to the margins was the same for both in the intact and defective restoration [Kidd and O'Hara, 1990]. Although, Hewlett et al. found the likelihood of radiographic secondary caries was much higher for defective restorations than for intact restorations through the investigation of radiographic secondary caries prevalence in 6285 teeth clinically defective restorations, it was still suggested that defective restoration status should be combined with radiographic examination [Hewlett et al., 1993]. Therefore, the presence of ditched margins where are plaque stagnation areas which might enhance the prevalence of secondary caries development, however, is not a sufficient factor to determine a possible process of secondary caries formation [Pimenta et al., 1995]. Furthermore, the progression of caries is determined by the dynamic balance between pathological factors that lead to demineralization and protective factors that lead to remineralization. If either the pathological factors are not sufficient or protective factor are present, caries will not develop regardless of tooth morphology [Featherstone, 2004].

According to the definition, secondary caries is a new primary caries and should be differentiated from residual caries. In the past, on the basis of the extension-for-prevention concept, the cavity preparation principles established by G.V. Black, students were taught to prepare the cavity as clean as possible. Nowadays, as the development of conservative dentistry and minimal intervention dentistry and remineralization, it is recommended that dentists should distinguish the affected tissue which could be healed by remineralization and infected tissue, only infected should be removed to preserve more dental tissue and

increase the longevity of the teeth [Fusayama, 1988; Kidd, 2010; Massler, 1967;]. However, it is impossible to predict whether these residual lesions will progress. Thus, it is thought-provoking that the modern dentistry might increase the difficulty of distinguishing the secondary and residual caries. Or it might not be so important to differentiate the secondary and residual caries.

To diagnose the carious lesion, either primary or secondary, the dentists need good lighting, clean teeth, sharp eyes and even good bitewing radiography [kidd, 1984]. Secondary caries develops more frequently at the cervical and interproximal margins [Mjör, 1985; Mjör, 2005], more attention must be paid to find better methods or techniques to detect the secondary caries, despite of those difficulties to make an accurate diagnosis of secondary caries. The conventional visual and tactile methods using a sharp explorer have been advocated in the diagnosis of primary and secondary caries [kidd, 1990]. However, in recent years it has been shown that the sharp explorer seems to be an unwise instrument to detect secondary caries. On one hand, a sharp explorer could cause cavitation of an outer lesion, damage the margin of a restoration, or even become impacted in a marginal discrepancy which might then be misinterpreted as a carious lesion [Bergman and Lindén, 1969; Ekstrand et al, 1987]. On the other hand, wall lesions of secondary caries can not easily be detected until they have reached an advanced stage [Kidd, 1990], it is very difficult for explorer to contact the lesion and detect it at the early stage. And it is important to keep in mind that a sharp explorer will stick in any crevice, regardless of whether there is carious lesion [Mjör, 2005]. Additionally, discoloration around dental restorations may be due to the variety of factors such as the physical presence of amalgam, corrosion products, or secondary caries. It could be concluded that colors or stains next to restorations are not always predictive of secondary caries and not useful for the detection of secondary caries [kidd et al., 1995, Rudolph, 1995], whereas, it is very difficult to distinguish whether the discoloration originated from the restoration or was due to the demineralization [Ando et al., 2004]. Until now, besides the most common and traditional method of visual examination with a tactile instrument, there are some several other methods available to measure the mineral loss, such as microradiograph [Arends et al., 1987] and CLSM (confocal laser scanning microscopy), which measures the fluorescence area to determine the secondary caries [Fontana et al., 1996]. It is reported that QLF (light-induced fluorescence) might be a suitable technique for detection of early secondary carious lesions less than 400 μ m meanwhile LF (infrared laser fluorescence) might be a suitable technique for the detection of secondary caries, especially for lesions over 400 μ m or dentinal lesions [Ando et al., 2004].

3. Etiology of secondary caries

3.1 Microbiology of secondary caries

Dental caries is determined by the dynamic balance between pathological factors that lead to demineralization and protective factors that lead to remineralization [Featherstone, 2004]. As a major pathological factor, oral bacteria, especially acidogenic bacteria, can dissolve the tooth mineral. Those acidogenic bacteria are also aciduric and can live preferentially under acid conditions [Loesche, 1986].

Hitherto, it is unclear about the microbiology of secondary caries yet. Although secondary caries is described alike primary caries in histopathology, whether the etiology of secondary caries is the same as that of primary caries is a matter in dispute. Kidd et al. found no

significant differences between the microflora in samples from cavity walls involving primary and secondary caries next to the amalgam [Kidd et al., 1993]. However, Thomas et al. investigated bacterial composition in relation to primary and secondary caries via an in situ model, and found a phenomenon of higher proportion of caries-associated bacteria on composite surfaces. Then they indicated that the microbiology on the surface of the primary caries differs from that on the surface of lesion around composite, and secondary caries around composite may differ from the primary lesions process [Thomas et al., 2008]. In addition, some studies focused on the ecology under the restorations. Mejàre et al. found the bacterial colonization beneath composite similar to that observed in dental plaque mainly including Streptococci and Actinomyces spp. [Mejàre et al., 1979]. Nevertheless, according to the experiment conducted by Splieth et al., it was the other way around [Splieth et al., 2003]. They compared the microbial spectrum under composite and amalgam fillings with special attention to the anaerobic flora. The results showed that bacterial composition under amalgam was similar to the flora of carious dentin and carious plaque, with anaerobic and facultative anaerobic gram-positive rods dominating. On the contrary, huge amounts of Bacteroides and Prevotella spp. were detected under many composite fillings, similar to the microflora of infected root canals with potentially pulpopathogenic microbes. Thus, the study suggested that the types of restorative materials seemed to have an effect on the composition of the microflora on the surface of secondary caries, and that beneath the restorations, and then the differences might exist between the microbial flora of secondary caries and primary caries. In this study, it was indicated that inadequate composite fillings might stimulate the growth of cariogenic as well as obligate anaerobic and potentially pulpopathogenic bacteria. This could be explained as follows: 1) The microspace between the restoration and the cavity floor favors the obligate anaerobic, and then leads to the detection of those bacteria; 2) It is not surprising to discover many obligate anaerobic normally colonize in human oral, even in oral of people without obvious endodontic diseases. 3) It doesn't mean that people without clinical symptoms of toothaches or pulpitis don't have chronic or arrested tooth diseases, so it is possible to detect those anaerobic bacteria. However, existence does not mean participation, so it is necessary to certify the participation of those obligate anaerobic in the progress of secondary caries in further studies.

According to the viewpoint of Marsh that any species with the ability producing acids and tolerating the cariogenic environment can contribute to the dental caries process [Marsh, 2006]. *Streptococci mutans* (*S. mutans*), *Lactobacilli* and *Actinomyces naeslundii* have been used by various models in vitro studying secondary caries for a long time. *S. mutans* and lactobacilli can produce a series of acid and stay in a low pH environment for a long time, leading to demineralization of teeth and caries lesion. It has been shown that the three bacteria were widely present and might play an important role in the development of secondary caries around amalgam [González-Cabezas, 1999]. However, in a recent in situ study, *S. mutans* were not detected in each sample, but *Lactobacilli*. Meanwhile, *A. Odontolyticus* and *Candida spp.* were also found in most samples [Thomas et al., 2008]. In addition, in recent years, Beighton put forward a point of view — *S. mutans* might be good makers of secondary caries but not necessarily the etiological agents [Beighton, 2005]. The experiment by Thomas et al. described before, in which *S. mutans* was not found in every sample, but *Lactobacilli* and *A. Odontolyticus*, seemed to support Beighton's view. And scientists conjectured that there might be unknown caries-associated bacteria, which can not

grow on blood agar [Thomas et al., 2008]. In the past decade, the detection of *A. Odontolyticus* and *Candida spp.* has caused the serious concern to researchers. It has been found that *Candida albicans* can dissolve hydroxyapatite in a liquid culture at a 20-fold higher rate than *S. mutants*, despite the much lower growth rate [Nikawa et al., 2003]. Klinke et al. assumed that *Candida albicans* might make a significant contribution to caries pathogenesis in caries-active children, and it could be taken into account *Candida albicans* as an appraisal of caries pathogenicity [Klinke et al, 2009]. Besides, it should be noted that some people may have serious caries activities without *S. mutants* dominating in dental plaque. Therefore, further research need to be carried out to determine the microbiology of secondary caries, such as the role of *S. mutants*, *A. Odontolyticus* and *Candida spp.* in the development of secondary caries and the relationship between restorations and microorganism of secondary caries.

3.2 The relevance of microleakage to secondary caries

Microleakage refers to the clinically undetectable leakage between the cavity wall and the filling [Kidd, 1976]. Irie et al. found that a gap of 6-10 μ m formed immediately even after applying an acid etch and a bonding agent [Irie et al., 2002]. Iwami et al. have confirmed that any restorative material can completely eliminate the microleakage between restoration and the cavity wall [Iwami et al., 2005], supported by other researches [Irie and Suzuki, 1999; Huang et al., 2002; Piwowarczyk et al, 2005]. A study in vitro showed that there was no significant difference in the degree of microleakage between conventional caries removal and chemo-mechanical removal [Mousavinenasab and Jafary, 2004]. Those above all show us that microleakage is inevitable.

The microspace between the restoration wall and tooth can allow salivary pellicle accumulation and bacterial invasion [González-Cabezas et al., 1999; González-Cabezas et al., 2002; Splieth et al., 2003]. In a sense, it provides a favorable environment for the oral bacteria, especially cariogenic bacteria, such as *S. mutants* and *Lacotobacilli*, to demineralize the tooth structure along the cavity wall, as long as conditions are adequate and suitable. The histopathological appearance of the wall lesion in the secondary caries is also explained by hydrogen ions due to the diffusion of bacteria into the space between restoration and cavity wall and its acidiogenic activities afterwards [Hals and Nernaes, 1971]. So microleakage has been considered as a potential predictor for secondary caries and has caused serious concern to many researchers. In some article, the wall lesion was described as the consequence of microleakge [Diercke et al., 2009].

Up to now, there has been no conclusive statement about the relationship between microleakage and secondary caries. Several studies in vitro have shown a positive relationship between the two things. Jørgensen and Wakumoto in a 1968 research found that there was an increasing likelihood of secondary caries with the increasing size of the microspace [Jørgensen and Wakumoto, 1968], which is in agreement with that reported by some other researches [Goldbeg et al., 1981; Dérand et al., 1991]. In a recent in vitro study on relationship of gap size and secondary caries, the findings suggested that the gap size between tooth and restoration affected the development of secondary caries along the cavity wall [Totiam et al., 2007], for which the rationale was that bigger gaps would provide necessary space for bacterial colonization and enough nutrients for cariogenic microorganisms leading to the creation of larger wall lesions. On the other hand, within

smaller spaces, minerals dissolved from the tooth structure due to the acid attacks would supersaturate the space immediately and create the remineralization of tooth tissue and smaller wall lesions.

In contrast, other studies have not stated any association between gap presence and secondary caries [Kidd and O'Hara, 1990; Pimenta et al., 1995]. Some suggested that there was no caries lesion along the cavity wall, unless large voids or gaps of $\geq 250\mu\text{m}$ [Ozer and Thylstrup, 1995] or even $\geq 400\mu\text{m}$ [Kidd et al., 1995]. Jørgensen and Wakumoto found poor correlation between the two only when gaps was $\geq 50\mu\text{m}$ [Jørgensen and Wakumoto, 1968]. Thomas et al. found no clear caries along the cavity wall next to composite, but to acrylic resin through an in situ study [Thomas et al., 2007]. Besides, observed cracks in teeth might be the best clinical evidence for microleakage does not lead to dental caries. These cracks and the adjacent areas can be stained over time, however, there is no caries development. The stained component is considered to be the proteinaceous material in the crack or crevice, and similar in composition to that of the biofilm which normally covers all teeth and restorations [Mjör, 2005].

Recently, a few studies have been conducted concerning the relationship between gap size and secondary caries in the presence or absence of fluoride. Cenci et al. in 2008 suggested that microleakage did not seem to influence secondary caries while the presence of fluoride in the plaque like biofilm (PLB) provided either by glass ionomer cement (GIC) or fluoride dentifrice (FD) [Cenci et al., 2008]. In 2009, Cenci et al. demonstrated that carious lesion depth increased with gap size for composite resin (CR) and suggested that the gap width affected secondary caries formation at the cavity wall, but only in the absence of fluoride released from fluoride-containing materials, such as GIC [Cenci et al., 2009]. Thus, these findings give implications for clinical caries treatment choices and further studies in vivo or clinical experiments are needed to investigate the relationship between the gap size, fluoride presence and secondary caries.

In sum, up to the present, there is no specific conclusion on the relationship between microleakage and secondary caries, specially the wall lesion of the cavity. The possible reasons are as follows: 1) Oral cavity is such an extremely complex that it is impossible to simulate completely, so the research results may be not all-inclusive. 2) Secondary caries is caused by various factors, so it might be difficult for researchers to consider fully when designing their experiments. Thus, in consequence, different experiments bring out different results, and sometimes those results are even conflicting. 3) For individual differences, people have varying degrees of susceptibility to caries. Therefore, different clinical studies may lead to different results and conclusions. 4) Some clinical studies may lack reasonable designs, which lead to incomprehensive results. However, there is a consensus that microleakage is indeed associated with secondary caries due to the existence of bacteria. It seems that microleakage is just a necessary but not a sufficient condition for the formation of a wall lesion [Kidd et al., 1995; Thomas et al., 2007], although in 2009, Diercke et al. carried out a pure in vitro experiment, in which the development of the outer lesion in the secondary caries was inhibited to study the relation between the gap size and the wall lesion independently, and confirmed the occurrence of wall lesions without the presence of outer lesion and indicated the extent of wall lesion increased with increasing gap width ranging from 50 to $250\mu\text{m}$ [Diercke et al., 2009]. Therefore, more in-depth studies are needed to get a thorough understanding about the relationship between microleakage and secondary caries.

4. Prevention and treatment of secondary caries

4.1 Prevention of secondary caries

As secondary caries is one of the major reasons for restoration replacement, a large number of clinical dentists and scientists have placed great emphasis on preventing or slowing down the procession of secondary caries lesion from many aspects, so as to increase clinical restoration durability. Secondary caries, the same as other types of dental caries, is determined by the dynamic balance between pathological factors that lead to demineralization and protective factors that lead to remineralization. It is also considered that bacteria are an important etiologic factor leading to demineralization for secondary caries. Generally, the rationales of all the modification of restorative material or prevention of secondary caries normally include two fundamental points: one is the decrease of demineralization and/or increase of remineralization of the hard tooth tissues; the other is to interfere the metabolism of caries-related bacteria and/or to decrease the amount of bacteria/inhibit bacteria growth in the plaque or /and the carious dentin under restorations. Thus, in all the past years, most scientists and clinical dentists focused on adding anticaries substance into restorative materials.

It has been well-known such restorative materials can release copper, Ag-Cu alloy, zinc, calcium, aluminum and fluoride, which are able to inhibit bacteria growth or decrease colonization and acidogenicity of oral plaque, play antibacterial activities and reduce the rate of restoration replacement. The followings are several basic fillings used and researched by clinical dentists and scientists throughout the world: amalgam restorations, zinc oxide eugenol cement; common composite resin (CR); common glass ionomer cement (GIC); and different ion-released restorative materials containing fluoride-containing materials.

Clemens Boeckh et al. investigated the antimicrobial effects of five restorative materials and showed that the most remarkable inhibitory activity was observed with ZOE [Boeckh et al., 2002]. The antimicrobial effects of zinc oxide and ZOE are well recognized [Podbielski et al., 2000; Yap et al., 1999]. Unfortunately, ZOE cannot be widely used except for temporary filling due to its high solubility and insufficient mechanical properties. Different types of amalgam may have different effects on *S. mutans* growth and bacterial penetration [Fayyad and Ball, 1987]. For instance, a low-copper amalgam can decrease the lesion size significantly [Grossman and Matejka, 1995], non-gamma-2 amalgam can inhibit the metabolic activity of microorganisms due to the release of copper [Wallman-Björklund et al., 1987].

It has been widely shown in long term studies that CR have higher rate of restorations replacement than GIC and amalgam [Leinfelder, et al., 1987; Collins et al., 1998]. An in situ study showed that the percentage of streptococci in plaque on different materials was to be 13.7% on composite, 4.3% on amalgam and 1.1% on glass ionomer cement [Svanberg et al., 1990]. Another study showed up to eight times more microbes beneath composite restorations compared to amalgam and suggested the type of restorative material may have influence on the composition of the microflora [Splieth et al., 2003]. The high rate replacement of CR occurred might be due to its shrinkage and non-fluoride release [Savarino et al., 2004]. Thus, scientists have been making great efforts to improve CR, such as reducing the polymerization shrinkage of composite, increasing the adhesion stress. Remarkably, a modified ion-releasing resin composite (IRCR) has been invented, which can

release hydroxyl, calcium, and fluoride ions at low pH [Boeckh et al., 2002]. The rationales of anticaries effect of IRCR include: OH^- ions can neutralize the organic acids produced by the plaque bacteria [Heintze, 1999], and the calcium and fluoride ions released from IRCR can prevent demineralization and promote remineralization [ten Cate, 1990; ten Cate and van Duinen, 1995; Featherstone, 1994; Forss and Seppä, 1990; Kraft and Hoyer, 1999]. Thus, the restoration can perform anticaries activities. Studies have shown the release of hydroxyl and calcium can exist for a long period [Heintze, 1999]. Persson and his colleagues showed that IRCR could counter the plaque pH fall and maintain it at levels where less enamel and dentin demineralization can occur [Persson et al., 2004], however, the previous research did not consider IRCR could present significant antibacterial effects [Boeckh et al., 2002].

The inhibition of fluoride at acidic pH is due to the effect of hydrogen fluoride, which can penetrate into the bacteria cell membrane [Nakajo et al., 2009]. The HF can dissociate into hydrogen ion and fluoride ion. Some researchers confirmed that the fluoride can reduce the activities of enolase and proton-extruding ATPase, which are very important for metabolism of bacteria [Hayacibara et al., 2003]. Besides, the hydrogen ion can promote cytoplasmic acidification, which is critical for enzymes of the glycolytic pathway [Hüther et al., 1990]. So the combination effects of hydrogen ion and fluoride can have negative influence on the glycolytic acid production and the metabolism of caries-related bacteria. As a result, fluoride-containing restorative material can inhibit bacteria growth and decrease the demineralization of tooth tissue and the occurrence of secondary caries around restorations. However, these antimicrobial effects in caries prevention are often regarded as little or of no importance as compared to the direct interactions of fluoride with the hard tissue during caries development and progression [Wiegand et al., 2007]. Recent observations have found fluoride in the aqueous phase surrounding the carbonated apatite crystals is much more effective in inhibiting demineralization than fluoride incorporated into the crystal [Rølla and Ekstand, 1996]. Fluoride may precipitate onto tooth surfaces as calcium fluoride-like layer, which serves as a reservoir for fluoride when the pH drops [Rølla et al., 1993]. While amount of *in vitro* studies showed the inhibitive effect of fluoride on the demineralization of both enamel and dentin around the restoration in primary and permanent teeth [Attar and Önen, 2002; Donly and Gomez, 1994; Francci et al., 1999; Hicks et al., 2002; Tam et al., 1997; Yaman, 2004], the results from some *in situ* studies are not consistent with that *in vitro*, which have not confirmed the preventive ability of fluoride to secondary caries [Kielbassa et al., 1999, 2003; Papagiannouslis et al., 2002]. And this conflict is also showed among varieties of clinical studies. In a six-year follow-up assessment, class I restorations in permanent molars exhibited significantly less secondary caries for glass-ionomers(2%) compared to amalgam(10%) [Mandari et al., 2003]. Another five-year evaluation showed the glass-ionomer had a lower survival time and greater loss of anatomic form and marginal integrity, but less secondary caries compared to amalgam [Welbury et al., 1991]. Instead, Van Dijken found no difference in secondary caries development of class III cavities restored with two fluoride-containing materials and one composite in a three-year observation period [van Dijken, 1996]. Moreover, there is no clear evidence for inhibition of secondary caries by glass-ionomer cements as shown in a recent review summarizing extensive literature research [Randall and Wilson, 1999].

The above conflicts might be explained by the following factors: 1) the intrinsic formulation of fluoride-containing materials, the duration of fluoride releasing may influence its effect. The antibacterial effect of dentin is obtained only when the fluoride release is very large

[Kawai et al., 1998]. 2) The ability of fluoride uptake by different dental hard tissue. Due to differences in micro-structure and porosities, the amount of fluoride uptake from restorations and the depth of fluoride penetration are higher for both dentin and cementum than for enamel [Souganidis et al., 1981; Retief et al., 1984]. 3) Other environmental conditions. A decrease in pH increases the dissolution of the material leading to a higher fluoride level and the highest fluoride release is found in acidic and demineralizing-remineralizing regimes and lowest in saliva [Karantakis et al., 2000]. A pellicle forming by the components from saliva on the surface of the restorative material and various bleaching agents can impede fluoride ion release [Behrend and Geurtsen, 2001; Bell et al., 1999; Levallois et al., 1998]. 4) Extra application of fluoride. In a recent research, Cenci et al. found that the fluoride provided either by GI or fluoride dentifrice might be important to decrease demineralization adjacent to fillings, and by using fluoride dentifrice, demineralization adjacent to the restorations were similar [Cenci et al., 2008], which was testified by the previous study [Hara et al., 2006]. 5) In some cases, cavity type may play a significant role in the development of secondary caries [da Rosa Rodolpho et al., 2006], for example class II restorations involve the marginal ridges and significantly reduce the tooth resistance to fracture [Mondelli et al., 1980], and is susceptible to the biodegradation of saliva esterase activity [Finer and Santerre, 2004].

Since the final formation of caries is influenced by multiple factors, the prevention of secondary caries beginning at the time of restoration replacement contains a variety of aspects including the excavation of carious tissue; wise choice of restorative materials; fluoride regimen implementation (rinses, gels, fluoridated toothpastes); salivary flow rate assessment; healthy dietary; oral health or medical education and so on. Therefore, the prevention of secondary caries not only depends on the clinical operation by dentists, but also is influenced by other significant aspects from patients themselves.

4.2 Treatment of secondary caries

Restoration replacement has been invariably deemed as the sequela of clinically diagnosed secondary caries. Although practitioners are suggested should pay attention to the differentiation between secondary caries and discoloration, defective margin and residual caries, generally, a localized surface defect adjacent to restoration features clinically diagnosed secondary carious lesion [Mjör, 2005]. However, Some dental teaching programs related to localized defects on restorations including secondary caries, indicate that repair, rather than replacement, of the restoration is adopted frequently as an alternative to total replacement [Mjör and Gordan, 2002; Blum et al., 2002; Blum et al., 2003; Gordan et al., 2003]. Moreover, the modern conservative dentistry and minimal intervention dentistry call for repairing and refurbishing any localized defects at restoration margins, clinically diagnosed secondary caries rather than total replacement of restoration [Ericson et al., 2003]. Despite of the difficulties of detection and diagnosis of secondary caries, dentists should be trained and should be deliberate in making the decision of total replacement of restoration.

5. Conclusion

Secondary caries has been considered to account for majority of restoration failures and result in restoration replacement. It plays a significant role in human oral health and the longevity of restorations. Until now, there is no standardized criterion for diagnosis of secondary caries, although it is possible to detect the tiny carious lesions using advanced

techniques such as QLF and LF. Further experiments and clinical studies are needed to clarify those specific problems. Regardless of those difficulties and conflicts related to secondary caries, the key point is that more care need to be taken to prevent secondary caries and dentists should be cautious when they decide to replace the restoration completely. Besides, patients should be educated to protect the restoration through good oral hygiene and caries-preventive approaches.

6. Acknowledgement

This work was supported by Science and Technology Commission of Shanghai (08DZ2271100) and Shanghai Leading Academic Discipline Project (Project Number: S30206).

7. References

- Ando, M., González-Cabezas, C., Isaacs, R. L., Eckert, G. J., & Stookey, G.K. (2004). Evaluation of Several Techniques for the Detection of Secondary Caries Adjacent to Amalgam Restorations. *Caries Research*, Vol. 38(4), pp. 350-356.
- Arends, J., Dijkman, T., & Christoffersen, J. (1987). Average mineral loss in dental enamel during demineralization. *Caries Research*, Vol. 21(3), pp. 249-254.
- Attar, N., & Önen, A. (2002). Artificial formed caries-like lesions around esthetic restorative materials. *Journal of Clinical Pediatric Dentistry*, Vol. 26(3), pp. 289-296.
- Behrend, B., & Geurtsen, W. (2001). Long-term effects of four extraction media on the fluoride release from four polyacid-modified composite resins (compomers) and one resin-modified glass-ionomer cement. *Journal of Biomedical Materials Research*, Vol. 58(6), pp. 631-637.
- Beighton, David. (2005). The complex oral microflora of high-risk individuals and groups and its role in the caries process. *Community Dentistry and Oral Epidemiology*, Vol. 33(4), pp. 248-255.
- Bell, A., Creanor, S. L., Foye, R. H., & Saunders, W. P. (1999). The effect of saliva on fluoride release by a glass-ionomer filling material. *Journal of Oral Rehabilitation*, Vol. 26(5), pp. 407-412.
- Bergman, G., & Lindén, L. A. (1969). The action of the explorer on incipient caries. *Svensk Tandläkare Tidskrift. Swedish Dental Journal*, Vol. 62(10), pp. 629-634.
- Bernardo, M., Luis, H., Martin, M. D., Leroux, B. G., Rue, T., Leitão, J., & DeRouen, T. A. (2007). Survival and reasons for failure of amalgam versus composite posterior restorations placed in a randomized clinical trial. *Journal of the American Dental Association*, Vol. 138(6), pp. 775-783.
- Black GV. *A work on operative dentistry*. Chicago: Medico-Dental Publishing; 1908. The technical procedures in filling teeth; Vol. 2.
- Blum, I R, Schriever, A, Heidemann, D, Mjör, I A, & Wilson, N H F. (2003). The repair of direct composite restorations: an international survey of the teaching of operative techniques and materials. *European Journal of Dental Education*, 7(1), pp. 41-48.
- Blum, Igor R, Schriever, Anette, Heidemann, Detlef, Mjör, Ivar A, & Wilson, Nairn H F. (2002). Repair versus replacement of defective direct composite restorations in teaching programmes in United Kingdom and Irish Dental Schools. *The European Journal of Prosthodontics and Restorative Dentistry*, Vol. 10(4), pp. 151-155.

- Boeckh, Clemens, Schumacher, E., Podbielski, Andreas, & Haller, Bernd. (2002). Antibacterial Activity of Restorative Dental Biomaterials in vitro. *Caries Research*, Vol. 36(2), pp. 101-107.
- Boyd, M. A., & Richardson, A. S. (1985). Frequency of amalgam replacement in general dental practice. *Journal Canadian Dental Association*, Vol. 51(10), pp. 763-766.
- Burke, F. J., Cheung, S. W., Mjör, I A, & Wilson, N. H. (1999a). Reasons for the placement and replacement of restorations in vocational training practices. *Primary Dental Care: Journal of the Faculty of General Dental Practitioners*, Vol. 6(1), pp. 17-20.
- Burke, F. J., Cheung, S. W., Mjör, I A, & Wilson, N. H. (1999b). Restoration longevity and analysis of reasons for the placement and replacement of restorations provided by vocational dental practitioners and their trainers in the United Kingdom. *Quintessence International*, Vol. 30(4), pp. 234-242.
- ten Cate, J. M. (1990). In vitro studies on the effects of fluoride on de- and remineralization. *Journal of Dental Research*, Vol. 69 Spec No, 614-619; discussion pp. 634-636.
- ten Cate, J. M., & van Duinen, R. N. (1995). Hypermineralization of dentinal lesions adjacent to glass-ionomer cement restorations. *Journal of Dental Research*, Vol. 74(6), pp. 1266-1271.
- Cenci, M S, Pereira-Cenci, T., Cury, J. A., & Ten Cate, J. M. (2009). Relationship between gap size and dentine secondary caries formation assessed in a microcosm biofilm model. *Caries Research*, Vol. 43(2), pp. 97-102.
- Cenci, M.S., Tenuta, L. M. A., Pereira-Cenci, T., Del Bel Cury, A. A., ten Cate, J. M., & Cury, J. A. (2008). Effect of Microleakage and Fluoride on Enamel-Dentine Demineralization around Restorations. *Caries Research*, Vol. 42(5), pp. 369-379.
- Collins, C. J., Bryant, R. W., & Hodge, K. L. (1998). A clinical evaluation of posterior composite resin restorations: 8-year findings. *Journal of Dentistry*, Vol. 26(4), 311-317.
- Dahl, J. E., & Eriksen, H. M. (1978). Reasons for replacement of amalgam dental restorations. *European Journal of Oral Sciences*, Vol. 86(5), pp. 404-407.
- Deligeorgi, V., Mjör, I A, & Wilson, N. H. (2001). An overview of reasons for the placement and replacement of restorations. *Primary Dental Care: Journal of the Faculty of General Dental Practitioners*, Vol. 8(1), pp. 5-11.
- Dérاند, T., Birkhed, D., & Edwardsson, S. (1991). Secondary caries related to various marginal gaps around amalgam restorations in vitro. *Swedish Dental Journal*, Vol. 15(3), pp. 133-138.
- Diercke, K., Lussi, A., Kersten, T., & Seemann, R. (2009). Isolated development of inner (wall) caries like lesions in a bacterial-based in vitro model. *Clinical Oral Investigations*, Vol. 13(4), pp. 439-444.
- van Dijken, J. W. (1996). 3-year clinical evaluation of a compomer, a resin-modified glass ionomer and a resin composite in Class III restorations. *American Journal of Dentistry*, Vol. 9(5), pp. 195-198.
- Donly, K., & Gomez, C. (1994). In vitro demineralization-remineralization of enamel caries at restoration margins utilizing fluoride-releasing composite resin. *Quintessence International*, Vol. 25(5), pp. 355-358.
- Ekstrand, K., Qvist, V., & Thylstrup, A. (1987). Light microscope study of the effect of probing in occlusal surfaces. *Caries Research*, Vol. 21(4), pp. 368-374.

- Ericson, D., Kidd, E., McComb, D., Mjör, I., & Noack, M. J. (2003). Minimally Invasive Dentistry--concepts and techniques in cariology. *Oral Health & Preventive Dentistry*, Vol. 1(1), pp. 59-72.
- Fayyad, M. A., & Ball, P. C. (1987). Bacterial penetration around amalgam restorations. *The Journal of Prosthetic Dentistry*, Vol. 57(5), pp. 571-574.
- Featherstone, J. D. (1994). Fluoride, remineralization and root caries. *American Journal of Dentistry*, Vol. 7(5), pp. 271-274.
- Featherstone, J. D. B. (2004). The Continuum of Dental Caries--Evidence for a Dynamic Disease Process. *Journal of Dental Research*, Vol. 83(suppl 1), pp. C39-C42.
- Finer, Y., & Santerre, J. P. (2004). Salivary Esterase Activity and Its Association with the Biodegradation of Dental Composites. *Journal of Dental Research*, Vol. 83(1), pp. 22 - 26.
- Fédération Dentaire Internationale. (1962). Special commission on oral and dental statistics: General principles concerning the international standardization of dental caries statistics. *International Dental Journal*, Vol. 12 pp. 15.
- Fontana, M., Li, Y, Dunipace, A. J., Noblitt, T. W., Fischer, G., Katz, B. P., & Stookey, G K. (1996). Measurement of enamel demineralization using microradiography and confocal microscopy. A correlation study. *Caries Research*, Vol. 30(5), pp. 317-325.
- Fontana, M., & González-Cabezas, C. (2000). Secondary caries and restoration replacement: An unresolved problem. *Compendium of continuing education in dentistry*, Vol. 21(1), pp. 15.
- Forss, H, & Seppä, L. (1990). Prevention of enamel demineralization adjacent to glass ionomer filling materials. *Scandinavian Journal of Dental Research*, Vol. 98(2), pp. 173-178.
- Forss, Helena, & Widström, E. (2004). Reasons for restorative therapy and the longevity of restorations in adults. *Acta Odontologica Scandinavica*, Vol. 62(2), pp. 82-86.
- Francci, C., Deaton, T. G., Arnold, R. R., Swift, E. J., Perdigao, J., & Bawden, J. W. (1999). Fluoride Release from Restorative Materials and Its Effects on Dentin Demineralization. *Journal of Dental Research*, Vol. 78(10), pp. 1647 -1654.
- Friedl, K. H., Hiller, K. A., & Schmalz, G. (1995). Placement and replacement of composite restorations in Germany. *Operative Dentistry*, Vol. 20(1), pp. 34-38.
- Fusayama, T. (1988). Clinical guide for removing caries using a caries-detecting solution. *Quintessence International*, Vol. 19(6), pp. 397-401.
- Goldberg, J., Tanzer, J., Munster, E., Amara, J., Thal, F., & Birkhed, D. (1981). Cross-sectional clinical evaluation of recurrent enamel caries, restoration of marginal integrity, and oral hygiene status. *Journal of the American Dental Association*, Vol. 102(5), pp. 635-641.
- González-Cabezas, C, Li, Y, Gregory, R L, & Stookey, G K. (1999). Distribution of three cariogenic bacteria in secondary carious lesions around amalgam restorations. *Caries Research*, Vol. 33(5), pp. 357-365.
- González-Cabezas, Carlos, Li, Yiming, Gregory, Richard L, & Stookey, George K. (2002). Distribution of cariogenic bacteria in carious lesions around tooth-colored restorations. *American Journal of Dentistry*, Vol. 15(4), pp. 248-251.
- Gordan, V V, Mjör, I A, Blum I R, & Wilson, N. (2003). Teaching students the repair of resin-based composite restorations: A survey of North American dental schools. *The Journal of the American Dental Association*, Vol. 134(3), pp. 317 -323.

- Grossman, E. S., & Matejka, J. M. (1995). Amalgam restoration and in vitro caries formation. *The Journal of Prosthetic Dentistry*, Vol. 73(2), pp. 199-209.
- Hals, E. (1975a). Histology of natural secondary caries associated with silicate cement restorations in human teeth. *Archives of Oral Biology*, Vol. 20(4), pp. 291-296.
- Hals, E. (1975b). The structure of experimental in vitro lesions around silicate fillings in human teeth. *Archives of Oral Biology*, Vol. 20(4), pp. 283-289.
- Hals, E., Andreassen, B. H., & Bie, T. (1974). Histopathology of natural caries around silver amalgam fillings. *Caries Research*, Vol. 8(4), pp. 343-358.
- Hals, E., & Nernaes, Å. (1971). Histopathology of in vitro Caries Developing around Silver Amalgam Fillings. *Caries Research*, Vol. 5(1), pp. 58-77.
- Hals, E., & Norderval, I. T. (1973). Histopathology of experimental in vivo caries around silicate fillings. *Acta Odontologica Scandinavica*, Vol. 31(6), pp. 357-367.
- Hals, E., & Simonsen, L. T. (1972). Histopathology of experimental in vivo caries around silver amalgam fillings. *Caries Research*, Vol. 6(1), pp. 16-33
- Hara, A. T., Turssi, C. P., Ando, M., González-Cabezas, C, Zero, D. T., Rodrigues, A. L., Jr, Serra, M. C., et al. (2006). Influence of fluoride-releasing restorative material on root dentine secondary caries in situ. *Caries Research*, Vol. 40(5), pp. 435-439.
- Hayacibara, M. F., Rosa, O. P. S., Koo, H., Torres, S. A., Costa, B., & Cury, J. A. (2003). Effects of fluoride and aluminum from ionomeric materials on *S. mutans* biofilm. *Journal of Dental Research*, Vol. 82(4), pp. 267-271.
- Heintze, S. D. (1999). A new material concept for inhibiting the formation of secondary caries. *American Journal of Dentistry*, Vol. 12 Spec No, pp. S4-7.
- Hewlett, E. R., Atchison, K. A., White, S. C., & Flack, V. (1993). Radiographic Secondary Caries Prevalence in Teeth with Clinically Defective Restorations. *Journal of Dental Research*, Vol. 72(12), pp. 1604 -1608.
- Hicks, J., Garcia-Godoy, F., Donly, K., & Flaitz, C. (2003). Fluoride-releasing restorative materials and secondary caries. *Journal of the California Dental Association*, Vol. 31(3), pp. 229-245.
- Hicks, John, Milano, M., Seybold, S., García-Godoy, Franklin, & Flaitz, Catherine. (2002). Fluoride-releasing resin bonding of amalgam restorations in primary teeth: in vitro secondary caries effect. *American Journal of Dentistry*, Vol. 15(6), pp. 361-364.
- Huang, C., Tay, F. R., Cheung, G. S. P., Kei, L. H., Wei, S. H. Y., & Pashley, D. H. (2002). Hygroscopic expansion of a compomer and a composite on artificial gap reduction. *Journal of Dentistry*, Vol. 30(1), pp. 11-19.
- Hüther, F. J., Psarros, N., & Duschner, H. (1990). Isolation, characterization, and inhibition kinetics of enolase from *Streptococcus rattus* FA-1. *Infection and Immunity*, Vol. 58(4), pp. 1043-1047.
- Irie, M., & Suzuki, K. (1999). Marginal gap formation of light-activated base/liner materials: effect of setting shrinkage and bond strength. *Dental Materials*, Vol. 15(6), pp. 403-407.
- Irie, M., Suzuki, K., & Watts, D. C. (2002). Marginal gap formation of light-activated restorative materials: effects of immediate setting shrinkage and bond strength. *Dental Materials*, Vol. 18(3), pp. 203-210.
- Iwami, Y., Shimizu, A., Hayashi, M., Takeshige, F., & Ebisu, S. (2005). Three-dimensional evaluation of gap formation of cervical restorations. *Journal of Dentistry*, Vol. 33(4), pp. 325-333.

- Jørgensen K. D., & Wakumoto, S. (1968). Occlusal amalgam fillings: marginal defects and secondary caries. *Odontologisk Tidsskrift*, Vol. 76(1), pp. 43-54.
- Karantakis, P., Helvatjoglou-Antoniades, M., Theodoridou-Pahini, S., & Papadogiannis, Y. (2000). Fluoride release from three glass ionomers, a compomer, and a composite resin in water, artificial saliva, and lactic acid. *Operative Dentistry*, Vol. 25(1), pp. 20-25.
- Kawai, K., Tantbirojn, D., Kamalawat, A. S., Hasegawa, T., & Retief, D. H. (1998). In vitro enamel and cementum fluoride uptake from three fluoride-containing composites. *Caries Research*, Vol. 32(6), pp. 463-469.
- Kelsey, W. P., 3rd, France, S. J., Blankenau, R. J., Cavel, W. T., & Barkmeier, W. W. (1981). Caries as a cause of restoration replacement: a clinical survey. *Quintessence International*, Vol. 12(9), pp. 971-974.
- Kidd, E. A. (1976). Microleakage: a review. *Journal of Dentistry*, Vol. 4(5), pp. 199-206.
- Kidd, E. A. (1984). The diagnosis and management of the "early" carious lesion in permanent teeth. *Dental Update*, Vol. 11(2), pp. 69-70, 72-74, 76-78 passim.
- Kidd, E. A. (1990). Caries diagnosis within restored teeth. *Adv Dent Res*, Vol. 4, 10-13.
- Kidd, E. A. (2001). Diagnosis of secondary caries. *Journal of Dental Education*, 65(10), pp. 997-1000.
- Kidd, E. A. (2010). Clinical threshold for carious tissue removal. *Dental Clinics of North America*, Vol. 54(3), pp. 541-549.
- Kidd, E. A., & Beighton, D. (1996). Prediction of Secondary Caries around Tooth-colored Restorations: A Clinical and Microbiological Study. *Journal of Dental Research*, Vol. 75(12), pp. 1942-1946.
- Kidd, E. A., & O'Hara, J. W. (1990). The caries status of occlusal amalgam restorations with marginal defects. *Journal of Dental Research*, Vol. 69(6), pp. 1275-1277.
- Kidd, E. A., Joyston-Bechal, S., & Beighton, D. (1993). Microbiological validation of assessments of caries activity during cavity preparation. *Caries Research*, Vol. 27(5), pp. 402-408.
- Kidd, E. A., Joyston-Bechal, S., & Beighton, D. (1995). Marginal Ditching and Staining as a Predictor of Secondary Caries Around Amalgam Restorations: A Clinical and Microbiological Study. *Journal of Dental Research*, Vol. 74(5), pp. 1206-1211.
- Kielbassa, A. M., Müller, U., & García-Godoy, F. (1999). In situ study on the caries-preventive effects of fluoride-releasing materials. *American Journal of Dentistry*, Vol. 12 Spec No, pp. S13-14.
- Kielbassa, A. M., Schulte-Monting, J., Garcia-Godoy, F., & Meyer-Lueckel, H. (2003). Initial in situ secondary caries formation: effect of various fluoride-containing restorative materials. *Operative Dentistry*, Vol. 28(6), pp. 765-772.
- Klinke, T., Kneist, S., de Soet, J. J., Kuhlisch, E., Mauersberger, S., Forster, A., & Klimm, W. (2009). Acid production by oral strains of *Candida albicans* and lactobacilli. *Caries Research*, Vol. 43(2), pp. 83-91.
- Kraft U, Hoyer MI(1999): Effect of fluoride released from filling materials on the formation of artificial enamel and dentine lesions (abstract No 75). *Caries Res*, Vol. 33, pp. 306.
- Leinfelder, K. F. (1987). Evaluation of criteria used for assessing the clinical performance of composite resins in posterior teeth. *Quintessence International*, Vol. 18(8), pp. 531-536.

- Letzel, H., van't Hof, M. A., Vrijhoef, M. M., Marshall, G. W., Jr, & Marshall, S. J. (1989). A controlled clinical study of amalgam restorations: survival, failures, and causes of failure. *Dental Materials*, Vol. 5(2), pp. 115-121.
- Levallois, B., Fovet, Y., Lapeyre, L., & Gal, J. Y. (1998). In vitro fluoride release from restorative materials in water versus artificial saliva medium (SAGF). *Dental Materials*, Vol. 14(6), pp. 441-447.
- Loesche, W. J. (1986). Role of *Streptococcus mutans* in human dental decay. *Microbiological Reviews*, Vol. 50(4), pp. 353-380.
- Mandari, G. J., Frencken, J. E., & van't Hof, M. A. (2003). Six-year success rates of occlusal amalgam and glass-ionomer restorations placed using three minimal intervention approaches. *Caries Research*, Vol. 37(4), pp. 246-253.
- Marsh, P. D. (2006). Dental plaque as a biofilm and a microbial community – implications for health and disease. *BMC Oral Health*, Vol. 6(Suppl 1), pp. S14-S14.
- Massler, M. (1967). Pulpal reactions to dental caries. *International Dental Journal*, Vol. 17(2), pp. 441-460.
- Mejàre, B., Mejàre, I., & Edwardsson, S. (1979). Bacteria beneath composite restorations--a culturing and histobacteriological study. *Acta Odontologica Scandinavica*, Vol. 37(5), pp. 267-275.
- Mjör, I A. (1985). Frequency of secondary caries at various anatomical locations. *Operative Dentistry*, Vol. 10(3), pp. 88-92.
- Mjör, I A. (1996). Glass-ionomer cement restorations and secondary caries: a preliminary report. *Quintessence International*, Vol. 27(3), pp. 171-174.
- Mjör, I A. (1997). The reasons for replacement and the age of failed restorations in general dental practice. *Acta Odontologica Scandinavica*, Vol. 55(1), pp. 58-63.
- Mjör, I A. (1998). The location of clinically diagnosed secondary caries. *Quintessence International*, Vol. 29(5), pp. 313-317.
- Mjör, I A. (2005). Clinical diagnosis of recurrent caries. *The Journal of the American Dental Association*, Vol. 136(10), pp. 1426 -1433.
- Mjör, I A, & Gordan, V V. (2002). Failure, repair, refurbishing and longevity of restorations. *Operative Dentistry*, Vol. 27(5), pp. 528-534.
- Mjör, I A, & Jokstad, A. (1993). Five-year study of Class II restorations in permanent teeth using amalgam, glass polyalkenoate (ionomer) cement and resin-based composite materials. *Journal of Dentistry*, Vol. 21(6), pp. 338-343.
- Mjör, I A, & Qvist, V. (1997). Marginal failures of amalgam and composite restorations. *Journal of Dentistry*, Vol. 25(1), pp. 25-30.
- Mjör, I A, & Toffenetti, F. (2000). Secondary caries: a literature review with case reports. *Quintessence International*, Vol. 31(3), pp. 165-179.
- Mondelli, J., Steagall, L., Ishikiriyama, A., de Lima Navarro, M. F., & Soares, F. B. (1980). Fracture strength of human teeth with cavity preparations. *The Journal of Prosthetic Dentistry*, Vol. 43(4), pp. 419-422.
- Mousavinasab SM, Jafary M (2004): Microleakage of Composite Restorations Following Chemo-mechanical and Conventional Caries Removal. *Journal of Dentistry (TUMS)*, Vol. 1, pp. 12-17.
- Nakajo, K., Imazato, S., Takahashi, Y., Kiba, W., Ebisu, S., & Takahashi, N. (2009). Fluoride released from glass-ionomer cement is responsible to inhibit the acid production of caries-related oral streptococci. *Dental Materials*, Vol. 25(6), pp. 703-708.

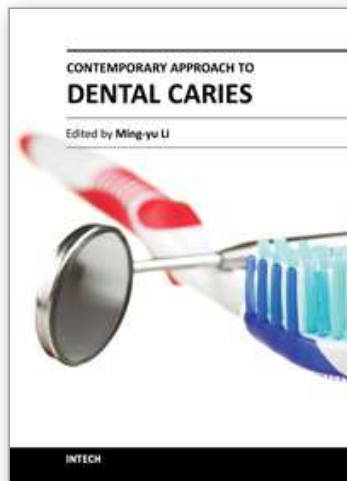
- Nikawa, H., Yamashiro, H., Makihira, S., Nishimura, M., Egusa, H., Furukawa, M., Setijanto, D., et al. (2003). In vitro cariogenic potential of *Candida albicans*. *Mycoses*, Vol. 46(11-12), pp. 471-478.
- Ozer, L., & Thylstrup, A. (1995). What is Known About Caries in Relation to Restorations as a Reason for Replacement? a Review. *Advances in Dental Research*, Vol. 9(4), pp. 394-402.
- Papagiannoulis, L., Kakaboura, A., & Eliades, G. (2002). In vivo vs in vitro anticariogenic behavior of glass-ionomer and resin composite restorative materials. *Dental Materials*, Vol. 18(8), pp. 561-569.
- Persson, A., Lingström, P., Bäcklund, T., & Dijken, J. W. V. (2004). Evaluation of a skin reference electrode used for intraoral pH measurements in combination with a microtouch electrode. *Clinical Oral Investigations*, Vol. 8(3), pp. 172-175.
- Pimenta, L. A., Navarro, M. F., & Consolaro, A. (1995). Secondary caries around amalgam restorations. *The Journal of Prosthetic Dentistry*, Vol. 74(3), pp. 219-222.
- Piwowarczyk, A., Lauer, H., & Sorensen, J. (2005). Microleakage of various cementing agents for full cast crowns. *The Journal of Prosthetic Dentistry*, Vol. 94(6), pp. 548-548.
- Podbielski, A., Boeckh, C., & Haller, B. (2000). Growth inhibitory activity of gutta-percha points containing root canal medications on common endodontic bacterial pathogens as determined by an optimized quantitative in vitro assay. *Journal of Endodontics*, Vol. 26(7), pp. 398-403.
- Qvist, V., Qvist, J., & Mjör, I A. (1990). Placement and longevity of tooth-colored restorations in Denmark. *Acta Odontologica Scandinavica*, Vol. 48(5), pp. 305-311.
- Qvist, V., Thylstrup, A., & Mjör, I A. (1986). Restorative treatment pattern and longevity of amalgam restorations in Denmark. *Acta Odontologica Scandinavica*, Vol. 44(6), pp. 343-349.
- Randall, R. C., & Wilson, N.H.F. (1999). Glass-ionomer Restoratives: A Systematic Review of a Secondary Caries Treatment Effect. *Journal of Dental Research*, Vol. 78(2), pp. 628 - 637.
- Retief, D. H., Bradley, E. L., Denton, J. C., & Switzer, P. (1984). Enamel and Cementum Fluoride Uptake from a Glass Ionomer Cement. *Caries Research*, Vol. 18(3), pp. 250-257.
- Rølla G., Ekstrand J. (1996). *Fluoride in oral fluids and dental plaque*. In: Fluoride in dentistry. 2nd ed. Fejerskov O, Ekstrand J, Burt J, editors. Copenhagen: Munksgaard, pp. 215-229.
- Rølla, G., Ogaard, B., & Cruz, R. de A. (1993). Topical application of fluorides on teeth. New concepts of mechanisms of interaction. *Journal of Clinical Periodontology*, Vol. 20(2), pp. 105-108.
- da Rosa Rodolpho, P. A., Cenci, Maximiliano Sérgio, Donassollo, T. A., Loguercio, A. D., & Demarco, F. F. (2006). A clinical evaluation of posterior composite restorations: 17-year findings. *Journal of Dentistry*, Vol. 34(7), pp. 427-435.
- Rudolph, M. P., van Amerongen, J. P., Penning, C., & ten Cate, J. M. (1995). Grey discoloration and marginal fracture for the diagnosis of secondary caries in molars with occlusal amalgam restorations: an in vitro study. *Caries Research*, Vol. 29(5), pp. 371-376.

- Savarino, L., Breschi, L., Tedaldi, M., Ciapetti, G., Tarabusi, C., Greco, M., Giunti, A., et al. (2004). Ability of restorative and fluoride releasing materials to prevent marginal dentine demineralization. *Biomaterials*, Vol. 25(6), pp. 1011-1017.
- Söderholm, K.-J.; Antonson, D.E.; and Fischlschweiger, W. (1989): *Correlation Between Marginal Discrepancies at the Amalgam-Tooth Interface and Recurrent Caries*. In: Quality Evaluation of Dental Restorations. Criteria for Placement and Replacement. K.J. Anusavice, Ed., Chicago: Quintessence, pp. 95-108.
- Souganidis, D. J., Athanassouli, T. M. N., & Papastathopoulos, D. S. (1981). A Study of in vivo Fluoride Uptake by Dental Tissues from Fluoride-containing Silver Amalgams. *Journal of Dental Research*, Vol. 60(2), pp. 105 -108.
- Splieth, C., Bernhardt, O., Heinrich, A., Bernhardt, H., & Meyer, G. (2003). Anaerobic microflora under Class I and Class II composite and amalgam restorations. *Quintessence International*, Vol. 34(7), pp. 497-503.
- Svanberg, M., Mjör, I.A., & Ørstavik, D. (1990). Mutans Streptococci in Plaque from Margins of Amalgam, Composite, and Glass-ionomer Restorations. *Journal of Dental Research*, Vol. 69(3), pp. 861 -864.
- Tam, L. E., Chan, G. P., & Yim, D. (1997). In vitro caries inhibition effects by conventional and resin-modified glass-ionomer restorations. *Operative Dentistry*, Vol. 22(1), pp. 4-14.
- Thomas, R. Z., van der Mei, H. C., van der Veen, M. H., de Soet, J. J., & Huysmans, M. C. D. N. J. M. (2008). Bacterial composition and red fluorescence of plaque in relation to primary and secondary caries next to composite: an in situ study. *Oral Microbiology and Immunology*, Vol. 23(1), pp. 7-13.
- Thomas, R. Z., Ruben, J. L., ten Bosch, J. J., Fidler, V., & Huysmans, M. C. D. N. J. M. (2007). Approximal secondary caries lesion progression, a 20-week in situ study. *Caries Research*, Vol. 41(5), pp. 399-405.
- Totiam, P., Gonzalez-Cabezas, C., Fontana, M. R., & Zero, D. T. (2007). A New in vitro Model to Study the Relationship of Gap Size and Secondary Caries. *Caries Research*, Vol. 41(6), pp. 467-473.
- Wallman-Björklund, C., Svanberg, M., & Emilson, C. G. (1987). Streptococcus mutans in plaque from conventional and from non-gamma-2 amalgam restorations. *Scandinavian Journal of Dental Research*, Vol. 95(3), pp. 266-269.
- Welbury, R. R., Walls, A. W., Murray, J. J., & McCabe, J. F. (1991). The 5-year results of a clinical trial comparing a glass polyalkenoate (ionomer) cement restoration with an amalgam restoration. *British Dental Journal*, Vol. 170(5), pp. 177-181.
- Wiegand, A., Buchalla, W., & Attin, T. (2007). Review on fluoride-releasing restorative materials—Fluoride release and uptake characteristics, antibacterial activity and influence on caries formation. *Dental Materials*, Vol. 23(3), pp. 343-362.
- Wilson, N. H., Burke, F. J., & Mjör, I A. (1997). Reasons for placement and replacement of restorations of direct restorative materials by a selected group of practitioners in the United Kingdom. *Quintessence International*, Vol. 28(4), pp. 245-248.
- Yaman, S. D., Er, O., Yetmez, M., & Karabay, G. A. (2004). In vitro inhibition of caries-like lesions with fluoride-releasing materials. *Journal of Oral Science*, Vol. 46(1), pp. 45-50.

Yap, A. U., Khor, E., & Foo, S. H. (1999). Fluoride release and antibacterial properties of new-generation tooth-colored restoratives. *Operative Dentistry*, Vol. 24(5), pp. 297-305.

IntechOpen

IntechOpen



Contemporary Approach to Dental Caries

Edited by Dr. Ming-Yu Li

ISBN 978-953-51-0305-9

Hard cover, 488 pages

Publisher InTech

Published online 14, March, 2012

Published in print edition March, 2012

With an update of the recent progress in etiology, pathogenesis, diagnosis, and treatment of caries, it may be said that the final defeat of dental caries is becoming possible soon. Based on the research in this area in recent decades, "Contemporary Approach to Dental Caries" contained the caries in general, the diagnosis of caries, caries control and prevention, the medical treatment of caries, dental caries in children and others such as secondary caries. This book provides the reader with a guide of progress on the study of dental caries. The book will appeal to dental students, educators, hygienists, therapists and dentists who wish to update their knowledge. It will make you feel reading is profitable and useful for your practice.

How to reference

In order to correctly reference this scholarly work, feel free to copy and paste the following:

Guang-yun Lai and Ming-yu Li (2012). Secondary Caries, Contemporary Approach to Dental Caries, Dr. Ming-Yu Li (Ed.), ISBN: 978-953-51-0305-9, InTech, Available from:

<http://www.intechopen.com/books/contemporary-approach-to-dental-caries/secondary-caries>

INTECH
open science | open minds

InTech Europe

University Campus STeP Ri
Slavka Krautzeka 83/A
51000 Rijeka, Croatia
Phone: +385 (51) 770 447
Fax: +385 (51) 686 166
www.intechopen.com

InTech China

Unit 405, Office Block, Hotel Equatorial Shanghai
No.65, Yan An Road (West), Shanghai, 200040, China
中国上海市延安西路65号上海国际贵都大饭店办公楼405单元
Phone: +86-21-62489820
Fax: +86-21-62489821

© 2012 The Author(s). Licensee IntechOpen. This is an open access article distributed under the terms of the [Creative Commons Attribution 3.0 License](#), which permits unrestricted use, distribution, and reproduction in any medium, provided the original work is properly cited.

IntechOpen

IntechOpen