

We are IntechOpen, the world's leading publisher of Open Access books Built by scientists, for scientists

4,800

Open access books available

122,000

International authors and editors

135M

Downloads

Our authors are among the

154

Countries delivered to

TOP 1%

most cited scientists

12.2%

Contributors from top 500 universities



WEB OF SCIENCE™

Selection of our books indexed in the Book Citation Index
in Web of Science™ Core Collection (BKCI)

Interested in publishing with us?
Contact book.department@intechopen.com

Numbers displayed above are based on latest data collected.

For more information visit www.intechopen.com



Standards for Electrical Impedance Mammography

Marina Korotkova and Alexander Karpov
*Clinical Hospital #9, Yaroslavl
Russia*

1. Introduction

1.1 Imaging technique, employing feeble alternating current

Currently, a variety of electrical impedance diagnostic systems is used both in academic studies and in clinical practice. A significant part of such systems employs electrodes which reside in a single array and two-dimensional mathematical conductivity reconstruction algorithms in the array of the electrodes. Electrical impedance mammograph belongs to the class of 3D tomography systems. Thus, all the measurements are made on the surface of the object under investigation. The change of surface potential difference (compared with the homogeneous case), as a rule, is caused by the presence of a local heterogeneous area in the object. It is mainly concentrated in the area which is a projection of the local heterogeneous area on the surface of the object. Therefore, the main objective of electrical impedance mammography is to visualize the reconstructed three-dimensional electrical conductivity distribution of the object basing on the results of electrical measurements on its surface. For this purpose various modifications of mathematical method of “back projection” are employed. Mathematical methods provide also cross-sectional slices of conductivity.

The usage of alternating current for this purpose is justified from several positions. Extreme complication of electrical conductivity measuring in biological systems at direct (i.e. unidirectional) current is conditioned by high degree of polarization of cellular membranes. Moreover, the flow of direct current through biological tissues is accompanied by irreversible chemical reactions at the electrodes, through which the object is connected with the external part of the circuit. Therefore, only alternating electric current of sufficiently high frequency is employed in medical diagnostics.

1.2 Tissue-specific peculiarities of electrical conductivity

In biological tissue, electric current affects the components and structures that have a net electric charge and / or an electric dipole moment. This influence is carried out in an environment characterized by the presence of numerous interface regions. An example of such interface regions are cell membranes. In the space, surrounding cell membranes from both sides, the changes are carried by electric charges, mainly in the form of ions and the sources of dipole moment in the form of polar water molecules and mobile polar

macromolecules. Moreover, the polarization ability of the cell membrane itself due to protein and lipid structures determines its exceptional electrical properties. Thus, the electrical properties of biological tissue as a colloid-disperse system in an alternating electric field are determined by the concentration and «the behaviour» of chemical compounds in it.

2. Indications for application

- Evaluation of palpable lesions of the mammary gland.
- Evaluation of the impalpable changes which do not manifest clinically.
- Formation of groups of people with heightened risk of breast cancer development, using the percentile curves of the age-related electrical conductivity.
- Screening for oncopathology.
- Additional examination of the dense tissue of the mammary gland.
- Examination in the age group under 50, including adolescents.
- Examination of pregnant and lactating women.
- Monitoring during hormonal contraception and hormone replacement therapy.
- Monitoring after pharmacotherapy or operative therapy.
- Examination of the women after cosmetic surgery.

3. Technical requirements and safety assurances for doctors and patients

- Parameters of current employed: alternating current, frequency - 50 kHz, current intensity - 0.5 mA.
- The abovementioned characteristics are allowed for medical use and are safe both for a doctor and a patient; also they are significantly lower than «threshold values», i.e. do not induce pain or other sensations.
- Patient's name/code, examination date, probing current characteristics and initial adjustments shall be displayed on the screen.
- Examination results digital recording.
- Penetration depth ≥ 4.0 cm.

4. Examination quality criteria

For high-quality diagnostic and continuity of work it is necessary that electrical impedance mammograms met specific quality criteria.

- Appropriate visualization of mammary gland tissue: the nipple shall be in the centre of the image.
- If the mammary gland is not completely covered by the panel or if there are palpable lesions out of the electrodes panel area, the examination shall be carried out by segments, clockwise (upper - external - lower - internal segment of the mammary gland).
- Proper designation: patient data, indication of the side and the date of the examination, physiological period, other features, for example, skin changes.
- Sufficient compression: optimal number of good contacts. It is necessary to achieve the maximum possible number of good contacts, however, excessive compression of the breast shall be avoided.

- The absence of motion distortions and artifacts.
- The absence of skin folds.
- The images acquired using improper examination techniques are not accepted for interpretation.

5. Types of mammary gland structure from the perspective of electrical impedance mammography

Electrical conductivity index (IC), calculated during the electrical impedance examination, is a quantitative value, which characterizes the status of the breast. The results of 1,632 electrical impedance mammograph examinations, obtained from healthy women from different age groups, were analyzed. The women were selected for the examination according to the following criteria: absence of complaints on the mammary glands, a normal menstrual cycle, uncomplicated perimenopausal period, absence of chronic somatic and gynaecological diseases and absence of hormonal contraceptives taking or hormone replacement therapy. The women were distributed by age in years as follows: 20-30 (380 women), 31-40 (428), 41-50 (449) and 51-60 (375). All the examinations described in the chapter were carried out with the help of the electroimpedance computer mammograph "MEIK" v.5.6 (0.5 mA, 50 kHz), developed and manufactured by PKF "SIM-Technika", Russia.

Fluctuations of electrical conductivity index in 1,632 studies were as follows: lower limit – 0.01 conventional units, upper limit – 0.68 conventional units. In order to identify the structure of electrical impedance index distribution there were elaborated 8 ranges of criteria at a step of 0.09 and the quantity of studies was calculated in each range (Table 1).

Electrical conductivity index	Number of studies
0.00 – 0.09	67
0.10 – 0.19	279
0.20 – 0.29	471
0.30 – 0.39	435
0.40 – 0.49	299
0.50 – 0.59	75
0.60 – 0.69	6
Total	1632

Table 1. Arrangement of electrical conductivity index frequencies.

Fig. 1 shows the frequency histogram of electrical conductivity index data. Mean electrical conductivity index constituted 0.29, median value – 0.29 and mode – 0.26.

Taking into consideration a bell-shaped curve, close mean, median and mode values one can speak about standard (Gauss) distribution of the quantitative value, in this case, of electrical conductivity index. Typically, mean value and standard deviation are used to describe standard distribution. More detailed data can be obtained using 3th, 10th, 25th, 40th, 75th, 90th and 97th percentiles (Figure 2). In this case, the information on the shape of criterion distribution graph is not required.

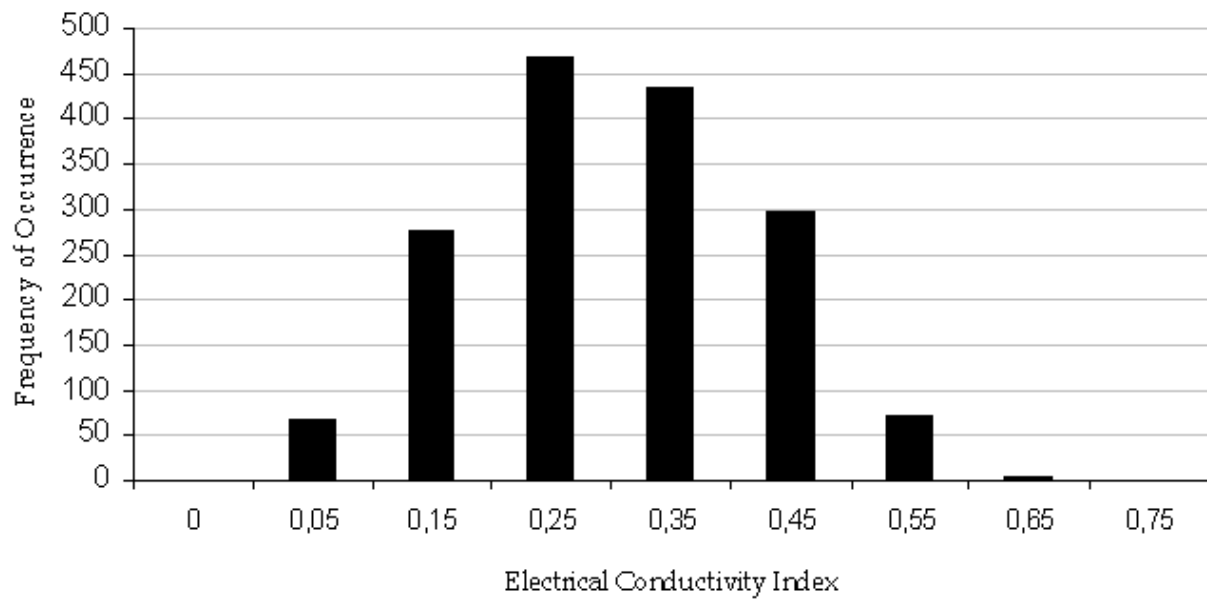


Fig. 1. Frequency histogram of electrical conductivity index data.

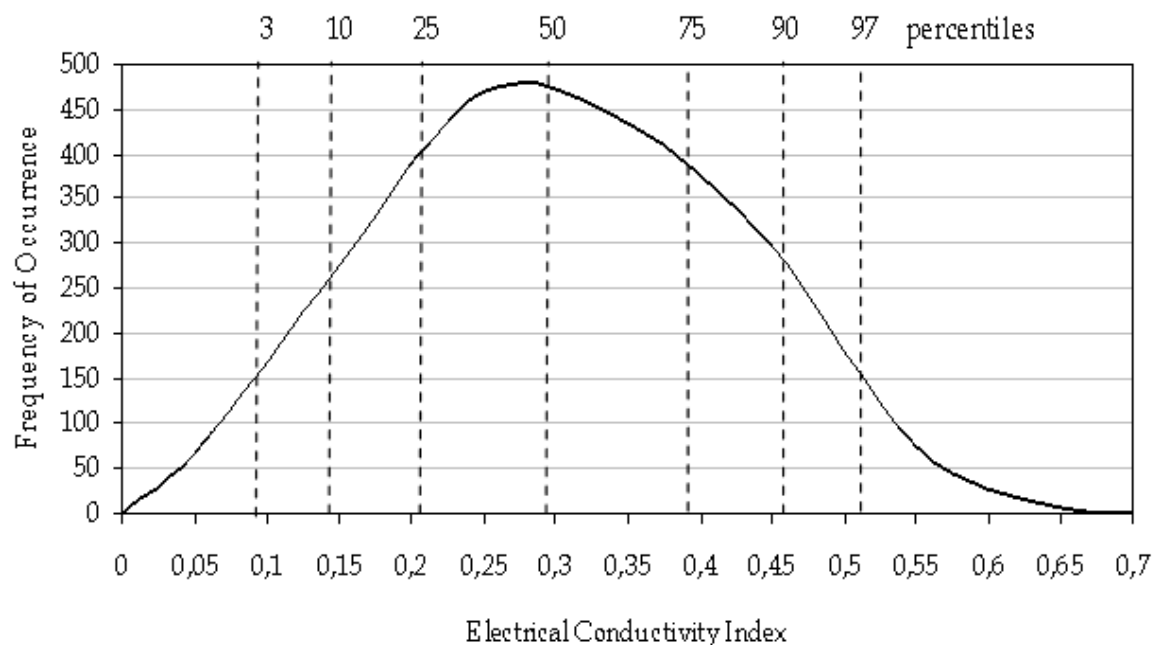


Fig. 2. Frequency histogram of electrical conductivity index data and percentile ranges.

The following pattern was identified after the age-related characteristics of women belonging to the percentile ranges were analyzed. Women aged from 20 to 30, whose data fell to the ranges less than 3rd percentile ($IC < 0.09$) and from 3rd to 10th percentile ($IC = 0.1-1.4$) constituted more than 50%. Women aged from 50 to 60, whose data fell to the ranges higher than 97th percentile ($IC > 0.53$) and from 90th to 97th percentile ($IC = 0.47-0.52$) constituted more than 50%. Age of the women whose data ranged between 25th and 75th percentiles ($IC = 0.21-0.39$) distributed in a uniform manner, the percentage of each age-group constituted from 20 to 30% without any prevalence (Figure 3).

“Loss” of acinar/ductal epithelium in women aged from 50 to 60 is the reason for high electrical conductivity index of the mammary glands. When progressive decrease of estradiol secretion occurs, terminal-duct secretory epithelium is substituted by connective tissue with a varied correlation of tissue elements. Intercellular substance includes the ground substance, which contains a large amount of mucopolysaccharides. Loose connective tissue, filling the space between bodies, blood vessels, nerves, muscles and other structures of the body, creates the internal environment, through which the delivery of nutrients to cells and the removal of the waste products of their metabolism are carried out. The major mucopolysaccharide of the ground substance of connective tissue is hyaluronic acid, which carries a large number of negative charges. Its ability to bind and retain water dipoles determines the electrical properties of amorphous substance of connective tissue, making it a good conductor. Therefore, the predominance of connective tissue in the breast should expect high electrical conductivity. The predominance of women in this age group is observed in two percentile ranges - more than 97th percentile and from 90th to 97th percentile. Therefore, the status of mammary glands possessing electrical conductivity index higher than 0.47 cu, should be regarded as amorphous type of the mammary gland structure (Fig. 5).

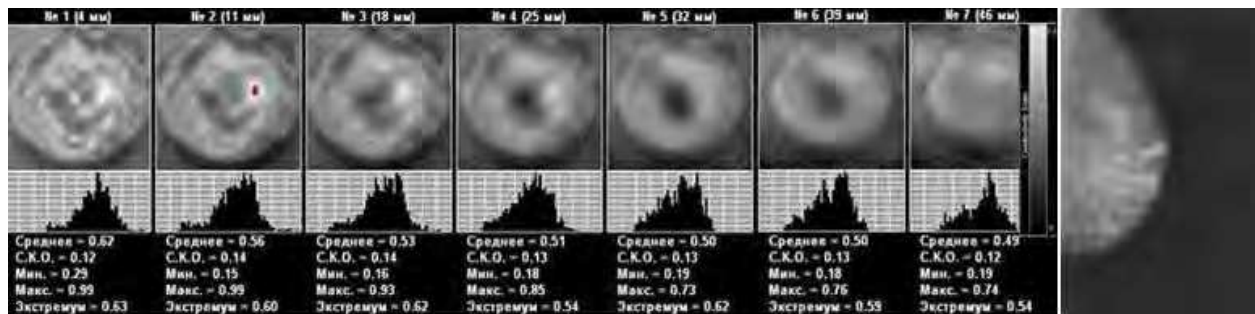


Fig. 5. EIM. Seven scan planes. A 52 years-old patient. Amorphous type of mammary gland structure. High values of mean electrical conductivity index – (> 90 pct). On the right - X-ray mammogram.

Different combinations of acinar/ductal components and connective tissue with adipocytes are the reasons for electrical conductivity index variations from 0.21-0.39 in women of all age groups. Therefore, the status of mammary glands possessing electrical conductivity index within the range from 0.21 to 0.39 cu, should be regarded as a mixed type of the mammary gland structure. Different combinations of the structures that determine the conductivity of tissues, define the wide range of the values of electrical conductivity index (Fig. 6).

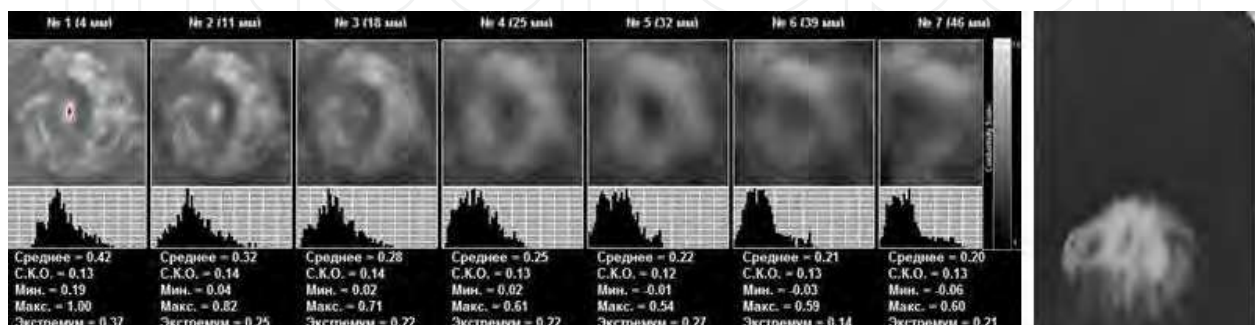


Fig. 6. EIM. Seven scan planes. Age 39 years. Mixed type of mammary gland structure. Mean electrical conductivity index – 25-75 pct. On the right - X-ray mammogram.

Within the ranges from 10th to 25th percentile and from 75 to 90th percentile the data of two age groups of women prevail. Therefore, the status of mammary glands possessing electrical conductivity index within these ranges, should be regarded as a mixed type of the mammary gland structure with prevalence of acinar/ductal or amorphous component respectively.

Below the summary table of structure estimates for the breast in terms of electrical impedance mammography is provided (Table 2).

	Formulation	Electrical conductivity	Percentiles
Type Ia	Amorphous type of mammary gland structure.	above 0.47	>90‰
Type Ib	Mixed type of mammary gland structure with amorphous component predominance.	0,40 - 0,46	75-90‰
Type II	Mixed type of mammary gland structure.	0,21 - 0,39	25-75‰
Type III	Mixed type of mammary gland structure with acinar/ ductal component predominance. High density of ductal component.	0,14 - 0,20	10-25‰
Type IV	Acinar/ ductal type of mammary gland structure. Extremely high density of acinar/ ductal component	below 0.14	<10‰

Table 2. Types of mammary gland structure from the perspective of electrical impedance mammography.

Thus the estimation of mammary gland structure from the perspective of electrical impedance mammography using electrical conductivity index is possible. It is known that the structure of the mammary gland determines their density. Thus, the defined ranges of electric conductivity correspond to different types of mammary gland "density". Low values of electric conductivity correspond to "dense" breasts of the so-called combined ductal/lobular type. High values of electrical conductivity index are characteristics of the amorphous type of breasts, consisting mainly of fat and connective tissue. A distinctive feature of this method for evaluating structure of the breast is the expression of its anatomical and histological structure in numerical terms. Estimation of the density of mammary glands from the perspective of electrical impedance mammography using electrical conductivity index in ACR terms is provided below (Table 3).

	<i>EIM</i> classification	<i>ACR</i> classification
Type Ia	Amorphous type of mammary gland structure. IC >90‰.	Predominantly fat. Under 25% of tissue is represented by parenchyma
Type Ib	Mixed type of mammary gland structure with amorphous component predominance. IC=75-90‰.	
Type II	Mixed type of mammary gland structure. IC=25-75‰.	Fat with some fibroglandular tissue. 25-50% of tissue is represented by parenchyma
Type III	Mixed type of mammary gland structure with acinar/ ductal component predominance. High density of acinar/ ductal component. IC=10-25‰.	Heterogeneously dense. 50-75% of tissue is represented by parenchyma
Type IV	Acinar/ ductal type of mammary gland structure. Extremely high density of acinar/ ductal component. IC < 10‰.	Extremely dense. 75-100% of parenchyma tissue.

Table 3. Mammary gland structure from the perspective of electrical impedance mammography execution and breast density types according to the classification of the American College of Radiology (ACR).

6. System for description of mammary glands images

6.1 Terminology

- Electrical conductivity scale - electrical conductivity index values from 0 to 1.00, or in gray-scale - changes from black to white, respectively.
- Hyperimpedance structure, lesion - electrical conductivity is lower than electrical conductivity of the surrounding tissue of the breast and corresponds to IC < 0.20.
- Isoimpedance structure, lesion - electrical conductivity is approximately equal to the electrical conductivity of the surrounding tissue of the breast and corresponds to IC = 0.3-0.5.
- Hypoimpedance structure, lesion - electrical conductivity is higher than the electrical conductivity of the surrounding tissue of the breast and corresponds to IC = 0.6-0.8.
- Animpedance structure, lesion - electrical conductivity is considerably higher than the electrical conductivity of the surrounding tissue of the breast and corresponds to IC > 0.90.

6.2 Normal signs in the electrical impedance mammogram

6.2.1 The septa

The septa (layers) consisting of delicate fibrillary tissue are going deep into the mass of the mammary gland from connective tissue capsule that surrounds it. The septa, radiating from the centre, which form the connective tissue stroma of the mammary gland are characterized by a hyperimpedance structure (Fig. 7).

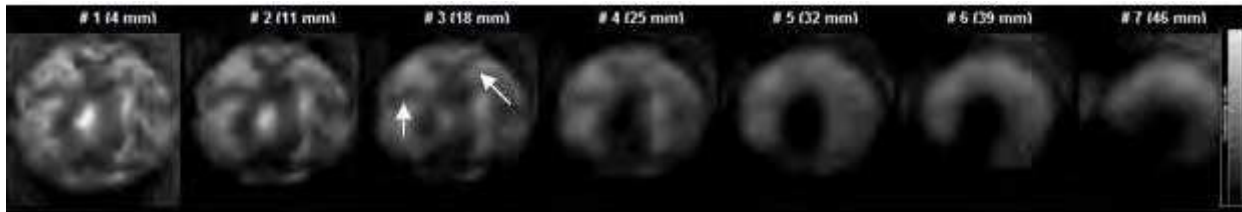


Fig. 7. EIM. Seven scan planes. Connective tissue septa, radiating from the areola (indicated with arrows).

6.2.2 The parenchyma

One distinguishes the parenchyma, which consists of alveolar-tubular glands, and the connective tissue stroma, which is represented by a small amount of cells, delicate fibres and ground intercellular substance. The parenchyma is characterized by an isoimpedance structure and is located between the septa. (Fig. 8).

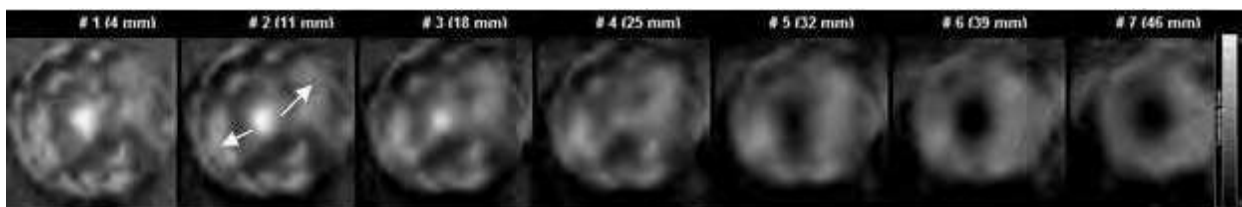


Fig. 8. EIM. Seven scan planes. Parenchyma as isoimpedance areas located between the connective tissue septa (indicated with arrows).

6.2.3 The lactiferous sinus zone

Before reaching the nipple milk ducts gain in breadth and create a lactiferous sinus (sinus lactiferi) which accumulates secreta as well as the milk. There are about 15-25 sini in the retromamillary area. The lactiferous sinus zone is visualized as a vast hypoimpedance area located in the centre of the mammogram (fig. 9).

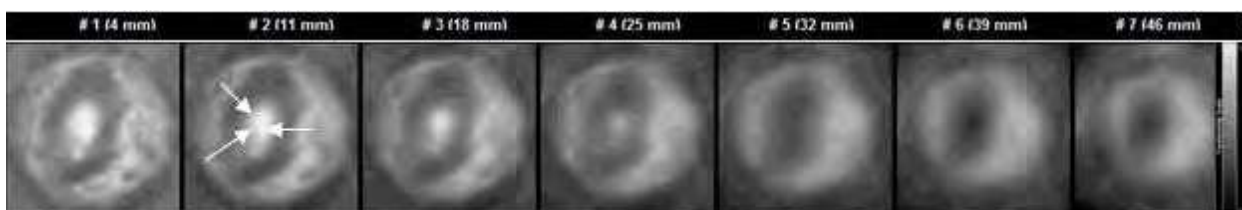


Fig. 9. EIM. Seven scan planes. A hypoimpedance area in the centre of the mammogram corresponds to the location of the lactiferous sinus zone (indicated with arrows).

6.2.4 The nipple

The nipple consists of the excretory ducts of the breast lobes, surrounded by fibrous tissue and a large number of sebaceous glands. High electrical impedance of the nipple is determined by the absence of the excretory ducts of perspiratory glands in it. In the electrical impedance tomogram the nipple is visualized in the centre as a circular or linear hyperimpedance area, located closely to the lactiferous sinus zone (fig. 10).

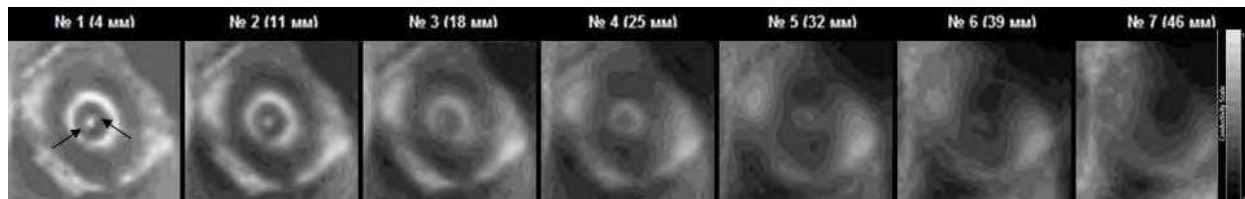


Fig. 10. EIM. Seven scan planes. The nipple is visualized in the centre as a rounded hyperimpedance area (indicated with arrows). In the centre of the nipple there are excretory ducts which are characterized by hypoimpedance. Around the nipple there is the hypoimpedance area of the lactiferous sinus zone.

6.2.5 The areola

In the dermis of areola there are circular smooth muscle fibres, numerous sebaceous glands and a large number of pigment cells. Large sebaceous glands located on the periphery of the areola cause the formation of protrusions (Montgomery's tubercles). High electrical impedance of the areola, as well as that of the nipple, is determined by the absence of the excretory ducts of perspiratory glands in it. In the electrical impedance mammogram the areola is visualized as a circular hyperimpedance formation surrounding the lactiferous sinus zone (fig. 11).

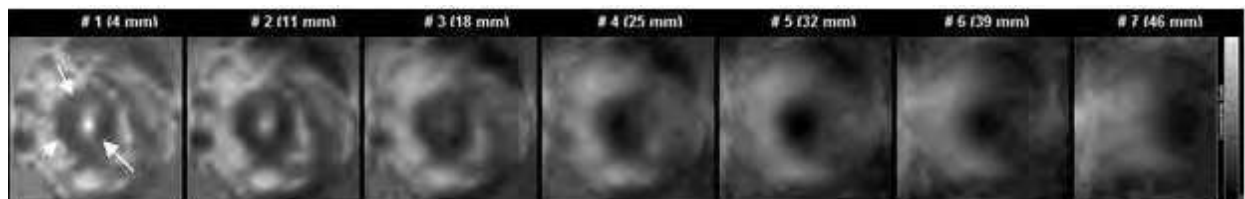


Fig. 11. EIM. Seven scan planes. A hyperimpedance area in the centre of the mammogram corresponds to the location of the areola (indicated with arrows).

6.3 Volumetric lesion

Volumetric lesion – a dimensional lesion, detected in several scan planes. The analysis of images includes assessment of the shape, contour, internal electrical structure and changes of the surrounding tissues.

6.3.1 Assessment of volumetric lesion shape in accordance with the terms of BI-RADS ACR

a. Round – a lesion of a spherical, circular or spherical shape (Fig. 12). The size is determined by lesion's diameter. Typical example – a cyst.

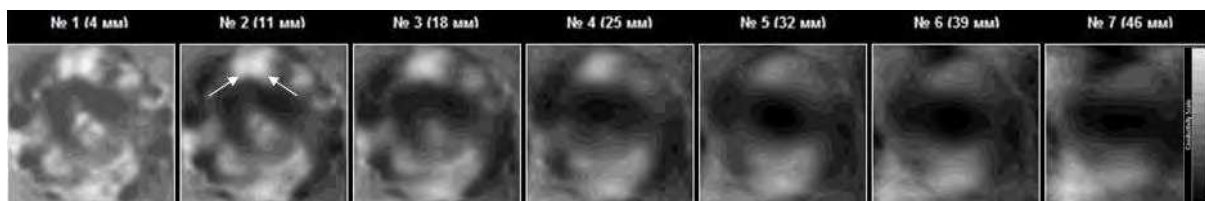


Fig. 12. EIM. Seven scan planes. In the upper segment there can be visualized two lesions of rounded shape (indicated with arrows).

b. Oval – an ellipsoid or obovoid lesion (Fig. 13). The size is determined by longitudinal and lateral axes. Typical example – fibroadenoma, cancer.

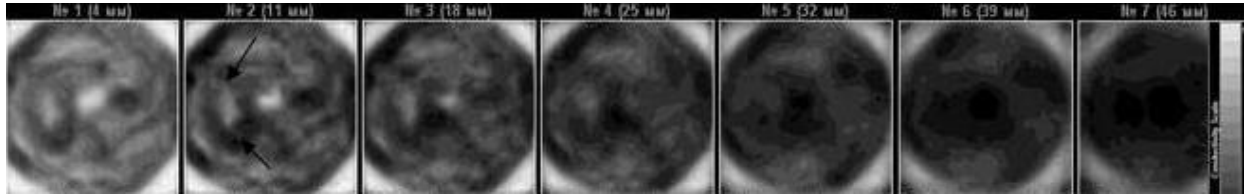


Fig. 13. EIM. Seven scan planes. The obovoid lesion is visualized at 9 on the clock dial (indicated with arrows).

c. Lobular – a lesion with the undulated contour (Fig. 14). The size is determined by longitudinal and lateral axes. Typical example – fibroadenoma.

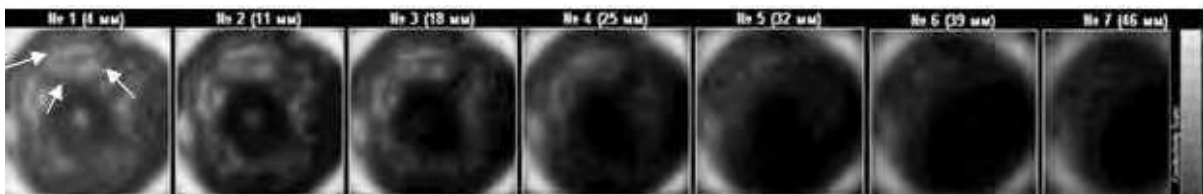


Fig. 14. EIM. Seven scan planes. In the upper segment at 12 on the clock dial, there can be observed two round hypoimpedance lesions.

d. Irregular - the shape of a lesion cannot be characterized and does not correspond to round, oval or lobular (Fig. 15). Typical example – breast cancer.

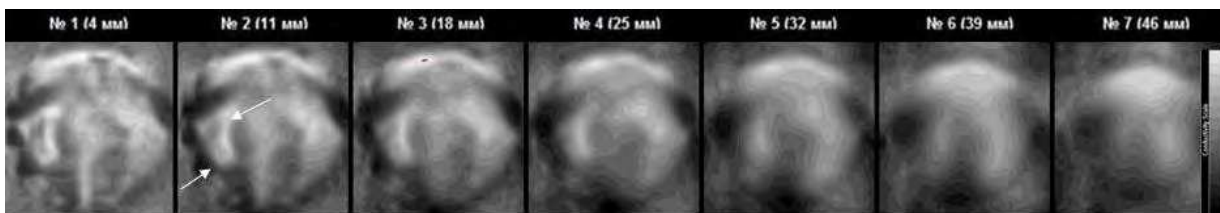


Fig. 15. EIM. Seven scan planes. In the upper segment there can be visualized a lesion with a lobed contour (indicated with arrows).

6.3.2 Assessment of volumetric lesion contours in accordance with the terms of BI-RADS ACR

a. Sharp (well defined or distinct) – the contours of a lesion are clearly observable. Abrupt junction of the lesion and surrounding tissues (Fig. 16).

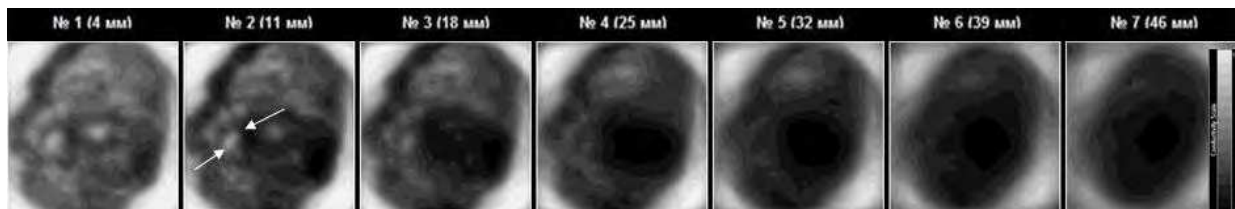


Fig. 16. EIM. Seven scan planes. The lesion with a sharp distinct contour is visualized at 9 on the clock dial (indicated with arrows).

b. Vague, indistinct (poorly observable) – the contours of a lesion are uneasy to define. The transition between the lesion and surrounding tissues is gradual and indistinct (Fig. 17). Typical example of an invasive ductal carcinoma.

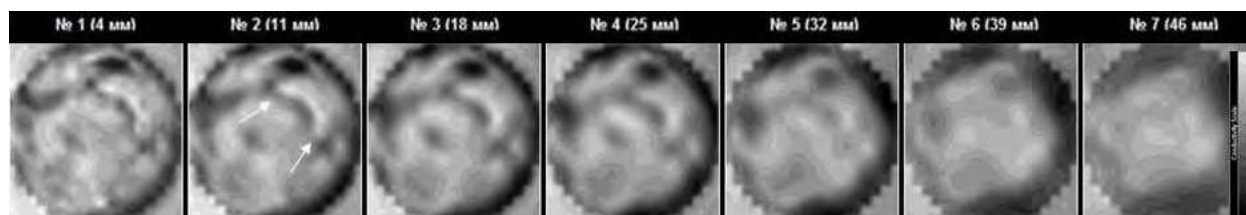


Fig. 17. EIM. Seven scan planes. The irregular-shaped lesion with indistinct contours is visualized at 12-3 on the clock dial (indicated with arrows).

c. Infiltrated - the contours of a lesion are clearly distinguishable and are characterized by hyperimpedance (Fig. 18). Typical example – breast cancer.

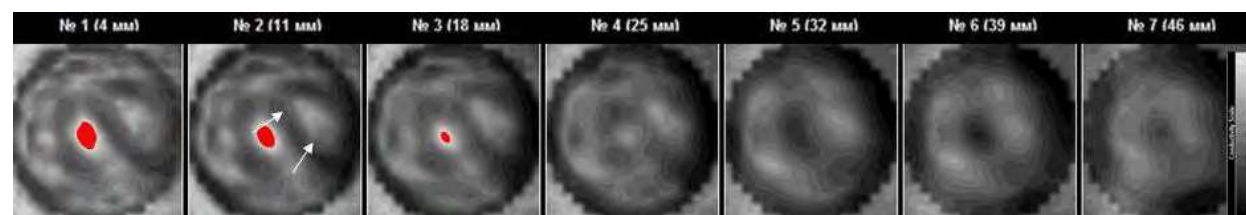


Fig. 18. EIM. Seven scan planes. The obovoid lesion with hyperimpedance contours is visualized at 3 on the clock dial (indicated with arrows).

6.3.3 Assessment of the internal electrical structure of a volumetric lesion

Taken separately, the internal electrical structure of the lesion is not the criterion for judging on its possible malignancy. However, it is an important characteristic, especially in combination with other evaluation criteria. The increase of electrical conductivity is correlated with an increase of the probability of malignancy.

a. Hyperimpedance - electrical conductivity of the lesion is lower than electrical conductivity than that of the surrounding tissue of the breast (Fig. 19). Typical example – mastitis in the stage of infiltration.

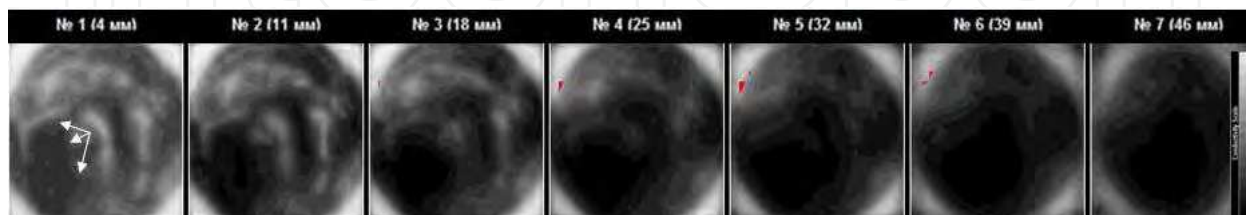


Fig. 19. EIM. Seven scan planes. The obovoid lesion with hyperimpedance structure is visualized at 8 on the clock dial (indicated with arrows).

b. Isoimpedance - electrical conductivity of the lesion corresponds to that of the surrounding tissue of the breast (Fig. 20). Typical examples – fibroadenoma, cancer.

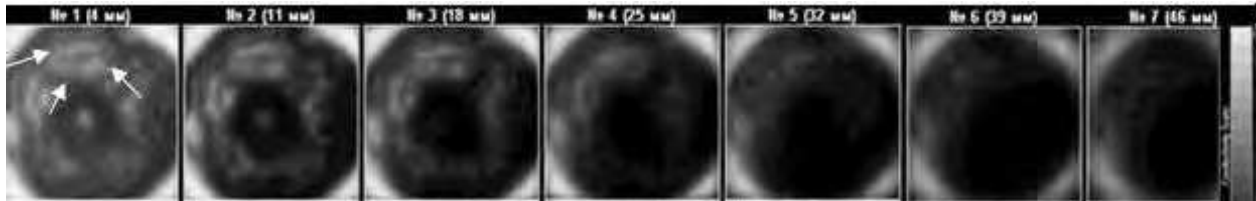


Fig. 20. EIM. Seven scan planes. The lesion with isoimpedance structure is visualized at 12 on the clock dial (indicated with arrows).

c. Hypoimpedance - electrical conductivity of the lesion is higher than that of the surrounding tissue of the breast (Fig. 21). Typical example - a cyst.

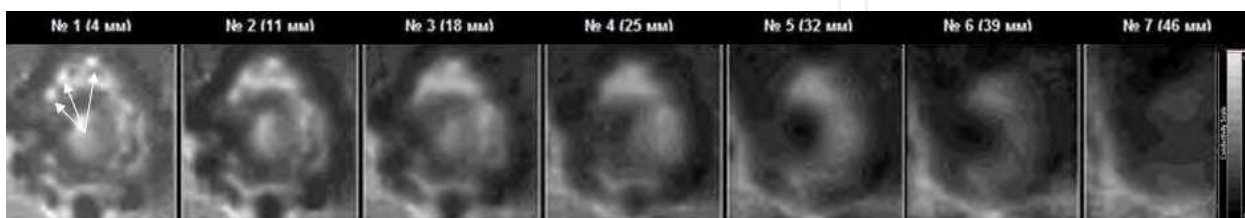


Fig. 21. EIM. Seven scan planes. In the upper segment there can be visualized three hypoimpedance lesions of rounded shape (indicated with arrows).

d. Animpedance - electrical conductivity of the lesion is considerably higher than that of the surrounding tissue of the breast (Fig. 22). Typical example - breast cancer.

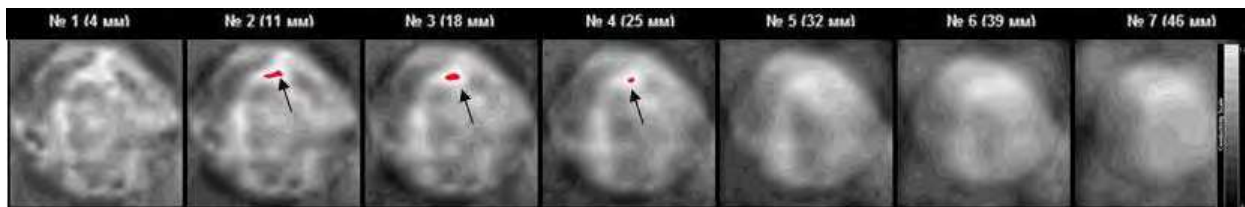


Fig. 22. EIM. Seven scan planes. In the upper segment, at 12 on the clock dial there is an irregular-shaped lesion with animpedance structure (highlighted in red and indicated with arrows).

6.4 Assessment of volumetric lesion influence on the surrounding tissue in accordance with the terms of BI-RADS ACR

a. Skin thickening - a significant one-sided hyperimpedance change of the contour around the mammary gland (Fig. 23). Typical example - mastitis-like carcinoma.

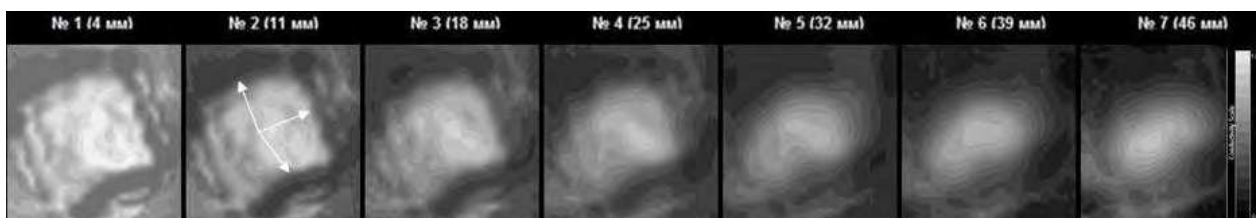


Fig. 23. EIM. Seven scan planes. A pronounced hyperimpedance change of the contour around the mammary gland (indicated with arrows).

b. Skin extrusion or retraction – a local change of mammary gland contour: In case of the retraction – into the mamma, in case of extrusion – entoectad (Fig. 24, 25). Typical example – breast cancer, mastitis.

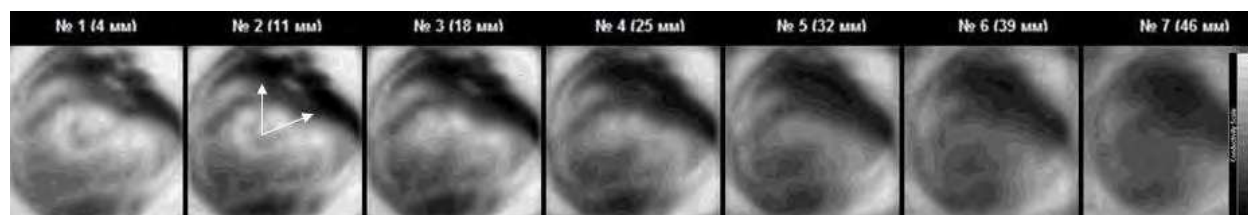


Fig. 24. EIM. Seven scan planes. In the upper segment, a change of the contour (retraction) of the mammary gland (indicated with arrows)

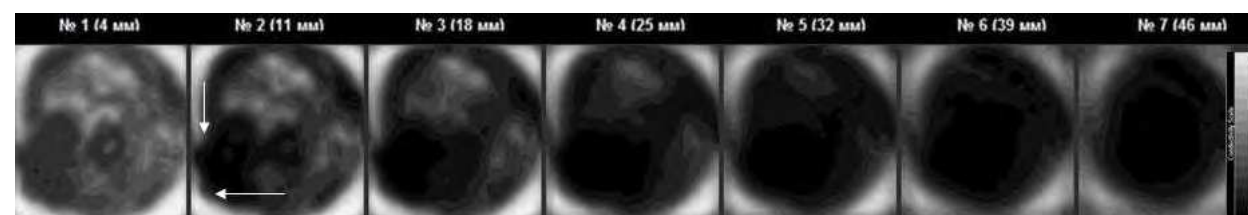


Fig. 25. EIM. Seven scan planes. At 7 on the clock dial, a change of the contour (extrusion) of the mammary gland (indicated with arrows).

c. Skin or nipple infiltration – a local hyperimpedance change of the contour of a mammary gland or of a nipple (Fig. 26, 27). Typical example – breast cancer, Paget's cancer.

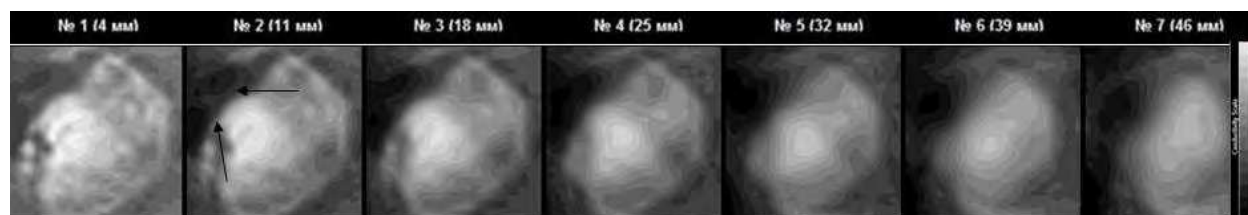


Fig. 26 EIM. Seven scan planes. A unilateral local hyperimpedance change of the mammary gland contour (indicated with arrows).

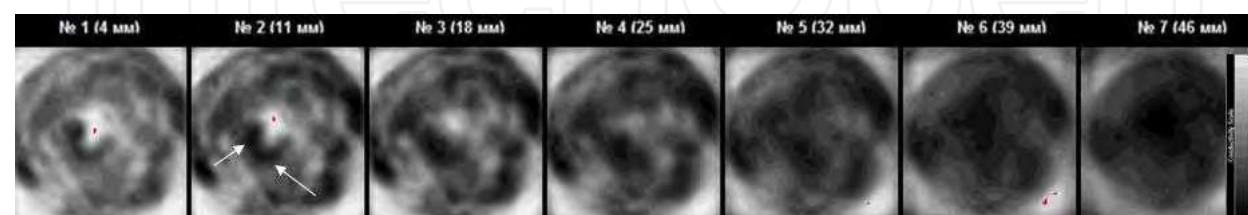


Fig. 27. EIM. Seven scan planes. A unilateral hyperimpedance change of the nipple contour (indicated with arrows).

d. Alterations of the breast anatomy – focal disruption of the normal mammographic scheme. Alteration of the age-related electrical impedance structure (Fig. 28, 29). Typical example – mastitis, breast cancer.

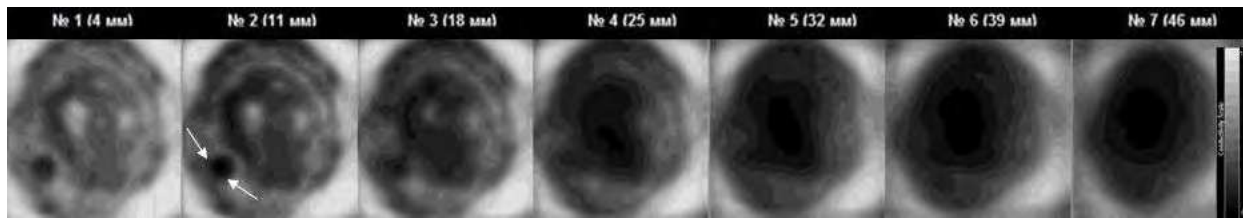


Fig. 28. EIM. Seven scan planes. Alteration of the normal mammographic scheme represented by a hyperimpedance lesion at 7 on the clock dial (indicated with arrows).

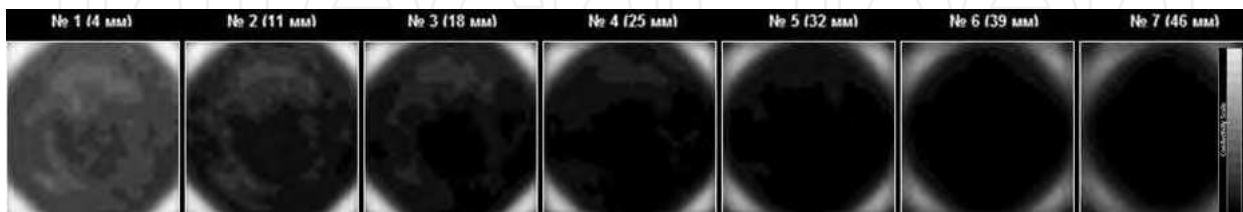


Fig. 29. EIM. Seven scan planes. Total alteration of the age-related electrical impedance structure.

6.5 Lactiferous sinus zone assessment

The visualization of lactiferous sinus zone depends on the age and physiological period of a patient. In women of elder age during the postmenopause the lactiferous sinus zone is hardly visualized. An extensive round hypo- or animpedance area in the centre of the mammogram is typical for the lactation period (Fig. 30). When pathology, there can be observed deformation and fragmentation of the lactiferous sinus zone (Fig. 31).

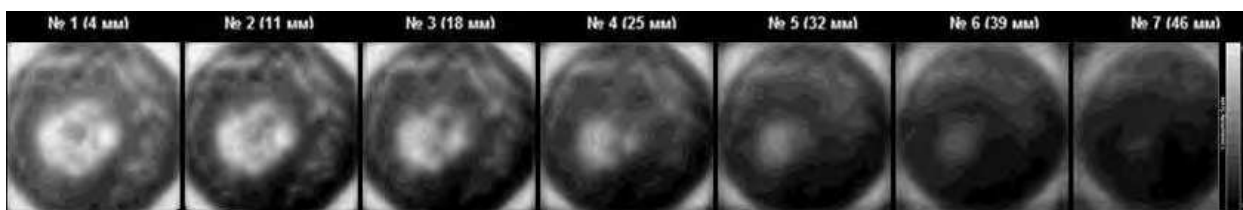


Fig. 30. EIM. Seven scan planes. There is a vast undistorted hypoiimpedance area in the centre of the mammogram, which corresponds to the location of the lactiferous sinus zone.

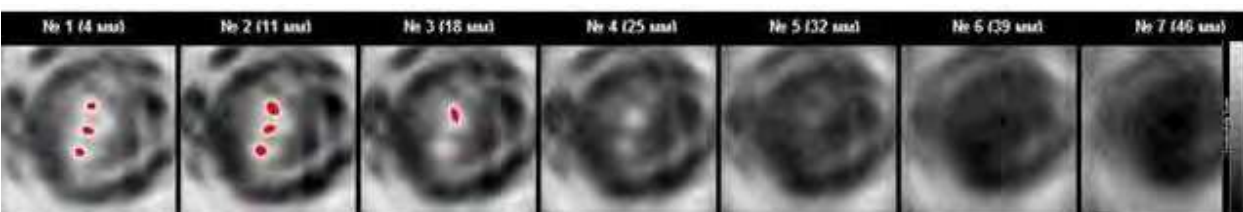


Fig. 31. EIM. Seven scan planes. There is a divided hypoiimpedance area in the centre of the mammogram, which corresponds to the location of the lactiferous sinus zone. It is highlighted in red.

6.6 Age-related and comparative electrical conductivity

6.6.1 Age-related conductivity

Age-related conductivity is the alteration of electrical conductivity of the breast with respect to age-related percentile curve of electrical conductivity (Fig. 32). The so-called percentile method as an approach to brief description of distributions is wide-spread in medical and biological research. This method does not require the data on distribution structure, i.e. it is non-parametric. The assessment of the average electrical conductivity in healthy women of different ages allowed creating the percentile curves of age-related electrical conductivity.

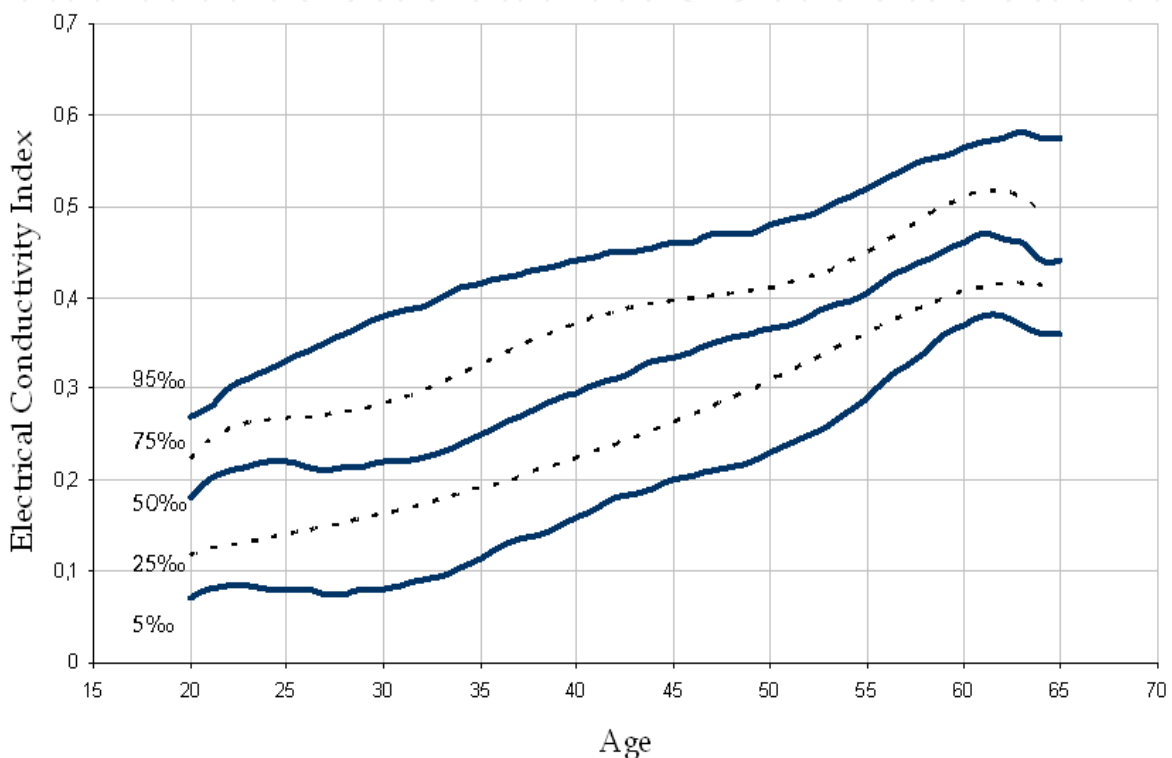


Fig. 32. Percentile curves of age-related electrical conductivity.

According to these curves each age group corresponds to a certain range of electrical conductivity. In accordance with the proposed assessment rules, the values which are less than 5th percentile shall be considered as pronouncedly low, from 5 to 25 percentiles - as low, from 25 to 75 percentiles - as medium, from 75 to 95 percentiles - as heightened and above 95 percentile - as pronouncedly heightened (Fig. 32). Formation of groups of people with heightened risk of breast cancer development can be performed using the percentile curves of the age-related electrical conductivity.

6.6.2 Comparative conductivity

Comparative conductivity is the alteration of electrical conductivity of one breast with respect to the other (Fig. 33). The histograms of the electrical conductivity distribution variance percent is chosen with the help of the Kolmogorov-Smirnov nonparametric test (more than 40%) and is highly informative ($j > 3.0$ according to Kullback). Typical example - breast cancer, mastitis.

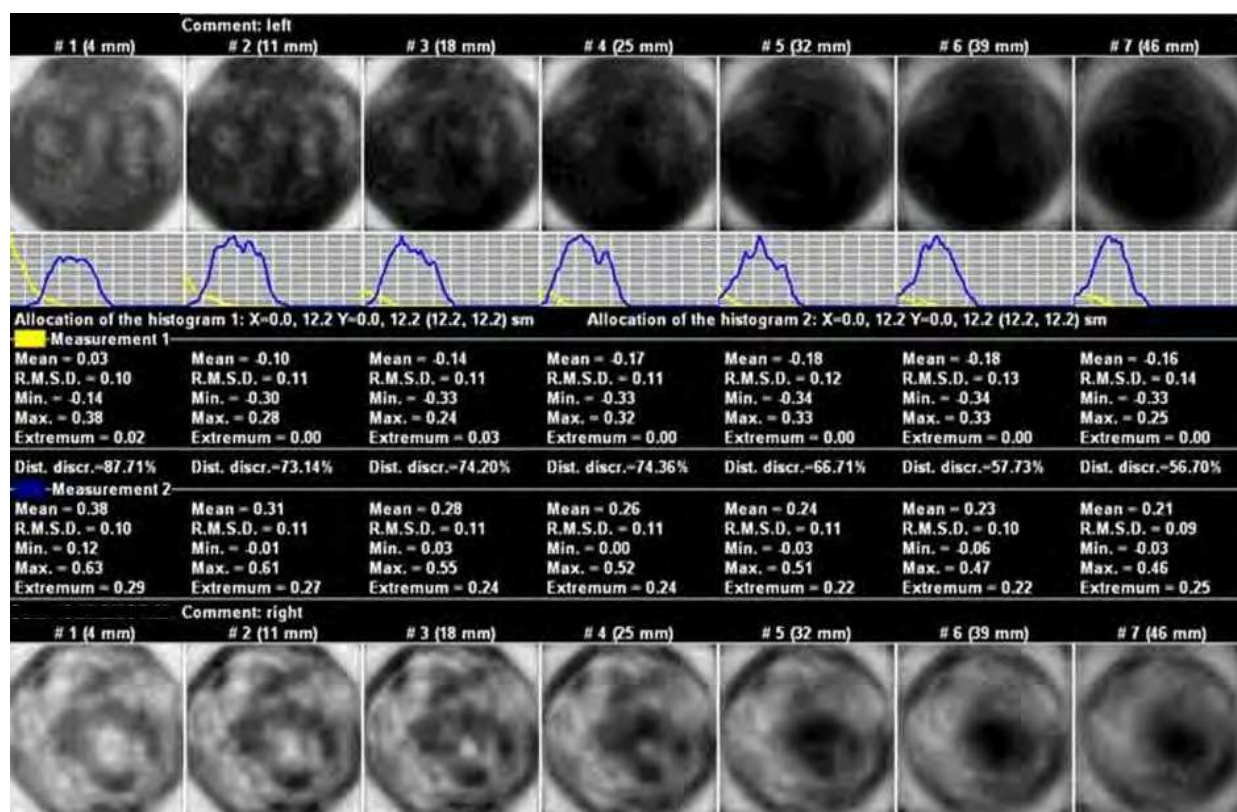


Fig. 33. Upper row - EIM. Seven scan planes. Breast cancer. Bottom row - EIM. Seven scan planes. Healthy gland. The second row shows the divergence between the histograms of electrical conductivity distribution of the affected and healthy gland.

7. Diagnostic criteria for electrical impedance mammography

In order to sort out the diagnostic criteria the diagnostic chart was created, in which each criterion was measured in points (Table 4).

Using the numerical score for evaluation of volumetric and non-volumetric lesions within the mammary gland in electrical impedance mammography allowed comparing this information to BI-RADS ACR categories (See Table 5).

The above description of the system of images and diagnostic criteria for electrical impedance mammography provides diagnostics of various breast diseases, including neoplastic, inflammatory, dishormonal and other disorders. However, we believe the detection of breast cancer at early stages to be the high-priority of the method. The basic features of electrical impedance mammography in early diagnostics of breast cancer are the following.

8. Early diagnostics of breast cancer

If the method of diagnostics under examination permits to acquire a numerical result, the so-called "breaking point" (the value exceeding of which is considered as a sufficient cause for qualitative assessment) should be determined. In this case the estimation of diagnostic

Diagnostic criteria	Electrical impedance mammography points
Shape	
round, oval	1
lobular, irregular	2
Contour	
sharp	1
hyperimpedance, indistinct	2
Surrounding tissues	
preserved	0
structure alteration/displacement	1
thickening/extrusion/retraction	2
Internal electrical structure	
hyperimpedance (IC <0.2)	0
iso- and hypoimpedance (IC = 0.3-0.8)	1
animpedance (IC > 0.90)	2
Comparative electrical conductivity	
divergence between the histograms < 30%	0
divergence between the histograms 30-40 %	1
divergence between the histograms > 40%	2

Table 4. Diagnostic criteria for differentiating volumetric lesions in electrical impedance mammography.

EIM	ACR
<i>Common scale</i>	<i>BI-RADS categories</i>
no score	BI-RADS 0 poor image
0-1	BI-RADS 1 lesion is not defined
2-3	BI-RADS 2 benign tumours - routine mammography
4	BI-RADS 3 probably benign findings
5-7	BI-RADS 4 suspicious abnormality - biopsy
8-10	BI-RADS 5 highly suggestive of malignancy - treatment/biopsy

Table 5. EIM numerical score allows for standardizing the description of volumetric lesions and for the usage of patient monitoring algorithm, developed by the American College of Radiology in electrical impedance mammography.

technique efficiency may be limited to sensitivity and specificity assessment. The diagnostic criterion when screening for early stages of breast cancer is the following: high electrical conductivity areas (above 0.95 cu) outside the lactiferous sinus zone - the so-called animpedance areas, which differ markedly from electrical conductivity of healthy mamma's areas (Fig. 34).

It seems that membrane permeability increase is necessary in both directions to support vital activity of dedifferentiated cells during the intraductal stage of oncologic process. The membrane permeability of cancer cells during intraductal and early extraductal stage increases both for chemical compounds and electric charges. This process results in increase of electrical conductivity.

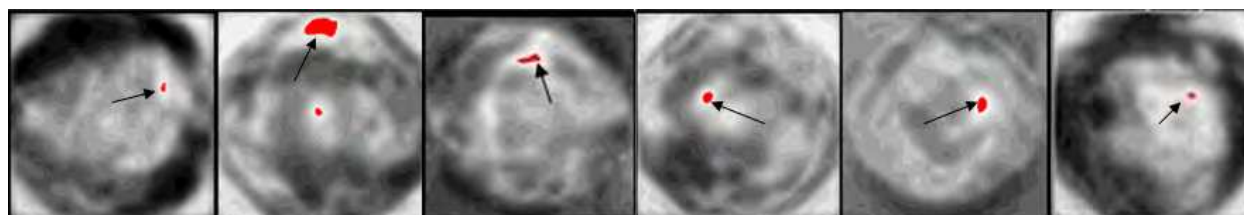


Fig. 34. High electrical conductivity area (above 0.95 cu) outside the lactiferous sinus zone, which is highlighted with red (indicated with arrows).

The example of electrical impedance diagnostic. Figure 35 represents the electrical impedance mammogram of a patient. There can be distinguished a focal lesion, in the form of an impedance area, highlighted with red, with electrical conductivity index over 0.95 conditional units. This is the criterion for early diagnostics of breast cancer. Roentgenogram and US image of the same mammary gland are represented below (Fig. 36).

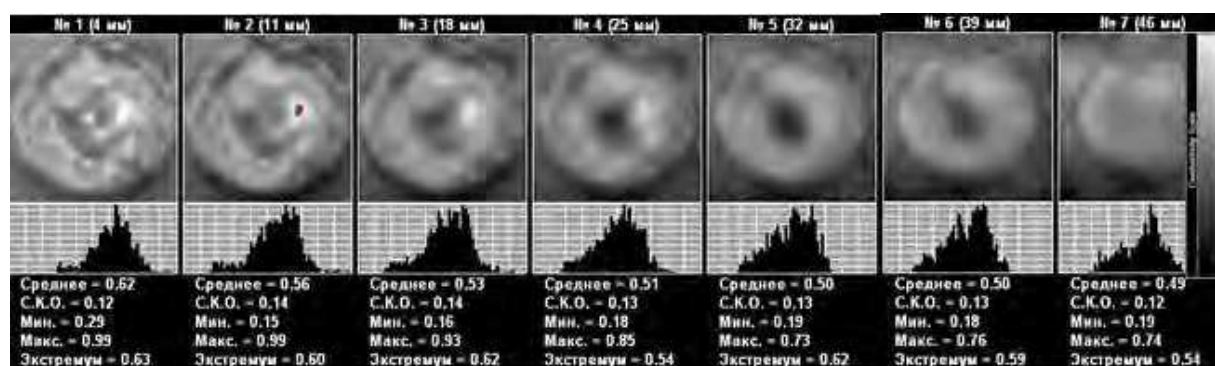


Fig. 35. EIM. Amorphous type of mammary gland structure. In the outer segment of the left mammary gland, at 3 o'clock position there is observed an impedance area, which is highlighted with red in the second scan plane, less than 10 mm in size.

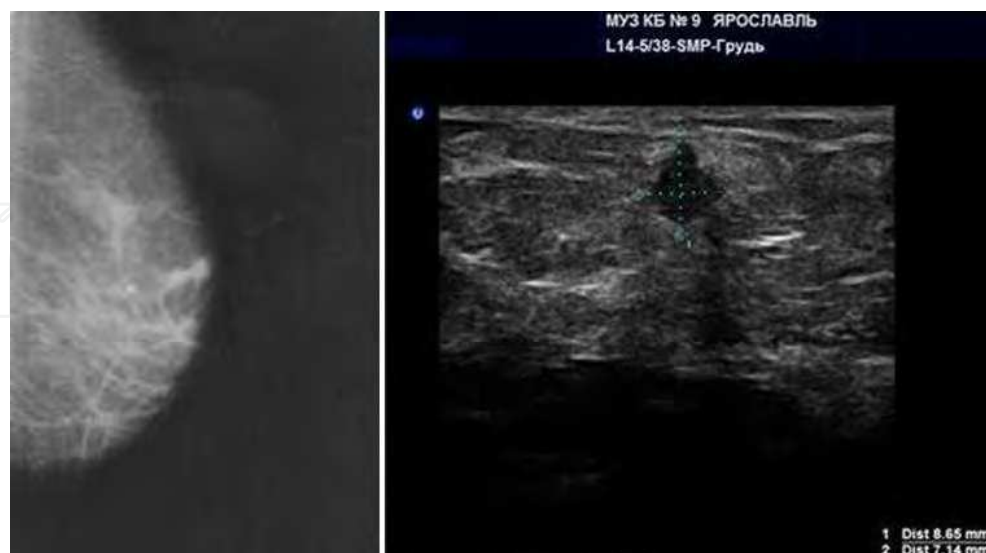

Fig. 36. Roentgenogram (left): fibro-fatty involution. In upper-outer segment there is observed a lesion up to 1 cm in size with a radiant contour. Ultrasound (right): The structure of parenchyma with adipose lobules and connective tissue layers. An inhomogeneous 8x7 mm lesion of irregular shape is located at 28 mm distance from the nipple and at 12 mm depth.

With such a breaking point the sensitivity and specificity of electrical impedance mammography are quite high: sensitivity is 84-93%, specificity – 87-99% (according to the data given by different authors).

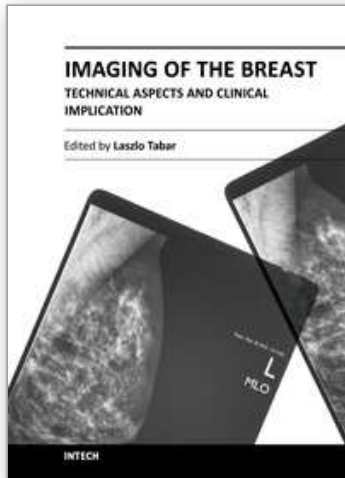
Impedance mammography is in the beginning of its development. The authors sincerely hope that their modest paper will help to arouse interest of a wide range of medical researchers.

9. Acknowledgement

The authors would like to express their gratitude to radiologists A. Bulatov and A. Frizyuk, oncologists N. Sotskova and S. Korotkov as well as to all the staff of PKF "SIM-technika" for their help in conducting clinical trials.

10. References

- Glants S. Medical and Biological Statistics. McGraw-Hill, 1994
- Gubler E. Quantitative methods for analysis and identification of pathology. Leningrad, 1978
- Karpov A.; Korotkova M., Mumtazuddin Ahmed M., Myachin M., Tsofin Yu. Seminar on electrical impedance potential mammography. Yaroslavl, 2011, Biomedical Engineering, v24/is4-6, 1996
- Cherepenin V.; Karpov A., Korjnevsky A., Kornienko V., Mazaletskaya A., Mazurov D. A 3D electrical impedance tomography (EIT) system for breast cancer detection. *Physiological Measurement*. 2001, 22, 9-18.
- Dunaeva O.; Gerasimov D., Karpov A., Machin M., Tchayev A., Tsofin Yu., Tsyplyonkov V. Using Backprojection Algorithm for 3D Image Reconstruction in EIT. *World Congress on Medical Physics and Biomedical Engineering, Munich, Germany, 2009, Electrical Impedance Tomography*. IOP, 2005
- Karpov A.; Korjnevsky A., Mazurov D., Mazaletskaya A. 3D Electrical Impedance Scanning of Breast Cancer. *World Congress on Medical Physics and Biomedical Engineering, Chicago, 2000*, p.62
- Korotkova M.; Karpov A. Procedure for assessment of the mammary gland electrical impedance images. *XIII international conference on electrical bio-impedance*. Graz, Austria, 2007.
- Mumtazuddin Ahmed M. Histology functional and Clinical. HEC Islamabad, 2009



Imaging of the Breast - Technical Aspects and Clinical Implication

Edited by Dr. Laszlo Tabar

ISBN 978-953-51-0284-7

Hard cover, 224 pages

Publisher InTech

Published online 16, March, 2012

Published in print edition March, 2012

Early detection of breast cancer combined with targeted therapy offers the best outcome for breast cancer patients. This volume deal with a wide range of new technical innovations for improving breast cancer detection, diagnosis and therapy. There is a special focus on improvements in mammographic image quality, image analysis, magnetic resonance imaging of the breast and molecular imaging. A chapter on targeted therapy explores the option of less radical postoperative therapy for women with early, screen-detected breast cancers.

How to reference

In order to correctly reference this scholarly work, feel free to copy and paste the following:

Marina Korotkova and Alexander Karpov (2012). Standards for Electrical Impedance Mammography, Imaging of the Breast - Technical Aspects and Clinical Implication, Dr. Laszlo Tabar (Ed.), ISBN: 978-953-51-0284-7, InTech, Available from: <http://www.intechopen.com/books/imaging-of-the-breast-technical-aspects-and-clinical-implication/standards-for-electrical-impedance-mammography>

INTECH
open science | open minds

InTech Europe

University Campus STeP Ri
Slavka Krautzeka 83/A
51000 Rijeka, Croatia
Phone: +385 (51) 770 447
Fax: +385 (51) 686 166
www.intechopen.com

InTech China

Unit 405, Office Block, Hotel Equatorial Shanghai
No.65, Yan An Road (West), Shanghai, 200040, China
中国上海市延安西路65号上海国际贵都大饭店办公楼405单元
Phone: +86-21-62489820
Fax: +86-21-62489821

© 2012 The Author(s). Licensee IntechOpen. This is an open access article distributed under the terms of the [Creative Commons Attribution 3.0 License](#), which permits unrestricted use, distribution, and reproduction in any medium, provided the original work is properly cited.

IntechOpen

IntechOpen