

We are IntechOpen, the world's leading publisher of Open Access books Built by scientists, for scientists

4,800

Open access books available

122,000

International authors and editors

135M

Downloads

Our authors are among the

154

Countries delivered to

TOP 1%

most cited scientists

12.2%

Contributors from top 500 universities



WEB OF SCIENCE™

Selection of our books indexed in the Book Citation Index
in Web of Science™ Core Collection (BKCI)

Interested in publishing with us?
Contact book.department@intechopen.com

Numbers displayed above are based on latest data collected.

For more information visit www.intechopen.com



Management of Early-Stage Tongue Cancer

Kiyoto Shiga, Katsunori Katagiri,
Ayako Nakanome, Takenori Ogawa and Toshimitsu Kobayashi
*Department of Otolaryngology-Head and Neck Surgery, Tohoku University Hospital,
Japan*

1. Introduction

In general, tongue cancer is usually treated surgically and additional therapy is carried out if patients have advanced cancers. Although surgical treatment is performed at the early stage of tongue cancer, still some problems emerge, such as late cervical lymph node metastasis and elective neck dissection. We previously recommended elective neck dissection for patients with T2 tongue cancers (Tateda et al., 2000). However, the range of tumor sizes that would require elective neck dissection remains to be determined.

Between 2001 and 2005, a total of 43 patients with oral tongue cancers were treated at Tohoku University Hospital. As for our patients with T2 N0 cancer, the pathological examination results revealed that 3 (43%) of the 7 patients who underwent elective neck dissection (late T2) had a lymph node metastasis. On the other hand, 4 of the 6 patients who did not undergo elective neck dissection in the first surgery (early T2) had a recurrence at the neck. In total, 7 (54%) of the 13 patients who were found to have T2 N0 tongue cancers developed lymph node metastases after the initial treatment. When there was a regional recurrence, salvage therapies were conducted. However, 3 of the 4 patients with early T2 who had a regional recurrence died of the disease. These data indicate that elective neck dissection should be considered for treating patients with T2 N0 tongue cancer to improve the poor prognoses associated with not undergoing elective neck dissection. We also investigated the relationship between nodal metastasis and tumor diameter and depth of tumor invasion. There was a significant difference between the frequency of the nodal metastasis in the patients with tumors less than 4 mm in depth and that in patients with tumors greater than 4 mm in depth, indicating that the depth of the tumor invasion is a critical factor for lymph node metastasis (Shiga et al., 2007).

Since 2005, we had been treating patients with T2 N0 tongue cancers by surgical removal of the tumor, that is, partial glossectomy and elective neck dissection. The improvement of the treatment results and the prognoses of the patients with early-stage oral tongue cancers are described and discussed.

2. Background

Tongue cancer is the most common type of oral cancer worldwide, and the majority of cases are defined as early cancer lesions. Because a standardized treatment strategy has not yet

been developed, various therapies such as surgery, brachytherapy, chemotherapy, and radiation therapy are chosen to treat patients with tongue cancers in different hospitals. In our hospital, tongue cancer is usually treated surgically and additional therapy is conducted for patients with advanced clinical stage diseases. Elective neck dissection as a treatment for patients with early-stage oral tongue cancers and clinically normal necks remains a controversial issue (Haddadin et al., 1999; Hughes et al., 1993; Keski-Santti et al., 2006; O'Brien et al., 1986; Veness et al., 2005; Yuen et al., 1997). Several reports have described the results of immediate elective neck dissection versus delayed elective neck dissection, that is, performing the surgery after the patient is observed or watched to have developed of early-stage N0 tongue cancers, and it has been reported that the survival rate of "watched" patients was worse than that of patients having elective neck dissection (Cunningham et al., 1986; Ho et al., 1992; Lydiatt et al., 1993; Persky and Lagmay, 1999; Yuen et al 1997).

There have been several reports about histopathological parameters that predict neck metastasis of tongue cancer. Among these parameters, tumor thickness and depth of invasion have been studied and have often been documented (Asakage et al., 1998; Brown et al., 1989; Byers et al., 1998; Fukano et al., 1997; Jones et al., 1992; Lim et al., 2004; Rasgon et al., 1989; Sparano et al., 2004; Spiro et al., 1986). However, indications for elective neck dissection according to tumor thickness or depth of invasion have not yet been previously reported. Perhaps this is because of the clinical difficulty in accurately measuring tumor thickness and depth of invasion before the initial treatment.

We investigated the size of tongue cancers that require neck dissection. In our study from 2001 through 2005, the patients with N0 tumors smaller than 30 mm in diameter (T1 and early T2) underwent only partial glossectomy. The patients with N0 tumors larger than 30 mm in diameter (late T2) underwent partial glossectomy and elective neck dissection. As described in the following discussion, the patients with early T2 tumor had poorer outcomes because they had regional recurrences and distant metastases. In our study after 2005, the patients with T2 N0 tumors underwent partial glossectomy and elective neck dissection and showed remarkably better prognoses.

In addition, our results indicated that tumor thickness is a critical indicator of cervical lymph node metastasis in patients with T1 or T2 tongue cancers because a significant difference was observed even in our small number of patients.

3. 2001 series

3.1 Patients and methods

Between November 2001 and June 2005, 43 patients with tongue carcinomas were treated at the Tohoku University Hospital. None of the patients had distant metastasis at the time of first admission to the hospital. The tumors were defined according to the TNM classification by clinical examination, and computed tomographic (CT) scan and/or magnetic resonance imaging (MRI) findings. There were 8 patients with T1 N0 tumors (stage I) and 13 patients with T2 N0 tumors (stage II). There were 26 male and 17 female patients. The median patient age was 59 years (range, 24–86 years). All but 1 of the patients were found to have squamous cell carcinomas by histopathological examination. One patient with a T1 N0 tumor had a verrucous carcinoma of the tongue.

In our hospital, the initial treatment for early-stage tongue cancer is surgical resection of the primary tumor, that is, partial glossectomy with or without neck dissection. The neck dissection conducted for the patients with late T2 N0 tumors was supraomohyoid neck dissection (SOND). If a recurrent tumor was found in the neck after the surgery in the patients who did not undergo neck dissection at the first surgery, a neck dissection was conducted if possible. If a surgical resection was not possible, the patients were treated mainly by radiation therapy. If distant metastases were found, the patients were treated mainly by chemotherapy by using Docetaxel, cisplatin, and 5-fluorouracil.

The statistical analyses of the data were performed by the chi-square test and the Student *t* test. All the follow-up data were updated at the end of May 2006. The survival curves of the patients were calculated using the Kaplan–Meier method based on the first day of the patients' admission to the hospital. The survival curves were subjected to a log-rank test and the generalized Wilcoxon test.

3.2 Results

The characteristics and the outcomes of the patients with T1 N0 tumors were evaluated. One patient had a recurrent tumor in the ipsilateral neck (rN1) and underwent modified radical neck dissection. The other 9 patients with T1 N0 tumors had not encountered any recurrent tumors. The characteristics and the outcomes of the patients with T2 N0 tumors were also evaluated. One patient had a recurrent tumor in the neck (N3), which was not resectable. Although the patient underwent chemoradiation therapy, the neck tumor was not controlled by the therapy, and the patient died of the disease 11 months after the first treatment. Another patient also had a recurrent neck tumor (rN2a), and she underwent radical neck dissection 7 months after the first surgery. Although her neck tumor was completely resected and she had no recurrence, she had multiple lung metastases and died 19 months after the first treatment. However, another patient also had a recurrent neck tumor (rN2b), and he underwent radical neck dissection 12 months after the first surgery. Although his neck tumor was completely resected and he had no recurrence, he had multiple brain metastases and died of the disease 25 months after the first treatment. At 40 months, as determined by the Kaplan–Meier analysis, the disease-free survival rates of the patients with T1 N0 tumors and the patients with T2 N0 tumors were 100% and 60%, respectively (Shiga et al., 2007). There were no significant differences in survival rates between these 2 groups.

The depth of invasion of the tumors and their diameters were analyzed according to the existence of lymph node metastases. The analysis included all the patients with T1 or T2 tumors ($n = 15$ and 15 , respectively). The diameters of the tumors ranged from 7 to 38 mm (mean, 23 mm) for the tumors without lymph node metastases, whereas they ranged from 15 to 35 mm (mean, 27 mm) for the tumors with lymph node metastases. There was no significant difference in diameter between these two groups. The depths of the tumors ranged from 1 to 17 mm (mean, 7.0 mm) for tumors without lymph node metastases, whereas they ranged from 4 to 22 mm (mean, 10.3 mm) for tumors with lymph node metastases. The shortest depth of tumor invasion that led to lymph node metastasis was 4 mm, and no lymph node metastases were observed in the patients whose tumors were shorter than 4 mm in depth of invasion. There was a significant difference between the frequencies of nodal metastasis in the patients with tumors less than 4 mm thick and those

of the patients with tumors greater than 4 mm thick ($p = 0.013$). There was no significant difference in the frequencies of lymph node metastasis between the groups according to age, sex, or histopathological differentiation of squamous cell carcinoma, except for depth of invasion.

4. 2005 series

4.1 Patients and methods

Between July 2005 and June 2010, 75 patients with tongue carcinomas were treated at the Tohoku University Hospital. One patient had distant metastasis at the time of first admission to the hospital. Table 1 shows the TN classification of the patients with T1 and T2 tumors at the time of initial treatment. The tumors were defined according to the TNM classification by clinical examination, CT scan and/or MRI findings, and ^{18}F -fluorodeoxy glucose-positron emission tomography (FDG-PET). There were 16 patients with T1 N0 tumors (stage I) and 20 patients with T2 N0 tumors (stage II). There were 49 male and 26 female patients. The mean and median patient ages were 60.3 and 62 years, respectively (range, 24-86 years). All of the patients were found to have squamous cell carcinomas by histopathological examination.

	N0	N1	N2a	N2b	N2c	N3	
T1	16	1	0	0	0	0	17
T2	20	6	0	6	1	0	33
	36	7	0	6	1	0	50

Table 1. TN classification of the patients with T1 and T2 tongue cancers.

The treatment strategy was the same as that described previously except for the T2 N0 tumors. All of the patients who initially had T2 N0 tongue cancer underwent partial glossectomy and elective neck dissection.

The statistical analyses of the data were performed by the chi-square test and the Student t test. All the follow-up data were updated at the end of July 2011. The survival curves of the patients were calculated using the Kaplan–Meier method based on the first day of the patient's admission to the hospital. The survival curves were subjected to a log-rank test and the generalized Wilcoxon test.

4.2 Results

The characteristics and the outcome of the patients with T2 N0 tumors are summarized in Table 2. Four patients (patients 5, 7, 11, and 12) had lymph node metastases, which were revealed by the pathological examination results after the initial surgery. Patient 5 died of lung cancer 7 months after the surgery. Patient 7 had a local recurrence 4 months after the first surgery, and he hoped to receive brachytherapy in another hospital. Patient 16 had local recurrence, and resurgery was conducted. However, she died of lung and liver metastases 7 months after the second surgery. Patient 20 had recurrent neck tumors, but she did not see

doctors until the tumor was unresectable. She was provided with the best supportive care. The follow-up data of the patients during the period 2021–2005 were updated at the end of July 2011, and the disease-free survival curves of the patients were calculated by Kaplan–Meier analysis. The disease-free survival rates at 60 months of the patients with T2 N0 tumors during the period of 2001–2005 and those during the period of 2005–2010 were 71.6% and 86.7%, respectively (Figure 1). There were no significant differences in disease-free survival rates between these 2 groups.

	Age	Gender	cTN	pTN	Differen- tiation	Diameter (mm)	Depth (mm)	Outcome
1	56	M	T2N0		MOD	26	7	NER
2	55	M	T2N0		*	*	*	NER
3	70	M	T2N0		WELL	38	18	NER
4	33	M	T2N0		WELL	27	9	NER
5	75	M	T2N0	T2N2b	MOD	*	10	7M, DND (lung cancer)
6	84	M	T2N0		WELL	30	8	NER
7	31	M	T2N0	T2N1	WELL	28	11	4M, local rec
8	68	M	T2N0		WELL	35	15	NER
9	73	F	T2N0		WELL	38	11	NER
10	28	M	T2N0		MOD	23	4	NER
11	75	M	T2N0	T2N1	POOR	39	15	NER
12	62	M	T2N0	T2N1	WELL	21	5	NER
13	59	M	T2N0		WELL	25	1	NER
14	61	M	T2N0		WELL	21	6	NER
15	24	M	T2N0		WELL	37	9	NER
16	58	F	T2N0		POOR	23	12	6M, local rec, surgery, 15M,DOD (lung & liver meta)
17	80	M	T2N0		WELL	23	6	NER
18	65	M	T2N0		MOD	25	5	NER
19	42	M	T2N0		MOD	26	8	NER
20	74	F	T2N0		WELL	36	15	18M, DOD (regional rec)

WELL, well differentiated squamous cell carcinoma; MOD, moderately differentiated squamous cell carcinoma; Poor, poorly differentiated squamous cell carcinoma; NER, no evidence of recurrence; DND, died not of disease; DOD, died of disease; M, months; rec, recurrence; meta, metastases. The asterisk indicates not determined. All patients underwent supraomohyoid neck dissection at surgery.

Table 2. Clinical features of patients with T2N0 tongue cancers.

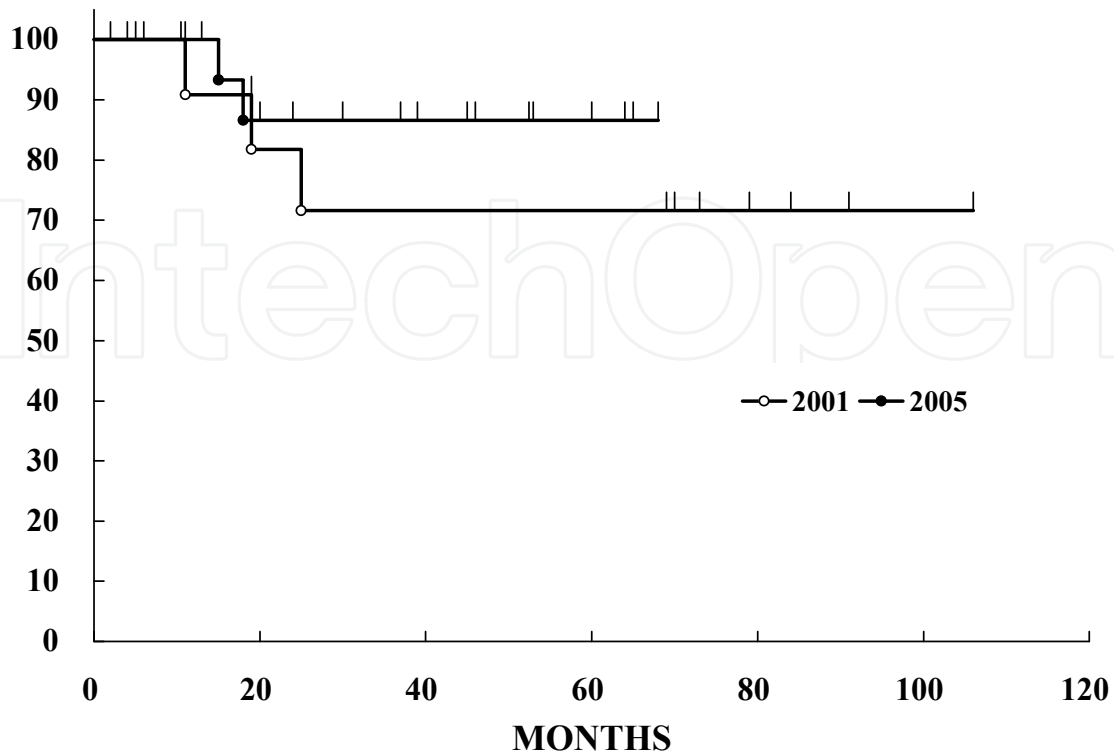


Fig. 1. Disease-free survival curve of the patients with T2 N0 tongue cancers. *Open circle*, the patients treated from 2001 to 2005; *closed circle*, the patients treated from 2005 to 2010.

5. Discussion - Management of early-stage oral tongue cancer

As for our T2 N0 cases between 2001 and 2005, the pathological examination results revealed that 3 (43%) of the 7 patients who underwent elective neck dissection (late T2) had a lymph node metastasis. On the other hand, 4 (67%) of the 6 patients who did not undergo elective neck dissection at the first surgery (early T2) had a recurrence at the neck. In total, 7 (54%) of the 13 patients who were initially found to have clinical T2 N0 tongue cancers had lymph node metastases at the time of initial treatment or afterwards. When the patients with T1 N0 and T2 N0 tumors were included, 5 (36%) of the 14 patients who did not undergo elective neck dissection at the time of the first surgery (T1 N0 + early T2 N0) had recurrences at the neck. This regional recurrence rate was as high as that reported previously (Cunningham et al., 1986; Haddadin et al., 1999; Ho et al., 1992; Keski-Santti et al., 2006; Yuen et al., 1997). When there was a regional recurrence, salvage therapies, such as neck dissection and/or radiation, and chemotherapy were conducted. Three of the 4 patients with early T2 cancer who had a regional recurrence died of the disease. The reasons for their deaths were uncontrolled regional recurrence, lung metastasis, and brain metastasis. These results indicated a poor survival rate of the patients with T2 N0 cancer in our 2001–2005 series, indicating that elective neck dissection is necessary for a good outcome in patients with T2 N0 tongue cancers. At this time, we concluded that elective neck dissection was necessary for the patients with clinical T2 N0 tumors because of the unexpectedly high incidences of regional lymph node metastases and the very poor prognoses of the patients with early T2 tumors.

In contrast to the patients with T2 N0 tumors during the period between 2001 and 2005, the recurrence of the tumors were observed in only 3 of the 20 patients with clinical T2 N0 tongue cancers in our 2005–2010 series. Two of them had a local recurrence after the initial treatment, and the other patient had a regional recurrence. The pathological examination results revealed that 20% (4 of the 20 patients) of the cases initially diagnosed as clinical T2 N0 tongue cancer had lymph node metastases, and this rate was lower than that of the cases in our 2001–2005 series. We assumed that one of the reasons why the frequencies of lymph node metastasis found by pathological examination of the surgical specimens were reduced was the introduction of the use of FDG-PET in the initial diagnostic examination of the patients with tongue cancers. We experienced some cases that were diagnosed as T2 N2c M0 tongue cancer and treated by surgery, with no lymph node metastasis found in the specimens. Although in some cases, overdiagnosis in the patients were obvious, in most of the cases, lymph node metastases were detected accurately by FDG-PET imaging. It should be revealed that accurate diagnosis is made by several modalities, such as CT scan, MRI, ultrasonography, and FDG-PET, by using these modalities effectively.

We conclude that elective neck dissection is necessary for patients with T2 N0 tumors because of the unexpectedly high frequency of regional lymph node metastases of T2 N0 tumors and the very poor prognoses of patients with early T2 tumors who did not undergo elective neck dissection.

As described in previous studies, the focus was on tumor thickness and depth of invasion as histopathological parameters that predict neck metastases of tongue cancers. There have been studies well documented in several literatures (Asakage et al 1998; Brown et al 1989; Byers et al 1998; Fukano et al 1997; Jones et al 1992; Lim et al 2004; Rasgon et al 1989; Sparano et al 2004; Spiro et al., 1986). However, indications for elective neck dissection according to tumor thickness or depth of invasion have not been previously reported. Perhaps this is because of the clinical difficulty in accurately measuring tumor thickness and depth of invasion before the initial treatment. Indeed, as a significant difference was observed even in our small number of patients, tumor thickness is a critical indicator of cervical lymph node metastasis in patients with T1 or T2 tongue cancers. There were some probes engineered using ultrasound sonography to detect tumors in oral cavities (Kodama et al., 2010; Yuen et al., 2008). We think these new modalities of ultrasound sonography and MRI findings are the powerful tools for detecting tumor thickness or depth of invasion of the tumors in the oral cavity. Investigating tumor thickness or depth of invasion before surgery, we could appropriately indicate surgery for patients with N0 tongue cancers. If the tumor is thick or invasion is deep, we must conduct elective neck dissection for the patients, even for those with T1 N0 tongue cancers.

6. Conclusion

Elective neck dissection is needed for patients with T2 N0 tongue cancers to reduce the rate of recurrence and improve the prognosis of the patients. At the same time, accurate diagnosis of the lymph node metastasis of the patients by several modalities including FDG-PET should be made to reduce the rate of misdiagnosis. Depth of the invasion of the tumor is a critical marker for the lymph node metastasis of patients with tongue cancers.

7. References


- Asakage, T., Yokose, T., Mukai, K., Tsugane, S., Tsubono, Y., Asai, M., & Ebihara, S. (1998). Tumor thickness predicts cervical metastasis in patients with stage I/II carcinoma of the tongue. *Cancer*, Vol. 82, No. 8, (April 1998), pp. 1443-1448, ISSN 1097-0142
- Brown, B., Barnes, L., Mazariegos, J., Taylor, F., Johnson, J., & Wagner, R.L. (1989). Prognostic factors in mobile tongue and floor of mouth carcinoma. *Cancer*, Vol. 64, No. 6, (September 1989), pp. 1195-1202, ISSN 1097-0142
- Byers, R.M., El-Naggar, A.K., Lee, Y.Y., Rao, B., Fornage, B., Terry, N.H., Sample, D., Hankins, P., Smith, T.L., & Wolf, P.J. (1998). Can we detect or predict the presence of occult nodal metastases in patients with squamous cell carcinoma of the oral tongue? *Head & Neck*, Vol. 20, No. 2, (March 1998), pp. 138-144, ISSN 1097-0347
- Cunningham, M.J., Johnson, J.T., Myers, E.N., Schramm, V.L. Jr., & Thearle, P.B. (1986). Cervical lymph node metastasis after local excision of early squamous cell carcinoma of the oral cavity. *American Journal of Surgery*, Vol. 152, No. 4, (October 1986), pp. 361-366, ISSN 0002-9610.
- Fukano, H., Matsuura, H., Hasegawa, Y., & Nakamura, S. (1997). Depth of invasion as a predictive factor for cervical lymph node metastasis in tongue carcinoma. *Head & Neck*, Vol. 19, No. 3, (May 1997), pp. 205-210, ISSN 1097-0347
- Haddadin, K.J., Souter, D.S., Oliver, R.J., Webster, M.H., Robertson, A.G., & MacDonald, D.G. (1999). Improved survival for patients with clinically T1/T2, N0 tongue tumors undergoing a prophylactic neck dissection. *Head & Neck*, Vol. 21, No. 6, (September 1999), pp. 517-525, ISSN 1097-0347
- Ho, C.M., Lam, K.H., Wei, W.I., Lau S.K., & Lam, L.K. (1992). Occult lymph node metastasis in small oral tongue cancers. *Head & Neck*, Vol. 14, No. 5, (September-October 1992), pp. 359-363, ISSN 1097-0347
- Hughes, C.J., Gallo, O., Spiro, R.H., & Shah, J.P. (1993). Management of occult neck metastases in oral cavity squamous cell carcinoma. *American Journal of Surgery*, Vol. 166, No. 4, (October 1993), pp. 380-383, ISSN 0002-9610
- Jones, K.R., Lodge-Rigal, R.D., Reddick, R.L., Tudor, G.E., & Shockley, W.W. (1992). Prognostic factors in the recurrence of stage I and II squamous cell cancer of the oral cavity. *Archives of Otolaryngology – Head & Neck Surgery*, Vol. 118, No. 5, (May 1992), pp. 483-485, ISSN 0886-4470
- Keski-Santti, H., Atula, T., Tornwall, J., Koivunen, P., & Makitie A. (2006). Elective neck treatment versus observation in patients with T1/T2 N0 squamous cell carcinoma of oral tongue. *Oral Oncology*, Vol. 42, No. 1, (January 2006), pp. 96-101, ISSN 1368-8375
- Kodama, M., Khanal, A., Habu, M., Iwanaga, K., Yoshioka, I., Tanaka, T., Morimoto, Y., & Tominaga, K. (2010). Ultrasonography for intraoperative determination of tumor thickness and resection margin in tongue carcinomas. *Journal of Oral and Maxillofacial Surgery*, Vol. 68, No. 8, (August 2010), pp. 1746-1752, ISSN 0278-2391

- Lim, S.C., Zhang, S., Ishii, G., Endoh, Y., Kodama, K., Miyamoto, S., Hayashi, R., Ebihara, S., Cho, J.S., & Ochiai, A. (2004). Predictive markers for late cervical metastasis in stage I and II invasive squamous cell carcinoma of the oral tongue. *Clinical Cancer Research*, Vol. 10, No. 1, (January 2004), pp. 166-172, ISSN 1078-0432
- Lydiatt, D.D., Robbins, K.T., Byers R.M., & Wolf, P.F. (1993). Treatment of stage I and II oral tongue cancer. *Head & Neck*, Vol. 15, No. 4, (July-August 1993), pp. 308-312, ISSN 1097-0347
- O'Brien, C.J., Lahr, C.J., Soong, S.J., Gandour, M.J., Jones, J.M., Urist, M.M., & Maddox, W.A. (1986). Surgical treatment of early-stage carcinoma of the oral tongue—would adjuvant treatment be beneficial? *Head & Neck Surgery*, Vol. 8, No. 6, (July-August 1986), pp. 401-408, ISSN 0148-6403.
- Persky, M.S., & Lagmay, V.M. (1999). Treatment of the clinically negative neck in oral squamous cell carcinoma. *Laryngoscope*, Vol. 109, No. 1, (July 1999), pp. 1160-1164, ISSN 1531-4995.
- Rasgon, B.M., Cruz, R.M., Hilsinger, R.L. Jr., & Sawicki, J.E. (1989) Relationship of lymph-node metastasis to histopathologic appearance in oral cavity and oropharyngeal carcinoma: a case series and literature review. *Laryngoscope*, Vol. 99, No. 11, (November 1989), pp. 1103-1110, ISSN 1531-4995
- Shiga, K., Ogawa, T., Sagai, S., Kato, K., & Kobayashi, T. (2007) Management of the patients with early stage oral tongue cancers. *The Tohoku Journal of Experimental Medicine*, Vol. 212, No. 4, (August 2007), pp. 389-396, ISSN 0040-8727
- Sparano, A., Weinstein, G., Chalian, A, Yodul, M., & Weber, R. (2004). Multivariate predictors of occult neck metastasis in early oral tongue cancer. *Otolaryngology – Head & Neck Surgery*, Vol. 131, No. 4, (October 2004), pp. 472-476, ISSN 0886-4470
- Spiro, R.H., Huvos, A.G., Wong, G.Y., Spiro, J.D., Gnecco, C.A., & Strong, E.W. (1986). Predictive value of tumor thickness in squamous cell carcinoma confined to the tongue and floor of the mouth. *American Journal of Surgery*, Vol. 152, No. 4, (October 1986), pp. 345-350, ISSN 0002-9610
- Tateda, M., Shiga, K., Saijo, S., & Yokoyama, J. (2000). A clinical study of oral tongue cancer. *The Tohoku Journal of Experimental Medicine*, Vol. 192, No. 1, (September 2000), pp. 49-59, ISSN 0040-8727
- Veness, M.J., Morgan, G.J., Sathiyaseelan, Y., & Gebiski, V. (2005). Anterior tongue cancer and the incidence of cervical lymph node metastases with increasing tumor thickness: should elective treatment to the neck be standard practice in all patients? *ANZ Journal of Surgery*, Vol. 75, No. 3, (March 2005), pp. 101-105, ISSN 1445-1433
- Yuen, A.P., Wei, W.I., Wong, Y.M., & Tang, K.C. (1997). Elective neck dissection versus observation in the treatment of early oral tongue carcinoma. *Head & Neck*, Vol. 19, No. 7, (October 1997), pp. 583-588, ISSN 1097-0347

Yuen, A.P.O., Ng, R.W.M., Lam, P.K.Y., & Ho, A. (2008). Preoperative measurement of tumor thickness of oral tongue carcinoma with intraoral ultrasonography. *Head & Neck*, Vol. 30, No. 2, (February 2008), pp. 230-234, ISSN 1097-0347

IntechOpen

IntechOpen



Oral Cancer

Edited by Dr. Kalu U. E. Ogbureke

ISBN 978-953-51-0228-1

Hard cover, 388 pages

Publisher InTech

Published online 14, March, 2012

Published in print edition March, 2012

Oral cancer is a significant public health challenge globally. Although the oral cavity is easily accessible, early diagnosis remains slow compared to the enhanced detection of cancers of the breast, colon, prostate, and melanoma. As a result, the mortality rate from oral cancer for the past four decades has remained high at over 50% in spite of advances in treatment modalities. This contrasts with considerable decrease in mortality rates for cancers of the breast, colon, prostate, and melanoma during the same period. This book attempts to provide a reference-friendly update on the etiologic/risk factors, current clinical diagnostic tools, management philosophies, molecular biomarkers, and progression indicators of oral cancer.

How to reference

In order to correctly reference this scholarly work, feel free to copy and paste the following:

Kiyoto Shiga, Katsunori Katagiri, Ayako Nakanome, Takenori Ogawa and Toshimitsu Kobayashi (2012). Management of Early-Stage Tongue Cancer, *Oral Cancer*, Dr. Kalu U. E. Ogbureke (Ed.), ISBN: 978-953-51-0228-1, InTech, Available from: <http://www.intechopen.com/books/oral-cancer/management-of-early-stage-tongue-cancer>

INTECH
open science | open minds

InTech Europe

University Campus STeP Ri
Slavka Krautzeka 83/A
51000 Rijeka, Croatia
Phone: +385 (51) 770 447
Fax: +385 (51) 686 166
www.intechopen.com

InTech China

Unit 405, Office Block, Hotel Equatorial Shanghai
No.65, Yan An Road (West), Shanghai, 200040, China
中国上海市延安西路65号上海国际贵都大饭店办公楼405单元
Phone: +86-21-62489820
Fax: +86-21-62489821

© 2012 The Author(s). Licensee IntechOpen. This is an open access article distributed under the terms of the [Creative Commons Attribution 3.0 License](#), which permits unrestricted use, distribution, and reproduction in any medium, provided the original work is properly cited.

IntechOpen

IntechOpen