

# We are IntechOpen, the world's leading publisher of Open Access books Built by scientists, for scientists

**4,800**

Open access books available

**122,000**

International authors and editors

**135M**

Downloads

Our authors are among the

**154**

Countries delivered to

**TOP 1%**

most cited scientists

**12.2%**

Contributors from top 500 universities



**WEB OF SCIENCE™**

Selection of our books indexed in the Book Citation Index  
in Web of Science™ Core Collection (BKCI)

Interested in publishing with us?  
Contact [book.department@intechopen.com](mailto:book.department@intechopen.com)

Numbers displayed above are based on latest data collected.

For more information visit [www.intechopen.com](http://www.intechopen.com)



## Diagnostic Aids in Oral Cancer Screening

Pegah Mosannen Mozafari, Zahra Delavarian and Nooshin Mohtasham  
*Oral and Maxillofacial Diseases Research Center, Mashhad Dental Faculty,  
 Mashhad University of Medical Sciences, Mashhad,  
 Iran*

### 1. Introduction

At the world level, head and neck cancer is the sixth most common cancer (Fedele 2009). Oral squamous cell carcinoma (OSCC) accounts for about 40% of head and neck and 90-95% of oral malignancies (Neville et al. 1995; Pektas et al. 2006). OSCC is preceded by visible changes in the oral mucosa, such as: white plaque, redness, ulcer or exophytic lesion, with no other signs/symptoms. (Delavarian et al. 2010). If OSCC is diagnosed and treated in this stage, it will be curable and inexpensive to treat with excellent treatment outcomes and survival (Rosenberg and Cretin 1989).

Five-year survival is about 76% to 80% if diagnosis is performed in stage 1 and 2. Late diagnosis in stage 3 and 4 can decrease this value to 41% and 9% respectively (Mashberg and Feldman 1988; Neville et al. 1995; Maraki, Becker, and Boecking 2004; Pektas et al. 2006). At this time, metastasis to regional lymph nodes has occurred and cancer cannot be treated without undesirable complications and morbidity (such as mucosities, xerostomia, surgical defect, etc...). Unfortunately majority of cases are diagnosed at stage 3 and 4 with more than 50% of them exhibiting metastatic lymphadenopathy (Eisenbud and Sciubba 1978). Despite advances in diagnostic procedures in medical practice, mortality of OSCC has remained unchanged in the past 40 years and a significant diagnostic delay (up to 8 months) has persisted over time. (Abdo et al. 2007; Peacock, Pogrel, and Schmidt 2008) For example, the mortality rate for oral cancer is similar to that of colon cancer even though it is much easier to screen and detect oral cancers than it is for colon cancer. The most important factor in patient survival and prognosis is early diagnosis. Studies have shown that most OSCC could have been detected 3 to 7 month earlier by a trained dentist (Bruun 1976), but as mentioned, 50% of patients have regional or distant metastasis at the time of diagnosis (Acha 2005; Fedele 2009). There are some reasons for this delay (Wood and Goaz 1997; Abdo et al. 2007; Peacock, Pogrel, and Schmidt 2008;):

1. Lack of public awareness about signs, symptoms and risk factors of oral cancer.
2. Absence of routine oral examination in at least 50% of public.
3. Absence of symptoms in early stages of oral cancer.
4. Development of cancer in parts of oral cavity which normally escape inspection by the patients and/or physician (e.g. floor of the mouth).
5. Similarity of lesions to benign ones (e.g.; candidiasis, recurrent aphthous stomatitis, etc.).
6. Absences of prevention and early detection by health care providers (e.g. lack of knowledge and ability to recognize oral cancer in early stages and absence of generally accepted screening tests which can be easily performed by general dentists).

OSCC very often arises from an oral premalignant lesion (OPL). OPL is defined as a benign, morphologically altered tissue that has a greater than normal risk of malignant transformation (Neville et al. 1995). Erythroplakia, leukoplakia, oral lichen planus and oral submucous fibrosis are examples of OPL. Erythroplakia either isolated or concomitant with leukoplakia may show severe dysplasia or carcinoma *In Situ*. Indeed 90% of erythroplakia lesions are histologically diagnosed as carcinoma *In Situ* or cancer (Mashberg and Feldman 1988; Mills and Carter 2004; Maraki, Becker, and Boecking 2004; Kujan et al. 2005).

Leukoplakia is the most common OPL in the oral cavity with a 4-40% chance for malignant changes (Waldron and Shafer 1975; Sciubba 1999; Maraki, Becker, and Boecking 2004). A new cohort showed that 17.9% of leukoplakia lesions developed into oral cancer with a mean duration of 5.2 years. (Liu et al. 2010). Oral lichen planus may become cancerous in 0.4 to 2.5% of cases (Sciubba 1999; Maraki, Becker, and Boecking 2004). A new retrospective study in Spain revealed 0.9% chance of malignancy in oral lichen planus with the tongue as the most common location (Bermejo-Fenoll et al. 2009).

Sometimes oral cancer develops *de novo*- from a normal mucosa- and is not preceded by an OPL, but usually a small part of an OPL may undergo dysplasia or malignant changes. Early removal of this part can prevent emergence of malignant lesions. But the question is-how can we find early malignant changes in an apparently benign lesion? To answer this question we must be familiar with adjunctive diagnostic aids which if employed properly, can enhance diagnosis and improve treatment outcomes. In the next section we introduce the diagnostic aids in oral Cancer screening or diagnosis.

## 2. Diagnostic aids in screening of oral cancer

Diagnostic aids can help the physician to decide whether the suspicious lesion needs biopsy or removal for cancer detection. Sometimes malignant changes occur without any clinical evidence of malignancy. In this situation even an expert eye may overlook malignant changes. Diagnostic aids can reveal these occult changes. In other word, diagnostic aids can be used as screening or as adjunctive tools. The decision whether to screen for oral cancer or not depends on many factors. Table1 shows the criteria for implementation of a screening program. (Lingen et al. 2008) when screening is indicated for oral cancer in a certain population, a suitable test should be employed. Table2 illustrates the characteristics of a good screening test. (Lingen et al. 2008)

The disease must be an important health problem
An accepted treatment must be available for patients with recognized disease
Facilities for diagnosis and treatment must be available
There must be a recognizable latent or early symptomatic stage
A suitable test must be available
The test should be acceptable to the population
The natural history of the condition should be adequately understood
There should be an agreed policy on whom to treat as patients
The screening program should be cost-effective
The screening process should be a continuing process and not a 'once and for all' project

Table 1. Criteria for the implementation of a screening program (Lingen et al. 2008)

There are different screening tests for oral cancer with variable indications, limitations and implications. Yet the gold standard for cancer diagnosis is surgical biopsy and histopathologic examination. But not every suspicious lesion should be surgically biopsied. There is a spectrum ranging from clinical examination to surgical biopsy. Diagnostic tests are located in the middle of this spectrum and have their own indications. Here we discuss diagnostic procedures, which can be employed in early detection of oral cancer.

A screening test should:
Be simple, safe and acceptable to the public
Detect disease early in its natural history
Preferentially detect those lesions which are likely to progress
Detect lesions which are treatable or where an intervention will prevent progression
Have a high positive predictive value and low false negatives (high sensitivity)

Table 2. Characteristics of a good screening test (Lingen et al. 2008)

Screening test must be evaluated with respect to their diagnostic value. This value includes sensitivity (SN), specificity (SP), positive predictive value (PPV) and negative predictive value (NPV). If calculating of these values is considered the results must be compared to the gold standard. The gold standard of oral cancer diagnosis is yet scalpel biopsy (surgical biopsy). The gold standard is used to classify subjects as to their true state of disease. Table 3 shows the SN, SP, PPV and NPV and the way to calculate them.

$$SN = \frac{a}{a + c}$$

$$SP = \frac{d}{d + b}$$

$$PPV = \frac{a}{a + b}$$

$$NPV = \frac{d}{d + c}$$

Diagnostic test		Gold Standard		Total
		Disease present	Disease absent	
+	a	d	a+d	
	True positive	False positive		
-	c	b	c+b	
	False negative	True negative		
Total		a + c	b + d	a+b+c+d

Table 3. Standard 2X2 table for the calculation of sensitivity(SN), specificity(SP), positive predictive value(PPV) and negative predictive value(NPV)

## 2.1 Clinical examination

Diagnosis of oral cancer begins with a complete history taking followed by a thorough clinical examination. Oral cavity is the most accessible site of alimentary track for clinical examination. (Chiodo, Eigner, and Rosenstein 1986) Precise inspection of all parts of oral mucosa using an incandescent light can reveal abnormal changes. The physician must examine the whole oral cavity accurately. Posterior portions and floor of the mouth must be surveyed meticulously. Even self-examination of oral cavity can be performed by the individuals for early detection of oral cancer (Elango et al. 2011). Any symptom or sign must be assessed exactly. The teeth must be examined for any evidence of mobility or tilting. Sometimes radiographic examination is necessary to complete the clinical examination. The clinician must palpate any lesion to find induration or firmness. Apparently normal mucosa must be palpated to reveal any mass or abnormal change (e.g. roughness, altered texture...). Cervical lymph nodes must be palpated to find metastatic lymphadenopathy in occult oropharynx malignancy

At the time of evaluating an OPL, any evidence of roughness, ulceration, redness and induration must be further examined by histopathologic examination. Diagnostic value of clinical examination has been reported in literature. (Sankaranarayanan et al. 2005; Downer et al. 1995; Nagao et al. 2000; Jullien et al. 1995; Downer et al. 2004; Mignogna and Fedele 2005). A Meta analysis on different studies of oral cancer screening showed an overall sensitivity of 0.857. (95% CI 0.73, 0.92) and specificity of 0.97(95% CI 0.93, 0.98), Indicating a satisfactory test performance for oral examination (Downer et al. 2004). This study also suggested that trained auxiliaries are able to screen with a degree of accuracy similar to dental practitioner.

Mortality of oral cancer can be decreased by clinical examination. One study reported a 32% reduction in mortality of OSCC in high risk individuals, suggesting that about 40000 deaths can be prevented by oral examination worldwide (Mignogna and Fedele 2005; Sankaranarayanan et al. 2005). Even self examination can improve early detection of oral cancer, although compliance to seek treatment is still low (32%).(Elango et al. 2011; Warnakulasuriya et al. 1984) . False positive referrals for definite diagnosis can result in anxiety which can be decreased by public education for the individuals who receive oral examination. (Patton 2003)

To increase cost effectiveness of oral cancer screening programs, it is better to perform targeted clinical examinations of high-risk subjects (opportunistic screen) than mass screening (Speight et al. 2006; Patton 2003). A Cochrane systematic review found that there is no evidence to recommend inclusion or exclusion of screening for oral cancer using a visual examination unless randomized controlled trials provide the most reliable information for decision in clinical practice (Kujan et al. 2005).

Despite benefits of clinical examination, it has been demonstrated that between 4.5 and 15.3% of OPL and early stage oral cancers can not be adequately identified by visual inspection alone and may be overlooked even by highly trained professionals, potentially increasing the false negative rate (Moles, Downer, and Speight 2003). Because of this innate pitfall of visual inspection, other diagnostic aids can be employed to improve early detection of oral cancer.

## 2.2 Cytopathologic studies

### 2.2.1 Oral exfoliative cytology

Cytopathology is the microscopic study of cell samples collected from mucosal surfaces obtained by exfoliative cytology (via smears, scraping or lavage) or by fine needle aspiration (Sarah Freygang et al. 2011). Cytology has been applied to diagnose human diseases, since Papanicolaou and Traut validated it for diagnosis of cervical cancer (Papanicolaou GN 1941). Since then cytology of the oral cavity began to be used as a cytopathologic diagnostic technique. In early studies on this technique no satisfactory results were obtained, mainly due to its limitations and improper application. In this technique a collecting device (swab, spatula and brush) is placed and rotated against the mucosal surface and the cells are collected.

The next step is to prepare a smear by spreading the cells onto a glass slide. After fixation and papanicolaou staining the slide is examined by pathologist. Interpretation of the results must be performed by an expert pathologist familiar with cytopathology. Sometimes cells are collected by a cytobrush. Diagnostic values of exfoliative cytology have a wide range due to kind of sampling instrument. A positive result is defined as definitive cellular evidence of epithelial dysplasia or carcinoma and atypical result is defined as abnormal epithelial changes of uncertain diagnostic significance (Maraki, Becker, and Boecking 2004). Studies from 1950 to 1970s reported high false negative results for exfoliative cytology (Folsom et al. 1972; Shklar, Cataldo, and Meyer 1970; Rovin 1967). For example Folsom et al reported 37% false negative result in 148 oral lesions (Folsom et al. 1972).

Recent studies have reported better results (Navone et al. 2004) due to combining molecular analysis with exfoliative cytology which will be discussed in a separate section. Some researchers have analyzed the reliability of oral cytology and its cytometric analysis in the early detection of oral cancer. The SN 98.2%, SP100%, PPV of 100% and NPV of 99% have been reported (Remmerbach et al. 2003). Mehrotra et al Reviewed 22 articles and found SN and SP of oral exfoliation cytology to be 76.8% - 100% and 88.9% - 100% respectively (Mehrotra et al. 2009).

### 2.2.2 Brush biopsy

Oral CD-x brush is a kind of specialized oral brush, which can penetrate the thickness of the mucosa and collect representative sample of the lesion. (Acha 2005) Basal and parabasal cells- which are the precursor of malignant changes- are collected by this specially designed brush. "Brush biopsy" employs oral CD-x brush, which is then analyzed by computer. Some studies have used oral CD-x brush, but have analyzed the result by visual histopathology examination and not by computer (Mehrotra et al. 2006; Delavarian et al 2010).

The diagnostic value of brush biopsy has been reported in several studies. SN from 71 to 100 percent, SP varied from 27 to 94 percent, PPVs ranged from 38 to 88 percent and NPVs from 60 to 100 percent have been reported. According to a systematic review by Patton et al, oral CD-x cytological test has advantages in detecting dysplastic changes in high risk mucosal lesions but in low risk populations or clinical innocuous lesions its application remains in doubt. This technique can not be performed in place of surgical biopsy. (Patton, Epstein, and



Kerr 2008) It seems that OralCDx technique overestimates dysplastic lesions and has a low PPV(Bhoopathi, Kabani, and Mascarenhas 2009)

### 2.2.3 Liquid based cytology (LBC)

Since 1990, liquid-based cytology (LBC) has been designed to improve slide quality and quantity of conventional cytology (Davey et al. 2006). LBC is an improvement in cytology technique that can compensate many disadvantages of conventional exfoliate cytology. Instead of a unique smear, a suspension of cells is obtained and several slides could be prepared. In LBC the sample collector with the sample is immersed in a tube containing preservative fluid, which fixes the cells immediately and can be a useful source of cells for upcoming researches. The fluid is placed on a centrifugal force and the cells make a thin high cellular confined zone on the glass slide, which can be assessed easily by the pathologist. Many artifacts of conventional cytology do not occur in LBC technique. By employing this technique unsatisfactory slides and false negative results have been reduced and the diagnostic value of cytology has improved. Up to now, only few studies in oral cavity –based on LBC technique- have been published in English literature. In Hayama study; 44 different oral lesions were examined by both conventional and liquid based (Autocyte Inc) cytological examination using a cytobrush –not specified for oral mucosa. It was concluded that the two techniques led to the same diagnosis and the same papanicolaou class was assigned in all adequate cases. Three conventional smears were hypocellular, hence making the cytological diagnosis impossible. The LBC preparations showed a satisfactory higher improvement in slide quality (thinness, even cell distribution, absence of overlapping and bleeding) (Hayama et al. 2005).

In Navone study 2006, results of conventional exfoliative cytology and LBC (by using dermatologic curette) were compared with scalpel biopsy. Both sensitivity and specificity were higher in LBC group than in conventional cytology. The false negative and positive results were 7/89 and 2/89 in conventional smear group and 4/384 and 3/384 in LBC group. Upon these results, it can be concluded that LBC gives better results and enhances SN and SP (Navone et al. 2007). Recently Navone reported a 95.1% SN and 99% SP for LBC technique. (Navone 2009)

### 2.2.4 A modified liquid-based cytology using OralCDx® Brush

Although the diagnostic values of brush biopsy or LBC technique have been published previously there are some pitfalls: First, in many brush biopsy studies not all of samples with different brush results underwent scalpel biopsy so the reported values for sensitivity, specificity, etc., could be questionable. Second, in the case of performing both brush and biopsy, there are few, if ever, studies which both techniques are done simultaneously and exactly from the same area. Third, all of LBC studies in oral cavity are performed using cervical or dermatological tools for sample collection and never a specialized oral tool (e.g. CDx brush) has been employed (Hayama et al. 2005; Navone et al. 2007). Because of non rigid nature of cervical brushes, inadequate results are expected. This leads to false negative results and significant diagnostic delay (Potter, Summerlin, and Campbell 2003).

So, we planned a study to use LBC technique employing a specialized oral brush (OralCDx® Brush), simultaneously and exactly from the same area to determine the

diagnostic value (sensitivity, specificity, positive and negative predictive values and positive and negative likelihood ratios) of modified LBC technique in detection of dysplasia /malignancy in oral potentially malignant and cancerous lesions and to evaluate diagnostic agreement between this technique and scalpel biopsy. (Delavarian et al. 2010)

Since only a few laboratories evaluate the OralCDx® results by computer-assisted analysis, we examined microscopic slides visually. First, we designed a pilot study on 3 normal mucosa and 7 epithelial lesions to qualify slide properties, using standard protocol of OralCDx® kits. After manipulation of standard protocol neither the quality nor the quantity of slides were suitable for cytopathologic diagnosis, so we applied an LBC technique and modified the conventional protocol in this way:

First, instead of spreading the brush onto a glass slide, the brush was placed in the supplied glass tube, containing formalin (10%), and sent to the cytopathology laboratory. There the brush and the formalin, containing cells dispersed from brush were placed in a vortex for 5 minutes in 4000 RPM. This centrifugal force helped to sediment the cells and taken them off from the brush hairs. Then 100  $\lambda$  (mm<sup>3</sup>) of this sediment was placed onto the cup of Cytospine (Shandon UK) centrifuge in 1000RPM(similar to power recommended in this vortex for vaginal samples). Two to 4 samples were obtained from each cellular sediment. The more the sediment was rich in cellular material or blood component, the more glass slides were prepared.

The study group consisted of 25 patients with 26 lesions which had been visited from Oct 2005 to Jan 2007, at Oral Medicine Department of Mashhad Faculty of Dentistry and Otorhinolaryngology Departments of QAEM, IMAM REZA and OMID hospitals, Mashhad, Iran. (Table 4)The study protocol was approved by the committee on ethics of Mashhad University of the Medical Sciences (MUMS) on the basis of the Helsinki consent 2005. Patients were informed with regard to the research objectives, methods, possible benefits and potential risks and a written consent was obtained from all participants.

Inclusion criterion was: lesions clinically diagnosed as oral potentially malignant (leukoplakia, OLP) or malignant lesions (OSCC and verrucous carcinoma) and requiring an incisional (scalpel) biopsy for definite diagnosis. Exclusion criteria were: A) History of any treatment for the lesion (drug, radiation and chemotherapy) and B) A systemic contraindication for scalpel biopsy.

The most appropriate site of biopsy was determined upon the most probable site of dysplasia/malignancy (e.g. presence of firmness and indurations and roughness or red surface or high risk areas for dysplasia/malignancy (e.g. Ventral tongue and floor of the mouth) or the most surgically accessible site.

Demographic data were recorded. After determination of the site of biopsy, under local anesthesia, needed for scalpel biopsy, the Oral CDx brush was placed in the selected area and turned 5 to 10 times until appearing pinpoint bleeding-upon to manufacturer's recommendation. The brush was sent to cytopathology laboratory immersing in supplied 10 %formalin glass tube. The scalpel biopsy was also done immediately in site of pinpoint bleeding.

In cytopathology laboratory, the slides were prepared by Modified Liquid Based Techniques. By using cytopspine vortex the cells were compacted in a 20mm<sup>2</sup> area ,then they



were fixed in 96° alcohol for 20 minutes and papanicolaou staining was done. They were examined by a pathologist informed about clinical diagnosis, but blind to the histopathological results; using Leica BME (Leica Buffalo state, US) microscopes in 100X and 400X magnifications.

The cytopathological findings were categorized as three groups: 1) Positive: dysplastic epithelial changes. 2) Negative: absence of any evidence suggesting dysplasia. 3) Inadequate sampling: means two entities: A) Inadequate depth of sampling -absence of basal and parabasal cell layers in slide. B) Inadequate quantity of cells-hypocellularity.

The histopathologic preparations were observed by the same pathologist blind to cytopathological study and informed about clinical diagnosis. The Pindborg criteria (Warnakulasuriya et al. 2008) for detecting dysplasia and malignancy were used and the histopathologic diagnosis was made. The presence of dysplasia/malignancy in histopathology (P.D.M.H) was classified as normal (no dysplasia/malignancy), mild, moderate and severe dysplasia (level 1 to 3), carcinoma *In Situ* (level 4) and carcinoma (level 5) (table 4).

Quantitative variables were analyzed by T test as  $\bar{X} \pm SD$  and for qualitative variables  $\chi^2$  and Exact Fisher tests were done using SPSS11.5 software. SN, SP, PPV and NPV were calculated for modified technique and clinical examination. Positive likelihood ratio (LR+) and negative likelihood ratio (LR-) were calculated for modified technique. Kappa value was calculated to determine diagnostic agreement between the modified technique and scalpel biopsy, the gold standard.

Thirteen male and 12 female contributed to this study (Table 4). In one female patient (Table 4 -pt (patient) No 25) two sites with two different clinical diagnoses (one proved to be severely dysplastic and one OSCC in histopathologic assessment) were biopsied (Fig 1). The mean age of patients was  $54.00 \pm 17.38$  (12 females;  $54.23 \pm 19.77$  and 13 males;  $53.77 \pm 15.43$  years). T test revealed senile contingency in two groups. Six lesions were clinically diagnosed as OLP, six as leukoplakia, 13 as OSCCs and one as verrucous carcinoma (Table 4).

The Modified LBC results showed 10 negative and 16 positive results, without any inadequate results, hence all the specimens were included basal and parabasal layers and enough quantity. Histopathologic results were as follow: (Table 4) 7 lesions diagnosed as OLP, 5 as leukoplakia, 11 as OSCC and one as verrucous carcinoma, two lesions (pt Nos 9 and 23), were diagnosed as Granular Cell Tumors (GCT) of tongue.

Clinical diagnosis was in agreement in 88.4% (23/26) with histopathological findings. One lichenoid reaction clinically diagnosed as leukoplakia and two granular cell tumors clinically diagnosed as OSCCs. In 92.3% (24/26,  $p < 0.001$ ) results of modified LBC were in agreement with presence of malignancy/dysplasia in histopathology. The two false negative results were outcomes of histopathologically focal dysplasia (one mild and one moderate dysplasia).

Kappa value (an index of diagnostic agreement) was calculated 0.806 for modified LBC and scalpel biopsy. In our study, SN, SP, PPV and NPV of modified LBC technique were calculated as follows: 88.8%, 100%, 100% and 80%. All the samples contained cells of all epithelial layers (including basal and parabasal layers) because of specialized designed rigid

hairs of CDx brush. This is an advantage, which can resolve the problem of false negative and inadequate results and help to improve sensitivity. It is the first attempt to apply Liquid Based Cytology (LBC) using a specialized oral cytology instrument (OralCDx® Brush), hence other LBC studies in oral cavity have used cervical or dermatologic tools for sample collection (Hayama et al. 2005; Navone et al. 2007).

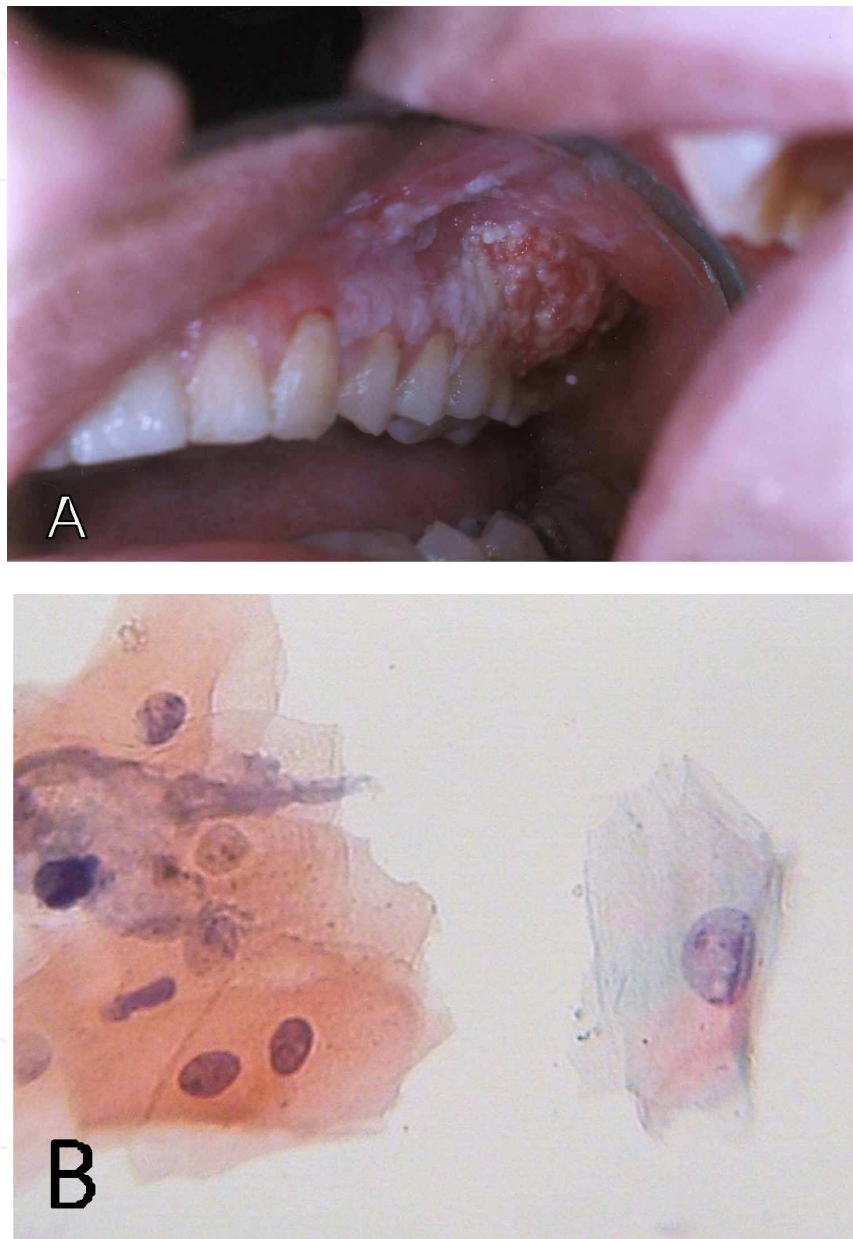


Fig. 1. Patient NO.25. **A)** malignant changes (posterior portions) in a severely dysplastic leukoplakia (anterior portions) on maxillary gingiva. **B)** LBC prepared cytologic slides revealed dysplasia in leukoplakic area, note to different nucleus size and high protein synthesis activity (100X magnification - Papanicolaou staining)

False negative ratio (11%=2/18) was slightly higher than other studies (3.5%, 1.9%, 5%) (Christian 2002; Potter, Summerlin, and Campbell 2003; Scheifele et al 2004; Navone et al 2004). Because of small sample size, especially in premalignant lesions, it is not possible to

compare researches. Svirsky reported 4 false negatives but three out of four false negative results seemed to originate from incompatible site and time of both biopsy techniques; indeed only 1 "false negative" was reported which could be the result of the technique *per se*. Other negative results seemed to originate from (Svirsky et al. 2002). In our study, performing brush biopsy simultaneously on the exact biopsy site could compensate this shortcoming.

Two clinically diagnosed malignancies (OSCCs)-proved to be granular cell tumors of tongue- had negative brush results. This suggests more specificity for brush compared to clinical diagnosis. SN 88.8% was almost similar to some results of oral exfoliative cytology researches (86.5%, 71.4% and 92.3%) (Scheifele et al. 2004; Navone et al. 2004; Poate et al. 2004; Sciubba 1999) and in contrast to results of other study with extremely high SN (100%) (Sciubba 1999). 100% PPV was higher than previous studies (38.3% 7.4% and 7.9%) (Bhoopathi, Kabani, and Mascarenhas 2009; Svirsky et al. 2002), which can be due to higher prevalence of dysplasia and malignancy in our sample group.

LR+ and LR- are two tools that combine information about the SN and SP of a test and are not commonly reported in oral medicine's literature. LR+ >10 and LR- <0.1 makes a test suitable for clinical use. They were infinity and 0.11 respectively that express positive results may be always true. It seems that this finding is because of great prevalence of disease in study group and larger sample size can near this result to more realistic value. LR- =0.11 shows "moderate decrease in the likelihood of the disease".

There was a high diagnostic agreement between brush biopsy and histopathologic examination. In two dysplastic lesions the brush could not reveal atypical changes, so contingency coefficient was 92.3%. Kappa value was calculated to show diagnostic agreement. Based on literature review Kappa value has not been calculated for brush biopsy yet. Kappa result (0.806) was greater than 0.7 and shows substantial agreement between brush biopsy and scalpel biopsy.

Based on our study, high SN, SP, LR+ and Kappa value, showed that modified LBC is a suitable test for clinical use. Our modification can eliminate some of the disadvantages of conventional, brush and liquid -based cytology, previously attempted in oral cavity. This study has some great advantages: 1) All subjects under went scalpel biopsy so we could compare our results with gold standard so the reported SN, SP, PPV and NPV are reliable. 2) Both samples were obtained from the same site. 3) The special oral brush was used to collect cells for LBC. It seems that our study combines the benefits of brush biopsy and LBC in early detection of oral premalignant and malignant changes.

## 2.3 Vital tissue staining

### 2.3.1 Vital iodine stain

Vital iodine stain (3% lugol solution) has been used to determine the best site for biopsy in endoscopy of alimentary tract and cervix. (Navone 2009). This technique works on binding of iodine to glycogen granules in the cytoplasm, resulting in a black brown tissue color (Maeda et al. 2010; Maeda et al. 2009). In a study of 54 patients with oral cancer or OPL, this dye was used to determine surgical margins. The results showed a significantly low (<2%) recurrence rate (Navone 2009).

<i>Patient number</i>	<i>Age<sub>(Yrs.)</sub></i>	<i>Sex*</i>	<i>Clin Dia. †</i>	<i>Brush Results</i>	<i>Histo Dia. ‡</i>	<i>(P.D.M.H) §</i>
1	65	M	SCC¶	Pos	SCC	level 5
2	48	M	LEUK**	Pos	LEUK	level 3
3	71	M	SCC	Pos	SCC	level 5
4	67	F	SCC	Pos	SCC	level 5
5	74	M	LEUK	Pos	LEUK	level 1
6	40	M	LEUK	Neg	LEUK	level 2
7	79	F	LEUK	Neg	OLP‡‡	level 1
8	70	F	SCC	Pos	SCC	level 5
9	49	F	SCC	Neg	GCT	Normal
10	74	F	SCC	Pos	SCC	level 5
11	73	F	Ver.car‡‡	Pos	Ver.car	level 5
12	55	F	OLP‡‡	Pos	OLP	level 2
13	70	M	OLP	Neg	OLP	Normal
14	47	F	SCC	Pos	SCC	level 5
15	36	M	OLP	Neg	OLP	Normal
16	36	M	OLP	Neg	OLP	Normal
17	39	M	SCC	Pos	SCC	level 5
18	69	M	SCC	Pos	SCC	level 5
19	35	F	SCC	Pos	SCC	level 5
20	64	M	SCC	Pos	SCC	level 5
21	35	M	OLP	Neg	OLP	Normal
22	52	M	OLP	Neg	OLP	Normal
23	42	F	SCC	Neg	GCT	Normal
24	70	F	LEUK	Neg	LEUK	Normal
25(Lesion1)	22	F	LEUK	Pos	LEUK	level 3
25(Lesion2)	22	F	SCC	Pos	SCC	level 5

Abbreviations: \*sex is defined as Male(M) and Female(F), †Clinical diagnosis, ‡ histopathological diagnosis, § presence of dysplasia/malignancy in histopathology, ¶ squamous cell carcinoma, \*\*leukoplakia, †† verrucous carcinoma, ‡‡ oral lichen planus or lichenoid reaction. Brush biopsy results are defined as Positive (Pos), Negative (Neg), and in adequate results (IAR)

Table 4. Demographic data in addition to clinical, modified (Liquid-Based) brush biopsy and histopathological diagnosis.

### 2.3.2 Toluidine blue staining

Toluidine blue (TB) is a metachromatic dye that binds to nucleic acids (DNA or RNA) and can help to better visualization of high risk areas-with rapid cell proliferation of oral SCC or OPL. This will guide the clinician to :

- Detect carcinoma in situ and early invasive OSCC
- Delineation of surgical fields for biopsy sites
- Detection of second primary cancers or satellite tumors
- Recognition of post-treatment recurrence (Rosenberg and Cretin 1989)



There have been some studies about diagnostic accuracy of TB staining (Epstein et al. 2008; Epstein and G,neri 2009; Lingen et al. 2008; Patton, Epstein, and Kerr 2008; Rhodus 2009). These studies have addressed some limitations. Ligen et al reviewed these studies and concluded that absence of randomized clinical trials and histological diagnosis as gold standard and variability of methods of applications are the major factors in exact diagnostic value of TB. (Lingen et al. 2008) In other reported studies, SN is high but SP is low due to dye absorption by inflammatory lesions. It is a cheap, easy and none-invasive technique. (Epstein and G,neri 2009; Epstein et al. 2007; Rhodus 2009). SN and SP are calculated at 38-100% and 9-100 %, respectively. (Awan, Morgan, and Warnakulasuriya 2011; Epstein and G,neri 2009; Epstein et al. 1997; Martin, Kerawala, and Reed 1998; Warnakulasuriya and Johnson 1996)

It seems that SN in detecting dysplasia is still low. A high false positive result is a great limitation of clinical implication as a screening method. Sometimes subjective interpretation of the mucosal staining (dark royal blue compared to pale blue) cause differences in results (Lingen et al. 2008). A comprehensive review on clinical effectiveness of TB showed that TB is not a cost-effective method of picking up OSCC in primary care setting (Gray et al. 2000).

ViziLite plus is a system which uses TB in combination with ViziLite pens- a disposable chemiluminescent light device- to enhance the malignant changes of oral mucosa (see light-based detection systems)

### 2.3.3 Other staining methods

Methylene blue has been used for detection of oral cancer and OPL. SN, SP, PPV and NPV has been reported 90%, 69%, 74% and 87% respectively (Chen, Lin, Fong, et al. 2007; Chen, Lin, Wu, et al. 2007).

Rose bengal RB has been used to detect non-healthy epithelial mucosa such as ocular epithelium specially neoplasms (Kim 2000; Khan-Lim and Berry 2004; Wilson 2nd 1976; Singh et al. 2004). One study was conducted in 132 cases of oral OPLs and oral SCC with a refined 4-grades shade guide. The results showed SN, SP, PPV and NPV to be 93.9%, 73.7%, 55.4% and 97.2% respectively. Six lesions with normal appearance in clinical examination were disclosed by RB staining. The authors concluded that RB staining can be used as a valuable diagnostic procedure in hospital-based population (with a high prevalence of malignancy dysplasia). Further research is necessary to reveal its benefits as a screening test (Du et al. 2007).

## 2.4 Light-based detection systems

### 2.4.1 Chemluminescence (reflective tissue fluorescence)

In this technique the mouth is rinsed with 1% acetic acid wash, which helps to remove debris and increase the visibility of epithelial cell nuclei as a result of mild cellular dehydration. The blue white illumination will be reflected by abnormal tissue, making occult lesion distinguishable from normal mucosa (Lingen et al. 2008). The normal mucosa appears blue whereas abnormal mucosal lesions reflect the light and appear more aceto-white with brighter, sharper and more distinct margins (Epstein et al. 2006; Farah and McCullough 2007; Kerr, Sirois, and Epstein 2006; Ram and Siar 2005).



In a clinical survey of 150 patients *visiLite* system was used to examine oral lesions. Since all lesions were not biopsied and compared with gold standard, diagnostic accuracy was not achieved (Huber, Bsoul, and Terezhalmay 2004). One case with normal clinical appearance was detected by *ViziLite*. All cases of leukoedema were aceto-white. These findings suggest that despite high SN of *ViziLite*, SP is still low. Several studies about *viziLite* examination for case-finding or screening of oral cancer (Farah and McCullough 2007; Huber, Bsoul, and Terezhalmay 2004; Oh and Laskin 2007) but the majority of them lack histopathologic correlation, which questions the diagnostic value. Most researchers found that this device has little benefit in discriminating occult lesions. In addition distracting highlights produced by *ViziLite* system may make oral examination more difficult than with normal operating light (Oh and Laskin 2007). If well controlled clinical trials can show its benefit in differentiating lesions, from normal appearing mucosa, this technology can be used as a true screening tool (Lingen et al. 2008).

Some studies (Bhalang et al. 2008; Oh and Laskin 2007) showed benefit with the use of acetic acid 1% or vinegar (5% acetic acid) pre-rinse for better visualization of oral mucosa, so acetic acid can be used without the accompanying light system.

#### **2.4.2 Tissue fluorescence imaging**

In this technique an intense blue excitation light (400-460 nm) is illuminated to oral mucosa and the abnormal tissue emits fluorescence due to altered structure and metabolism of epithelium and subepithelial stroma. Normal mucosa emits a pale green autofluorescence while abnormal tissue appears darker in comparison to surrounding healthy tissue. *MicroLux*, *orascopic* and *veloscope* are examples of this technique. Case series have found high sensitivity (98-100%) and specificity (3-100%) of *veloscope* in identifying areas of dysplasia and cancers that extended beyond the clinically evident tumors (Abdo et al. 2007; De Veld et al. 2005; Lingen et al. 2008; Onizawa et al. 1999; Patton, Epstein, and Kerr 2008). To date there are no published studies about using *veloscope* as a diagnostic adjunct in screening low risk population or in patients examined by primary health care providers (Lingen et al. 2008).

#### **2.4.3 Tissue fluorescence spectroscopy**

This technique consists of a small optical fiber that produces various excitation wave lengths and a spectrograph which receives and records on a computer and analyzes via a dedicated software, the spectra of reflected fluorescence from the tissue (De Veld et al. 2005; Inaguma and Hashimoto 1999; Lingen et al. 2008; Patton, Epstein, and Kerr 2008). This technique is very accurate in distinguishing normal mucosa from different lesions, but due to small size of optical fiber it is not practical to scan large areas of oral mucosa. Also it can not distinguish benign lesions from malignancy (De Veld et al. 2005; Inaguma and Hashimoto 1999; Lingen et al. 2008; Patton, Epstein, and Kerr 2008).

#### **2.4.4 Other light-based techniques**

Contact endoscopy and endoscopic high frequency ultra sound are promising new imaging systems which have been used in nasopharyngeal lesions. These techniques have been used in oral cavity and a SN=91.3% and SP=100% have been reported (Mallia et al. 2008). Narrow

band imaging is a novel technique which uses narrow-band spectrum optical filters to enhance the visualization of mucosal and sub-mucosal microvascular patterns. (Piazza et al. 2010) SN, SP, PPV and NPV for this technique in combination with a high definition television have been reported as 96%, 100%, 100% and 93% respectively (Piazza et al. 2010). Further research is necessary to better understand the diagnostic value of these new technologies (Andrea et al. 1997; Andrea, Dias, and Santos 1995; Speight et al. 1995).

## 2.5 Cellular and molecular techniques

There are many diagnostic aids which can detect premalignant and malignant changes in cellular and molecular level at early stages. Examples are cytomorphometric and histomorphometric analysis, molecular analysis and genetic alteration assessment. These methods employ immunohistochemistry, histochemistry and immunologic techniques in detection of early changes. Yet these techniques are used for research purposes and are not clinically applicable. (Bourhis et al. 1996 ; Remmerbach et al. 2001; Maraki, Becker, and Boecking 2004; Maraki, Hengge, et al. 2006; Maraki, Yalcinkaya, et al. 2006; Yamazaki et al. 2008 ; Nagamani et al. 2010; Mohtasham et al. 2010; OHTA et al. 2010; Böcking et al. 2011). In addition these methods are expensive and are not widely accessible and only expert clinicians can use them for early diagnosis. More studies must be conducted to evaluate these techniques as screening methods of oral cancer.

## 3. Conclusion

There are many diagnostic aids for early detection of oral cancer. Yet the gold standard of oral cancer diagnosis is surgical biopsy, which can be performed by a trained dentist/physician. Diagnostic aids can be used in different situations specially when a surgical biopsy is not indicated and can help the clinician to:

1. Choose the best site for biopsy
2. Follow up a patient with a premalignant lesion
3. Screen for oral cancer in high risk patients or high risk sites of oral cavity (e.g. ventral tongue, floor of the mouth etc.)
4. Make a preliminary diagnosis when there is a systemic contraindication for surgical biopsy
5. Differentiation of pseudoepitheliomatous hyperplasia from a real malignancy.

## 4. Acknowledgement

The authors are most grateful to Prof. Dr Abbas Javadzadeh, who not only served as an excellent scientific consultant, but also encouraged and challenged us throughout our academic activity. The authors also would like to extend their appreciation to the Vice Chancellor For Research, MUMS (Mashhad University of Medical Sciences) and Oral And Maxillofacial Diseases Research Center (OMFDRC) for their support.

## 5. References

Abdo, E.N., A. de Almeida Garrocho, A.A. Barbosa, E.L. de Oliveira, L. França-Filho, S.L.C. Negri, and I.A. Pordeus. 2007. Time elapsed between the first symptoms, diagnosis

- and treatment of oral cancer patients in Belo Horizonte, Brazil. *Med oral patol oral cir bucal (Internet)* 12(7):E467-73.
- Acha, A. 2005. Applications of the oral scraped (exfoliative) cytology in oral cancer and precancer. *Med oral patol oral cir bucal* 10(2):95-102.
- Andrea, M., O. Dias, C. Macor, A. Santos, and J. Varandas. 1997. Contact endoscopy of the nasal mucosa. *Acta oto-laryngologica* 117 (2):307-311.
- Andrea, M., O. Dias, and A. Santos. 1995. Contact endoscopy during microlaryngeal surgery: a new technique for endoscopic examination of the larynx. *Ann oto, rhinol laryngol* 104 (5):333.
- Awan, KH, PR Morgan, and S. Warnakulasuriya. 2011. Utility of chemiluminescence (ViziLite™) in the detection of oral potentially malignant disorders and benign keratoses. *J Oral Pathol Med* 40(7): 541-544.
- Bermejo-Fenoll, A., M. Sanchez-Siles, P. López-Jornet, F. Camacho-Alonso, and N. Salazar-Sanchez. 2009. Premalignant nature of oral lichen planus. A retrospective study of 550 oral lichen planus patients from south-eastern Spain. *Oral oncol* 45 (8):e54-e56.
- Bhalang, K., A. Suesuwan, K. Dhanuthai, P. Sannikorn, L. Luangjarmekorn, and S. Swasdison. 2008. The application of acetic acid in the detection of oral squamous cell carcinoma. *Oral Surg Oral Med Oral Pathol Oral Radiol and Endod* 106 (3):371-376.
- Bhoopathi, V., S. Kabani, and A.K. Mascarenhas. 2009. Low positive predictive value of the oral brush biopsy in detecting dysplastic oral lesions. *Cancer* 115 (5):1036-1040.
- Böcking, A., C. Sproll, N. Stöcklein, C. Naujoks, R. Depprich, N.R. Kübler, and J. Handschel. 2011. Role of Brush Biopsy and DNA Cytometry for Prevention, Diagnosis, Therapy, and Followup Care of Oral Cancer. *J Oncol* Article ID 875959, 7 pages doi:10.1155/2011/875959.
- Bourhis, J., R. Lubin, B. Roche, S. Koscielny, J. Bosq, I. Dubois, M. Talbot, P. Marandas, G. Schwaab, and P. Wibault. 1996. Analysis of p53 serum antibodies in patients with head and neck squamous cell carcinoma. *J National Can Ins* 88 (17):1228.
- Bruun, J.P. 1976. Time lapse by diagnosis of oral cancer. *Oral Surg Oral Med Oral Pathol* 42 (2):139-149.
- Chen, Y.W., J.S. Lin, J.H.J. Fong, and I. Wang. 2007. Use of methylene blue as a diagnostic aid in early detection of oral cancer and precancerous lesions. *Br J Oral Maxillofac Surg* 45 (7):590-591.
- Chen, Y.W., J.S. Lin, C.H. Wu, M.T. Lui, S.Y. Kao, and Y. Fong. 2007. Application of in vivo stain of methylene blue as a diagnostic aid in the early detection and screening of oral squamous cell carcinoma and precancer lesions. *J Chinese Med Assoc* 70 (11): 497-503.
- Chiodo, GT, T. Eigner, and DI Rosenstein. 1986. Oral cancer detection. The importance of routine screening for prolongation of survival. *Postgraduate med* 80 (2):231.
- Christian, D.C. 2002. Computer-assisted analysis of oral brush biopsies at an oral cancer screening program. *J Am Dent Assoc* 133 (3):357.
- Davey, E., A. Barratt, L. Irwig, S.F. Chan, P. Macaskill, P. Mannes, and A.M. Saville. 2006. Effect of study design and quality on unsatisfactory rates, cytology classifications, and accuracy in liquid-based versus conventional cervical cytology: a systematic review. *Lancet* 367 (9505):122-132.

- De Veld, D. C., M. J. Witjes, H. J. Sterenberg, and J. L. Roodenburg. 2005. The status of in vivo autofluorescence spectroscopy and imaging for oral oncology. *Oral Oncol* 41 (2):117-31.
- Delavarian, Z., N. Mohtasham, P. Mosannen-Mozaffari, A. Pakfetrat, M.T. Shakeri, and R. Ghafoorian-Maddah. 2010. Evaluation of the diagnostic value of a modified liquid-based cytology using OralCDx® brush in early detection of oral potentially malignant lesions and oral cancer. *Med Oral Patol Oral Cir Bucal* 15 (5):e671-6.
- Downer, M.C., D.R. Moles, S. Palmer, and P.M. Speight. 2004. A systematic review of test performance in screening for oral cancer and precancer. *Oral oncol* 40 (3):264-273.
- Downer, MC, AW Evans, CM Hallett, JA Jullien, PM Speight, and JM Zakrzewska. 1995. Evaluation of screening for oral cancer and precancer in a company headquarters. *Commun dent oral epidemiol* 23 (2):84-88.
- Du, G., C. Li, H. Chen, X. Chen, Q. Xiao, Z. Cao, S. Shang, and X. Cai. 2007. Rose bengal staining in detection of oral precancerous and malignant lesions with colorimetric evaluation: A pilot study. *Int j cancer* 120 (9):1958-1963.
- Eisenbud, L., and JJ Sciubba. 1978 .Oral cancer: a multidisciplinary challenge. *J hosp dent practice* 12 (3):96.
- Elango, K.J., N. Anandkrishnan, A. Suresh, S.K. Iyer, S.K. Ramalyer, and M.A. Kuriakose. 2011. Mouth self-examination to improve oral cancer awareness and early detection in a high-risk population. *Oral Oncol* 47(7): 620-624.
- Epstein, J. B., M. Gorsky, S. Lonky, S. Silverman, Jr., J. D. Epstein, and M. Bride. 2006. The efficacy of oral lumenoscopy (ViziLite) in visualizing oral mucosal lesions. *Spec Care Dentist* 26 (4):171-4.
- Epstein, J.B., and P. G.neri. 2009. The adjunctive role of toluidine blue in detection of oral premalignant and malignant lesions. *Cur opin otolaryng head neck surg* 17 (2):79.
- Epstein, J.B., C. Oakley, A. Millner, S. Emerton, E. van der Meij, and N. Le. 1997. The utility of toluidine blue application as a diagnostic aid in patients previously treated for upper oropharyngeal carcinoma. *Oral Surg Oral Med Oral Pathol Oral Radiol and Endod* 83 (5):537-547.
- Epstein, J.B., J. Sciubba, S. Silverman Jr, and H.Y. Sroussi. 2007. Utility of toluidine blue in oral premalignant lesions and squamous cell carcinoma: continuing research and implications for clinical practice. *Head neck* 29 (10):948-958.
- Epstein, JB, S. Silverman Jr, JD Epstein, SA Lonky, and MA Bride. 2008. Analysis of oral lesion biopsies identified and evaluated by visual examination, chemiluminescence and toluidine blue. *Oral oncol* 44 (6):538-544.
- Farah, C. S., and M. J. McCullough. 2007. A pilot case control study on the efficacy of acetic acid wash and chemiluminescent illumination (ViziLite) in the visualisation of oral mucosal white lesions. *Oral Oncol* 43 (8):820-4.
- Fedele, S. 2009. Diagnostic aids in the screening of oral cancer. *Head Neck Oncology*. 1(5): doi:10.1186/1758-3284-1-5.
- Folsom, T.C., C.P. White, L. Bromer, H.F. Canby, and G.E. Garrington. 1972. Oral exfoliative study:: Review of the literature and report of a three-year study. *Oral Surg Oral Med Oral Pathol* 33 (1):61-74.
- Gray, M., L. Gold, A. Burls, K. Elley, K. House, W. Bromwich, and M. Bosworth. 2000. The clinical effectiveness of toluidine blue dye as an adjunct to oral cancer screening in




- general dental practice. *Birmingham: University of Birmingham, Department of Public Health and Epidemiology. A West Midlands Development and Evaluation Service Report.*
- Hayama, F.H., A.C.F. Motta, A.P.G. Silva, and D.A. Migliari. 2005. Liquid-based preparations versus conventional cytology: specimen adequacy and diagnostic agreement in oral lesions. *Med oral patol oral cir bucal* 10(2):115-122.
- Huber, M. A., S. A. Bsoul, and G. T. Terezhalmly. 2004. Acetic acid wash and chemiluminescent illumination as an adjunct to conventional oral soft tissue examination for the detection of dysplasia: a pilot study. *Quintessence Int* 35 (5):378-84.
- Inaguma, M., and K. Hashimoto. 1999. Porphyrin-like fluorescence in oral cancer: In vivo fluorescence spectral characterization of lesions by use of a near-ultraviolet excited autofluorescence diagnosis system and separation of fluorescent extracts by capillary electrophoresis. *Cancer* 86 (11):2201-11.
- Jullien, JA, MC Downer, JM Zakrzewska, and PM Speight. 1995. Evaluation of a screening test for the early detection of oral cancer and precancer. *Commun dent health* 12 (1):3.
- Kerr, A. R., D. A. Sirois, and J. B. Epstein. 2006. Clinical evaluation of chemiluminescent lighting: an adjunct for oral mucosal examinations. *J Clin Dent* 17 (3):59-63.
- Khan-Lim, D., and M. Berry. 2004. Still confused about rose bengal? *Current eye research* 29 (4-5):311-317.
- Kim, J. 2000. The use of vital dyes in corneal disease. *Curr Opin Ophthalmol* 11 (4):241-7.
- Kujan, O., A.M. Glenney, J. Duxbury, N. Thakker, and P. Sloan. 2005. Evaluation of screening strategies for improving oral cancer mortality: a Cochrane systematic review. *J Dent Edu* 69 (2):255.
- Lingen, M.W., J.R. Kalmar, T. Karrison, and P.M. Speight. 2008. Critical evaluation of diagnostic aids for the detection of oral cancer. *Oral oncol* 44 (1):10-22.
- Liu, W., Y.F. Wang, H.W. Zhou, P. Shi, Z.T. Zhou, and G.Y. Tang. 2010. Malignant transformation of oral leukoplakia: a retrospective cohort study of 218 Chinese patients. *BMC cancer* 10 (1):685.
- Maeda, K., T. Suzuki, Y. Ooyama, K. Nakakuki, M. Yamashiro, N. Okada, and T. Amagasa. 2010. Colorimetric analysis of unstained lesions surrounding oral squamous cell carcinomas and oral potentially malignant disorders using iodine. *Int J Oral and Maxillofac Surg* 39 (5):486-492.
- Maeda, K., M. Yamashiro, Y. Michi, T. Suzuki, Y. Ohyama, N. Okada, and T. Amagasa. 2009. Effective staining method with iodine for leukoplakia and lesions surrounding squamous cell carcinomas of the tongue assessed by colorimetric analysis. *J Med Dent Sci* 56 (4):123-3.
- Mallia, R.J., S.S. Thomas, A. Mathews, and R. Kumar. 2008. Laser induced autofluorescence spectral ratio reference standard for early discrimination of oral cancer. *Cancer* 112 (7):1503-1512.
- Maraki, D., J. Becker, and A. Boecking. 2004. Cytologic and DNA cytometric very early diagnosis of oral cancer. *J Oral Pathol Med* 33 (7):398-404.
- Maraki, D., UR Hengge, J. Becker, and A. Boecking. 2006. Very early cytological and DNA cytometric diagnosis of in situ carcinoma in an immunosuppressed liver transplant recipient. *J Oral Pathol Med* 35 (1):58-60.
- Maraki, D., S. Yalcinkaya, N. Pomjanski, M. Megahed, A. Boecking, and J. Becker. 2006. Cytologic and DNA cytometric examination of oral lesions in lichen planus. *J Oral Pathol Med* 35 (4):227-232.



- Martin, IC, CJ Kerawala, and M. Reed. 1998. The application of toluidine blue as a diagnostic adjunct in the detection of epithelial dysplasia. . *Oral Surg Oral Med Oral Pathol Oral Radiol and Endod* 85 (4):444-446.
- Mashberg, A., and L.J. Feldman. 1988. Clinical criteria for identifying early oral and oropharyngeal carcinoma: Erythroplasia revisited+. *Am J Surg* 156 (4):273-275.
- Mehrotra, R., A. Gupta, M. Singh, and R. Ibrahim. 2006. Application of cytology and molecular biology in diagnosing premalignant or malignant oral lesions. *Mol Cancer* 5 (1):11.
- Mehrotra, R., M. Hullmann, R. Smeets, T. E. Reichert, and O. Driemel. 2009. Oral cytology revisited. *J Oral Pathol Med* 38 (2):161-6.
- Mignogna, M.D., and S. Fedele. 2005. Oral cancer screening: 5 minutes to save a life. *Lancet* 365 (9475):1905-1906.
- Mills, S.E., and D. Carter. 2004. *Sternberg's diagnostic surgical pathology*. Vol. 1: Lippincott Williams & Wilkins Philadelphia, PA.
- Mohtasham, N., N. Mahdavi-Shahri, J. Salehinejad, H. Ejtehad, M. Torabi-Parizi, and N. Ghazi. 2010. Detection of nucleoproteins in squamous cell carcinoma, and dysplastic and normal mucosa in the oral cavity by methyl green-pyronin staining. *J Oral Sci* 52 (2):239-243.
- Moles, D.R., M.C. Downer, and P.M. Speight. 2003. Oral cancer and precancer screening studies have high discriminatory ability. *Evidence-Based Dentistry*, 2000; 3: 79-80. *Evid Based Dent* 4 (2):45-45.
- Nagamani, N., G. Julie, S. Tyler, T. Daniel, T. Gavin, and K. James. 2010. Desmosomal Component Expression in Normal, Dysplastic, and Oral Squamous Cell Carcinoma. *Dermatol Res Pract* Article ID 649731, 7 pages; doi:10.1155/2010/649731.
- Nagao, T., N. Ikeda, H. Fukano, H. Miyazaki, M. Yano, and S. Warnakulasuriya. 2000. Outcome following a population screening programme for oral cancer and precancer in Japan. *Oral oncol* 36 (4):340-346.
- Navone, R. 2009. Cytology of the oral cavity: a re-evaluation. *Pathologica* 101 (1):6-8.
- Navone, R., P. Burlo, A. Pich, M. Pentenero, R. Broccoletti, A. Marsico, and S. Gandolfo. 2007. The impact of liquid based oral cytology on the diagnosis of oral squamous dysplasia and carcinoma. *Cytopathol* 18 (6):356-360.
- Navone, R., A. Marsico, I. Reale, A. Pich, R. Broccoletti, M. Pentenero, and S. Gandolfo. 2004. Usefulness of oral exfoliative cytology for the diagnosis of oral squamous dysplasia and carcinoma]. *Minerva stomatologica* 53 (3):77.
- Neville, B.W., D.D. Damm, C.M. Allen, and J.E. Bouquot. 1995. *Oral & maxillofacial pathology*. Vol. 620: Saunders Philadelphia.
- Oh, E. S., and D. M. Laskin. 2007. Efficacy of the ViziLite system in the identification of oral lesions. *J Oral Maxillofac Surg* 65 (3):424-6.
- Ohta, K., I. Ogawa, S. Ono, M. Taki, K. Mizuta, M. Miyauchi, M. Takechi, H. Shigeishi, T. Takata, and N. Kamata. 2010. Histopathological evaluation including cytokeratin 13 and Ki-67 in the border between Lugol-stained and-unstained areas. *Oncol rep* 24 (1):9-14.
- Onizawa, K., H. Saginoya, Y. Furuya, H. Yoshida, and H. Fukuda. 1999. Usefulness of fluorescence photography for diagnosis of oral cancer. *Int J Oral Maxillofac Surg* 28 (3):206-10.

- Papanicolaou GN, Traut HF. 1941. The diagnostic value of vaginal smears in carcinoma of the uterus. *Am J Obstet Gynecol* 42:193-205
- Patton, L. L., J. B. Epstein, and A. R. Kerr. 2008. Adjunctive techniques for oral cancer examination and lesion diagnosis: a systematic review of the literature. *J Am Dent Assoc* 139 (7):896-905; quiz 993-4.
- Patton, L.L. 2003. The effectiveness of community-based visual screening and utility of adjunctive diagnostic aids in the early detection of oral cancer. *Oral oncol* 39 (7):708-723.
- Peacock, Z.S., M.A. Pogrel, and B.L. Schmidt. 2008. Exploring the reasons for delay in treatment of oral cancer. *J Am Dent Assoc* 139 (10):1346.
- Pektas , Z.Ö., A. Keskin, Ö. Günhan, and Y. Karsliog lu. 2006. Evaluation of nuclear morphometry and DNA ploidy status for detection of malignant and premalignant oral lesions: quantitative cytologic assessment and review of methods for cytometric measurements. *J Oral Maxillofac surg* 64 (4):628-635.
- Piazza, C., D. Cocco, F. Del Bon, S. Mangili, P. Nicolai, A. Majorana, A. Bolzoni Villaret, and G. Peretti. 2010. Narrow band imaging and high definition television in evaluation of oral and oropharyngeal squamous cell cancer: a prospective study. *Oral oncol* 46 (4):307-310.
- Poate, TWJ, JAG Buchanan, TA Hodgson, PM Speight, AW Barrett, DR Moles, C. Scully, and SR Porter. 2004. An audit of the efficacy of the oral brush biopsy technique in a specialist Oral Medicine unit. *Oral oncol* 40 (8):829-834.
- Potter, T.J., D.J. Summerlin, and J.H. Campbell. 2003. Oral malignancies associated with negative transepithelial brush biopsy. *J Oral Maxillofac Surg* 61 (6):674-677.
- Ram, S., and C. H. Siar. 2005. Chemiluminescence as a diagnostic aid in the detection of oral cancer and potentially malignant epithelial lesions. *Int J Oral Maxillofac Surg* 34 (5):521-7.
- Remmerbach, T.W., H. Weidenbach, C. Muller, A. Hemprich, N. Pomjanski, B. Buckstegge, and A. Bocking. 2003. Diagnostic value of nucleolar organizer regions (AgNORs) in brush biopsies of suspicious lesions of the oral cavity. *Analytical Cellular Pathology* 25 (3):139-146.
- Remmerbach, T.W., H. Weidenbach, N. Pomjanski, K. Knops, S. Mathes, A. Hemprich, and A. Bocking. 2001. Cytologic and DNA-cytometric early diagnosis of oral cancer. *Analytical Cellular Pathology* 22 (4):211-222.
- Rhodus, N. L. 2009. Oral cancer and precancer: improving outcomes. *Compend Contin Educ Dent* 30 (8):486-8, 490-4, 496-8 passim; quiz 504, 520.
- Rosenberg, D., and S. Cretin. 1989. Use of meta-analysis to evaluate toloum chloride in oral cancer screening. *Oral Surg Oral Med Oral Pathol* 67 (5):621-627.
- Rovin, S. 1967. An assessment of the negative oral cytologic diagnosis. *J Am Dent Assoc* 74 (4):759.
- Sankaranarayanan, R., K. Ramadas, G. Thomas, R. Muwonge, S. Thara, B. Mathew, and B. Rajan. 2005. Effect of screening on oral cancer mortality in Kerala, India: a cluster-randomised controlled trial. *The Lancet* 365 (9475):1927-1933.
- Sarah Freygang, M., R. Grasieli de Oliveira, R. Elena Riet Correa, M. Filipe, and G. Liliane Janete. 2011. Techniques for Precancerous Lesion Diagnosis. *J Oncol Article ID 326094*, 5 pages doi:10.1155/2011/326094.

- Scheifele, C., A.M. Schmidt-Westhausen, T. Dietrich, and P.A. Reichart. 2004. The sensitivity and specificity of the OralCDx technique: evaluation of 103 cases. *Oral oncol* 40 (8):824-828.
- Sciubba, J.J. 1999. Improving detection of precancerous and cancerous oral lesions: computer-assisted analysis of the oral brush biopsy. *J Am Dent Assoc* 130 (10):1445.
- Shklar, G., E. Cataldo, and I. Meyer. 1970. Reliability of cytologic smear in diagnosis of oral cancer: a controlled study. *Archives of Otolaryngology- Head and Neck Surgery* 91 (2):158.
- Singh, J. K., F. E. Dhawahir, A. F. Hamid, and P. B. Chell. 2004. The use of dye in ophthalmology. *J Audiov Media Med* 27 (2):62-7.
- Speight, PM, AE Elliott, JA Jullien, MC Downer, and JM Zakzrewska. 1995. The use of artificial intelligence to identify people at risk of oral cancer and precancer. *Br Dent J* 179 (10):382-387.
- Speight, PM, S. Palmer, DR Moles, MC Downer, DH Smith, M. Henriksson, and F. Augustovski. 2006. The cost-effectiveness of screening for oral cancer in primary care. *Health Technol Assess* 10 (14):1-144.
- Svirsky, JA, JC Burns, WM Carpenter, DM Cohen, I. Bhattacharyya, JE Fantasia, DA Lederman, DP Lynch, JJ Sciubba, and SL Zunt. 2002. Comparison of computer-assisted brush biopsy results with follow up scalpel biopsy and histology. *Gen dent* 50 (6):500.
- Waldron, C.A., and W.G. Shafer. 1975. Leukoplakia revisited. A clinicopathologic study 3256 oral leukoplakias. *Cancer* 36 (4):1386-1392.
- Warnakulasuriya, K., ANI Ekanayake, S. Sivayoham, J. Stjernswärd, JJ Pindborg, LH Sobin, and K. Perera. 1984. Utilization of primary health care workers for early detection of oral cancer and precancer cases in Sri Lanka. *Bulletin of the World Health Organization* 62 (2):243.
- Warnakulasuriya, K., and N.W. Johnson. 1996. Sensitivity and specificity of OraScanÆ toluidine blue mouthrinse in the detection of oral cancer and precancer. *J Oral Pathol Med* 25 (3):97-103.
- Warnakulasuriya, S., J. Reibel, J. Bouquot, and E. Dabelsteen. 2008. Oral epithelial dysplasia classification systems: predictive value, utility, weaknesses and scope for improvement. *J Oral Pathol Med* 37 (3):127-133.
- Wilson 2nd, FM. 1976. Rose bengal staining of epibulbar squamous neoplasms. *Ophthalmic surgery* 7 (2):21.
- Wood, N.K., and P.W. Goaz. 1997. Differential diagnosis of oral and maxillofacial lesions. Mosby: St. Louis, London.
- Yamazaki, Y., I. Chiba, M. Ishikawa, C. Satoh, K. Notani, Y. Ohiro, Y. Totsuka, S. Mizuno, and Y. Kitagawa. 2008. Serum p53 antibodies as a prognostic indicator in oral squamous cell carcinoma. *Odontol* 96 (1):32-37.



## **Oral Cancer**

Edited by Dr. Kalu U. E. Ogbureke

ISBN 978-953-51-0228-1

Hard cover, 388 pages

**Publisher** InTech

**Published online** 14, March, 2012

**Published in print edition** March, 2012

Oral cancer is a significant public health challenge globally. Although the oral cavity is easily accessible, early diagnosis remains slow compared to the enhanced detection of cancers of the breast, colon, prostate, and melanoma. As a result, the mortality rate from oral cancer for the past four decades has remained high at over 50% in spite of advances in treatment modalities. This contrasts with considerable decrease in mortality rates for cancers of the breast, colon, prostate, and melanoma during the same period. This book attempts to provide a reference-friendly update on the etiologic/risk factors, current clinical diagnostic tools, management philosophies, molecular biomarkers, and progression indicators of oral cancer.

### **How to reference**

In order to correctly reference this scholarly work, feel free to copy and paste the following:

Pegah Mosannen Mozafari, Zahra Delavarian and Nooshin Mohtasham (2012). Diagnostic Aids in Oral Cancer Screening, Oral Cancer, Dr. Kalu U. E. Ogbureke (Ed.), ISBN: 978-953-51-0228-1, InTech, Available from: <http://www.intechopen.com/books/oral-cancer/diagnostic-aids-in-oral-cancer-screening>

**INTECH**  
open science | open minds

#### **InTech Europe**

University Campus STeP Ri  
Slavka Krautzeka 83/A  
51000 Rijeka, Croatia  
Phone: +385 (51) 770 447  
Fax: +385 (51) 686 166  
[www.intechopen.com](http://www.intechopen.com)

#### **InTech China**

Unit 405, Office Block, Hotel Equatorial Shanghai  
No.65, Yan An Road (West), Shanghai, 200040, China  
中国上海市延安西路65号上海国际贵都大饭店办公楼405单元  
Phone: +86-21-62489820  
Fax: +86-21-62489821

© 2012 The Author(s). Licensee IntechOpen. This is an open access article distributed under the terms of the [Creative Commons Attribution 3.0 License](#), which permits unrestricted use, distribution, and reproduction in any medium, provided the original work is properly cited.

IntechOpen

IntechOpen