

# We are IntechOpen, the world's leading publisher of Open Access books Built by scientists, for scientists

4,800

Open access books available

122,000

International authors and editors

135M

Downloads

Our authors are among the

154

Countries delivered to

TOP 1%

most cited scientists

12.2%

Contributors from top 500 universities



WEB OF SCIENCE™

Selection of our books indexed in the Book Citation Index  
in Web of Science™ Core Collection (BKCI)

Interested in publishing with us?  
Contact [book.department@intechopen.com](mailto:book.department@intechopen.com)

Numbers displayed above are based on latest data collected.  
For more information visit [www.intechopen.com](http://www.intechopen.com)



# The Distal Forearm Region – Ultrasonographic Anatomy in Children and Adolescents

Johannes M. Mayr<sup>1,\*</sup>, Wolfgang Grechenig<sup>2</sup>, Ursula Seebacher<sup>3</sup>,  
Andreas Fette<sup>3</sup>, Andreas H. Weiglein<sup>4</sup> and Sergio Sesia<sup>1</sup>

<sup>1</sup>Department of Pediatric Surgery, University Children's Hospital Basel, Basel,

<sup>2</sup>Medical University of Graz, Graz,

Department of Traumatology

<sup>3</sup>Medical University of Graz,

Department of Pediatric Surgery

<sup>4</sup>Department of Anatomy, Medical University of Graz, Graz

<sup>1</sup>Switzerland

<sup>2,3,4</sup>Austria

## 1. Introduction

The distal forearm, particularly the distal radius, the radio-carpal joint and surrounding soft tissues are commonly affected by acute and chronic disorders. Ultrasonography has gained increasing importance in both the evaluation of acute injuries and chronic disorders in adults and in the diagnosis and follow-up of fractures in children and adolescents<sup>1-4</sup>. In children, the use of ultrasonography allows the chondral parts of the epiphyseal region to be better evaluated without exposure to radiation than using standard radiographic techniques.

The main advantage of sonography over CT and MRI is the possibility of performing dynamic examinations, resulting in exact clinical functional evaluation of the muscles, tendons and joints in question<sup>3,5,6</sup>. Furthermore, the contralateral limb can be examined in direct comparison when initial findings are uncertain.

It is the aim of this study, to demonstrate the normal ultrasonographic findings in the distal forearm region in children and adolescents, as this area is frequently involved in injuries.

## 2. Probands and methods

We studied 100 children and adolescents 2 months - 18 years old (mean  $\pm$  standard deviation [SD] = 7.1  $\pm$  4.5 years) and 25 healthy adults aged between 20 and 60 years. Children were recruited from our institution's paediatric surgical outpatient clinics. The patients had been admitted for unrelated disorders, requiring surgery, and the ultrasound study of the distal forearm was obtained together with the ultrasound study of the abdomen, urinary tract or soft tissue small parts. The area of the distal forearm was used first to demonstrate the painlessness

---

\*Corresponding Author

of the ultrasound examination to the child and the parents. Thereafter the linear ultrasound scanning probe was adjusted at the beginning of the ultrasound study, and the sonography of the distal forearm together with the ultrasound examination of the abdomen, retroperitoneum or small part region of interest was carried out. Consent was obtained from the parents, or in the case of older children, from both the children and parents. Patients with a history of forearm trauma or pathology were excluded from this investigation. However, a limited number of these patients are shown to demonstrate different pathological ultrasound findings (like fractures and osteomyelitis) in a separate chapter.

A 12-5 MHz linear probe ( Philips-ATL®, HDI 5000, Philips®, Bothell, WA, USA ) and high frequency probes ( 7.5 - 12 MHz ) (Siemens® Acuson® and Elegra®, Siemens®, Erlangen, FRG) were used for static and dynamic examination of the distal forearm region concentrating on the distal radius, the radiocarpal joint and surrounding soft tissues.

All 100 children and adolescents were examined in 3 longitudinal and 2 transverse standard planes and Doppler colour sonography was used to demonstrate vessels running within the cartilage of the distal radius supplying the epiphysis of the distal radius(Fig. 1). The wrist joint was examined in neutral position with the child sitting in front of a table either on a chair or on a parent's lap.

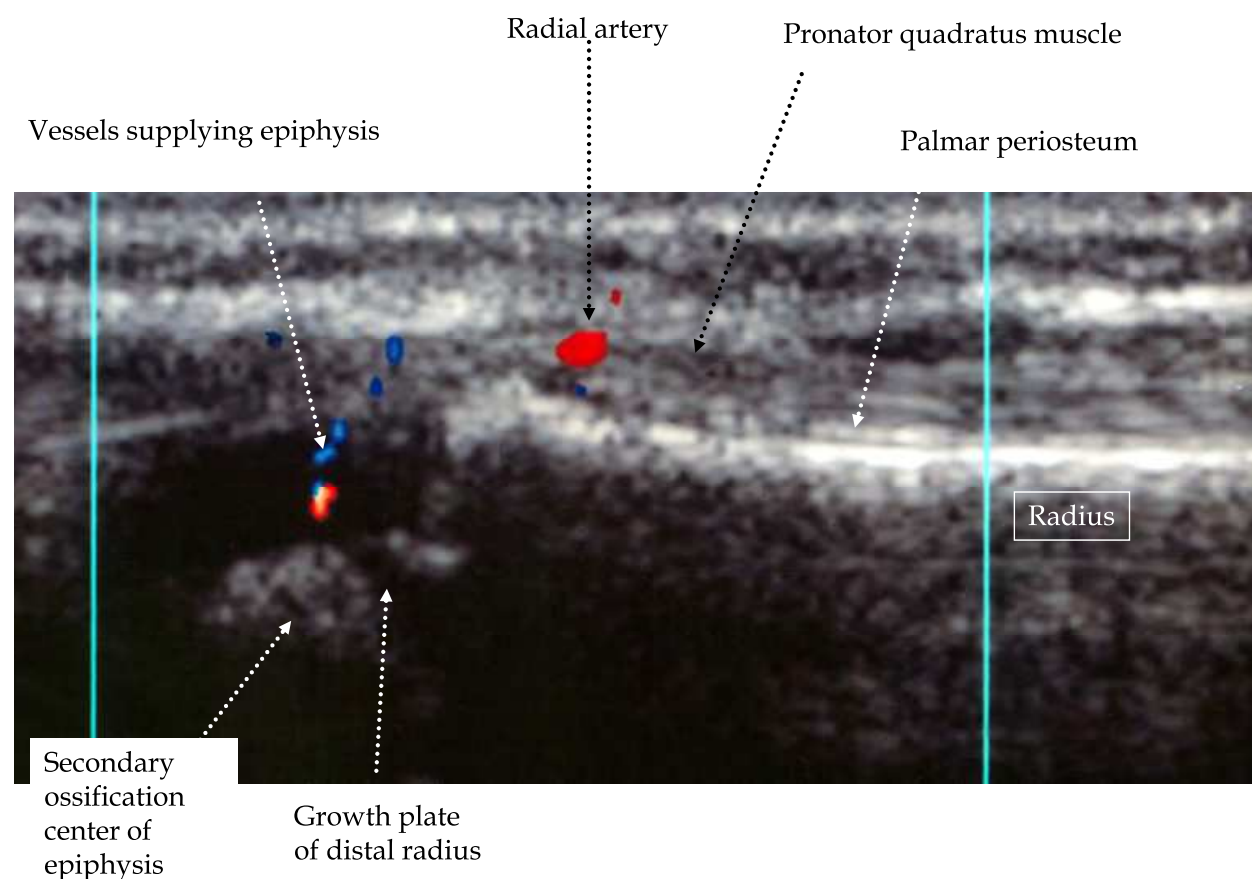


Fig. 1. Palmar-radial longitudinal colour coded duplex sonography scan in a boy aged 3 years showing the radial artery and an epiphyseal vessel. The ossification centre shows an echogenic reflex with dorsal acoustic shadow; the pronator quadratus muscle is visualised transversely beneath the radial artery.

The median nerve was visualized during static and dynamic ultrasound investigation. No standoff pad was used. Instead, a liberal amount of coupling gel was applied. For young children pre-warmed contact gel was used. The contra-lateral limb was also investigated to allow comparison.

For evaluation of age-related changes, the patients were divided into 4 groups (25 children per group). Group 1 included infant and toddler children from 2 months - 3 years old; group 2, young children 4 - 6 years old; group 3, pre-adolescent children 7 - 11 years old; and group 4, adolescent and teenage children 12 - 18 years old.

### **3. Technique of examination / standard planes**

A dorsal, radial and volar longitudinal plane and corresponding transverse sections were investigated. The radius was defined as the leading structure for longitudinal scans. By moving the probe distally, the cavity of the radiocarpal joint was localised and positioned in the centre of the image. From this standard position, the probe was moved in both a radial and ulnar direction, maintaining an "orthograde" probe position to avoid hypo-echogenicity of tendons caused by a non-orthograde transducer position<sup>7</sup>.

In the dorsal transverse plane, the scan began in the distal forearm region, identifying the radius and ulna as osseous leading structures.

The dorsal longitudinal scans were used to measure the width and investigate the echogenicity of the epiphyseal growth plate cartilage and to document the ossification of the secondary ossification centre of the distal epiphysis of the radius. From the dorsal radio-ulnar position, the probe was moved distally along the distal forearm, the wrist joint and the carpus.

The musculo-tendinous junction of the dorsal forearm muscles and the course of the extensor tendons was examined.

In order to evaluate the tendons, the probe was placed in an orthograde position and slow active and/or passive movement of the tendons and muscles was performed to demonstrate the function of the forearm muscles and their tendons.

The volar region of the distal forearm and wrist was examined using a similar technique.

To identify the median nerve the probe was placed in the transverse volar position and the focus was adjusted to a position just beneath the level of the skin. The median nerve was identified in its course running between the palmaris longus tendon and the flexor carpi radialis tendon.

The volar longitudinal scans were used to search for branches of the radial artery supplying the distal epiphysis of the radius.

### **4. Ultrasonographic findings in adult probands (n = 25)**

In all planes, the osseous structures were shown as bright echogenic lines with dorsal acoustic shadows, due to the difference in impedance of bone when compared to the surrounding soft tissue. The radiocarpal joint was identified as an echo-free gap between the

radius and the carpal bones. The proportion of articular cartilage of the carpal bones that could be visualized was dependent on the functional position of the hand. This should be considered when anechoic formations or structures (e.g. ganglia; intraarticular effusions) are evaluated.

Dynamic examination in a dorsal radio-ulnar plane allows the course of the extensor tendons to be accurately evaluated. Special attention has to be paid to the course of the extensor pollicis longus tendon in the region of Lister's tubercle, as the tendon crosses the underlying tendons of the extensor carpi radialis longus and brevis muscles. In the region of the musculo-tendinous junctions of the forearm extensor muscles, the tendons are occasionally surrounded by a thin hypoechoic muscular layer. Ultrasonographically, this small hypoechoic area must not be confused with extensor tenosynovitis<sup>3</sup>.

The radial neurovascular bundle on the volar aspect of the distal forearm was identified by its pulsation by grey-scale ultrasound and confirmed by its flow characteristics by colour Doppler sonography in all probands. The course of the radial artery and its distribution can be depicted by distal movement of the probe. Due to the width of the soft tissue coverage on the volar aspect, identification of a single tendon is easier when compared to the dorsal distal forearm region. By functional evaluation, the superficial and deep flexor tendons were depicted in the longitudinal plane. Both the carpal joint and the median nerve were clearly identified. The flexor retinaculum is difficult to separate from the surrounding tissue<sup>8</sup>. The flexor retinaculum was identified in 13 of 25 patients (52%), suspected in 3 patients (12%) and not seen in 9 patients (36%). The main problem encountered with the identification of the flexor retinaculum was its hypoechoicity, which was similar to the echogenicity of the overlying subcutaneous fat. The median nerve is characterised by its lower echogenicity when compared to its neighbouring tendons and its course between the superficial and deep flexor tendons is easily followed in a proximal direction<sup>3,4,6</sup>. Whilst the proband is moving his or her fingers, a characteristic transposition and change in the transverse shape of the median nerve can be noted. The median nerve is easily detected as it runs between the tendons of the flexor sublimis and flexor carpi radialis, and rather towards the radial side of the tendon of the palmaris longus. The palmaris longus tendon shows no longitudinal displacement during finger movements. The interosseous membrane and the pronator quadratus muscle on the volar aspect were identified easily in the transverse plane in all patients.

## 5. Ultrasonographic findings in children

Depending on the age of children various sonographic findings of the distal forearm region were observed.

In group 1 children (2 months - 3 years old), no ossification of the distal radial ossification centre was seen in 5 infants (aged up to 6 months). The echogenicity of the cartilage at the region of the distal radial growth plate was either anechoic with weak reticular echogenic pattern (5 children, aged from 0 - 3 months) or anechoic with weak echogenic spots (10 children). In 8 of 25 children (32 %) colour Doppler identified at least one small vessel within the cartilage of the volar distal radial epiphysis (Fig.1). Due to investigator problems (like coupling problems, more frequent forearm movements of infants, and very small

structures) the median nerve was documented by ultrasound in only 18 of 25 children (72 %). Other sonographic characteristics of the distal forearm region are presented in Table 1.

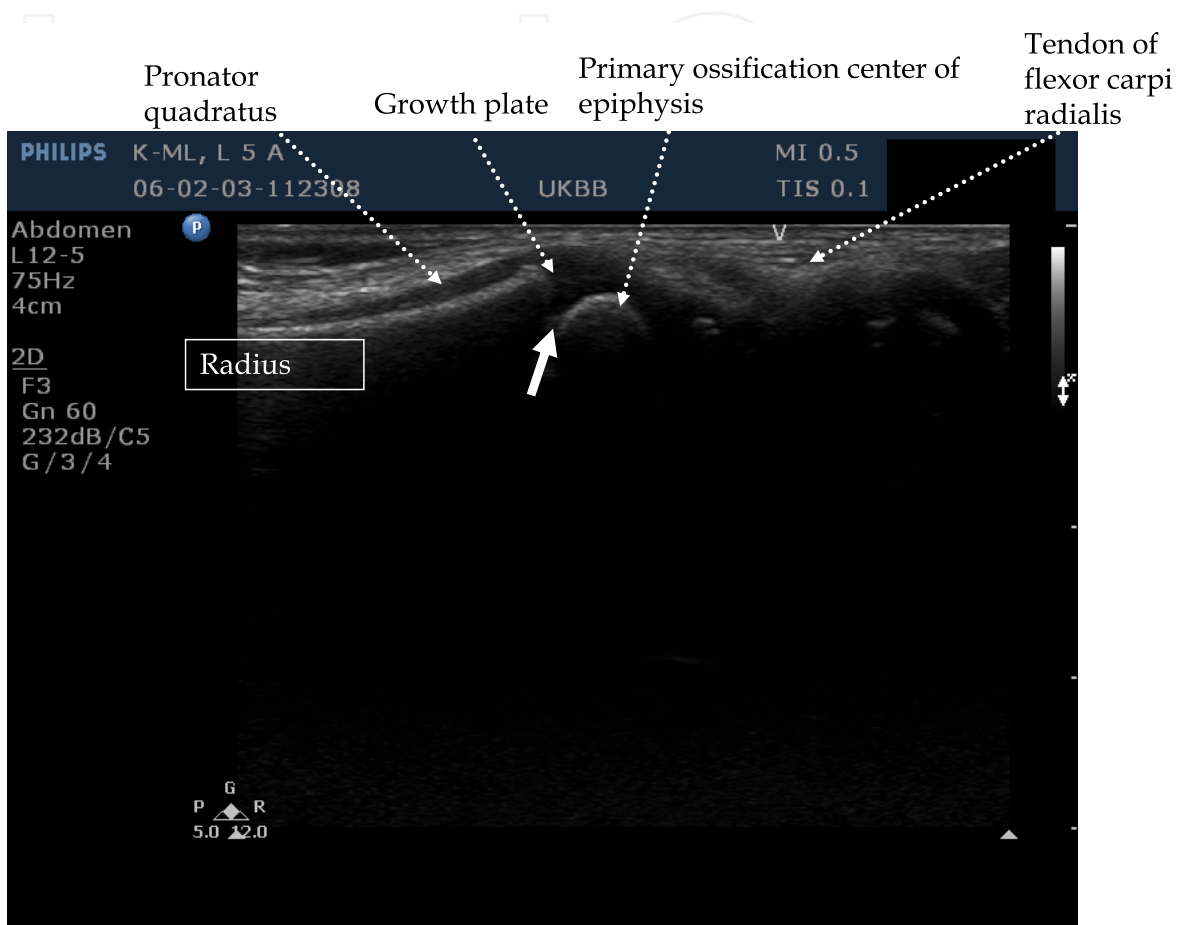
|  | Group 1<br>(2 months - 3 years)          | Group 2<br>(4 - 6 years)   | Group 3<br>(7 - 11 years)  | Group 4<br>(12 - 18 years)                                       |
|--|--|----------------------------|----------------------------|--|
| Proximodistal diameter of the distal radial growth plate; mm <sup>1</sup>              | 4.16 ± 1.16 (2.8 - 6.0)<br>(n = 20 / 25) | 2.65 ± 0.49<br>(1.8 - 3.8) | 2.19 ± 0.47<br>(1.4 - 3.5) | 1.39 ± 0.86<br>(0.1 - 3.0)<br>(growth plate fused in 5 children) |
| Absent ossification of the secondary ossification centre of the distal radius          | 5/25 (20 %)                              | 0/25                       | 0/25                       | 0/25   |
| Sonographic characteristics of the distal radius growth plate and epiphyseal cartilage |  |                            |                            |  |
| - Anechoic   | 10/25 (40 %)                             | 2/25 (8 %)                 | 1/25 (4 %)                 | 4/25 (16 %)  |
| - Mixed type (echogenic spots / bands / reticular pattern) within anechoic cartilage   | 15/25 (60 %)                             | 23/25 (92 %)               | 24/25 (96 %)               | 16/25 (64 %)   |
| - Epiphyseal growth plate fused  | 0/25                                     | 0/25                       | 0/25                       | 5/25 (20 %)  |
| Presence of vessels within the epiphyseal cartilage                                    | 8/25 (32 %)                              | 0/25                       | 1/25(4%)                   | 0/25   |
| Visualisation of the median nerve  | 18/25 (72 %)                             | 25/25 (100 %)              | 25/25 (100 %)              | 25/25 (100 %)  |
| Identification of the radial neurovascular bundle (grey scale and Doppler sonography)  | 25/25 (100 %)                            | 25/25 (100 %)              | 25/25 (100 %)              | 25/25 (100 %)  |

\* data are for n = 100 children (25 per group)

<sup>1</sup> mean ± standard deviation; range are shown in parenthesis.

Table 1. Sonographic characteristics of the distal forearm region in children and adolescents according to age groups\*.

The majority of children in group 2 (4 - 6 years old) showed weak punctuated echoes (76 %) or weak echogenic bands (16 %) within an anechoic growth plate cartilage (Fig.2). The median nerve was seen in all children on grey scale sonography. On colour Doppler sonography, no vascularisation was noted in the cartilage of the distal radial epiphysis or growth plate.



Palmar longitudinal transducer position along the distal radius

Fig. 2. Boy, 5 years of age; palmar longitudinal transducer position. Linear 12-5 MHz probe is placed along the distal radius. Anechoic cartilage of the growth plate and epiphysis of the radius shows small hypoechoic band-like spot within the growth plate cartilage (solid arrow).

In group 3 children the proximal-distal diameter of the distal radial growth plate was smaller when compared to group 2 (mean values 2,19 mm; 2,65 mm respectively). The appearance of the distal radial growth plate cartilage and epiphyseal cartilage in group 3 children (7 - 11 years old) resembled the appearance in group 2 children (4 - 6 years old) (Fig. 3-8). No problems were encountered during visualisation of the median nerve in group 3 children. On colour Doppler sonography, no vascularization was found in the cartilage of the growth plate. However, in one of these children a vessel was visualized entering the cartilage of the epiphysis from the palmar aspect of the epiphysis of the distal radius (Fig. 4).

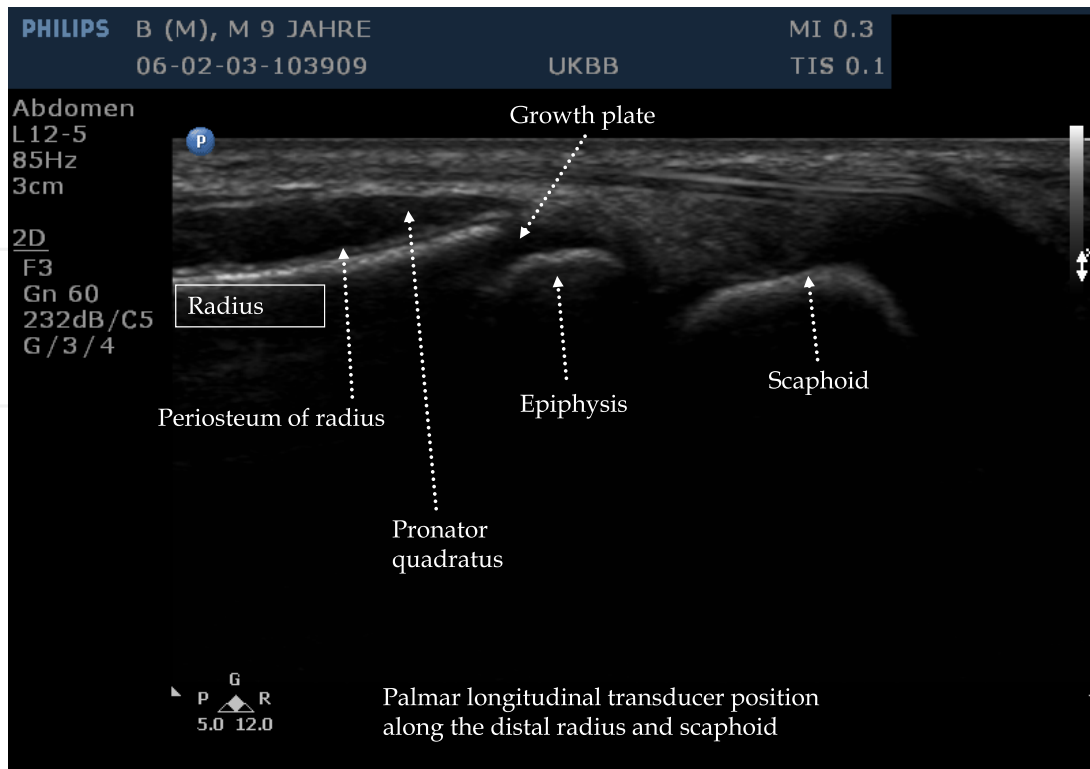


Fig. 3. Boy, 9 years of age; palmar longitudinal transducer position. The linear 12-5 MHz probe is placed along the distal radius.

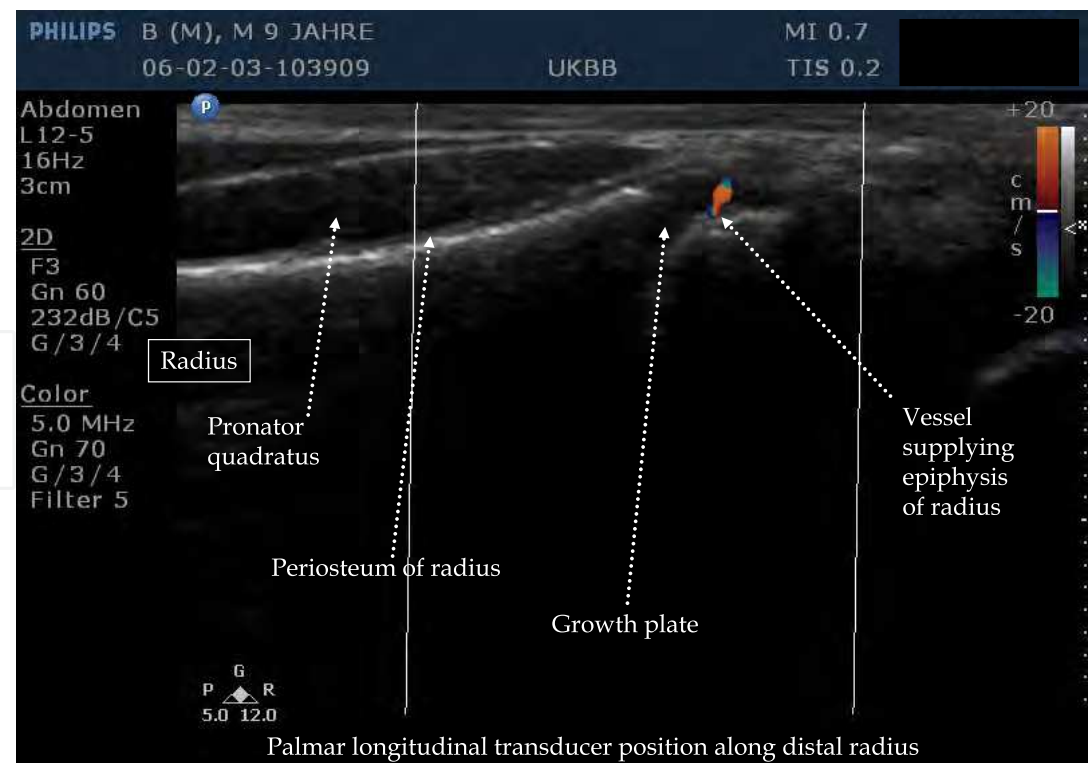


Fig. 4. Boy, 9 years of age; palmar longitudinal transducer position. Linear 12-5 MHz probe is placed along the distal end of the radius. Colour coded duplex ultrasound study shows vessel supplying the secondary ossification centre of the epiphysis.



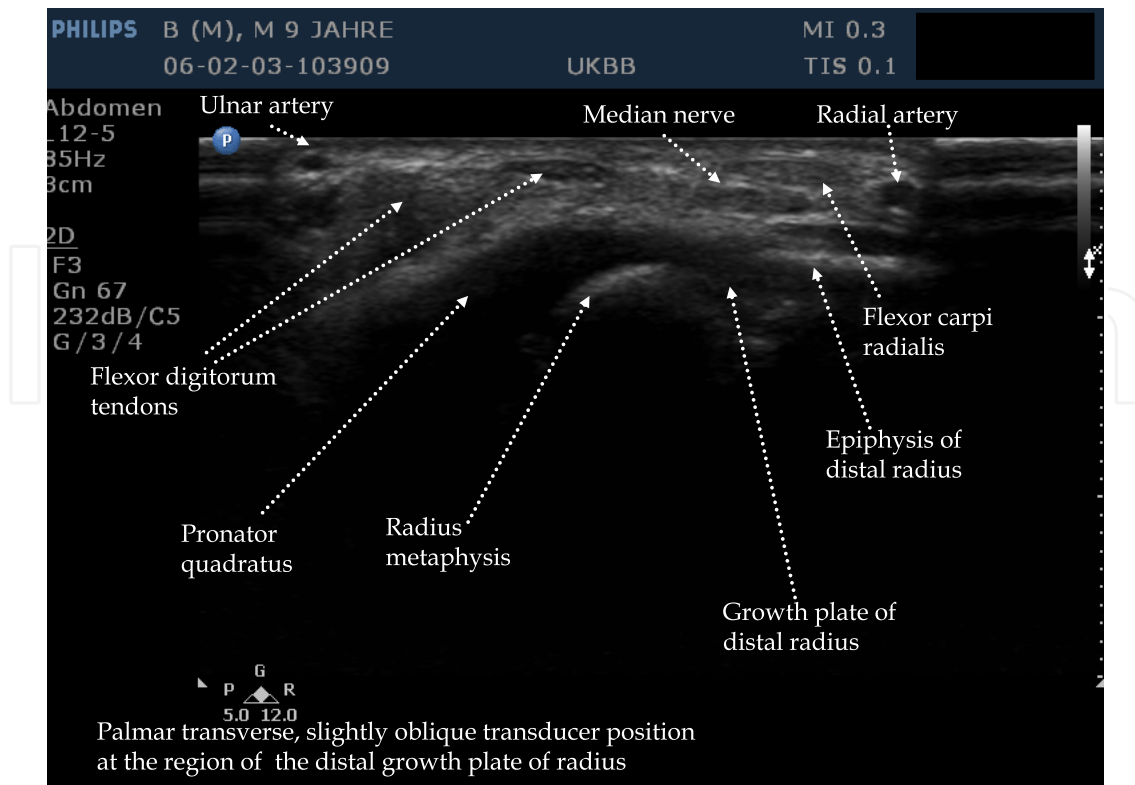


Fig. 5. Boy, 9 years of age; palmar transverse, slightly oblique transducer position. Linear 12-5 MHz probe is placed across the region of the growth plate of the distal radius. The cartilage of the growth plate of the radius appears anechoic.

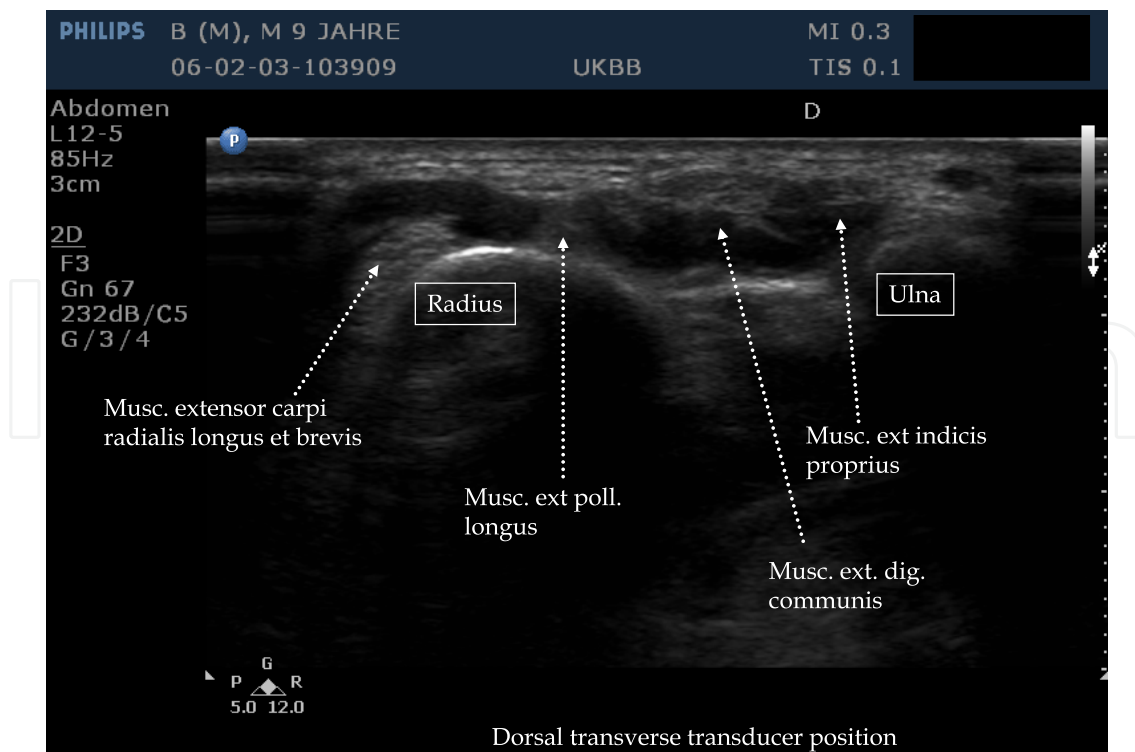


Fig. 6. Boy, 9 years of age; dorsal transverse transducer position. Linear 12-5 MHz probe is placed across the metaphyseal area of the distal forearm. The extensor tendons are shown.

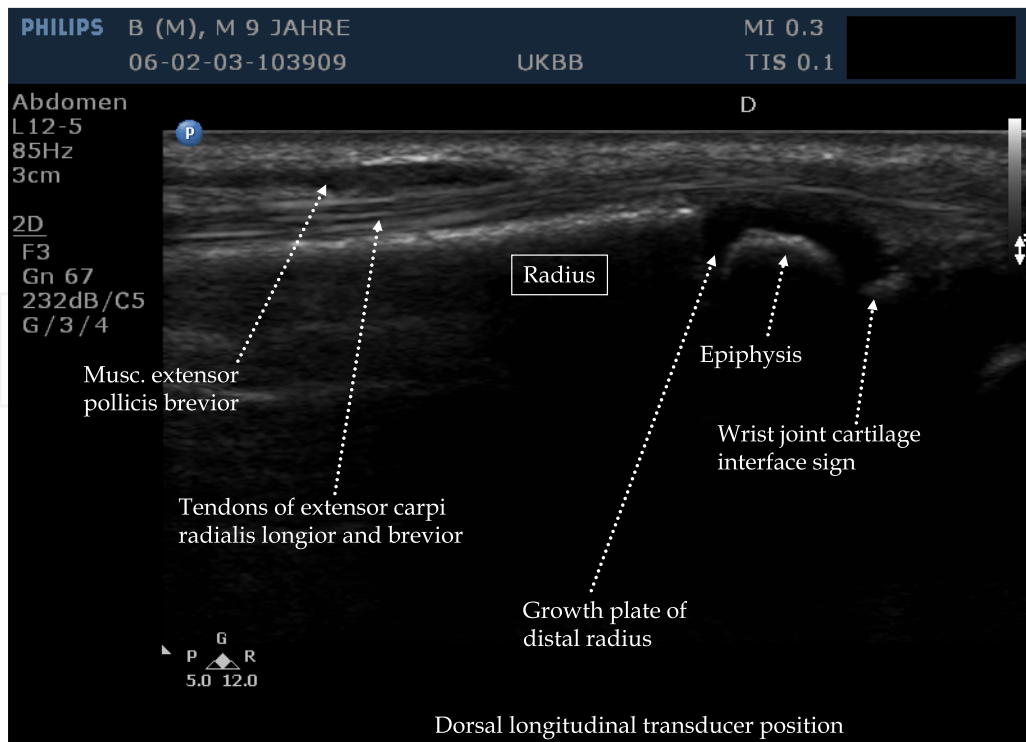


Fig. 7. Boy, 9 years of age; dorsal longitudinal transducer position. Linear 12-5 MHz probe is placed along the distal radius. The epiphyseal and growth plate cartilage of the distal epiphysis of the radius appears anechoic. Extensor tendons are overlying the dorsal contour of the distal radius.

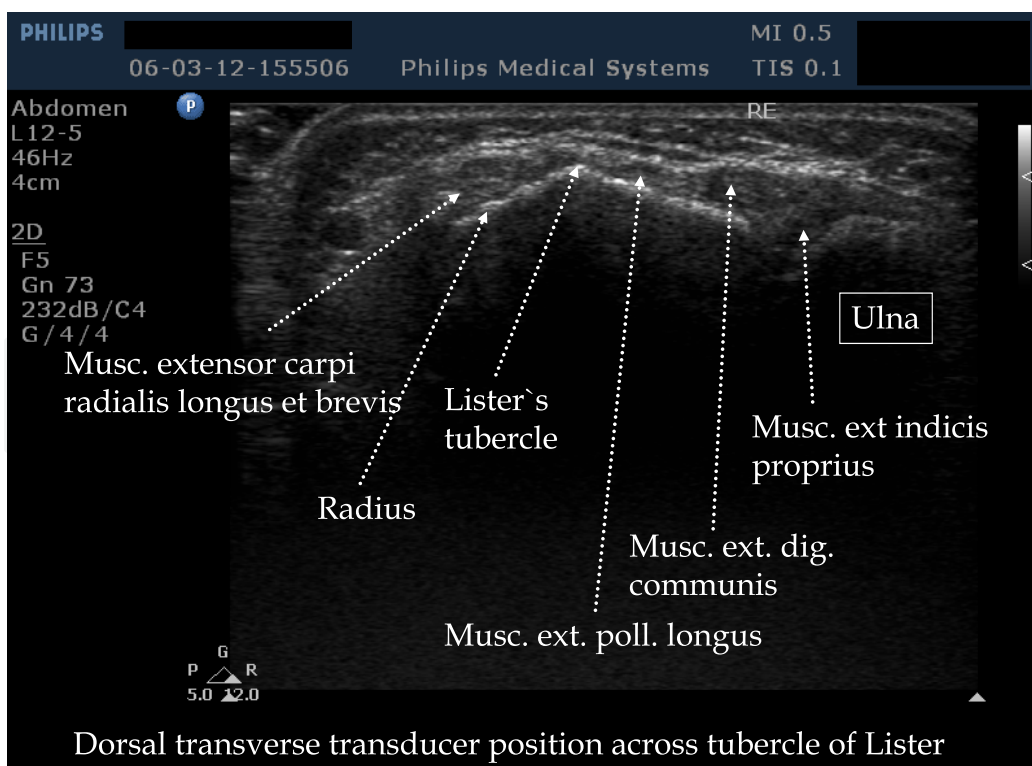


Fig. 8. Boy, 10 years of age; dorsal transverse transducer position. Linear 12-5 MHz probe is placed across Lister's tubercle. The extensor tendons are shown.

In 5 children of group 4 (12 - 18 years old) the distal radial epiphyseal growth plate was fused (20 %). In the remaining children, the epiphyseal growth plate cartilage was either anechoic (16 %)(Fig. 9) or anechoic with weak echogenic spots within the cartilage (64 %). The median nerve was identified by ultrasound in all children of group 4(Fig. 10). No vessels were noted penetrating the epiphyseal or growth plate cartilage at colour Doppler sonography.

During the growth period, characteristic morphologic changes occur within the distal part of the radius which can be sonographically observed. The secondary ossification centre within the distal radial epiphysis appears on plain x-ray images as late as three to eighteen months post partum. However, morphologic changes during ossification are clearly visible: firstly, towards the end of the first trimester, the epiphyseal centre shows an increasing echogenicity. Subsequently, a small epiphyseal area with high echogenicity and dorsal ultrasound extinction develops.

Using colour coded duplex sonography, vessels supplying the epiphyseal cartilage during the first and second year of life can be visualised frequently(Fig.1). Ultrasonographically, the periosteum is visible as a hyperechoic thin band-like structure, separated from the cortical reflex by a thin hypoechoic line.

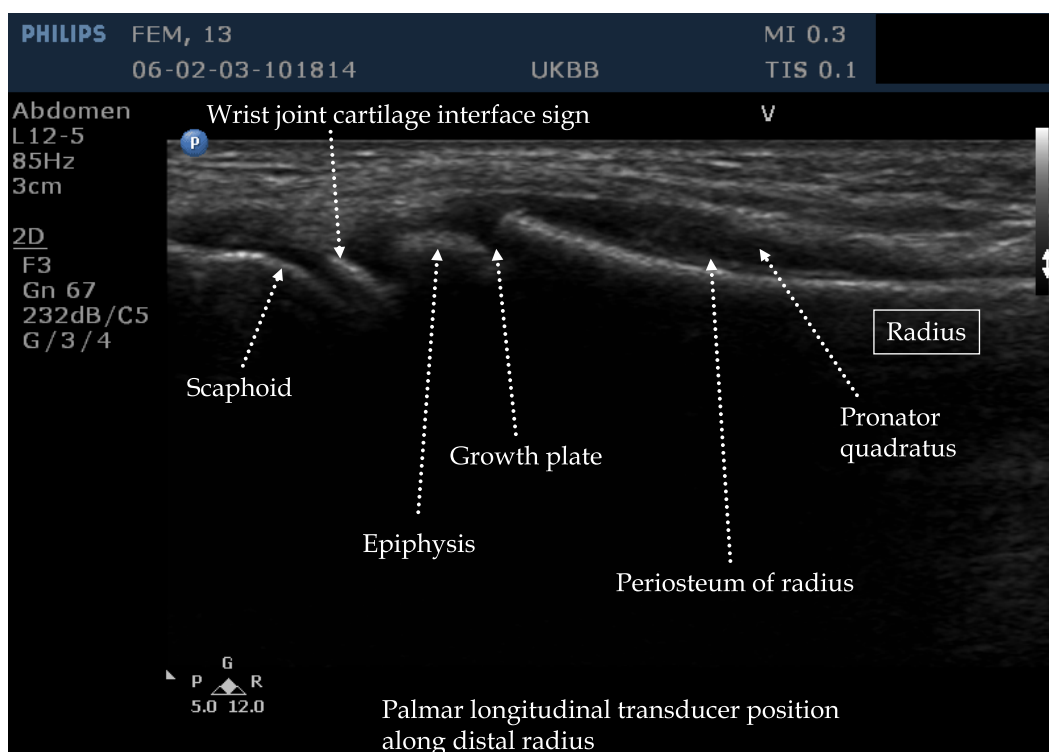


Fig. 9. Girl, 13 years of age; palmar longitudinal transducer position. Linear 12-5 MHz probe is placed along the distal radius. The cartilage interface sign is visible between the distal radius and the scaphoid articular cartilage.

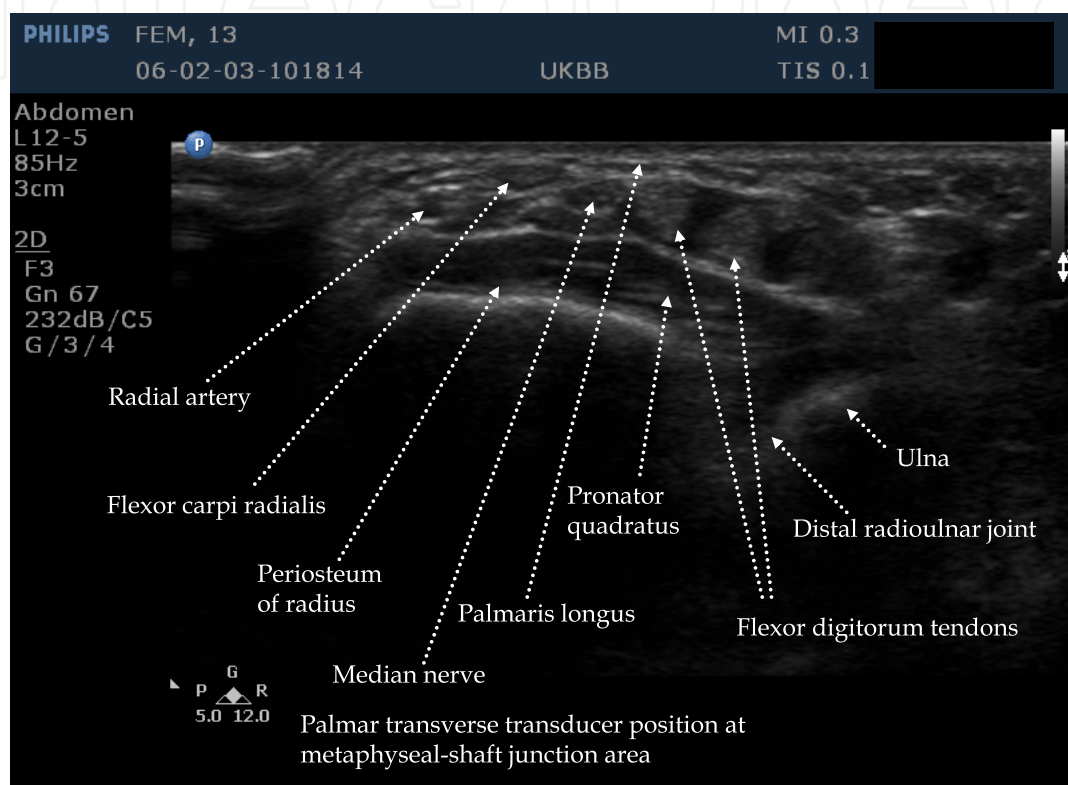


Fig. 10. Girl, 13 years of age; palmar transverse transducer position. Linear 12-5 MHz probe is placed across the distal metaphyseal-shaft junction of the forearm. Note the transverse muscle fibers of the pronator quadratus muscle. The median nerve and the flexor tendons are visualized.

The distal growth plate of the radius can not be differentiated from the cartilage of the epiphysis ultrasonographically, unless the secondary ossification centre is already discernable within the distal radial epiphysis (Fig. 1). The sonomorphologic characteristics of the distal radial growth plate are shown in Table 1. Its width gradually decreases during further development (Tab.1). With increasing age of the child, the chondro-osseous junction bends towards the epiphysis or appears slightly interdentated. Approaching the age of fusion of the distal radial epiphysis, it is represented by a narrow gap in the cortical bone and repetitive echoes can be seen posterior to the surface of the growth plate (Fig. 11).

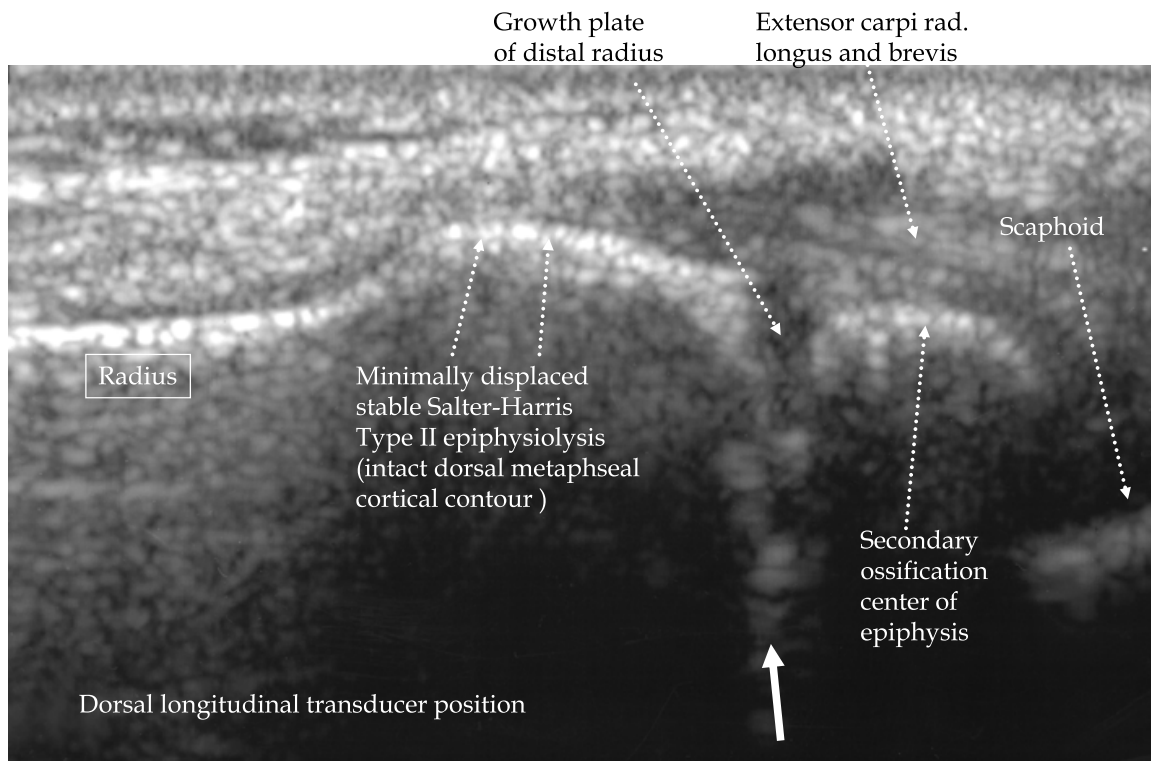


Fig. 11. Girl, 13 years of age; undisplaced Salter-Harris type II epiphysiolysis; This fracture is considered stable because there is no break in the dorsal metaphyseal corticalis of the radius. Longitudinal dorsal transducer position. Repetitive echoes are visible within the central part of the growth plate( marked by solid arrow).

Depending mainly on the gender of the individual, fusion of the distal radial epiphysis occurs between 15 and 18 years of age. During fusion of the distal radial physis towards the end of skeletal growth the gap like anechoic remnant of the physis was found to be wider on the dorsal side when compared to the palmar side of the radius.

*General findings:* At dynamic investigation using limited, slow movements of the wrist joint a characteristic change in shape and position of the median nerve was noted, whereas the palmaris longus tendon and flexor carpi radialis tendon showed longitudinal movements and nearly no change in shape. In contrast to the fine reticular fibrillary pattern of the flexor tendons the median nerve showed a coarse-grained fibrillary pattern.

After the occurrence of the hyperechoic secondary ossification centre of the distal radius the width of the dorsal epiphyseal cartilage was 1 - 2 mm wider when compared to the width of the volar epiphyseal cartilage (measurements taken between the dorsal contour of the secondary ossification centre and dorsal boarder of the epiphyseal cartilage); and the volar contour of the secondary ossification centre and volar contour of the epiphyseal cartilage (respectively).

## 6. Ultrasound applications in the region of the distal forearm

In the hands of an experienced clinician using high frequency linear probes (more than 7 MHz), and adequate equipment, ultrasonography is a suitable technique for the investigation of cortical structures and surrounding soft tissues<sup>3-6</sup>. Furthermore, there is the substantial advantage of dynamic examination, direct comparison to the contralateral limb and the lack of exposure to radiation<sup>5-7</sup>. As in most joints, the use of linear probes is also preferable in the distal radius region<sup>7</sup>. As the soft tissue coverage is relatively thin, high resolution and low penetration is preferable for this examination. Depending on the resolution capacity, the use of an echo-free standoff pad to increase the distance to the tissue can be helpful<sup>7</sup>.

In the longitudinal plane, tendons are depicted as longitudinal structures of high echogenicity with parallel echos<sup>3,5-7</sup>. In the horizontal plane, a punctuated reticular, hyperechoic tendon fibre structure is seen<sup>3,5-7</sup>. The examiner must take into account that the probe is aligned parallel to the tendon and the sonographic impulse is directed orthograde to the tendon<sup>7</sup>. When high frequency probes are used, deviations of 15° from the orthograde transducer position can change the echogenicity of tendons and nerves. Because of these physical phenomena, smooth circular surfaces of small dimension create a reflex only in that area, where the sound impulse arrives perpendicularly. Furthermore, if there is no "orthograde" alignment, the whole tendon diameter shows lower echogenicity<sup>7</sup>. Thus, not all tendons are clearly depicted in a transverse plane and areas of low echogenicity are found. These artefacts have to be kept in mind especially in the evaluation of pathologic changes of the peritendinous tissue and fluid accumulation within the tendon sheaths and the carpal canal, respectively<sup>7</sup>. However, even tendon aplasia in children can be accurately diagnosed using this ultrasonographic technique<sup>9</sup>.

Furthermore, it is very important to use an "orthograde" position of the probe towards the evaluated structure (bone, tendon) (Fig. 5,7). In most cases, it is impossible to find this position both for tendons and bones within one singular plane.

Ultrasonography can be considered as the gold standard for evaluation of tendinous disorders<sup>3,5-7</sup>, localization and differentiation of fluid accumulations (possibility of sonographically guided puncture)<sup>3</sup>, diagnosis of intraarticular effusions<sup>10</sup>, diagnosis of soft tissue tumors (ganglia, cysts, neuromas)<sup>3,4,11</sup> and foreign bodies<sup>5,12,13</sup>.

It is especially important in children to consider the radiation exposure during radiographic diagnosis and follow-up of fractures. At ultrasonography the metaphyseal cortex is easily identified as a marked hyperechoic line with a dorsal acoustic shadow. Subsequently, fractures can be clearly evaluated, as well (Fig.11). So, ultrasonography is a reliable tool for the follow-up of distal fractures of the radius in children. In addition to the evaluation of the fracture gap, the course of fracture consolidation supplemented by stability tests and dynamic examination can also be evaluated and estimated<sup>14</sup>. So the follow-up of fractures could be a special field of interest for ultrasonography in the children in the future. However, primary radiologic diagnosis will not be replaced by sonography, especially in fractures of the distal forearm region. It must be kept in mind, that obtaining an ultrasound study is more time consuming compared to obtaining X-rays. Ultrasonography is especially

suitable for the follow-up of fractures in children and adolescents, when there is no closed plaster cast applied. The examiner has to pay special attention to the investigation of the periosteum, as the width of the hypoechoic line between the periosteum and bone surface is of outstanding clinical relevance in the diagnosis of subperiosteal fluid accumulation, for example in acute osteomyelitis (Fig. 12). Therefore, it should only be evaluated in comparison to the contralateral limb. Due to the stable affixation of periosteum / perichondrium at the region of the growth plate, compared to the diaphyseal and metaphyseal region, subperiosteal fluid accumulations are only found in the metaphyseal and diaphyseal region (Fig. 12).

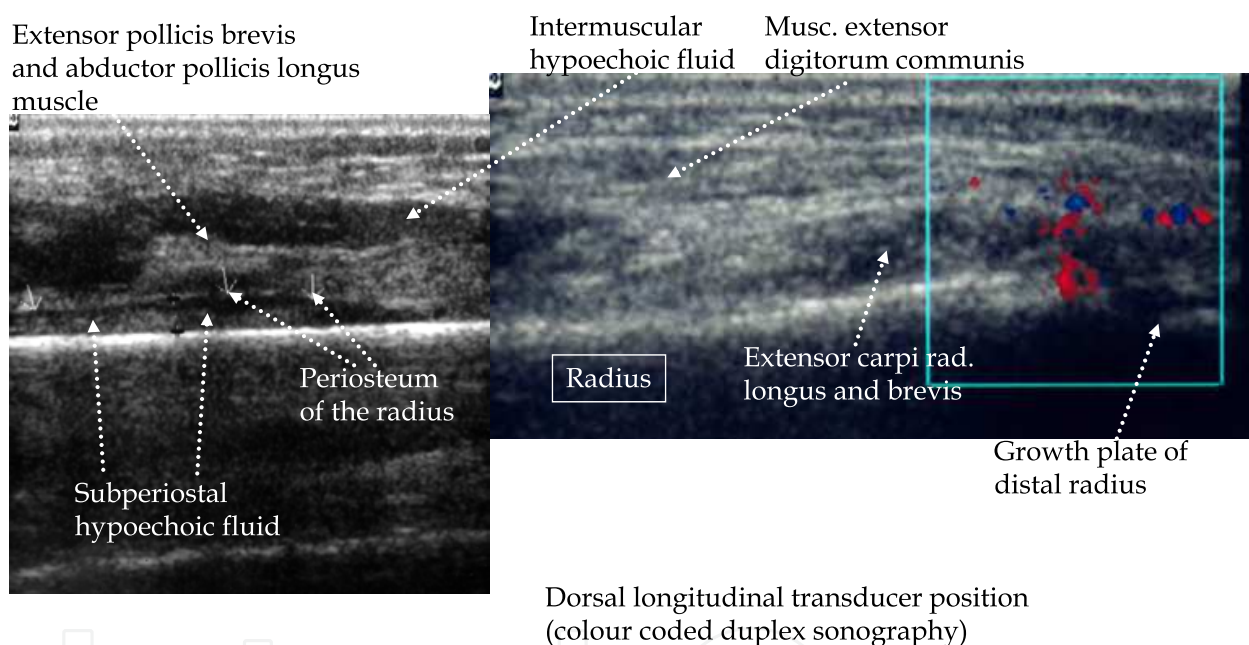


Fig. 12. Longitudinal distal dorsal-radial ultrasound scan in a boy aged 9 years suffering from acute osteomyelitis of the distal radius. The periosteum is detached from the corticalis of the distal radius, there is subperiosteal hypoechoic fluid accumulation with some low level echos. At operation acute purulent osteomyelitis of the distal radius complicated by subperiosteal abscess formation and phlegmonous infiltration of the intermuscular spaces between the forearm extensor muscles was confirmed.

However, difficulties might arise during investigation of intra- and extraarticular pathologic changes of low echogenicity. For example, the differentiation of purely chondral articulating surfaces is facilitated only by the depiction of the "cartilage interface sign", a smooth, hypoechoic borderline reflex at the region of the articular gap (Fig. 9).

## 7. Conclusion

High frequency ultrasonography can yield reliable information about the distal radial epiphysis and growth plate, the median nerve and the forearm tendons. The sonographic features of the normal distal forearm during growth described herein may hopefully contribute to a more widespread use of ultrasound in this anatomic region.

## 8. Acknowledgement

The authors want to thank Mrs. Helen Parker, Nottingham, GB for assistance in the translation of the manuscript.

No financial support for this investigation was given to any of the authors or their institutions.

## 9. References


- [1] Cohen E, Blankstein A, Rosenstock M, Atou D. Greenstick fractures of distal radius followed-up by ultrasound - a prospective study. *Akt Traumatol* 2000; 30:227-229
- [2] Hübner U, Schlicht W, Outzen S, Barthel M, Halsband H. Ultrasound in the diagnosis of fractures in children. *JBJS* 2000; 82B:1170 -3
- [3] Ferrara Ma, Marcelis S. Ultrasound of the wrist. *J Belge Radiol* 1997;80:78-80
- [4] Fornage BD. Peripheral nerves of the extremities: imaging with US. *Radiology* 1988;167:179-18
- [5] Fornage BD, Schernberg FL, Rifkin MD. Ultrasound of the hand. *Radiology* 1985;155:785-8
- [6] Fornage BD, Rifkin MD. Ultrasound examination of the hand and foot. *Radiol Clin North Am* 1988;26:109-29
- [7] Fornage BD: The hypoechoic normal tendon - a pitfall. *J Ultrasound Med* 1987;6:19-22
- [8] Nakamichi K, Tachibana S. Transverse sliding of the median nerve beneath the flexor retinaculum. *J Hand Surg* 1992; 17B: 213-216
- [9] Grechenig W, Mayr J, Clement H, Peicha G. Aplasia of the flexor tendon of the fifth finger in a new born child - sonographic diagnosis. *Eur Surg* 2002; Suppl. 184 : 114-115.
- [10] Fornage BD. Soft-tissue changes in the hand in rheumatoid arthritis: evaluation with US. *Radiology* 1989; 173: 735-737
- [11] Cardinal E, Buckwalter KA, Braunstein EM, Mik AD. Occult dorsal carpal ganglion: comparison of ultrasound and MR imaging. *Radiology* 1994;193: 259-262
- [12] Jacobson JA, Powell A, Craig J, Bouffard J, Van Holsbeeck M. Wooden foreign bodies in soft-tissue: detection at US. *Radiology* 1998; 206: 45-48
- [13] Fornage BD, Schernberg FL. Sonographic preoperative localization of a foreign body in the hand. *J Ultrasound Med* 1987;6:217-9



- [14] Dias JJ, Hui ACW, Lamont AC. Real time ultrasonography in the assessment of movement at the site of a scaphoid fracture non-union. *J Hand Surg* 1994;19B: 498-504

IntechOpen

IntechOpen



## **Orthopedic Surgery**

Edited by Dr Zaid Al-Aubaidi

ISBN 978-953-51-0231-1

Hard cover, 220 pages

**Publisher** InTech

**Published online** 09, March, 2012

**Published in print edition** March, 2012

Orthopaedic surgery is the widest and the strongest growing surgical specialty. It is clear, that the process of improving treatments and patients care, requires knowledge, and this requires access to studies, expert opinion and books. Unfortunately, the access to this knowledge is being materialized. As we believe that access to the medical knowledge should be reachable to everyone free of charge, this book was generated to cover the orthopaedic aspect. It will provide the reader with a mix of basic, but as well highly specialized knowledge. In the process of editing this book, my wife Jurgita has been, as usual, the most supportive person. I would like to thank her for being in my life. I would like to thank Mr. Greblo, the Publishing Process Manager, for all his help and last but not least thanks to our readers, as without them this book would have no meaning.

### **How to reference**

In order to correctly reference this scholarly work, feel free to copy and paste the following:

Johannes M. Mayr, Wolfgang Grechenig, Ursula Seebacher, Andreas Fette, Andreas H. Weiglein and Sergio Sesia (2012). The Distal Forearm Region - Ultrasonographic Anatomy in Children and Adolescents, Orthopedic Surgery, Dr Zaid Al-Aubaidi (Ed.), ISBN: 978-953-51-0231-1, InTech, Available from: <http://www.intechopen.com/books/orthopedic-surgery/the-distal-forearm-region-ultrasonographic-anatomy-in-children-and-adolescents>

**INTECH**  
open science | open minds

### **InTech Europe**

University Campus STeP Ri  
Slavka Krautzeka 83/A  
51000 Rijeka, Croatia  
Phone: +385 (51) 770 447  
Fax: +385 (51) 686 166  
[www.intechopen.com](http://www.intechopen.com)

### **InTech China**

Unit 405, Office Block, Hotel Equatorial Shanghai  
No.65, Yan An Road (West), Shanghai, 200040, China  
中国上海市延安西路65号上海国际贵都大饭店办公楼405单元  
Phone: +86-21-62489820  
Fax: +86-21-62489821

© 2012 The Author(s). Licensee IntechOpen. This is an open access article distributed under the terms of the [Creative Commons Attribution 3.0 License](#), which permits unrestricted use, distribution, and reproduction in any medium, provided the original work is properly cited.

IntechOpen

IntechOpen