

We are IntechOpen, the world's leading publisher of Open Access books Built by scientists, for scientists

4,800

Open access books available

122,000

International authors and editors

135M

Downloads

Our authors are among the

154

Countries delivered to

TOP 1%

most cited scientists

12.2%

Contributors from top 500 universities

**WEB OF SCIENCE™**Selection of our books indexed in the Book Citation Index
in Web of Science™ Core Collection (BKCI)

Interested in publishing with us?
Contact book.department@intechopen.com

Numbers displayed above are based on latest data collected.
For more information visit www.intechopen.com



Nd:YAG Laser (1064 nm) in Management of Pilonidal Sinus

Ezzat A. Badawy
¹Alexandria University
²Americal Safat Medical Center
¹Egypt
²Kuwait

1. Introduction

Pilonidal sinus (PNS) is chronic inflammatory process of the skin in the cleavage between the buttocks (natal cleft). It is caused by keratin plug and debris clinically observed as a pit, having penetrated the dermis (1). The term pilonidal comes from a combination of Latin words meaning hair (pilus) and nest (nidal). PNS was first described by Hodges in 1880 (2).

PNS occurs ten times more often in men than in women (3). This may be attributed to the presence of more hair in men than in women. PNS usually occurs after puberty (4). PNS is more likely to occur in obese people and in those with thick, stiff body hair. Although the upper natal cleft is the most common site (Figure 1), PNS may occur in other sites especially where there is irregularity of skin surface with pressure applied to that region (5). The same condition can be seen in the clefts between fingers in those persons dealing with hair such as barbers and hairdressers (6, 7). It has been reported in other areas such as the umbilicus (8-10), the interdigital spaces of the foot (11), the finger pulp (12), the clitoris (13, 14), penis (15-17), the intermammary (18), the periungual (19) and the perineal regions (20).

2. Clinical picture

2.1 Etiology

The origin of the problem is not well understood. In the past, PNS was thought to be a congenital condition. However, there is nearly a consensus that it is an acquired condition. PNS has high incidence in certain communities which can be explained by the different hair distribution and its growth pattern. The condition is less common in Asians and Africans than in Caucasians (21). Nevertheless, most of the investigators suggest the acquired theory of PNS. Certain factors may be in favor of the occurrence of PNS. These factors are hormonal, presence of hair, friction, sitting or driving for long periods and infection. The risk factors of PNS were found in one study to be sedentary occupation (44%), positive family history (38%), obesity (50%) and local irritation or trauma prior to onset of symptoms (34%) (4). Akinci et al have studied the incidence of certain etiological factors in soldiers with and without PNS. They found that family history; obesity; being the driver of a vehicle;

and having folliculitis or a furuncle can be associated with the presence of PNS (22). Harlak et al have suggested that hairy people who sit down for more than six hours a day and those who take a bath two or less times per week have an increased risk for PNS than those without these risk factors (23).

Hormonal factor was thought to be one of the factors that can play a role in the etiology of PNS. At puberty, androgens are secreted to enhance the development of the pilo-sebaceous glands, which coincides with the onset of PNS (24). The early presentation of PNS is the visible pit in the midline of the natal cleft. This is actually the microscopic appearance of enlarged hair follicles. The weight of the buttocks can cause stretching of the follicular openings (25). It is explained by relatively high force of buttocks' weight applied over very small area of pilo-sebaceous follicle (about 1 mm²), over the sacro-coccygeal joint. All the movements and sitting for long time can amplify the force applied to this area. When the force applied reaches a critical level, this can cause rupture of the follicle base; the weakest part. The friction between buttocks is another factor added to this force which can help for sucking keratin and hair into the distended follicles.

It has been postulated for long time that hair follicles were the source of PNS (25). Recently, studies have found that the specimens of excised lesions had the pits penetrating into the dermis but not all of them arose in hair follicles (26). Nevertheless, the hair has an important role in the development of inflammation. Sorts of treatments directed against hair follicles gave very good therapeutic effects.

2.2 Patho-physiology

In 1992, Karydkis has explained the patho-physiology of the PNS as an acquired condition. He called it "The hair insertion process". It consists of three main factors; the loose hair, the presence of vacuum force and the vulnerability of the skin (27). The entering hair causes an inflammatory foreign body reaction which can lead to the formation of multiple micro-abscesses. Eventually, that migrates further into the subcutaneous tissue forming a sinus which might complicate by abscess formation or creating more sinus tracts that open laterally forming fistulous tracts. However, during the surgical operations, only 50-70% of PNS had actually been found to contain hair (1, 28).

2.3 Symptoms and signs

Symptoms of PNS vary from a small asymptomatic dimple to a huge painful abscess with oozing pus (29). Early lesion appears as a pit or dimple which may be asymptomatic for the patient. However, PNS can cause discomfort and pain. Severe acute pain with or without a purulent discharge may be the presentation when an abscess is formed. Suppuration is very annoying to the patients causing staining of the underwear with unpleasant smell.

Chronic pain is the usual presentation of the chronic and complicated cases. Discharge, fistulae and disfiguring scarring can be seen in the neglected cases (4). On clinical examination, single or multiple sinuses can be seen. Discharge, debris and hair are seen arising from the sinus (Figure 1). Recurrent lesion is a common feature even after complete and wide surgical excision of PNS (Figure 2). Surgical treatment and recurrence lead to permanent scarring (Figure 3).

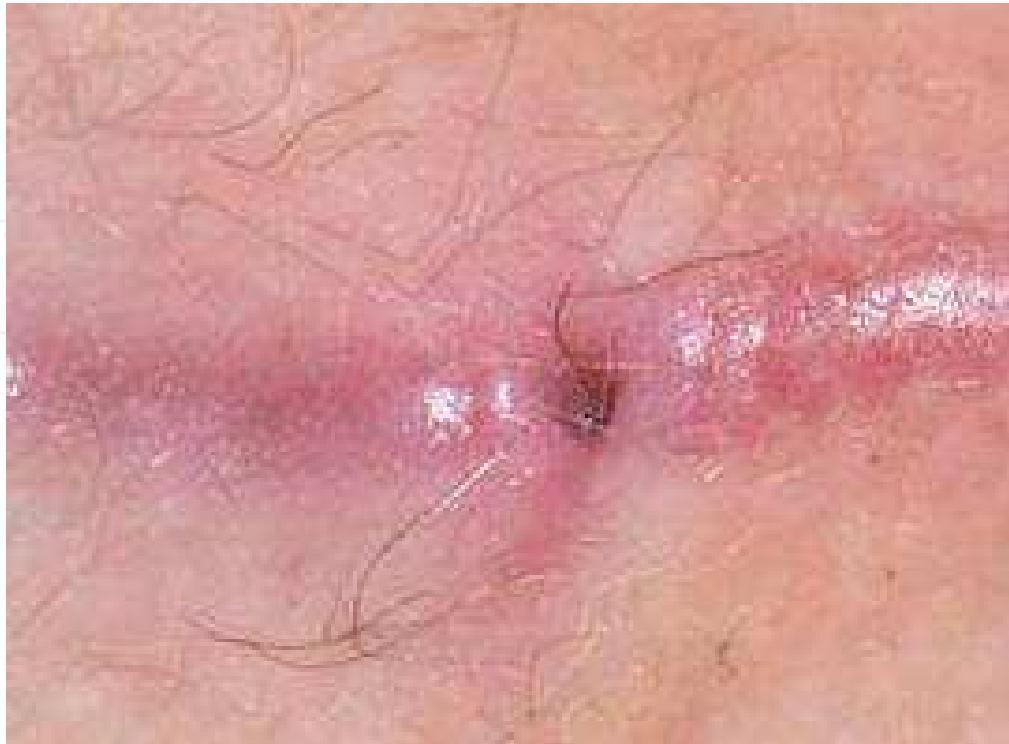

Fig. 1. PNS with hair protruding out of its opening. (Provided by Dr. Metwally Afifi)

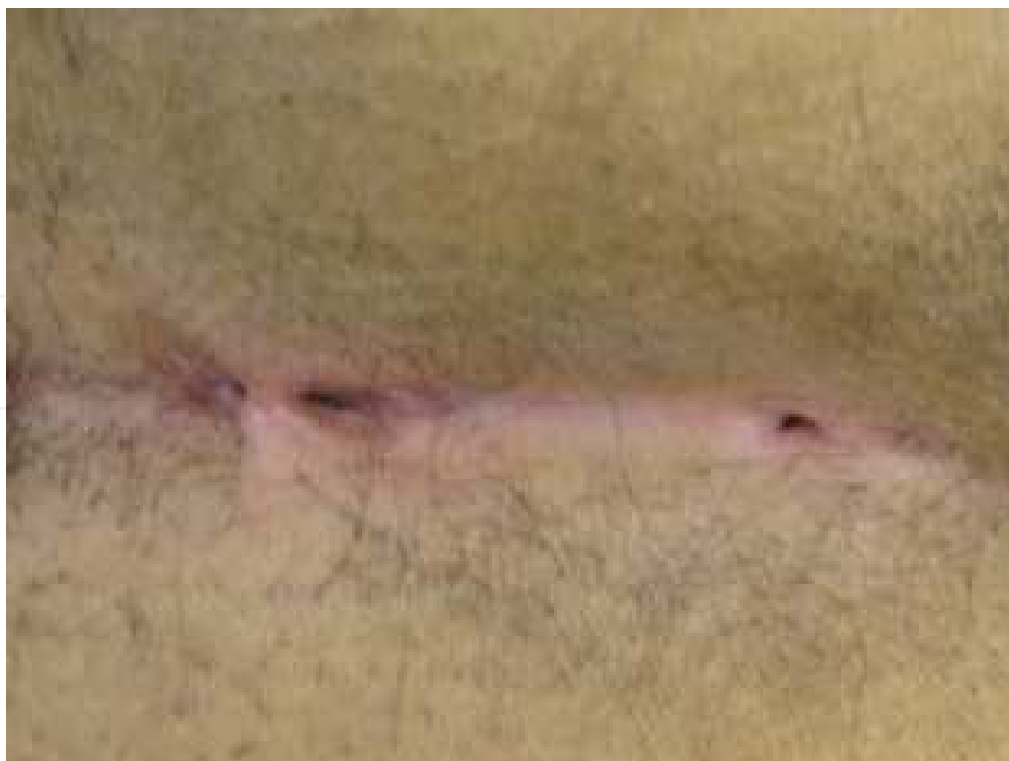

Fig. 2. Recurrent PNS. (Provided by Dr. Metwally Afifi)

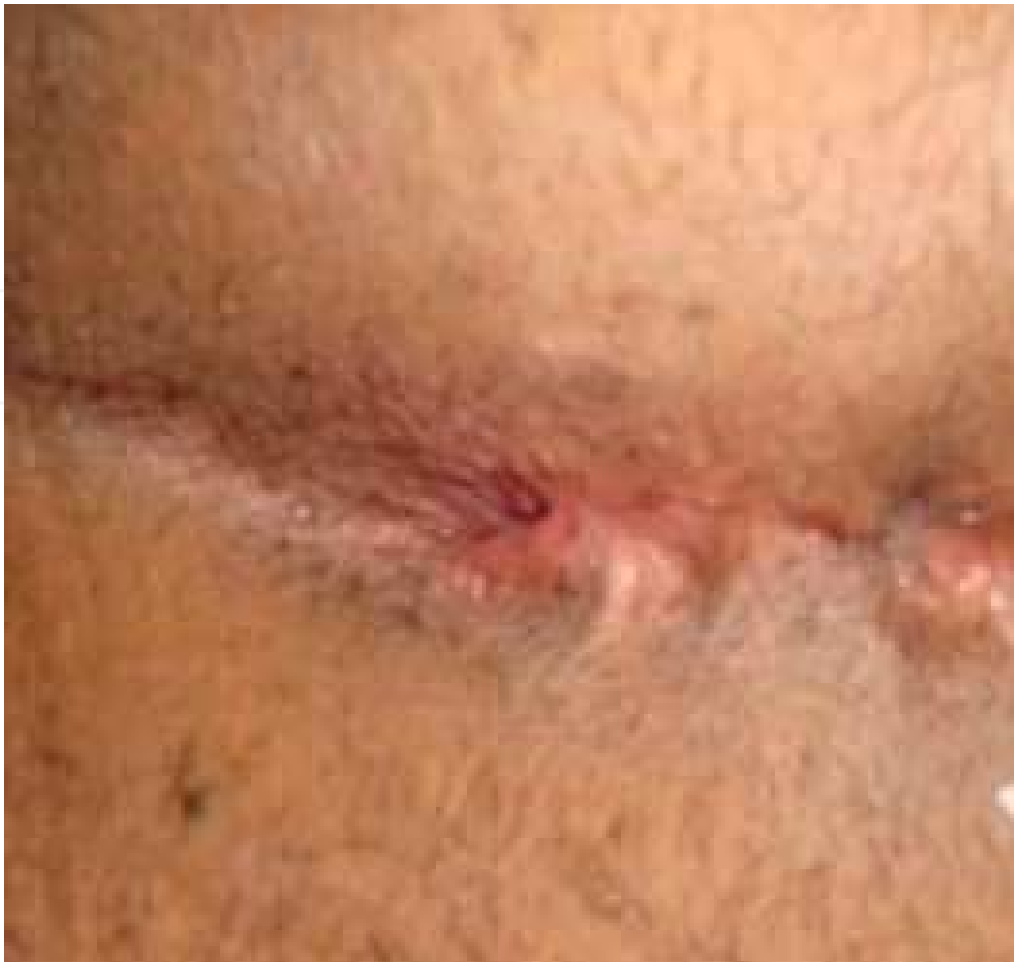

Fig. 3. Recurrent PNS with scarring and fistula. (Provided by Dr. Metwally Afifi)

2.4 PNS complications

Abscess formation is the most common complication of PNS. Recurrence rate of PNS (Figures 2 and 3) is very high whatever the sort of management (30). Chronicity of PNS can develop if the drainage at the abscess stage is not adequate. Development of fistulae is common due to repeated infection with suppuration with subsequent scarring (Figure 3). Systemic infection is a rare complication. Severe pyomyositis caused by methicillin-sensitive *Staphylococcus aureus* was reported secondary to an operated PNS in an apparently healthy young male patient (31). Moreover, septic arthritis was reported in a patient with rheumatoid arthritis after the resection of PNS (32). Although Actinomycosis associated with PNS of the penis is extremely rare, few cases have been reported (16, 17, 33). Neglected PNS can lead to unusual and life-threatening consequences. Necrotizing fasciitis and toxic shock syndrome have been developed in a previously healthy patient (34).

PNS rarely develops malignant changes (26, 35). If it happens, squamous cell carcinoma is the most common presentation (26, 36). Malignant changes usually occur in young men on very long standing antecedent recalcitrant PNS. Malignant changes of a chronic wound have worse prognosis than skin malignancy arising de novo (37). Although malignant change of PNS is rare, it carries bad prognosis.

2.5 Pathology

The pathological findings occurred in PNS were thought to be mainly due to the hair entry and its subsequent changes. The enlargement of follicles precedes the presence of hair inside the developed PNS (25). Being a foreign body inside PNS, hair is the main cause of the inflammatory reaction with subsequent edema, distension and obstruction of the pilosebaceous follicle. Infection can cause suppuration leading to abscess formation. If the patient is not probably treated, a chronic abscess will develop. Both aerobe and anaerobe can be detected in PNS (38, 39). The tissue can form a track to drain the abscess leading to sinus. Recurrence is a main feature of this condition. PNS rarely develops malignant changes (26, 35).

The histologic examination of PNS revealed the presence of chronic inflammation surrounding a sinus in the sub-cutaneous tissue. Hair in sinuses was found in three quarters of the specimens examined. Examination showed that hair entered via one of the created sinus openings. Pits were found to be indentations of the skin containing keratin plugs and debris. They may be isolated or connected with hair follicles (1).

2.6 Laboratory studies

The diagnosis of PNS is easy and depends mainly on clinical inspection and localization of the lesion. No specific laboratory tests are needed to confirm the diagnosis. Swab from oozing pus in acute abscess may be needed to do bacterial culture and antibiotic sensitivity. Excisional biopsy and histo-pathologic examination can be carried out for neglected cases and when malignancy is suspected.

3. Surgical management of PNS

Patients with mild form of PNS with no marked symptoms need no surgical intervention at this stage (26) but proper hygiene and hair removal are needed to prevent inflammation and complications. There are many types of surgical interventions to treat PNS (40-47). Nevertheless, all forms of surgical management have a significant failure rate, with a high incidence of recurrence (30). No single surgical technique can be relied upon to prevent recurrence (5). Different modalities of surgery have been used, but they often result in recurrence, and additional surgery is needed (30, 40). Conservative methods have been applied to treat PNS. The most commonly used conservative treatment is injecting phenol as a sclerosing agent (48 - 50).

The choice of the surgical intervention depends on the severity of signs and symptoms, being primary or recurrent and presence or absence of complications. If the patient presents with an abscess, primary incision and drainage of purulent discharge should be performed to relief symptoms. Complete drainage of the discharge with curettage to remove debris and infected tissue is important to improve the rate of healing (43). The application of platelet-derived growth factors to the post-operative PNS wound enhanced the healing process (51). Systemic antibiotics have been found to improve the healing rate after surgical excision (52). Otherwise, surgical excision of PNS may be followed by either primary closure or closure by secondary intention. Surgical unroofing of primary PNS gave a shorter time to heal and carried a lower complication rate compared to wide local excision (53). Recently, it is advocated to do surgical excision with primary closure (54).

Whatever the sort of management and surgical procedure in treating PNS, the recurrence rate is high (41-43). Reconstructive surgical procedures after excision of the PNS can be performed in cases of failure of the classic excision and for complex or complicated PNS (55-59).

4. ND:YAG laser in management of PNS

4.1 Role of Laser hair removal (LHR)

Management of PNS should be directed to treat the underlying etiological factors. Cubukcu et al had found that obese patients with high body mass index had a higher risk of recurrence of PNS after surgical intervention (60). Nevertheless, Cubukcu et al in another study have found that obesity alone is not an important factor in the etiology of PNS (61). Moreover, the presence of the hair seems to be the most important triggering factor in the pathogenesis and recurrence of PNS. By different ways of approach, many studies have confirmed the role of hair in the evolution and inflammation of PNS. Karydakos has concluded that hair insertion is the cause of PNS, and it prevents spontaneous recovery and delays healing of any wound in the depth of the natal cleft. He stated that hair is the cause of recurrence (27). Moreover, removal of hair can prevent further inflammation, progression and recurrence of PNS (62 - 64). As a conclusion of the extensive research carried out on the different types of PNS, management objectives should be directed not only at eradicating the obvious lesion present but also to prevent recurrence through managing the etiological factors. The re-accumulation or re-growth of hair may be the most important factors in the development of inflamed PNS (5). Odili and Gault have concluded that Laser hair removal (LHR) in the natal cleft is by no means a cure for PNS. Removal of hair by laser represents an alternative and effective method of hair removal. They have studied the effect of laser on the healing process of PNS. LHR was found to allow the PNS to heal rapidly. Odili and Gault have stated that LHR should thus be considered as an aid to an effective healing tool of the problem (65). As a matter of fact, removal of the hair in the natal cleft can prevent inflammation and recurrence of PNS. Nevertheless, regular razor epilation of hair increased the recurrence rate of PNS (66). Razor hair epilation can insert hair into skin and thus, it can aid in PNS recurrence and inflammation. Because LHR was found to be an effective adjunct in preventing the recurrence of PNS, many investigators suggested that LHR should be offered routinely to all patients (63, 64, 67 - 69). In a case report, a patient with recurrent PNS was satisfactorily treated by LHR using a ruby laser. The follow up period was 6 months (70). It is well documented now that eliminating the hair of the affected area could be a new approach to the treatment of patients with PNS. Six young men having PNS in a study done by Landa et al have also been treated by LHR. None of those patients experienced recurrence of PNS. Landa et al have concluded that LHR of the natal cleft should be considered a first choice treatment for recurrent PNS. Preventive LHR of the natal cleft in patients with recurrent folliculitis could avoid future surgery (71). Benedetto and Lewis have treated two patients with recalcitrant PNS by LHR using diode laser (72).

4.2 Advantages of Nd:YAG LHR

The destruction of hair follicles by laser is very efficient and popular method worldwide. Different types of laser and non-laser machines are used remove hair permanently (73), namely; normal mode ruby laser (694 nm), normal mode alexandrite laser (755 nm), diode lasers (800, 810 nm), Nd:YAG laser (1,064 nm), and intense pulsed light (IPL) sources (590-

1,200 nm). Moreover, Nd:YAG laser has peculiar advantages over the other devices. Nd:YAG laser was superior in hair reduction than Diode laser and it provided higher patient satisfaction (74). The wave-length of Nd:YAG-laser is 1064 nm. Consequently, the penetration of the laser beam through the skin is deeper than the other known lasers targeting the melanin and thus, it can treat the hair follicles which are present in the deeper part of skin. Because of its deeper penetration, it can reach also the base of PNS.

As general potential side effects, all laser types can potentially cause scarring, hypo, or hyperpigmentation especially in dark skin types. The risk of skin types V and VI to get either hypo- or hyper-pigmentation following laser treatment is very high. Nevertheless, this risk is very low with Nd:YAG laser. Nd:YAG laser can be used to treat all skin types with less risk of discoloration. Even skin type VI can be treated safely with this type of laser. Moreover, Nd:YAG laser has much less complications compared to other types of laser. Studies done by Goh (75) and Lanigan (76) have shown that Nd:YAG laser has been used successfully to treat abnormal hair in patients with skin types V and VI. In both studies, no risk of serious adverse side effects has been noted with the Nd:YAG laser (75, 76). However, pain is the most prominent side effect of Nd:YAG laser (62, 75, 76). Good cooling during treatment and proper choice of laser parameters can reduce the perception of pain.

4.3 Experience of Nd:YAG laser in PNS

We have carried out a study on twenty five patients to evaluate the effect of Nd:YAG LHR on the recurrence rate of PNS following surgical treatment. Fifteen of the patients have undergone LHR using Nd:YAG laser while ten patients did not have LHR during the study and follow-up period. All the twenty five patients underwent surgical excision to remove PNS prior to LHR sessions. None of the patients who performed LHR by Nd:YAG laser had shown recurrence of PNS during the study and follow-up period. Recurrence of PNS was seen in seven of those who had no LHR (62). Pain was the most prominent side effect seen in our study as it was a complaint of six patients out of fifteen. Nevertheless, the pain did not affect the patients passively. Two thirds of the patients were either satisfied or highly satisfied. All patients appreciated the improvement of hair density to different degrees. The degree of improvement was correlated with the number of LHR sessions. Avoidance of further surgical intervention was achieved by the use of Nd:YAG laser.

4.4 Protocol of Nd:YAG LHR in treatment of PNS

Generally, it is preferable to do primary closure of the excised PNS wound to assure rapid healing and to minimize the post-operative pain. LHR can be started after complete wound healing. Before doing LHR treatment, the area to be treated should be shaved and cleaned with local non-irritant antiseptic cleanser. Usually, no topical anesthetic cream should be applied before Nd:YAG laser treatment. However, sensitive patient can use topical EMLA cream one hour prior to treatment. Hair removal by Nd:YAG (1064-nm wavelength) laser is carried out in its normal mode. The usual spot size of the laser beam used in hair removal is ranged between 10 to 15 mm. The spot size more than 15 mm can be more painful. The range of effective laser fluence depends on the used laser spot size. Fluence of 35 to 50 J/cm² can be used with 10 mm spot size laser beam. Less fluence can be used for larger spot size. In case of dark skin types, it is advised to use longer laser pulse width than that used for lighter skin. Skin type VI needs pulse width of 35 - 40 msec. or more. The laser treatment

should be accompanied with a cooling method to alleviate the potential pain of laser. The cooling air is widely used and it is effective as well. It should be used during the whole laser treatment. The laser treatment is carried out on the area of natal cleft, extending at least 5 cm laterally in both sides, up to 5 cm above the PNS scar and down to the anal orifice. Larger area can be treated especially in hairy persons.

Mild to moderate erythema is seen immediately after treatment and it lasts few minutes up to few hours. Skin of the treated area becomes warm. Cooling of the skin is achieved by application of an ice-pack on the treated area immediately after treatment. Soothing gel and local antibiotic cream can be applied to reduce any unpleasant sensation and to avoid secondary infection. Non-infective folliculitis may be seen later on. If it happens, it lasts two to three days. Patients are examined clinically before each treatment in order to assess the degree of hair reduction, to exclude recurrence of PNS, to exclude any sign of infection, and to record any side effect. Treatments are usually performed at 6- to 8-week intervals. The intervals between sessions are becoming prolonged with advancement of treatment. That is because the hairs take more time to re-grow. Hair density in the treated area is becoming less with treatment and hair caliber is getting finer. Generally, the patients are requested to do session of LHR once they noticed regrowth of hairs. Fine hairs usually need more treatment sessions than coarse dark hairs.

4.5 Future treatment of PNS by Nd:YAG laser

Unpublished research has been carried out to evaluate the effect of Nd:YAG laser in treating the PNS itself without performing any surgical interventions. The underlying concept was to destroy the hairs inside the PNS itself in order to evaluate the subsequent effect on the inflamed PNS lesion. The preliminary results were very promising. The use of Nd:YAG laser can accelerate the healing of inflamed PNS. It helped in achieving marked improvement of mild to moderate lesions without carrying out surgical treatment. One of our treated patients had long history of unhealed post-operative wound which lasted few months. The unhealed wound showed rapid healing after Nd:YAG laser treatment. Other investigators have used Nd:YAG laser in the same way to treat PNS. Lindholt et al have succeeded in treating a case of PNS by Nd:YAG laser (77). Bashir and Kurwa have used the laser to destroy the hair within an active PNS in a 30-year-old white male patient, in order to remove the source of the foreign body reaction. They succeeded in treating the PNS which was finally healed (78).

Studies have shown that Nd:YAG laser is a good tool in different therapeutic aspects. It is very effective in hair removal, treating vascular lesions, for skin rejuvenation and as surgical ablation device. No risk of serious adverse side effects has been noted with the Nd:YAG laser (75, 76). Palesty et al have used it in pilonidal cystectomy. Patient postoperative satisfaction after laser excision was greater when compared with those who had traditional surgical excisions. Postoperative pain was less (79). Excision of PNS by laser seems to be promising therapeutic modality in the management of this condition.

5. Conclusion

Treatment of PNS is important, not only to alleviate pain and to reduce inflammation, but also to avoid long term complications. Malignant transformation is one of the important fatal complications (80) m60). Although the Malignant degeneration of PNS is a rare complication, it is associated with a high recurrence rate and poor prognosis (81) m61). The

management of both asymptomatic non-inflamed, recurrent and inflamed PNS can be directed towards removal of the hair in the area by Nd:YAG laser. It can be done before the surgical intervention and post-operative to prevent recurrence. PNS itself can be removed by Nd:YAG laser and thus, patients can avoid risk of surgical complications. Nd:YAG laser may be a hope for this benign yet troublesome condition.

6. Acknowledgement

We kindly thank Dr. Metwally Afifi, consultant of general surgery, Al-Safat American Medical Center (Kuwait) for providing us with PNS photos.


7. References

- [1] Sondena K, Pollard ML. Histology of chronic pilonidal sinus. *APMIS (Acta Pathologica, Microbiologica, et Immunologica Scandinavica)* 1995; 103(4): 267-72
- [2] Hodges RM. Pilonidal sinus. *Boston Med Surg J* 1880; 103: 485-586.
- [3] Dwight RW, Maloy JK. Pilonidal sinus: experience with 449 cases. *N Engl J Med* 1953; 249: 926-30
- [4] Sondena K, Andersen E, Nesvik I, Soreide JA. Patient characteristics and symptoms in chronic pilonidal sinus disease. *Int J Colorectal Dis* 1995; 10(1): 39-42.
- [5] Stephens FO, Stephens RB. Pilonidal sinus: management objectives. *Aust N Z J Surg.* 1995; 65(8): 558-60.
- [6] Vergles D, Cupurdija K, Lemac D, Legac A, Kopljar M. Interdigital pilonidal sinus in a female hairdresser. *ANZ J Surg.* 2010; 80(11): 856.
- [7] Aydin HU, Mengi AS. Recurrent interdigital pilonidal sinus treated with dorsal metacarpal artery perforator flap. *J Plast Reconstr Aesthet Surg.* 2010; 63(12): e832-4.
- [8] Eby CS, Jetton RL. Umbilical pilonidal sinus. *Arch Dermatol.* 1972; 106(6): 893.
- [9] Abdelnour A, Aftimos G, Elmasri H. Conservative surgical treatment of 27 cases of umbilical pilonidal sinus. *J Med Liban.* 1994;42(3):123-5.
- [10] Abdulwahab BA, Harste K. Umbilical pilonidal sinus. *Ugeskr Laeger.* 2010; 172(41): 2848-9.
- [11] O'Neill AC, Purcell EM, Regan PJ. Interdigital pilonidal sinus of the foot. *Foot (Edinb).* 2009; 19(4): 227-8.
- [12] Grant I, Mahaffey PJ. Pilonidal sinus of the finger pulp. *J Hand Surg Br.* 2001; 26(5): 490-1.
- [13] Palmer E. Pilonidal cyst of the clitoris. *Am J Surg.* 1957; 93(1): 133-6.
- [14] Baker T, Barclay D, Ballard C. Pilonidal cyst involving the clitoris: a case report. *J Low Genit Tract Dis.* 2008; 12(2): 127-9.
- [15] Rao AR, Sharma M, Thyveetil M, Karim OM . Penis: an unusual site for pilonidal sinus. *Int Urol Nephrol.* 2006;38(3-4):607-8.
- [16] Chikkamuniyappa S, Scott RS, Furman J. Pilonidal sinus of the glans penis associated with actinomyces case reports and review of literature. *ScientificWorldJournal.* 2004; 4: 908-12
- [17] Val-Bernal JF, Azcarretazabal T, Garijo MF. Pilonidal sinus of the penis. A report of two cases, one of them associated with actinomycosis. *J Cutan Pathol.* 1999; 26(3): 155-8.
- [18] Sunkara A, Wagh D, Harode S. Intermammary pilonidal sinus. *Int J Trichology.* 2010; 2(2): 116-8

- [19] Ngan PG, Varey AH, Mahajan AL. Periungual pilonidal sinus. *J Hand Surg Eur* 2011; 36(2): 155-7
- [20] Testini M, Miniello S, Di Venere B, Lissidini G, Esposito E. Perineal pilonidal sinus. Case report. *Ann Ital Chir.* 2002; 73(3): 339-41
- [21] Berry DP. Pilonidal sinus disease. *J Wound Care* 1992; 1(3): 29-32.
- [22] Akinci OF, Bozer M, Uzunköy A, Düzgün SA, Coşkun A. Incidence and aetiological factors in pilonidal sinus among Turkish soldiers. *Eur J Surg.* 1999; 165(4): 339-42.
- [23] Harlak A, Menten O, Kilic S, Coskun K, Duman K, Yilmaz F. Sacrococcygeal pilonidal disease: analysis of previously proposed risk factors. *Clinics (Sao Paulo).* 2010; 65(2): 125-31.
- [24] Price ML, Griffiths WAD. Normal body hair: a review. *Clin Exp Dermatol* 1985; 10: 87-97
- [25] Bascom JU. Pilonidal disease: correcting over treatment and under treatment. *Contemporary Surg* 1981; 18: 13-28
- [26] Lineaweaver WC, Brunson MB, Smith JF, Franzini DA, Rumley TO. Squamous carcinoma arising in a pilonidal sinus. *J Surg Oncol* 1984; 27(4): 39-42.
- [27] Karydkis G E. Easy and successful treatment of PNS after explanation of its causative process. *Aust N Z J Surg* 1992; 62 (5): 385-9
- [28] Bascom J. Pilonidal disease: origin from follicles of hairs and results of follicle removal as treatment. *Surgery.* 1980; 87(5): 567-72
- [29] Solla JA, Rothenberger DA. Chronic pilonidal disease. An assessment of 150 cases. *Dis Col Rec* 1990; 33(9): 758-61.
- [30] Bascom J, Bascom B. Failed pilonidal surgery: new paradigm and new operation leading to cures. *Arch Surg* 2002; 137: 1146-50.
- [31] Lorenz U, Abele-Horn M, Bussen D, Thiede A. Severe pyomyositis caused by Pantone-Valentine leucocidin-positive methicillin-sensitive *Staphylococcus aureus* complicating a pilonidal cyst. *Langenbecks Arch Surg.* 2007; 392(6):761-5
- [32] Borer A, Weber G, Riesenberger K, Schlaeffer F, Horowitz J. Septic arthritis due to *bacteroides fragilis* after pilonidal sinus resection in a patient with rheumatoid arthritis. *Clin Rheumatol.* 1997; 16(6): 632-4
- [33] Saharay M, Farooqui A, Chappell M. Actinomycosis associated with pilonidal sinus of the penis. *Br J Urol.* 1996; 78(3): 464-5
- [34] Velitchkov N, Djedjev M, Kirov G, Losanoff J, Kjossev K, Losanoff H. Toxic shock syndrome and necrotizing fasciitis complicating neglected sacrococcygeal pilonidal sinus disease: report of a case. *Dis Colon Rectum.* 1997; 40(11): 1386-90.
- [35] Tirone A, Gaggelli I, Francioli N, Venezia D, Vuolo G. Malignant degeneration of chronic pilonidal cyst. Case report. *Ann Ital Chir.* 2009; 80(5): 407-9.
- [36] Bark T, Wilking N. Squamous-cell carcinoma in a pilonidal sinus. Case report. *Acta Chir Scand.* 1986; 152: 703-4.
- [37] Trent JT, Kirsner RS. Wounds and malignancy. *Adv Skin Wound Care* 2003; 16(1): 31-34
- [38] Miocinović M, Horzić M, Bunoza D. The prevalence of anaerobic infection in pilonidal sinus of the sacrococcygeal region and its effect on the complications. *Acta Med Croatica.* 2001;55(2):87-90.
- [39] Søndena K, Nesvik I, Andersen E, Natås O, Søreide JA. Bacteriology and complications of chronic pilonidal sinus treated with excision and primary suture. *Int J Colorectal Dis.* 1995;10(3):161-6.
- [40] Iesalnieks I, Furst A, Rentsch M, Jauch KW. Primary midline closure after excision of a pilonidal sinus is associated with a high recurrence rate. *Chirurg* 2003; 74: 461-8.

- [41] Soll C, Hahnloser D, Dindo D, Clavien PA, Hetzer F. A novel approach for treatment of sacrococcygeal pilonidal sinus: less is more. *Int J Colorectal Dis.* 2008; 23(2): 177-80.
- [42] Abdul-Ghani AK, Abdul-Ghani AN, Ingham Clark CL. Day-care surgery for pilonidal sinus. *Ann R Coll Surg Engl.* 2006; 88(7): 656-8.
- [43] Berry DP. Pilonidal sinus disease. *J Wound Care* 1992; 1(3): 29-32.
- [44] Al-Salamah SM, Hussain MI, Mirza SM. Excision with or without primary closure for pilonidal sinus disease. *J Pak Med Assoc.* 2007; 57(8): 388-91.
- [45] Tejirian T, Lee JJ, Abbas MA. Is wide local excision for pilonidal disease still justified? *Am Surg.* 2007; 73(10): 1075-8.
- [46] LORD PH, MILLAR DM. PILONIDAL SINUS: A SIMPLE TREATMENT. *Br J Surg.* 1965; 52: 298-300.
- [47] Millar DM, Lord PH. The treatment of acute postanal pilonidal abscess. *Br J Surg.* 1967; 54(7): 598-9.
- [48] Maurice B A, Greenwood R K. Conservative treatment of pilonidal sinus. *Br J Surg.* 1964;51:510-512.
- [49] Sakçak I, Avşar FM, Coşgun E. Comparison of the application of low concentration and 80% phenol solution in pilonidal sinus disease. *JRSM Short Rep.* 2010; 1(1): 5.
- [50] Kayaalp C, Olmez A, Aydın C, Piskin T, Kahraman L. Investigation of a one-time phenol application for pilonidal disease. *Med Princ Pract.* 2010; 19(3): 212-5.
- [51] Spyridakis M, Christodoulidis G, Chatzitheofilou C, Symeonidis D, Tepetes K. The role of the platelet-rich plasma in accelerating the wound-healing process and recovery in patients being operated for pilonidal sinus disease: preliminary results. *World J Surg.* 2009; 33(8): 1764-9
- [52] Bunke HJ, Schultheis A, Meyer G, Düsel W. Surgical revision of the pilonidal sinus with single shot antibiotics. *Chirurg.* 1995; 66(3): 220-3
- [53] Lee SL, Tejirian T, Abbas MA. Current management of adolescent pilonidal disease. *J Pediatr Surg.* 2008; 43(6): 1124-7.
- [54] Toccaceli S, Persico Stella L, Diana M, Dandolo R, Negro P. Treatment of pilonidal sinus with primary closure. A twenty-year experience. *Chir Ital.* 2008; 60(3): 433-8.
- [55] Anderson JH, Yip CO, Nagabhushan JS, Connelly SJ. Day-case karydakis flap for pilonidal sinus. *Dis Colon Rectum.* 2008; 51(1): 134-8.
- [56] Menten O, Bagci M, Bilgin T, Ozgul O, Ozdemir M. Limberg flap procedure for pilonidal sinus disease: results of 353 patients. *Langenbecks Arch Surg.* 2008 ; 393(2): 185-9.
- [57] Bessa SS. Results of the lateral advancing flap operation (modified Karydakis procedure) for the management of pilonidal sinus disease. *Dis Colon Rectum.* 2007 ; 50(11): 1935-40.
- [58] Milito G, Gargiani M, Gallinella MM, Crocoli A, Spyrou M, Farinon AM. Modified Limberg's transposition flap for pilonidal sinus. Long term follow up of 216 cases. *Ann Ital Chir.* 2007; 78(3): 227-31.
- [59] Mahdy T. Surgical treatment of the pilonidal disease: primary closure or flap reconstruction after excision. *Dis Colon Rectum.* 2008 Dec;51(12):1816-22.
- [60] Cubukcu A, Gonullu NN, Paksoy M, Alponat A, Kuru M, Ozbay O. The role of obesity on the recurrence of pilonidal sinus disease in patients, who were treated by excision and Limberg flap transposition. *Int J Colorectal Dis.* 2000; 15(3): 173-5.
- [61] Cubukcu A, Carkman S, Gonullu NN, Alponat A, Kayabasi B, Eyuboglu E. Lack of evidence that obesity is a cause of pilonidal sinus disease. *Eur J Surg.* 2001; 167(4): 297-8.
- [62] Badawy EA, Kanawati MN. Effect of hair removal by Nd:YAG laser on the recurrence of pilonidal sinus. *J Eur Acad Dermatol Venereol.* 2009; 23(8): 883-6.

- [63] Conroy FJ, Kandamany N, Mahaffey PJ. Laser depilation and hygiene: preventing recurrent pilonidal sinus disease. *J Plast Reconstr Aesthet Surg*. 2008; 61(9): 1069-72.
- [64] Sadick NS, Yee-Levin J. Laser and light treatments for pilonidal cysts. *Cutis*. 2006; 78(2): 125-8.
- [65] Odili J, Gault D. Laser depilation of the natal cleft—an aid to healing the pilonidal sinus. *Ann R Coll Surg Engl* 2002; 84: 29–32.
- [66] Petersen S, Wietelmann K, Evers T, Hüser N, Matevossian E, Doll D. Long-term effects of postoperative razor epilation in pilonidal sinus disease. *Dis Colon Rectum*. 2009; 52(1): 131-4
- [67] Schulze SM, Patel N, Hertzog D, Fares LG 2nd. Treatment of pilonidal disease with laser epilation. *Am Surg*. 2006 ; 72 (6): 534-7.
- [68] Lukish JR, Kindelan T, Marmon LM, Pennington M, Norwood C. Laser epilation is a safe and effective therapy for teenagers with pilonidal disease. *J Pediatr Surg*. 2009; 44(1): 282-5.
- [69] Oram Y, Kahraman F, Karıncaoğlu Y, Koyuncu E. Evaluation of 60 patients with pilonidal sinus treated with laser epilation after surgery. *Dermatol Surg*. 2010; 36(1): 88-91.
- [70] Lavelle M, Jafri Z, Town G. Recurrent pilonidal sinus treated with epilation using a ruby laser. *J Cosmet Laser Ther* 2002; 4: 45–7.
- [71] Landa N, Aller O, Landa-Gundin N, Torrontegui J, Azpiaz JL. Successful treatment of recurrent pilonidal sinus with laser epilation. *Dermatol Surg*. 2005; 31(6): 726-8.
- [72] Benedetto AV, Lewis AT. Pilonidal sinus disease treated by depilation using an 800 nm diode laser and review of the literature. *Dermatol Surg*. 2005; 31(5): 587-91.
- [73] Haedersdal M, Haak CS. Hair removal. *Curr Probl Dermatol*. 2011;42:111-21.
- [74] Wanitphakdeedecha R, Thanomkitti K, Sethabuttra P, Eimpunth S, Manuskiatti W. A split axilla comparison study of axillary hair removal with low fluence high repetition rate 810 nm diode laser vs. high fluence low repetition rate 1064 nm Nd:YAG laser. *J Eur Acad Dermatol Venereol*. 2011 Sep 19. doi: 10.1111/j.1468-3083.2011.04231.
- [75] Goh CL. Comparative study on a single treatment response to long pulse Nd:YAG lasers and intense pulse light therapy for hair removal on skin type IV to VI—is longer wavelengths lasers preferred over shorter wavelengths lights for assisted hair removal. *J Dermatolog Treat*. 2003; 14(4): 243-7.
- [76] Lanigan SW. Incidence of side effects after laser hair removal. *J Am Acad Dermatol*. 2003; 49(5): 882-6.
- [77] Lindholt CS, Lindholt JS, Lindholt J. Treatment of pilonidal cyst with Nd-YAG laser. *Ugeskr Laeger*. 2008; 170(26-32): 2321-2.
- [78] Bashir S, Kurwa H. Successful resolution of a chronic pilonidal sinus with laser epilation. *JAAD* 2009; 60 (3 suppl 1): AB195.
- [79] Palesty JA, Zahir KS, Dudrick SJ, Ferri S, Tripodi G. Nd:YAG laser surgery for the excision of pilonidal cysts: a comparison with traditional techniques. *Lasers Surg Med*. 2000;26(4):380-5.
- [80] Menten O, Akbulut M, Bagci M. Verrucous carcinoma (Buschke-Lowenstein) arising in a sacrococcygeal pilonidal sinus tract: report of a case. *Langenbecks Arch Surg*. 2008; 393(1): 111-4.
- [81] de Bree E, Zoetmulder FA, Christodoulakis M, Aleman BM, Tsiftsis DD. Treatment of malignancy arising in pilonidal disease. *Ann Surg Oncol*. 2001; 8(1): 60-4.



Nd YAG Laser

Edited by Dr. Dan C. Dumitras

ISBN 978-953-51-0105-5

Hard cover, 318 pages

Publisher InTech

Published online 09, March, 2012

Published in print edition March, 2012

Discovered almost fifty years ago at Bell Labs (1964), the Nd:YAG laser has undergone an enormous evolution in the years, being now widely used in both basic research and technological applications. Nd:YAG Laser covers a wide range of topics, from new systems (diode pumping, short pulse generation) and components (a new semiorganic nonlinear crystal) to applications in material processing (coating, welding, polishing, drilling, processing of metallic thin films), medicine (treatment, drug administration) and other various fields (semiconductor nanotechnology, plasma spectroscopy, laser induced breakdown spectroscopy).

How to reference

In order to correctly reference this scholarly work, feel free to copy and paste the following:

Ezzat A. Badawy (2012). Nd:YAG Laser (1064 nm) in Management of Pilonidal Sinus, Nd YAG Laser, Dr. Dan C. Dumitras (Ed.), ISBN: 978-953-51-0105-5, InTech, Available from: <http://www.intechopen.com/books/nd-yag-laser/nd-yag-laser-1064-nm-in-management-of-pilonidal-sinus>

INTECH
open science | open minds

InTech Europe

University Campus STeP Ri
Slavka Krautzeka 83/A
51000 Rijeka, Croatia
Phone: +385 (51) 770 447
Fax: +385 (51) 686 166
www.intechopen.com

InTech China

Unit 405, Office Block, Hotel Equatorial Shanghai
No.65, Yan An Road (West), Shanghai, 200040, China
中国上海市延安西路65号上海国际贵都大饭店办公楼405单元
Phone: +86-21-62489820
Fax: +86-21-62489821

© 2012 The Author(s). Licensee IntechOpen. This is an open access article distributed under the terms of the [Creative Commons Attribution 3.0 License](#), which permits unrestricted use, distribution, and reproduction in any medium, provided the original work is properly cited.

IntechOpen

IntechOpen