

We are IntechOpen, the world's leading publisher of Open Access books Built by scientists, for scientists

4,800

Open access books available

122,000

International authors and editors

135M

Downloads

Our authors are among the

154

Countries delivered to

TOP 1%

most cited scientists

12.2%

Contributors from top 500 universities



WEB OF SCIENCE™

Selection of our books indexed in the Book Citation Index
in Web of Science™ Core Collection (BKCI)

Interested in publishing with us?
Contact book.department@intechopen.com

Numbers displayed above are based on latest data collected.

For more information visit www.intechopen.com



The Role of Functional MRI in Intracranial Glioma Resection

Eftychia Z. Kapsalaki¹, Dimitrios Verganelakis², Ioannis Z. Kapsalakis²,
Efstathios D. Gotsis² and Kostas N. Fountas¹

¹*Departments of Diagnostic Radiology and Neurosurgery University Hospital of Larisa,
School of Medicine, University of Thessaly Larissa,*

²*Department of Magnetic Resonance Imaging, Euromedica- Encephalos, Athens,
Greece*

1. Introduction

It is generally accepted that tumor extirpation constitutes the treatment goal in cases of intracranial tumors. It is also well known that intracranial gliomas are infiltrative lesions with ill-defined borders, and their total resection is often quite challenging. Moreover, the presence of a glioma in an eloquent cortical area may make its extirpation even more difficult. It has been demonstrated that extensive glioma resection is associated with prolonged survival and better quality of life, and the overall outcome of patients with intracranial gliomas is associated with the extent of the tumor's surgical resection [Lacroix et al., 2001; McDonald et al., 1999; National Comprehensive Cancer Network, 2007; Sanai & Berger, 2008; Stafford et al., 1998). Therefore, every effort to achieve maximal tumor resection without jeopardizing vital neuronal functions becomes of paramount importance in cases of intracranial gliomas. Exact knowledge of the cortical topography, accurate identification of all eloquent cortical areas as well as delineation of their relationships with the tumor, constitute key elements in avoiding all functional cortical areas, while aggressive tumor resection is accomplished.

It is well known that conventional imaging studies providing pure structural anatomical information are not sufficient for identifying and localizing functional cortical areas, since there are frequent anatomical variations, and cortical functional center shift due to brain distortion and plasticity, particularly in glioma cases. Various methodologies have been developed for identifying different functional areas of the cerebral cortex and accurately localize them, in regard to the studied tumor on each individual case. Intraoperative electrophysiological studies such as recording of Somato-Sensory Evoked Potentials (SSEPs), Motor Evoked Potentials (MEPs), Direct Cortical Stimulation (DCS), and spontaneous Electro-Myo-Graphy (sEMG) are considered the gold standard for cortical mapping and delineation of functional cortical networks. The major drawback of these methodologies however, is the fact that all are invasive tests and cannot provide all this valuable information preoperatively. Thus, the development of non-invasive tests for cortical mapping seems to be mandatory. Recently, advanced imaging and electrophysiological studies such as Positron Emission Tomography (PET), brain SPECT imaging, functional

Magnetic Resonance Imaging (fMRI), Magneto-Encephalo-Graphy (MEG) and Magnetic Source Imaging (MSI), as well as high-density Electro-Encephalo-Graphy (hdEEG), have been employed, with various success rates, in cerebral cortical mapping. The wide clinical application of MRI, the high spatial resolution of fMRI compared with all other functional methods, its non-invasive character, and its low cost compared with all other methods, have made fMRI the most popular methodology for cortical functional mapping. Functional MRI can provide the neurosurgeon with critical information for a safe and aggressive surgical planning, thus, allowing maximal tumor resection and minimizing the possibility of a new postoperative neurological deficit.

2. Functional magnetic resonance imaging: Advantages and drawbacks

Since its introduction, during the 1990s, functional Magnetic Resonance Imaging has proven to be a powerful technique for the non-invasive imaging of various brain functional centers, such as motor, sensory, language, vision, odor and others. Functional MRI can constructively help towards a safe pre-operative or radiation treatment planning for various pathologies. In neurosurgical practice, fMRI is used in order to assess suitability of patients for resection of tumors and/or resective epilepsy surgery. In neurosurgery, the aim is to maximize the removal of pathological tissue with the minimum post-operative functional deficit. Therefore, the pre-operative knowledge of the proximity of the pathological tissue to the eloquent cortex is of fundamental importance for accurate and safe neurosurgical planning. Functional MRI provides information regarding anatomical variations, as well as tumor related shift of functional cortical centers.

Functional MRI is based on a physiological phenomenon called the Blood-Oxygenation-Level-Dependent (BOLD) contrast. BOLD is strongly coupled, to neuronal activity and cerebral hemodynamics [Roy & Sherrington, 1890]. The BOLD signal expresses small changes in the volume of the oxygenated blood in a specific brain volume during increased neuronal activity. When an examinee is subjected to a stimulus, there is an increased neuronal activity of the corresponding cluster of neurons responsible for this particular function. This is translated into a regionally increased metabolic demand. In order for this demand to be met, the supply of oxygenated blood locally increases, via dilation of the surrounding capillaries. The regional cerebral blood flow (CBF) and volume (CBV) increase with a surplus of oxygen (2%-6%). This produces an increased ratio of oxygenated versus de-oxygenated blood in the local system of capillaries and veins, in regard to the adjacent idle neurons. Oxygenated blood contains oxy-hemoglobin, a diamagnetic material, while deoxygenated blood contains de-oxyhemoglobin, a paramagnetic material. Microscopically, this decreased paramagnetism causes less signal loss on T_2^* weighted images [Ogawa et al., 1990]. Therefore, a relative signal increase is generated during the active neuron period, with respect to the passive neurons' period. The pulse sequence that is used in order to image the BOLD effect is the Gradient-Echo Echo-Planar-Imaging (GE-EPI), which is T_2^* weighted, i.e. sensitive to magnetic susceptibility effects [Stehling et al., 1991]. Thus, the BOLD fMRI response to a neuronal activity is a hemodynamic response function, which is the change in BOLD fMRI signal due to a short period of neural activity. Hemodynamic Response Factor reflects variations in vascular physiology generated by a neuronal activity. The major advantage of fMRI is its non-invasive character, especially when compared to the electrophysiological cortical stimulation studies. In addition, it has a relatively low cost, is reproducible, has a short examination time compared to the electro-cortical stimulation

studies, and is well tolerated by the vast majority of patients [Giussani et al., 2010 G]. Moreover, fMRI may be performed in pediatric patients, which is not the case for intraoperative cortical stimulation studies during an awake craniotomy. Functional MRI can test multiple language tasks, and check larger cortical areas for auxiliary language networks [Giussani et al., 2010]. Comparing fMRI with other non-invasive techniques, such as Magneto-Encephalo-Graphy (MEG) and high-density Electro-Encephalo-Graphy (EEG), fMRI has the advantage of studying both cortical and intrasulcal areas, as well as deep brain areas. It has been demonstrated that fMRI has higher spatial resolution than MEG/MSI, PET, SPECT, and hdEEG, and comparable temporal resolution to the MEG/MSI. Furthermore, fMRI does not require intravascular injection of contrast media or radioisotopes.

Several drawbacks of fMRI may however limit its clinical applications. Most importantly, only cooperative patients may undergo an fMRI study, since motion artifacts secondary to head movements, respiratory movements, and cardiac pulsation may influence the quality of the obtained study. Moreover, the patient's ability to understand the functional paradigm and promptly perform the necessary tasks, are essential in obtaining a high quality fMRI. It has to be emphasized that fMRI constitutes an indirect measurement of neuronal activity, and it indicates where this indirect measurement takes place, without however describing the exact underlying mechanism. Besides, fMRI does not exhibit the neuronal networks, which interconnect the various functional clusters of neurons that collaborate for the performance of a particular function. Furthermore, there are other aspects that require attention in interpreting fMRI findings, such as the HRF and the BOLD signal. The HRF is a function: i) of the studied brain area, its regional blood volume and blood flow, ii) of the patient, and iii) of the employed stimulus. Similarly, the BOLD signal may be influenced by: i) hypoxia, ii) hypercapnia, iii) presence of cerebral vascular pathologies, iv) lack of sleep, v) anemia, vi) smoking, vii) various brain degenerative pathologies, viii) proximity of large veins to the activated neuronal clusters (vein effect), and ix) previous brain anatomical injuries.

Since fMRI is based on magnetic susceptibility, hemorrhage within a brain tumor may alter the accuracy of the BOLD effect and misplace the location of the detected signal. Particular attention should be taken in such cases and further preoperative, possibly invasive studies, need to be performed. In high grade gliomas, the presence of neovascularization, the induction of neuro-chemical changes in the cytosol and the subsequent alteration of the regional cerebral blood flow and the oxygen extraction fraction, the presence of arterio-venous shunting, and the presence of tumor-associated edema and mass effect causing mechanical vasoconstriction, as well as the presence of scar tissue secondary to a previous craniotomy may result into significant BOLD signal changes [Atlas et al., 1996; Giussani et al., 2010; Haberg et al., 2004; Krishnan et al., 2004]. It has been demonstrated, that in 10-31% of the performed fMRI studies the obtained data cannot be processed, and this percentage in glioma populations ranges between 0-30% [Haberg et al., 2004]. Moreover, gliomas are usually surrounded by edema and cause mass effect. During the fMRI study the activation area is located in the brain tissue that may be displaced by the lesion. At the time of the craniectomy, decompression of the brain occurs and alteration of the measured distances between the activation area and the brain tumor may take place. Therefore, we need to refer to the anatomical structures, especially the sulci, rather than the actual distance between the brain tumor and the activation area, when evaluating an fMRI study.

2.1 Neurosurgical considerations and clinical experience

It is widely accepted that surgical resection of intracranial gliomas is the treatment method of choice. Glioma resection reduces the tumor's mass effect on the surrounding brain, reduces the tumor-associated edema, ensures the establishment of an accurate histological diagnosis, and induces residual tumor cells into active mitotic process thus making them more vulnerable to the adjuvant administered radiotherapy and chemotherapy. It has been demonstrated that extensive resection of gliomas is associated with prolonged survival and better quality of life [Lacroix et al., 2001; McDonald et al., 1999; National Comprehensive Cancer Network, 2007; Sanai & Berger, 2008; Stafford et al., 1998]. Accurate knowledge of the anatomical relationship of a glioma with neighboring eloquent cortical areas is of paramount importance for maximizing tumor resection, minimizing the chance of postoperative neurological deficit, and thus maximizing the patient's safety. Functional MRI has been employed for more than 15 years in the preoperative evaluation of patients harboring intracranial gliomas for identifying, accurately localizing, and intraoperatively avoiding functional cortical centers [Atlas et al., 1996; Berntsen et al., 2010; Bizzi et al., 2008; Fandino et al., 1999; Fitzgerald et al., 1997; Giussani et al., 2010; Haberg et al., 2004; Hirsch et al., 2000; Hoenig et al., 2005; Krasnow et al., 2003; Krishnan et al., 2004; Lehericy et al., 2000; Li et al., 2010; Lurito et al., 2000; Mueller et al., 1996; National Comprehensive Cancer Network, 2007; Petrovich et al., 2005; Pouratian et al., 2002; Puce et al., 1995; Roux et al., 2003; Ruge et al., 1999; 2003; Rutten et al., 2002; Sanai & Berger, 2008; Schulder et al., 1998; Signorelli et al., 2003; Tieleman et al., 2007; Tomczak et al., 2000; Yetkin et al., 1997; Yousry et al., 1995] (Figures 1 & 2). Several clinical studies have been performed comparing fMRI with intraoperative electrophysiological stimulation studies, with varying results, and frequently contradictory conclusions [Atlas et al., 1996; Berntsen et al., 2010; Bizzi et al., 2008; Fandino et al., 1999; Fitzgerald et al., 1997; Giussani et al., 2010; Haberg et al., 2004; Hirsch et al., 2000; Hoenig et al., 2005; Krasnow et al., 2003; Krishnan et al., 2004; Lehericy et al., 2000; Li et al., 2010; Lurito et al., 2000; Mueller et al., 1996; National Comprehensive Cancer Network, 2007; Petrovich et al., 2005; Pouratian et al., 2002; Puce et al., 1995; Roux et al., 2003; Ruge et al., 1999; Rutten et al., 2002; Sanai & Berger, 2008; Schulder et al., 1998; Signorelli et al., 2003; Tieleman et al., 2007; Tomczak et al., 2000; Yetkin et al., 1997; Yousry et al., 1995]. Unfortunately, the utilized methodologies vary significantly among these studies, their populations are frequently limited and non-homogenous, and a large number of them are retrospective studies. Therefore, their results are not comparable, in the vast majority of cases. However, a systematic review of the existent clinical studies show that fMRI constitutes a routine clinical practice in many neuro-oncology centers around the world, which provides the opportunity to the performing neurosurgeon for a more realistic and accurate preoperative discussion with the patient, a wiser decision-making process, a safer surgical planning, and a more aggressive tumor resection [Atlas et al., 1996; Berntsen et al., 2010; Bizzi et al., 2008; Fandino et al., 1999; Fitzgerald et al., 1997; Giussani et al., 2010; Haberg et al., 2004; Hirsch et al., 2000; Hoenig et al., 2005; Krasnow et al., 2003; Krishnan et al., 2004; Lehericy et al., 2000; Li et al., 2010; Lurito et al., 2000; Mueller et al., 1996; National Comprehensive Cancer Network, 2007; Petrovich et al., 2005; Pouratian et al., 2002; Puce et al., 1995; Ruge et al., 1999; Roux et al., 2003; Rutten et al., 2002; Sanai & Berger, 2008; Schulder et al., 1998; Signorelli et al., 2003; Tieleman et al., 2007; Tomczak et al., 2000; Yetkin et al., 1997; Yousry et al., 1995]. Several studies also emphasize that fMRI can localize more accurately motor and sensory cortical areas than language areas, and therefore they indicate the necessity for employing complimentary intraoperative electrophysiological stimulation

studies, in cases of tumor proximity to language-associated cortical areas [Berntsen et al., 2010; Giussani et al., 2010; Hirsch et al., 2000; Roux et al., 2003; Ruge et al., 1999].

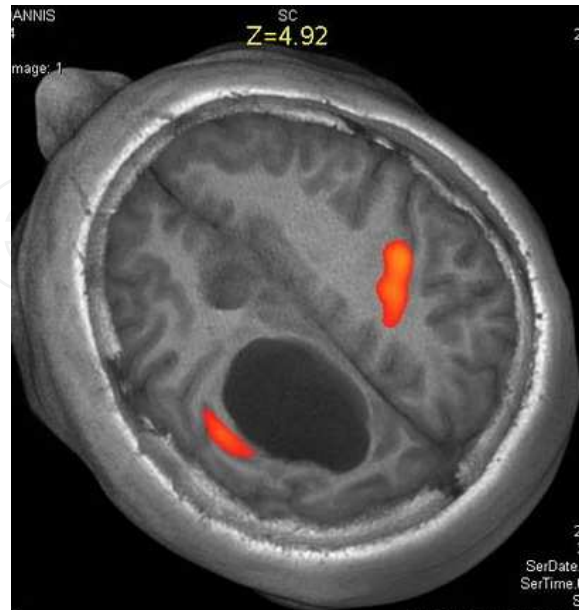


Fig. 1. Preoperative fMRI demonstrating the displacement of the motor cortex and its relationship with a low grade glioma (astrocytoma grade II) during an active right foot plantar flexion.

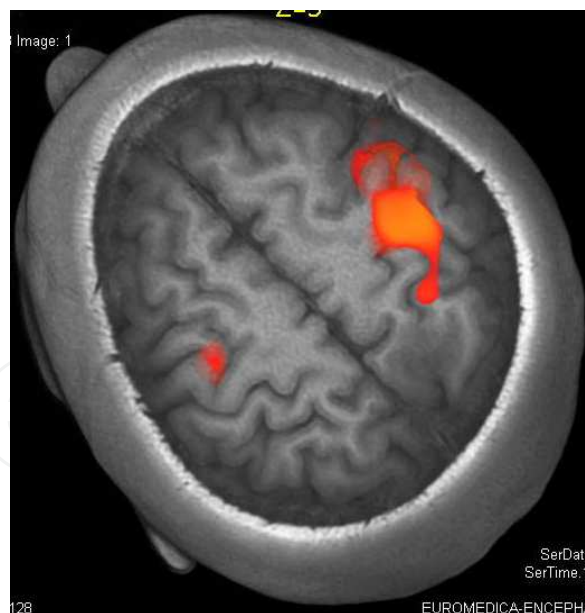


Fig. 2. Preoperative fMRI demonstrating activated hand motor cortex and its relationship to a low grade glioma during a left fist clenching paradigm.

In one of the earliest published prospective, clinical studies comparing preoperative fMRI and DCS for identifying cortical motor areas, Yousry et al. [Yousry et al., 1995] reported a series of six patients with gliomas. All participants underwent preoperative fMRI at 1.5T for localizing the motor cortex [Yousry et al., 1995]. A repetitive opening-closing of the hand

paradigm was used for the fMRI, while DCS was intraoperatively employed for identification and localization of the motor strip [Yousry et al., 1995]. They found that the fMRI accuracy in localizing the motor cortex was 100% when error margin was confined to 10mm [Yousry et al., 1995]. Likewise, Puce et al. [Puce et al., 1995] in a series of four tumor cases, found in their prospective study good agreement between preoperative fMRI and intraoperative DCS/SSEP, regarding localization of the sensori-motor cortex. Their fMRI protocol included sponge squeezing as a motor task, and electrical stimulation of the median nerve, palm light brushing, and palm air blowing as sensory tasks [Puce et al., 1995]. Mueller et al. [Mueller et al., 1996] reported 10 patients with intracranial tumors and 2 patients with intracranial vascular lesions undergoing preoperative fMRI at 1.5T for sensori-motor cortex localization, and intraoperative DCS. Their fMRI protocol included index-thumb tapping as a motor task, and palm light scratching as a sensory task [Mueller et al., 1996]. They found that fMRI accuracy was 100% in their retrospective study [Mueller et al., 1996]. They also reported that they had no postoperative motor deficits, when their resection distance was more than 5 mm from the fMRI identified motor cortex [Mueller et al., 1996]. At approximately the same time, Schulder et al. [Schulder et al., 1998] reported a series of 12 patients with various intracranial tumors undergoing preoperative fMRI at 1.5T and intraoperative DCS/SSEP studies, for sensori-motor cortex localization. They reported that fMRI accuracy in their prospective study was 100%, while they concluded that maximal tumor resection and no new postoperative neurological deficits were observed in their series [Schulder et al., 1998]. Contrariwise, Atlas et al. [Atlas et al, 1996] reported a series of seven patients with gliomas, undergoing preoperative fMRI at 1.5T. Their fMRI protocol included single- or multi-stage active finger tapping as motor tasks [Atlas et al, 1996]. They reported that in 28.5% of their cases fMRI failed to identify the motor cortex, while they postulated that glioblastomas and high-grade gliomas may alter the obtained BOLD signal [Atlas et al, 1996]. Fandino et al. [Fandino et al., 1999] reported similar findings from a series of 11 patients with central area tumors, undergoing preoperative fMRI at 1.5T and intraoperative DCS for motor cortex localization. They considered that there was concordance between their fMRI and DCS findings when there was a discrepancy of less than 20 mm [Fandino et al., 1999]. They found that fMRI accuracy in their series was 82% [Fandino et al., 1999]. In a more recent study, Lehericy et al. [Lehericy et al., 2000] reported their results from a retrospective study of 26 patients with intracranial tumors, undergoing preoperative fMRI at 1.5T and intraoperative DCS for motor cortex localization. Their fMRI protocol included active flexion/extension of fingers/toes, and lip contraction as motor tasks [Lehericy et al., 2000]. They found 92% agreement between fMRI and DCS results, while fMRI accuracy was 100% when error margin was 15 mm [Lehericy et al., 2000]. Similarly, Hirsch et al. [Hirsch et al, 2000] reported their results from a large prospective study of 125 patients with various intracranial pathologies, and of 63 healthy volunteers. All their participants underwent fMRI at 1.5T unit for sensori-motor, language, and visual cortex localization [Hirsch et al, 2000]. Their fMRI protocol included active finger tapping as a motor task, passive tactile hand stimulation as a sensory task, and picture naming by silent speech and object or name listening as language tasks [Hirsch et al, 2000]. They were able to localize with fMRI the central sulcus in 100% of their healthy volunteers and in 98.4% of their patients [Hirsch et al, 2000]. They were also able to localize by fMRI the Wernicke's and Broca's areas in 91% and 77%, respectively, in their patients, while the respective percentages were 100% and 93% for their volunteers [Hirsch et al, 2000]. The primary visual cortex was identified by fMRI in

100% of their tested cases [Hirsch et al, 2000]. Haberg et al. [Haberg et al., 2004] reported a series of 21 patients with gliomas, undergoing preoperative fMRI at 1.5T for localizing sensori-motor and language associated cortical areas. Their fMRI protocol included active thumb-index opposition, active toe flexion, and active tongue movement as motor tasks, and thinking of a short action-verb and silent construction of a short noun as language paradigms [Haberg et al., 2004]. They reported that 80% of their patients were able to successfully finish their fMRI studies, while in 20% of their cases fMRI was unsuccessful due to EPI signal voids, secondary to previous craniotomy, head motion artifacts, and patient's inability to perform the task. They found that 73% of their patients had no postoperative neurological deficits, while 27% had a new permanent postoperative deficit [Haberg et al., 2004]. It has to be emphasized however, that 43.3% of these patients developing new deficits, knew that before the operation, from the obtained fMRI [Haberg et al., 2004]. Similarly, Krishnan et al. [Krishnan et al., 2004] reported their results from a prospective study including 54 patients with various intracranial tumors. All their patients underwent preoperative fMRI at 1.5T and intraoperative DCS/SSEP studies for localization of motor cortex [Krishnan et al., 2004]. They examined their total resection rates and the observed morbidity in association with the distance of the resection margin from the fMRI defined motor cortex [Krishnan et al., 2004]. They found that when this distance was > 15 mm their resection rate was 85.7%, while 53% of their patients remained neurologically unchanged postoperatively and 47% were improved [Krishnan et al., 2004]. When this distance was between 10-15 mm, total resection was achieved in 86.6% of their patients, 13.3% developed new postoperative neurological deficits, 60% remained unchanged, while 37.3% were improved [Krishnan et al., 2004]. When the distance was between 5-10 mm, total resection was observed in 83.3%, while 50% remained neurologically stable, and the remaining 50% were postoperatively improved [Krishnan et al., 2004]. Finally, when this distance was between 0-5 mm, total resection was accomplished in 85%, neurological worsening occurred in 35%, 50% remained stable, while 15% were improved [Krishnan et al., 2004]. They pointed out that the obtained BOLD signal may be varying with the utilized functional paradigm, and they concluded that fMRI is a valuable tool in surgical planning [Krishnan et al., 2004].

Li et al. [Li et al, 2010] in a recent study reported their experience from five patients with gliomas, undergoing preoperative fMRI at 3T and intraoperative DCS for motor cortex localization. They found that the accuracy of fMRI was 100% in their series, and postulated that 3T field provides an increased BOLD signal [Li et al, 2010]. Berntsen et al. [Berntsen et al., 2010] reported their results from a prospective study including 51 patients with various intracranial lesions (33 patients with gliomas), undergoing preoperative fMRI for sensori-motor cortex localization. Interestingly, 3.9% of their patients did not undergo surgery because of the preoperative MRI and fMRI findings. They reported that 13% of their patients could not finish their fMRI study, either due to reduced cooperation or excessive head motion artifacts [Berntsen et al., 2010]. They reported that in 42% of their cases more than 95% of the tumor was resected, while their mean residual tumor was 11% (range: 0-94%) [Berntsen et al., 2010]. They also found, that 88% of their patients had stable postoperative neurological status, while 12% experienced some worsening [Berntsen et al., 2010]. The lesion to eloquent area distance was related to the amount of tumor residual, and this relationship was statistically significant in their series [Berntsen

et al., 2010]. They postulated that fMRI accuracy depends highly on the skills of the obtained data analyst [Berntsen et al., 2010].

Several clinical studies with significantly varying results have been published in regard to the language-associated cortical areas identification and localization by employing fMRI [Bizzi et al., 2008; Fandino et al., 1999; Fitzgerald et al., 1997; Giussani et al., 2010; Lurito et al., 2000; Mueller et al., 1996; Pouratian et al., 2002; Roux et al., 2003; Ruge et al., 1999; Rutten et al., 2002; Signorelli et al., 2003; Tomczak et al., 2000; Yetkin et al., 1997]. Mueller et al. [Mueller et al., 1996] reported their results from a series of 12 patients (10 tumor and 2 vascular cases) undergoing fMRI and intraoperative language mapping for language-associated cortical areas localization. Their fMRI protocol included audible and silent word generation paradigms [Mueller et al., 1996]. They reported that their fMRI findings were concordant to their intraoperative findings in 100% of their cases [Mueller et al., 1996]. Similarly, Yetkin et al. [Yetkin et al., 1997] reported a series of 28 patients (but only five tumor cases), undergoing preoperative fMRI at 1.5T for language mapping and intraoperative DCS. Their fMRI protocol included silent word generation and number counting tasks, while their DCS protocol included text recitation and number counting [Yetkin et al., 1997]. They found that the fMRI accuracy in localizing language centers was 100% when the error margin was 20 mm, and 86% when the error margin was 10 mm [Yetkin et al., 1997]. Likewise, Ruge et al. [Ruge et al., 1999] reported their results from a series of 21 patients with various intracranial tumors undergoing preoperative fMRI at 1.5T for language mapping and intraoperative DCS. Their fMRI protocol included object naming and word listening, while their DCS paradigms were object naming and number counting [Ruge et al., 1999]. They found concordance between the fMRI and DCS findings in 100% of their cases [Ruge et al., 1999]. Fitzgerald et al. [Fitzgerald et al., 1997] reported their findings from a series of 11 patients (but only 8 tumor cases), undergoing preoperative fMRI at 1.5T and intraoperative DCS for language mapping. Their fMRI tasks were word reading, verb generation, text listening, and word listening, while their DCS paradigms included object naming and number counting [Fitzgerald et al., 1997]. They reported 81% sensitivity and 53% specificity for fMRI when the margin error was 10 mm, while the respective percentages were 92% and 0% when the margin error was 20 mm [Fitzgerald et al., 1997]. Similarly, Signorelli et al. [Signorelli et al., 2003] reported two glioma cases undergoing fMRI at 1.5T and reported excellent fMRI accuracy and high reproducibility.

Contrariwise, Lurito et al. [Lurito et al., 2000] reported three glioma cases undergoing preoperative fMRI at 1.5T and intraoperative DCS for language mapping. They employed object naming and number counting tasks for both fMRI and DCS [Lurito et al., 2000]. They reported good but imperfect correlation between fMRI and DCS findings [Lurito et al., 2000]. Likewise, Tomczak et al. [Tomczak et al., 2000] reported a large series of 41 tumor cases (34 gliomas), undergoing preoperative fMRI at 1.5T and intraoperative DCS for language mapping. Their fMRI paradigm was a semantic test for word relations, while their DCS protocol included speech comprehension, word production, object naming, and text reading [Tomczak et al., 2000]. They reported agreement between their fMRI and DCS findings in only 33.3% of their cases [Tomczak et al., 2000].

Pouratian et al. [Pouratian et al., 2002] in a more recent study of 10 patients (none of them with glioma) undergoing preoperative fMRI at 3T and intraoperative DCS for language mapping, found that fMRI was more accurate in localizing language-associated areas in the frontal lobe than the temporal and parietal lobes. The observed fMRI sensitivity and

specificity were 100% and 66.7%, respectively for the frontal lobe, while the respective percentages for the temporal and parietal lobes were 96.2% and 69.8% [Pouratian et al., 2002]. Their fMRI protocol included object naming, word generation, auditory responsiveness, visual responsiveness, and sentence comprehension, while their DCS protocol included only object naming [Pouratian et al., 2002]. Roux et al. [Roux et al., 2003] reported their results from a series of 14 tumor patients (11 gliomas, 3 meningiomas) undergoing preoperative fMRI at 1.5T and intraoperative DCS for language mapping. Their fMRI and DCS protocol included object naming and verb generation paradigms [Pouratian et al., 2002]. They reported 59% sensitivity and 97% specificity for fMRI, and they concluded that fMRI cannot be used alone for surgical planning, in critically-located tumors in the language cortical areas [Pouratian et al., 2002].

Rutten et al. [Rutten et al., 2002] reported their findings from a series of 13 epilepsy patients undergoing preoperative fMRI and intraoperative DCS for language mapping. Their fMRI protocol included object naming and verb generation paradigms, while their DCS protocol included only object naming [Rutten et al., 2002]. They reported 100% sensitivity and 61% specificity for fMRI in their study [Rutten et al., 2002]. Likewise, Bizzi et al. [Bizzi et al., 2008] reported a large series of tumor cases (28 gliomas, 2 metastatic tumors, and 1 meningioma) undergoing preoperative fMRI at 1.5T and intraoperative DCS for language mapping. Their fMRI and DCS protocol included solely a verb generation paradigm [Bizzi et al., 2008]. They found that fMRI had 80% sensitivity and 78% specificity in their series [Bizzi et al., 2008].

2.2 Future directions of preoperative fMRI in gliomas

Further development of fMRI techniques may strengthen its role in the preoperative evaluation of patients with gliomas. The wide clinical application of higher magnetic fields may increase fMRI's quality. It has been demonstrated that higher magnetic fields change the relaxation rate R2 and thus provide better BOLD signal and more accurate fMRI studies [Hoenig et al., 2005; Krasnow et al., 2003; Tieleman et al., 2007]. Higher strength magnets allow fMRI studies to be performed in shorter times, and provide the opportunity for almost real time imaging of cortical activation during stimulation [Scarabino et al., 2007]. The development of advanced software packages, allowing further decrease of susceptibility artifacts, may well improve the quality and the accuracy of fMRI [Li et al., 2010].

Moreover, the development of more concrete paradigms and protocols may further improve fMRI's accuracy and reproducibility. It has been shown that loud speech tasks provide more accurate fMRI data than silent speech tasks [Petrovich et al., 2005]. Therefore, the development of multi-stage, loud language tasks examining several aspects of language may further increase fMRI's accuracy. The implementation of other advanced MR imaging techniques such as Diffusion Tensor Imaging and intraoperative fMRI and DTI may allow better identification and localization not only of the cortical language-associated centers but also their interconnecting networks, and thus may make glioma resection safer [Nimsky, 2011].

The development of paradigms and protocols for testing higher cognitive functions such as memory, emotion, affect, and other high-cognitive functions may further increase the applicability of fMRI in the preoperative evaluation of patients with gliomas. These potential fMRI developments along with the technological evolution of the frameless neuro-navigational systems may allow more aggressive and safer resection of gliomas of eloquent cerebral cortex.

3. Conclusions

Functional MRI constitutes a non-invasive imaging modality that lends itself to the identification and localization of eloquent cortical areas and cerebral functional mapping. Its ability to depict neuronal activity is based on the Blood-Oxygenation-Level-Dependent (BOLD) phenomenon, which is correlated with the relative concentrations of oxy- and deoxy-hemoglobin in an activated cerebral region. It represents thus, an indirect evaluating tool of neuronal activity. The acquisition of Gradient Echo-Echo Planar Imaging (GE-EPI) T_2^* sequences is required for fMRI studies. Strength of at least 1.5T is required for obtaining an adequate resolution fMRI, while several studies postulate that higher magnetic field MR units may provide better quality and more accurate fMRI studies. Functional MRI is characterized by higher spatial resolution than PET, hdEEG, MEG/MSI, or SPECT functional studies, while its temporal resolution is comparable, if not better, to that of all other functional imaging methodologies. Moreover, MR units are easily accessible, and definitely more widely distributed than any of the other methodologies.

Identification and localization of motor, sensory, and language-associated cortical, but also deep-sited areas can be performed with fMRI. Various performance tasks and protocols have been proposed and utilized in clinical practice, with variable success rates. It can be postulated that active thumb-index opposition, active hand squeezing, and active finger tapping are the most commonly employed motor tasks. Palm light brushing, palm air-puff blowing, and median nerve electrical irritation are the most commonly applicable sensory tasks. Object naming, word generation, and number counting are the most popular speech tests, although a wide variability occurs in language tests, and several issues (silent vs. loud language testing) remain still controversial. It has to be emphasized that the selection of the appropriate performance tasks (especially for language) frequently needs to be individualized. Another issue that requires attention is the application of the same language tests during fMRI and intraoperative DCS, when both studies are performed, for standardizing the comparison of these methodologies.

The role of preoperative fMRI in the management of patients with intracranial gliomas is of paramount importance. Functional MRI allows the preoperative localization of sensorimotor and language associated areas, and their relationships with the studied tumor. This information enables the neurosurgeon to discuss with the patient the possibility of total tumor resection, the chance of postoperative neurological deficits, and the calculation of the benefit to risk ratio. Furthermore, it provides the opportunity for a safer surgical planning, and potentially for a more aggressive tumor resection. Functional MRI allows cortical mapping even in cases that DCS during awake-craniotomy is impossible, as in pediatric or psychologically unstable patients. The vast majority of the published clinical studies demonstrate that the accuracy of fMRI in localizing sensori-motor cortex is extremely high, while that of language-associated cortical areas is lower. There are several studies postulating that fMRI language-associated cortical areas may be inaccurate, particularly in cases of temporal or parietal localization of speech areas. Additionally, the presence of scar tissue due to a previous craniotomy, the presence of neovascularization in cases of high grade gliomas, the presence of tumor-induced cellular chemical changes, and the proximity of large veins to the tumor, may confound the accuracy of fMRI.

The development of novel, high-reproducibility, high-resolution software fMRI packages, along with the application of higher magnetic field strength may further increase fMRI's accuracy, and minimize the confounding effect of various glioma-associated parameters.

The preoperative evaluation with fMRI of higher cognitive functions may allow even safer glioma surgical resection in the near future.

4. References

- Atlas, S., Howard, RS., Maldjian, J., Alsop, D., Detre, JA., Listerud, J., D'Esposito, M., Judy, KD., Zager, E., & Stecker, M. (1996). Functional magnetic resonance imaging of regional brain activity in patients with intracerebral gliomas: findings and implications for clinical management, *Neurosurgery* Vol. 38, No. 2, (February 1996), pp. 329-338, ISSN 0148-396X
- Berntsen, EM., Gulati, S., Solheim, O., Kvistad, KA., Torp, SH., Selbekk, T., Unsgård, G., & Håberg, AK. (2010). Functional magnetic resonance imaging and diffusion tensor tractography incorporated into an intraoperative 3-dimensional ultrasound-based neuronavigation system: impact on therapeutic strategies, extent of resection, and clinical outcome, *Neurosurgery* Vol. 67, No. 2, (August 2010), pp. 251-264, ISSN 0148-396X
- Bizzi, A., Blasi, V., Falini, A., Ferroli, P., Cadioli, M., Danesi, U., Aquino, D., Marras, C., Caldiroli, D., & Broggi, G. (2008). Presurgical functional MR imaging of language and motor functions: validation with intraoperative electrocortical mapping, *Radiology* Vol. 248, No. 2, (August 2008), pp. 579-589, ISSN 0033-8419
- Fandino, J., Kollias, SS., Wieser, HG., Valavanis, A., & Yonekawa, Y. (1999). Intraoperative validation of functional magnetic resonance imaging and cortical reorganization patterns in patients with brain tumors involving the primary motor cortex, *J Neurosurg* Vol. 91, No. 2, (August 1999), pp. 238-250, ISSN 0022-3085
- Fitzgerald, DB., Cosgrove, GR., Ronner, S., Jiang, H., Buchbinder, BR., Belliveau, JW., Rosen, BR., & Benson, RR. (1997). Location of language in the cortex: a comparison between functional MR imaging and electrocortical stimulation, *AJNR Am J Neuroradiol* Vol. 18, No. 8, (September 1997), pp. 1529-1539, ISSN 0195-6108
- Giussani, C., Roux, FE., Ojemann, J., Sganzerla, EP., Pirillo, D., & Papagno, C. (2010). Is preoperative functional magnetic resonance imaging reliable for language areas mapping in brain tumor surgery? Review of language functional magnetic resonance imaging and direct cortical stimulation correlation studies, *Neurosurgery* Vol. 66, No. 1, (January 2010), pp. 113-120, ISSN 0148-396X
- Haberg, A., Kvistad, KA., Unsgard, G., & Haraldseth, O. (2004). Preoperative blood oxygen level-dependent functional magnetic resonance imaging in patients with primary brain tumors: clinical application and outcome, *Neurosurgery* Vol. 54, No. 4, (April 2004), pp. 902-915, ISSN 0148-396X
- Hirsch, J., Ruge, MI., Kim, KH., Correa, DD., Victor, JD., Relkin, NR., Labar, DR., Krol, G., Bilsky, MH., Souweidane, MM., DeAngelis, LM., & Gutin, PH. (2000). An integral functional magnetic resonance imaging procedure for preoperative mapping of cortical areas associated with tactile, motor, language, and visual functions, *Neurosurgery* Vol. 47, No. 3, (September 2000), pp. 711-722, ISSN 0148-396X
- Hoening, K., Kuhl, CK., & Scheef, L. (2005). Functional 3.0-T MR assessment of higher cognitive function: are there advantages over 1.5-T imaging?, *Radiology* Vol. 234, No. 3, (March 2005), pp. 860-868, ISSN 0033-8419
- Krasnow, B., Tamm, L., Greicius, MD., Yang, TT., Glover, GH., Reiss, AL., & Menon, V. (2003). Comparison of fMRI activation at 3 and 1.5 T during perceptual, cognitive,

- and affective processing, *Neuroimage* Vol. 18, No. 4, (April 2003), pp. 813-826, ISSN 10538119
- Krishnan, R., Raabe, A., Hattingen, E., Szelényi, A., Yahya, H., Hermann, E., Zimmermann, M., & Seifert, V. (2004). Functional magnetic resonance imaging-integrated neuronavigation: correlation between lesion-to-motor cortex distance and outcome, *Neurosurgery* Vol. 55, No. 4, (October 2004), pp. 904-915, ISSN 0148-396X
- Lacroix, M., Abi-Said, D., Fourney, DR., Gokaslan, ZL., Shi, W., DeMonte, F., Lang, FF., McCutcheon, IE., Hassenbusch, SJ., Holland, E., Hess, K., Michael, C., Miller, D., & Sawaya, R. (2001). A multivariate analysis of 416 patients with glioblastoma multiforme: prognosis, extent of resection, and survival, *J Neurosurg* Vol. 95, No. 2, (August 2001), pp. 190-198, ISSN 0022-3085
- Lehericy, S., Duffau, H., Cornu, P., Capelle, L., Pidoux, B., Carpentier, A., Auliac, S., Clemenceau, S., Sichez, JP., Bitar, A., Valery, CA., Van Effenterre, R., Faillot, T., Srouf, A., Fohanno, D., Philippon, J., Le Bihan, D. & Marsault, C. (2000). Correspondence between functional magnetic resonance imaging somatotopy and individual brain anatomy of the central region: comparison with intraoperative stimulation in patients with brain tumors, *J Neurosurg* Vol. 92, No. 4, (April 2000), pp. 589-598, ISSN 0022-3085
- Li, SW., Wang, JF., Jiang, T., Li, SW., Zhang, WB., Li, ZX., Zhang, Z., Dai, JP., & Wang, ZC. (2010). Preoperative 3T high field blood oxygen level dependent functional magnetic resonance imaging for glioma involving sensory cortical areas, *Chin Med J* Vol. 123, No. 8, (April 20), pp. 1006-1010, ISSN
- Lurito, JT., Lowe, MJ., Sartorius, C., & Mathews, VP. (2000). Comparison of fMRI and intraoperative direct cortical stimulation in localization of receptive language areas, *J Comput Assist Tomogr* Vol. 24, No. 1, (January-February 2000), pp. 99-105, ISSN 0363-8715
- McDonald, JD., Chong, BW., Lewine, JD., Jones, G., Burr, RB., McDonald, PR., Koehler, SB., Tsuruda, J., Orrison, WW., & Heilbrun, MP. (1999). Integration of preoperative and intraoperative functional brain mapping in a frameless stereotactic environment for lesions near eloquent cortex. Technical note, *J Neurosurg* Vol. 90, No. 3, (March 1999), pp. 591-598, ISSN 0022-3085
- Mueller, WM., Yetkin, ZF., Hammeke, TA., Morris, GL 3rd., Swanson, SJ., Reichert, K., Cox, R., & Haughton, VM. (1996). Functional magnetic resonance imaging mapping of the motor cortex in patients with cerebral tumors, *Neurosurgery* Vol. 39, No. 3, (September 1996), pp. 515-521, ISSN 0148-396X
- National Comprehensive Cancer Network. (2007). *Central Nervous System Cancer Guidelines*. Jenkintown, PA: NCCN Press
- Nimsky, C. (2011). Intraoperative acquisition of fMRI and DTI, *Neurosurg Clin N Am* Vol. 22, No. 2, (April 2011), pp. 269-277, ISSN 1050-6438
- Petrovich, N., Holodny, AL., Tabar, V., Correa, DD., Hirsch, J., Gutin, PH., & Brennan, CW. (2005). Discordance between functional magnetic resonance imaging during silent speech tasks and intraoperative speech arrest, *J Neurosurg* Vol. 103, No. 2, (August 2005), pp. 267-274, ISSN 0022-3085
- Pouratian, N., Bookheimer, SY., Rex, DE., Martin, NA., & Toga, AW. (2002). Utility of preoperative functional magnetic resonance imaging for identifying language


- cortices in patients with vascular malformations, *Neurosurg Focus* Vol. 13, No.4,(October 2002), pp. 21-32, ISSN 1092-0684
- Puce, A., Constable, T. Luby, ML., McCarthy, G., Nobre, AC., Spencer, DD., Gore, JC., & Allison, T. (1995). Functional magnetic resonance imaging of sensory and motor cortex: comparison with electrophysiological localization, *J Neurosurg* Vol. 83, No. 2, (August 1995), pp. 262-270, ISSN 0022-3085
- Roux, FE., Boulanouar, K., Lotterie, JA., Mejdoubi, M., LeSage, JP., & Berry, I. (2003). Language functional magnetic resonance imaging in preoperative assessment of language areas: correlation with direct cortical stimulation, *Neurosurgery* Vol. 52, No. 6, (June 2003), pp. 1335-1347, ISSN 0148-396X
- Ruge, MI., Victor, J., Hosain, S., Correa, DD., Relkin, NR., Tabar, V., Brennan, C., Gutin, PH., & Hirsch, J. (1999). Concordance between functional magnetic resonance imaging and intraoperative language mapping, *Stereotact Funct Neurosurg* Vol. 72, No. 2-4, pp. 95-102, ISSN 0022-3085
- Rutten, GJ., Ramsey, NF., van Rijen, PC., Noordmans, HJ., & van Veelen, CW. (2002). Development of a functional magnetic resonance imaging protocol for intraoperative localization of critical temporoparietal language areas, *Ann Neurol* Vol. 51, No. 3, (March 2002), pp. 350-360, ISSN 1531-8249
- Sanai, N., & Berger, MS. (2008). Glioma extent of resection and its impact on patient outcome, *Neurosurgery* Vol. 62, No. 4, (April 2008), pp. 753-764, ISSN 0148-396X
- Scarabino, T., Giannatempo, GM., Popolizio, T., Tosetti, M., d'Alesio, V., Esposito, F., Di Salle, F., Di Costanzo, A., Bertolino, A., Maggialelli, A., & Salvolini, U. (2007). 3.0-T functional brain imaging: a 5-year experience, *Radiol Med* Vol. 112, No.1, (February 2007), pp. 97-112, ISSN 0033-8362
- Schulder, M., Maldjian, JA., Liu, WC., Holodny, AI., Kalnin, AT., Mun, IK., & Carmel, PW. (1998). Functional image-guided surgery of intracranial tumors located in or near the sensorimotor cortex, *J Neurosurg* Vol. 89, No. 3, (September 1998), pp. 412-418, ISSN 0022-3085
- Signorelli, F., Guyotat, J., Schneider, F., Isnard, J., & Bret, P. (2003). Technical refinements for validating functional MRI-based neuronavigation data by electrical stimulation during cortical language mapping, *Minim Invasive Neurosurg* Vol. 46, No. 5, (October 2003), pp. 265-268, ISSN 09467211
- Stafford, SL., Perry, A., Suman, VJ., Meyer, FB., Scheithauer, BW., Lohse, CM., & Shaw, EG. (1998). Primarily resected meningiomas: outcome and prognostic factors in 581 Mayo Clinic patients, 1978 through 1988, *Mayo Clin Proc* Vol. 73, No. 10, (October 1998), pp. 936-942, ISSN 0025-6196
- Tieleman, A., Vandemaële, P., Seurinck, R., Deblaere, K., & Achten, E. (2007). Comparison between functional magnetic resonance imaging at 1.5 and 3 Tesla: effect of increased field strength on 4 paradigms used during presurgical work-up, *Invest Radiol* Vol. 42, No. 2, (February 2007), pp. 130-138, ISSN 0020-9996
- Tomczak, RJ., Wunderlich, AP., Wang, Y., Braun, V., Antoniadis, G., Görich, J., Richter, HP., & Brambs, HJ. (2000). fMRI for preoperative neurosurgical mapping of motor cortex and language in a clinical setting, *J Comput Assist Tomogr* Vol. 24, No. 6, (November-December 2000), pp. 927-934, ISSN 0363-8715
- Yetkin, ZF., Mueller, WM., Morris, GL., McAuliffe, TL., Ulmer, JL., Cox, RW., Daniels, DL., & Houghton, VM. (1997). Functional MR activation correlated with intraoperative

cortical mapping, *AJNR Am J Neuroradiol* Vol. 18, No. 7, (August 1997), pp. 1311-5, ISSN 0195-6108

Yousry, TA., Schmid, UD., Jassoy, AG., Schmidt, D., Eisner, WE., Reulen, HJ., Reiser, MF., & Lissner, J. (1995). Topography of the cortical motor hand area: prospective study with functional MR imaging and direct motor mapping at surgery, *Radiology* Vol.195, No.1, (April 1995), pp.23-29, ISSN 0033-8419

IntechOpen

IntechOpen



Neuroimaging - Clinical Applications

Edited by Prof. Peter Bright

ISBN 978-953-51-0200-7

Hard cover, 576 pages

Publisher InTech

Published online 09, March, 2012

Published in print edition March, 2012

Modern neuroimaging tools allow unprecedented opportunities for understanding brain neuroanatomy and function in health and disease. Each available technique carries with it a particular balance of strengths and limitations, such that converging evidence based on multiple methods provides the most powerful approach for advancing our knowledge in the fields of clinical and cognitive neuroscience. The scope of this book is not to provide a comprehensive overview of methods and their clinical applications but to provide a "snapshot" of current approaches using well established and newly emerging techniques.

How to reference

In order to correctly reference this scholarly work, feel free to copy and paste the following:

Eftychia Z. Kapsalaki, Dimitrios Verganelakis, Ioannis Z. Kapsalakis, Efstathios D. Gotsis and Kostas N. Fountas (2012). The Role of Functional MRI in Intracranial Glioma Resection, *Neuroimaging - Clinical Applications*, Prof. Peter Bright (Ed.), ISBN: 978-953-51-0200-7, InTech, Available from: <http://www.intechopen.com/books/neuroimaging-clinical-applications/the-role-of-functional-mri-in-intracranial-glioma-resection>

INTECH
open science | open minds

InTech Europe

University Campus STeP Ri
Slavka Krautzeka 83/A
51000 Rijeka, Croatia
Phone: +385 (51) 770 447
Fax: +385 (51) 686 166
www.intechopen.com

InTech China

Unit 405, Office Block, Hotel Equatorial Shanghai
No.65, Yan An Road (West), Shanghai, 200040, China
中国上海市延安西路65号上海国际贵都大饭店办公楼405单元
Phone: +86-21-62489820
Fax: +86-21-62489821

© 2012 The Author(s). Licensee IntechOpen. This is an open access article distributed under the terms of the [Creative Commons Attribution 3.0 License](#), which permits unrestricted use, distribution, and reproduction in any medium, provided the original work is properly cited.

IntechOpen

IntechOpen