

# We are IntechOpen, the world's leading publisher of Open Access books Built by scientists, for scientists

4,800

Open access books available

122,000

International authors and editors

135M

Downloads

Our authors are among the

154

Countries delivered to

TOP 1%

most cited scientists

12.2%

Contributors from top 500 universities



WEB OF SCIENCE™

Selection of our books indexed in the Book Citation Index  
in Web of Science™ Core Collection (BKCI)

Interested in publishing with us?  
Contact [book.department@intechopen.com](mailto:book.department@intechopen.com)

Numbers displayed above are based on latest data collected.

For more information visit [www.intechopen.com](http://www.intechopen.com)



# Neurocristopathies: Role of Glial Cells, Genetic Basis and Relevance of Brain Imaging for Diagnosis

M<sup>a</sup> Carmen Carrascosa Romero<sup>1</sup> and Carlos de Cabo de la Vega<sup>2</sup>

<sup>1</sup>Neuropediatrics and <sup>2</sup>Neuropsychopharmacology Units, Albacete General Hospital  
Spain

## 1. Introduction

The concept of neurocristopathy was introduced by Bolande in 1974 to describe a group of diseases arising from aberrations in the development, migration and differentiation of the embryonic neural crest (NC). This cell lineage differentiates into pigmentary and neural cells and forms part of the autonomous nervous system, nervous enteric plexus, as well as endocrine glands (adrenals, parathyroid gland) and chemoreceptors (carotid and aortic bodies). Neurocristopathies derived from a failure in NC development and range from alterations in intestinal ganglion cells, as seen in Hirschsprung's Disease or in intestinal neuronal dysplasia, to alterations in skin pigmentation (such as neurofibromatosis, Waardenburg-Shah syndrome and piebaldism) (Spritz, 1997). In recent years, fostered by the increasing research on the NC ontogeny (Trainor, 2005), the notion of cristopathies has widened (Bolande, 1997), particularly with the inclusion of craniofacial syndromes of cranial crest mesoectodermal origin, often accompanied by morphological brain abnormalities (Couly & Aicardi, 1988), as well as the association with other diseases (Martucciello et al., 2005), including chromosomopathies (Down syndrome), embryopathies (fetal alcohol and fetal cocaine syndromes) and tumors of the endocrine system (multiple endocrine neoplasia type IIB).

Based on the accumulating knowledge of the role of NC in development, Jones (1990) proposed a new classification of cristopathies according to the pathological mechanism involved. The first group includes the defects and disorders originally defined as neurocristopathies including pheochromocytoma, neurofibromatosis, and the multiple endocrine adenomatoses. These diseases can be explained as dysplasia of neural crest derivatives. Affected individuals rarely exhibit actual morphological malformations but do carry a risk for impaired growth of crest-derived tissue. The second group corresponds to defects and disorders which derive from migrational abnormalities primarily of cranial NC cells such as frontonasal dysplasia, the DiGeorge sequence, velo-cardio-facial syndrome and Waardenberg syndrome represent true malformations. The genetic origins of some of these syndromes have been identified: microdeletions at the locus 22q11.2 (DiGeorge sequence and velo-cardio-facial syndromes) and mutations in the PAX3, MITF, EDNRB, EDN3 and SOX10 genes (Waardenberg syndrome I-IV types)

Hirschsprung's disease (HSCR) or aganglionic megacolon is perhaps the best-studied neurocristopathy. HSCR is a congenital defect characterized by complete absence of intramural neuronal ganglion cells in the myenteric (Auerbach's) plexus and the submucosal (Meissner's) plexus from distal portions of the intestinal tract caused by failure in the migration of these cells from the NC. HSCR is a disorder with multifactorial etiology including genetic factors (Kusafuka & Puri, 1998). Mutations in at least 8 genes have been associated with HSCR, most of the mutations occurring in the RET gene. According to epidemiology studies (Amiel & Lyonnet, 2001; Luis et al., 2006; Polly & Coran, 1993), HSCR appears as an isolated trait in 70% of cases. HSCR is associated with a chromosomal abnormality in 12% of cases, of which trisomy 21 (Down syndrome) represents >90%. A recent report raises the incidence of Down syndrome up to a 17.6 % of HSCR patients (Carrascosa-Romero et al., 2007). Association with other congenital multimalformative syndromes and isolated dysmorphic conditions anomalies are found in up to 18% of HSCR patients. The ones occurring at a frequency above that expected by chance include gastrointestinal malformation, cleft palate, polydactyly, cardiac septal defects, and craniofacial anomalies. HSCR has also been connected with nervous system malformations related to alterations in the development of the anterior segment of the NC: defects in the closure of the neural tube such as anencephalia and myelomeningocele, as well as impairment of neuronal migration and brain dysgenesis (Carrascosa-Romero et al., 2007; Juliá et al., 2003; Shahar & Shinawi, 2003).

## **2. Evidence that glial cell are critical participants in every major aspect of brain development, function, and disease**

Astrocytes are the most abundant cell type in the mammalian brain. Interest in astrocyte function has increased dramatically in recent years because of their newly discovered roles in synapse formation, maturation, efficacy, and plasticity. However, our understanding of astrocyte development has lagged behind that of other brain cell types. We do not know the molecular mechanism by which astrocytes are specified, how they grow to assume their complex morphologies, and how they interact with and sculpt developing neuronal circuits. Recent work has provided a basic understanding of how intrinsic and extrinsic mechanisms govern the production of astrocytes from precursor cells and the generation of astrocyte diversity. Moreover, new studies of astrocyte morphology have revealed that mature astrocytes are extraordinarily complex, interact with many thousands of synapses, and tile with other astrocytes to occupy unique spatial domains in the brain. A major challenge for the field is to understand how astrocytes talk to each other, and to neurons, during development to establish appropriate astrocytic and neuronal network architectures (Freeman, 2010). Astrocytes influence synaptic transmission in many ways. They secrete distinct factors that promote synaptogenesis, neurotransmitter release, and postsynaptic receptors (Barres, 2008); in addition, they release so-called gliotransmitters in response to stimulation and contribute to the calcium waves that correlate with blood flow (Haydon & Carmignoto, 2006; Volterra A & Meldolesi, 2005). However, they also participate directly in synaptic transmission through the expression of high-affinity transporters for neurotransmitters.

Emerging evidence indicates that signalling between perisynaptic astrocytes and neurons at the tripartite synapse plays an important role during the critical period when neural circuits

are formed and refined. Cross-talk between astrocytes and neurons during development mediates synaptogenesis, synapse elimination and structural plasticity through a variety of secreted and contact-dependent signals. Recent live imaging studies reveal a dynamic and cooperative interplay between astrocytes and neurons at synapses that is guided by a variety of molecular cues. A unifying theme from these recent findings is that astrocytes can promote the development and plasticity of synaptic circuits. Insight into the molecular mechanisms by which astrocytes regulate the wiring of the brain during development could lead to new therapeutic strategies to promote repair and rewiring of neural circuits in the mature brain following central nervous system (CNS) injury and neurodegenerative disease (Stevens, 2008).

### **3. Neuron-to-glia signalling in the central and enteric nervous system – Implications for neural disease**

Dysfunction of non-neuronal cells such as astrocytes and microglia have been involved in the process of neurodegeneration in the CNS. In fact, they have been proposed as therapeutic targets since their selective survival is capable of slowing down the process of neuronal death in animal models of neurodegenerative disease (Boillee et al., 2006; Yamanaka et al. 2008). In a healthy individual, astrocytes seem to respond to synaptic activity in the CNS in a synapse-specific way and, in turn, they appear to precisely regulate synaptic activity. These processes have been shown to involve the activity and expression of plasma membrane transporters (Bergles et al., 1999). The excitatory amino acid transporters (EAATs) control spillover of glutamate from one synapse to another. Besides this, they also prevent accumulation of glutamate at the synapse and subsequent toxicity and they serve to recycle the released transmitter for packaging and subsequent release. Most transporters are expressed at the nerve terminal, where they are well positioned to serve both functions. However, the major EAAT isoforms GLAST (human EAAT1) and GLT1 (human EAAT2) are expressed by glia and localize to astrocytic processes that reside at varying distances from the synapse. Recent experimental *in vivo* work has shown that presynaptic terminals regulate astroglial GLT1/EAAT2 expression (Yang et al., 2009). The regulation of GLT1 expression by presynaptic input also raises important questions about cause and effect in neural degeneration. It is very clear that loss of GLT1/EAAT2 causes severe toxicity, and downregulation may occur in ALS. However, several works (Bergles et al., 1999; Yang et al., 2009) suggest that the downregulation observed may reflect rather than cause neuronal loss. Indeed, downregulation in the absence of neural input might have less deleterious consequences than in the intact state, where the release of more glutamate has greater potential to produce toxicity. Neuronal regulation presumably serves to coordinate glutamate clearance with glutamate release. However, a defect in the signalling mechanism might trigger the degenerative process without a primary disorder of the neuron, and even secondary changes in EAATs expression may propagate the neuronal injury.

Glia in the peripheral nervous system also respond to neuronal activity. Enteric glia are intimately associated with the neurons from the enteric nervous system (ENS) This association is similar in morphology and molecular nature to that shown by neurons and glia in the CNS. Astrocyte-like enteroglial cells are actively involved in enteric neuronal activity via neurotransmitter receptors. In the ENS, the purine adenosine triphosphate (ATP) is released together with noradrenaline and acetylcholine by enteric neurons (Al-Humayyd

& White, 1985; Nurgali et al., 2003). ATP plays a pivotal role in regulating synaptic transmission in CNS astrocytes (Abbracchio & Ceruti, 2006) and it is involved in controlling gastrointestinal motility, secretomotor function, blood flow, and synaptic transmission (Bornstein, 2008; Christofi, 2008; Ren & Bertrand, 2008). Enteric glia express purinergic receptors and has been reported to respond to ATP *in vitro* (Gomes et al., 2007; Zhang et al., 2003) which suggested enteric glia participation in functional gastrointestinal responses to nerve signalling. More recently, activation of enteric neurons using electrical field stimulation of interganglionic fiber tracts in a longitudinal muscle myenteric plexus preparation from Guinea pig colon was able to elicit enteric glial cell activity as assessed by intracellular Ca<sup>2+</sup> imaging *in situ* through P2Y<sub>4</sub> ATP receptors (Gulbransen & Sharkey, 2009), providing the first evidence of neuron-to-glia signalling in the ENS. Further to this, the same team using a combination of techniques to selectively stimulate or eliminate intrinsic and extrinsic populations of neurons found that enteric glia are specifically activated by sympathetic postganglionic neurons innervating the colonic myenteric plexus (Gulbransen et al., 2010). This result supports the notion that glia are not indiscriminate detectors of neuronal activity and can discern activity from specific neural pathways. Interestingly, the case of a HSCR patient with a SOX10 gene mutation has recently been reported showing neurological impairment entirely due to glial maldevelopment including peripheral dysmyelinating neuropathy and enteric neuroglia deficiency (Shimotake et al., 2007). This discovery has driven renewed interest for neuron-to-glia interactions and neuroimaging in the field of neurocristopathies.

#### **4. Hirschsprung disease (HSCR) or aganglionic megacolon and its association with other malformations**

HSCR is a cause of functional intestinal obstruction with an incidence of 1/5000 alive newborns (NB) (Lister & Irving, 1990; Amiel & Lyonnet, 2001). However, the incidence has been shown to vary significantly among ethnic groups: 1.5, 2.1, and 2.8 per 10 000 live births in Caucasians, African-Americans, and Asians, respectively, in the state of California (Amiel & Lyonnet, 2001). For comparison, in our Albacete Health Service Area the incidence is 1.6 per 5000 alive NB (Carrascosa-Romero et al., 2007). Although there are many sporadic cases, a heterogeneous familial incidence has also been described involving several genetic factors (Amiel & Lyonnet, 2001).

There is abundant literature connecting HSCR with other malformations (Table 1), frequently including cleft palate, iris coloboma and congenital cardiac defects, among others (Amiel & Lyonnet, 2001; Scriver et al., 2002). Often, HSCR may appear as part of a well-known neurocristopathy syndrome such as piebaldism (MIM 172800), Shah-Waardenburg (MIM 277580), congenital central hypoventilation (Haddad, MIM 209880) or Riley-Day (MIM 223900) syndromes, or associated to other types of dysmorphic syndromes, such as Aarskog (MIM 100050), Rubinstein-Taybi (MIM 180849), or Smith-Lemli-Opitz syndromes (MIM 270400), where HSCR is not always present but shows an incidence higher than expected by chance. Of interest, Carrascosa-Romero et al., 2007 also reported an unusual case of HSCR associated with FG syndrome (MIM 305450), a X-linked heterogeneous genetic disorder characterized by hair whorls, broad thumbs and severe constipation (Romano et al., 1994), presenting with severe mental retardation.



<b>SYNDROMES</b>	<b>MIM</b>	<b>KEY CLINICAL FEATURES</b>
<b>• NEUROCRESTOPATHIES</b>		
WS4 (Shah-Waardenburg)	277580	Pigmentary anomalies (white forelock, iris hypoplasia, patchy hypopigmentation), deafness.
Hipopigmentación- Sordera-Ceguera Yemenite	601706	Hearing loss, eye anomalies (microcornea, coloboma, nystagmus), pigmentary anomalies
BADS (black locks, oculocutaneous albinism, sensorineural deafness)	227010	Hearing loss, hypopigmentation of the skin and retina
Piebaldism	172800	Patchy hypopigmentation of the skin and hair
Haddad	209880	Congenital central hypoventilation
MEN2A	171400	Medullary thyroid carcinoma, pheochromocytoma, hyperplasia of the parathyroid
Riley-Day	223900	Autonomic nervous system anomalies
<b>HSCR MANDATORY</b>		
Goldberg-Shprintzen	609460 235740	Cleft palate, hypotonia, microcephaly, mental retardation, dysmorphic facial features Hypertelorism, deafness, polydactyly, unilateral renal agenesis
HSCR with limbs anomalies	235750 235760 604211 306980	Postaxial polydactyly, ventricular septal defect Hypoplasia of distal phalanges and nails, dysmorphic features Preaxial polydactyly, heart defect, laryngeal anomalies. Brachydactyly type D
BRESHECK	300404	Brain abnormalities, Retardation, Ectodermal dysplasia, Skeletal malformation, HSCR, Ear/eye anomalies, Cleft palate/Cryptorchidism and Kidney dysplasia/hypoplasia
Mesomelic dysplasia, Werner type		Mesomelia, polydactyly
<b>HSCR FREQUENTLY ASSOCIATED</b>		
Mowat-Wilson	255730	Dysmorphic facial features, microcephaly, mental retardation, agenesis of corpus callosum, heart disease, urogenital/renal anomalies
<b>HSCR OCCASIONALLY ASSOCIATED</b>		
Bardet-Biedl	209900	Pigmentary retinopathy, obesity, hypogenitalism, mild mental retardation, postaxial polydactyly
Kauffman-McKusick	236700	Hydrometrocolpos, postaxial polydactyly, congenital heart defect.

Smith-Lemli-Opitz	270400	Growth retardation, microcephaly, mental retardation, hypospadias, 2-3 toes syndactyly, dysmorphic features
Cartilage-hair hypoplasia	250250	Short limb dwarfism, metaphyseal dysplasia, immunodeficiency
<b>HSCR RARELY ASSOCIATED</b>		
Fukuyama congenital muscular dystrophy	253800	Muscular dystrophy, polymicrogyria, hydrocephalus, mental retardation, seizures.
Clayton-Smith	258840	Dysmorphic features, ichthyosis, hypoplastic toes and nails
Kaplan	304100	Agenesis of corpus callosum, adducted thumbs, ptosis, muscle weakness
Okamoto	308840	Agenesis of corpus callosum, hydrocephalus, cleft palate.

Table 1. Syndromes associated with HSCR (reprinted and adapted from Scriver CM et al, eds. "The metabolic and molecular bases of inherited diseases" 8th ed. Chap 251. New York: McGraw-Hill: 6231-55.)

For other syndromes, HSCR is a mandatory feature for diagnosis such as BRESHECK (Brain Abnormalities, Retardation, Ectodermal dysplasia, Skeletal malformation, Hirschsprung disease, Ear/eye anomalies, Cleft palate/Cryptorchidism and Kidney dysplasia) (MIM 300404) and the subtypes of HSCR with limb anomalies (MIM 235750, 235760, 604211 and 306980). HSCR is also a mandatory feature for Goldberg-Shprintzen megacolon syndrome (GOSHS MIM 609460)(Goldberg & Shprintzen, 1981). This syndrome is characterized by microcephaly, hypertelorism, short stature, cleft palate, learning problems, and seems to be caused by homozygous nonsense mutations in KIAA 1279 located at 10q22.1. GOSHS presents various common characteristics with the Mowat-Wilson syndrome (MIM 235730), which will be discussed below in section 5.

HSCR has also been connected with malformations of the nervous system: defects in the neural tube closure such as anencephaly (Mathew, 1998) and meningomyelocele (Merkler et al., 1985), as well as anomalies in neuronal migration and or cerebral dysgenesis (Cass, 1990), predominantly agenesis of corpus callosum (Sayed & Al-Alaigan, 1996). These phenomena have been regarded as alterations in the embryonic development of the anterior portion of the NC (Currie et al., 1986; Hurst et al., 1986). The actual incidence of associated brain anomalies has been studied for other neurocristopathies. For example, Couly & Aicardi (1983) reported that of a group of 3000 children presenting with facial dysembryoplasias, 13 % also showed brain malformations. Another study showed up to 82 % (18 out of 25) of children with uni- or bilateral maxillomandibular neurocristopathies (Goldenhar's, Franceschetti's first arch syndromes or transient forms) also presented morphological and motor anomalies of the brain stem and its corresponding cranial nerves, as assessed by neurological and cerebral computed tomography examinations (Couly & Le Lievre-Ayer, 1983). However, we have failed to find previous literature studying the incidence of brain malformations associated with HSCR. Available reports dealt with isolated cases (Turkdogan-Sozuer et al., 1998), sometimes under other denominations such as GOSHS. All these cases nonetheless share a common denominator: psychomotor delay,

associated to alterations in the CNS, generally: microcephaly, agenesis of corpus callosum, white matter atrophy, ventricular dilatation. Few reports describe pachygyria, polymicrogyria as well as cerebellar hypoplasia in HSCR patients (Carrascosa-Romero et al., 2007), perhaps due to the fact that neuroimaging studies are rarely performed on this type of patients. Our team did study the incidence of brain malformations associated with HSCR in our Albacete Health Service Area. In our study we found 10 cases of isolated HSCR versus 7 cases of HSCR associated with other structural anomalies or psychomotor retardation, which indicated a high incidence of anomalies associated with HSCR (41,1%) in our territory.

#### **4.1 Molecular genetics in HSCR: The RET proto-oncogene**

Segregation studies in nonsyndromic HSCR have shown sibling recurrence risk ranging from 1 to 33 %, and it is considered a multifactorial disorder, the effect of genes predominating over environmental factors (relative risk of 200). The higher susceptibility for HSCR in some families allowed establishing the locus 10q11.2q21.2 as a genetic origin of the disease (Fewtrell et al., 1994.) The RET proto-oncogene is located in this region and has been shown to be highly involved in neurocristopathies (Amiel & Lyonnet, 2001). The RET proto-oncogene is a tyrosine-protein kinase receptor essential for the glial cell-derived neurotrophic factor (GDNF) actions preventing neuroectodermal cell apoptosis (Mograbi et al., 2001). De Pontual et al., 2006, genotyped RET in 143 patients with two syndromic HSCR entities: congenital central hypoventilation (CCHS) and Mowat-Wilson syndrome (MWS), caused by PHOX2B and ZFH1B gene mutations, respectively, finding that there were both RET dependent and RET independent HSCR cases. Besides this, RET mutations have been found only in 50 % of familial and 15 % to 20 % sporadic HSCR cases (Attie et al., 1995). Therefore, notwithstanding the importance of the mutations in the RET gene, there are other genes involved in human HSCR: neurturin (NTN), endothelin B receptor (EDNRB), endothelin-3 (EDN3), endothelin-converting enzyme (ECE1), as well as the SOX10 and SIP1 genes (Amiel & Lyonnet, 2001; Mollaaghababa & Pavan, 2003).

Substance P -a neurotransmitter specific marker of neuronal differentiation- has been found downregulated in HSCR suggesting a role for peptidergic innervation in the pathogeny of this disease (Tam, 1986). The possible connection between the above mentioned genes, substance P and GDNF and the causal mechanism the alteration of neuronal migration in the NC morphogenesis is not yet clear, since a high proportion of genetic anomalies cannot be identified using a standard screening of genomic DNA. A multiple origin is likely including other types of molecular parameters. For example, elevated levels of maternal homocysteine have been established as a risk toxicity factor for congenital defects during embryonic development, particularly anomalies in the neural tube closure and neurocristopathies (Brauer & Tierney, 2004), whereas a prophylactic role has been observed for folic acid in both types of pathologies (Antony, 2007).

### **5. Mowat-Wilson syndrome**

Mowat-Wilson syndrome (MWS, MIM 235730) is a condition that involves multiple congenital defects described by Mowat et al., 1998. They reported a series of six children presenting mental retardation, microcephaly, and short stature with a distinctive facial



phenotype accompanied by other variable types of congenital anomalies. Five of these patients also had HSCR and one presented an interstitial deletion of chromosome 2, del (2)(q21q23). These children strongly resembled the patient earlier reported by Lurie et al. 1994, with HSCR and dysmorphic features also associated with del (2) (q22q23). They concluded that these children had a distinct syndrome for which HSCR was not a mandatory feature and that could be caused by a contiguous gene syndrome, or a single gene disorder, or disruption of a critical region within 2q22-23. In 2001, two independent teams (Cacheux et al., 2001; Wakamatsu et al., 2001) identified the cause of MWS as either a heterozygous deletion or truncation mutations in the Zinc finger E-box-binding homeobox 2 gene, ZEB2, (MIM 605802, previously called ZFH1B) which encodes a smad interacting protein 1 (SIP1) located in the above mention chromosome region 2q22-23.

Since the first description by Mowat et al (1998), approximately 200 patients have been reported and over 100 mutations have been described (Dastot-Le Moal et al., 2007). The phenotype/genotype correlation for these mutations is very variable, not only for a given mutation (Cerruti-Mainardi et al., 2005; Zweier et al., 2003) but also within the same family (McGaughan et al., 2005). The syndrome has been identified in several ethnic groups (Dastot-Le Moal et al., 2007), with similar clinical features in all populations. The male/female ratio is approximately 1,42:1 (Adam et al., 2006; Horn et al., 2004).

The prevalence of MWS is currently unknown, but it seems probable that the syndrome is under-diagnosed, particularly in patients without HSCR (Cerruti-Mainardi et al., 2005). For this reason the identification of the facial phenotype is of special relevance for the initial clinical diagnosis (Garavelli L & Cerruti-Mainardi, 2007). The clinical features of the face are: high forehead, frontal bossing, eyebrows are large, medially flaring and sparse in the middle part, hypertelorism with hollow but large eyes, big and uplifted ear lobes with a central depression, saddle nose, open mouth, with M-shaped upper lip, frequent smiling and occasional drooling (Fig. 1, a and b), and a prominent but narrow and triangular pointed chin that further elongates with age ( Fig. 2, a and b).

At birth, patients show growth parameters with values within normal percentiles but they develop microcephaly and short stature progressively with age. The facial phenotype also evolves in older children. For example, the eyebrows become thicker, broad and horizontal, with an increased wide middle separation and medial sparseness. The nasal tip lengthens and becomes more depressed, the columella is more prominent, the nasal profile becomes convex, the face tends to elongate and the jaw is more pronounced. The uplifted ear lobes do not change significantly with time and are an excellent diagnostic clue (Mowat et al., 2003) (Fig. 3).

The clinical manifestations of MWS in the about 200 cases described presenting with ZEB2 mutations have been recently reviewed Garavelli and Cerruti-Mainardi, 2007. In brief, the distinct facial phenotype is present in 97% of the patients, at least moderate but usually severe mental retardation in all the cases, microcephaly is present in 81%, epilepsy in 73%, HSCR in 57%, constipation in 26%, and congenital heart disease (principally, patent ductus arteriosus, pulmonary stenosis, ventricular and atrial septal defects, pulmonary artery sling, Tetralogy of Fallot and aortic coarctation), in 52% of the cases; urogenital/renal anomalies were demonstrated in 51 % of the patients (of which 51% presented hypospadias, 36% cryptorchidism and 12.8 % several renal defects). Oropharyngeal and gastrointestinal malformations include pyloric stenosis, arched palate, among others. Musculoskeletal

anomalies occur in many patients and eye defects have also been demonstrated (4.1% of the published cases). Microcephaly is a common feature and is present in 81% of the published cases. Brain anomalies reported so far include hypoplasia or agenesis of corpus callosum, present in 43% of the published cases, cortical atrophy (Garavelli et al., 2003), pachygyria and cerebellar hypoplasia (Silengo et al., 2004), hippocampal formation hypoplasia (Kääriäinen et al., 2001) and frontotemporal hypoplasia with temporal dysplasia (Cacheux et al., 2001, Mowat et al., 2003). These findings may be under-represented because not all published cases employed brain imaging

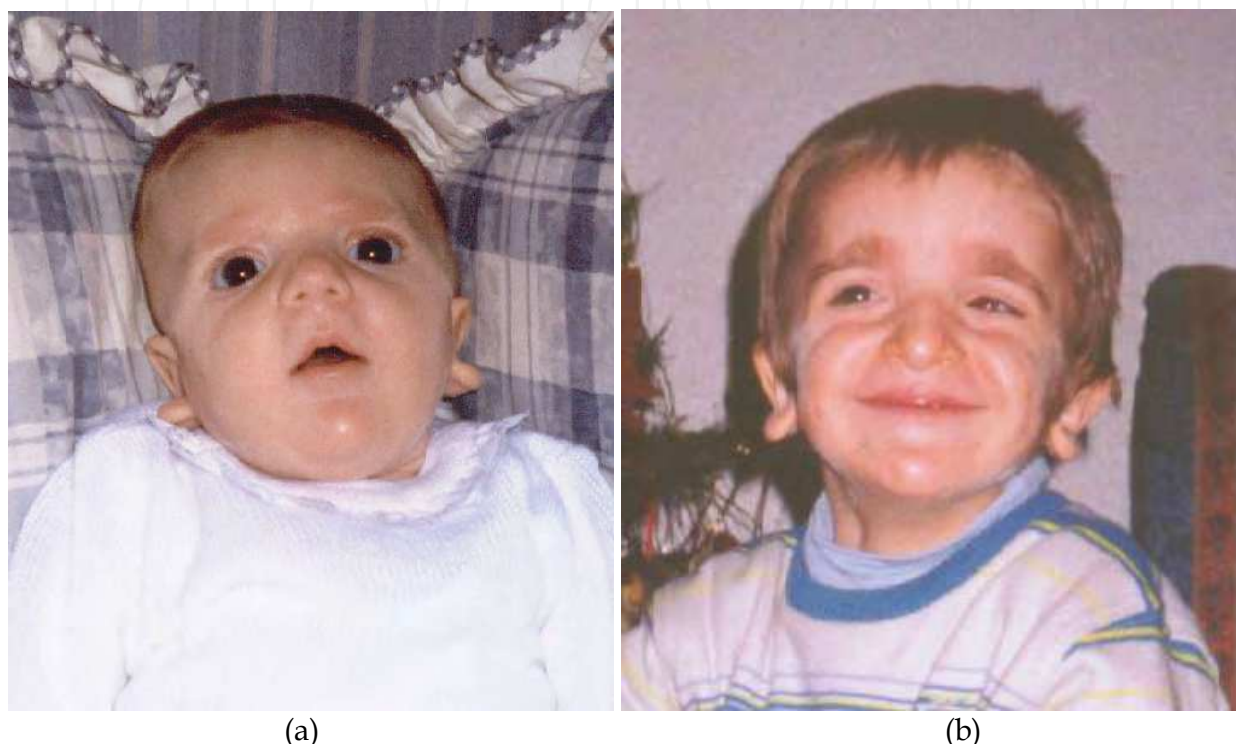
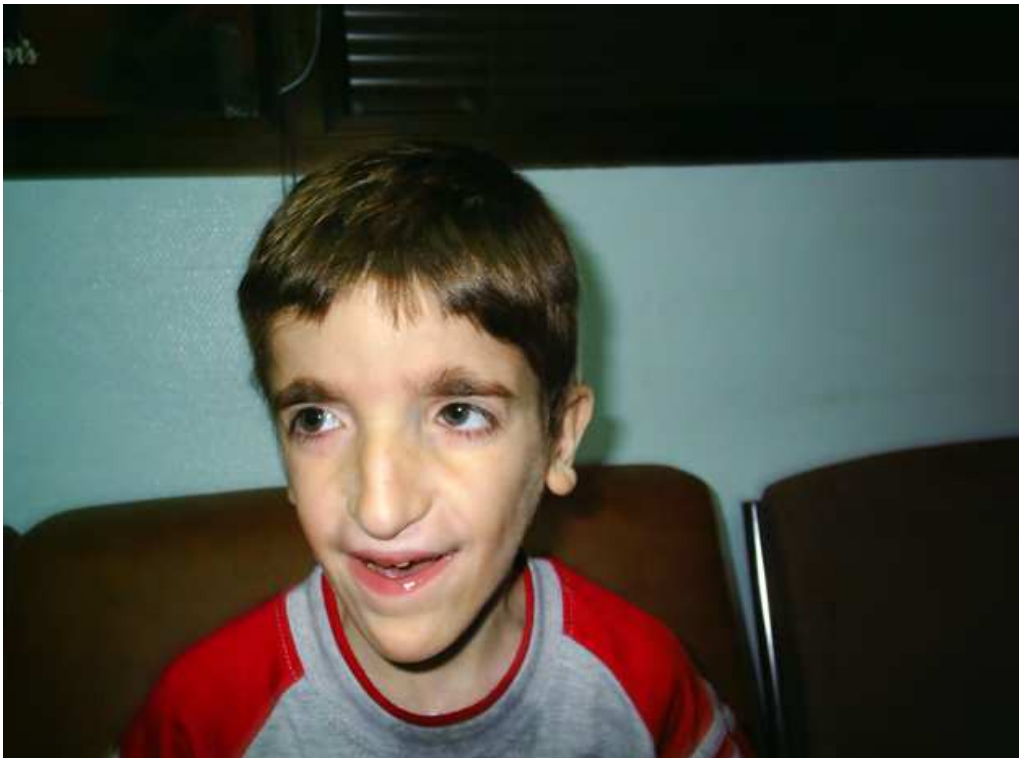
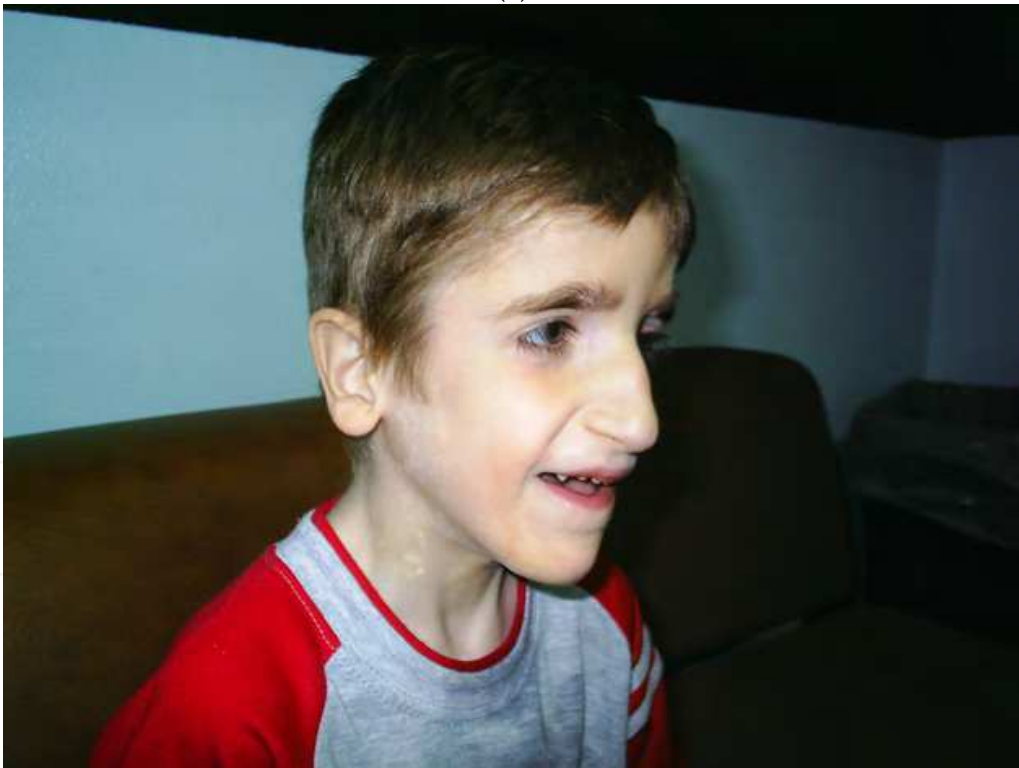Fig. 1. Clinical facial features in MWS: a) In the neonate, excess nuchal skin and scarce fine hair can be observed together with high forehead, prominent frontal bone, large wide eyebrows, but thinning in the middle part, hypertelorism, strabismus, epicanthus, large hollow eyes that originate prominent cheek bones, wide nasal bridge and open mouth, with M-shaped upper lip b) Some years later: saddle nose, prominent rounded nasal tip. The large and uplifted ear lobes with a central depression do not change significantly with age.

Regarding differential diagnosis, the facial phenotype of patients with MWS is very characteristic. However, due to the frequent presence of HSCR, epilepsy and mental retardation it may initially be mistaken as GOSHS, as we previously mentioned in section 4. The patients with GOSHS share clinical features such as HSCR, epilepsy and mental retardation, but have different facial features (high nasal bridge, synophrys, long curled eyelashes, palpebral ptosis, and cleft palate). The differential diagnosis can be carried out on the basis of facial phenotype and confirmed by mutational analysis of the ZEB2 gene. This is important for genetic counseling, since GOSHS is autosomal recessive, whereas MWS is a sporadic condition. Since individuals with MWS often show an ataxic-like gait and a smiling, sociable personality, combined with absent speech, microcephaly and seizures, they can be given a presumptive diagnosis of Angelman syndrome (Williams et al., 2001).



(a)



(b)

Fig. 2. Clinical facial features in MWS: 10 years old. Dysmorphic facial features: wide forehead, hypertelorism con antimongoloid palpebral fissure, large dense eyebrows, long eyelashes, low-set ears, prominent uplifted ear lobes, saddle nose, thin upper lip, the face becomes long and thin, with prognathism, and a long, pointed or "chisel-shaped" chin, smiley face.



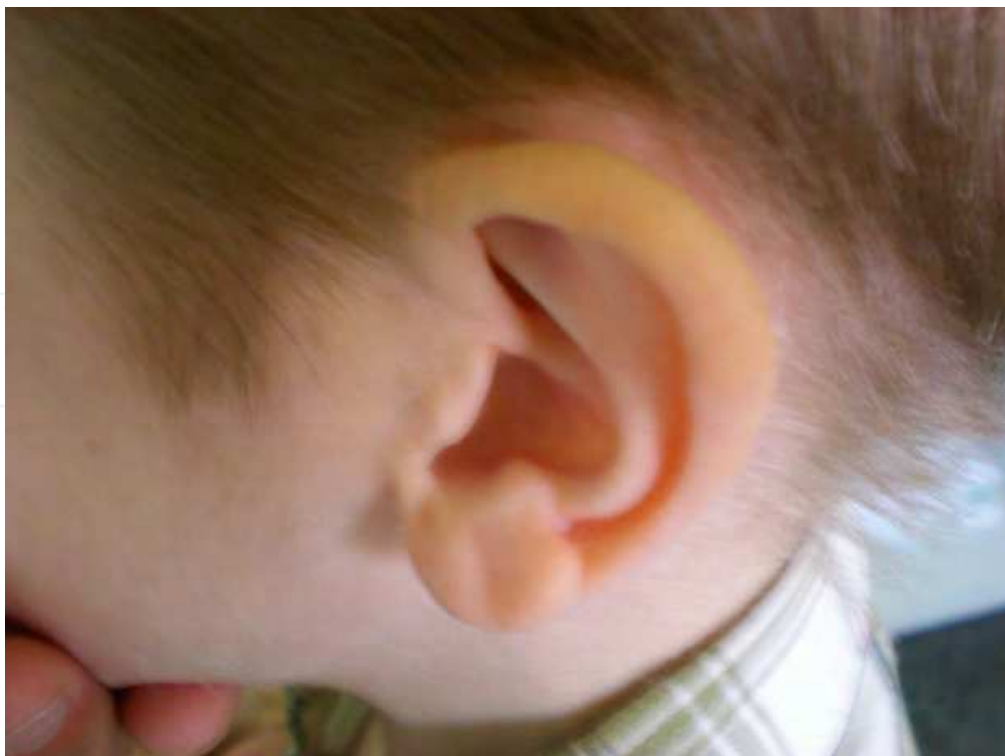
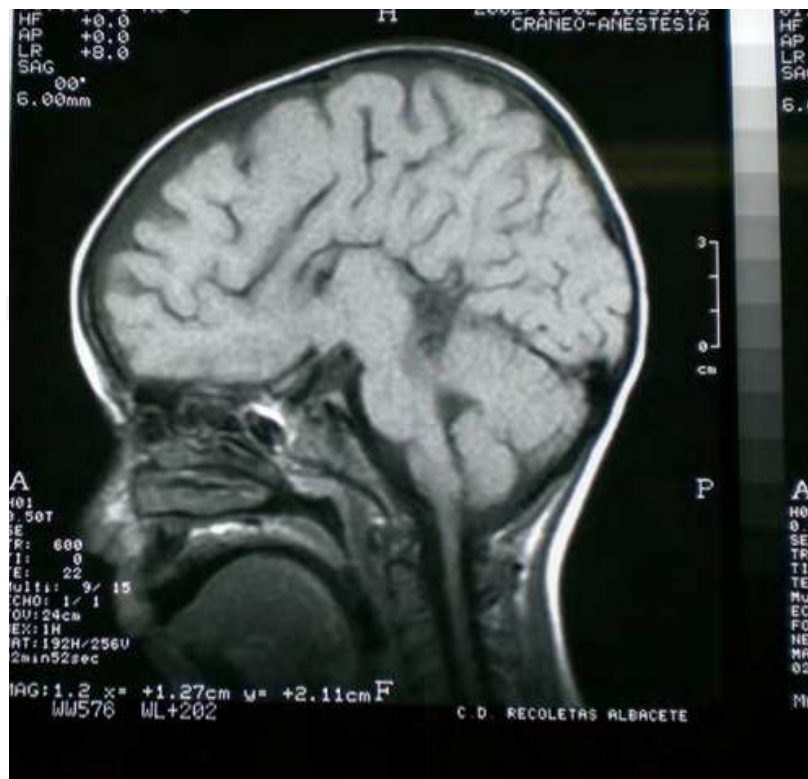
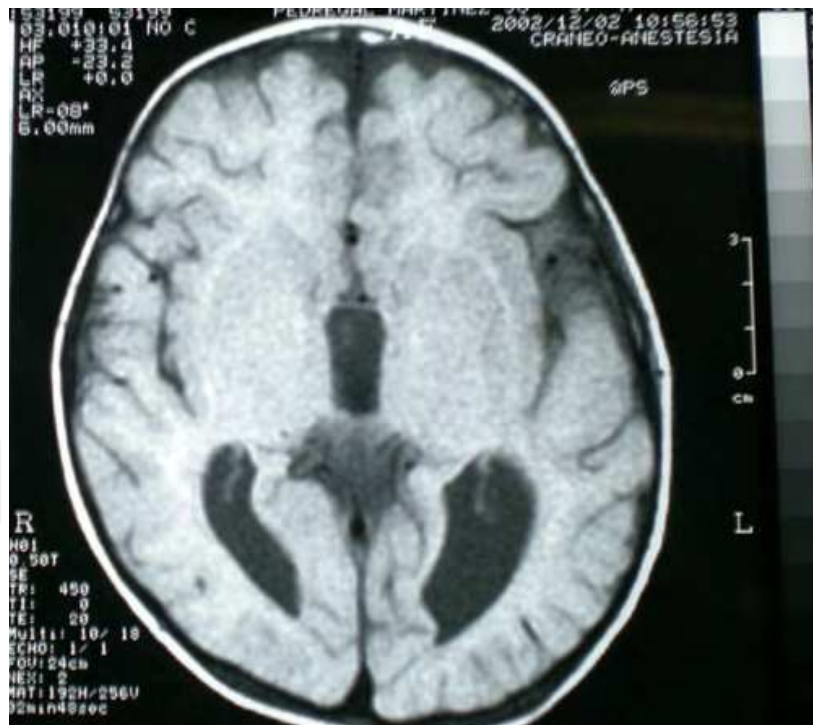
Fig. 3. Clinical facial features in MWS. The ear lobes are very typical. They are large and uplifted with a central depression and have been described as being like "orecchiette pasta" or like "red blood corpuscles" in shape. They do not change significantly with time (with the exception of the central depression, which is less obvious in adults) and are an excellent diagnostic clue

However, the distinct facial features of MWS, in addition to the other typical congenital anomalies, should allow distinguishing these two conditions. Differential diagnosis is also necessary for MWS patients presenting with hypospadias and mental retardation to avoid misdiagnosis as Smith-Lemli-Opitz syndrome, Opitz G/BBB syndrome or X-linked mental retardation-alpha thalassemia syndrome. Again, facial phenotype should be the clue for correct diagnosis.

In this context, we have recently diagnosed a patient with MWS with the help of molecular genetics and neuroimaging (Carrascosa Romero et al., 2009), which we consider an interesting and illustrative case. This patient presented a typical facial phenotype and molecular genetics analysis showed a heterozygous deletion mutation in the ZEB2 gene never described before in the literature. Parents showed no genetic anomalies. Our MWS patient showed some previously described malformations such as patent ductus arteriosus, Tetralogy of Fallot, atrial septal defect (small ostium secundum) and presented with HSCR. Magnetic resonance imaging (MRI) of the brain (Fig. 4, a and b) revealed agenesis of corpus callosum and colpocephaly with an important elevation of the third ventricle, cortical dysgenesis showing pachygyria in the left perisylvian region and decreased myelination at the biparietal level. The patient also showed severe mental retardation, happy and smiling behavior, developed epilepsy when two years of age and was not able to walk until 4 years old. The finding of CNS demyelination, detected with neuroimaging, is of special interest. This decrease in oligodendroglia maybe meaningful in the context of neurocristopathies given the role of these cells in nervous system maturation, particularly in the regulation of ventral neuroectodermal progenitor cell fate (Jakovcevski et al., 2009; Pucharcós et al., 1999)



(a)



(b)

Fig. 4. a and b. Magnetic resonance imaging (MRI) of our MWS patient brain. Image analysis revealed agenesis of corpus callosum and colpocephaly with an important elevation of the third ventricle, cortical dysgenesis showing pachygyria in the left perisylvian region and decreased myelinization at the biparietal level.



### 5.1 The ZEB2 gene: Expression and role in neurocristopathies

As mentioned above, at least 100 mutations have been described for the ZEB2 gene (Dastot-Le Moal et al., 2007) connected with MWS -including the mutation found for our patient (Carrascosa Romero et al., 2009)- which reveals the importance of this gene for the development of this disease.

The ZEB2 gene is 70 Kb long consists of 10 exons and 9 introns and encodes SIP1 (Smad interacting protein 1). Although its mechanisms of action on morphogenesis and neurogenesis still remain to be clarified, its clinical implications suggest that ZEB2 is involved in the development of the cells from the NC (ENS, craniofacial mesoectoderm), CNS, and cardiac septation, as well as in the development of the median line (agenesis of corpus callosum, urogenital/renal anomalies, pyloric stenosis)(Zweier et al., 2002; Ishihara et al., 2004).

Using mass spectrometry, Verstappen et al. 2008, found that ZEB2 associated with multiple subunits of the NURD complex, which plays a key role in transcriptional repression. Mi2-beta (CHD4; 603277) was identified as a specific cofactor for ZEB2-mediated repression of E-cadherin (CDH1; 192090). The N-terminal 289 amino acids of ZEB2 were sufficient for interaction with NURD complex subunits. In vitro studies in *Xenopus* oocytes showed broad Zeb2 expression at the gastrula stage, with stronger expression in neural tissues and neural crest cells at the neurula stage, suggesting a role in neural development. Endogenous Mi2-beta expression broadly overlapped Zeb2 expression, and antisense morpholino knockdown of Mi2-beta resulted in reduced Zeb2-mediated repression of Bmp4 (112262) and decreased induction of neural marker Ncam (116930). Further studies showed that a mutant ZEB2 protein (605802.0014), differing in the first 24 amino acids from the wildtype protein and causing a mild form of Mowat-Wilson syndrome (235730), was unable to interact with the NURD complex and showed decreased transcriptional repression of Bmp4.

To investigate the breadth of clinical variation associated with mutations in ZFHX1B, Yamada et al. 2001, studied DNA samples from 6 patients with clinical features similar to those described for ZFHX1B deficiency, except that they did not have Hirschsprung disease. The results showed the R695X mutation (605802.0002) to be present in 3 cases, with 3 novel mutations being identified in the other 3 patients. All mutations occurred in 1 allele and were de novo events. The results demonstrated that ZFHX1B deficiency is an autosomal dominant complex developmental disorder and that individuals with functional null mutations present with mental retardation, delayed motor development, epilepsy, and a wide spectrum of clinically heterogeneous features suggestive of neurocristopathies at the cephalic, cardiac, and vagal levels.

To clarify the molecular mechanisms underlying the clinical features of Hirschsprung disease-mental retardation syndrome, Van de Putte et al. 2003 generated mice that carried a *Zfhx1b* mutation comparable to those found in several human patients. They showed that *Zfhx1b* knockout mice did not develop postotic vagal neural crest cells, the precursors of the enteric nervous system that is affected in patients with Hirschsprung disease, and displayed a delamination arrest of cranial neural crest cells, which form the skeletomuscular elements of the vertebral head. This suggests that the gene product is essential for the development of vagal neural crest precursors and the migratory behavior of cranial neural crest in the mouse. Furthermore, they showed that the gene product was involved in the specification of

neuroepithelium. SIP1-knockout embryos died around embryonic day 9.5, with failed neural tube closure, lack of a sharp boundary between the neural plate and the rest of the ectoderm, and lack of the first branchial arch. It was found that conditional deletion of *Zeb2* in mouse neural crest precursors was lethal at embryonic stages. Mutant mice displayed craniofacial and gastrointestinal malformations similar to those of patients with Mowat-Wilson syndrome. In addition, mutant mice had defects in the heart, melanoblasts, and sympathetic and parasympathetic anlagen (Van de Putte et al., 2007).

A single layer of neuroepithelial cells lining the embryonic neural tube gives rise to the entire repertoire of neurons, astrocytes, and oligodendrocytes in the adult central nervous system. Seuntjens et al. 2009, found that conditional SIP1 deletion in young mouse neurons induced premature production of upper layer neurons at the expense of deep layers, precocious and increased generation of glial precursors, and elevated numbers of astrocytes at early postnatal stages. Microarray analysis showed that *Ntf3* (162660) and *Fgf9* (600921) were over- and prematurely expressed in mutant brains. In the absence of SIP1, there was also a premature peak of MAPK (176948) signalling in neural progenitor cells. It was concluded that SIP1 functions in the postmitotic compartment of the neocortex to control the expression of growth factor genes that feed back to progenitor cells to regulate production of the neurons and glial cells required for corticogenesis.

## 6. Conclusion: Relevance of brain imaging and genetics in the diagnosis of neurocristopathies

The association of HSCR (either isolated or within the context of a specific malformation syndrome) with neuronal migration anomalies is so strong (23.5%), that we recommend performing a full evaluation of HSCR patients including: a) specialized molecular genetic studies, b) a complete neurological exploration for all patients diagnosed with HSCR and c) neurologist-monitored brain imaging studies in search for cerebral dysgenesis. Conversely, when confronting cases of children presenting with mental retardation, dysmorphic features and severe constipation, anorectal manometry seems advisable to rule out HSCR.

The development of neuroimaging techniques is now making possible the detailed identification of cerebral dysgenesis compatible with neuronal migration impairments that are at the root of a wide range of brain diseases including epilepsy and mental retardation. The application of neuroimaging techniques in combination with molecular genetics to patients diagnosed with neurocristopathies has an extraordinary potential to connect genotype to phenotype and discover possible brain malformations associated with the mutations causing these syndromes.

## 7. References

- Abbracchio MP, Ceruti S. Roles of P2 receptors in glial cells: focus on astrocytes. *Purinergic Signal* 2006;2:595–604.
- Adam MP, Schelley S, Gallagher R, Brady AN, Barr K, Blumberg B, Shieh JTC, Graham J, Slavotinek A, Martin M, Keppler-Noreuil K, Storm AL, Hudgins L: Clinical features and management issues in Mowat-Wilson syndrome. *Am J Med Genet* 2006; 140 A:2730-2741.

- Al-Humayyd M, White TD. Adrenergic and possible nonadrenergic sources of adenosine 5'-triphosphate release from nerve varicosities isolated from ileal myenteric plexus. *J Pharmacol Exp Ther* 1985;233:796-800.
- Amiel J, Lyonnet S: Hirschsprung disease, associated syndromes, and genetics: a review. *J Med Genet* 2001; 38: 729-739.
- Antony AC: In utero physiology: role of folic acid in nutrient delivery and fetal development. *Am J Clin Nutr.* 2007 Feb;85(2):598S-603S.
- Attie T, Pelet A, Edery P et al: Diversity of RET proto-oncogene mutations in familial and sporadic Hirschsprung disease. *Hum Mol Genet* 1995; 4:1381-6.
- Barres, B.A: The mystery and magic of glia: a perspective on their roles in health and disease. *Neuron.* 2008 Nov 6; 60(3):430-40. Review.
- Bergles DE, Diamond JS, Jahr CE. Clearance of glutamate inside the synapse and beyond. *Curr Opin Neurobiol.* 1999 Jun;9(3):293-8. Review.
- Boillee S, Yamanaka K, Lobsiger CS, et al. Onset and progression in inherited ALS determined by motor neurons and microglia. *Science* 2006;312:1389-1392.
- Bolande RP: Neurocristopathy: its growth and development in 20 years. *Pediatr Pathol Lab Med.* 1997 Jan-Feb;17(1):1-25.
- Bolande RP: The Neurocristopathy. A unifying concept of disease arising in neural crest maldevelopment. *Human Pathol,* 1974; 5: 409-429.
- Bornstein JC. Purinergic mechanisms in the control of gastrointestinal motility. *Purinergic Signal* 2008;4:197-212.
- Brauer PR, Tierney BJ. Consequences of elevated homocysteine during embryonic development and possible modes of action. *Curr Pharm Des.* 2004;10(22):2719-32.
- Cacheux V, Dastot-Le Moal F, Kaariainen H, Bondurand N, Rintala R, Boissier B, Wilson M, Mowat D, Goossens M. Loss-of-function mutations in SIP1 Smad interacting protein 1 result in a syndromic Hirschsprung disease. *Hum Mol Genet.* 2001; 10:1503-1510.
- Carrascosa Romero MC, Barros Angueira F, Castillo Serrano A, Fernández Córdoba MS, Sorli García M, Quintanilla Mata ML: "Síndrome de Mowat-Wilson con una deleción en el Gen ZEB2 no descrita previamente. Boletín del ECEMC: Revista de Dismorfología y Epidemiología. Serie V. nº 8, 2009. ISSN: 0210-3893. pp 9-17.
- Carrascosa-Romero MC, Fernandez Cordoba MS, Gonzalez Piñera jJ, Gutierrez-Junquera C, Pardal-Fernandez JM "Neurocristopathies: a high incidence of cerebral dysgenesis in patients with Hirschsprung's disease." *Rev Neurol.*2007; 45(12):707-12.
- Cass K: Aganglionosis: Associated Anomalies. *J Pediatr Child Health* 1990; 26: 351-354.
- Cerruti-Mainardi P, Garavelli L, Pastore G, Viridis R, Pedori S, Godi M, Provera S, Rauch A, Zweier C, Castronovo C, Zollino M, Banchini G, Bernasconi S, Neri G: Mowat-Wilson syndrome and mutation in the Zinc Finger Homeo Box 1B Gene: a new síndrome probably under-diagnosed. *Italian J Pediatr* 2005, 31:116-125.
- Cheng W Au DKK Knowles CH Anand P Tam PKH: Hirschsprung's Disease: A More Generalised Neuropathy? *J Pediatr Surg* 2001; 36: 296-300.

- Christofi FL. Purinergic receptors and gastrointestinal secretomotor function. *Purinergic Signal* 2008;4:213-236.
- Couly G Aicardi J: Associated morphological anomalies of the face and brain in infants *Arch Fr Pediatr*. 1988 Feb;45(2):99-104.
- Couly G Le Lievre-Ayer C: Laterofacial malformations (maxillomandibular neurocristopathies) associated with anomalies of the brain stem and cranial nerves. *Rev Stomatol Chir Maxillofac*. 1983;84(5):254-63.
- Currie ABM Haddad M Honeyman M Boddy SM: Associated Developmental Abnormalities of the Anterior End of the Neural Crest: Hirschsprung's Disease, Waardenburg's Syndrome. *J Pediatr Surg* 1986; 21: 248-250.
- Dastot-Le Moal F, Wilson M, Mowat D, Collot N, Niel F, Goossens M: ZFH1B mutations in patients with Mowat-Wilson syndrome. *Hum Mutat* 2007, 4:313-321.
- De Pontual L Pelet A Trochet D Jaubert F Espinosa-Parrilla Y Munnich A y col: Mutations of the RET gene in isolated and syndromic Hirschsprung's disease in human disclose major and modifier alleles at a single locus. *J. Med. Genet*. 2006; 43: 419-423.
- Fewtrell MS Tam PK Thomson AH Fitchett M Currie J Huson SM Mulligan LM: Hirschsprung's disease associated with a deletion of chromosome 10 (q11.2q21.2): a further link with the neurocristopathies? *J Med Genet*. 1994 Apr;31(4):325-7.
- Freeman MR: Specification and morphogenesis of astrocytes. *Science*. 2010 Nov 5; 330(6005):774-8.
- Garavelli L, Donadio A, Zanacca C, Banchini G, Della Giustina E, Bertani G, Albertini G, Del Rossi C, Zeweier C, Rauch A, Zollino M, Neri G. Hirschsprung disease, mental retardation, characteristic facial features and mutation in the gene ZFH1B (SIP1): confirmation of the Mowat-Wilson syndrome. *Am J Med Genet A*.2003; Feb 1; 116A (4):385-8.,
- Garavelli L, Mainardi PC: Mowat-Wilson syndrome. *Orphanet J Rare Dis*. 2007, 2:42 (<http://www.OJRD.com/content/2/1/42>).
- Goldberg RB Shprintzen RJ: Hirschsprung megacolon and cleft palate in two sibs. *J Craniofac Genet Dev Biol*. 1981; 1: 185-189.
- Gulbransen BD, Sharkey KA: Purinergic neuron-to-glia signaling in the enteric nervous system. *Gastroenterology* 2009;136:1349-1358.
- Haydon PG, Carmignoto G.: Astrocyte control of synaptic transmission and neurovascular coupling. *Physiol Rev*. 2006 Jul;86(3):1009-31. Review
- Horn D, Weschke B, Zweier C, Rauch A: Facial phenotype allows diagnosis of Mowat-Wilson syndrome in the absence of Hirschsprung disease. *Am J Med Genet* 2004, 124 A:102-104.
- Hurst JA Markewicz M Kumar K Brett EM: Unknown Syndrome, Hirschsprung's Disease, Microcephaly, and Iris Coloboma: a New Syndrome of Defective Neuronal Migration. *J Med Genet* 1988; 25: 494-500.
- Ishihara N, Yamada K, Yamada Y, Miura K, Kato J, Kuwabara N, Hara Y, Kabayashi Y, Hoshino K, Nomura Y, Mimaki M, Ohya K, Matsushima M, Nitta H, Tanaka K, Segawa M, Ohki T, Ezoe T, Kumagai T, Onuma A, Kurada T, Yoneda M, Yamanaka



- T, Saeki M, Segawa M, Saji T, Nagaya M, Wakamatsu N: Clinical and molecular analysis of Mowat-Wilson syndrome associated with ZFH1B mutations and deletions at 2q22-24.1. *J Med Genet* 2004, 41:387-393..
- Jakovcevski I, Filipovic R, Mo Z, Rakic S, Zecevic N. Oligodendrocyte development and the onset of myelination in the human fetal brain. *Front Neuroanat.* 2009; 3:5. Epub 2009 Jun 1 (3, article 5):1-15.
- Jones MC: The neurocristopathies: reinterpretation based upon the mechanism of abnormal morphogenesis *Cleft Palate J.* 1990 Apr;27(2):136-40.
- Juliá V, Albert A, Cusi V, Gómez A, López L, Morales L: Hipoganglionismos y displasias neuronales: tienen las mismas malformaciones asociadas que la enfermedad de hirschsprung?. *Comunicación al XLII Congreso de la SECP Valencia-2003.*
- Kusafuka T, Puri P: Genetic Aspects of Hirschsprung's Disease. *Semin Pediatr Surg* 1998; 7: 148-155.
- Lister J, Irving IM: *Neonatal Surgery* 3ed ed London, Butterwoths 1990: 408-529.
- Luis LA, Encinas JL, Avila LF: Enfermedad de Hirschsprung: enseñanzas en los últimos 100 casos. *Cir Pediatr* 2006;19:177-181.
- Lurie IW, Supovitz KR, Rosenblum-Vos LS, Wulfsberg EA. Phenotypic variability of del(2)(q22-q23): report of a case with a review of the literature. *Genet Couns.* 1994; 5:11-14.
- Martucciello G, Pini Prato A, Puri P, Holschneider AM, Meier-Ruge W, Jasonni V y col: Controversies concerning diagnostic guidelines for anomalies of the enteric nervous system: a report from the fourth International Symposium on Hirschsprung's disease and related neurocristopathies. *J Pediatr Surg.* 2005 Oct; 40(10):1527-31.
- Mathew A: Anencephaly-Associated Aganglionosis. *Am J Med Genet* 1998; 80:518-520.
- McGaughran J, Sinnott S, Dastot-Le Moal F, Wilson M, Mowat D, Sutton B, Goossens: Recurrence of Mowat-Wilson syndrome in siblings with the same proven mutation. *Am J Med Genet* 2005; 137A:302-304.
- Merkler RC, Solish SB, Scherzer AL: Meningomyelocele and Hirschsprung Disease: Theoretical and Clinical Significance. *Pediatrics* 1985; 76: 299-300.
- Mograbi B, Bocciardi R, Bougert I: The Sensitivity of Activated Cys Ret Mutants to Glial Cell Line-Derived Neurotrophic Factor Is Mandatory To Rescue. *Neuroectodermic Cells from Apoptosis. Mol Cel Biol.*2001; Vol. 21, No. 20:6719-6730.
- Mollaaghababa R, Pavan WJ: The importance of having your SOX on: role of SOX10 in the development of neural crest-derived melanocytes and glia. *Oncogene.* 2003 May 19;22(20):3024-34.
- Mowat DR, Croaker GDH, Cass DT, Kerr BA, Chaitow J, Adès LC, Chia NL, Wilson MJ: Hirschsprung disease, microcephaly, mental retardation, and characteristic facial features: delineation of a new syndrome and identification of a locus at chromosome 2q22-q23. *J Med Genet* 1998, 35:617-623.
- Mowat DR, Wilson MJ, Goossens M: Mowat-Wilson syndrome. *J Med Genet* 2003; 40:305-310.




- Nurgali K, Furness JB, Stebbing MJ. Analysis of purinergic and cholinergic fast synaptic transmission to identified myenteric neurons. *Neuroscience* 2003; 116:335-347.
- Polly T Coran A: Hirschsprung's Disease in the Newborn. *Pediatr Surg Int* 1993; 1: 80-83.
- Pucharcós C, Fuentes JJ, Casas C, de la Luna S, Alcántara S, Arbonés ML, Soriano E, Estivill X, Pritchard M. Alu-splice cloning of human Intersectin (ITSN), a putative multivalent binding protein expressed in proliferating and differentiating neurons and overexpressed in Down syndrome. *Eur J Hum Genet*. 1999 Sep;7(6):704-12.
- Ren J, Bertrand PP. Purinergic receptors and synaptic transmission in enteric neurons. *Purinergic Signal* 2008;4:255-266.
- Romano C Baraitser M Thompson E: A clinical follow-up of British patients with FG syndrome. *Clin. Dysmorph.* 1994; 3: 104-114.
- Sayed M Al-Alaigan S: Agenesis of corpus callosum, hypertrophic Pyloric Stenosis and Hirschsprung Disease: Coincidence or Common Etiology? *Neuropediatrics* 1996; 27: 204-206.
- Scriver CM et al, eds, .2002. "The metabolic and molecular bases of inherited diseases" 8th ed. Chap 251. New York: McGraw-Hill: 6231-55. Volume 2. 8th Edition. McGraw-Hill, 2002ISBN0079130356, 9780079130358. 6338 pp.
- Seuntjens, E., Nityanandam, A., Miquelajauregui, A., Debruyne, J., Stryjewska, A., Goebbels, S., Nave, K.-A., Huylebroeck, D., Tarabykin, V. SIP1 regulates sequential fate decisions by feedback signaling from postmitotic neurons to progenitors. *Nature Neurosci.* 2009; 12: 1369-1376,
- Shahar E Shinawi M: Neurocristopathies presenting with neurologic abnormalities associated with Hirschsprung's disease. *Pediatr Neurol.* 2003 May;28(5):385-91.
- Shimotake T, Tanaka S, Fukui R, Makino S, Maruyama R. Neuroglial disorders of central and peripheral nervous systems in a patient with Hirschsprung's disease carrying allelic SOX10 truncating mutation. *J Pediatr Surg.* 2007Apr;42(4):725-31.
- Silengo M, Ferrero GB, Wakamatsu : Pachygyria and cerebellar hypoplasia in a patient with a 2q22-q23 deletion that includes the ZFHX1B gene. *Am J Med Genet* 2004, 127A:109.
- Spritz RA: Piebaldism, Waardenburg syndrome, and related disorders of melanocyte development. *Semin Cutan Med Surg.* 1997 Mar;16(1):15-23.
- Stevens B.: Neuron-astrocyte signaling in the development and plasticity of neural circuits. *Neurosignals.* 2008;16(4):278-88. Epub 2008 Jul 18.
- Tam PKH: An Immunochemical Study With Neuron-Specific-Enolase And Substance P of Human Enteric Innervation. The Normal Developmental Pattern And Abnormal Deviations in Hirschsprung's Disease And Pyloric Stenosis. *J Pediatr Surg* 1986; 21: 227-232.
- Trainor PA: Specification of neural crest cell formation and migration in mouse embryos. *Semin Cell Dev Biol.* 2005 Dec;16(6):683-93.

- Turkdogan-Sozuer D, Ozek MM, Sehiralti V, Kurtkaya O, Sav A: Hemimegalencephaly and Hirschsprung's Disease: a Unique Association. *Pediatr Neurol* 1998 ;18: 452-455.
- Van de Putte, T., Francis, A., Nelles, L., van Grunsven, L. A., Huylebroeck, D. Neural crest-specific removal of *Zfhx1b* in mouse leads to a wide range of neurocristopathies reminiscent of Mowat-Wilson syndrome. *Hum. Molec. Genet.* 2007; 16: 1423-1436.
- Van de Putte, T., Maruhashi, M., Francis, A., Nelles, L., Kondoh, H., Huylebroeck, D., Higashi, Y. Mice lacking *Zfhx1b*, the gene that codes for Smad-interacting protein-1, reveal a role for multiple neural crest cell defects in the etiology of Hirschsprung disease-mental retardation syndrome. *Am. J. Hum. Genet.* 2003; 72: 465-470,
- Verstappen, G., van Grunsven, L. A., Michiels, C., Van de Putte, T., Souopgui, J., Van Damme, J., Bellefroid, E., Vandekerckhove, J., Huylebroeck, D. Atypical Mowat-Wilson patient confirms the importance of the novel association between *ZFHX1B/SIP1* and NuRD corepressor complex. *Hum. Molec. Genet.* 2008; 17: 1175-1183.
- Volterra A, Meldolesi J. Astrocytes, from brain glue to communication elements: the revolution continues. *Nat Rev Neurosci.* 2005 Aug;6(8):626-40. Review
- Wakamatsu N, Yamada Y, Yamada K, Ono T, Nomura N, Taniguchi H, Kitoh H, Mutoh N, Yamanaka T, Mushiake K, Kato K, Sonta S, Nagoya M. Mutations in *SIP1*, encoding Smad interacting protein-1, cause a form of Hirschsprung disease. *Nat Genet* 2001; 27:369-370.
- Williams C, Lossie A, Driscoll D, and the RC Phillips Unit. Angelman syndrome: mimicking conditions and phenotypes. *Am J Med Genetics* 2001;101:59-64.
- Yamada, K., Yamada, Y., Nomura, N., Miura, K., Wakako, R., Hayakawa, C., Matsumoto, A., Kumagai, T., Yoshimura, I., Miyazaki, S., Kato, K., Sonta, S., Ono, H., Yamanaka, T., Nagaya, M., Wakamatsu, N. Nonsense and frameshift mutations in *ZFHX1B*, encoding Smad-interacting protein 1, cause a complex developmental disorder with a great variety of clinical features. *Am. J. Hum. Genet.* 2001; 69: 1178-1185.
- Yamanaka K, Chun SJ, Boillee S, et al. Astrocytes as determinants of disease progression in inherited amyotrophic lateral sclerosis. *Nat Neurosci* 2008;11:251-253.
- Yang Y, Gozen O, Watkins A, Lorenzini I, Lepore A, Gao Y, Vidensky S, Brennan J, Poulsen D, Won Park J, Li Jeon N, Robinson MB, Rothstein JD Presynaptic regulation of astroglial excitatory neurotransmitter transporter *GLT1*. *Neuron.* 2009 Mar 26;61(6):880-94.
- Zhang W, Segura BJ, Lin TR, et al. Intercellular calcium waves in cultured enteric glia from neonatal guinea pig. *Glia* 2003;42:252-262.
- Zweier C, Albrecht B, Mitulla B, Behrens R, Beese M, Gillessen-Kaesbach G, Rott HD, Rauch A: "Mowat-Wilson" Syndrome with and without Hirschsprung Disease is a distinct, recognizable Multiple Congenital Anomalies-Mental Retardation Syndrome caused by Mutations in the Zinc finger homeobox 1 B gene (*ZFHX1B*). *Am J Med Genet* 2002, 108(3):177-181.

Zweier C, Temple IK, Beemer F, Zackai E, Lerman-Sagie T, Weschke B, Anderson CE, Rauch A: Characterisation of deletions of the ZFH1B region and genotype-phenotype analysis in Mowat-Wilson syndrome. *J Med Genet* 2003, 40:601-605.

IntechOpen

IntechOpen



## **Neuroimaging - Clinical Applications**

Edited by Prof. Peter Bright

ISBN 978-953-51-0200-7

Hard cover, 576 pages

**Publisher** InTech

**Published online** 09, March, 2012

**Published in print edition** March, 2012

Modern neuroimaging tools allow unprecedented opportunities for understanding brain neuroanatomy and function in health and disease. Each available technique carries with it a particular balance of strengths and limitations, such that converging evidence based on multiple methods provides the most powerful approach for advancing our knowledge in the fields of clinical and cognitive neuroscience. The scope of this book is not to provide a comprehensive overview of methods and their clinical applications but to provide a "snapshot" of current approaches using well established and newly emerging techniques.

### **How to reference**

In order to correctly reference this scholarly work, feel free to copy and paste the following:

M<sup>a</sup> Carmen Carrascosa Romero and Carlos de Cabo de la Vega (2012). Neurocristopathies: Role of Glial Cells, Genetic Basis and Relevance of Brain Imaging for Diagnosis, *Neuroimaging - Clinical Applications*, Prof. Peter Bright (Ed.), ISBN: 978-953-51-0200-7, InTech, Available from:  
<http://www.intechopen.com/books/neuroimaging-clinical-applications/neurocristopathies-role-of-glial-cells-genetic-basis-and-relevance-of-brain-imaging-for-diagnosis>

**INTECH**  
open science | open minds

### **InTech Europe**

University Campus STeP Ri  
Slavka Krautzeka 83/A  
51000 Rijeka, Croatia  
Phone: +385 (51) 770 447  
Fax: +385 (51) 686 166  
[www.intechopen.com](http://www.intechopen.com)

### **InTech China**

Unit 405, Office Block, Hotel Equatorial Shanghai  
No.65, Yan An Road (West), Shanghai, 200040, China  
中国上海市延安西路65号上海国际贵都大饭店办公楼405单元  
Phone: +86-21-62489820  
Fax: +86-21-62489821

© 2012 The Author(s). Licensee IntechOpen. This is an open access article distributed under the terms of the [Creative Commons Attribution 3.0 License](#), which permits unrestricted use, distribution, and reproduction in any medium, provided the original work is properly cited.

IntechOpen

IntechOpen