

We are IntechOpen, the world's leading publisher of Open Access books Built by scientists, for scientists

4,800

Open access books available

122,000

International authors and editors

135M

Downloads

Our authors are among the

154

Countries delivered to

TOP 1%

most cited scientists

12.2%

Contributors from top 500 universities



WEB OF SCIENCE™

Selection of our books indexed in the Book Citation Index
in Web of Science™ Core Collection (BKCI)

Interested in publishing with us?
Contact book.department@intechopen.com

Numbers displayed above are based on latest data collected.

For more information visit www.intechopen.com



Landau Kleffner Syndrome: Neuroradiology Aspect

José Guevara Campos¹ and Lucía González Guevara²

¹*Pediatric Service of the Hospital "Felipe Guevara Rojas",
Universidad de Oriente, El Tigre,*

²*Epilepsy and Electroencephalography Unit, El Tigre
Venezuela*

1. Introduction

1.1 Magnetoencephalography

The first recording of electromagnetic fields in the brain, or magnetoencephalography (MEG), were performed in 1968 at the Massachusetts Institute of Technology in Boston, by the David Cohen team, exploring alpha rhythm with the aid of a single sensor machine (Cohen, 1968). In 1972 Cohen again studied alpha rhythm in normal subjects, and response to hyperventilation in a patient with partial complex seizures (Cohen, 1972). Until the mid-eighties, MEG equipment had a single sensor that in practice meant, in addition to spatial limitation of the study, that it was necessary to prolong the studies excessively until it was possible to gather the required data.

Magnetoencephalography, with up to 148 channels, has been more useful in dipole localization and evaluating transcallosal spread than traditional EEG, given the limited channels in the 10-20 system. At present, over hundred MEG installations worldwide contribute to our knowledge about the function and development of the human brain (Pateau, 2002). Most MEG studies have been conducted with adult subjects, but some MEG data already exist on children. Pediatric MEG studies have mainly focused on epilepsy surgery, on the Landau-Kleffner syndrome and related disorders, on sensory cortex properties in progressive myoclonus epilepsies, and on dyslexia.

MEG is a noninvasive technique that measures the magnetic fields generated by intracellular current flow in the dendrites of the pyramidal neurons of the brain cortex. The fluctuations of the magnetic field produced by this flow of current can be recorded from the outside of the scalp and can subsequently be used to locate the cortical generators of that activity with a temporal resolution measured in milliseconds. These characteristics made MEG an invaluable tool to study the brain centers of cognitive functions. The way MEG has served to show that there is a neuronal dynamic neuronal involved in the language process (Pulvermüller, et al., 2003; Wilson, et al., 2005; Pàmmer, et al., 2004) and that measuring the magnetic fields derived from that activity helps to locate the sources of electrical activity in the human brain in a noninvasive manner (Ray & Bowyer, 2010).

Despite being a relatively new technique, MEG is fast becoming an essential tool for clinical physicians, including neurophysiologists, to give an accurate diagnosis. Although the main applications of the technique are found in the area of presurgical evaluation, epilepsy and

brain tumors (Frye,et al.,2009), especially in the functional localization of epileptic focus, another condition in for which it may be useful include autism (Roberts,et al.,2008), stroke vascular, (Tecchio,et al.,2007) schizophrenia,(Rutter,et al.,2009) Parkinson's disease (Stoffers,et al.,2008) and language disorders.

The integration of MEG with other functional techniques such as PET (positron emission tomography, SPECT (single photon emission computed tomography) and fMRI (functional magnetic resonance) and MRS (magnetic resonance spectroscopy) has been an important contribution to increasing our knowledge of the biologic substrates of the various neurocognitive process and shows the importance of certain areas determine in behaviors. However, these techniques fail to provide information on the functional organization paths of the neuronal networks involved in cognition (Del Rio,et al., 2005).

The capacity of MEG to define the epileptogenic area and its propagation paths has been confirmed by validating the data obtained by using that technique with those obtained by means of electrocorticography or recording made with intracranial electrodes (Del Rio,et al.,2005).

Once of the aspects in which MEG can more quickly define its contributions are without and doubt its application to presurgical study of patients with epilepsy resisted to medical treatment (Shibasaki,et al., 2007).

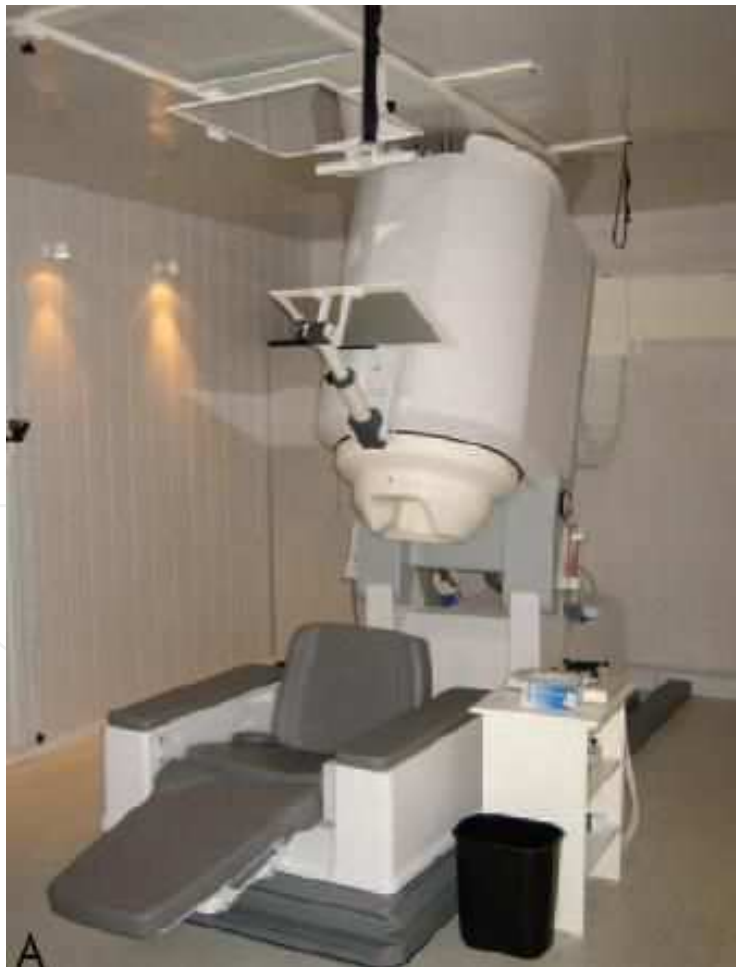

Fig. 1. A, Biomagnetometer in a electrically shielded room. Patients can be comfortably studied in a seated or supine position.

MEG's special sensitivity towards the currents discharges in the cerebral sulci and fissures have fostered the study of patients with Landau-Kleffner syndrome, for whom an epileptogenic area is proposed in the persylvian region. In these patients, MEG has had an important role for the selection of patients who are candidates to multiple subpial transection treatment (Pateau, et al., 1999).

The contribution of MEG to epilepsy surgery does not simply lie in more accurate or exact definition of the epileptogenic area alone, but, in addition, MEG contributes non-invasive alternatives to locate eloquent cortex area that must be preserved during a surgical procedure (Sibasaki, et al., 2007).

1.2 Basic principles of MEG

A moving electric charge is always associated with an electric field and concomitant magnetic field surrounding the axis movement (fig 2a). Electroencephalogram (EEG) and MEG signals are believed to reflect synchronous postsynaptic currents in thousands of parallel apical dendrites. Despite being ultimately due to the same primary currents, EEG and MEG signals differ at some important points (Paetau, 2002). First, only tangential currents, parallel to the head surface, give rise to an extracranial magnetic field. Because the apical dendrites typically run perpendicular to the cortex surface, MEG signals mainly arise in fissure walls (fig 2b). The EEG signals, on the other hand, are dominated by radial currents, while the tangential ones may require signal averaging to be detected. The complementary sensitivity to current warrants combined use of EEG and MEG whenever possible. Second, in homogeneous tissue conductivity of the human head tends to spread out the signal, but does not alter the magnetic fields. Therefore, tumors, cysts, calcified lesions and skull defects cause less distortion on MEG than EEG signals (Vander, et al., 1998). Third, signal attenuation in EEG is caused by poorly conducting tissue, while the magnetic field fades off proportionally to the second power of the distance from the source. Infant and persons with small heads should preferably be studied with systems composed of two part-head devices adjustable according to the head size or with specially designed baby devices. Fourth, different practical problems hamper data acquisition. MEG sensors are in a rigid helmet and the head as to be kept immobile with respect to the helmet. Long Term recordings or recordings of major motor seizure areas are far not possible with MEG, but continuous monitoring of the head position may offer relief to some of the movement problems. Finally, MEG and EEG have partly differing artifact profiles: MEG is less sensitive to muscle artifacts than EEG. On the other hand, magnetic materials moving with respiration (Traces from craniotomy drills, some shunt materials, tooth braces, cochlear implants, etc) may cause serious artifacts or even destroy the MEG data.

1.3 MEG in acquired epileptiform regression syndromes

Acquired epileptic regression syndromes are disabling childhood disorders, where a previously healthy child deteriorates over a week to months. The children may or may not show overt seizures, but their EEG usually displays almost continuous epileptiform spike and wave activity, especially during sleep. In acquired epileptic aphasia or the Landau-Kleffner syndrome (Landau, 1957), the regression affects receptive language and/or auditory perception. Epileptiform spike-and wave discharges appear during the first few weeks, and have been proposed to be causally related to cognitive disability. Some LKS children develop giant auditory N100m response with similar auditory cortex sources and

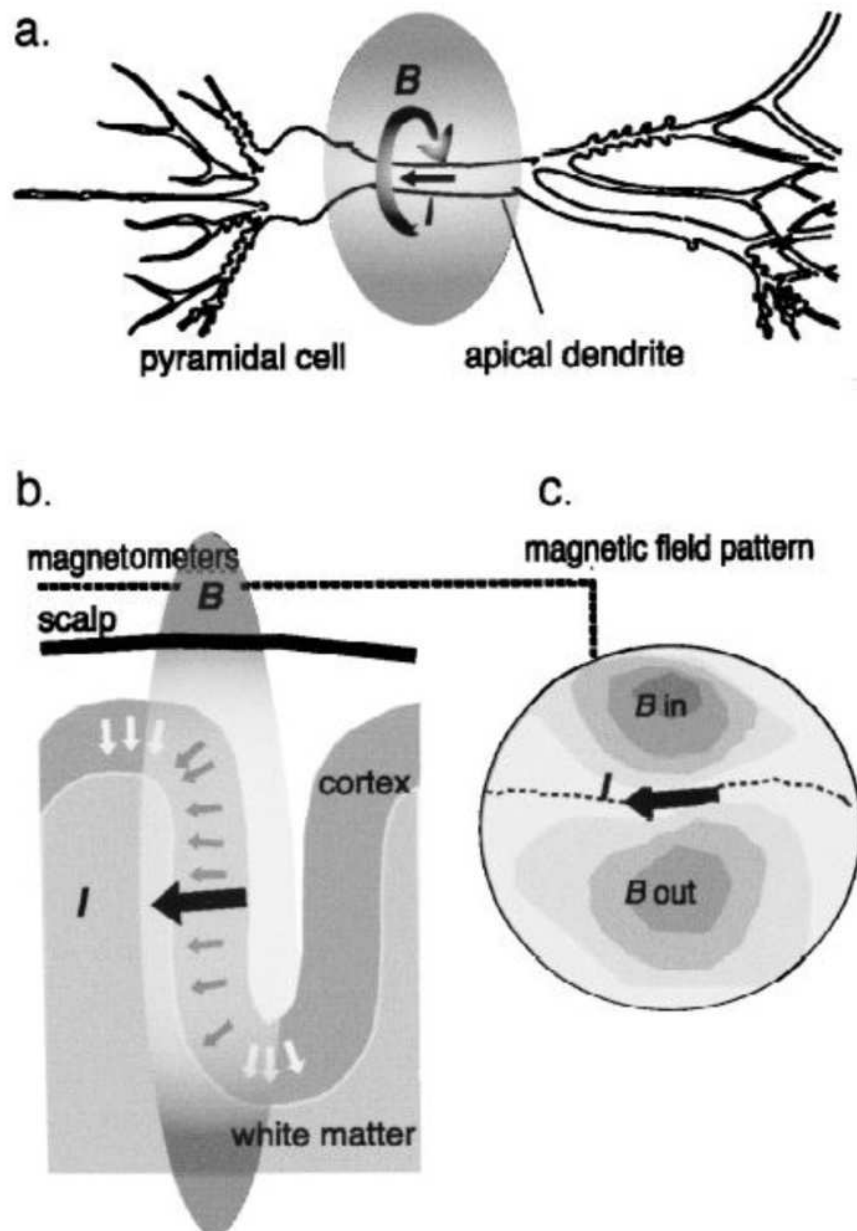


Fig. 2. Physical basis of MEG signals. (a) The intracellular current I in the apical dendrite of a pyramidal cell is associated with a surrounding magnetic field B . (b) In the brain, pyramidal cells typically are perpendicular to cortex surface, and may be radial (white arrows), oblique or tangential (dark arrows) to the scalp. Only the tangential currents and the tangential component of oblique currents contribute to the extracranial magnetic field, which can be detected by sensitive SQUID magnetometers. (c) Dipolar magnetic field pattern viewed above. B in indicates the magnetic flux into the head and B out the flux out from the head. An equivalent current dipole (ECD; the thick black arrow) represents the concerted action lines of all fissural dipoles. Its orientation is parallel to the isofield lines and it is located underneath the steepest gradient halfway between the in- and out-flowing flux. Its depth determines the distance between the two extremes, and its strength is proportional to the number of active pyramidal cells.

reactivity as the normal N100m, but with morphology and amplitude identical to the patient's epileptic spikes (Pateau, 2002). LKS Patient's verbal auditory agnosia can, therefore, be understood as local epilepsy of the auditory cortex, activated by sounds. MEG alone or combined with EEG has proved useful in identifying the sources of epileptic activity in LK, as well as in childhood epileptic autistic regression disorders (Sobel et al., 2000; Muñoz Yunta et al., 2008).

2. Landau-Kleffner syndrome

In 1957 Landau and Kleffner described six children with acquired aphasia syndrome and epileptic seizures with encephalographic alterations (Landau, 1957). The syndrome had two basic symptoms: on the one hand an acute or sub-acute acquired aphasia in previously normal children, and on the other, a paroxysmal encephalographic plot with spikes and waves more frequently located in region temporal region that may reach an epileptic stage during the slow stage. Convulsive seizures, if shown come before or follow the beginning of the slow speech impairment but these epileptic discharges in the electroencephalogram are invariably present (Guevara Campos & González Guevara, 2007). It may be accompanied by behavior or demeanor disorders, such as hyperactivity, expression of aggressive, rebelliousness and autistic features.

The etiology of the LKS is unknown. Although encephalitis has been proposed as an etiology, some of empirical evidence has raised doubts. For example, the course of LKS is very different from that of Rasmussen chronic encephalitis and temporal lobectomy histology in two cases of LKS was not consistent with encephalitis (Rasmussen & Mc Cann 1968; Coke et al., 1988). Based on the results of conventional angiography in some patients with LKS, Pascual-Castroviejo (Castroviejo et al., 1992) proposed vasculitis as an etiology. These investigators treated patients with calcium blockers with a favorable response. Others have considered whether an underlying autoimmune mechanism may contribute to the pathogenesis of LKS give the fact autoimmune processes may be involved in the pathogenesis of child development disorders and epilepsy (Nesimalova et al., 1992). This idea is supported by Connolly (Connolly et al., 2006). Who reported an increase in IgM autoantibodies to endothelial cells and IgG autoantibodies to myelin basic protein as compared to healthy controls. A small number of brain lesions have been reported in association with the LKS, including neurocysticercosis (Bhatia et al., 1994), toxoplasmosis (Michalowiec et al., 1989), temporal lobe astrocytoma (Solomon et al., 1993), and temporal lobe glioma (Solomon et al., 1993). The increased risk of LKS in monozygotic twins and siblings suggests a genetic etiology (Feekery et al., 1993). Thus, it is very likely that the etiology of the LKS is variable with several etiologies. It would be useful to classify LKS as cryptogenic or symptomatic. The cause of epilepsy and continuous aphasia still remains a mystery (Deonna, 1991).

3. Clinical manifestations

3.1 Aphasia

Single photon emission computed tomography imaging demonstrated hypometabolism in 22 of his 25 patients (O'Regan et al., 1998), suggested that aphasia occurs as a manifestation of a hypometabolic encephalopathy secondary to a local postictal state (O'Regan et al., 1998). Positron emission tomography has shown dynamic changes in the metabolism of glucose in

the temporal lobe during episodes of aphasia (Luat, et al., 2006). Temporary changes in the positron emission tomography images suggest that the metabolism of glucose in LKS cannot be attributed only to the epileptiform interictal activity (Luat, et al., 2006).

MEG offers the possibility to study the organization of the neuronal networks involved in language processes and shows with high precision, and in a noninvasive fashion, the spatial and temporal patterns of brain activity related to this cognitive function in order to determine the neurocognitive reorganization of language in several diseases such as aphasia or epilepsy, and the relationship of this functional reorganization to behavioral language problems (Ortíz et al., 2009).

Although aphasia is present in all patients, it constitutes the first manifestations in only half. Its onset may be abrupt or progressive over several days or weeks (Guevara Campos, et al., 1989). Typically, the aphasia is receptive; the child begins to have difficulty understanding language to the point that deafness may be suspected. The capacity for oral expression gets impaired quickly; mutism is frequent. Non-verbal skills are usually preserved, thereby allowing sign language to be used for some degree of communication. Writing is preserved in older children (Deonna, 1991). The integrity of the thalamic auditory pathways is confirmed by normal brainstem potentials. Alterations in the evoked cortical latencies support posterior temporal region dysfunction (Zouari & Choyakh, 1997).

Expressive aphasia was present in two of the original Landau-Kleffner patients (Landau & Kleffner, 1957), and 6 of the 77 cases studied by Dugas, (Dugas, et al., 1992). A detailed study of aphasia shows that it is possible to find virtually every type, including semantic pragmatic disorders (Paquier, et al., 1992).

The course of the aphasia found in the LKS is one of its most disconcerting characteristics. A relationship between one age of onset and the long term results has been reported: the younger the child, the worse the prognosis for the recuperation of speech. The effects are devastating in young children that have not yet developed linguistic abilities since the cortical mechanisms to process speech cannot develop. In older children, the effects are less serious because they have already learned language (Bishop, 1985). In general, total recovery is very difficult, and variable difficulties persist in oral communication in most cases. Non-verbal communication can be unaffected, but there is the possibility that it may not be even when it is present (Baynes, et al., 1998).

3.2 Epilepsy

Most researchers support the hypothesis that paroxysmal activity produces a functional disconnection of the cortical areas related to speech. The exact origin of epileptic activity has been shown through brain mapping techniques. Paroxysms have been shown to be located in the depths of Sylvian fissure through dipole modeling (Nakano, et al., 1989). This is supported by results of positron emission tomography, single photon emission computed tomography and magnetoencephalography studies (Baumgartner & Pataraira, 2006).

MEG and EEG record synchronous postsynaptic currents in thousands of cortical pyramidal cell apical dendrites, with a temporal resolution at the level of the millisecond. Although EEG reflects cortical currents of all orientations, MEG is mainly sensitive to fissure currents and, therefore, provides an optimal method to identify the fissure generators of LKS spikes. During a single spike-wave complex, spike propagation from a fissure wall to the adjoining convexity can take between 10 and 30 ms, and propagation time between left and right perisylvian areas is similar. Both MEG and EEG can differentiate between primary

(independent) spike foci and secondary spikes (Paetau, 2009) MEG and EEG are necessary for the spatial and temporal understanding of the perisylvian region and epileptic networks in Landau -Kleffner syndrome.

The 4 potential roles for MEG in the localization of the ictal onset zones (IOZ) and functional cortex: 1) MEG confirmations of localization based on traditional noninvasive methods, allowing epilepsy surgery to proceed without long term intracaneal EEG monitoring; 2) MEG demonstration of bilateral, multifocal, or diffuse ictal onset, indicating an unfavorable candidate for epilepsy surgery; 3) MEG locations adjacent to or distant from that of traditional methods or focally, when traditional methods suggest multifocal activity, potentially altering clinical decision making regarding epilepsy surgery; and 4) MEG localization of eloquent cortex to guide surgical trajectory. These data will serve to refine prospective studies on the optimal use of MEG in the localization of the IOZ and functional cortex in children with treatment-resistant epilepsy (Schawartz, et al., 2008).

Epileptic seizures constitute the first manifestation in approximately half the cases of LKS. Beaumanoir (Beaumanoir, 1992) found that nightly partial seizures were most common, followed by generalized tonic-clonic, atypical absences and, rarely, myoclonic absences. Extremely rare cases have been reported of partial complex seizure patients with automatism (Deonna, 1991; Guevara Campos et al., 1989). Clinical seizures only appear in around 70% of the patients. A third of clinical seizure patients have isolated single seizures. Status epilepticus occurs in some (Hirsch, et al., 1990). Seizures are not very frequent in patients between the ages of 5 to 10 years of age (Pablo, et al., 2002) After the age of 10 years old, only one fifth of the patients experiences sporadic seizures. Seizures rarely persist in older adolescence. (Guevara Campos, et al., 1989)

In most cases, monotherapy with anti-epileptic is effective to control the seizure but not the aphasia (Deonna, 1991). In most the patients, no close relationship is established between the frequency of the seizures and the degree aphasia, which can be serious even in absence of seizures (Guevara Campos & González Guevara, 2007). Seizures almost always disappear in adulthood, although rare cases have been reported in the literature or refractory epilepsy that persists until adulthood (Beaumanoir, 1992).

3.3 Paroxysmal alterations of the EEG

The behavioral and cognitive alterations characteristic of patients with LKS are believed to be secondary to epilepsy rather than structural damage to the central nervous system. The affirmation is based on the fact that frequent and intense epileptic discharges are focally located in language areas important for speech and the fact recovery, either spontaneous or induced by treatment, is always associated with the disappearance of EEG paroxysmal activity (Guevara Campos & González Guevara, 2007).

In the theory of the pathogenic mechanisms that lead to the LKS syndrome there is general consensus on the epileptiform discharges normally active in the non REM sleep stage and the regression of speech. The spikes on the electroencephalograms are usually temporal, central-temporal or bilateral parietal-occipital and synchronous. Experiences with brain injuries have shown that a healthy hemisphere is sufficient to acquire normal speech. Therefore, the regression of speech in LKS suggests a bilateral dysfunction of the auditory cortex and related speech cortex, both hemisphere having independent epileptic injuries or a unilateral injury that induces the functions paralysis of the healthy hemisphere due to bombarding of epileptic discharges through commissural injuries (Paetau, 2009).

Magnetoencephalography detect extra-cranial magnetic fields. Spike generated in the perisylvian convexities are detected only with the EEG, while the spikes generated by the intrasylvian region are selectively seen by MEG. The spike generated by EEG and the MEG are detected by using equivalent dipoles that represent the cortical activity of the pyramidal neurons in the cortex. MEG localizes 1-2-cm generated cortical spikes with spatial precision and a one millisecond resolution.

MEG studies that, in approximately 80% of LKS patients, epileptic discharges are bilateral and are generated in the auditory and speech cortex, and are related. Approximately 20% of children with LKS have a unilateral pacemaker in the perisylvian region that triggers the secondary bilateral synchrony of the spikes. This 20% could recover the speech ability after performing a supial intracortical transaction in the pacemaker (Paetau, 2009).

EEG abnormalities are present in all patients. The background rhythms are usually normal, but theta slowing is occasionally present in the same regions as the spike. Spike paroxysms or spike and wave complexes can be unilateral or bilateral and may be focal, multifocal or diffuse (Beaumanoir, 1992). Discharges are bitemporal in 50% of the patients and in the parietal-occipital regions in 30% of the patients. Discharges are usually active by sleep. Paroxysms are frequently similar to those found in Benign Rolandic Epilepsy. There is a clear activation of the epileptiform activity in Rolandic epilepsy during sleep that can transform into continuous spike and wave. In such patients the sleep index never reaches 85% (Deonna, 1991). Most of the foci are localized to the temporal or temporal central region and are more commonly found in the left hemisphere.

Bilateral foci are frequent (Beaumanoir, 1992); they tend increase by more than 85% during sleep and can transform into continuous spike and wave sleep (CSWS) or electrical status epilepticus during slow sleep (ESES). The term CSWS is used synonymously with that ESS. The discharges in ESES are located in the frontal or frontocentral region, while they tend to be located in the temporal or parietal areas in LKS. The seizures seen in patients with ESES are similar to the ones of LKS, but drop, myoclonic and unilateral clonic seizures may be more common. The nature of the cognitive deterioration is more diffuse in ESES than in LKS. The correlation between the EEG paroxysmal activity and the neuropsychological deficits supports the opinion that these are a direct result of the epileptic process, thus permitting the consideration that both LKS and ESES syndrome belong to the group epileptic encephalopathies (Aicardi, 1999).

Hyperventilation and photostimulation activation maneuvers are rare positive. The disappearance of the spike and wave complexes in sleep fortells the improvement of aphasia and it may be a good index of the efficacy of treatment (Li et al., 1996). However, neither full nor partial recovery of aphasia is ever noted before CSWS disappears (Aicardi, 1999).

The EEG constitutes the basic tool to follow up on anti-epileptic therapy aimed at suppressing the marked paroxysmal alterations shown in the EEG, most specially the activity of the CSWS (Li et al., 1996).

3.4 Behavioral changes

Behavioral changes are extremely common in patients with LKS (Dugas, et al., 1992). These include hyperkinesias, outburst of wrath, rebelliousness and aggressive expressions. Some of these behaviors may be related to the frustration associated to speech difficulties. Autistic features and autism with all its components are very frequent and in some cases, they can even control the clinical manifestations (Nesimalova, et al., 1992). Hyperkinesia is usually

described as psychomotor disorder; hyperkinesia and slight verbal auditory agnosia occurs in the early stages of LKS; it can be mistaken for cases of attention deficit with hyperkinesia. Personality disorders, aggressiveness and depression are also evident (Guevara Campos & González Guevara, 2007). Neville (Neville, et al., 1998) have pointed out the fact that many children with LKS show various degrees of motor disorder. Thirteen out a total of 30 children with LKS showed moderate motor disorders expressed as clumsiness, slowness and imprecise movements with six showing serious dysfunctions (Neville, et al., 1998).

4. Diagnostic studies

In general diagnostic research has not clear defined the etiology of LKS. In a child with language regression or apparent deafness, it is mandatory to perform an EEG that includes a recording during extended sleep (Aicardi, 1999). Neither the evoked potentials nor auditory test have contributed useful data for diagnosis (Zouari & Choyakh, 1997; Pablo et al., 2002). The analysis of cerebral fluid is almost always normal, although case in which a slight elevation of total protein has been reported (Perniola, et al., 1993). Axial computer tomography and magnetic imaging are always normal, although non-specific finding, such as white matter changes or structural damage, have been reported (Perniola, et al., 1993). In a small number of patients single photon emission computed tomography and positron emission tomography have revealed perfusion and glucose metabolism abnormalities in the temporal lobes (Luat, et al., 2006; Guerreiro, et al., 1996; Da Silva et al., 1997). There have been case report about the use of MEG in patients with LKS (Sobel, et al., 2000). Magnetoencephalography can provide excellent pre-surgery localization of epileptiform activity as well as functional language mapping if surgical treatment, such as multiple subpial transection, the role MEG in evaluating patients with epilepsy continues to evolve. MEG is sensitive to epileptic activity originating from depths of sulci, such as the fissure, because it reveals magnetic fields generated by transmembrane synaptic currents oriented in a plane tangential to the skull surface (Seppo, et al., 2010). The precise locations afforded by MEG compared with EEG can sometimes obviate the need for invasive video EEG recording as well as direct the placement of intraoperative electrodes when surgery is being considered for patients with medically intractable epilepsy, Specially, for patients with LKS, MEG is useful in confirming the diagnosis and may prove useful in preoperative localitation if subpial intracortical trasction becomes widely accepted for the treatment of intractable cases. Magnetoencephalography has added valuable data in presurgical planning in determining the location of the dominant focus along and within the sylvian fissure during secondary discharges see in CSWS (Smith, 2004).

5. Conclusions

MEG and EEG are fundamentally different functional magnetic resonance imaging (fMRI), positron emission tomography (PET) or other anatomical imaging methods, where the spatial resolution is based on voxel size. The most important advantage of MEG and EEG over any present functional imaging modality is their submillisecond temporal resolution. At present, MEG provides the most efficient single tool for real time tracking of distributed brain activities during a number of cognitive tasks or epileptic discharges. The MEG finding have impacted patient management in nearly every case and have been universally accepted by pediatric neurologist and pediatric neurosurgeon as beneficial for their patients.


Specially, these benefits include substantiated decisions not to offer surgical resection, decisions to move ahead with intracranial grid placements; and lesion detection in the setting of nonlesional structural imaging.

6. References

- Aicardi J, (1999) Landau-Kleffner syndrome. *Rev Neurol* 29:380-385.
- Baumgartner C, Pataraira E. (2006) Revisiting the role of magnetoencephalography in epilepsy. *Curr Opin Neurol* 19:181-186.
- Baynes K, Kegel J.A, Brentari D, Kussmaul C, Poizner H (1998) chronic auditory agnosia following Landau-Kleffner syndrome: a 23 year outcome study. *Brain Lang* 63:381-425.
- Beaumanoir A (1992) The Landau-Kleffner syndrome, in: *Epileptic Syndromes in Infancy, Childhood and Adolescence*, Roger J, Bureau M, Dravet C, Dreifuss FE, Perret A, Wolf P, 213-243. John Libbey, London.
- Bhatia M.S, Shome S, Chadda P.K and Saurabh II (1994) Landau-Kleffner syndrome in cerebral cysticercosis. *Indian Pediatr* 31: 584-587.
- Bishop D.V, (1985) Age of onset and outcome in “acquired aphasic with convulsive disorders” (Landau-Kleffner syndrome). *Dev Med Child Neurol* 27:705-712.
- Castroviejo-Pascal I, López Martin V, Martinez Bermejo A and Pérez-Higueras A (1992) Is cerebral arteritis the cause of Landau-Kleffner syndrome? Four cases in childhood with angiographic study. *Cann J Neurol Sci* 19: 46-52.
- Cohen D (1968) Magnetoencephalography: evidence of magnetic fields produced by alpha rhythm current. *Science* 161: 784-786.
- Cohen D (1972) Magnetoencephalography: detection of the brain’s electrical activity with a superconducting magnetometer. *Science* 175: 664-666
- Coke A.J, Andermann F, Taylor L (1988) The Landau-Kleffner syndrome of acquired aphasia: unusual clinical outcome, surgical experience, and absence of encephalitis, *Neurology* 38:31-38.
- Connolly A.M, Chez M,, Streif E.M (2006) Brain derived neurotrophic factor and autoantibodies to neural antigens in serum of children with autistic spectrum disorders, Landau-Kleffner syndrome, and epilepsy. *Biol Psychiatry* 59:354-363.
- Da Silva E, Chugani D, Muzik O, Chugani H (1997) Landau-Kleffner syndrome: metabolic abnormalities in temporal lobe are a common feature. *J Child Neurol* 12:489-495.
- Del Rio, Santiuste M, Capilla A, Maestú F, Campo P, Fernández Lucas A, Ortiz T (2005) Bases neurológicas del lenguaje. Aportaciones desde la magnetoencefalografía. *Rev Neurol* 41: 109-114.
- Deonna T.W (1991) Acquired epileptiform aphasia in children (Landau-Kleffner Syndrome), *J Clin Neurophysiology* 8: 288-298.
- Dugas M, Manson M, Le Heuzey M F, Regnier N (1992) Childhood acquired aphasia with epilepsy (Landau-Kleffner syndrome), 12 personal cases. *Rev Neurol (Paris)* 138:817-823.
- Feekery C.J, Parry-Fielder B and Hopkins I.J (1993) Landau-kleffner syndrome six patients including discordant monozygote twins. *Pediatr Neurol* 9: 49-53.
- Frye RE, Rezaie R, Papanicolaou AC (2009) Functional neuroimaging of Language using Magnetoencephalography. *Phys Life Rev* 6(1):1-13.
- Guerreiro M.M, Camargo E, Kato M (1996) Brain single photon emission computed tomography imaging in Landau-Kleffner syndrome. *Epilepsia* 37:60-67.

- Guevara Campos J, Guevara González L, and Dravet Ch (1989) Síndrome de Landau-Kleffner. *Rev Fund José Ma Vargas* 13:14-16.
- Guevara Campos J, González de Guevara L (2007) Síndrome de Landau-Kleffner: análisis de 10 Casos en Venezuela, *Rev Neurol* 44(11):652-656.
- Guevara Campos J, González Guevara L (2007) Landau-Kleffner syndrome. *J Pediatr Neurol* 5:93-99.
- Hirsch E, Marescaux C, Maquet P (1990) Landau-Kleffner syndrome: a clinical and EEG study of five cases. *Epilepsia* 31:756-767.
- Landau W and Kleffner F (1957) Syndrome of acquired aphasia with convulsive disorder in children. *Neurology* 7: 523-530.
- Li M, Hao XY, Qing J, Wu R (1996) Correlation between CSWS and aphasia in Landau-Kleffner syndrome: a study of three cases. *Brain Dev* 18:197-200.
- Luat A.F, Chuagani H.T, Asano E (2006) Episode receptive aphasia in a child with Landau-Kleffner syndrome: PET correlates. *Brain Dev* 28: 592-596.
- Michalowiez R, Jozwiak S, Szwabwska-Orzeszo E, Ignatowicz L and Ignatowicz R (1989) Landau-Kleffner *Wiad Lek* 42: 256-259.
- Muñoz-Yunta JA, Ortiz T, Palau- Badell M, Martín -Muñoz L, Salvadó-Salvadó B, Valls-Santasusana A (2008) Magnetoencephalographic pattern of epileptiform activity in children with early -onset autism spectrum disorders. *Clin Neurophysiol* 119: 626-34.
- Nakano S, Okuno T, Mikawa H. (1989) Landau Kleffner syndrome: EEG topographic studies. *Brain Dev* 11:43-50.
- Nesimalova S, Tauberova A, Doutilik S, Kucera V and Diouha O (1992) A role of autoimmunity in the etiopathogenesis of Landau- Kleffner syndrome? *Brain Dev* 14: 342-345.
- Neville B, Burch V, Cass H (1998) Motor disorder in Landau-Kleffner syndrome. *Epilepsia* 39:123 A.
- O'Regan M.E , Brown J.K, Geodiwin G.M and Clark M (1998) Epileptic aphasia: a consequence of regional hypometabolic encephalopathy? *Dev Med Child Neurol* 40: 508-516.
- Ortiz T, Palau- Baduel M, Salvadó-Salvadó B, Valls-Santasusana A (2009) Estudio de los trastornos del espectro autista y trastornos del lenguaje mediante magnetoencefalografía. Aportación científica del Dr. Muñoz Yunta. *Rev Neurol* 48(2):3-12.
- Pablo MJ, Valdizán JR, Carvajal P (2002) Landau-Kleffner syndrome. *Rev Neurol* 34:262-264.
- Paetau R, Granstom ML, Blomstedt G, Jousmaki V, Korkman M, Liukkone E (1999) Magnetoencephalography in presurgical of children with the Landau-kleffner syndrome *Epilepsia* 40: 326-335.
- Paetau Ritva (2002) Magnetoencephalography: in pediatric neuroimaging. *Developmental Science* 5:3,361-370.
- Paetau Ritva, (2009) Magnetoencephalography in Landau-Kleffner syndrome. *Epilepsia* 50:51-54.
- Pammer K, Hansen PC, Kringelbach ML, Holliday I, Barnes G, Hillebrand A (2004) Visual word recognition: the first half second. *Neuroimage* 22: 1819-25.
- Paquier. P.F Van Dongen H.R and Loonen C.B (1992) The Landau Kleffner syndrome acquired aphasia with convulsive disorder Long-term follow-up of six children and review after the recent literature. *Arch Neurol* 49:354-359.

- Perniola T, Margari L, Buttiglione M, Andreula C, Simone I, Santostasi R (1993) A case of Landau-Kleffner syndrome secondary to inflammatory demyelinating disease. *Epilepsia* 34:551-556.
- Pulvermuller F, Shtyrov Y, Ilmoniemi R (2003) Spatiotemporal dynamics of neural language processing: an MEG study using minimum -norm current estimates. *Neuroimage* 20: 1020-1025.
- Rasmussen T and Mc Cann W (1968) Clinical studies of patients with focal epilepsy due to chronic encephalitis, *Trans Am Neurol* 93: 89-94.
- Ray A, Bowyer SM (2010) Clinical applications of magnetoencephalography in epilepsy. *An Indian Acad Neurol* 13(1): 14-22.
- Roberts T.P, Schmidt G.L, Egeth M, Blaskey L, Rey M.M, Edgar J.C, Levy S.L (2008) Electrophysiological signatures: magnetoencephalography studies of the neural correlates of language impairment in autism spectrum disorders. *Int J Psychophysiol* 68:149-80.
- Rutter L, Carver F.W, Hoiroyd T, Nadare S.R, Mitchell-Francis J, Apud J,(2009) Magnetoencephalography gamma power reduction in patients with schizophrenia during resting condition. *Hum Brain Mapp* 30: 3254-64.
- Schwartz E.S, Dlugos D.J, Storm P.B, Dell J, Magee R, Flynn T.P, Zarnow D.M, Zimmerman R.A, Roberts TPL (2008) Magnetoencephalography for Pediatric Epilepsy: How We Do It. *Am J Neuroradiol* 29:832-837.
- Seppo P, Ahlfors Jooman Han, John W. Belliveau, Matti S. Hamalainen (2010) Sensitivity of MEG and EEG to Source Orientation. *Brain Topogr* 23:227-232.
- Shibasaki H, Ikeda A, Nagamine T (2007) Use of magnetoencephalography in presurgical evaluation of epilepsy patients. *Clin Neurophysiol* 118: 1438-48.
- Smith M (2004) The utility of Magnetoencephalography in the evaluation of secondary bilateral synchrony: A case report. *Epilepsia* 45:57-60.
- Sobel DF, Aung M, Otsubo H, Smith MC(2000) Magnetoencephalography in children with Landau- Kleffner syndrome and acquired epileptic aphasia. *Am J Neuroradiol* 21: 301-307.
- Solomon G.L, Carson D, Pavlaskis S, Fraser R and Labar D (1993) Intracranial EEG monitoring in Landau- Kleffner syndrome associated with a left temporal lobe astrocytoma. *Epilepsia* 34: 557-560.
- Stoffers D, Bosboom JL, Deijen JB, Wolters ECh, Stam CJ, Berendse HW (2008) Increased cortico cortical functional connectivity in early-stage Parkinson's disease: an MEG study. *Neuroimage* 41:212-22.
- Tecchio F, Zappasodi F, Tombini M, Caulo M, Vermieri F, Rossini PM (2007) Interhemispheric asymmetry of primary hand representation and recovery after stroke: a MEG study. *Neuroimage* 36: 1057-64.
- Vander Broek S, Reinders F, Donderwinkel M, Peters M (1998) Volume conduction effects in EEG and MEG. *Electroencephalography and Clinical Neurophysiology* 106: 522-534.
- Wilson T.W, Leuthold A.C, Lewis S.M, Georgopoulos A.P, Pardo P.J (2005) The time and space of lexicality : a neuromagnetic view. *Exp Brain Res* 162: 1-13.
- Zouari N, Choyakh F (1997) Early middle latency and late auditory evoked potentials a case of acquired epileptic aphasia (Landau-Kleffner syndrome). *Rev Laryngol Otol Rhinol* 118:267-270.



Neuroimaging - Clinical Applications

Edited by Prof. Peter Bright

ISBN 978-953-51-0200-7

Hard cover, 576 pages

Publisher InTech

Published online 09, March, 2012

Published in print edition March, 2012

Modern neuroimaging tools allow unprecedented opportunities for understanding brain neuroanatomy and function in health and disease. Each available technique carries with it a particular balance of strengths and limitations, such that converging evidence based on multiple methods provides the most powerful approach for advancing our knowledge in the fields of clinical and cognitive neuroscience. The scope of this book is not to provide a comprehensive overview of methods and their clinical applications but to provide a "snapshot" of current approaches using well established and newly emerging techniques.

How to reference

In order to correctly reference this scholarly work, feel free to copy and paste the following:

José Guevara Campos and Lucía González Guevara (2012). Landau Kleffner Syndrome: Neuroradiology Aspect, Neuroimaging - Clinical Applications, Prof. Peter Bright (Ed.), ISBN: 978-953-51-0200-7, InTech, Available from: <http://www.intechopen.com/books/neuroimaging-clinical-applications/landau-kleffner-syndrome-neuroradiology-aspect>

INTECH
open science | open minds

InTech Europe

University Campus STeP Ri
Slavka Krautzeka 83/A
51000 Rijeka, Croatia
Phone: +385 (51) 770 447
Fax: +385 (51) 686 166
www.intechopen.com

InTech China

Unit 405, Office Block, Hotel Equatorial Shanghai
No.65, Yan An Road (West), Shanghai, 200040, China
中国上海市延安西路65号上海国际贵都大饭店办公楼405单元
Phone: +86-21-62489820
Fax: +86-21-62489821

© 2012 The Author(s). Licensee IntechOpen. This is an open access article distributed under the terms of the [Creative Commons Attribution 3.0 License](#), which permits unrestricted use, distribution, and reproduction in any medium, provided the original work is properly cited.

IntechOpen

IntechOpen