

# We are IntechOpen, the world's leading publisher of Open Access books Built by scientists, for scientists

**4,800**

Open access books available

**122,000**

International authors and editors

**135M**

Downloads

Our authors are among the

**154**

Countries delivered to

**TOP 1%**

most cited scientists

**12.2%**

Contributors from top 500 universities



**WEB OF SCIENCE™**

Selection of our books indexed in the Book Citation Index  
in Web of Science™ Core Collection (BKCI)

Interested in publishing with us?  
Contact [book.department@intechopen.com](mailto:book.department@intechopen.com)

Numbers displayed above are based on latest data collected.

For more information visit [www.intechopen.com](http://www.intechopen.com)



# Vascular Endothelial Growth Factor (VEGF) and Epidermal Growth Factor (EGF) in Papillary Thyroid Cancer

Aleksander Konturek and Marcin Barczynski  
*Department of Endocrine Surgery  
Jagiellonian University College of Medicine, Kraków  
Poland*

## 1. Introduction

Early diagnosis and radical management of thyroid cancer do not always result in curing the patient. Long-term analyses of deaths due to thyroid cancer have allowed for establishing systems for distinguishing increased risk groups, such as AMES or AGES. These commonly employed prognostic systems recognize the role of four basic factors only (age, stage, extent of the tumor, its size [AGES] and metastases [AMES]), which constitute the foundation for establishing the low and high-risk groups. Despite the progress in oncology and oncological surgery, a major problem still lies in early cancer detection, when the tumor is still at a stage that allows for curing the patient, as well as in identifying individuals, in whom - despite radical treatment - the prognosis of a complete cure is poor and there is an increased risk of a local recurrence and death due to the cancer.

## 2. Epidemiology of papillary thyroid carcinoma

Papillary thyroid carcinoma accounts for the majority of thyroid cancers and is commonly believed to be the least malignant type. In Europe and the United States, it presently constitutes approximately 75-80% of all diagnosed thyroid cancers [1]. It is characterized by a mild clinical course and a slow growth rate. The tumor is detected in young individuals (usually before they turn 40 years of age) and is 2-3 times more common in females. As a rule, it is a multifocal disease (in 60% of patients) involving one thyroid lobe, although in 50% of cases microscopic neoplastic lesions are present in the contralateral lobe. One should be also aware of the possible presence of a small, 2-10 mm focus of papillary thyroid carcinoma termed „microcarcinoma”, which is asymptomatic and detected by chance in the course of histopathology of the thyroid gland resected in a patient with goiter or in serial autopsies of the thyroid (such post-mortem examinations detected 35.6% microcarcinoma foci). Approximately 50% of patients demonstrate the presence of metastases in the lymph nodes. Papillary carcinoma of the thyroid is a hormonally dependent tumor (TSH). The 5-year survival rate is approximately 95% [2, 3]. [Fig. 1,2,3,4]

### 3. Oncogenesis

The presently prevalent opinion states that genetic factors play an ever-increasing role in the development of neoplastic lesions. In view of the present knowledge, a prerequisite for neoplastic transformation to occur is a mutation involving two basic groups of genes - proto-oncogenes and suppressor genes, also called anti-oncogenes. Proto-oncogenes function as positive proliferation regulators. Under the effect of various external and internal factors, they may be converted into oncogenes. In turn, oncogene products may be divided into two groups of proteins, which are responsible for encoding the production of growth factors and affect the expression of surface receptors, either cytoplasmic or nuclear, thus indirectly participating in transcription inhibition or activation. Early neoplastic lesions usually involve a single cell line and appear as a consequence of a single or several serial mutations. Such mutations result in an increased capability of the cells to undergo mitotic divisions with a simultaneous decrease of their apoptotic capability as compared to the adjacent cells. Thus, a cell line develops that may give origin to for example hyperplasia of the thyroid tissue associated with neoplastic growth, since the borderline separating neoplastic transformation and hyperplastic proliferation is very thin [4,5].

In view of the high metabolism of cells undergoing division, the growth of a non-vascularized tumor is low. The clinical presentation of this growth phase is most commonly carcinoma in situ. The subsequent phase of tumor growth depends on the formation of new blood vessels (neoangiogenesis). Neoangiogenesis is a process composed of numerous interactions occurring in the paracrine and endocrine path between neoplastic cells and cells forming the vascular endothelium, connective tissue interstitium and some morphotic blood elements, such as macrophages or mastocytes. In consequence of these interactions, the microenvironment in the area surrounding the tumor changes, thus providing the neoplastic lesion with an opportunity for further uncontrollable growth and progression. A prerequisite for the initiation of angiogenic phenomena is a disturbed balance between the systems of pro- and anti-angiogenic factors. Of the identified to date proangiogenic factors (VEGF; bFGF; aFGF; PDGF; TGF- $\alpha$ ; TGF- $\beta$ ; EGF; IGF-1), not all meet the three defining criteria: exerting a specific effect on the endothelium, possessing the system of specific cell receptors and inhibiting or inducing angiogenesis through changes in their levels. Some of these factors co-act with mediators secreted by other cells (e.g. macrophages - TNF) in triggering and promoting the development of neoplastic disease. In accordance with currently accepted theories, the initiation of angiogenesis occurs through hypoxia of neoplastic cells that are situated the most distally from the lumen of a blood vessel, as well as through a defect of the genetic apparatus, in consequence of which the so-called angiogenic phenotype emerges. The term denotes the condition characterized by a permanent, constitutional activation of genes that encode growth factors. An additional loss of function by suppressor genes (e.g. the p53 gene) facilitates neoangiogenesis [8,19,20]. [Figure 5]

Endocrine glands constitute typical, richly vascularized organs; the circulating blood is the basis of their normal functioning and provides a close control of the feedback systems. As early as more than 20 years ago, investigators demonstrated that an increase in thyroid vascularization in patients with hyperthyroid goiter was regulated by cytokines secreted by thyrocytes. In subsequent years (reports by Goodman), the concept was confirmed and

extended by articles on the paracrine effect of connective tissue interstitial cells of the thyroid gland [17].

The regulation of this process is complex and the contributing factors include both neoplastic cells capable of producing such factors as cytokines and chemokines, as well as immunocompetent cells situated in the vicinity of tumor cells or infiltrating the tumor itself; the latter also produce cytokines, chemokines and growth factors. The interrelation of such factor production, especially in the case of chemokines, significantly intensifies angiogenesis. Chemokines, which contain the repeated sequence of glutamine-leucine-arginine, show an angiogenic activity [6-10].

#### **4. Angiogenesis**

The basic process of the formation of new blood vessels originating from the previously existing structures is the branching off of capillary vessels and budding of new vascular limbs that takes place both in fetal life and in mature organisms. The process is short-lived (approximately 5 days on the average), subject to strict regulations, and its sudden termination results from the reduction of stimulatory factors and/or a decrease of inhibitor levels. [1-9]. Angiogenesis is a pathomechanism involved in lesions developing in autoimmune diseases (rheumatoid arthritis, lupus erythematosus, hemangiomas, scleroderma, endometriosis) and in neoplastic diseases. [11-13].

A good part of publications in world literature on the role of angiogenic cytokines and epithelial growth factors in the process of tumor growth concentrate on processes occurring in the gastrointestinal tract [14-16]. Nevertheless, their presence and possible effect on the development and growth of tumors of endocrine origin have been recently recognized [17, 18].

VEGF is among relatively well-known endothelial growth factors. This specific protein is believed to play a key role in vascularization of solid tumors, including thyroid cancers. In keeping with the theory adopted by Folkman that states that tumor growth is limited by its vascularization, attempts were made at demonstrating higher VEGF expression in neoplastic tissues as compared to the population of normal cells. These studies show such an association with respect to cancers involving the stomach, colon, uterus, mammary glands and ovaries [14-16]. Also in the case of thyroid tumors, the key role in neoangiogenesis is played by VEGF, especially in view of the fact that the ability to produce and release this factor is characteristic not only of epithelial thyroid cells, but also of interstitial cells [18].

To date, infrequent reports have dealt with peripheral blood serum VEGF determinations in patients with highly differentiated thyroid cancers, what has prompted us to attempt assessing the clinical relevance of determining the level of vascular endothelial growth factor (VEGF) in patients with papillary thyroid cancers.

EGF is among the most potent stimulators of thyroid gland growth and its multiple activity is determined by its binding with specific EGF receptors. In vitro, EGF is a factor that stimulates the proliferation of follicular thyroid cells. A factor that intensifies EGF binding with receptors is thyreotropin (TSH), which - stimulating an increase in the number of EGF receptors - potentiates its activity [24,25]. In contrast to TSH, however, to reveal its mitogenic activity, EGF does not require the presence of other chemokines. [28]. Subsequent

investigators have attempted to determine the importance of positive EGF receptor expression in neoplastic thyroid tissue in the clinical course of the disease. EGF levels have been compared in various types of thyroid carcinomas and the highest expression has been found to be characteristic of anaplastic and medullary thyroid cancers. Also adenomas have been demonstrated to show marked expression of EGF receptors; however, this phenomenon involved solely certain regions of the tumor. The observation may weigh in favor of the possible neoplastic transformation of tumor tissues towards malignant processes [26]. The studies of Akslen et al. provided information on the importance of EGF receptor expression in the cytoplasm of papillary thyroid cancer cells, which was closely associated with extrathyroid growth of the tumor [27].

Summing up the results of studies on the serum concentration values of selected growth factors - VEGF and EGF - in patients with papillary thyroid cancer, one should state that they both participate in the induction and progression of neoplastic processes involving the thyroid gland, most likely acting, however, at various stages of tumor development - VEGF at the stage of neoangiogenesis induction, and EGF at the stage of invasion and possible remote metastases formation. [Figure 6]. To provide a firm and unambiguous confirmation of our observations it is necessary to conduct further investigations of the angiogenic activity, demonstrating a correlation between microvessel density (MVD) in the primary and metastatic tumors, as well as the presence and expression of receptors of these chemokines on the one hand, and the clinical stage of the tumor on the other; and showing whether these growth factors indeed have a prognostic value in identifying patients with a poor prognosis and expected shorter recurrence-free survival.

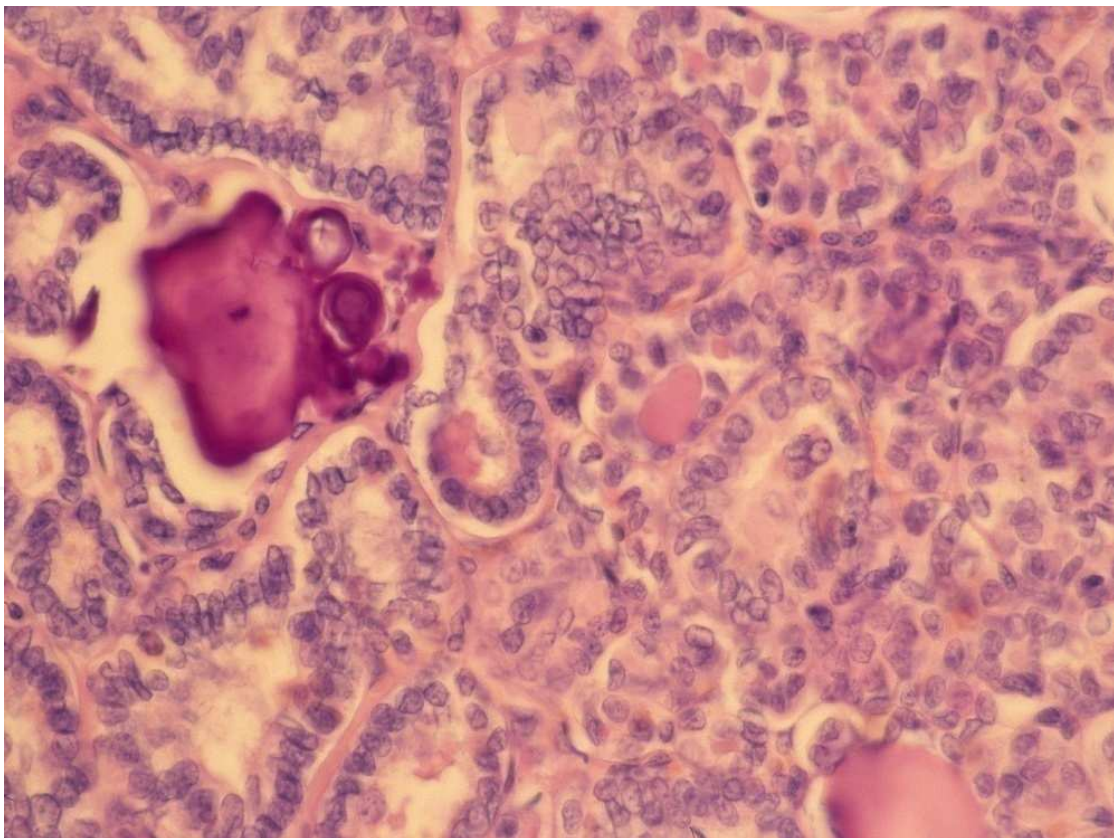


Fig. 1. Papillary thyroid cancer – psammoma body.

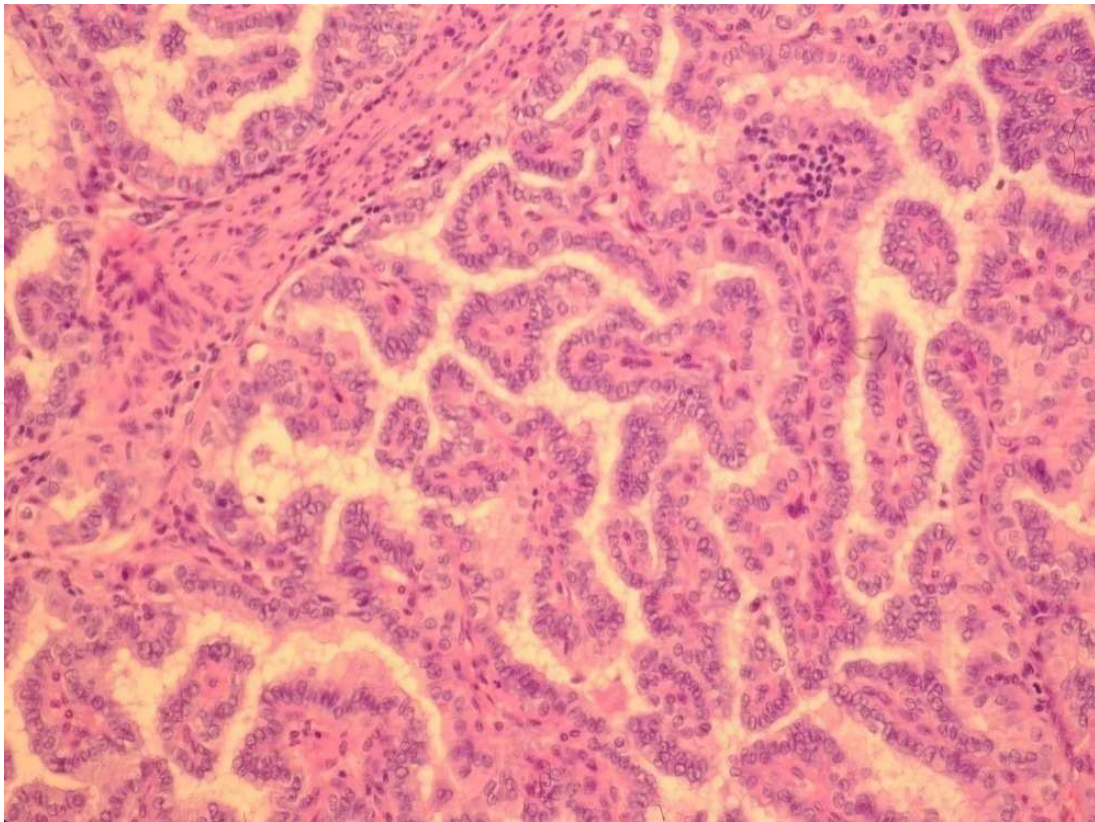


Fig. 2. Papillary thyroid cancer – a typically view

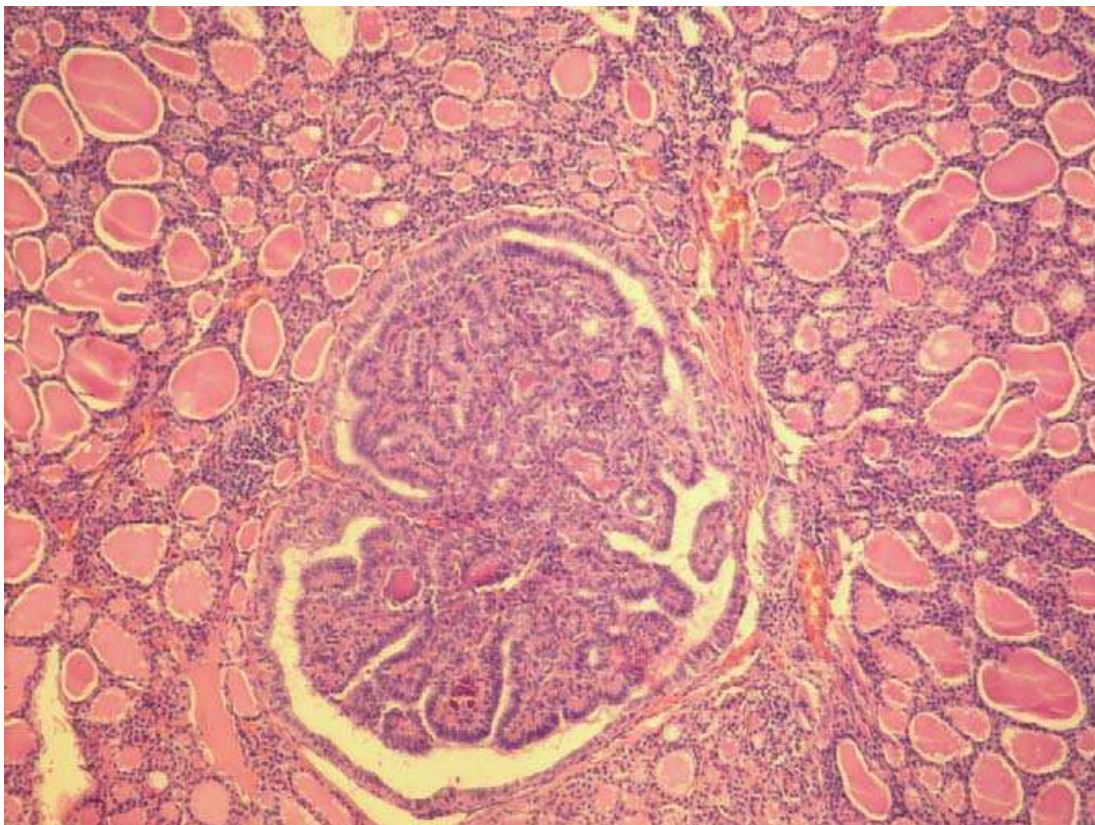


Fig. 3. Papillary thyroid cancer – a microcarcinoma variant

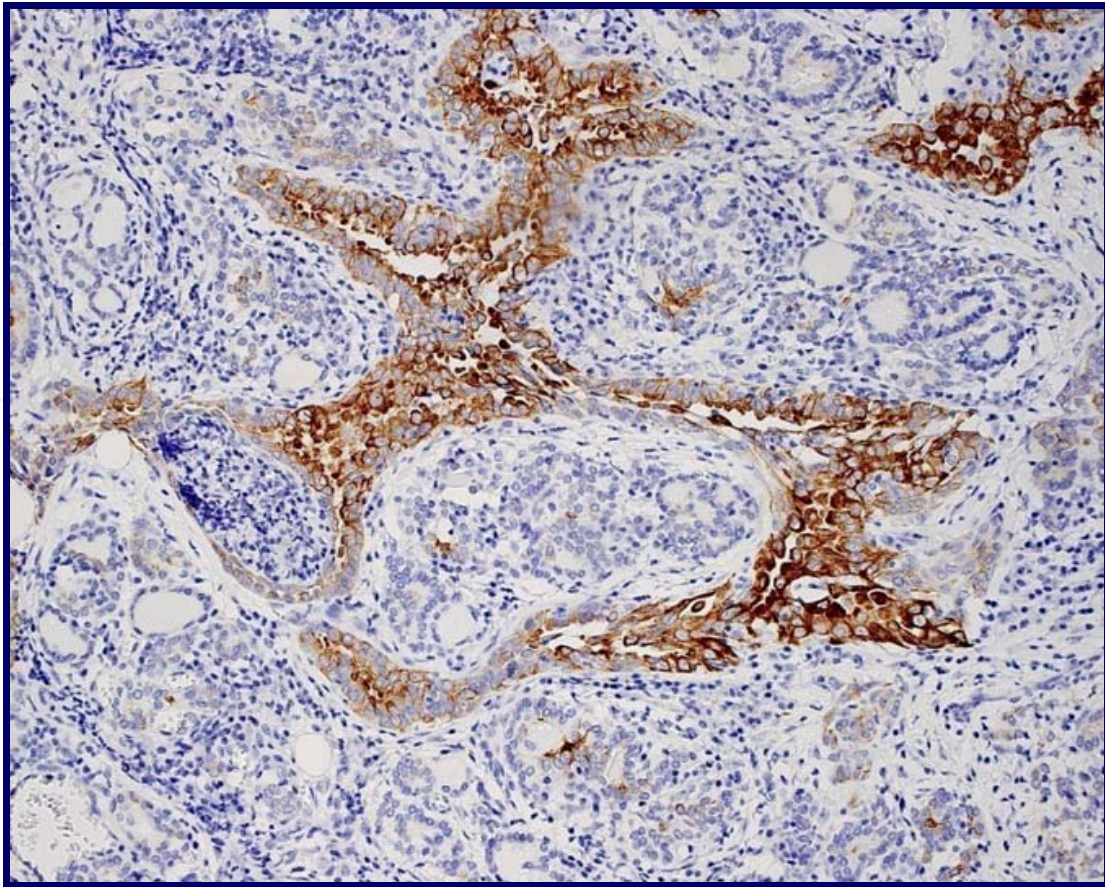


Fig. 4. Papillary thyroid cancer – high positive test of CK - 19

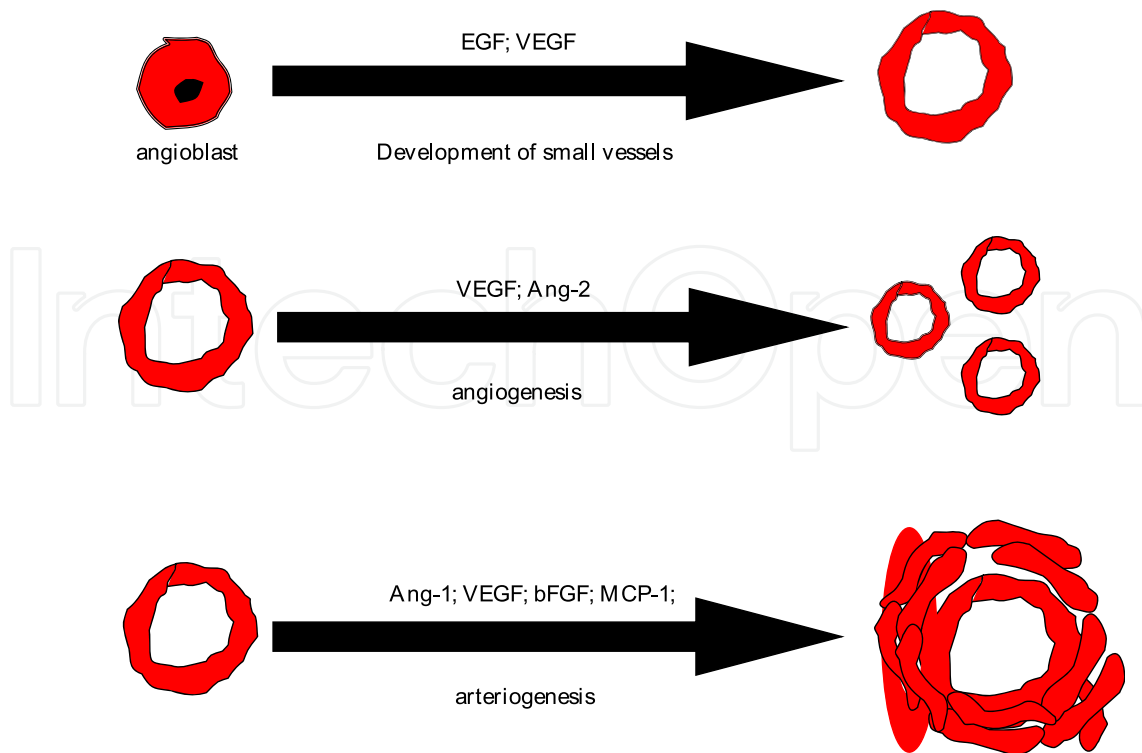


Fig. 5. Vascular growth factors and the effects of their acting.

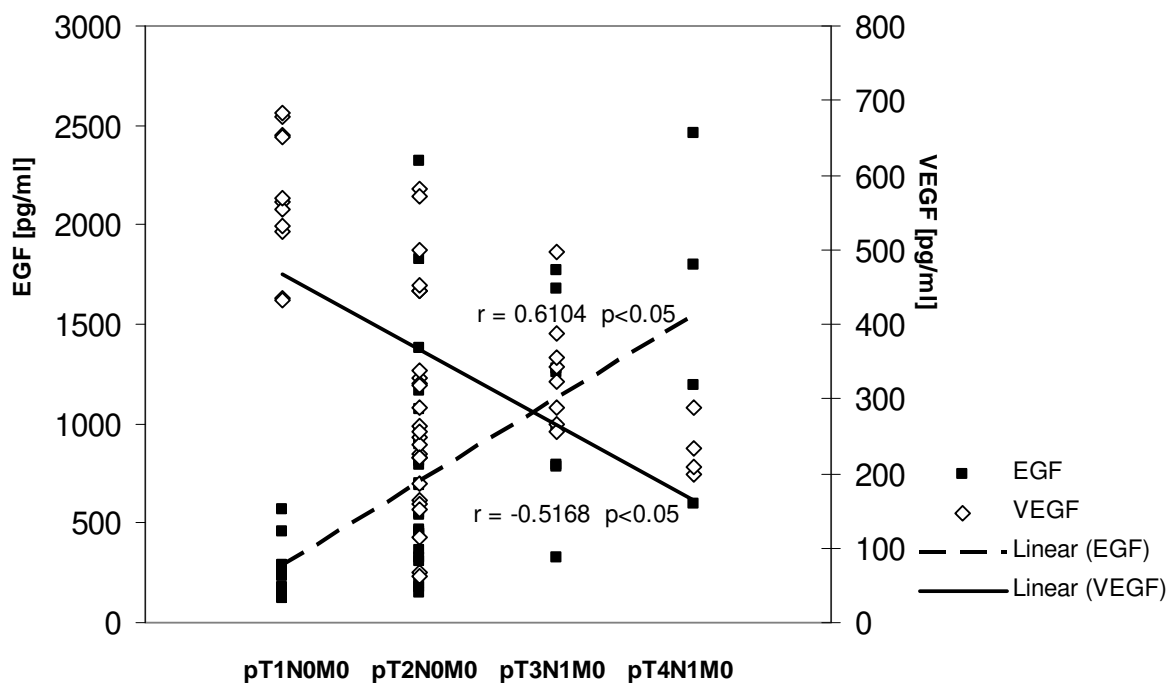


Fig. 6. Correlation between VEGF, EGF and staging of papillary thyroid cancer in pTNM classification ( $r$  = Pearson's correlation coefficient). The hypothesis of influence.

### 5. Keywords


Papillary thyroid cancer, vascular endothelial growth factor, epidermal growth factor, prognostic value

### 6. References

- [1] American Cancer Society (1991) Cancer Statistics 41: 28-29.
- [2] DeGroot LJ, Kaplan EL, McCormik M, Straus FH (1990) Natural history, treatment and course of papillary thyroid carcinoma. *J Clin Endocrinol Metab* 71: 414-424.
- [3] Schindler AM, van Melle G, Evequoz B, Scazziga B (1991) Prognostic factors in papillary carcinoma of the thyroid. *Cancer* 68:324-330.
- [4] Goretzki PE, Simon D, Dotzenrath C, Schulte KM, Röher HD (2000) *Growth Regulation of Thyroid and Thyroid Tumors in Humans*. *World J Surg* 24:913-922.
- [5] Falk SA (1997) *Thyroid disease: endocrinology, surgery, nuclear medicine and radiotherapy*. Lippincott, Williams & Wilkins and Raven Publishers, Philadelphia-New York.
- [6] Folkman J, Shing Y (1992) Angiogenesis. *J Biol Chem* 359:843-848.
- [7] Yancopoulos GD, Klagsburn M, Folkman J (1998) Vasculogenesis, angiogenesis and growth factors: ephrins enter the fray at the border. *Cell* 93:661-664.
- [8] Risau W (1997) Mechanism of angiogenesis. *Nature* 386:671-674.
- [9] Carmeliet P (2000) Mechanism of angiogenesis and arteriogenesis. *Nature Medicine* 6:389-395.



- [10] Balkwill F. (2003) :Chemokines biology in cancer. *Seminars in Immunology* 15: 49-55.
- [11] Reichlin M (1998) Systemic lupus erythematosus. In: Rose NR, Mackay IR (eds.) *The Autoimmune diseases*. Academic Press, Philadelphia, pp 1-37.
- [12] Norrby W (1997) Angiogenesis: a new aspects relating to its initiation and control. *Acta Pathol Microbiol Immunol Scand* 105:417-437.
- [13] Eliseenko VI, Skobelkin OK, Chegin VM (1998) Microcirculation and angiogenesis during wound healing by first and second intention. *Bull Experiment Biol Med* 105:289-292.
- [14] Maeda K, Chung YS, Ogawa Y (1996) Prognostic value of vascular endothelial growth factor expression in gastric carcinoma. *Cancer* 77:858-863.
- [15] Okada F, Rak J, St.Croix B, Lieubeau B, Kaya M, Roncari L, Shirasawa S, Sasazuki T, Kerbel RS (1998) Impact of oncogenes on tumor angiogenesis: mutant K-ras upregulation of VEGF/VPF is necessary but not sufficient for tumorigenicity of human colorectal carcinoma cells. *Proc Natl Acad Sci* 95:3609-3614.
- [16] Gasparini G, Toi M, Gion M, Verderio P, Dittadi R, Hanatani M, Matsubara I, Vinante O, Bonoldi E, Boracchi P, Gatti C, Suzuki H, Tominaga T (1997) Prognostic significance of vascular endothelial growth factor protein in node-negative breast carcinoma. *J Natl Cancer Inst* 89:139-147.
- [17] Goodman AL, Rone JD (1987) Thyroid angiogenesis: endotheliotropic chemoattractant activity from rat thyroid cell in culture. *Endocrinology* 121:2131-2140.
- [18] Turner HE, Harris AL, Melmed SH, Wass JAH (2003) Angiogenesis in endocrine tumors. *Endocrine Rev* 24:600-632.
- [19] Rak J, Mrtshashi Y, Bayko L, Filmus J, Sasazuki T, Kerbel RS (1995) Mutant ras oncogenes upregulate VEGF/VPF expression: implications for induction or inhibition of tumor angiogenesis. *Cancer Res* 55:4575-4580.
- [20] Kerbel RS, Vilona-Petit A, Okada F, Rak J (1998) Establishing a link between oncogenes and tumor angiogenesis. *Molecular Medicine* 4:286-295.
- [21] Lin SY, Wang YY, Sheu WH (2003) Preoperative plasma concentrations of vascular endothelial growth factor and matrix metalloproteinase 9 are associated with stage progression in papillary thyroid cancer. *Clin Endocrinol* 58:513-518.
- [22] Lennard CM, Patel A, Wilson J, Reinhardt B, Tuman C, Fenton C, Blair E, Francis GL, Tuttle RM (2001) Intensity of vascular endothelial growth factor expression associated with increased risk of recurrence and decreased disease-free survival in papillary thyroid cancer. *Surgery* 129:552-558.
- [23] Huang SM, Lee JC, Wu TJ, Chow NH (2001) Clinical relevance of vascular endothelial growth factor for thyroid neoplasms. *World J Surg* 25:302-306.
- [24] Westermarck K, Westermarck B (1982) Mitogenic effect of epidermal growth factor on sheep thyroid cells in culture. *Exp Cell Res* 138:47-55.
- [25] Westermarck K, Karlsson A, Westermarck B (1985) Thyrotropin modulates EGF receptor function in porcine thyroid follicle cells. *Mol Cell Endocrinol* 40:17-23.
- [26] Masuda H, Sugeno A, Kobayashi S, Kasuga Y, Iida F (1988) Epidermal growth factor receptor on human thyroid neoplasm. *World J Surg* 12:616-622.
- [27] Alslen LA, Myking AO, Salvesen H, Varhaug JE (1993) Prognostic impact of EGF-receptor in papillary thyroid carcinoma. *Br J Cancer* 68:808-812.
- [28] Westermarck K, Karlsson FA, Westermarck B (1983) Epidermal growth factor modulates thyroid growth and function in culture. *Endocrinology* 112:1680-1686.



## **Thyroid and Parathyroid Diseases - New Insights into Some Old and Some New Issues**

Edited by Dr. Laura Ward

ISBN 978-953-51-0221-2

Hard cover, 318 pages

**Publisher** InTech

**Published online** 07, March, 2012

**Published in print edition** March, 2012

This book was designed to meet the requirements of all who wish to acquire profound knowledge of basic, clinical, psychiatric and laboratory concepts as well as surgical techniques regarding thyroid and parathyroid glands. It was divided into three main sections: 1. Evaluating the Thyroid Gland and its Diseases includes basic and clinical information on the most novel and quivering issues in the area. 2. Psychiatric Disturbances Associated to Thyroid Diseases addresses common psychiatric disturbances commonly encountered in the clinical practice. 3. Treatment of Thyroid and Parathyroid Diseases discusses the management of thyroid and parathyroid diseases including new technologies.

### **How to reference**

In order to correctly reference this scholarly work, feel free to copy and paste the following:

Aleksander Konturek and Marcin Barczynski (2012). Vascular Endothelial Growth Factor (VEGF) and Epidermal Growth Factor (EGF) in Papillary Thyroid Cancer, Thyroid and Parathyroid Diseases - New Insights into Some Old and Some New Issues, Dr. Laura Ward (Ed.), ISBN: 978-953-51-0221-2, InTech, Available from: <http://www.intechopen.com/books/thyroid-and-parathyroid-diseases-new-insights-into-some-old-and-some-new-issues/angiogenesis-in-well-differentiated-thyroid-cancer->

**INTECH**  
open science | open minds

### **InTech Europe**

University Campus STeP Ri  
Slavka Krautzeka 83/A  
51000 Rijeka, Croatia  
Phone: +385 (51) 770 447  
Fax: +385 (51) 686 166  
[www.intechopen.com](http://www.intechopen.com)

### **InTech China**

Unit 405, Office Block, Hotel Equatorial Shanghai  
No.65, Yan An Road (West), Shanghai, 200040, China  
中国上海市延安西路65号上海国际贵都大饭店办公楼405单元  
Phone: +86-21-62489820  
Fax: +86-21-62489821

© 2012 The Author(s). Licensee IntechOpen. This is an open access article distributed under the terms of the [Creative Commons Attribution 3.0 License](#), which permits unrestricted use, distribution, and reproduction in any medium, provided the original work is properly cited.

IntechOpen

IntechOpen