

We are IntechOpen, the world's leading publisher of Open Access books Built by scientists, for scientists

5,300

Open access books available

130,000

International authors and editors

155M

Downloads

Our authors are among the

154

Countries delivered to

TOP 1%

most cited scientists

12.2%

Contributors from top 500 universities



WEB OF SCIENCE™

Selection of our books indexed in the Book Citation Index
in Web of Science™ Core Collection (BKCI)

Interested in publishing with us?
Contact book.department@intechopen.com

Numbers displayed above are based on latest data collected.

For more information visit www.intechopen.com



Evidence-Based Invasive Treatments for Cerebral Vasospasm Following Aneurysmal Subarachnoid Hemorrhage

Geoffrey Appelboom¹, Adam Jacoby²,
Matthew Piazza² and E. Sander Connolly³

¹*Postdoctoral Research Scientist, Department of Neurological Surgery
Columbia University, New York, NY*

²*Research Fellow, Department of Neurological Surgery
Columbia University, New York, NY*

³*Bennett M. Stein Professor of Neurological Surgery
Columbia University, New York, NY
USA*

1. Introduction

Starting in 1984, the technique of angioplasty was no longer confined to only the treatment of peripheral and coronary arteries. In the original paper investigating the technique of angioplasty in cerebral arteries after cerebral vasospasm from aneurysmal subarachnoid hemorrhage (aSAH), Zubkov et al. found an overall decrease in headaches and focal neurological deficits after the procedure (Zubkov et al, 1984). Despite advances in both medical and endovascular treatment of cerebral vasospasm since then, vasospasm remains a prominent source of morbidity and mortality for patients in the Neuro-Intensive Care Unit. At an estimated incidence rate of 10-28/100000 people, aSAH is associated with a 20% to 40% risk of development of symptomatic, cerebral vasospasm. Of these patients experiencing symptomatic vasospasm, an estimated 10-15% will die before medical therapy while the other 85-90% will have an overall mortality rate of 32-67% (Weant et al, 2010; Frontera et al, 2009).

In a review of the literature investigating endovascular treatment of cerebral vasospasm, an absence of standardization is present across these studies. Starting from the basics, the literature has not produced a “gold standard” definition of vasospasm. While some groups define vasospasm by a clinical, neurological deterioration (Andaluz et al, 2002), others use a variety of diagnostic modalities, such as Transcranial Doppler Velocities (Oskouian et al, 2002), digital subtraction angiography (Frontera et al, 2009), and narrowing of vessel diameter via CT angiography (Coenen et al, 1998), to make the same diagnosis. Therefore, assessing the overall efficacy of angioplasty for cerebral vasospasm is difficult when the literature provides different indications for the same treatment.

Once a diagnosis of cerebral vasospasm is confirmed, a lack of standardization continues throughout its treatment. While some groups have associated a good neurological grade

upon admission to the hospital and an early, clinical response to initial treatment for vasospasm with improved outcomes, a treatment regimen for vasospasm is far from standardized (Charpentier et al, 1999; Frontera et al, 2010). Although treatment for vasospasm differs from hospital to hospital, most studies examining the management of vasospasm use a combination of hypervolemia, hemodilution, and hypertension (triple-H) therapy as well as the calcium channel blocker nimodipine as their first-line treatments (Frontera et al, 2009). Besides applying these two “core” therapies, recent studies have tried various combinations of endovascular therapies, such as intra-arterial papaverine and verapamil, as well as transluminal balloon angioplasty, first described by Zubkov in 1984 (Frontera et al, 2009; Zubkov et al, 1984). Despite evidence of improved outcomes from papaverine, verapamil, and angioplasty therapies, the absence of a large, prospective, multi-center, randomized, controlled trial, evaluating these treatments has prevented the creation of a gold standard protocol for treatment of vasospasm (Frontera et al, 2009; Zubkov et al, 1984).

2. Definition of vasospasm

Zubkov set the stage for investigating the endovascular treatments of vasospasm after aneurysmal subarachnoid hemorrhage. Epidemiologically, aneurysms are estimated to be present in between 1% and 9% of the population; the incidence of aSAH is around 1 per 10,000 people and increases with age and female sex (Dupont et al, 2010). While the cause of aneurysms and subsequent ruptures are not completely elucidated, risk factors for aSAH include smoking, alcohol use, cocaine use, and hypertension (Dupont et al, 2010).

Cerebral vasospasm after aSAH, macroscopically, is a contraction of smooth muscle in cerebral arteries (Al-Tamimi et al, 2010). This contraction, however, is difficult to measure and define from direct observation. From the articles reviewed, vasospasm definitions can be divided into three categories; groups have defined vasospasm by either clinical indications, Transcranial Doppler Velocity measurements, or by angiographic vessel diameter evidence. While Kaku et al. define vasospasm as a Transcranial Doppler mean flow velocity greater than 100 cm/sec or an increase of more than 30 cm/sec (Kaku et al, 1992), Firlik et al. report vasospasm by measuring percentage stenosis through angiogram analysis (Firlik et al, 1997). Frontera et al. include a definition for vasospasm, which is defined by the development of new focal neurological symptoms or deficits after other causes have been excluded (Frontera et al, 2011). Below, Table 1 reports the variation in definitions of vasospasm used by different studies in this literature review.

3. Pharmaceutical, non-endovascular treatments of vasospasm

While studies investigating endovascular therapy for cerebral vasospasm are mostly retrospective with a small sample size, a group of prospective, randomized, controlled trials on the efficacy of non-endovascular, pharmaceutical treatment of vasospasm does exist. Recent trials have investigated the efficacy of statins, calcium channel blockers, a nonglucocorticoid aminosteroid, recombinant tissue plasminogen activator, and an endothelin receptor antagonist in vasospasm therapy. Although this review focuses on endovascular treatments for vasospasm, the future of vasospasm therapy also involves non-endovascular treatments.

First Author	Date/Journal	Definition of Vasospasm
Keuskamp	2008, J Neurosurg	Angiographic CT 0, no vasospasm. Mild <20%, Mild Moderate 21-40%, moderate 41-60%, moderate-severe 61-80%. Severe >81% constriction
Firlik	1997, J Neurosurg	Angiographic CT 0, no vasospasm. Mild, <50% stenosis. Moderate 50% stenosis. Severe >50% stenosis.
Kaku	1992, J Neurosurg	Symptomatic (new neurological deficit not attributable to other causes) and TCD velocity >100 cm/sec
Elliott	1998, J Neurosurg	TCD > 120 cm/sec and vessel diameter via CT; >25% narrowing
Coenen	1998, Neurosurgical Focus	25% decrease in the vessel diameter was defined as mild, moderate was 50%, severe was 75%;
Oskouian	2002, Neurosurgical Focus	on TCD measurements alone, VMCA >120 cm/s and HR VMCA/VEC-ICA of more than 3.
Eskridge	1998, Neurosurgery	TCD and Angiography, unclear scales used
Jestaedt	2008, Neurosurgery	TCD > 120 cm/s Retrospective CT angiography 0, no vasospasm; 1, vessel narrowing less than 70%; 2, vessel narrowing greater than 70%; or 3, subtotal occlusion with high-grade hemodynamic compromise Symptomatic (50% decrease in somatosensory evoked potential amplitude, increase in somatosensory evoked potential latency or increase of greater than 150 cm/second, or clinical vasospasm by new neurological deficit or loss of two points on GCS), decrease to less than 15 mmHg in tissue oxygenation; also verified via digital subtraction angiography
Beck	2006, J Neurosurg	TCD velocity >120 cm/s in presence of Lindegaard index of >3 and severe vasospasm recorded was >200 cm/s
Zweinenberg-Lee	2008, Stroke	Symptomatic and angiographic >50% narrowing
Frontera	2011, Acta Neurochir Suppl	Symptomatic (delayed neuronal deficits not explained by hydrocephalus, cerebral edema, infection, or other causes)
Katoh	1999, Neurological Focus	TCD velocities; between 150 and 200 cm/s mild vasospasm and >200 moderate and >250 severe
Muizelaar	2001, Acta Neurochir Suppl	Angiographic (mild vasospasm <50% reduction in vessel diameter, moderate = 50% reduction, severe >50% reduction)
Kassell	1992, J Neurosurg	Angiographic >50% reduction in diameter
Fujii	1995, Neurosurg Rev	Angiographic; <30% luminal narrowing mild, between 30 and 60% moderate, and over 60% severe
Jun	2010, AJNR	Angiographic; decrease in 50% or more in diameter of vessel segment
Choi	2011, J Korean Neurosurg	Symptomatic (new focal neurological deficit not attributable to seizure, hematoma, brain edema, or hydrocephalus)
Santillan	2011, Neurosurgery	Symptomatic and Angiographic (clinical, not defined greater than 50% constriction of vessel for angiographic)
Murai	2005, Surgical Neurology	Symptomatic defined by onset of delayed neurological deficit with 2 or more decrease on GCS

Table 1.

a. Statin therapy

The statins, or 3-hydroxy-3-methylglutaryl coenzyme A (HMGCoA) reductase inhibitors, have been theorized to have a protective role in the development of cerebral vasospasm. In addition to inhibiting the synthesis of cholesterol, statins are also thought to regulate endothelial and nitric oxide synthase function (Al-Tamimi et al, 2010), and therefore might affect the spasticity of the cerebral vasculature. Two statins, specifically simvastatin and pravastatin, have been investigated in randomized, placebo-controlled, trials. The results on simvastatin treatment of cerebral vasospasm have been mixed. While Vergouwen et al. find that simvastatin treatment provided no improvement on TCD-defined vasospasm (Vergouwen et al, 2009), Chou et al. report that angiographic vasospasm was present in 5/19 patients treated with simvastatin compared with 8/20 patients given a placebo (Chou et al, 2008). No differences, however, are statistically significant. In their meta-analysis, Etminan et al. include only 190 patients and find this number to be too small to make conclusions about the efficacy of statin therapy (Etminan et al, 2011).

b. Calcium antagonist therapy

Nimodipine, a calcium antagonist and part of the current standard of care for treatment of cerebral vasospasm, inhibits calcium entry. However, other pathways exist within the cell that affect calcium utilization and also serve as possible targets for the treatment of vasospasm. In a prospective, randomized, placebo-controlled, double-blind trial, Shibuya et al. investigated the efficacy of AT877, an inhibitor of myosin light-chain kinase, of protein kinases A,G, and C, and of the actions of free intracellular calcium ions (Shibuya et al, 1992). With intravenous therapy of AT877, Shibuya et al. report a statistically significant reduction of angiographic vasospasm by 38% as well as a reduction in symptomatic vasospasm by 30%. Clinically, Shibuya et al. find AT877's effect on outcomes to be similar to nimodipine's; the article reports a significant reduction in poor outcomes associated with vasospasm by 54% and finds no significant adverse side effects (Shibuya et al, 1992). A possible downside of treatment with AT877 is its short half-life. Although Shibuya et al. report that AT877's metabolite still shows spasmolytic qualities, the parent compound has an estimated half-life of under fifteen minutes.

c. Treatment with tirilazad mesylate

In response to the possible connection between free radical-induced lipid peroxidation and vasospasm, the 21 aminosteroid, tirilazad mesylate, was created to inhibit this pathway (Kassell et al, 1996). In a prospective, randomized, double-blind, controlled trial of 1023 patients, Kassell et al. investigated the efficacy of tirilazad mesylate, using symptomatic vasospasm and Glasgow Outcome Scale scores at three months as outcome measures. Although Kassell et al. do not report a statistically significant reduction in symptomatic vasospasm with aSAH after treatment with tirilazad mesylate, they argue for the presence ($p=.048$) of a decrease in vasospasm at higher doses of tirilazad mesylate. The most promising statistics from this article, however, concern the three month outcomes for patients in the treatment group. Kassell et al. report in the highest dosage of tirilazad mesylate, 63% of patients had a good recovery, compared to 53% of the vehicle treated group (Kassell et al, 1996). This difference was statistically significant. Despite minor injection site phlebitis, tirilazad mesylate was not associated with life-threatening or adverse medical events.

d. Endothelin receptor antagonist therapy

Systemic vasoconstriction is controlled by many physiological hormones, including adrenergic agonists, angiotensin II, and antidiuretic hormone. Endothelin, a powerful

vasoconstrictor possibly increased after aSAH (Macdonald et al, 2008) and its pathway to vasoconstriction have been investigated for possible targets in the treatment of vasospasm. Specifically, Macdonald et al. looked at the efficacy of the endothelin receptor antagonist, clazosentan, in the prospective, randomized, double-blind, placebo-controlled CONSCIOUS-1 trial. While Macdonald et al. report no significant difference between the treatment and control groups with respect to morbidity and mortality, they find a reduction of moderate or severe vasospasm from 66% in the placebo group to 23% in the highest dosage treatment group (Macdonald et al, 2008). Complications associated with clazosentan administration included anemia, hypotension and pulmonary issues including pneumonia, pleural effusions, pulmonary edema, and acute respiratory distress syndrome. The results of the CONSCIOUS-1 trial point to the disconnect between vasospasm and clinical outcome. While Macdonald et al. report a decrease in vasospasm from digital subtraction angiography after treatment, they find no effect on morbidity and mortality (Macdonald et al, 2008). Like other studies in this review of the literature, this trial calls for further exploration in the connection between vasospasm and clinical consequences.

e. Fibrinolytic therapy

The correlation between subarachnoid clot thickness and degree of vasospasm led to the possibility of fibrinolytic therapy in the treatment of cerebral vasospasm. In a prospective, randomized, blinded, placebo-controlled trial by Findlay, the efficacy of intracisternal, recombinant tissue plasminogen activator for prevention of vasospasm was investigated with angiographic vasospasm serving as the primary endpoint (Findlay, 1995). Although Findlay reports angiographic vasospasm in 74.4% of placebo patients and 64.6% of treatment patients, the difference between the two groups was not statistically significant ($P=.31$). An interesting, significant finding from the same study comes from the treatment of patients with thick subarachnoid clots. In this group, Findlay finds a 56% relative risk reduction of severe vasospasm in the treatment group, suggesting a very specific indication for treatment with recombinant tissue plasminogen activator. While Findlay also reports a pattern of lower mean velocities on transcranial Doppler, reduced delayed neurological worsening, a lower 14 day mortality rate, and improved 3 month outcome in the treatment group, none of these findings was statistically significant (Findlay, 1995). As with all fibrinolytic treatment, the possibility of treatment associated hemorrhage presents as a risk. While these studies, investigating the efficacy of pharmaceutical, non-endovascular treatments of vasospasm, are well-designed and have promising results, future larger scale, multi-center trials, with mortality serving as a primary outcome measure, would help determine which therapies should be added to the standard protocol for treatment of cerebral vasospasm.

4. Current institutional protocols for treatment of aSAH and vasospasm

While a standard of care has not been completely established for the treatment of cerebral vasospasm, common themes are ubiquitous throughout a review of the literature. After diagnosis of aSAH, the following treatment can be divided into two sections, common to most recent studies. The first part of therapy involves stabilizing the patient's aSAH while the second focuses on the prevention or management of cerebral vasospasm. Before cerebral vasospasm is even considered, the aSAH is ideally treated surgically by either endovascular coiling or clipping. However, the timing of surgery, similar to the definition of cerebral vasospasm, has not been completely standardized. While Choi et al.'s protocol (Choi et al,

2011) calls for surgery within twenty four hours of the aSAH, Murai et al. include patients whose aneurysms had been clipped or coiled within forty eight hours of aSAH (Murai et al, 2005). After the subarachnoid hemorrhage has been managed surgically, the goal of therapy begins to focus on the treatment of cerebral vasospasm.

Typically after surgery today, patients are then treated with oral nimodipine and a combination of induced hypertension, hemodilution, and volume expansion ("Triple-H") therapy to minimize the effects of cerebral vasospasm (Komotar et al, 2008). Nimodipine, a dihydropyridine calcium channel blocker, which blocks L-type, slow conducting, voltage-dependent, calcium channels, has been shown to reduce cerebral infarction, when compared to untreated patients (Weant et al, 2010) , while triple-H therapy focuses on maintaining high cerebral perfusion pressures to increase cerebral blood flow during vasospasm (Komotar et al, 2008).

These treatments, however, are not applied without controversy. With Triple-H therapy comes the risk of possible organ damage, pulmonary edema, and organ ischemia. On the other hand, the use of nimodipine in the treatment of cerebral vasospasm has raised questions about the connection between cerebral vasospasm and poor outcomes. Mechanistically, the administration of a calcium channel blocker "makes sense"; prevention of an increasing concentration of intracellular calcium should reduce smooth muscle contraction within the cerebral vasculature.

While Pickard et al. do report a significant reduction in cerebral infarction events in those treated with nimodipine after aSAH (Pickard et al, 1989), they do not find a change in Transcranial Doppler Velocities between those treated and the controls. It has been suggested that antithrombotic actions of nimodipine might be responsible for its therapeutic effects (Weant et al, 2010). Nimodipine's clinical benefits without changing Transcranial Doppler Velocities suggests that vasospasm may be correlated with adverse clinical outcomes but may not cause them. Similarly, Frontera et al. report that a Transcranial Doppler Velocity greater than 120 cm/sec, a measurement indicative of vasospasm, is not necessarily a predictor of clinical outcome (Frontera et al, 2009). A recent meta-analysis by Etminan et al., investigating the efficacy of pharmaceutical treatment on delayed cerebral ischemia (DCI), also reported a decrease in radiographic vasospasm without clinical benefit (Etminan et al, 2011). The exact relationship between vasospasm and clinical outcome must still be fully elucidated.

Although nimodipine and Triple-H therapy have been shown to improve clinical outcome, even administration of these therapies are not standardized. While Zweinenberg-Lee et al. report a protocol (Zwiezenberg-Lee et al, 2008) of maintaining hematocrit levels between 30-35%, Oskouian et al.'s protocol (Oskouian et al, 2002) calls for a target of 31-35%. Similarly, across these studies on the treatment of vasospasm, a common, unifying goal of hypertensive therapy is not present. Rosenwasser et al. report elevating mean arterial pressure to 130-140 mm Hg (Rosenwasser et al, 1999), while Oskouian et al. present a protocol calling for a perfusion pressure of 70 mm Hg (Oskouian et al, 2002) and Coyne et al. report a maintenance level of 240 mm Hg for systolic blood pressure (Coyne et al, 1994). The methods to achieve high levels of cerebral blood flow and hypertension are also not standardized. While Keuskamp et al. report using neosynephrine, ephedrine, and dopamine in their triple-H therapy (Keuskamp et al, 2008), Murai et al. use dobutamine alone (Murai et al, 2005). Therefore, the current "gold standard," a combination of Triple-H therapy and nimodipine, is not uniformly executed.

5. Experimental endovascular treatments for vasospasm

Besides medical therapy with intravenous or oral nimodipine and Triple-H therapy, cerebral vasospasm after aSAH, has been experimentally treated with methods that are theoretically sound. While nitric oxide donors, phosphodiesterase inhibitors, endothelin antagonists, statins, and magnesium (Weant et al, 2010; Fathi et al, 2001; Shankar et al, 2011) have all been investigated for treating cerebral vasospasm through expected vasodilatory effects, the focus of current endovascular studies has predominantly remained on intra-arterial medical therapy with the calcium channel antagonist, verapamil, or the phosphodiesterase inhibitor, papaverine, or transluminal balloon angioplasty of the affected vessels.

a. Intra-arterial medical treatment and its efficacy

The methods of administering intra-arterial medical therapy differ slightly from group to group and depend on the specific article from the review of the literature. A representative technique, however, is described by Feng et al. A 5F or 6F guiding catheter is used to infuse the specified drug in the internal carotid or vertebral arteries. With this technique, the physician hopes to deliver medical therapy to the spastic vessels (Feng et al, 2002). Some groups, such as Jun et al., report a slightly different protocol if severe vasospasm is present in the ACA or MCA.; they describe using a microcatheter to reach the spastic portions of the ACA and MCA to deliver medical therapy (Jun et al, 2010).

Although most studies evaluating the efficacy of intra-arterial medical therapy and angioplasty are retrospective with a relatively small sample size, they do show some promise in the treatment of cerebral vasospasm. While Kaku et al. report an improvement in neurological function in 80% of patients treated with intra-arterial papaverine (Kaku et al, 1992), Keuskamp et al. describe a median reduction of 2 units on their vasospasm scale after treatment with intra-arterial verapamil (Keuskamp et al, 2008). However, the data on intra-arterial medical treatment of cerebral vasospasm are not completely straightforward; Coenen et al. report that the benefits from intra-arterial papaverine administration are neither reliable nor sustained. Another problem that arises in comparing studies, evaluating the efficacy of intra-arterial medical treatment, is the dosage of drug administered (Coenen et al, 1998). While Kassell et al. use 100-300 mg of papaverine in their protocol (Kassell et al, 1992), Firlik et al. report using between 300 and 600 mg of the same drug (Firlik et al, 1997). It is difficult to generalize the efficacy of intra-arterial medical therapy given the variety of dosage protocols across studies in this literature review.

However, intra-arterial treatment of cerebral vasospasm does not come without risk. Investigating the risks of intra-arterial verapamil infusion and papaverine therapy respectively, Feng et al. and Keuskamp et al. find no significant changes in intracranial pressure, heart rate, or hemodynamic parameters after intra-arterial treatment (Feng et al, 2002; Keuskamp et al, 2008). These are not the only parameters, however, by which safety of intra-arterial therapies should be assessed. Intra-arterial administration of papaverine and verapamil have both been associated with case reports of seizures (Zubkov et al, 1984) while papaverine alone has been linked to aphasia, mental status changes, and even respiratory arrest. On the cellular level, papaverine might also adversely affect neuronal mitochondrial respiration (Weant et al, 2010). Although Feng et al. and Keuskamp et al. report that intra-arterial therapy is safe, further research should be conducted before verapamil or papaverine use is widely accepted as treatment for vasospasm.

b. Angioplasty for cerebral vasospasm and its efficacy

Beginning in 1984, the treatment of cerebral vasospasm after aSAH came to include the physical dilation of cerebral arteries using transluminal balloon angioplasty. The original

technique of angioplasty, described by Zubkov et al., involved puncturing the common carotid artery and placing a balloon catheter in the internal carotid artery. In an X-ray room, the balloon catheter was then repetitively inflated and deflated in the proximal part of the affected artery. This procedure then continued distally and after this technique, cerebral blood flow was monitored with a Xe-133 administration (Zubkov et al, 1984).

Since Zubkov's original paper, the actual technique of angioplasty has progressed at a relatively slow rate; today, angioplasty very much resembles the original procedure performed by Zubkov, including the repetitive inflation-deflation cycles. Similar to the description of intra-arterial medical treatment for vasospasm, the current techniques of angioplasty differ slightly from group to group and depend on the specific article from the literature. A representative method of angioplasty for cerebral vasospasm is described by Jun et al (Jun et al, 2010). In this study, Jun et al. report intravenous heparinization prior to angioplasty. Unlike Zubkov et al., they begin treating the distal portions of the spastic artery before the proximal portions. Although angioplasty for cerebral vasospasm has shown promise with respect to clinical outcomes, the technique is not without limitations. Terada et al. and Jun et al. both exclude smaller, distal cerebral arteries as targets of treatment with angioplasty for fear of vessel rupture (Terada et al, 1997; Jun et al, 2010). While each group "sets their own limits" with respect to the smallest vessel they will treat with angioplasty, Jun et al. report treating vasospasm in the supraclinoid ICA, M1 MCA, A1 ACA, intracranial vertebral artery, basilar artery, and P1 PCA (so called "proximal vessels"), while they find treatment of M2 MCA, A2 ACA, P2 PCA (so called "distal vessels") to be too risky (Jun et al, 2010). With every procedure comes the possibility of complications. While the risks of mechanical dilation of spastic cerebral vessels by transluminal angioplasty are lessened by a skilled physician, they are still present. Vessel rupture, thrombosis, and occlusion are possible complications during the angioplasty procedure (Weant et al, 2010).

Since Zubkov's paper, studies have investigated the efficacy of his technique. Overall, the results of cerebral angioplasty have been promising; in a 50 patient pilot study, Eskridge et al. report a 61% sustained neurological improvement after angioplasty (Eskridge et al, 1998). Although most studies in this literature review look positively upon angioplasty for cerebral vasospasm, not all trials have proven to be efficacious. While Fujii et al. and Eskridge et al., respectively, describe an 83% increase in diameters of affected cerebral arteries (Fujii et al, 1995) and a 73% recovery in patients experiencing focal neurological deficits after treatment (Eskridge et al, 1990), Coenen et al. find angioplasty to be an unreliable method of treating cerebral vasospasm. Similar to other conclusions made in this literature review, the results of these retrospective angioplasty trials do not provide a straightforward judgment on its efficacy (Coenen et al, 1998).

Once again, comparing these studies, which assess the efficacy of angioplasty for cerebral vasospasm, is difficult given the absence of standardization of the procedure. One difference, amongst groups, lies in the type and size of balloon used during angioplasty. For example, while Eskridge et al. use a 3 mm. x 12 mm. silicone balloon from Target Therapeutics (Eskridge et al, 1998), Bejjani et al. report using a 3.5 mm. Cirrus balloon (Bejjani et al, 1998). While these differences might not practically affect the procedure or its results, they should be considered when evaluating the efficacy of this technique.

c. Comparison of angioplasty with intra-arterial medical therapy

Although retrospectively, the efficacy of intra-arterial medical therapy and angioplasty for vasospasm have been compared. Similar to the studies on the efficacy of both of these modes of treatment, the groups comparing these two therapies have produced mixed

results. Elliott et al. report a favorable clinical outcome in 67% of patients after angioplasty compared with a 62% favorable outcome after treatment with papaverine (Elliott et al, 1998), while Katoh et al. report a 58% clinical improvement after angioplasty compared with a 25% improvement after papaverine (Katoh et al, 1999). Elliott et al. also report an increase in Transcranial Doppler velocities on Day 2 after treatment with papaverine, suggesting an absence of sustainable effect from the papaverine (Elliott et al, 1998). Although these studies suggest that angioplasty is a more effective endovascular treatment for cerebral vasospasm, the data are not all one-sided. Coenen et al. report that both angioplasty and papaverine are equivalently ineffective in producing reliable and sustained results (Coenen et al, 1998). Theoretically, an interesting procedure would be combining both angioplasty and intra-arterial medical therapy in the same treatment.

d. Combination therapy with angioplasty and intra-arterial medical treatment

Since it is believed that angioplasty in smaller, more distal vessels, is too risky, it is logical that a combination of intra-arterial medical treatment with angioplasty might be effective in treating both proximal and distal cerebral vasospasm. In a retrospective study by Frontera et al. the group compares combined therapy with chemical vasodilation alone. Frontera et al. find that while 39% of patients undergoing combination therapy developed recurrent angiographic and symptomatic vasospasm, 82% of patients receiving chemical vasodilation, alone, developed vasospasm (Frontera et al, 2011). Future, large-scaled and multicenter trials on the efficacy of combination therapy should help elucidate the most effective combinations of medical endovascular treatment with angioplasty.

Amongst these experimental, endovascular treatments, angioplasty seems beneficial for the larger, more proximal, and more accessible cerebral vessels while treatment with intra-arterial papaverine and verapamil is more appropriate for smaller, more distal, and less accessible arteries where a large risk of rupture is present.

6. Limitations to efficacy comparisons across studies

However, problems with these studies, investigating the efficacy of experimental treatments for cerebral vasospasm, do exist. The small sample sizes and retrospective nature of a vast majority of these studies make it difficult to establish definitive conclusions with respect to efficacy of different endovascular treatments. Also, the criteria to begin endovascular treatment differ from group to group. For example, while Bejjani et al report treating vasospasm with angioplasty only after Triple-H therapy has failed (Bejjani et al, 1998), Santillan et al. use a decrease in vessel diameter via angiography as one of their indications for treatment (Santillan et al, 2011). Therefore, constructing a meta-analysis, combining the results of these studies, is difficult as different groups make their own decisions about when to treat patients endovascularly. Table 2, below, lists the criteria to treat cerebral vasospasm, from several groups, reviewed in the literature.

7. Recommendations for invasive treatments

Although most experimental studies investigating the efficacy of invasive treatments for cerebral vasospasm after aSAH are retrospective in nature, effective patterns can be extracted from these studies. From the studies in this literature review, it appears that Triple-H therapy combined with administration of nimodipine is the first line of treatment or prevention of cerebral vasospasm. Once the vasospasm is deemed refractory to this

Author/Date	Indication for Endovascular Treatment
Feng, 2002	Verapamil was given "to prevent catheter-induced vasospasm," for treatment of mild vasospasm that did not warrant angioplasty, and for the treatment of moderate to severe vasospasm that could not be safely treated with angioplasty
Firlik, 1997	CBF new region < 20 ml/100 g/minute were treated with angioplasty
Bejjani, 1998	Do angioplasty after failed HHH therapy; digital subtraction angiography performed first.
Kaku 1992	Angioplasty (to deliver papaverine) if onset of new neurological deficit not attributable to other causes, no evidence of infarction on CT, unsuccessful treatment of neurological deficit by conventional medical and pharmacological therapies, mean flow velocity 100 cm/sec or increase in mean flow velocity greater than 30 cm/sec w/in 24 hours in affected vessel by TCD, and vasospasm seen angiographically in location consistent with neurological deficit.
Terada, 1997	Endovascular therapy if new neurological signs appear after SAH, not deriving from hematoma, brain edema, or hydrocephalus, neurological signs are related to vascular territory of vasospasm, vessel diameter is less than 50% of initial diameter angiographically, no low density area is related to vasospasm on CT, clinical signs progress despite medical treatment, and ruptured aneurysm has been treated
Andaluz, 2002	Refractory vasospasm (not clearly defined) to HHH therapy; included if all aneurysm clipped or coiled before Day 3 after SAH, clinical vasospasm defined by the presence of a new neurologic deficit not explained by hydrocephalus, infection, electrolyte imbalance, or other medical complication, clinical vasospasm in patients treated with nimodipine and with symptoms not reversed by maximal HHH treatment, and endovascular therapy instituted w/in 12 hours of onset of symptoms
Eskridge, 1998	hypertensive therapy started if suspicion of vasospasm; angioplasty if new onset of a neurological deficit not attributable to other causes, no evidence of established cerebral infarction on CT scans, deficit persisting despite hypertensive, hypervolemic therapy, and angiographic evidence of vasospasm in a distribution that could explain the deficit
Rosenwasser, 1999	If new deficit, CT scan to eliminate hydrocephalus or bleeding. HHH therapy maximized to elevate MAP to 130-140 mm Hg. If not reversible then go to get angioplasty
Jestaedt, 2008	Clinical symptoms or high grade vessel narrowing (>70%)
Beck, 2006	HHH protocol; symptoms still then get MR; if PW DW mismatch then continue HHH; then DS angiography then TBA
Zwienenberg-Lee, 2008	Randomized to either angioplasty or no angioplasty
Frontera 2011	All patients digital subtraction angiography; vessels which responded to IACV and could not be treated with angioplasty only IACV; accessible vessels with residual vasospasm after IACV then TBA
Eskridge, 1990	Inclusion criteria included new onset of a neurologic deficit after subarachnoid hemorrhage that was not attributable to other causes, such as hydrocephalus, hematoma, mass effect, no evidence of infarction on CT scan, neurologic deficit not reversed by hypervolemic and hypertensive therapy, and angiographically apparent vasospasm in location responsible for deficit
Muizelaar, 2001	All patients had SAH and Fisher Grade III on CT scan w/in first two days of SAH; had to have surgical or neurointerventional treatment of ruptured aneurysm; then TBP could be performed

Fujii, 1995	developed symptomatic vasospasm in spite of intensive medical supportive therapy including hypertension, volume expansion, and administration of brain protective agents, the cases whose showed either consciousness deterioration worse than 30 in Japan Coma Scale and/or distinct neurological deficit, and cases whose angiogram performed as early as possible after emergence of symptoms showed the responsible narrowing in intracranial arteries.
Jun, 2010	Severe proximal CV (luminal narrowing >60%) treated with PTA and distal CV (luminal narrowing >30%) with verapamil
Choi, 2011	CT scan in patients with clinical deterioration; vasospasm defined as increase in TCD flow to 150 cm/second. If greater than 150 cm/second, MRI, DWI and MRA; if infraction or narrowing by MRA, angioplasty was recommended
Santillan, 2011	Indication for TBA neurological deficits were referable to vascular territory of the VSP angiographically, vessel diameter less than 50% of initial diameter angiographically, no evidence of hypodensity on non-contrast head CT scan suggestive of ischemic infarct due to VSP prior to angiogram, and baseline diameter of vessel on initial cerebral angiogram or CT was not less than approximately 2 mm in size.
Murai, 2005	DINDs assumed vasospasm if between 3-14 days after SAH; some had angiograms to determine vasospasm (50% or more narrowing when compared to admission CT); heparinization w/angioplasty if deficit could be related to distribution of vasospasm
Coyne, 1994	Symptomatic vasospasm defined as onset of delayed neurological deficit (2 or more decrease on Glasgow Coma Scale); treated initially with hypervolemia, hypertensive therapy; maintain a capillary wedge pressure of 14 to 18 mm Hg. Maintain a systolic BP of 240 mm HG in clipping or 160 mm HG in unclipped; angioplasty if neurological deficit/CT showed no improvement

Table 2.

treatment, invasive treatments should be employed next. A combination of verapamil or papaverine to treat distal vasospasm with angioplasty to treat proximal vasospasm in larger, more available vessels falls in line with conclusions of many of the studies reviewed. Timing of invasive treatments may also prove to be critical. Rosenwasser's retrospective study finds improved clinical and angiographic outcomes in patients treated with angioplasty within a two hour window (Rosenwasser et al, 1999). Therefore, combined intra-arterial treatment with either papaverine or verapamil and angioplasty within a timely manner appears to be the most effective treatment.

8. Unclear role of vasospasm in clinical outcomes

A review of the literature on invasive treatments for cerebral vasospasm has highlighted a possible disconnect between the presence of cerebral vasospasm and clinical outcome. Frontera's group and Macdonald's group respectively find that Transcranial Doppler Velocities (Frontera et al, 2009) and angiography (Macdonald et al, 2008), consistent with cerebral vasospasm, are not necessarily predictors of a specific clinical outcome. These findings have led to the hypothesis that other mechanisms, after aSAH, may be responsible for poor clinical outcomes. Specifically, early brain injury, before the onset of vasospasm, has been explored. Classically, cerebral vasospasm is thought to occur between four and nine days after the ictus. Early brain injury, defined as injury within 72 hours of the aSAH, may provide insight into poor clinical outcomes after aSAH (Pluta et al, 2009). Within these 72 hours, early brain injury has been associated with an elevation of intracranial pressure, a

reduction in cerebral blood flow, blood-brain barrier disruption and neuronal cell death (Pluta et al, 2009). These changes, and not cerebral vasospasm, may be responsible for the subsequent clinical outcome.

Another recently proposed mechanism for the development of poor clinical outcomes has also been suggested. A mixture, similar to that of cerebrospinal fluid after SAH, has been shown to cause spreading cortical depolarization after application to the subarachnoid space (Pluta et al, 2009). This, in turn, has led to eventual ischemia and cortical necrosis. Similarly, 13 out of 18 patients, receiving surgical treatment after aSAH, have been shown to have similar waves of depolarization, consistent with the start of clinical deterioration (Pluta et al, 2009). Therefore, in addition to vasospasm, early brain injury and spreading cortical depolarization should be investigated for their importance in clinical outcomes.

9. Future directions in the treatment of cerebral vasospasm

Theoretically, endovascular therapy for cerebral vasospasm may include treatments other than intra-arterial pharmaceutical administration and cerebral artery angioplasty. Komotar et al. mention the possibility of using intra-aortic balloon counterpulsation to treat vasospasm. In this technique, an aortic balloon is placed distally to the origin of the left subclavian artery endovascularly. During diastole, the balloon inflates, redirecting blood to the coronary, carotid, and vertebral arteries in this part of the cardiac cycle (Komotar et al, 2008). The balloon then deflates during systole. The authors of this study report an average increase in cerebral blood flow by 69.3% (Nussbaum et al, 1998). Since the goal of Triple-H therapy is to improve cerebral blood flow, the intra-aortic balloon might be used in combination therapy with medical treatment for the reduction of cerebral vasospasm and ischemia after aSAH. As this device is implanted in the femoral artery, risks such as hemorrhage and dissection of the femoral artery are present (Komotar et al, 2008). A case report, by Appelboom et al., describes a similar procedure with a Neuroflo, intra-aortic, dual balloon catheter. In this report, two balloons, one above and one below the renal arteries, are inflated to redirect blood flow to the cerebral arteries during refractory vasospasm. An advantage of this technique is the avoidance of complications associated with direct manipulation of cerebral vasculature (Appelboom et al, 2010).

The future of cerebral vasospasm therapy depends on further elucidation of the pathophysiology of this condition. Komotar et al. report initial success with another free radical trapping agent. Just like tirilizad mesylate, disodium 2,4-disulfophenyl-N-tert-butyl nitron inhibits lipid peroxidation and has been associated with improvement in neurological function in primates (Komotar et al, 2008). Other evidence has suggested that the pathogenesis of vasospasm may depend on the immune system. Preventing the interaction between leukocytes and endothelial cells with blocking antibodies has also inhibited vasospasm after aSAH (Baybek et al, 1998). Similarly, patients undergoing therapy with steroids have a lower risk of developing delayed ischemic deficits after aSAH (Chyatte et al, 1987). The interplay between the immune system and development of cerebral vasospasm needs to be further investigated before immune modulating therapy can be directed towards the treatment of vasospasm.

10. Conclusion

A review of the literature on endovascular treatment for cerebral vasospasm has suggested the need for commonly used protocols and definitions to determine the efficacy of these

therapies. Although most studies in this review provided protocols that used Triple-H therapy and nimodipine as a first line treatment for cerebral vasospasm, the variation in institutional protocols in these studies made comparisons difficult. Similarly, the absence of a unifying or “gold standard” definition of vasospasm suggests that different indications in each study might call for the same treatment. Given that studies in this analysis use either CT angiography, symptoms, or Transcranial Doppler Velocities to assess for vasospasm, it is difficult to know if each study would treat the same patient for the same degree of vasospasm. It is therefore difficult to compare the results of different studies, investigating the same treatment. Similarly, the actual endovascular therapy, either intra-arterial medical treatment or transluminal angioplasty, was not the same in each study. Both the dosage of intra-arterial drug administered and the type and size of angioplasty balloon differed amongst the studies in this review of the literature.

The retrospective nature and small sample size of an overwhelming majority of the studies in this review call for a newly designed, novel study in the endovascular treatment of vasospasm. Zweinenberg-Lee et al. provide data from a Phase II, Multicenter, Randomized, Clinical Trial assessing the effects of prophylactic angioplasty on infarction rates after cerebral vasospasm. The results of this trial, that prophylactic angioplasty provided an absolute risk reduction of 5.9% for developing an infarction after cerebral vasospasm (Zweinenberg-Lee et al, 2008), may serve as a model for future trials assessing the efficacy of endovascular treatments of vasospasm although not all the data were statistically significant. Future research on endovascular treatment of vasospasm should also follow the study design of trials investigating non-endovascular, pharmaceutical therapy for vasospasm. These studies, included in Etminan’s meta-analysis, are prospective, randomized, adequately blinded, and placebo or vehicle controlled (Etminan et al, 2011).

This literature review has highlighted the need for a highly controlled, randomized, multicenter, clinical trial, assessing the efficacy of endovascular treatment. A randomized, controlled, clinical trial placing patients into either an intra-arterial papaverine group, an intra-arterial verapamil group, an intra-arterial papaverine and angioplasty group, an intra-arterial verapamil and angioplasty group, and an angioplasty group alone would provide the groundwork for a standardized protocol for effectively treating cerebral vasospasm endovascularly. Similarly, future studies should investigate vasospasm’s role in affecting clinical outcomes and possible novel treatments. The future of vasospasm treatment, however, depends on further elucidation of the pathophysiology of vasospasm after aSAH. The role of the immune system and lipid peroxidation after aSAH should be investigated in the pathogenesis of this condition.

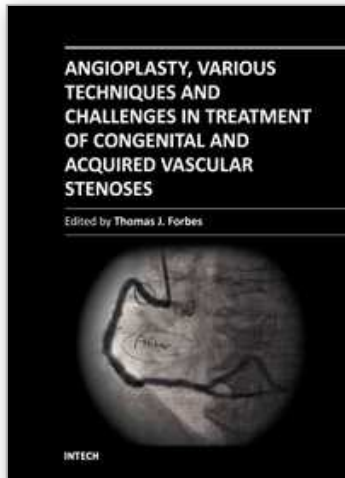
11. References

- Al-Tamimi YZ, Orsi NM, Quinn AC, Homer-Vanniasinkam S, Ross SA (2010) A review of delayed ischemic neurologic deficit following aneurysmal subarachnoid hemorrhage: historical overview, current treatment, and pathophysiology. *World Neurosurg* 73(6): 654-67.
- Andaluz N, Tomsick TA, Tew JM, van Loveren HR, Yeh HS, Zuccarello M (2002) Indications for endovascular therapy for refractory vasospasm after aneurysmal subarachnoid hemorrhage: Experience at the University of Cincinnati. *Surgical Neurology* 58:2 131-138.

- Appelboom G, Strozyk D, Hwayng BY, Prowda J, Badjatia N, Helbok R, Meyers PM (2010) Bedside Use of a Dual Aortic Balloon Occlusion for the Treatment of Cerebral Vasospasm. *Neurocrit Care* 13:385-388.
- Bavbek M, Polin R, Kwan AL, Arthur AS, Kassell NF, Lee KS (1998) Monoclonal antibodies against ICAM-1 and CD18 attenuate cerebral vasospasm after experimental subarachnoid hemorrhage in rabbits. *Stroke* 29(9):1930-5.
- Bejjani GK, Bank WO, Olan WJ, Sekhar LN (1998) The efficacy and safety of angioplasty for cerebral vasospasm after subarachnoid hemorrhage. *Neurosurgery* 42(5): 979-986.
- Charpentier C, Audibert G, Guillemin F, Civit T, Ducrocq X, Bracard S, Hepner H, Picard L, Laxenaire MC (1999) Multivariate analysis of predictors of cerebral vasospasm occurrence after aneurysmal subarachnoid hemorrhage. *Stroke* 30: 7 1402-1408.
- Choi BJ, Lee TH, Lee JI, Ko JK, Park HS, and Choi CH (2011) Safety and Efficacy of Transluminal Balloon Angioplasty Using a Compliant Balloon for Severe Cerebral Vasospasm after an Aneurysmal Subarachnoid Hemorrhage. *J Korean Neurosurg Soc.* 49(3): 157-162.
- Chou SH, Smith EE, Badjatia N, Noguera RG, Sims JR 2nd, Ogilvy CS, Rordor GA, Ayata C (2008) A randomized, double-blind, placebo-controlled pilot study of simvastatin in aneurysmal subarachnoid hemorrhage. *Stroke* 39(10): 2891-3.
- Chyatte D, Fode NC, Nichols DA, Sundt TM Jr (1987) Preliminary report: effects of high dose methylprednisolone on delayed cerebral ischemia in patients at high risk for vasospasm after aneurysmal subarachnoid hemorrhage. *Neurosurgery* 21(2):157-60.
- Coenen VA, Hansen CA, Kassell NF, Polin RS (1998) Endovascular treatment for symptomatic cerebral vasospasm after subarachnoid hemorrhage: transluminal balloon angioplasty compared with intraarterial papaverine. *Neurosurg Focus* 5 (4): Article 6.
- Coyne TJ, Montanera WJ, Macdonald RL, Wallace MC (1994) Percutaneous transluminal angioplasty for cerebral vasospasm after subarachnoid hemorrhage. *Can J Surg* 37(5): 391-396.
- Dupont SA, Wijedicks EF, Lanzino G, Rabinstein AA (2010) Aneurysmal subarachnoid hemorrhage: an overview for the practicing neurologist. *Semin Neurol* 30(5): 545-54.
- Elliott JP, Newell DW, Lam DJ, Eskridge JM, Douville CM, Le Roux PD, Lewis DH, Mayberg MR, Grady MS, Winn, HR (1998) Comparison of balloon angioplasty and papaverine infusion for the treatment of vasospasm following aneurysmal subarachnoid hemorrhage. *J Neurosurg* 88: 277-284.
- Eskridge JM, McAuliffe W, Song JK, Deliganis AV, Newell DW, Lewis DH, Mayberg MR, Winn RH (1998) Balloon Angioplasty for the Treatment of Vasospasm: Results of First 50 Cases. *Neurosurgery* 42 (3): 510-517.
- Eskridge JM, Newell DW, Pendleton GA (1990) Transluminal Angioplasty for Treatment of Vasospasm. *Cerebral vasospasm* 1(2) : 387-399.
- Etminan N, Vergouwen MD, Ilodigwe D, Macdonald RL (2011) Effect of pharmaceutical treatment on vasospasm, delayed cerebral ischemia, and clinical outcome in patients with aneurysmal subarachnoid hemorrhage: a systematic review and meta-analysis. *J Cereb Blood Flow Metab* 31(6):1443-1451
- Fathi AR, Bakthian KD, Pluta RM (2001) The role of nitric oxide donors in treating cerebral vasospasm after subarachnoid hemorrhage. *Acta Neurochir Suppl* 110: 93-97.
- Feng L, Fitzsimmons BF, Young WL, Berman MF, Lin E, Aagaard BDL, Duong H, Pile-Spellman J (2002) Intraarterially Administered Verapamil as Adjunct Therapy for

- Cerebral Vasospasm: Safety and 2-Year Experience. *AJNR AM J Neuroradiol* 23: 1284-1290.
- Findlay JM (1995) A randomized trial of intraoperative, intracisternal tissue plasminogen activator for the prevention of vasospasm. *Neurosurgery* 37(5): 1026-7
- Firlik AD, Kaufmann AM, Jungreis CA, Yonas H (1997) Effect of transluminal angioplasty on cerebral blood flow in the management of symptomatic vasospasm following aneurysmal subarachnoid hemorrhage. *J Neuro surg* 86: 830-839
- Frontera JA, Fernandez A, Schmidt JM, Claassen J, Wartenberg KE, Badjatia N, Connolly ES, and Mayer SA (2009) Defining Vasospasm After Subarachnoid Hemorrhage: What Is the Most Clinically Relevant Definition? *Stroke* 40: 1963-1968; published online before print as doi:10.1161/STROKEAHA.108.54470
- Frontera JA, Gowda A, Grilo C, Gordon E, Johnson D, Winn RH, Bederson JB, Patel A (2011) Recurrent vasospasm after endovascular treatment in subarachnoid hemorrhage. *Acta Neurochir Suppl* 110 (Pt 2): 117-122.
- Fujii Y, Takahashi A, Yoshimoto T (1995) Effect of balloon angioplasty on high grade symptomatic vasospasm after subarachnoid hemorrhage. *Neurosurg Rev* (18): 7-13.
- Jun P, Ko NU, English JD, Dowd CF, Halbach VV, Higashida RT, Lawton MT, Hetts SW (2010) Endovascular Treatment of Medically Refractory Cerebral Vasospasm Following Aneurysmal Subarachnoid Hemorrhage. *AJNR AM J Neuroradiol* 31:1911-16.
- Kaku Y, Yonekawa Y, Tsukahara T, and Kazekawa K (1992) Superselective intra-arterial infusion of papaverine for the treatment of cerebral vasospasm after subarachnoid hemorrhage. *J Neurosurg* 77(6): 842-847.
- Katoh H, Shima K, Shimizu A, Takiguchi H, Miyazawa T, Umezawa H, Nawashiro H, Ishihara S, Kaji T, Makita K, Tsuchiya K (1999) Clinical evaluation of the effect of percutaneous transluminal angioplasty and intra-arterial papaverine infusion for the treatment of vasospasm following aneurysmal subarachnoid hemorrhage. *Neurol Res* 21(2): 195-203.
- Kassell NF, Haley EC Jr., Apperson-Hansen C, Alves WM (1996) Randomized, double-blind, vehicle-controlled trial of tirilazad mesylate in patients with aneurysmal subarachnoid hemorrhage: a cooperative study in Europe, Australia, and New Zealand. *J Neurosurg* 84(2):221-8.
- Kassell NF, Helm G, Simmons N, Phillips CD, Cail WS (1992) Treatment of cerebral vasospasm with intra-arterial papaverine. *J Neurosurg* 77(6): 848-852.
- Keuskamp J, Murali R, Chao KH (2008) High-dose intraarterial verapamil in the treatment of cerebral vasospasm after aneurysmal subarachnoid hemorrhage. *J Neurosurg* 108(3):458-463.
- Komotar, R, Zacharia, B, Mocco J, Connolly S (2008) Controversies in the endovascular management of cerebral vasospasm after intracranial aneurysm rupture and future direction for therapeutic approaches. *Neurosurgery* 62(4): 897-905.
- Macdonald RL, Kassell NF, Mayer S, Ruefenacht D, Schmiedek P, Weidauer S, Frey A, Roux S, Pasqualin A (2008) Clazosentan to overcome neurologic ischemia and infarction occurring after subarachnoid hemorrhage (CONSCIOUS-1): randomized, double-blind, placebo-controlled phase 2 dose-finding trial. *Stroke* 39(11):3015-21.
- Murai Y, Kominami S, Kobayashi S, Mizunari T, Teramoto A (2005) The long-term effects of transluminal balloon angioplasty for vasospasms after subarachnoid hemorrhage: analyses of cerebral blood flow and reactivity. *Surg Neurol* 64:122-127.

- Nussbaum ES, Sebring LA, Ganz WF, Madison MT (1998) Intra-aortic balloon counterpulsation augments cerebral blood flow in the patient with cerebral vasospasm: a xenon-enhanced computed tomography study. *Neurosurgery* 42(1):206-13.
- Oskouian RJ, Martin NA, Lee JH, Glenn TC, Guthrie D, Gonzalez NR, Afari A, Viñuela F (2002) Multimodal Quantitation of the Effects of Endovascular Therapy for Vasospasm on Cerebral Blood Flow, Transcranial Doppler Ultrasonographic Velocities, and Cerebral Artery Diameters. *Neurosurgery* 51:1 30-43.
- Pickard JD, Murray GD, Illingworth R, Shaw MD, Teasdale GM, Foy PM, Humphrey PR, Lang DA, Nelson R, Richards P (1989) Effect of oral nimodipine on cerebral infarction and outcome after subarachnoid hemorrhage: British aneurysm nimodipine trial. *Br Med J* 298: 636-642.
- Pluta RM, Hansen-Schwartz J, Dreier J, Vajkoczy P, Macdonald RL, Nishizawa S, Kasuya H, Wellman G, Keller E, Zauner A, Dorsch N, Clark J, Ono S, Kiris T, Leroux P, Zhang JH (2009) Cerebral vasospasm following subarachnoid hemorrhage: time for a new world of thought. *Neurol Res* 31(2):151-8.
- Rosenwasser RH, Armonda RA, Thomas JE, Benitez RP, Gannon PM, Harrop J (1999) Therapeutic modalities for the management of cerebral vasospasm: timing of endovascular options. *Neurosurgery* 44: 975-979.
- Santillan A, Knopman J, Zink W, Patsalides A, Gobin YP (2011) Transluminal balloon angioplasty for symptomatic distal vasospasm refractory to medical therapy in patients with aneurysmal subarachnoid hemorrhage. *Neurosurgery* [Epub ahead of print].
- Shankar JJ, dos Santos MP, Deus-Silva L, Lum C (2011) Angiographic evaluation of the effect of intra-arterial milrinone therapy in patients with vasospasm from aneurysmal subarachnoid hemorrhage. *Neuroradiology* 53(2): 123-128.
- Shibuya M, Suzuki Y, Sugita K, Saito I, Sasaki T, Takakura K, Nagata I, Kikuchi H, Takemae T, Hidaka H (1992) Effect of AT877 on cerebral vasospasm after aneurysmal subarachnoid hemorrhage. Results of a prospective placebo-controlled double-blind trial. *J Neurosurg* 76(4): 571-7.
- Terada T, Kinoshita Y, Yokote H, Tsuura M, Nakai K, Itakura T, Hyotani G, Kuriyama T, Naka Y, Kido T (1997) The Effect of Endovascular Therapy for Cerebral Artery Spasm, its Limitation and Pitfalls. *Acta Neurochir (Wien)* 139:227-234.
- Vergouwen MD, Meijers JC, Geskus RB, Coert BA, Horn J, Stroes ES, van der Poll T, Vermeulen M, Roos YB (2009) Biologic effects of simvastatin in patients with aneurysmal subarachnoid hemorrhage: a double-blind, placebo-controlled randomized trial. *J Cereb Blood Flow Metab* 29(8): 1444-53.
- Weant KA, Ramsey CN, and Cook AM (2010) Role of Intraarterial Therapy for Cerebral Vasospasm Secondary to Aneurysmal Subarachnoid Hemorrhage. *Pharmacotherapy* 30:4 , 405-417.
- Zubkov YN, Nikirov BM, Shustin VA (1984) Balloon catheter technique for dilatation of constricted cerebral arteries after aneurysmal SAH. *Acta Neurochir* 70(1-2): 65-79
- Zwienerberg-Lee M, Hartman J, Rudisill N, Madden LK, Smith K, Eskridge J, Newell D, Verweij B, Bullock MR, Baker A, Coplin W, Mericle R, Dai J, Rocke D, Muizelaar JP (2008) Effect of Prophylactic Transluminal Balloon Angioplasty on Cerebral Vasospasm and Outcome in Patients With Fisher Grade III Subarachnoid Hemorrhage: Results of a Phase II Multicenter, Randomized, Clinical Trial *Stroke* 39: 1759-1765.



Angioplasty, Various Techniques and Challenges in Treatment of Congenital and Acquired Vascular Stenoses

Edited by Dr. Thomas Forbes

ISBN 978-953-51-0084-3

Hard cover, 236 pages

Publisher InTech

Published online 14, March, 2012

Published in print edition March, 2012

The field of performing transcatheter interventions to treat vascular lesions has exploded over the past 20 years. Not only has the technology changed, especially in the arena of balloon/stent devices, but the techniques of approaching complex lesions has evolved over the past decade. Lesions that no one would have imagined treating back in the 1990's are now being done routinely in the catheterization suite. This book provides an update on the current techniques and devices used to treat a wide variety of lesions. Though, at first, the outward appearance of the topics appears to be varied, they are all related by the common thread of treating vascular lesions. We hope, by publishing this book, to accomplish two things: First, to offer insight from experts in their field to treat, both medically and procedurally, complex vascular lesions that we frequently encounter. Secondly, we hope to promote increased communication between areas of medicine that frequently don't communicate, between adult interventional cardiologists, pediatric interventional cardiologists, interventional radiologists, and neurosurgeons. Much can be learned from our respective colleagues in these areas which can further our own world of interventions.

How to reference

In order to correctly reference this scholarly work, feel free to copy and paste the following:

Geoffrey Appelboom, Adam Jacoby, Matthew Piazza and E. Sander Connolly (2012). Chapter 6 Evidence-Based Invasive Treatments for Cerebral Vasospasm Following Aneurysmal Subarachnoid Hemorrhage, Angioplasty, Various Techniques and Challenges in Treatment of Congenital and Acquired Vascular Stenoses, Dr. Thomas Forbes (Ed.), ISBN: 978-953-51-0084-3, InTech, Available from:

<http://www.intechopen.com/books/angioplasty-various-techniques-and-challenges-in-treatment-of-congenital-and-acquired-vascular-stenoses/evidence-based-invasive-treatments-for-cerebral-vasospasm-following-aneurysmal-subarachnoid-hemorrhage>

INTECH
open science | open minds

InTech Europe

University Campus STeP Ri
Slavka Krautzeka 83/A
51000 Rijeka, Croatia
Phone: +385 (51) 770 447
Fax: +385 (51) 686 166

InTech China

Unit 405, Office Block, Hotel Equatorial Shanghai
No.65, Yan An Road (West), Shanghai, 200040, China
中国上海市延安西路65号上海国际贵都大饭店办公楼405单元
Phone: +86-21-62489820
Fax: +86-21-62489821

www.intechopen.com

www.intechopen.com

IntechOpen

IntechOpen

© 2012 The Author(s). Licensee IntechOpen. This is an open access article distributed under the terms of the [Creative Commons Attribution 3.0 License](#), which permits unrestricted use, distribution, and reproduction in any medium, provided the original work is properly cited.

IntechOpen

IntechOpen