

# We are IntechOpen, the world's leading publisher of Open Access books Built by scientists, for scientists

**4,800**

Open access books available

**122,000**

International authors and editors

**135M**

Downloads

Our authors are among the

**154**

Countries delivered to

**TOP 1%**

most cited scientists

**12.2%**

Contributors from top 500 universities



**WEB OF SCIENCE™**

Selection of our books indexed in the Book Citation Index  
in Web of Science™ Core Collection (BKCI)

Interested in publishing with us?  
Contact [book.department@intechopen.com](mailto:book.department@intechopen.com)

Numbers displayed above are based on latest data collected.

For more information visit [www.intechopen.com](http://www.intechopen.com)



## Below the Knee Techniques: Now and Then

Daniel Brandão<sup>1,2</sup>, Joana Ferreira<sup>1,2</sup>,  
Armando Mansilha<sup>3,4</sup> and António Guedes Vaz<sup>1</sup>

<sup>1</sup>Angiology and Vascular Surgery Department  
Vila Nova de Gaia / Espinho Hospital Center

<sup>2</sup>Department of Biochemistry, Faculty of Medicine of the University of Porto

<sup>3</sup>Angiology and Vascular Surgery Department; São João University Hospital, Porto

<sup>4</sup>Faculty of Medicine of the University of Porto  
Portugal

### 1. Introduction

Critical Limb Ischemia (CLI) is defined as the presence of ischemic rest pain for more than two weeks or ischemic tissue loss associated with an absolute ankle pressure less than 50 mmHg or great toe pressure less than 30 mmHg (Norgren et al., 2007). Patients with CLI experience high amputation rates, significant morbidity and cardiovascular events exceeding those in patients with symptomatic coronary heart disease (Varu et al., 2010). In spite of recent developments in revascularization techniques and wound care centers, amputations continue to be performed, partly because patients with CLI are referred late to vascular surgeons (Varu et al., 2010). However, revascularization when compared with amputation have an overall lower perioperative mortality and enhanced long-term survival (Brosi et al., 2007; Varu et al., 2010). However, CLI is associated with multisegmental complex arterial lesions and consequently with high rates of revascularization failure (Allie et al., 2009). Specific features of the tibial vessels, such as the small caliber, the remote location, the slow flow of the distal bed, and the need of preserving runoff capacity, make this vascular territory particularly challenging for endovascular treatment (Blevins and Schneider, 2010). Meanwhile, continued technical improvements and very encouraging results have changed the paradigm of CLI therapy, until recently based on vein graft bypass. As so, the endovascular approach is, nowadays, the first-line modality for limb-threatening ischemia for a majority of authors (Allie et al., 2009; DeRubertis et al., 2007).

### 2. Epidemiology

CLI is a global epidemic, with high clinical, social and economic costs (Adam et al., 2005; Allie et al., 2009; Brosi et al., 2007). Its incidence in the United States (US) is estimated to be 50-100 per 10 000 every year (Adam et al., 2005). It affects 1% of the population aged 50 and older and the incidence roughly doubles in the over 70 age group (Allie et al., 2009). The prevalence of CLI is also higher in diabetic patients and its prognosis is even worst in this population: one of every four diabetics will face CLI within his/her lifetime, and a diabetic is at 7 to 40 times greater risk of an amputation than a non-diabetic (Allie et al., 2009). As so,

it is expected that the incidence of CLI would rise significantly with the current aging population and the expected increase in inactivity, obesity and consequently in diabetes (Allie et al., 2009; van Dieren et al., 2010). As a result and despite advances in medical therapies, the number of patients needing lower limb revascularization for severe limb ischemia will probably increase in the near future (Adam et al., 2005). Moreover, the diagnosis of CLI remains a predictor of poor survival and outcomes (Varu et al., 2010): the overall mortality in these patients approaches 50% at 5 years and 70% at 10 years (Varu et al., 2010). Within one year of being diagnosed with CLI, 20% to 25% will die and 40% to 50% of the diabetics will experience an amputation (Allie et al., 2009; Kroger et al., 2006). The economic impact of CLI is considerable. It has been assessed that the total cost of treating CLI in the US is \$10 to \$20 billion per year (Allie et al., 2009). The cost of follow-up, long-term care, and treatment for an amputee who remains at home has been estimated at \$49,000 per year compared to only \$600 to \$800 per year after limb salvage (Allie et al., 2009). It is estimated that just a 25% reduction in amputations could save \$2.9 to \$3.0 billion yearly in US healthcare costs (Allie et al., 2009). Despite the facts noted above, CLI is still poorly understood, infrequently reported and inconsistently treated (Allie et al., 2009).

### 3. The arterial lesions in patients with critical limb ischemia

CLI is highly predictive for failure of both primary and secondary patency, as a result of the increased prevalence of advanced lesion severity and treatment complexity (DeRubertis et al., 2007). There is several indicators of lesion severity in these patients: (1) increasing TASC grade (mostly C and D lesions); (2) multilevel intervention; (3) general involvement of tibial arteries in diabetic patients; (4) diffusely diseased tibial arteries (combination of long stenoses and occlusions); (5) reduced outflow bed (DeRubertis et al., 2007; Graziani et al., 2007; Ihnat and Mills, 2010).

## 4. Revascularization in CLI patients

### 4.1 Bypass surgery approach

Historically, infrainguinal autogenous saphenous vein bypass surgery has been considered the gold-standard therapy for CLI, with long-term anatomical patency, clinical durability and high limb salvage rates (Adam et al., 2005; Allie et al., 2009; Varu et al., 2010). The Pomposelli's classic report of more than 1000 pedal bypasses over a decade documented a 10-year primary patency rate of 37.7% and limb salvage rates of 57.8% (Pomposelli et al., 2003). Regrettably, most of these single center series were reported in optimal surgical candidates with favorable anatomy and adequate autogenous vein conduits (Allie et al., 2009). Furthermore, the durability of the vein graft may rely on routine ultrasonography surveillance, frequently leading to repeated prophylactic re-interventions and relevant resource utilization (Adam et al., 2005; Varu et al., 2010). Unfortunately an adequate vein is often unavailable and the long-term results of bypasses constructed with prosthetic graft are clearly much less satisfactory (Adam et al., 2005). The good results of infrainguinal surgery are not applicable to contemporary CLI patients who seldom have favorable anatomy and recurrently have poor autogenous conduits (Allie et al., 2009). Additionally, the *real world* CLI patients are frequently very elderly and have numerous medical issues, significantly increasing the mortality and morbidity associated with infrainguinal bypass (Allie et al., 2009; Brosi et al., 2007). Consequently the open surgery option could come at the cost of high morbidity and mortality, as well as substantial resource use (Adam et al., 2005).

Abou-Zamzam et al. analyzed the functional outcomes after surgery in CLI patients (Abou-Zamzam et al., 1997). This report aimed at identifying the *ideal* post-infrainguinal bypass results from CLI patient's functional perspective (Abou-Zamzam et al., 1997). The patient who survived the intervention, had his wounds healed at 6 months, was living independently and completely mobile, was defined as the *ideal functioning* patient (Abou-Zamzam et al., 1997). Disappointingly, despite excellent graft patency and limb salvage rates, only 14.3% of their infrainguinal bypass patients achieved the *ideal* result at 6 months (Allie et al., 2009). Avoidance of incisional wound creation and subsequent common healing problems have been strongly considered an advantage in favor of endovascular intervention versus infrainguinal bypass in our practice (Allie et al., 2009; Chung et al., 2006).

Meanwhile, in patients expected to live more than two years and who were fit, the apparent improved durability and reduced re-intervention rate of surgery might outweigh the short-term considerations of increased morbidity and cost (Adam et al., 2005).

#### 4.2 Endovascular approach

The endoluminal therapy for lower extremity occlusive disease has extraordinarily evolved in the last decade and the armamentarium now available for the vascular interventionist is quite considerable (DeRubertis et al., 2007). This has allowed an impressive expansion of the endovascular approach in complex, formerly considered unachievable, infra-inguinal lesions (Allie et al., 2009). As a result, the endoluminal intervention is now considered the first-line treatment in CLI patients for a majority of authors.

In addition, the understanding of CLI patients had improved considerably (Allie et al., 2009). The so called *limb salvage-graft patency gap* has been consistently identified in all infrainguinal bypass surgery reports regardless of conduits (Allie et al., 2009). Even after an occlusion of an infrainguinal bypass graft following limb salvage, the limb will oftentimes remain viable and not regress back to CLI since the blood flow and metabolic needs to achieve wound healing in CLI are much greater than to keep viability (Allie et al., 2009). This paradigm shift has opened the door to a potential change of the goals in the post procedural follow-up of the CLI patients from vessel patency to limb salvage. This has become the cornerstone in treating CLI patients, allowing an impressive expansion of endovascular therapy indications (Allie et al., 2009).

In fact, scrutinizing the data of endovascular approach for CLI treatment from the last decade shows very encouraging results in regard to limb salvage.

Dorros et al. used percutaneous transluminal angioplasty (PTA) as the first treatment in 235 CLI patients with a 91% 5-year limb salvage rate and a small number of complications (Dorros et al., 2001).

Faglia et al. reported tibial PTA as primary treatment in 993 CLI diabetic patients. During a 26±15 months follow-up, only 1.7% underwent major amputation. Limb salvage was achieved in more than 98% of patients and an 88% 5-year primary clinical patency rate was described (Faglia et al., 2005).

Kudo et al. also published a 10-year PTA experience in 111 CLI patients. A 0.9% procedural mortality and a 96.4% technical success rate were described. The 5-year limb salvage rate was 89.1% (Kudo et al., 2005). The same authors published their 12-year experience of tibial PTA versus bypass surgery in 192 CLI patients. They further concluded that PTA was safe and effective, pointing it as the primary treatment for CLI (Kudo et al., 2006).

A meta-analysis of 30 articles from Romiti et al. looked at immediate technical success, primary and secondary patency, limb salvage, and survival after infrapopliteal PTA in CLI patients. The results were compared with a meta-analysis of popliteal-to-distal vein bypass graft that the authors had previously published (Albers et al., 2006). Even if there was a significant difference in favor of vein bypass concerning durability, the limb salvage rates were equivalent between both techniques (Albers et al., 2006; Romiti et al., 2008).

From the data presented, it results that endovascular approach is currently considered as the first-line treatment for CLI patients with below-the-knee arteries involvement.

## **5. Below-the-knee intervention – Technical issues**

### **5.1 Access**

The access for below the knee (BTK) vessels can be granted either by antegrade ipsilateral approach or by retrograde contralateral approach.

#### **5.1.1 Antegrade ipsilateral approach**

As it allows a nearer distance to the tibial arteries, the antegrade technique permits the utilization of shorter devices, which leads to an improvement of the guidewires and catheters' characteristics like pushability, torqueability, crossability or trackability. As a result, it may become easier to treat complex lesions as long occlusions, distal lesions as in foot vessels or use complex techniques like the pedal-plantar loop technique. However, the antegrade puncture implies that the iliac arteries and the proximal superficial femoral artery are free of significant disease. Even if the pattern of arterial involvement in diabetic, CLI patients is mostly at BTK level, the presence of palpable femoral and popliteal pulses should not be considered as synonym of absence of an upstream significant lesion. As so, an arterial ultrasound of the iliac and femoral arteries should be previously performed to insure that an adequate inflow is available. Moreover, the antegrade approach can be difficult in obese patients. In those patients, some tricks can help in turning the puncture easier: (1) wrap the abdominal pannus with tape in cranial and contralateral directions; (2) put a folded sheet under the ipsilateral hip; (3) place the patient in Trendelenburg position; (4) consider longer needles; (5) consider reinforced sheaths (e.g. SuperArrow® Flex). The antegrade technique is also more prone to local complications and should be performed using a single wall needle to avoid a double puncture and its consequent additional potential problems. It should also be completed under fluoroscopy to localize the femoral head and puncture the common femoral artery (Dotter et al., 1978; Grier and Hartnell, 1990). In hostile heavily scarred groins or in very obese patients, ultrasound guided puncture of either the common femoral or the superficial femoral arteries may reduce radiation doses, screen times and complications (Biondi-Zoccai et al., 2006; Marcus et al., 2007; Yeow et al., 2002).

#### **5.1.2 Retrograde contralateral approach**

Contralateral puncture is technically easier to achieve and safer in regard to local complications (Nice et al., 2003). It permits performing a strategic arteriography and the correction of proximal iliac and femoral lesions. It allows a more secure utilization of closure devices and maintains the puncture site remote from the treated segment. The utilization of long sheaths especially designed for BTK intervention (e.g. Cook® Shuttle Tibial) may provide additional external support, allowing intervention in more demanding cases, but



potentially increasing total costs. Meanwhile, distal lesions are still difficult to reach and unfavorable aortic bifurcations or aortic grafts may preclude its utilization.

Table 1 summarizes the advantages and disadvantages of each approach.

	Antegrade access	Contralateral access
More complex and distal lesion	√	
Iliac and proximal SFA lesions		√
More technically demanding	√	
More frequent local complications	√	
Remote access from treated segment		√
Safer closure devices utilization		√

Table 1. Antegrade and contralateral retrograde access

## 5.2 Tibial vessel selection for intervention – The key step

Perhaps the most critical decision in revascularizing CLI patients with predominant BTK arteries involvement is to decide which vessel(s) should be approached to achieve successful limb salvage. In spite of arbitrarily recanalize a tibial artery only based on arteriography, one should consider some basic and prevailing principles.

### 5.2.1 Angiosome model

The angiosome concept was initially described in plastic and reconstructive surgery papers and was intended to provide the basis for a logical planning of incisions and flaps (Taylor and Palmer, 1987; Taylor and Pan, 1998). These anatomical studies delineated three-dimensional anatomic units of tissue (from skin to bone) fed by a given source artery, defined as angiosomes. In foot it has been described six angiosomes, arising from the posterior tibial artery (n=3), the anterior tibial artery (n=1), and the peroneal artery (n=2) (figure 1). The posterior tibial artery gives rise to a calcaneal branch that supplies the medial ankle and plantar heel, a medial plantar artery that feeds the medial plantar instep and a lateral plantar artery that supplies the lateral forefoot, plantar midfoot and entire plantar forefoot. The anterior tibial artery continues as the *dorsalis pedis* artery feeding the dorsum of the foot. The peroneal artery supplies the lateral ankle and plantar heel via the calcaneal branch and the lateral anterior upper ankle via an anterior perforating branch. Alexandrescu et al. applied more recently this angiosome model to guide endovascular procedures in diabetic CLI patients with remarkable results (Alexandrescu et al., 2008). This rational approach for the revascularization of the foot was followed by several authors who confirmed its relevance for ulcer healing and consequent limb salvage (Alexandrescu et al., 2011; Iida et al., 2010; Neville et al., 2009). In fact, Iida et al. analyzed 203 limbs in 177 patients and separated them into direct and indirect groups depending on whether feeding artery flow to the site of ulceration was successfully acquired or not based on the angiosome concept. They found that limb salvage rate was significantly higher in the direct group (86%) than in the indirect group (69%) for up to 4 years after the procedure (Iida et al., 2010).

Lately, Alexandrescu et al. compared 213 CLI limbs revascularized prior (n=89) and after (n=134) the introduction of the angiosome model. They also concluded that angiosome-targeted revascularization was associated with significantly higher limb preservation (89% vs. 79% at 36 months) (Alexandrescu et al., 2011). To simply allow pulsatile flow to the correct portion of the foot is the contemporary paramount for ulcer healing.

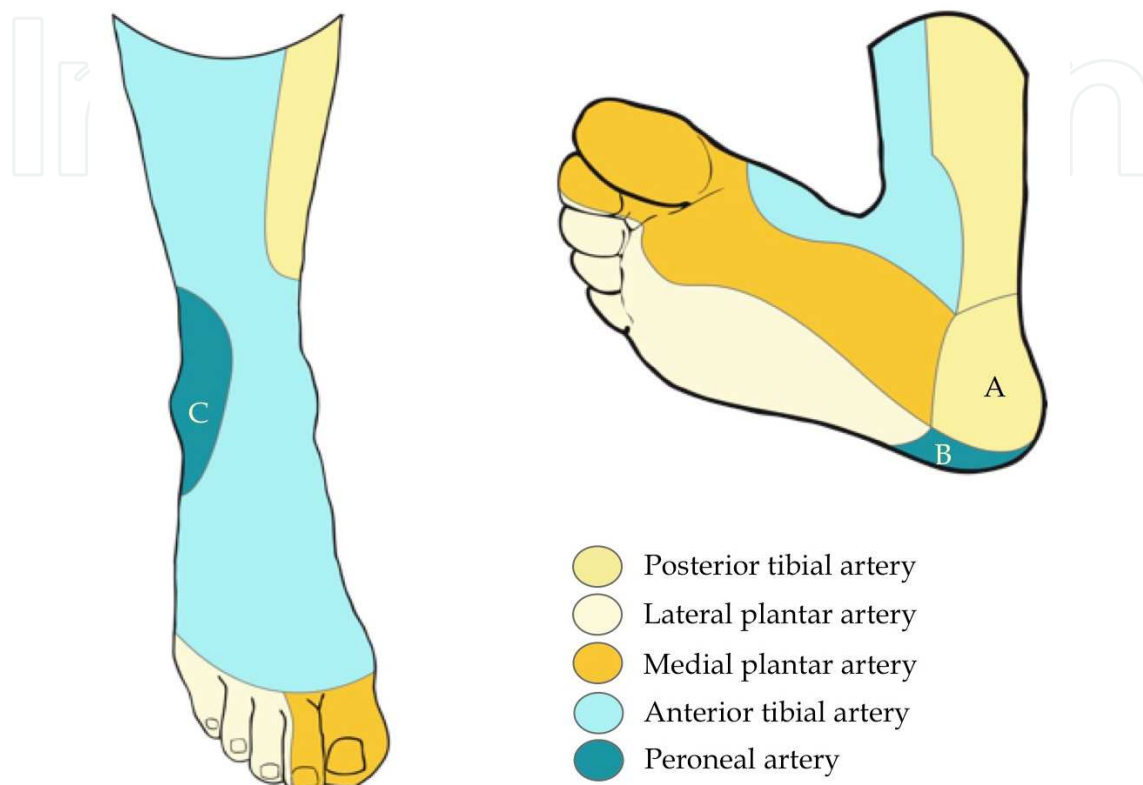


Fig. 1. Angiosome model. A - Calcaneal branch of the posterior tibial artery. B - Calcaneal branch of the peroneal artery. C - Anterior perforating branch of the peroneal artery.

### 5.2.2 Additional concepts

Adjacent angiosomes are bordered by reduced caliber (choke) or artery-similar caliber (true) anastomoses, which link neighboring angiosomes to one another and demarcate the border of each angiosome (Attinger et al., 2006; Taylor and Pan, 1998). In addition, these vessels are important safety conduits that allow a given angiosome to provide blood flow to an adjacent angiosome if the latter's source artery is damaged.

This concept should be taken into account in CLI limb revascularization. In fact, after having revascularized the key artery according to the angiosome concept, one may consider revascularizing other tibial vessels. The rationale to do so can be based on: (1) limited permeability rates with current angioplasty techniques may compromise the feeding artery before complete lesion healing; (2) trophic lesion may include more than one angiosome. Nevertheless, this attempt should never place the recanalized feeding artery at risk.

Meanwhile, some technical issues, as the lack of visible run-off, the presence of heavy calcification precluding transluminal or subintimal occlusion crossing, an occlusion at an arterial bifurcation (like the anterior tibial artery origin) or the presence of an important collateral at the beginning of an occlusion may restrict or prevent revascularization

according to the angiosome model. In those circumstances, approaching an alternative tibial vessel considering the anastomoses between angiosomes may be the only option available in trying to preserve a CLI limb.

### 5.3 BTK Recanalization

In the past, the BTK interventional techniques were performed with large caliber, non-specific instruments, which resulted in poor results and skepticism upon its applicability in this specific sector. The relative similarity between BTK and coronary vessels led vascular interventionists to employ low profiling coronary devices, which improved outcomes. Additional developments brought specifically designed devices, achieving results that changed the paradigm of CLI patients treatment approach.

#### 5.3.1 Imaging

Fluoroscopy is supposed to have high resolution (less than 0.3 mm), should allow roadmapping and overlay techniques and must permit a high range of angulation. In fact, the last point is highly relevant since some significant lesions can be occulted or underestimated by standard posterior-anterior view. Moreover, oblique incidences allow clear observation of tibial vessels avoiding superposed bone and potentially revealing useful calcifications that can be used as *natural roadmapping*.

#### 5.3.2 Guidewires

One may start with a 0.035" regular angled guidewire™ to cross simple stenoses. However, more complex lesions must be addressed with specific guidewires.

Vascular specialists began BTK treatment with some scarcity of options in regard to guidewires, but currently there has been an increasing choice in this particular matter (Table 2).

Tip load, tip stiffness, hydrophilic/hydrophobic coating of the tip and body, guidewire flexibility, ability to shape, shaping memory, shaft support, torque transmission, trackability, and pushability are all critical components for a BTK intervention guidewire, especially for chronic total occlusions (CTOs) (Godino et al., 2009) (see tables 2 & 3).

The selection should consider some specificities of the lesion: (1) the localization (some authors prefer 0.018" guidewires for tibial arteries, leaving 0.014" guidewires for pedal arteries); (2) CTO or stenosis (occlusions may require specifically designed tip); (3) length (long lesions, especially CTOs, usually demand additional support to allow the passage of other interventional devices).

Non-hydrophilic guidewires allow a better tactile feel and a more controlled torque response when compared with hydrophilic wires. They are less likely to cause dissection of a vessel but have a higher resistance within the lesion, which may decrease the chances of successful crossing, particularly in CTOs. To counterweigh this, some uncoated, spring-coil wires have a specifically designed tapered-tip which confers more penetrating power to the tip. On the other hand, some guidewires may have, rather than increased sharpness, greater tip stiffness due to weights addition, which increases their penetration ability.

Hydrophilic wires typically advance with minimal resistance, providing good maneuverability in tortuous and long vessels but at a cost of reduced tactile feel. They are also more prone in penetrating beneath plaque inducing a dissection of the vessel.



0.014" Guidewires	Hydrophilic		Tapered tip	Tip stiffness (g)	Remarks
	tip	body			
Abbott HT Winn™ 40, 80, 200	Y	HF	Y (0.012-0.009")	4.8, 9.7, 13	BTK GW
Abbott Pilot™ 50, 150, 200	Y	Y	N	2,4,6	Coronary GW
Abbott Wisper LS, MS, ES	Y	N	N	1	Coronary GW
Asahi Confianza™	N	N	Y (0.009")	9	Coronary GW
Asahi Intecc Miracle™	N	N	N	3, 4.5, 6, 9, 12	Coronary GW
Biotronik Cruiser® Hydro MS, ES	Y	N	N	0.27	Coronary GW
Biotronik Cruiser® MS, ES	HF	N	N	0.27	Coronary GW
Biotronik XT-14	Y	N	N	NA	BTK GW
BS PT Graphix™; Grafix P2™ LS, MS	Y	Y	N	3-4	Coronary GW
Cook Approach® Hydro ST	Y	N	N	NA	BTK GW
Cook Approach® CTO	N	N	N	6, 12, 18, 25	BTK GW
Cordis Shinobi™	Y	N	N	2	Coronary GW
Medtronic Provia™	N	Y/N	Y (0.009")*1	3, 6, 9, 12, 15	BTK GW

Table 2. Possible 0.014" guidewires for BTK purposes. BS - Boston Scientific. LS, MS, ES (light, medium, and extra support). Y/N - Both versions are available. \*1 - Only in the 9, 12 and 15 g tips. GW - Guidewire; HF hydrophobic; NA - Not Available.

0.018" Guidewires	Hydrophilic		Tapered tip	Tip stiffness (g)	Remarks
	tip	body			
Abbott SteelCore 18 LT	N	N	N	NA	
Biotronik Cruiser® 18	Y	N	N	NA	Increased body stiffness
BS V-18™ Control Wire®	Y	N	N	3-4	Increased body stiffness
Cook Roadrunner® ES	N	N	N	NA	Increased body stiffness

Table 3. Possible 0.018" guidewires for BTK purposes. BS - Boston Scientific; NA - Not Available.

### 5.3.3 Chronic Total Occlusions (CTOs)

CTOs are generally defined as occluded arteries of three months duration or longer (Stone et al., 2005). CTOs are characterized by proximal and distal fibrous caps, a mix of luminal *soft* and *hard* plaque, thrombin, fibrin, inflammatory cells (in the intima, media, and adventitia), and neovascularization. The plaque is composed of a collagen rich extracellular matrix, intra, and extracellular lipids, smooth muscle cells, and calcium (Katsuragawa et al., 1993; Srivatsa et al., 1997). The proximal and distal caps have higher concentrations of collagen and calcium (fibrocalcific), even if the distal cap is frequently softer than the proximal cap (Fefer et al.,

2010). This may explain, at least partially, the relative ease in crossing tibial CTOs by retrograde pedal approach. The composition of the core correlates with CTO age. Older CTOs have higher concentrations of fibrocalcific material (“*hard plaque*”), while CTOs present for less than one year have more cholesterol clefts and foam cells among less fibrous material (“*soft plaque*”). This may, in part, explain the greater simplicity in crossing these younger CTOs.

Neovascularization starts early, as part of the organization of the CTO, and increases with time. As it has been demonstrated in coronary arteries, many CTOs are not completely occluded when examined under the microscope (Srivatsa et al., 1997). In fact, the new sprouting vessels, in contrast with *vasa vasorum* that run in radial directions, proceed within and parallel to the occluded parent vessel (Strauss et al., 2005). As a result they may originate microchannels throughout the CTO which diameter can vary between 100 and 500  $\mu\text{m}$  (Srivatsa et al., 1997; Stone et al., 2005). Those can be used to engage the tip of the guidewire, which can further help in crossing CTOs. In this particular matter, tapered tips increase the ability to insert the guidewire in those microchannels, while hydrophilic tips are more prone to progress inside them.

### 5.3.3.1 Crossing CTOs

According to the lesion and the guidewire, different techniques to penetrate CTOs fibrous caps may be applied.

#### 5.3.3.1.1 Antegrade techniques

In the *drilling technique*, the tip is bended in a short extension and clockwise and counter-clockwise rotations of the guidewire are performed while the tip is pushed modestly against the CTO lesion (figure 2). The important issue in this technique is that one does not push the guidewire very hard. If the tip of the guidewire does not advance any more with gentle pushing, it is by far better to exchange for a stiffer wire, rather than continue pushing. If one pushes the wire hard, it will easily go into the subintimal space. Yet, when a stiff guidewire is used, it may be difficult to perceive whether the tip has been engaged in the true or in a false lumen inside the CTO. The movement of the tip may help in distinguishing one from the other. Typically, when the guidewire is in the subadventitial space, the tip budsges markedly. Additionally, the extension of the tip curve may look exaggerated, especially when using floppy tip guidewires. Tactile feel from the guidewire during pullback can also aid as true lumen usually offers higher resistance. This technique has an increased risk of perforation, especially when using stiff tips guidewires and is not usually recommended for complex lesions (Godino et al., 2009; Kim, 2010).

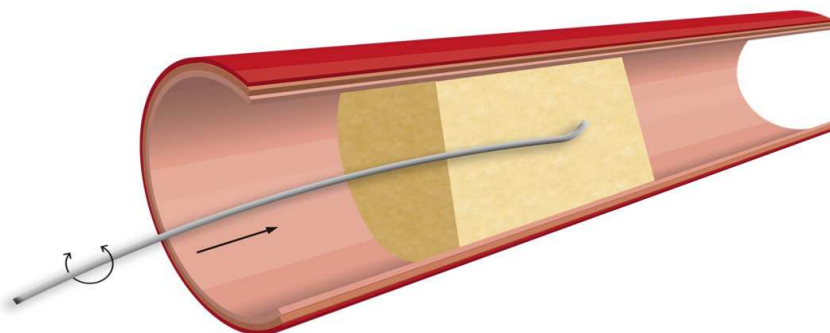


Fig. 2. Drilling technique.

In the *penetration technique*, the tip shape is usually straighter than in the drilling technique and a less rotational tip motion and a more direct forward probing is used (figure 3). Some heavily calcified CTO caps may require the use of very aggressive guidewires to achieve passage using the described technique (tapered stiff tips and increased body support guidewires, like the Abbott HT Winn 200™). Additionally, the target has to be clearly identified and careful monitoring of the progressive guidewire advancement should be done. Only experienced interventionists should make use of this technique in difficult CTOs, due to the particularly augmented risk of complications.

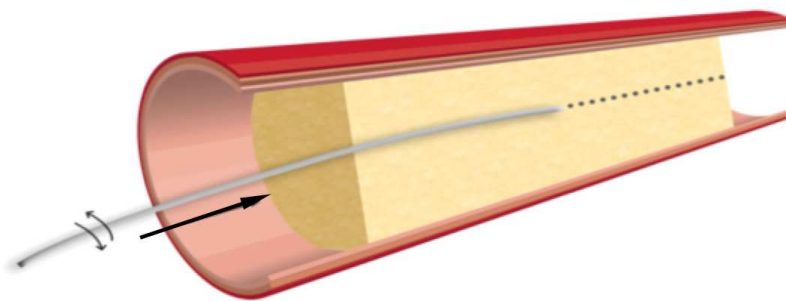


Fig. 3. Penetration technique.

The *sliding technique* utilizes hydrophilic guidewires. Reduced surface friction enhances passage through the CTO core. It is recommended that the tip is initially shaped with a single, long shallow bend and movement consists of simultaneous smooth tip rotation and gentle probing. The guidewire typically advances with minimal resistance and tactile feel, resulting frequently in inadvertent entry to the subintimal space.

This technique is particularly indicated for engaging softer CTOs with microchannels, subtotal occlusions or angulated lesions (Godino et al., 2009).

The *subintimal dissection technique* is usually performed when transluminal crossing has been unsuccessful. A hydrophilic guidewire with a floppy tip and an intermediate or stiff body is generally preferred. The loop is made with the floppy tip of the guidewire and should be relatively small to reduce the risk of perforation (figure 4).

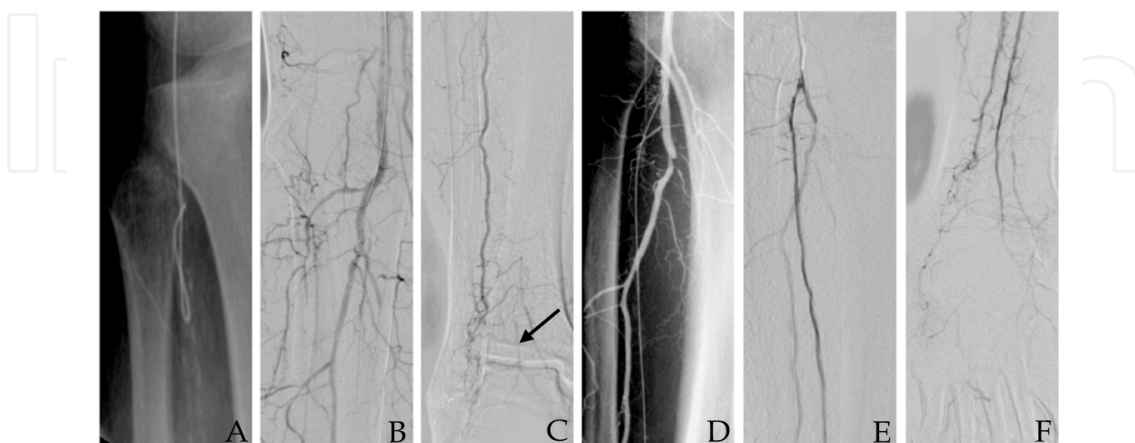


Fig. 4. A - Loop of the guidewire tip for *subintimal dissection* technique (BS V-18™ Control Wire®); B, C - Case of a long anterior tibial artery (ATA) occlusion (arrow pointing to distal ATA); D - Guidewire advanced subintimally all the way through ATA. E, F - Final result.

Highly calcified lesions may add some resistance to the guidewire progression, making predilatation necessary, and can, in addition, make difficult or impede re-entry in true lumen. Recoil is more common and care should be especially taken to avoid damaging collaterals. As subintimal space is larger than true lumen, the balloon should be slightly oversized (0.5 mm). In the *parallel wire technique*, when the initial wire passes into a dissection plane, it is left there using it as a reference point to assist in passing a second wire through the true lumen (figure 5). This technique has two main purposes: re-directing a wire inside the CTO and puncturing distal CTO fibrous cap.




Fig. 5. Parallel wire technique.

#### 5.3.3.1.2 Subintimal Arterial Flossing with Antegrade-Retrograde Intervention (SAFARI)

During antegrade recanalization, reentry into the distal true lumen can be difficult or impossible for several reasons. In those circumstances retrograde puncture has to be considered. This technique should also be envisaged when the proximal occlusion stump cannot be determined, which occurs most frequently with the anterior tibial artery (figure 6, case 1). It can be performed in all three leg arteries at the calf, ankle or foot levels. The puncture is performed under fluoroscopic guidance. Vessel calcification can be very useful. At the ankle or foot level, a 21 G, 4 cm long, needle can be used (the same needle used in a radial artery line placement). Crural level puncture implies a longer needle (21 G, 7 cm long, from a micropuncture kit). When the needle is in the artery lumen, a weak back-bleeding of arterial blood is observed. At that point, a 300 cm, 0.014", hydrophilic, intermediate or stiff shaft guidewire is engaged in the true lumen of the target vessel, subsequently assisted by a low profile support catheter or balloon catheter, without sheath placement. Subsequently, retrograde subintimal recanalization is carried out and continued until entry in the proximal true lumen or in the subintimal space from the antegrade approach is achieved. Sometimes, neither are obtained after several attempts. At that moment, the *rendez-vous technique* should be performed to break the membrane that separates the retrograde and antegrade subintimal spaces and, consequently, get continuity between them (figures 6-F and 7). At that time, the guidewire is typically snared or directed into the antegrade catheter or sheath to create a *flossing*-type guidewire which provides reliable access and adequate support (as it is fixed at both ends) for antegrade balloon angioplasty or stent placement (Figure 6) (Spinosa et al., 2003). When adequate flow has been reestablished into the target vessel, a catheter (diagnostic catheter, low profile support catheter or balloon catheter) is advanced distally to the lesion. The guidewire is then retrieved proximally, inverted and re-inserted (if not damaged). Hemostasis of the retrograde puncture site in foot and ankle is achieved by gentle local compression. At the calf level, hemostasis is performed by inflating a short balloon in the artery at the puncture site, usually for two minutes and at low pressure.



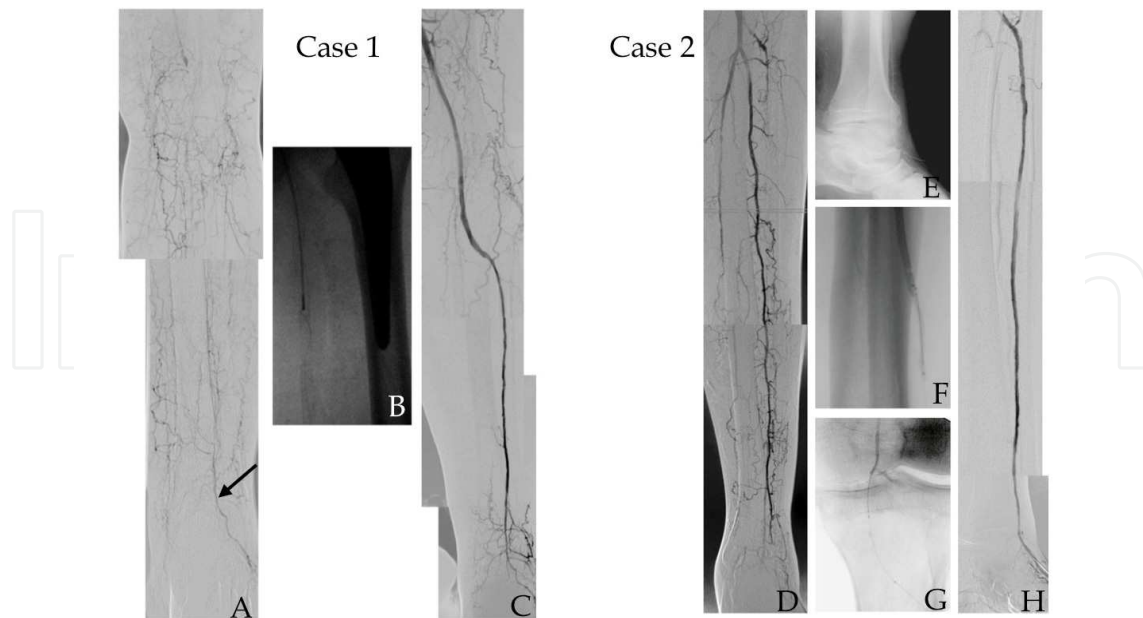


Fig. 6. SAFARI interventions. *Case 1.* A - Initial arteriography; occlusion of popliteal and all three tibial arteries (black arrow: patent *dorsalis pedis* artery). B - Snaring of the retrograde guidewire. C - Final result. / *Case 2.* D - Initial arteriography; patent peroneal artery, but ending in unsatisfactory collaterals (black arrow head: proximal anterior tibial artery). E - X-Ray showing percutaneous retrograde guidewire. F - *Rendez-vous* technique. G - Retrograde guidewire introduced inside 4F Bernstein catheter (the catheter should be turned to the arterial wall; the angled tip of the guidewire have to be engaged inside catheter lumen through simultaneous smooth tip rotation and gentle probing). H - Final result (guidewire can still be seen in the foot in a percutaneous position).

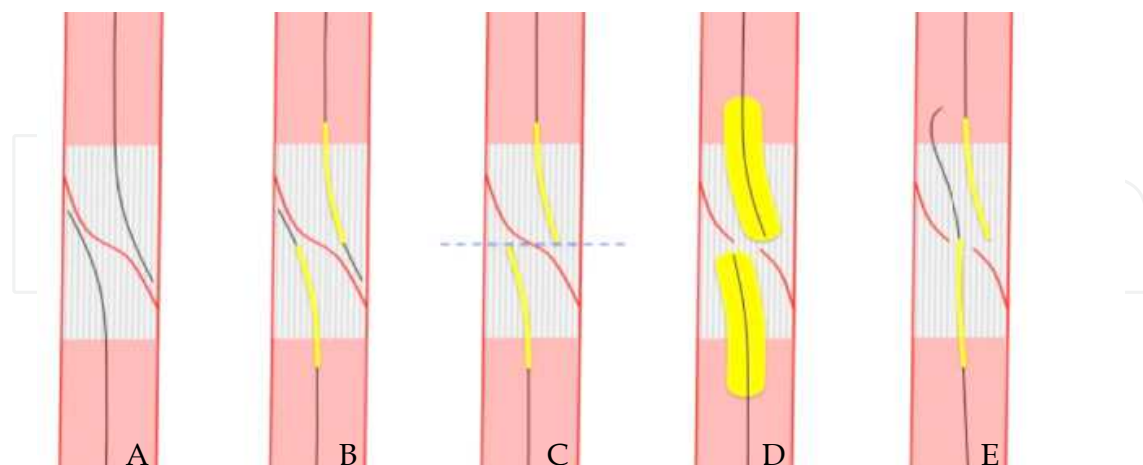


Fig. 7. *Rendez-vous* technique. A - Antegrade and retrograde guidewires in their respective subintimal space. B - A balloon catheter is advanced over each guidewire. C - The tip of the balloons are placed at the same level and guidewires tips are retrieved inside the balloon catheter. D - Balloons are inflated and the separating membrane broken. E - Retrograde guidewire is thoroughly advanced to proximal true lumen.



Meanwhile, there are several limitations to this technique. As so, an occluded or severely diseased artery may impede the puncture. Additionally, one should be extremely careful when the working artery is the only one patent in the leg, as a dissection, perforation or rupture may preclude a possible rescue surgery bypass.

#### 5.3.3.1.3 Pedal-plantar loop technique

This technique consists in creating a loop with the guidewire from the anterior tibial artery to the posterior tibial artery, or the inverse, through the foot vessels (Fusaro et al., 2007; Manzi et al., 2009). The most common pathway is through *dorsalis pedis* artery, deep plantar artery, deep plantar arterial arch, lateral plantar artery and posterior tibial artery. Indications for this technique are similar to the SAFARI technique. However, unlike the SAFARI technique, it can be performed when no distal vessel is available for puncture, being also less invasive. Moreover, this technique can provide a better outflow for tibial arteries.

On the other hand, complications related to foot vessels manipulations can precipitate a serious worsening of the ischemic condition.

Additional information in regard to this technique is provided in the chapter from the present book written by Manzi et al.

#### 5.3.3.1.4 Revascularization through peroneal artery collaterals

If neither the anterior nor the posterior tibial artery can be treated despite several intraluminal and subintimal crossing attempts, the alternative treatment may consist of providing direct flow along the peroneal artery. The distal peroneal artery has several collateral branches that connect with foot arteries. In particular, the communicating branch connects the peroneal with the posterior tibial artery, whereas the perforating branch goes through the interosseous membrane and links the peroneal to the *dorsalis pedis* artery. This technique aims at creating an effective pathway from the peroneal to tibial vessels by means of guidewire tracking through the referred collaterals (figure 8).

The *transcollateral* technique may be of value specifically when a proximal occlusion stump is not evident, when a dissection flap or a perforation in the proximal tract of the target vessel impairs guidewire advancement, or when distal disease makes retrograde percutaneous puncture impossible.

The major limitation of this technique is the absence of collaterals suitable for wiring (Fusaro et al., 2008; Graziani et al., 2008).

In all the above described techniques, a low-profile supportive catheter (Cook CXI™, Spectranetics® Quickcross®, Medtronic/Invatec Diver) or a low-profile balloon catheter can be used to provide additional support to the advancement of the guidewire. They also allow wire exchange without sacrificing the progress made through the lesion. Additionally, their lumen can be used to inject contrast and verify position and distal outflow. In this circumstances, diluted contrast, with diminished viscosity, may be preferable as the very low profile of catheter lumen is associated with high flow resistance.

### 5.3.4 Balloons

Specific low-profile balloons (less than 4F) have been recently designed for BTK purposes. They are made to work on a 0.014" or a 0.018" platform. The catheters of those balloons should provide increased shaft strength to allow adequate pushability, particularly in complex CTOs. In those circumstances, the over-the-wire technique should be preferred as it

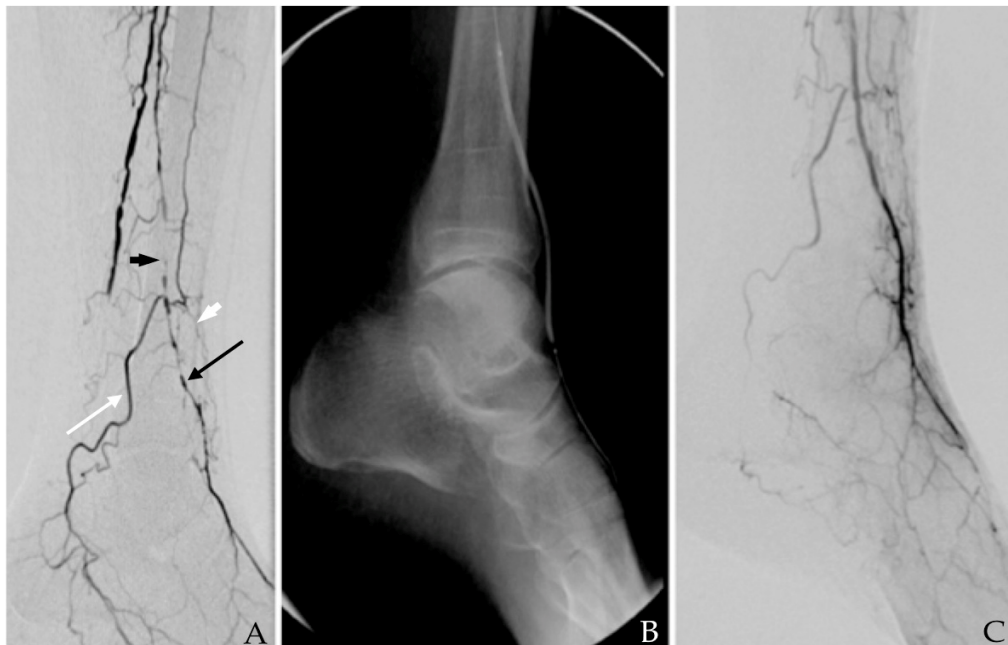


Fig. 8. *Transcollateral* technique. A – Black arrow head: peroneal artery; white arrow head: occlusion of the distal anterior tibial artery; white arrow head: occlusion of the distal anterior tibial artery; white arrow: communicating branch of peroneal artery anastomosing with posterior tibial artery; black arrow: perforating branch anastomosing with *dorsalis pedis* artery. B – Inflated balloon throughout distal peroneal artery, perforating branch and *dorsalis pedis* artery. Notice the posterior to anterior transition. C – Final result.

promotes better support when compared to the rapid-exchange monorail technique. The transition between the guidewire and the tip of the catheter should be as smooth as possible to avoid the catheter getting stuck in the lesion, optimizing its crossability. Hydrophilic coating of the catheter is particularly relevant in long complex lesions. Long catheters should be considered when the contralateral approach is performed.

In regard to the balloon itself, its compliance should be kept at minimum, as diameter accuracy is crucial for BTK interventions. In this particular matter, even conical balloons have been recently released. Long sizes are now available allowing angioplasty of an almost entire tibial vessel. The shoulders should be reduced to keep precision on the extension of the vessel to be treated. Segmental pre-dilatation with smaller diameter balloons may be required to allow the passage of the definitive balloon.

Although there is no consensus on insufflation time, most of the authors recommend a period longer than 3 minutes.

### 5.3.5 Bare-metal stents

The tibial arteries are small diameter vessels and have a limited flow. As so, they are particularly prone to neointimal hyperplasia and re-stenosis after balloon-expandable bare-metal stent (BMS) placement (Siablis et al., 2005). In fact, reocclusion occurs in up to 50% of the cases by one year (Scheinert et al., 2006; Siablis et al., 2007; Siablis et al., 2005). Additionally, balloon-expandable stents are available in only small lengths as they are originally coronary stents. There is only one long balloon-expandable stent device (up to 8 cm) dedicated to the infrapopliteal segment (Medtronic Invatec Chromis Deep). However, data regarding its

behavior is lacking (Karnabatidis et al., 2009a). Meanwhile, balloon expandable stents in tibial vessels seem to be surprisingly less vulnerable to compressions and fracture than in the femoro-popliteal sector, except if placed distally (Karnabatidis et al., 2009b).

Long, thin-strut, low-profile, self-expanding nitinol stents designed and engineered specifically for the infrapopliteal arteries are now commercially accessible. Yet, data concerning their efficacy is still scarce. More concrete and solid evidence will arise when the results from the Expand-Trial (Astron Pulsar Stent versus PTA in patients with symptomatic critical limb ischemia or Severe intermittent claudication) and the XXS-Trial (Balloon Angioplasty Versus Xpert Stent in CLI Patients) will become available.

Though, considering the existing data, bare metal stents should be reserved to bailout situations after balloon angioplasty. As so, they should be inserted in the following situations: flow-limiting dissection resistant to prolonged balloon angioplasty, significant elastic recoil, and relevant residual stenosis (higher than 30%). Still, they have also been advocated to correct challenging lesions in bifurcations using the *crush technique* originally described in coronary arteries (Colombo et al., 2003; Schwarzmaier-D'Assie et al., 2007).

#### 5.4 Complications

Systemic and access complications are common to all endovascular procedures. Additional considerations should be made in regard to some direct local complications.

A perforation or an arteriovenous fistula that occurs while attempting to cross a tibial CTO is rarely of any clinical significance as it will almost constantly closes within few minutes when only a guidewire or a low-profile catheter has passed extraluminally (Lyden, 2009) (figure 9). Thus, one should be sure to be inside the vessel before inflating a balloon. Removing the devices to above the proximal extremity of the CTO and reattempting to cross the lesion from the top, may allow successful passage and aid in solving the perforation or the arteriovenous fistula. When those complications do not auto-resolve, external compression guided by angiography or temporary vessel occlusion with a balloon can be attempted. In very rare situations, coiling must be envisaged.

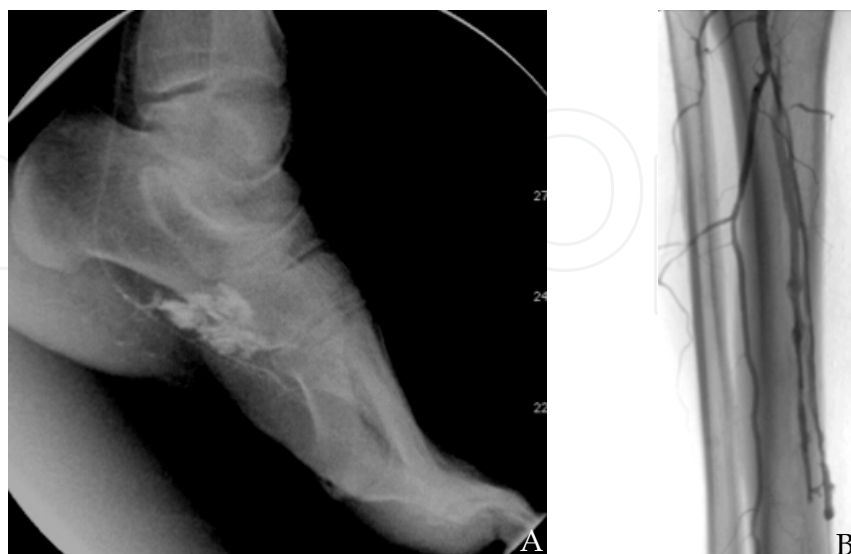

Fig. 9. A - Perforation; extraluminal contrast is easily noticed. B - Peroneal arteriovenous fistula.

### 5.5 Adjunctive medication

All patients should be placed on intravenous heparin when the sheath is introduced. The dose should be adjusted to keep an activated clotting time between 250 and 300. Other anticoagulants, such as bivalirudin, have been shown to be equally effective (Patel et al., 2010).

All patients should already be on a chronic aspirin regimen. Clopidogrel should be started 5 days before the procedure. Alternatively, a 300 mg load can be administered peri-procedure. Although adequate evidence is lacking, aspirin plus clopidogrel should be kept for six months.

Tibial arteries are particularly prone to vasospasm. As so, arterial vasodilators should be available at all times. There are mostly four that can be used in: nitroglycerin, papaverine, tansolusine and verapamil, although nitroglycerin is most commonly used (Cronenwett et al., 2005). Besides their use in treating catheterization-associated vasospasm, they may be administered prophylactically before balloon insufflation or guidewire manipulation of tortuous vessels, especially foot vessels.

Thrombolytics should also be accessible, as dissection, spasm or elastic recoil may precipitate an acute thrombosis.

### 5.6 Emergent techniques and alternatives

#### 5.6.1 Drug-eluting stents

Driven by the encouraging results of the trials on drug-eluting stents in coronary arteries, some vascular interventionists have applied them in the infrapopliteal arteries to overcome restenosis and prolong amputation- and reintervention-free survival of CLI patients (Schofer et al., 2003). Several single-center series have demonstrated that drug-eluting stents effectively seem to be associated with a higher primary patency and a reduced need for reintervention in comparison to bare metal stents (Scheinert et al., 2006; Siablis et al., 2009).

Meanwhile, considering that bare metal stents have currently restricted indications, most of CLI patients have long complex infrapopliteal lesions, only short coronary drug-eluting balloon-expandable stents are currently available, and taking into account the so called *limb salvage-graft patency gap*, one could consider that the potential role for drug-eluting stents in BTK vessels is still to be determined.

#### 5.6.2 Drug-coated balloons

The concept of delivering a local antiproliferative drug to the vessel surface utilizing drug-coated balloons to prevent restenosis without placing a permanent foreign material seems very appealing. Moreover, in opposition to current drug-eluting stents, drug-coated balloons can treat long lesions.

Nevertheless, more solid evidence is required to clarify the utility of drug-coated balloons in infrapopliteal arteries. The PICOLLO and PADI ongoing trials may provide the needed additional data (Hawkins and Hennebry, 2011).

#### 5.6.3 Atherectomy devices

The OASIS trial proved that orbital atherectomy in infrapopliteal vessels may provide predictable and safe lumen enlargement. Short-term data demonstrated substantial symptomatic improvement and infrequent need for further revascularization or amputation (Korabathina et al., 2010). Specific directional atherectomy devices are also available for

tibial vessels. Nevertheless, more consistent data is needed to determinate the precise role of these tools in BTK intervention.

#### **5.6.4 Additional technology**

There are additional devices, some already available, other still in the pipeline of manufacturers, which may become relevant in near future. Bioabsorbable stents (drug-eluting or not), cryoplasty, and laser atherectomy are among them.

### **6. Conclusions**

Endoluminal therapy for BTK arteries is now a key part of the vascular specialist armamentarium. Tibial arteries endovascular approach has demonstrated to lead to high limb salvage rates with low morbidity and mortality. As a result, the paradigm for treatment of CLI patients has changed. One should now consider endovascular intervention as the first line treatment in the majority of CLI patients, especially in those with significant medical comorbidities. To do so, the vascular specialist should have a consistent knowledge of the BTK endovascular techniques and devices. The first step decision in tibial endovascular therapy is the access. In this context, antegrade ipsilateral approach is generally preferred. The next critical decision is the choice of the vessel(s) to be approached in order to reach successful limb salvage. Allowing pulsatile flow to the correct portion of the foot is the contemporary paramount for ulcer healing. As so, an adequate understanding of the current angiosome model should enhance clinical results. However, this concept does not preclude the recanalization of the other tibial vessels as trophic lesion may include more than one angiosome and the limited long-term permeability rate of angioplasty may compromise the feeding artery before complete lesion healing. The selection of the devices should be judicious. The choice of the guidewire is extremely relevant and should be based on the characteristics of the lesion (location, length, and stenosis/occlusion) as well as on the characteristics of the guidewire itself (tip load, stiffness, hydrophilic/hydrophobic coating, flexibility, torque transmission, trackability, and pushability). Going through chronic total occlusions may be quite challenging. Therefore, the vascular interventionist should master the techniques that have been recently described: antegrade techniques, including the drilling technique, the penetrating technique, the subintimal technique and the parallel technique; subintimal arterial flossing with antegrade-retrograde intervention (SAFARI); pedal-plantar loop technique and revascularization through peroneal artery collaterals. The specifically designed, low-profile, increased shaft strength, balloons catheters were conceived for a 0.014" or a 0.018" platform. The balloons should have minimal compliance and be available in long sizes. Bare metal stents should be available, even though their use is presently reserved for bailout situations.

Meanwhile, the continuous arising of new technologies will possibly convulse the currently accepted BTK endovascular techniques. In fact, drug-eluting stents, drug-coated balloons, atherectomy devices, bioabsorbable stents among others may play a relevant role in BTK intervention in the near future.

### **7. Acknowledgements**

The authors would like to thank the staff of the Angiology and Vascular Surgery Department, the Radiology Technicians, the Radiology Nurses and the Staff of Diabetic Foot



Outpatient Clinic of the Vila Nova de Gaia/Espinho Hospital Center for their tireless efforts in providing the best possible conditions for the success of the endovascular procedures and the achievement of limb salvage.

## 8. References

- Abou-Zamzam, A.M., Jr., Lee, R.W., Moneta, G.L., Taylor, L.M., Jr. & Porter, J.M. (1997). Functional outcome after infrainguinal bypass for limb salvage. *J Vasc Surg* 25, 287-295.
- Adam, D.J., Beard, J.D., Cleveland, T., Bell, J., Bradbury, A.W., Forbes, J.F., Fowkes, F.G., Gillespie, I., Ruckley, C.V., Raab, G., et al. (2005). Bypass versus angioplasty in severe ischaemia of the leg (BASIL): multicentre, randomised controlled trial. *Lancet* 366, 1925-1934.
- Albers, M., Romiti, M., Brochado-Neto, F.C., De Luccia, N. & Pereira, C.A. (2006). Meta-analysis of popliteal-to-distal vein bypass grafts for critical ischemia. *J Vasc Surg* 43, 498-503.
- Alexandrescu, V., Vincent, G., Azdad, K., Hubermont, G., Ledent, G., Ngongang, C. & Filimon, A.M. (2011). A Reliable Approach to Diabetic Neuroischemic Foot Wounds: Below-the-Knee Angiosome-Oriented Angioplasty. *J Endovasc Ther* 18, 376-387.
- Alexandrescu, V.A., Hubermont, G., Philips, Y., Guillaumie, B., Ngongang, C., Vandenbossche, P., Azdad, K., Ledent, G. & Horion, J. (2008). Selective primary angioplasty following an angiosome model of reperfusion in the treatment of Wagner 1-4 diabetic foot lesions: practice in a multidisciplinary diabetic limb service. *J Endovasc Ther* 15, 580-593.
- Allie, D.E., Hebert, C.J., Ingraldi, A., Patlola, R.R. & Walker, C.M. (2009). 24-carat gold, 14-carat gold, or platinum standards in the treatment of critical limb ischemia: bypass surgery or endovascular intervention? *J Endovasc Ther* 16 Suppl 1, I134-146.
- Attinger, C.E., Evans, K.K., Bulan, E., Blume, P. & Cooper, P. (2006). Angiosomes of the foot and ankle and clinical implications for limb salvage: reconstruction, incisions & revascularization. *Plast Reconstr Surg* 117, 261S-293S.
- Biondi-Zoccai, G.G., Agostoni, P., Sangiorgi, G., Dalla Paola, L., Armano, F., Nicolini, S., Alek, J. & Fusaro, M. (2006). Mastering the antegrade femoral artery access in patients with symptomatic lower limb ischemia: learning curve, complications & technical tips and tricks. *Catheter Cardiovasc Interv* 68, 835-842.
- Blevins, W.A., Jr. & Schneider, P.A. (2010). Endovascular management of critical limb ischemia. *Eur J Vasc Endovasc Surg* 39, 756-761.
- Brosi, P., Dick, F., Do, D.D., Schmidli, J., Baumgartner, I. & Diehm, N. (2007). Revascularization for chronic critical lower limb ischemia in octogenarians is worthwhile. *J Vasc Surg* 46, 1198-1207.
- Chung, J., Bartelson, B.B., Hiatt, W.R., Peyton, B.D., McLafferty, R.B., Hopley, C.W., Salter, K.D. & Nehler, M.R. (2006). Wound healing and functional outcomes after infrainguinal bypass with reversed saphenous vein for critical limb ischemia. *J Vasc Surg* 43, 1183-1190.
- Colombo, A., Stankovic, G., Orlic, D., Corvaja, N., Liistro, F., Airolidi, F., Chieffo, A., Spanos, V., Montorfano, M. & Di Mario, C. (2003). Modified T-stenting technique with

- crushing for bifurcation lesions: immediate results and 30-day outcome. *Catheter Cardiovasc Interv* 60, 145-151.
- Cronenwett, J.L., Johnston, K.W. & Rutherford, R.B. (2005). *Rutherford's vascular surgery*, 6th ed. / [edited by] Jack L. Cronenwett, Peter Gloviczki. edn (Philadelphia, Pa., Saunders).
- DeRubertis, B.G., Pierce, M., Chaer, R.A., Rhee, S.J., Benjeloun, R., Ryer, E.J., Kent, C. & Faries, P.L. (2007). Lesion severity and treatment complexity are associated with outcome after percutaneous infra-inguinal intervention. *J Vasc Surg* 46, 709-716.
- Dorros, G., Jaff, M.R., Dorros, A.M., Mathiak, L.M. & He, T. (2001). Tibioperoneal (outflow lesion) angioplasty can be used as primary treatment in 235 patients with critical limb ischemia: five-year follow-up. *Circulation* 104, 2057-2062.
- Dotter, C.T., Rosch, J. & Robinson, M. (1978). Fluoroscopic guidance in femoral artery puncture. *Radiology* 127, 266-267.
- Faglia, E., Dalla Paola, L., Clerici, G., Clerissi, J., Graziani, L., Fusaro, M., Gabrielli, L., Losa, S., Stella, A., Gargiulo, M., et al. (2005). Peripheral angioplasty as the first-choice revascularization procedure in diabetic patients with critical limb ischemia: prospective study of 993 consecutive patients hospitalized and followed between 1999 and 2003. *Eur J Vasc Endovasc Surg* 29, 620-627.
- Fefer, P., Carlino, M. & Strauss, B.H. (2010). Intraplaque therapies for facilitating percutaneous recanalization of chronic total occlusions. *Can J Cardiol* 26 Suppl A, 32A-36A.
- Fusaro, M., Agostoni, P. & Biondi-Zoccai, G. (2008). "Trans-collateral" angioplasty for a challenging chronic total occlusion of the tibial vessels: a novel approach to percutaneous revascularization in critical lower limb ischemia. *Catheter Cardiovasc Interv* 71, 268-272.
- Fusaro, M., Dalla Paola, L. & Biondi-Zoccai, G. (2007). Pedal-plantar loop technique for a challenging below-the-knee chronic total occlusion: a novel approach to percutaneous revascularization in critical lower limb ischemia. *J Invasive Cardiol* 19, E34-37.
- Godino, C., Sharp, A.S., Carlino, M. & Colombo, A. (2009). Crossing CTOs-the tips, tricks, and specialist kit that can mean the difference between success and failure. *Catheter Cardiovasc Interv* 74, 1019-1046.
- Graziani, L., Silvestro, A., Bertone, V., Manara, E., Andreini, R., Sigala, A., Mingardi, R. & De Giglio, R. (2007). Vascular involvement in diabetic subjects with ischemic foot ulcer: a new morphologic categorization of disease severity. *Eur J Vasc Endovasc Surg* 33, 453-460.
- Graziani, L., Silvestro, A., Monge, L., Boffano, G.M., Kokaly, F., Casadidio, I. & Giannini, F. (2008). Transluminal angioplasty of peroneal artery branches in diabetics: initial technical experience. *Cardiovasc Intervent Radiol* 31, 49-55.
- Grier, D. & Hartnell, G. (1990). Percutaneous femoral artery puncture: practice and anatomy. *Br J Radiol* 63, 602-604.
- Hawkins, B.M. & Hennebry, T.A. (2011). Local Paclitaxel delivery for treatment of peripheral arterial disease. *Circ Cardiovasc Interv* 4, 297-302.
- Ihnat, D.M. & Mills, J.L., Sr. (2010). Current assessment of endovascular therapy for infrainguinal arterial occlusive disease in patients with diabetes. *J Vasc Surg* 52, 92S-95S.

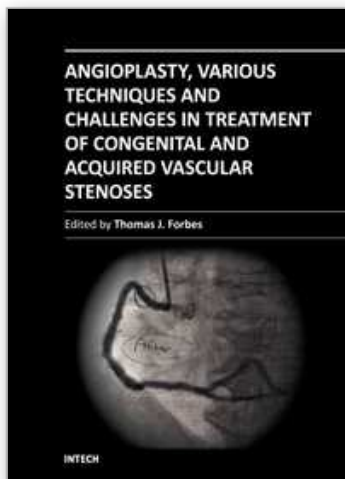
- Iida, O., Nanto, S., Uematsu, M., Ikeoka, K., Okamoto, S., Dohi, T., Fujita, M., Terashi, H. & Nagata, S. (2010). Importance of the angiosome concept for endovascular therapy in patients with critical limb ischemia. *Catheter Cardiovasc Interv* 75, 830-836.
- Karnabatidis, D., Katsanos, K. & Siablis, D. (2009a). Infrapopliteal stents: overview and unresolved issues. *J Endovasc Ther* 16 Suppl 1, I153-162.
- Karnabatidis, D., Katsanos, K., Spiliopoulos, S., Diamantopoulos, A., Kagadis, G.C. & Siablis, D. (2009b). Incidence, anatomical location, and clinical significance of compressions and fractures in infrapopliteal balloon-expandable metal stents. *J Endovasc Ther* 16, 15-22.
- Katsuragawa, M., Fujiwara, H., Miyamae, M. & Sasayama, S. (1993). Histologic studies in percutaneous transluminal coronary angioplasty for chronic total occlusion: comparison of tapering and abrupt types of occlusion and short and long occluded segments. *J Am Coll Cardiol* 21, 604-611.
- Kim, H.Y. (2010). Percutaneous recanalization of coronary chronic total occlusions: current devices and specialized wire crossing techniques. *Korean Circ J* 40, 209-215.
- Korabathina, R., Mody, K.P., Yu, J., Han, S.Y., Patel, R. & Staniloae, C.S. (2010). Orbital atherectomy for symptomatic lower extremity disease. *Catheter Cardiovasc Interv* 76, 326-332.
- Kroger, K., Stang, A., Kondratieva, J., Moebus, S., Beck, E., Schmermund, A., Mohlenkamp, S., Dragano, N., Siegrist, J., Jockel, K.H., et al. (2006). Prevalence of peripheral arterial disease - results of the Heinz Nixdorf recall study. *Eur J Epidemiol* 21, 279-285.
- Kudo, T., Chandra, F.A. & Ahn, S.S. (2005). The effectiveness of percutaneous transluminal angioplasty for the treatment of critical limb ischemia: a 10-year experience. *J Vasc Surg* 41, 423-435; discussion 435.
- Kudo, T., Chandra, F.A., Kwun, W.H., Haas, B.T. & Ahn, S.S. (2006). Changing pattern of surgical revascularization for critical limb ischemia over 12 years: endovascular vs. open bypass surgery. *J Vasc Surg* 44, 304-313.
- Lyden, S.P. (2009). Techniques and outcomes for endovascular treatment in the tibial arteries. *J Vasc Surg* 50, 1219-1223.
- Manzi, M., Fusaro, M., Ceccacci, T., Erente, G., Dalla Paola, L. & Brocco, E. (2009). Clinical results of below-the knee intervention using pedal-plantar loop technique for the revascularization of foot arteries. *J Cardiovasc Surg (Torino)* 50, 331-337.
- Marcus, A.J., Lotzof, K. & Howard, A. (2007). Access to the superficial femoral artery in the presence of a "hostile groin": a prospective study. *Cardiovasc Intervent Radiol* 30, 351-354.
- Neville, R.F., Attinger, C.E., Bulan, E.J., Ducic, I., Thomassen, M. & Sidawy, A.N. (2009). Revascularization of a specific angiosome for limb salvage: does the target artery matter? *Ann Vasc Surg* 23, 367-373.
- Nice, C., Timmons, G., Bartholemew, P. & Uberoi, R. (2003). Retrograde vs. antegrade puncture for infra-inguinal angioplasty. *Cardiovasc Intervent Radiol* 26, 370-374.
- Norgren, L., Hiatt, W.R., Dormandy, J.A., Nehler, M.R., Harris, K.A., Fowkes, F.G., Bell, K., Caporusso, J., Durand-Zaleski, I., Komori, K., et al. (2007). Inter-Society Consensus for the Management of Peripheral Arterial Disease (TASC II). *Eur J Vasc Endovasc Surg* 33 Suppl 1, S1-75.

- Patel, P.J., Hieb, R.A. & Bhat, A.P. (2010). Percutaneous revascularization of chronic total occlusions. *Tech Vasc Interv Radiol* 13, 23-36.
- Pomposelli, F.B., Kansal, N., Hamdan, A.D., Belfield, A., Sheahan, M., Campbell, D.R., Skillman, J.J. & Logerfo, F.W. (2003). A decade of experience with dorsalis pedis artery bypass: analysis of outcome in more than 1000 cases. *J Vasc Surg* 37, 307-315.
- Romiti, M., Albers, M., Brochado-Neto, F.C., Durazzo, A.E., Pereira, C.A. & De Luccia, N. (2008). Meta-analysis of infrapopliteal angioplasty for chronic critical limb ischemia. *J Vasc Surg* 47, 975-981.
- Scheinert, D., Ulrich, M., Scheinert, S., Sax, J., Braunlich, S. & Biamino, G. (2006). Comparison of sirolimus-eluting vs. bare-metal stents for the treatment of infrapopliteal obstructions. *EuroIntervention* 2, 169-174.
- Schofer, J., Schluter, M., Gershlick, A.H., Wijns, W., Garcia, E., Schampaert, E. & Breithardt, G. (2003). Sirolimus-eluting stents for treatment of patients with long atherosclerotic lesions in small coronary arteries: double-blind, randomised controlled trial (E-SIRIUS). *Lancet* 362, 1093-1099.
- Schwarzmaier-D'Assie, A., Karnik, R., Bonner, G., Vavrik, J. & Slany, J. (2007). Fracture of a drug-eluting stent in the tibioperoneal trunk following bifurcation stenting. *J Endovasc Ther* 14, 106-109.
- Siablis, D., Karnabatidis, D., Katsanos, K., Diamantopoulos, A., Spiliopoulos, S., Kagadis, G.C. & Tsolakis, J. (2009). Infrapopliteal application of sirolimus-eluting versus bare metal stents for critical limb ischemia: analysis of long-term angiographic and clinical outcome. *J Vasc Interv Radiol* 20, 1141-1150.
- Siablis, D., Karnabatidis, D., Katsanos, K., Kagadis, G.C., Kraniotis, P., Diamantopoulos, A. & Tsolakis, J. (2007). Sirolimus-eluting versus bare stents after suboptimal infrapopliteal angioplasty for critical limb ischemia: enduring 1-year angiographic and clinical benefit. *J Endovasc Ther* 14, 241-250.
- Siablis, D., Kraniotis, P., Karnabatidis, D., Kagadis, G.C., Katsanos, K. & Tsolakis, J. (2005). Sirolimus-eluting versus bare stents for bailout after suboptimal infrapopliteal angioplasty for critical limb ischemia: 6-month angiographic results from a nonrandomized prospective single-center study. *J Endovasc Ther* 12, 685-695.
- Spinosa, D.J., Leung, D.A., Harthun, N.L., Cage, D.L., Fritz Angle, J., Hagspiel, K.D. & Matsumoto, A.H. (2003). Simultaneous antegrade and retrograde access for subintimal recanalization of peripheral arterial occlusion. *J Vasc Interv Radiol* 14, 1449-1454.
- Srivatsa, S.S., Edwards, W.D., Boos, C.M., Grill, D.E., Sangiorgi, G.M., Garratt, K.N., Schwartz, R.S. & Holmes, D.R., Jr. (1997). Histologic correlates of angiographic chronic total coronary artery occlusions: influence of occlusion duration on neovascular channel patterns and intimal plaque composition. *J Am Coll Cardiol* 29, 955-963.
- Stone, G.W., Kandzari, D.E., Mehran, R., Colombo, A., Schwartz, R.S., Bailey, S., Moussa, I., Teirstein, P.S., Dangas, G., Baim, D.S., et al. (2005). Percutaneous recanalization of chronically occluded coronary arteries: a consensus document: part I. *Circulation* 112, 2364-2372.
- Strauss, B.H., Segev, A., Wright, G.A., Qiang, B., Munce, N., Anderson, K.J., Leung, G., Dick, A.J., Virmani, R. & Butany, J. (2005). Microvessels in chronic total occlusions: pathways for successful guidewire crossing. *J Interv Cardiol* 18, 425-436.

- Taylor, G.I.& Palmer, J.H. (1987). The vascular territories (angiosomes) of the body: experimental study and clinical applications. *Br J Plast Surg* 40, 113-141.
- Taylor, G.I.& Pan, W.R. (1998). Angiosomes of the leg: anatomic study and clinical implications. *Plast Reconstr Surg* 102, 599-616.
- Van Dieren, S., Beulens, J.W., van der Schouw, Y.T., Grobbee, D.E.& Neal, B. (2010). The global burden of diabetes and its complications: an emerging pandemic. *Eur J Cardiovasc Prev Rehabil* 17 Suppl 1, S3-8.
- Varu, V.N., Hogg, M.E.& Kibbe, M.R. (2010). Critical limb ischemia. *J Vasc Surg* 51, 230-241.
- Yeow, K.M., Toh, C.H., Wu, C.H., Lee, R.Y., Hsieh, H.C., Liau, C.T.& Li, H.J. (2002). Sonographically guided antegrade common femoral artery access. *J Ultrasound Med* 21, 1413-1416.

IntechOpen





## **Angioplasty, Various Techniques and Challenges in Treatment of Congenital and Acquired Vascular Stenoses**

Edited by Dr. Thomas Forbes

ISBN 978-953-51-0084-3

Hard cover, 236 pages

**Publisher** InTech

**Published online** 14, March, 2012

**Published in print edition** March, 2012

The field of performing transcatheter interventions to treat vascular lesions has exploded over the past 20 years. Not only has the technology changed, especially in the arena of balloon/stent devices, but the techniques of approaching complex lesions has evolved over the past decade. Lesions that no one would have imagined treating back in the 1990's are now being done routinely in the catheterization suite. This book provides an update on the current techniques and devices used to treat a wide variety of lesions. Though, at first, the outward appearance of the topics appears to be varied, they are all related by the common thread of treating vascular lesions. We hope, by publishing this book, to accomplish two things: First, to offer insight from experts in their field to treat, both medically and procedurally, complex vascular lesions that we frequently encounter. Secondly, we hope to promote increased communication between areas of medicine that frequently don't communicate, between adult interventional cardiologists, pediatric interventional cardiologists, interventional radiologists, and neurosurgeons. Much can be learned from our respective colleagues in these areas which can further our own world of interventions.

### **How to reference**

In order to correctly reference this scholarly work, feel free to copy and paste the following:

Daniel Brandão, Joana Ferreira, Armando Mansilha and António Guedes Vaz (2012). Below the Knee Techniques: Now and Then, Angioplasty, Various Techniques and Challenges in Treatment of Congenital and Acquired Vascular Stenoses, Dr. Thomas Forbes (Ed.), ISBN: 978-953-51-0084-3, InTech, Available from: <http://www.intechopen.com/books/angioplasty-various-techniques-and-challenges-in-treatment-of-congenital-and-acquired-vascular-stenoses/below-the-knee-techniques-now-and-then->

**INTECH**  
open science | open minds

### **InTech Europe**

University Campus STeP Ri  
Slavka Krautzeka 83/A  
51000 Rijeka, Croatia  
Phone: +385 (51) 770 447  
Fax: +385 (51) 686 166  
[www.intechopen.com](http://www.intechopen.com)

### **InTech China**

Unit 405, Office Block, Hotel Equatorial Shanghai  
No.65, Yan An Road (West), Shanghai, 200040, China  
中国上海市延安西路65号上海国际贵都大饭店办公楼405单元  
Phone: +86-21-62489820  
Fax: +86-21-62489821

© 2012 The Author(s). Licensee IntechOpen. This is an open access article distributed under the terms of the [Creative Commons Attribution 3.0 License](#), which permits unrestricted use, distribution, and reproduction in any medium, provided the original work is properly cited.

IntechOpen

IntechOpen