

We are IntechOpen, the world's leading publisher of Open Access books Built by scientists, for scientists

4,800

Open access books available

122,000

International authors and editors

135M

Downloads

Our authors are among the

154

Countries delivered to

TOP 1%

most cited scientists

12.2%

Contributors from top 500 universities

**WEB OF SCIENCE™**Selection of our books indexed in the Book Citation Index
in Web of Science™ Core Collection (BKCI)

Interested in publishing with us? Contact book.department@intechopen.com

Numbers displayed above are based on latest data collected.
For more information visit www.intechopen.com

Trabecular Surgery

Antonio Fea, Giulia Consolandi, Giulia Pignata, Davide Turco,
Paola Cannizzo, Elena Bartoli, Teresa Rolle and Federico M. Grignolo
*Clinica Oculistica, Università degli Studi di Torino
Italy*

1. Introduction

In glaucoma, the most commonly used surgical options attempt to establish communication between the anterior chamber and the subconjunctival space, either by removing part of the trabecular meshwork and thus decreasing resistance to the passage of the aqueous humour or by means of drainage tubes that conduct the aqueous humour toward extraocular subconjunctival reservoirs. Trabeculectomy is still the most widely performed glaucoma procedure worldwide. Nevertheless, it creates an artificial pathway for drainage of aqueous that is less optimal than physiologic outflow and is associated with numerous short and long-term serious complications. Surgical alternatives, such as deep sclerectomy, are more demanding, longer and seem to be surgeon-dependent. Although they achieve a high level of hypotensive effect, these forms of surgery are not exempt from potential complications and are highly dependent on the inflammatory and healing response of the patient.¹ The use of antimetabolites to regulate this healing response is also linked to a higher rate of complications.^{2,3,4,5,6}

The interest in new and possibly less invasive surgical techniques to lower intraocular pressure is growing. In particular, to avoid the eventual problems linked to surgical trauma to the conjunctiva and the ensuing inflammatory response, several new *ab interno* methods that attempt to achieve intraocular pressure control have been developed. Some of these methods are aimed at obtaining flow through Schlemm's canal, whereas others point to the possibility of obtaining flow from the anterior chamber to the suprachoroidal space. Gonioscopy is used in these *ab interno* procedures in order to visualize the site of implantation.

2. Visualizing the trabecular meshwork

Trabecular bypass surgery can be performed through the same incision used for phacoemulsification in cases of combined surgery, or by means of a paracentesis, when it is performed as a sole procedure. A temporal incision is warranted because of ease of patient's head positioning. Visualization of the angle using the gonioscope should be practiced in cases prior to performing surgery, in order to learn the correct techniques.

In the case of phakic patients, the instillation of a miotic is recommended to minimize the risk of lens injury. If the procedure is carried out under topical anaesthesia it is advisable to introduce lidocaine 1% into the anterior chamber, because some of the surgical manoeuvres

can be uncomfortable for the patient. It is perfectly possible to carry out the surgery under topical anaesthesia with intracameral lidocaine; however, when performing the operation for the first few times, it may be advisable to use some form of locoregional anaesthetic (retrobulbar, peribulbar or sub-Tenon).

Once the incision has been made in the temporal cornea, the anterior chamber must be filled with a cohesive viscoelastic that makes it possible to enlarge the region of the angle where surgery is planned.

A perfect view of the trabecular meshwork and of the angle must be achieved. The most common error is failure to position the microscope and/or the patient adequately in order to obtain an adequate view of the trabeculum. The patient's head must be turned approximately 45° away from the surgeon. The microscope should be tilted approximately 30° towards the operating surgeon.

3. Specific devices and surgical techniques

3.1 iStent®

The iStent® trabecular micro-bypass (Glaukos Corporation, Laguna Hills, CA) is made of titanium and coated with heparin (Duraflo® powder). It is L-shaped and measures 1 mm x 0.33 mm, with a nominal snorkel bore diameter of 120 microns (fig.1). The iStent is designed to fit into Schlemm's canal. The distal portion of the stent is bevelled and sharpened to facilitate penetration into the tissue of the trabecular meshwork. The external surface features three retention arches that impede the movement of the stent once it has been implanted. The implant weighs approximately 0.1 mg. It is delivered preloaded on an insertion device (fig.2) and it is implanted at the level of the trabecular meshwork with the aid of a Swan-Jacob type gonioscope (fig.3). Two versions of the iStent are available; one for the right eye and one for the left eye. The difference lies in the orientation of the rails, designed to facilitate the penetration of the implant into the trabecular meshwork. The distal tip of the implant should point towards the patient's feet at all times.



Fig. 1. iStent® trabecular bypass



Fig. 2. iStent® trabecular bypass in iStent inserter



Fig. 3. Swan-Jacob gonioscope

In all these techniques the patient is draped as for cataract surgery. Myosis is warranted if the surgery is not combined with phaco. Surgical steps are as follows:

1. A paracentesis is made generally using a 15 degree blade (fig.4).
2. If needed, the pupil is constricted with intracameral miotics and a cohesive viscoelastic is injected in the anterior chamber.
3. The tip of the stent, with the distal part parallel to the trabecular meshwork, should approach the trabecular meshwork at an angle of 15° to facilitate penetration of the tissue (fig.5). The stent should be placed parallel to the plane of the iris with the inner part covered by the meshwork and the lumen away from the iris. Excessive resistance indicates a path that is too perpendicular to the trabeculum or a wrong implantation site. Once the trabecular meshwork covers all of the implant, it should be released by pressing the applicator button. Only the proximal end of the stent should remain visible in the anterior chamber. The stent can be seated in its final position by gently tapping the side of the snorkel with the inserter tip. A small reflux of blood from Schlemm's canal is common and reflects adequate positioning of the stent.
4. At the end of surgery, blood and viscoelastic are removed(Fig.6). The corneal incision can be hydrated if the paracentesis is not watertight.

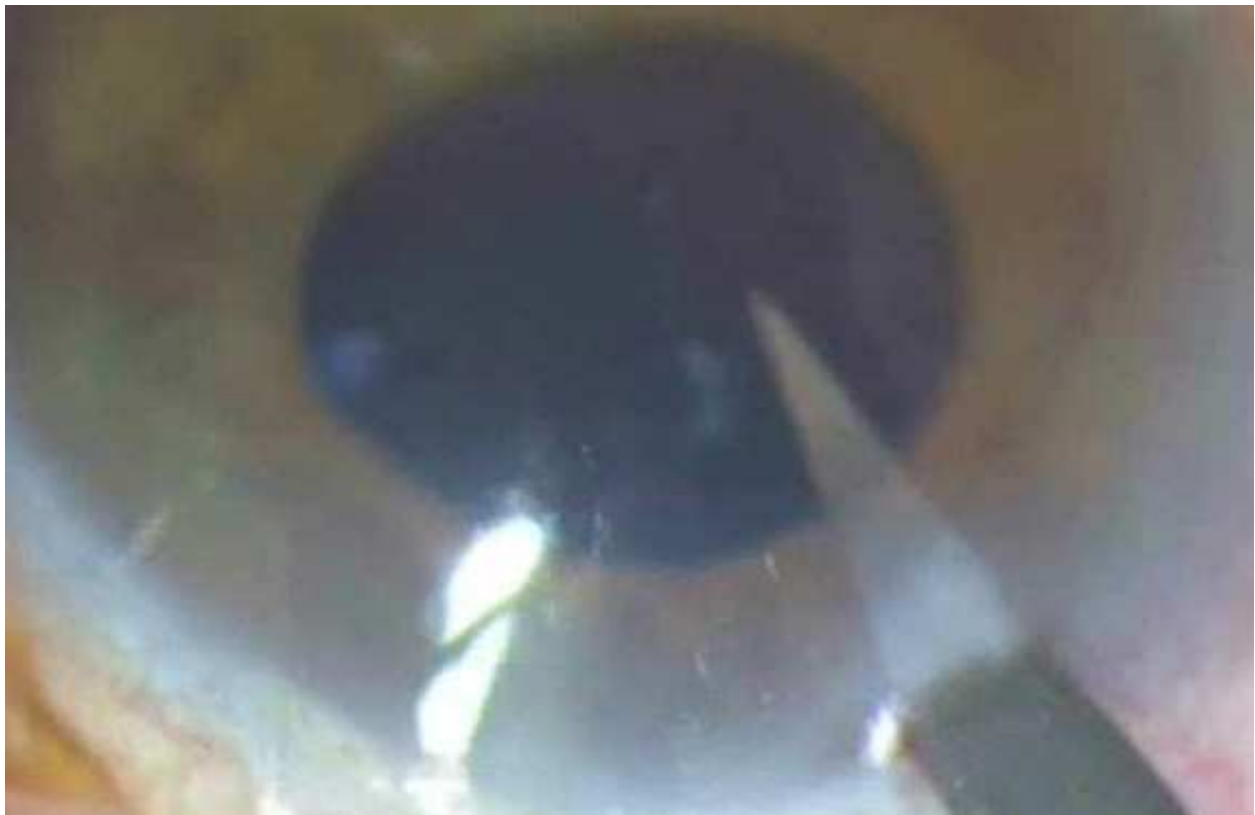

Fig. 4. A paracentesis is performed temporally.

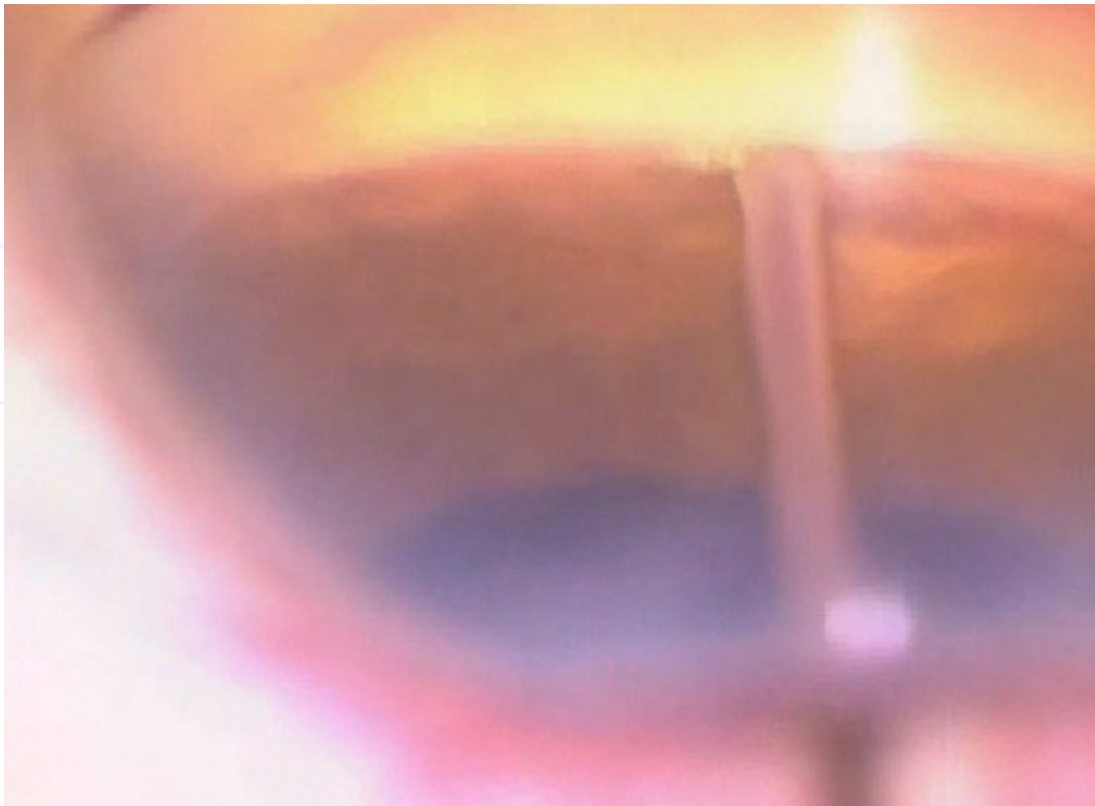


Fig. 5. The iStent is already half way within the trabecular meshwork.

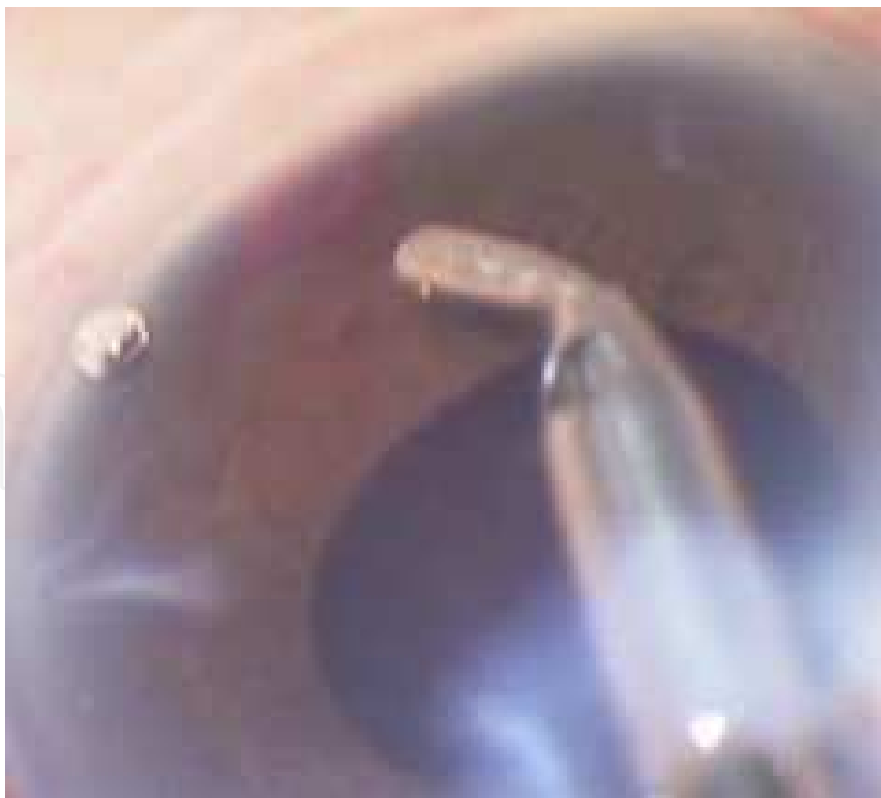

Fig. 6. Residual blood and viscoelastic are washed and aspirated by the anterior chamber with a coaxial I/A tip - the same can be done using a bimanual technique.

The post-operative suggested treatment should be similar to what is commonly used by each surgeon for an uncomplicated phacoemulsification procedure. Generally anti-glaucoma drugs are discontinued post-operatively and reintroduced if the patient does not achieve the target pressure.

iStent *inject* is a second generation trabecular bypass device that is also designed to restore conventional outflow (fig. 7). Two stents come preloaded in a sterile disposable injector that is placed on the meshwork. A stent release button on the injector is used to release the stents one at a time into the proper position (approximately 2-3 clock hours apart (fig. 8).

This new mechanism of implantation allows for implantation of two stents without exiting the inserter from the eye.



Fig. 7. iStent® inject (image provided by Glaukos)



Fig. 8. iStent® inject inserter (image provided by Glaukos)

3.2 Trabectome

The Trabectome™ (NeoMedix Inc., Tustin, CA, USA) device consists of a disposable handpiece tip (19.5-gauge) that will fit through a 1.6mm corneal incision. The handpiece is connected to a console with irrigation and aspiration, and also to a simple electrocautery generator. The foot pedal controls the irrigation, aspiration and electrocautery ablation via a stepwise foot control similar to a phacoemulsification system (fig. 9).

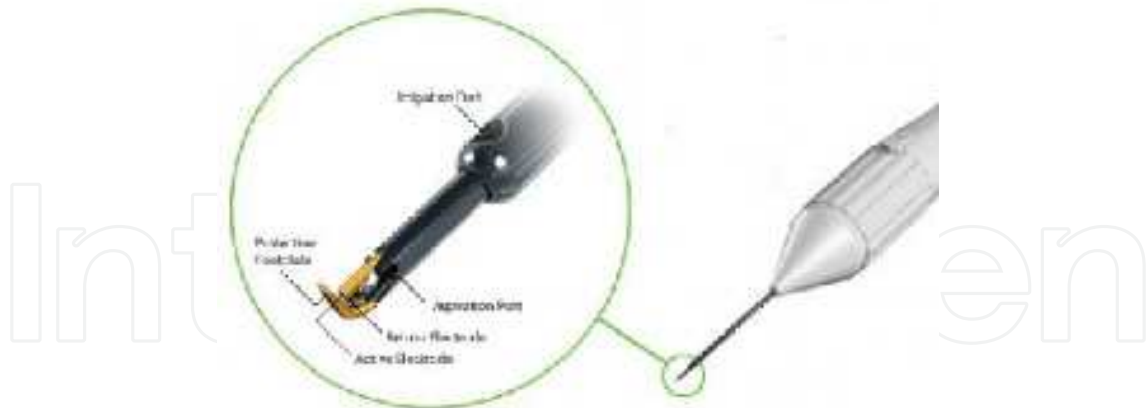

Fig. 9. Trabectome probe and tip

The tip of the handpiece is specially designed with an insulated footplate and is pointed for ease of insertion through the trabecular meshwork into Schlemm's canal. The footplate is coated with proprietary multilayered polymer, which provides thermal stability, mechanical strength, biocompatibility and chemical resistance in laboratory testing. The aspiration port is in close proximity (approximately 0.3 mm) to the cautery electrode and serves to remove debris during ablation. The irrigation is 3 mm from the surgical site and serves the dual purpose of keeping the eye pressurized and further dissipating heat energy. Although the irrigation and aspiration system role is important, the high-frequency electrocautery generator system is the pivotal point of this technology. The generator is a modified 800 EU unit from Aaron/Bovie (St. Petersburg, FL, USA) and operates at a frequency of 550 kHz with adjustable power setting in 0.1-W increment up to 10 W (recommended range 0.5–1.5 W). The target tissue is disrupted and disintegrated by applying heat energy in bursts with a high-peak power and low duty cycle. This ablation approach equates to high-energy bursts, which are bunched into small increments with comparably long time intervals in between. As a result, disruption and disintegration of tissue is achieved rather than a thermal-cooking effect such as that seen in traditional cautery of blood vessels.^{7,8}

Surgical steps: steps 1 and 2 are equal to the previous procedure, although a specially designed blade is provided by the manufacturer to obtain a water-tight paracentesis. A small paracentesis is more important with this procedure because during surgery the viscoelastic material is washed out by the water flowing through the tip of the instrument. 2) The tip of the footplate is inserted through the paracentesis aiming at the trabecular meshwork and then it is inserted through the trabecular meshwork into Schlemm's canal. A foot switch activates the aspiration and electro-surgical elements that ablate and remove the strip of trabecular meshwork and Schlemm's canal as the surgeon slowly advances the instrument along the meshwork in a clockwise and then counter clockwise direction using the insertion site as a fulcrum. A strip of trabecular meshwork and Schlemm's canal spanning 80°–100° is ablated and removed under direct gonioscopic visualization. Intraoperative reflux of blood through the resulting cleft is desirable in this procedure and confirms appropriate ab interno "unroofing" of Schlemm's canal. 4) At the end of surgery any residual viscoelastic or blood present in the anterior chamber is removed. It is generally not necessary to hydrate the paracentesis.

The post-operative suggested treatment includes: antibiotics used for prophylaxis. Pilocarpine 2% qid should be used starting on the first post-operative medication and continued for a month. Lotemax is advised for three weeks and then tapered. Directly post-operative it is advised to continue the previous pre-operative anti-glaucomatous therapy, although prostaglandins should possibly be avoided. Prof. Baerveldt recommends the eventual use of Latanoprost rather than other prostaglandins if they are absolutely necessary. Iopidine and Brimonidine can be used and are generally suggested. Anti-glaucoma medications can be reduced a month after surgery if target pressure is achieved.

3.3 Other procedures

Other approaches of gonioscopic surgery include the Ivantis method which simulates a short canaloplasty.

Two additional devices are aimed at improving flow of the aqueous humor from the anterior chamber to the suprachoroidal space. These are the Glaukos iStent *supra* and the Transcend Cypass. These devices will not be discussed, because the current data are less than one year post-operative.

4. Results

4.1 iStent

Numerous *in vitro* and *in vivo* studies support the stability, the effectiveness and the safety of the trabecular bypass iStent.

In 2004, Bahler demonstrated *in vitro* that the intraocular pressure was lowered after placement of a single stent, from 21.4 +/- 3.8 mm Hg to 12.4 +/- 4.2 mm Hg ($P < .001$).⁹ This corresponded to an 84% increase in facility of outflow. Eyes receiving more than one stent had final IOP of 11.9 +/- 3.7 mm Hg. Nine eyes underwent sequential implantation of additional stents and seven of these had a further decrease of IOP (13.6 +/- 4.1 to 10.0 +/- 4.3; $P = .02$). This work suggested that bypass of the trabecular meshwork lowers IOP in cultured human anterior segments. One stent produced the greatest change in pressure. The sequential addition of more stents further lowered pressure in seven of nine eyes. Parallel to this study the founders/manufacturers of the iStent evaluated the stability of the implant on *ex vivo* eyes confirming that the L shape of the stent could not be moved even with strong traction on the stent itself.

A small clinical case series (n=6) reaffirmed the potential clinical utility of the current titanium version inserted *ab interno* and provided additional confirmation that the device stayed in place and continued to function to lower IOP with fewer medications through follow-up of one year.¹⁰ All patients were seen day one, week one and at 1, 2, 6 and 12 months post-operatively. The mean pre-operative IOP of 20.2 ±6.3 decreased and stabilized at 14 to 15 mm Hg with reduced medications out to one year. All devices remained in place and no complications were noted.

A larger prospective, 24-month, uncontrolled, multicenter, multicountry evaluation of 58 patients with uncontrolled primary open-angle glaucoma (including pseudoexfoliation and pigmentary) evaluated the effectiveness of the concurrent phacoemulsification and stent implantation.¹¹ Of the 48 patients in the per protocol population, 42 completed the 12

months follow-up. At baseline, mean (\pm SD) intraocular pressure (IOP) was 21.7 \pm 3.98 mmHg. At 12 months, mean IOP was reduced to 17.4 \pm 2.99 mmHg, a mean IOP reduction of 4.4 \pm 4.54 mmHg ($p < 0.001$, 18.3%). At baseline, patients were taking a mean 1.6 \pm 0.8 medications. By 12 months, the mean number of medications was reduced to 0.4 \pm 0.62 ($p < 0.001$). Half the patients achieved an IOP \leq 18 mmHg and were able to discontinue hypotensive medication by the 12 month visit. The most commonly reported device-related adverse events were the appearance of stent lumen obstruction (seven eyes) and stent malposition (six eyes). None of the adverse events were deemed serious.

In 2010 Fea compared in a randomized study the results of phacoemulsification alone vs combined surgery (i.e. phacoemulsification and stent implantation).¹² The baseline IOP was similar in the two groups (combined group: 17.9 \pm 2.6; control group: 17.3 \pm 3.0 mm Hg) with a similar number of medications (2.0 \pm 0.9 in the combined group and 1.9 \pm 0.7 in the control group). Post-operative mean IOP at 15 months was 14.8 \pm 1.2 and 15.7 \pm 1.1 respectively in the combined and in the control group ($p = 0.031$). The author demonstrated that at 15 months the mean number of ocular hypotensive medications was significantly lower in the combined group (0.4 \pm 0.7 and 1.3 \pm 1.0, respectively; $P = .007$). Furthermore, after wash-out of ocular hypotensive medications, IOP was significantly lower in the combined group (16.6 \pm 3.1 mm Hg and 19.2 \pm 3.5 mm Hg). These results confirm the previous observation that IOP reduction could only partially be attributed to phacoemulsification and was in fact enhanced further by implantation of the iStent. The same author previously published a case report demonstrating the effectiveness of the procedure in one pseudophakic patient.¹³

More recently the effect of the iStent on flow was further elucidated by a fluorophotometric study by Fernandez-Barrientos et al.¹⁴ Thirty-three eyes of 33 patients were randomized to either two stents and cataract surgery ($n = 17$, Group 1) or cataract surgery alone ($n = 16$, Group 2). Before surgery, flow and outflow facility were similar between Groups 1 and 2 (1.78 \pm 0.44 and 1.74 \pm 0.82 $\mu\text{L}/\text{min}$; $P = 0.18$; 0.12 \pm 0.03 and 0.13 \pm 0.06 $\mu\text{L}/\text{min}/\text{mm Hg}$; $P = 0.71$, respectively). At one year, outflow facility was significantly higher in the group with two stents (0.45 \pm 0.27 $\mu\text{L}/\text{min}/\text{mm Hg}$ in Group 1 and 0.19 \pm 0.05 $\mu\text{L}/\text{min}/\text{mm Hg}$ in Group 2; $P = 0.02$).

A larger prospective, randomized, open-label, controlled, multicenter clinical trial with a total of 240 eyes with mild to moderate open-angle glaucoma with intraocular pressure (IOP) \leq 24 mmHg controlled on one to three medications compared the results of the patients who were randomized to undergo cataract surgery with iStent implantation (treatment group) or cataract surgery only (control).¹⁵ The primary efficacy measure was unmedicated IOP \leq 21 mmHg at one year. A secondary measure was unmedicated IOP reduction \geq 20% at one year. Safety measures included best-corrected visual acuity (BCVA), slit-lamp observations, complications and adverse events. The study met the primary efficacy endpoint, with 72% of treatment eyes versus 50% of control eyes achieving the criterion ($P < 0.001$). At one year, IOP in both treatment groups was statistically lower from baseline values. Sixty-six percent of treatment eyes versus 48% of control eyes achieved \geq 20% IOP reduction without medication ($P = 0.003$). The overall incidence of adverse events was similar between groups with no unanticipated adverse device effects. This larger series not only further demonstrates the efficacy of the iStent in further lowering the intraocular pressure in patients undergoing cataract surgery, but also points out the safety of the

procedure. A longer post-operative follow-up through two years was reported more recently.¹⁶ Best-corrected visual acuity of 20/40 or better was reported in 93% of treatment vs. 91% of control eyes at two years. Over the two year period, post-operative adverse events occurring at a level of 5% or greater included posterior capsular opacification (6% treatment vs. 10% control), elevated IOP (4% vs. 7%, respectively), visual disturbance (3% vs. 7%, respectively) and iritis (1% vs. 5%, respectively). Furthermore, in the treatment group, stent obstruction and malposition occurred in a small percentage of eyes (4% and 3%, respectively) and resolved shortly after occurrence (with or without treatment). The authors concluded that the overall long-term safety of iStents implanted during cataract surgery was similar to that of cataract surgery alone and that the adverse event/complication rate was low through the two year post-operative period.

4.2 Trabectome

The results obtained by the Trabectome can be summarized by a single paper which reports the experience of the Trabectome group. In this retrospective case series the authors reported their experience on follow-up through one year on 143 of 1127 Trabectome surgical procedures, including 102 through one year from 738 Trabectome-only and 41 through one year from 366 Trabectome-phacoemulsification surgeries¹⁷. It should be pointed out that many eyes at relatively high risk for filtering surgery failure were included after prior failed trabeculectomy or other previous surgeries were included in the study. Considering glaucoma surgery only: 273 underwent SLT, 170 ALT, 20 aqueous shunt surgery, 104 trabeculectomy, five prior Trabectome and five laser iridectomy.

Considering all cases, mean pre-operative IOP of 23.8 +/- 7.7 mm Hg decreased by 39% to 16.5 +/- 4.0 mm Hg at 24 months (n = 50). Intra-operative reflux bleeding occurred in 77.6%. Medications decreased from 2.8 to 1.2 by 24 months. Sixty-five patients (5.8%) had IOP elevation > 10 mm Hg above baseline on day one. Failure led to trabeculectomy in 5.9% (n = 67) and shunt installation in 1.6% (n = 18). Kaplan-Meier failure was defined across groups with at least two weeks follow-up as IOP > 21 mm Hg with or without medications and not reduced by 20% below baseline on two consecutive visits or repeat surgery. For Trabectome-only cases, mean preoperative IOP of 25.7 +/- 7.7 mm Hg was reduced by 40% to 16.6 +/- 4.0 mm Hg at 24 months (n = 46). No prolonged hypotony, choroidal effusion, choroidal haemorrhage or infections occurred. Failure led to trabeculectomy in 8.1% (n = 60) and shunt installation in 1.9% (n = 14). Medications decreased from 2.93 to 1.2 by 24 months. For Trabectome-phacoemulsification cases, baseline IOP of 20.0 +/- 6.2 mm Hg decreased at 12 months to 15.9 +/- 3.3 mm Hg (18%) (n = 45) and medications decreased from 2.63 +/- 1.12 to 1.50 +/- 1.36. Sixteen (4.4%) of 365 had prior failed trabeculectomy and 139 of 365 (38%) had prior laser trabeculoplasty.

Although the the large number of patients who underwent surgery of the study are very impressive, there are major limitations, including the retrospective nature and the fact that a very small number of procedures reported had been followed up postoperatively. Of the 738 patients who underwent only the Trabectome procedure, only 102 had a one year follow-up and of the 366 with combined surgery only 41 were followed up to one year. Furthermore, it is not clear if the patients with a longer follow-up and with available data include those high risk patients who were originally included in the study. If this is the case it would have been very important to analyse if there was any difference in terms of efficacy in the high versus low risk patients.

Recently, Knape and Smith¹⁸ presented the case of a patient who had intra-operative blood reflux onto peripheral iris during trabeculectomy 11 months after Trabectome surgery. After having left the eye firm after surgery, the author did not report any other episode of hyphema during the following period. He hypothesizes that the absence of overlying angle structures, including the roof of Schlemm's canal, may have allowed blood to reflux into the angle and onto peripheral iris during a sudden decrease in intraocular pressure in trabeculectomy surgery. This self-limited episode suggests that the trabeculotomy remained patent, although the patient was not compensated and points out that further studies to assess the consequences of permanent trabecular meshwork tissue removal may be warranted.

More recently, Jea¹⁹ reported on a cohort of patients and showed that a previously failed Trabectome surgery does not seem to impact the effect of subsequent trabeculectomy.

5. Complications prevention and treatment

Bleeding: bleeding with iStent, Trabectome or other trabecular bypass procedures is generally minimal, although aspiration of the blood in phakic eyes is suggested in order to allow proper visualization. A very rare occurrence of more significant bleeding in the anterior chamber is generally due to damage of the iris either because the surgeon did not aim at the correct site or because involuntary movements occurred during surgery. The use of air or viscoelastics can stop the haemorrhage. It is generally advisable to postpone the trabecular bypass procedure if massive bleeding occurred previously because angle visualization can be difficult and because the source of bleeding and the effect on the angle structures are easier to visualize after the hyphema has cleared.

Malposition: the iStent may at times appear malpositioned. This does not preclude the implantation of another one provided the angle can be visualized. It is advisable to move at least two or three clock hours away from the previous implant to better visualize the meshwork.

Occlusion: occlusion of the Stent by a seemingly fibrinous plug can sometimes be seen during the postoperative follow-up. This may sometimes be eliminated by a single YAG laser spot.

Endothelial damage: although possible, it has never been reported with any of the procedures described.

6. Conclusions

The idea of approaching the surgery site *ab interno* is certainly appealing. The opportunity to perform a more standardized procedure and the opportunity to preserve the conjunctiva and the sites of eventual subsequent surgery are attractive. Furthermore, creating a direct communication between Schlemm's canal and the anterior chamber is a more physiological approach to IOP reduction with a lower rate of complications and a faster surgery compared to any other available approach.

Several studies pointed out the efficacy of the iStent in the reduction of IOP, although these studies were mainly performed in conjunction with cataract surgery. Nevertheless, there is strong evidence both *in vitro* and *in vivo* that the stent insertion actually facilitates outflow independent of the concurrent phacoemulsification. The procedure is safe and complications

are mainly limited to a small (and transient) blood reflux into the anterior chamber immediately upon insertion into Schlemm's canal. It should be noted, however, that all studies were performed in eyes with relatively low pre-operative IOP. At present there is no published evidence of the efficacy in patients with severe glaucoma nor what would be the impact in patients with higher baseline IOP.

Upon casual review of the number of cases reported by the papers on the Trabectome and the length of the follow-up, it may appear that the evidence of efficacy of this surgical method is more stringent. The net IOP reduction seems higher with the Trabectome compared to the iStent and patients at higher risk had been treated with this method. However, a more accurate analysis of the literature reveals that a very small number of patients have been followed for a reasonable amount of time. Furthermore, the ablation of part of the trabecular meshwork is certainly a more destructive procedure, although it seems that this fact does not impact upon the results of conventional surgery in the limited series followed for an adequate postoperative timeframe.

IOP outcomes with both approaches are usually in the mid-teens. Although mid-teens IOP might be adequate for initial and moderate patients, traditional filtering surgery with anti-fibrotic enhancement and bleb formation will probably remain the principal surgical approach to eyes with advanced glaucomatous optic neuropathy. Eventually more advanced patients may benefit from trabecular bypass surgery combined with hypotensive medications, but too little data are available at present to sustain this approach. Assuming ongoing clinical studies continue to be favourable, a strong argument can be made for use of these minimally invasive procedures which do not lead to bleb formation nor require anti-fibrotics, early in the glaucoma injury process, especially considering the difficulties of compliance with medical therapy. Neither of these procedures damages the conjunctiva superiorly, leaving surgical alternatives where necessary open. Furthermore, continued development of suprachoroidal stents (such as the iStent supra and the newer Transcend Cypass) may offer additional IOP lowering and thus serve a broader population of patients with more advanced disease.

Given that glaucoma is typically a chronic disease and that the introduction of these methods is relatively new, follow-up of the patients at the moment is limited to two years at maximum.

Trabecular surgery requires some learning curve to visualize the angle using a hand-held gonioscopes and the diffuse illumination of the microscope gives a different appearance of the angle's structures as compared with slit lamp gonioscopy. Furthermore, the need for using a hand to hold the gonioscope makes any trabecular surgery strictly bimanual. During surgery, the implantation of the iStent is relatively easier compared with the Trabectome, because it does not need a continuous circumferential movement and because the chamber is well formed with viscoelastics. After the implantation of the device, the blood reflux in the anterior chamber is generally minimal with the iStent.

On the other hand, the Trabectome allows a visual feeling that the trabecular meshwork is ablated, whereas it is sometimes difficult to be sure of the correct iStent placement, especially when blood cannot be completely washed from the angle. Compared to trabeculectomy, additional costs with any device should also be considered. Furthermore at present only the Trabectome has been cleared by the FDA, although U.S. FDA approval of the iStent is expected in the near future.


7. References

- [1] Janz NK, Wren PA, Lichter PR, et al. The Collaborative Initial Glaucoma Treatment Study: interim quality of life findings after initial medical or surgical treatment of glaucoma. *Ophthalmology* 2001;108:1954-1965
- [2] Higginbotham EJ, Stevens RK, Musch DC, et al. Bleb related endophthalmitis after trabeculectomy with mitomycin C. *Ophthalmology* 1996;103:650-656.
- [3] Soltau JB, Rothman RF, Budenz DL, et al. Risk factors for glaucoma filtering bleb infections. *Arch Ophthalmol* 2000; 118:338-342.
- [4] Greenfield DS, Suner IJ, Miller MP, Kangas TA, Palmberg PF, Flynn HW. Endophthalmitis after filtering surgery with mitomycin. *Arch Ophthalmol* 1996;114:943-949.
- [5] Fontana H, Nouri-Mahdavi K, Lumba J, Ralli M, Caprioli J. Trabeculectomy with mitomycin C: outcomes and risk factors for failure in phakic open-angle glaucoma. *Ophthalmology* 2006;113:930-6
- [6] Anand N, Arora S, Clowes M. Mitomycin C augmented glaucoma surgery: evolution of filtering bleb avascularity, transconjunctival oozing, and leaks. *Br J Ophthalmol* 2006;90:175-80.
- [7] Trabectome description at <http://www.ncbi.nlm.nih.gov.proxy-medicina.unito.it/pubmed/16378021>.
- [8] Trabectome description at <http://www.ncbi.nlm.nih.gov.proxy-medicina.unito.it/pubmed/18936637>.
- [9] Bahler C, Smedley G, Zhou J, Johnson D. Trabecular bypass stents decrease intraocular pressure in cultured human anterior segments. *Am J Ophthalmol* 2004; 138:988-994.
- [10] Spiegel D, Wetzel W, Haffner DS, Hill RA. Initial clinical experience with the trabecular micro-bypass stent in patients with glaucoma. *Adv Ther* 2007;24:161-170.
- [11] Spiegel D, Wetzel W, Neuhann T, Sturmer J, Hoh H, Garcia-Feijoo J, Martinez de la casa JM, Garcia-Sanchez J. Coexistent primary open-angle glaucoma and cataract: interim analysis of a trabecular micro-bypass stent and concurrent cataract surgery. *Eur J Ophthalmol* 2009; 19:393-399.
- [12] Fea AM. Phacoemulsification versus phacoemulsification with micro-bypass stent implantation in primary open-angle glaucoma. *J Cataract Refract Surg* 2010;36:407-412.
- [13] Fea A, Dogliani M, Macetta F et al. Case report: The trabecular bypass stent in a pseudophakic glaucoma patient: A 1-year follow-up. *Clinical Ophthalmology* 2008;2:931-934.
- [14] Fernández-Barrientos Y, Garcia-Feijoo J, Martínez de la Casa JM, et al. Fluorophotometric study of the effect of the Glaukos trabecular micro-bypass stent on aqueous humor dynamics. *Invest Ophthalmol Vis Sci* 2010;51:3327-3332.
- [15] Samuelson TW, Katz LJ, Wells JM, et al. Randomized evaluation of the trabecular micro-bypass stent with phacoemulsification in patients with glaucoma and cataract. *Ophthalmology* 2011;118:459-467.
- [16] Craven ER. Prospective, Randomized Controlled Trial of Cataract Surgery with Trabecular Micro-Bypass Stent in Mild-Moderate Open Angle Glaucoma: Safety in Two Year Follow-up. Paper presented at 2011 American Society of Cataract and Refractive Surgeons, April, 2011; San Diego, CA.

- [17] Minckler D,* Mosaed S, Dustin L, Francis B, AND the Trabectome Study Group†. Trabectome (trabeculectomy-internal approach): additional experience and extended follow-up. *Trans Am Ophthalmol Soc* 2008;106:149-160
- [18] Knape RM and Smith MF. Anterior chamber blood reflux during trabeculectomy in an eye with previous Trabectome surgery. *J Glaucoma* 2010;19:499-500
- [19] Jea SY, Mosaed S, Vold SD, Rhee DJ. Effect of a Failed Trabectome on Subsequent Trabeculectomy. *J Glaucoma*. 2011 Feb 17. [Epub ahead of print]

IntechOpen

IntechOpen



Advances in Ophthalmology

Edited by Dr Shimon Rumelt

ISBN 978-953-51-0248-9

Hard cover, 568 pages

Publisher InTech

Published online 07, March, 2012

Published in print edition March, 2012

This book focuses on the different aspects of ophthalmology - the medical science of diagnosis and treatment of eye disorders. Ophthalmology is divided into various clinical subspecialties, such as cornea, cataract, glaucoma, uveitis, retina, neuro-ophthalmology, pediatric ophthalmology, oncology, pathology, and oculoplastics. This book incorporates new developments as well as future perspectives in ophthalmology and is a balanced product between covering a wide range of diseases and expedited publication. It is intended to be the appetizer for other books to follow. Ophthalmologists, researchers, specialists, trainees, and general practitioners with an interest in ophthalmology will find this book interesting and useful.

How to reference

In order to correctly reference this scholarly work, feel free to copy and paste the following:

Antonio Fea, Giulia Consolandi, Giulia Pignata, Davide Turco, Paola Cannizzo, Elena Bartoli, Teresa Rolle and Federico M. Grignolo (2012). Trabecular Surgery, *Advances in Ophthalmology*, Dr Shimon Rumelt (Ed.), ISBN: 978-953-51-0248-9, InTech, Available from: <http://www.intechopen.com/books/advances-in-ophthalmology/trabecular-surgery>

INTECH
open science | open minds

InTech Europe

University Campus STeP Ri
Slavka Krautzeka 83/A
51000 Rijeka, Croatia
Phone: +385 (51) 770 447
Fax: +385 (51) 686 166
www.intechopen.com

InTech China

Unit 405, Office Block, Hotel Equatorial Shanghai
No.65, Yan An Road (West), Shanghai, 200040, China
中国上海市延安西路65号上海国际贵都大饭店办公楼405单元
Phone: +86-21-62489820
Fax: +86-21-62489821

© 2012 The Author(s). Licensee IntechOpen. This is an open access article distributed under the terms of the [Creative Commons Attribution 3.0 License](#), which permits unrestricted use, distribution, and reproduction in any medium, provided the original work is properly cited.

IntechOpen

IntechOpen