

We are IntechOpen, the world's leading publisher of Open Access books Built by scientists, for scientists

4,800

Open access books available

122,000

International authors and editors

135M

Downloads

Our authors are among the

154

Countries delivered to

TOP 1%

most cited scientists

12.2%

Contributors from top 500 universities



WEB OF SCIENCE™

Selection of our books indexed in the Book Citation Index
in Web of Science™ Core Collection (BKCI)

Interested in publishing with us?
Contact book.department@intechopen.com

Numbers displayed above are based on latest data collected.

For more information visit www.intechopen.com



Deep Venous Thrombosis After Radical Pelvic Surgery

Bedeir Ali-El-Dein

*Mansoura University, Urology and Nephrology Center
Egypt*

1. Introduction

Deep venous thrombosis or DVT is a blood clot formation in one or more of the deep veins. The blood clot does not break down and therefore, it can become larger and occlude the blood flow within the affected vein. The most frequent sites are the leg veins (femoral and popliteal) and the deep pelvic veins. Rarely, the arm veins are affected (Paget-Schrötter disease). Pulmonary embolism (PE) is the most dangerous complication of DVT. PE occurs when the clot breaks into small pieces (emboli) and travel to the lung. The embolus may travel to other vital organs and cause life-threatening complications such as stroke or heart attack.

The etiology of thrombosis is exactly unknown, however, the Virchow's triad of slow circulation (stasis), increased blood coagulability and vessel wall intimal injury is the alleged mechanism.

DVT and PE developing after trauma and pelvic surgery are of a major concern to surgeons of all subspecialties. Therefore, proper assessment of the patient risk to develop DVT is of paramount importance. The risk of DVT can be decreased significantly by adopting some appropriate prophylactic procedures.

Although adopting anti-DVT prophylactic measures is not debatable, the use of these measures has not yet been a universal issue, even in patients having no contraindications to their use.

In this chapter, the term "radical pelvic surgeries" mean all types of major surgeries performed to treat malignancies developing in the pelvis, such as radical cystectomy, salvage cystectomy, radical prostatectomy, radical or pan-hysterectomy, radical surgery for colo-rectal cancer and excision of a local tumor recurrence after primary radical surgery or after definitive radiotherapy

2. Incidence

DVT constitutes a major health problem, especially among the elderly. In comparison with previous era, the incidence of DVT remains the same among men and possibly increasing in elderly females (Silverstein et al., 1998). On the other hand, the incidence of PE is decreasing

over years (Silverstein et al., 1998). However, the incidence of DVT and PE may be underestimated because of the missed diagnosis, absence of pertinent symptoms or the absence of laws to permit routine autopsies in sudden post-operative mortalities in most centers (Dalen & Alpert, 1975; Clagett, 1994). Furthermore, unexplained DVT may be the first presentation in some malignancies, such as prostate, colorectal and bladder (Monreal & Prandoni, 1999).

In a series of 2373 patients, the incidence of DVT was 0.87% after urologic surgeries for prostate and bladder tumors, 2.8% in general surgery and 2% in gynecological surgeries (Scarpa et al., 2007).

The incidence of DVT may be as low 2% after radical cystectomy (Ali-El-Dein et al., 2008; Ghoneim et al., 2008), or as high as 40% following prolonged gynecological or obstetrical surgery (Walsh et al., 1974; Clarke-Pearson et al., 1983). Patients undergoing large bowel surgery also have a considerable risk of DVT and pulmonary embolism. The incidence of DVT following radical cystectomy in our hospital is 2% to 2.6% and PE following DVT or without prior DVT has long been a leading cause of post-operative death (Ali-El-Dein et al., 2008; Ghoneim et al., 2008). In patients undergoing surgery or radiotherapy for treatment of localized prostate cancer the incidence of DVT was 2% for pelvic lymphadenectomy alone and 1.9% following prostatectomy, while fatal PE occurred in 2 patients (3.7%) after prostatectomy (Bratt et al., 1994).

The incidence of DVT after gynecologic and obstetrical surgeries varies according to the presence or absence of the known risk factors among patients and according to the methods of diagnosis. It has been reported that this incidence is 14% after benign gynecological surgeries (Walsh et al., 1974), while the rate has been higher (38%) for patients undergoing surgery for gynecological tumors (Crandon & Knotts, 1983). In addition, among all causes of death following gynecologic surgeries, PE has been a leading cause of postoperative mortality in high risk women with gynecologic malignancy (Clarke-Pearson et al., 1983). Following laparoscopic radical hysterectomy for cervical carcinoma the incidence of DVT has been 3% (Chen et al., 2008).

In the study of yang et al. on 3645 patients undergoing surgery for colorectal cancer, 31 (0.85%) developed symptomatic venous thromboembolism or VTE (Yang et al., 2011).

3. Pathogenesis and risk factors

The traditional Virchow's triad of hypercoagulability, Stasis of the venous stream and vessel wall (endothelial) trauma is still the basis of description of the pathophysiology of DVT.

One or more of these three factors may explain DVT in patients with radical pelvic surgeries. The risk factors and the underlying pathogenetic mechanisms of DVT are shown in table (1).

A major factor is immobilization (prolonged bed rest), which can impair venous drainage from the lower limb with subsequent venous stasis (Clark & Cotton, 1968).

The other reasons that can induce venous stasis as well as other risk factors for DVT/PE are enlisted in table (1).

Stasis:	<ul style="list-style-type: none"> -Immobilization. -Pelvic masses. - A gravid uterus - Surgically induced hematomas. - lymphocysts also can lead to venous stasis
Vessel wall injury:	<ul style="list-style-type: none"> -Surgical trauma. -Intravascular catheters. -Malignant involvement of the vessels of the tumor.
Thrombophilia	<ul style="list-style-type: none"> -Factor V Leiden mutation. -Prothrombin gene mutation. -G20210A. -Antithrombin deficiency -Factors I, V, VIII, IX, X, and XI. -The presence of activated intermediate coagulation products such as thrombin-antithrombin III complexes . -Abnormalities of the platelets . -Tissue factor and cancer procoagulant -Factors that influence vascular endothelial permeability such as vascular endothelial growth factor. -Protein C deficiency -Protein S deficiency
General factors:	<ul style="list-style-type: none"> -Obesity -Prior history of DVT -Hormonal therapy, -Chemotherapy, or radiotherapy for cancer -Old age -Oral contraceptive pills or hormonal replacement therapy -Pregnancy and the postpartum period -Burns -Sepsis -Systemic lupus erythematosus -Polycythemia rubra vera -Thrombocytosis -Erythropoiesis-stimulating agents -Dysfibrinogenemias and disorders of plasminogen activation -Intravenous (IV) drug abuse -Acute medical illness -Inflammatory bowel disease -Myeloproliferative disorders -Paroxysmal nocturnal hemoglobinuria -Nephrotic syndrome -Positive family history of DVT/PE -Smoking

Table 1. Risk factors in DVT following radical pelvic surgeries

Endothelial injury of the vessel wall may be induced by surgical dissection in various radical pelvic surgeries (e.g. radical cystectomy) or from infiltration of the vessel wall by the tumor. In addition, catheters placed distally or proximally in the venous system are among the risk factors (Evans et al., 2010). However, in this situation, the risk of DVT/PE is determined by multiple factors including catheter size (Evans et al., 2010), degree of vein trauma during catheter insertion and dwell and hypercoagulability of the patient's blood.

Hypercoagulability or thrombophilia or prothrombotic state is a blood coagulation disorder with a subsequent increase in the incidence of thrombosis (Heit, 2007). There are multiple genetic and acquired risk factors that influence thrombophilia. The presence of these inherited risk factors alone usually does not cause thrombosis unless an additional risk factor is present (Heit, 2007; Kyrle et al., 2010).

Antithrombin deficiency, which is the first major form of thrombophilia, was identified in 1965, while the most common defects, such as factor V Leiden mutation and prothrombin gene mutation G20210A were described in the 1990s (Dahlbäck, 2008; Rosendaal & Reitsma, 2009). The risk of developing DVT/PE increases significantly if one of these abnormalities is present in patients undergoing radical pelvic surgery.

There are various possibilities, which can induce a hypercoagulable state during major radical pelvic surgeries. These possibilities include decreased fibrinolytic activity associated with surgery (Egan et al., 1974), increased level of coagulation factors I, V, VIII, IX, X, and XI, the presence of activated intermediate coagulation products such as thrombin-antithrombin III complexes and abnormalities of the platelets (Piccioli et al., 1996). In addition, the malignant cells may secrete a substance promoting coagulation, such as tissue factor and cancer procoagulant or factors that influence vascular endothelial permeability such as vascular endothelial growth factor and subsequently stimulate fibrin deposition (Goad & Gralnick, 1996).

In the prospective study of Duke University Medical Center 411 patients undergoing major abdominal and pelvic gynecologic surgery were evaluated for DVT and the related possible risk factors (Clarke-Pearson et al., 1987). In this study, the important factors, which maintained statistical significance in stepwise logistic regression model were age, edema of the ankle, type of surgery, nonwhite race, presence of varicose veins, history of radiation preoperatively, past DVT and duration of surgery.

It has been found that the risk factors for distal DVT are different from those of proximal DVT. In the national (France) multicenter prospective OPTIMEV study, out of 6141 patients with symptoms suggestive of DVT, diagnosis was objectively confirmed in only 1643 and isolated distal DVT was more common than proximal one (Galanaud et al., 2009). In this study, acute or transient risk factors, such as recent surgery, recent plaster immobilization and recent travel, were more frequently discovered in distal DVT. On the other hand, in proximal DVT chronic risk factors such as active cancer, congestive heart failure or respiratory insufficiency and age above 75 years were more frequent.

Active cancer and related chemotherapy can increase the incidence of DVT by multiple mechanisms. In chronic lymphocytic leukemia patients, studies showed a link between lenalidomide associated DVTs and inflammation, upregulation of TNF α and endothelial cell dysfunction (Aue et al., 2011).

4. Diagnosis of DVT/PE

The majority of cases of DVT/PE have one or more risk factor. Many cases of DVT/PE are asymptomatic. Suspected pulmonary embolism is a medical emergency and can be fatal. In symptomatic DVT cases, the patient may present with lower limb pain, unilateral leg swelling, redness and sometimes prominent superficial veins. A tender calf, especially with dorsiflexion (Homan's sign) and rarely a palpable venous cord are among the possible physical signs. However, the presence of these manifestations is nonspecific, because in more than 50% of the cases presenting with these symptoms, DVT is absent (Dainty et al., 2004). Therefore, diagnosis of DVT based on symptoms only is problematic and proper hospital assessment and further diagnostic tools are needed for accurate diagnosis. Similarly, most of the symptoms and signs of PE are nonspecific and simulate post-surgery pulmonary complications. However, physicians should maintain a high degree of suspicion if the patient is complaining of pleuritic chest pain, hemoptysis, dyspnea, tachycardia and tachypnea.

4.1 Laboratory testing

The use of a simple prediction tool, together with the laboratory tests of D-dimers and arterial blood gases (ABG) in cases of suspected PE are useful tools to exclude or prove DVT (Crisan et al., 2011). D-dimers are fibrinogen degradation products which are generally present at higher concentrations than normal in the blood of people with DVT.

4.2 Imaging in DVT

Imaging for DVT includes B-mode duplex Doppler ultrasound, impedance plethysmography, contrast venography, and magnetic resonance venography (MRV). Doppler ultrasound is currently the most common technique for the diagnosis of symptomatic DVT. B-mode ultrasonography allows a bi-dimensional image of the vessels of the lower extremity and when compression techniques are used, a sensitivity of up to 90% and a specificity of 96% to 100% can be achieved in the detection of DVT (Cronan et al., 1987; O'Leary et al., 1988).

In duplex ultrasonography B-mode is combined with Doppler flow, therefore, providing information about flow velocity. When color Doppler flow is used with compression B-mode ultrasonography (color duplex ultrasonography), additional data on the direction of flow is gained (Cronan et al., 1987; O'Leary et al., 1988).

Impedance plethysmography is a noninvasive diagnostic test that has a good accuracy in the detection of proximal DVT, when the results are analyzed in combination with positive clinical data (Kearon et al., 1998). However, false positive results may be obtained with this test and if the results of this test are non-diagnostic or not coping with the clinical data, venography should be performed (Kearon et al., 1998).

Contrast venography is still the gold standard for the diagnosis of DVT and is used by investigators as a reference standard for testing the new noninvasive diagnostic DVT measures (Tapson et al., 1999).

The technique is done as classically described (Rabinov & Paulin, 1972). A misdiagnosis is expected if all the deep veins from the leg up to the vena cava are not seen. When there is a persistent filling defect in the lumen of 2 or more veins, the diagnosis of DVT is confirmed

(Rabinov & Paulin, 1972). Currently, contrast venography is rarely indicated nowadays and has been replaced by the noninvasive measures. It is sometimes performed to confirm the diagnosis of a clinically suspected DVT. However, if noninvasive imaging is normal or inconclusive and still DVT is clinically suspected, venography is done to confirm the diagnosis. In the cases of clinical suspicion of DVT, a negative contrast venography rules out the need for anticoagulant treatment (Hull et al., 1981). The test has certain limitations and complications.

Magnetic resonance venography (MRV) is an accurate noninvasive venographic technique for the detection of DVT. It has a sensitivity and specificity comparable to contrast venography (Carpenter et al., 1993). Furthermore, it can detect thrombi places not seen by the conventional venography, such as pelvic, ovarian veins or vena cava. Two major limitations for MRV are present, namely, the expensive cost and prolonged time necessary (Carpenter et al., 1993).

Scintigraphy has been described as a diagnostic tool for DVT (Knight, 1993). However, the data of its clinical efficacy compared to the standard methods are still lacking.

4.3 Imaging in PE

The diagnosis of PE may be made by a variety of imaging techniques, including chest X-ray, ventilation-perfusion scan, computed tomography (CT) of the chest vessels and pulmonary angiography.

On clinical suspicion of PE, the initial evaluation is made using chest X-ray, Electrocardiography (ECG) and ABG. Further evaluation is made by ventilation-perfusion scan, CT of the chest vessels (Gulsun Akpınar & Goodman, 2008).

Currently, CT venography combined with pulmonary CT angiography for the detection of PE is increasingly used to confirm the diagnosis of suspected PE and the results have been extremely promising (Krishan et al., 2011).

5. Prophylaxis of DVT/PE

The incidence of DVT and subsequent PE can be decreased by adopting certain prophylactic mechanical and/ or pharmacologic measures, which have been proved to be safe and effective in most types of major surgeries (Martino et al., 2007; Geerts et al., 2008). Mechanical methods act by reducing stasis of venous blood and may stimulate endogenous fibrinolysis, while pharmacologic agents act by clot prevention through the various steps of the clotting cascade (Martino et al., 2007; Geerts et al., 2008).

5.1 Mechanical measures

Mechanical prophylaxis is usually simple to conduct and relatively less costly. It may be achieved through the use of graduated compression stockings, anti-embolism stocking, electrical stimulation of the leg muscles, intermittent external pneumatic calf compression and/ or the use of specific tables (Martino et al., 2007; Geerts et al., 2008; Miller, 2011).

5.2 Pharmacologic measures

These measures are very effective in most surgeries and therefore, should be made a routine practice (Agnelli, 2004). Low-dose unfractionated heparin or low-molecular-weight heparin

(LMWH) are the drugs of choice in patients undergoing radical pelvic operations in the fields of general, vascular, major urologic and gynecologic surgeries (Agnelli, 2004). In urologic patients judged as low-risk, early postoperative mobilization is the only measure needed. On the other hand, higher-risk patients should receive vitamin K antagonists, LMWH and/ or fondaparinux (Agnelli, 2004).

Some investigators recommended a double prophylaxis of mechanical measures as well as pharmacologic measures using pre- and post-operative anticoagulation, usually in the form of LMWH (Whitworth et al., 2011). They found that the use of preoperative anticoagulation seems to significantly decrease the risk of DVT in high-risk patients undergoing major gynecologic surgeries. In addition, there was no significant change in the rates of complications secondary to this protocol.

5.3 Dual prophylaxis

DVT may develop while the patient is on prophylaxis, therefore, the idea of dual prophylaxis (mechanical and pharmacologic) has emerged (Dainty et al., 2004; Whitworth et al., 2011).

This combination has been evaluated in patients undergoing colorectal operations. A combination of low-dose unfractionated heparin and graduated compression stockings has been found to be 4-fold more effective than low-dose unfractionated heparin alone in DVT/PE prophylaxis (Wille-Jorgensen et al., 2003). Similarly, this dual prophylaxis has been found to be cost-effective in high-risk patients undergoing surgeries for gynecologic tumors (Dainty et al., 2004).

5.4 Duration of prophylaxis during radical pelvic surgeries

Following radical pelvic surgery, mechanical prophylaxis may be started before the operation, while pharmacologic prophylaxis is usually started after the operation and continued daily for 5–10 days or until the patient was fully mobile (Geerts et al., 2008; unpublished data by the author).

6. Treatment of DVT/PE

The goals of treatment of patients with DVT and PE are to prevent local growth of the thrombus, prevent the thrombus from breaking down into small pieces (emboli) and traveling to other places, prevent complications of DVT, prevent recurrence of the thrombus and in some clinical situations accelerate fibrinolysis (Hirsh & Hoak, 1996).

DVT is treated by immediate institution of anticoagulant therapy. Treatment is given as either unfractionated heparin or low molecular weight heparins, followed by few weeks to 6 months of oral anticoagulant therapy (Clarke-Pearson & Abaid, 2008). However, life-long anticoagulation has been recommended in some patients with active cancers after partial improvement or failure of treatment, because they remain at very high risk to recurrent DVT (Clarke-Pearson & Abaid, 2008). Low concentrations of heparin can inhibit the early stages of blood coagulation. However, higher concentrations are needed to inhibit the much higher concentrations of thrombin that are formed if the DVT process is not modulated (Hirsh & Hoak, 1996).

When unfractionated heparin is used, we usually start by a bolus injection followed by continuous infusion and the dose is then adjusted to maintain the level of activated partial thromboplastin time (APTT) at 1.5–2.5 times the control value (Clarke-Pearson & Abaid, 2008). Oral anticoagulation (warfarin) should be started on the first day of the heparin infusion aiming to achieve an international normalized ratio (INR) of 2.0–3.0. IV heparin may be discontinued in 5 days if an adequate INR level has been established (Clarke-Pearson & Abaid, 2008). Studies have demonstrated that some of the new anticoagulants, such as hirudin and its fragments, are effective inhibitors of clot-bound thrombin and therefore, they may provide a better efficacy than heparin in neutralizing the procoagulant effects of the fibrin-bound thrombin (Weitz et al., 1990).

Low molecular weight heparins such as enoxaparin and dalteparin have been proved to be as effective and safe as unfractionated heparin in the treatment and recurrence prophylaxis of DVT/PE (Quinlan et al., 2004). They have the advantage of the possibility to be given in the outpatient setting (Clarke-Pearson & Abaid, 2008).

Fibrinolysis can be performed by one of the fibrinolytic enzymes, such as streptokinase, urokinase and TPA, all of them can increase the dissolution rate of the thrombus or embolus (Hirsh & Hoak, 1996). They are not routinely recommended in the treatment of DVT/PE, because of their cost and the high risk of bleeding (Hirsh & Hoak, 1996). Thrombolytic therapy is indicated in all patients with massive pulmonary embolism and in some selected cases of proximal DVT or with severe obstruction (Hirsh & Hoak, 1996). Thrombolytic therapy has the advantage of preserving the pulmonary microcirculation after PE and decreasing the possibility of post-thrombotic syndrome (PTS) following DVT (Linn et al., 1988). Intrapulmonary artery infusion of urokinase in extensive PE has been found to be safe and effective in treatment of patients with and without contraindication to the use of systemic thrombolytic therapy (McCotter et al., 1999). With the recommended dose, thrombolytic therapy produces significant and rapid resolution of pulmonary emboli with a low morbidity and mortality rate. However, in lower extremity DVT, therapeutic thrombolysis is still controversial.

In PE immediate anticoagulant therapy is given and respiratory support is maintained. In addition, pulmonary artery catheterization with the administration of thrombolytic agents has been tried as previously mentioned (McCotter et al., 1999).

Surgical intervention of the thrombus or embolus is rarely indicated. However, surgical extirpation of the thrombus (venous thrombectomy), of the embolus (pulmonary embolectomy) and endovascular therapies to treat DVT have been reported with promising results (Lindow et al., 2010; Jenkins, 2011).

Long-term results after transfemoral venous thrombectomy for iliofemoral DVT has shown that the technique is safe and effective and can prevent the development of severe post-thrombotic syndrome in the long term (Lindow et al., 2010).

Inferior vena cava filters have been introduced to prevent PE in patients in whom anticoagulation therapy is contraindicated, has failed or has been associated with complications and in patients with extensive free-floating thrombi or residual thrombi following massive PE (Chung et al., 2008; Kalva et al., 2008).

7. Conclusion

Deep venous thrombosis and pulmonary embolism are among the major post-operative complications that develop after radical pelvic surgeries. Pulmonary embolism is one of the leading causes of post-operative mortality in these patients. Most of the cases are asymptomatic and in the majority of patients dying from pulmonary embolism the embolism is diagnosed at autopsy. Treatment is essentially prophylactic and the primary treatment objectives are to prevent PE, decrease morbidity and to prevent the risk of developing the post-thrombotic syndrome (PTS). High-risk patients may be subject for dual mechanical and pharmacologic prophylaxis with good results. Anticoagulation provides the main stay of treatment. Thrombolytic therapy is currently used for massive pulmonary embolism and some selected cases of deep venous thrombosis. Surgical (thrombectomy or embolectomy) or endovascular techniques have been tried with promising results.

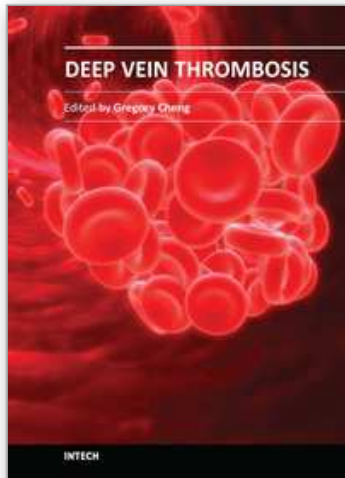
8. References

- Ali-El-Dein, B., Shaaban, A.A., Abu-Eideh, R.H., El-Azab, M., Ashamallah, A. & Ghoneim, M.A. (2008). Surgical complications following radical cystectomy and orthotopic neobladders in women. *J Urol*, 180,1,206-10.
- Agnelli, G. (2004). Prevention of venous thromboembolism in surgical patients. *Circulation*, 110, (24 Suppl 1), IV4-12.
- Aue, G., Nelson Lozier, J., Tian, X., Marie Cullinane, A., Soto, S., Samsel, L., McCoy, P. & Wiestner, A. (2011). Inflammation, TNF α and endothelial dysfunction link lenalidomide to venous thrombosis in chronic lymphocytic leukemia. *Am J Hematol*, Jun 27. doi: 10.1002/ajh.22114. [Epub ahead of print][<http://www.ncbi.nlm.nih.gov/pubmed/21812019>]
- Bratt, O., Elfving, P., Flodgren, P. & Lundgren, R. (1994). Morbidity of pelvic lymphadenectomy, radical retropubic prostatectomy and external radiotherapy in patients with localised prostatic cancer. *Scand J Urol Nephrol*, 28,3,265-71.
- Carpenter, J.P., Holland, G.A., Baum, R.A., Owen, R.S., Carpenter, J.T. & Cope, C. (1993). Magnetic resonance venography for the detection of deep venous thrombosis: comparison with contrast venography and duplex Doppler ultrasonography. *J Vasc Surg*, 18,5, 734-41.
- Chen, Y., Xu, H., Li, Y., Wang, D., Li, J., Yuan, J. & Liang, Z. (2008). The outcome of laparoscopic radical hysterectomy and lymphadenectomy for cervical cancer: a prospective analysis of 295 patients. *Ann Surg Oncol*, 15,10,2847-55.
- Chung, J. & Owen, R.J.T. (2008). Using inferior vena cava filters to prevent pulmonary embolism. *Can Fam Physician*, 54,1, 49 - 55 .
- Clagett, G.P. (1994) Prevention of postoperative venous thromboembolism: An update. *Am J Surg*, 168,6, 515-22.
- Clark, C. & Cotton, L.T. (1968). Blood-flow in deep veins of leg: Recording technique and evaluation of methods to increase flow during operation. *Br J Surg*, 55,3, 211-4.
- Clarke-Pearson, D.L., Jelovsek, F.R. & Creasman, W.T. (1983). Thromboembolism complicating surgery for cervical and uterine malignancy: Incidence, risk factors and prophylaxis. *Obstet Gynecol*, 61,1, 87-94.
- Clarke-Pearson, D.L., DeLong, E.R., Synan, I.S., Coleman, R.E. & Creasman, W.T. (1987). Variables associated with postoperative deep venous thrombosis: a prospective

- study of 411 gynecology patients and creation of a prognostic model. *Obstet Gynecol*, 69,2, 146-50.
- Clarke-Pearson, D. & Abaid, L. (2008). Venous Thromboembolism in Gynecologic Surgery. *Glob. libr. women's med.*, (ISSN: 1756-2228) 2008; DOI 10.3843/GLOWM.10069
- Crandon, A.J. & Knotts, J. (1983). Incidence of post-operative thrombosis in gynaecological oncology. *Aust NZ J Obstet Gynaecol*, 23,4, 216-9.
- Crişan, S., Vornicescu, D., Crişan, D., Pop, T. & Vesa, S. (2011). Concomitant acute deep venous thrombosis and superficial thrombophlebitis of the lower limbs. *Med Ultrason*, 13,1, 26-32.
- Cronan, J.J., Dorfman, G.S., Scola, F.H., Schepps, B. & Alexander, J. (1987). Deep venous thrombosis: US assessment using vein compression. *Radiology*, 162,1, 191-4.
- Dahlbäck, B. (2008). Advances in understanding pathogenic mechanisms of thrombophilic disorders. *Blood*, 112,1, 19-27.
- Dainty, L., Maxwell, G.L., Clarke-Pearson, D.L. & Myers, E.R. (2004). Cost-effectiveness of combination thromboembolism prophylaxis in gynecologic oncology surgery. *Gynecol Oncol*, 93,2, 366-73.
- Dalen, J.E. & Alpert, J.S. (1975). Natural history of pulmonary embolism. *Prog Cardiovasc Dis*, 17,4, 259-70.
- Egan, E.L., Bowie, E.J.W., Kazmier, F.J., Gilchrist, G.S., Woods, J.W. & Owens, C.A. Jr. (1974). Effect of surgical operations on certain tests used to diagnose intravascular coagulation and fibrinolysis. *Mayo Clin Proc*, 49,9, 658-64.
- Evans, R.S., Sharp, J.H., Linford, L.H., Lloyd, J.F., Tripp, J.S., Jones, J.P., Woller, S.C., Stevens, S.M., Elliott, C.G. & Weaver, L.K. (2010). Risk of symptomatic DVT associated with peripherally inserted central catheters. *Chest*, 138,4, 803-10.
- Galanaud, J.P., Sevestre-Pietri, M.A., Bosson, J.L., Laroche, J.P., Righini, M., Brisot, D., Boge, G., van Kien, A.K., Gattolliat, O., Bettarel-Binon, C., Gris, J.C., Genty, C., Quere, I. & OPTIMEV-SFMV Investigators. (2009). Comparative study on risk factors and early outcome of symptomatic distal versus proximal deep vein thrombosis: results from the OPTIMEV study. *Thromb Haemost*, 102,3, 493-500.
- Geerts, W.H., Bergqvist, D., Pineo, G.F., Heit, J.A., Samama, C.M., Lassen, M.R., Colwell, C.W. & American College of Chest Physicians. (2008). Prevention of venous thromboembolism: American College of Chest Physicians Evidence-Based Clinical Practice Guidelines (8th Edition). *Chest*, 133(6 Suppl), 381S-453S.
- Ghoneim, M.A., Abdel-Latif, M., el-Mekresh, M., Abol-Enein, H., Mosbah, A., Ashamallah, A. & el-Baz, M.A (2008). Radical cystectomy for carcinoma of the bladder: 2,720 consecutive cases 5 years later. *J Urol*, 180,1,121-7.
- Goad, K.E. & Gralnick, H.R. (1996). Coagulation disorders in cancer. *Hematol Oncol Clin North Am*, 10,2, 457-84.
- Gulsun Akpınar, M. & Goodman, L.R. (2008). Imaging of pulmonary thromboembolism. *Clin Chest Med*, 29,1, 107-16.
- Heit, J.A. (2007). Thrombophilia: common questions on laboratory assessment and management. *Hematology Am Soc Hematol Educ Program*, 2007(1), 127-35. doi:10.1182/asheducation-2007.1.127. PMID 18024620. <http://asheducationbook.hematologylibrary.org/cgi/content/full/2007/1/127>
- Hirsh, J. & Hoak, J. (1996). Management of deep vein thrombosis and pulmonary embolism. A statement for healthcare professionals. Council on Thrombosis (in consultation

- with the Council on Cardiovascular Radiology), American Heart Association. *Circulation*, 15,93,12, 2212-45.
- Hull, R., Hirsh, J., Sackett, D.L., Taylor, D.W., Carter, C., Turpie, A.G., Powers, P. & Gent, M. (1981). Clinical validity of a negative venogram in patients with clinically suspected venous thrombosis. *Circulation*, 64,3, 622-5.
- Jenkins, J.S. (2011). Endovascular therapies to treat iliofemoral deep venous thrombosis. *Prog Cardiovasc Dis*, 54,1, 70-6.
- Kalva, S.P., Chlapoutaki, C., Wicky, S., Greenfield, A.J., Waltman, A.C. & Athanasoulis, C.A. (2008). Suprarenal inferior vena cava filters: a 20-year single-center experience. *J Vasc Interv Radiol*, 19,7, 1041-7.
- Kearon, C., Julian, J.A., Newman, T.E. & Ginsberg JS. (1998). Noninvasive diagnosis of deep venous thrombosis. McMaster Diagnostic Imaging Practice Guidelines Initiative. *Ann Intern Med*, 128,8, 663-77.
- Knight, L.C. (1993). Scintigraphic methods for detecting vascular thrombus. *J Nucl Med*, 34,3 Suppl, 554-61.
- Krishan, S., Panditaratne, N., Verma, R. & Robertson, R. (2011). Incremental value of CT venography combined with pulmonary CT angiography for the detection of thromboembolic disease: systematic review and meta-analysis. *AJR Am J Roentgenol*, 196,5, 1065-72.
- Kyrle, P.A., Rosendaal, F.R. & Eichinger, S. (2010). Risk assessment for recurrent venous thrombosis. *Lancet*, 376(9757), 2032-9. doi:10.1016/S0140-6736(10)60962-2. PMID 21131039.
- Lindow, C., Mumme, A., Ascitutto, G., Strohmann, B., Hummel, T. & Geier B. (2010). Long-term results after transfemoral venous thrombectomy for iliofemoral deep venous thrombosis. *Eur J Vasc Endovasc Surg*, 40,1, 134-8.
- Linn, B.J., Mazza, J.J. & Friedenber, W.R. (1988). Treatment of venous thrombotic disease. *Postgrad Med*, 79,6, 171-80.
- Martino, M.A., Williamson, E., Rajaram, L., Lancaster, J.M., Hoffman, M.S., Maxwell, G.L. & Clarke-Pearson, D.L. (2007). Defining practice patterns in gynecologic oncology to prevent pulmonary embolism and deep venous thrombosis. *Gynecol Oncol*, 106,3, 439-45.
- McCotter, C.J., Chiang, K.S. & Fearington, E.L. (1999). Intrapulmonary artery infusion of urokinase for treatment of massive pulmonary embolism: a review of 26 patients with and without contraindications to systemic thrombolytic therapy. *Clin Cardiol*, 22,10, 661-4.
- Miller, J.A. (2011). Use and wear of anti-embolism stockings: a clinical audit of surgical patients. *Int Wound J*, 8,1, 74-83.
- Monreal, M. & Prandoni, P. (1999). Venous thromboembolism as first manifestation of cancer. *Semin Thromb Hemost*, 25,2,131-6.
- O'Leary, D.H., Kane, R.A. & Chase, B.M. (1988). A prospective study of the efficacy of B-scan sonography in the detection of deep venous thrombosis in the lower extremities. *J Clin Ultrasound*, 16,1, 1-8.
- Piccioli, A., Prandoni, P., Ewenstein, B.M. & Goldhaber, S.Z. (1996). Cancer and venous thromboembolism. *Am Heart J*, 132,4, 850-5.
- Quinlan, D.J., McQuillan, A. & Eikelboom, J.W. (2004). Low-molecular-weight heparin compared with intravenous unfractionated heparin for treatment of pulmonary

- embolism: a meta-analysis of randomized, controlled trials. *Ann Intern Med*, 140,3, 175-83.
- Rabinov, K. & Paulin, S. (1972). Roentgen diagnosis of venous thrombosis in the leg. *Arch Surg*, 104,2, 134-44
- Rosendaal, F.R. & Reitsma, P.H. (2009). Genetics of venous thrombosis. *J Thromb Haemost*, 7, Suppl 1,301-4.
- Scarpa, R.M., Carrieri, G., Gussoni, G., Tubaro, A., Conti, G., Pagliarulo, V., Mirone, V., De Lisa, A., Fiaccavento, G., Cormio, L., Bonizzoni, E., Agnelli, G. @RISTOS Study Group (2007). Clinically overt venous thromboembolism after urologic cancer surgery: results from the @RISTOS Study. *Eur Urol*,51,1,130-5
- Silverstein, M.D., Heit, J.A., Mohr, D.N., Petterson, T.M., O'Fallon, W.M. & Melton, L.J. 3rd. (1998). Trends in the incidence of deep vein thrombosis and pulmonary embolism: a 25-year population-based study. *Arch Intern Med*, 158, 6,585-93.
- Tapson, V.F., Carroll, B.A., Davidson, B.L., Elliott, C.G., Fedullo, P.R. & Hales, C.A., Hull, R.D., Hyers, T.M., Leeper, K.V. Jr., Morris, T.A., Moser, K.M., Raskob, G.E., Shure, D., Sostman, H.D. & Taylor Thompson, B. (1999). The diagnostic approach to acute venous thromboembolism. Clinical practice guideline. American Thoracic Society. *Am J Respir Crit Care Med*, 160, 3, 1043- 66.
- Walsh, J.J., Bonnar, J. & Wright, F.W. (1974). A study of pulmonary embolism and deep leg thrombosis after major gynecologic surgery using labeled fibrinogen phlebography and lung scanning. *J Obstet Gynaecol Br Commonw*, 81,4, 311-6.
- Weitz, J.I., Hudoba, M., Massel, D., Maraganore, J. & Hirsh, J. (1990). Clot-bound thrombin is protected from inhibition by heparin-antithrombin III but is susceptible to inactivation by antithrombin III-independent inhibitors. *J Clin Invest*, 86,2, 385-91.
- Whitworth, J.M., Schneider, K.E., Frederick, P.J., Finan, M.A., Reed, E., Fauci, J.M., Straughn, J.M. Jr. & Rocconi, R.P. (2011). Double prophylaxis for deep venous thrombosis in patients with gynecologic oncology who are undergoing laparotomy: does preoperative anticoagulation matter? *Int J Gynecol Cancer*, 21,6, 1131-4.
- Wille-Jorgensen, P., Rasmussen, M.S., Andersen, B.R. & Borly, L. (2003). Heparins and mechanical methods for thromboprophylaxis in colorectal surgery. *Cochrane Database Syst Rev*, 2003(4), CD001217.
- Yang, S.S., Yu, C.S., Yoon, Y.S., Yoon, S.N., Lim, S.B. & Kim, J.C. (2011). Symptomatic venous thromboembolism in Asian colorectal cancer surgery patients. *World J Surg*, 35,4, 881-7.



Deep Vein Thrombosis

Edited by Dr. Gregory Cheng

ISBN 978-953-51-0225-0

Hard cover, 184 pages

Publisher InTech

Published online 07, March, 2012

Published in print edition March, 2012

This book provides a comprehensive review of deep vein thrombosis. There are chapters on risk factors for DVT, post thrombotic syndrome and its management, vena cava malformation as a new etiological factor and thrombosis in the upper limbs. DVT is usually seen in patients undergoing major surgeries. The guidelines for thrombo-prophylaxis in orthopaedic patients, radical pelvic surgeries, laparoscopic operations and risks versus benefits in regions with a low prevalence of DVT are thoroughly addressed. Cancer and its treatment are recognized risk factors for VTE and extended prophylaxis in ambulatory cancer patients is reviewed. The role of imaging and endovascular therapies in acute DVT, hypercoagulability in liver diseases and the challenges in developing countries are discussed.

How to reference

In order to correctly reference this scholarly work, feel free to copy and paste the following:

Bedeir Ali-El-Dein (2012). Deep Venous Thrombosis After Radical Pelvic Surgery, Deep Vein Thrombosis, Dr. Gregory Cheng (Ed.), ISBN: 978-953-51-0225-0, InTech, Available from:

<http://www.intechopen.com/books/deep-vein-thrombosis/deep-venous-thrombosis-after-radical-pelvic-surgery>

INTECH

open science | open minds

InTech Europe

University Campus STeP Ri
Slavka Krautzeka 83/A
51000 Rijeka, Croatia
Phone: +385 (51) 770 447
Fax: +385 (51) 686 166
www.intechopen.com

InTech China

Unit 405, Office Block, Hotel Equatorial Shanghai
No.65, Yan An Road (West), Shanghai, 200040, China
中国上海市延安西路65号上海国际贵都大饭店办公楼405单元
Phone: +86-21-62489820
Fax: +86-21-62489821

© 2012 The Author(s). Licensee IntechOpen. This is an open access article distributed under the terms of the [Creative Commons Attribution 3.0 License](#), which permits unrestricted use, distribution, and reproduction in any medium, provided the original work is properly cited.

IntechOpen

IntechOpen