

We are IntechOpen, the world's leading publisher of Open Access books Built by scientists, for scientists

4,800

Open access books available

122,000

International authors and editors

135M

Downloads

Our authors are among the

154

Countries delivered to

TOP 1%

most cited scientists

12.2%

Contributors from top 500 universities



WEB OF SCIENCE™

Selection of our books indexed in the Book Citation Index
in Web of Science™ Core Collection (BKCI)

Interested in publishing with us?
Contact book.department@intechopen.com

Numbers displayed above are based on latest data collected.

For more information visit www.intechopen.com



Deep Vein Thrombosis of the Arms

Peter Marschang
Innsbruck Medical University
Austria

1. Introduction

Deep vein thrombosis is often regarded as a disease limited of the veins of the lower extremities, which may sometimes – in more severe cases – extend to the pelvic veins. Although this holds true for over 90% of all thromboses, clinically relevant thromboses may be found in virtually every vein system of the body. Of these uncommon localisations of thromboses, deep vein thrombosis of the arms is one of the most frequent entities, accounting for about 5% of all thromboses (Munoz et al., 2008; Isma et al., 2010). Most cases of deep arm vein thrombosis develop secondary in patients with indwelling central venous catheters, pacemakers, malignant disease, or after surgery. Conversely, primary upper extremity deep venous thrombosis is observed in patients after strenuous arm exercise (“thrombosis par effort”), in thoracic outlet syndrome and inherited or acquired thrombophilia (Bernardi et al., 2006). Acute and long-time complications of upper extremity thrombosis may be significant and include pulmonary embolism, post-thrombotic syndrome and recurrent thromboembolism. In this chapter, the clinical presentation, diagnostic procedures, treatment and prevention of thromboses of the upper extremity will be reviewed. It is not unusual to find thromboses of proximal arm veins and deep veins of the neck region at the same time. Therefore, thromboses of the internal jugular vein, which are also most often observed in the presence of indwelling central venous catheters, will also be discussed. In this review, special emphasis will be given to the practical aspects of the disease, like risk factors, clinical presentation, diagnosis, and treatment of arm vein thrombosis. For a detailed, comprehensive overview of pathophysiological mechanisms, the reader will be referred to other, excellent reviews within this field.

2. Epidemiology

The frequency of deep arm vein thrombosis relative to all deep thromboses has been reported to be between 1 and 14% (Hill & Berry, 1990; Joffe et al., 2004; Spencer et al., 2007). Recently, the prospective RIETE registry and the population based Malmö thrombophilia study reported both very similar rates of upper extremity deep vein thrombosis (4.4% and 5% of all thrombosis, respectively (Munoz et al., 2008; Isma et al., 2010). Therefore, it can be assumed that about 5% of all thrombosis will involve the deep arm veins, which corresponds to an annual incidence of approximately 3 per 100.000 patients per year (Bernardi et al., 2006). Less than 50% of these arm vein thromboses can be expected to extend into the internal jugular vein (Gbaguidi et al., 2011). About one

third of patients with deep arm vein thrombosis will have primary thrombosis, i.e. idiopathic and effort-related thrombosis (Paget-von Schroetter syndrome). The remaining two thirds of patients will have secondary upper extremity thrombosis with exogenous (e.g. central venous catheters) or endogenous (e.g. cancer) risk factors. In intensive care patients as well as in patients suffering from malignant disease with central venous catheters, rates of asymptomatic thrombosis as high as 30% to over 60% have been reported (Timsit et al., 1998; Van Rooden et al., 2005). There appears to be an increase in upper extremity deep vein thrombosis in the last decades, which may reflect the increasing use of central venous catheters (S. Mustafa et al., 2003; Czihal & Hoffmann, 2011), improved diagnostic methods, or both.

3. Anatomy of the deep arm veins

The anatomy of the deep veins of the upper extremity is shown schematically in Figure 1. The two brachiocephalic veins (also known as innominate veins) join to form the superior vena cava. Each brachiocephalic vein is formed by the confluence of the subclavian with the internal jugular vein. The subclavian vein arises from (usually more than one) axillary veins, which originate from the usually paired brachial veins. The main superficial arm veins, the cephalic and basilic veins, usually drain into the subclavian and axillary vein, respectively. The other, smaller arm veins (radial and ulnar veins) are only rarely involved in clinically significant deep vein thrombosis. Superficial thrombophlebitis may involve the cephalic and basilic veins as well as the smaller superficial veins in the cubital region or forearm. Of note, the subclavian vein passes between the clavicle and the first rib ventral of the anterior scalenus muscle, where it may be compressed in some patients especially during strenuous arm exercise. In some patients, this space is further limited by muscular hypertrophy (anterior scalenus or suclavius muscle) or bone abnormalities (clavicle, first rib, cervical rib), resulting in venous thoracic outlet syndrome (Illig & Doyle, 2010).

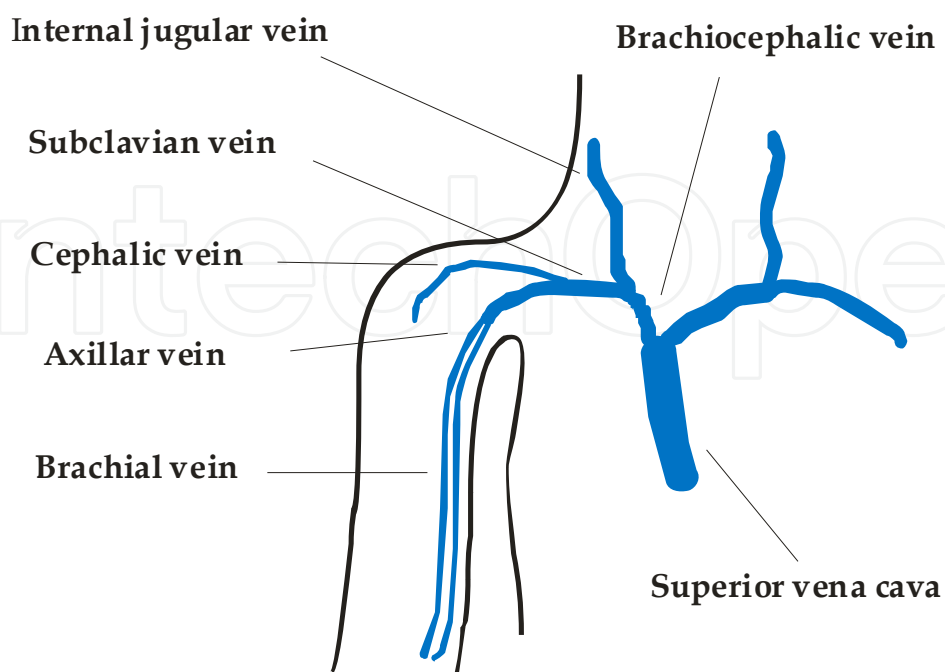


Fig. 1. Schematic view of the principal neck and arm veins.

4. Risk factors for arm vein thrombosis

Compared to deep vein thrombosis of the legs, local factors play a dominant role in deep arm vein thrombosis. By far the highest risk for thrombosis in this region is caused by foreign material in the lumen of the arm veins, most importantly indwelling central venous catheters and pacemaker leads. The odds ratio for arm vein thrombosis of patients carrying these intravascular devices compared to patients that do not has been reported to be as high as 10 to more than 1000 (Joffe et al., 2004; Blom et al., 2005), Table 1. This large variation in risk may in part be explained by specific features of the central venous catheter, as e.g. catheter type and material, site, technique and level of insertion as reviewed by Van Rooden et al., 2005. Additional factors that have an impact on the risk of thrombosis in patients with central venous catheters include the number of punctures during catheter insertion, the duration of catheterization, the fluid administered, and catheter related infections (Koksoy et al., 1995; Hernandez et al., 1998; Martin et al., 1999). In addition, wrong placement of the catheter tip in the upper half of the superior vena cava, subclavian or innominate veins results in a higher risk of thrombosis (Luciani et al., 2001; Verso et al., 2008). Implanted port a cath systems and pacemaker leads significantly increase the risk of arm vein thrombosis as well (Van Rooden et al., 2004; Goltz et al., 2010). The major pathogenetic mechanism appears to be the thrombogenicity of the foreign material itself. Other possible factors include injury of the vascular wall and disturbances of venous blood flow (Beathard, 2001). Different types of thrombi associated with central venous catheters have been described, ranging from fibrin sleeves that may be embolized following catheter removal, nonocclusive mural thrombi and complete venous obstruction (Brismar et al., 1981; Martin et al. 1999; Beathard, 2001). The second major risk factor for arm vein thrombosis is the presence of active malignant disease. Since chemotherapeutic agents are frequently delivered via central venous catheters, both major risk factors are often present in cancer patients. However, malignant disease carries a significant risk also in the absence of foreign material in the arm veins. The mechanisms by which malignant tumors promote thrombosis in various venous segments include local arrosion or invasion of blood vessels, hypercoagulability of the blood by the expression of tumor antigens, and stasis by tumor compression of venous segments proximal to the site of thrombosis (Sood, 2009; Martinelli et al., 2010). It is the experience of clinicians treating patients with thrombosis that this disease is most aggressive and difficult to treat in tumor patients. Hospitalisation has also been cited as a strong risk factor, which may be explained by the increasing frequency of complex therapeutic regimens requiring central venous lines for various indications (Joffe et al., 2004; Mai & Hunt, 2011). Other major risk factors are listed in Table 1 and include local factors (arm surgery, arm injury and immobilisation of the upper extremities by plaster casts), unusual strenuous arm exercise ("thrombosis par effort"), a family history of venous thromboembolism and inherited forms of thrombophilia, and the use of estrogen containing contraceptive drugs (Martinelli et al., 2004; Joffe et al., 2004; Blom et al., 2005). Although cited frequently, a thoracic outlet syndrome is diagnosed in comparably few cases (Blom et al., 2005). Several unusual risk factors for arm vein thrombosis have been reported in case reports, including backpacking (Schoen et al., 2007), portable computer games (Phipps & Joo, 2008), ambulatory blood pressure monitoring (Marschang et al., 2008), intravenous calcium gluconate injection (Chen et al., 2009), and infraclavicular lipoma (Palamari et al., 2010). Interestingly, two known risk factors for lower extremity deep vein thrombosis, namely age and obesity, do not appear to confer additional risk for upper deep vein thrombosis (Joffe et al., 2004; Mai & Hunt, 2011). Isolated thrombosis of the internal jugular vein may be observed in the context of two

distinct clinical entities, namely after recent oropharyngeal infections with anaerobic bacteria (*fusobacterium necrophorum*) and in the ovarian hyperstimulation syndrome (Gbaguidi et al., 2011). For the latter syndrome, the increased risk of thrombosis has been explained by the drainage of excessive estrogen concentrations in the peritoneal fluid via the thoracic and right lymphatic duct into the confluence region of the large neck veins (Bauersachs et al., 2007).

Risk factor	Odds ratio	95 % Confidence interval	Reference
Central venous catheter	1136	153 - 8448	Blom et al. 2005
	9.7	7.8 - 12.2	Joffe et al. 2004
Active cancer	18.1	9.4 - 35.1	Blom et al. 2005
Arm surgery	13.1	2.1 - 80.6	Blom et al. 2005
Plaster cast	7.0	1.7 - 29.5	Blom et al. 2005
Factor V Leiden*	6.2	2.5 - 15.7	Martinelli et al. 2004
Prothrombin G20210A*	5.0	2.0 - 12.2	Martinelli et al. 2004
Protein C, Protein S	4.9	1.1 - 22.0	Martinelli et al. 2004
Family history of VTE	2.8	1.6 - 4.9	Blom et al. 2005
Arm injury	2.1	0.7 - 6.2	Blom et al. 2005
Oral contraceptives	2.0	1.1 - 3.8	Blom et al. 2005
Unusual arm exercise	1.5	1.0 - 2.1	Blom et al. 2005

*heterozygous mutation. VTE venous thromboembolism

Table 1. Major risk factors for arm vein thrombosis with odds ratios adjusted for age and sex.

5. Clinical presentation

The presence of typical symptoms (swelling of the upper extremity, localized pain, and superficial collaterals) will raise the suspicion of the clinician to consider deep vein thrombosis of the arms. The most frequent symptom is edema of the upper extremity, which has been reported in 80% of cases by Joffe and coworkers. In addition, about 40% of patients report localized pain or aching discomfort in the involved extremity (Joffe et al., 2004). Other symptoms include reddish-blue discoloration, a sensation of heat or heaviness in the respective arm, or dilated superficial collateral veins on the upper arm, shoulder girdle, neck, and anterior chest wall (Prandoni et al., 1997a; Kommareddy et al., 2002; Bernardi et al., 2006). In at least 5% of cases, deep vein thrombosis of the arms will be completely asymptomatic (Mai & Hunt, 2011). In some cases, patients will become symptomatic only after the occurrence of complications, like dyspnea in the case of pulmonary embolism, or rarely venous gangrene (Kaufman et al., 1998). In dialysis patients, arm vein thrombosis may become symptomatic only by catheter dysfunction, like the inability to draw blood, increased dialysis pressure or arm swelling after dialysis (Hernandez et al., 1998).

In addition, classical syndromes have been described which share some but not all of their symptoms with the clinical picture described above. Superior vena cava syndrome has been described as a complication especially of catheter related arm vein thrombosis, but may also be caused by other mechanisms, e.g. venous compression by chest tumors (Lepper et al., 2011). It comprises usually bilateral edema of the face, neck, and upper extremities, together with cyanosis, plethora, and dilated subcutaneous vessels. Paget von Schroetter's syndrome, which was first described at the end of the 19th century, is defined as a primary thrombosis

of the subclavian vein at the costoclavicular junction. This syndrome is usually precipitated by musculoskeletal compression and / or repetitive microtrauma by strenuous arm exercise (thrombosis par effort) (Constans et al., 2008; Illig & Doyle, 2010). In some cases, a compression of the subclavian vein by muscular hypertrophy (anterior scalenus muscle, subclavian muscle) or by the clavicle and the first rib with extreme arm movements (hyperabduction and elevation) may be responsible (thoracic outlet syndrome). Likewise, the syndrome has been linked to certain sport activities, as e.g. weight lifters, baseball pitchers or tennis players (Sheeran et al., 1997; van Stralen et al., 2005). It is observed more frequently in young patients, men (2:1), and in the dominant extremity (Illig & Doyle, 2010). The typical clinical presentation of this syndrome is a sudden onset of the typical symptoms of deep vein thrombosis described above (Illig & Doyle, 2010). Isolated thrombosis of the internal jugular vein is a rare disease which may be due to local (central venous catheters, recent oropharyngeal infections with anaerobic bacteria like fusobacterium necrophorum) or systemic factors (cancer, thrombophilia, ovarian hyperstimulation syndrome) (Sheikh et al., 2002; Gbaguidi et al., 2011). Lemierre's syndrome, first described in 1910, is a severe condition of septic thrombosis following oropharyngeal infections, mostly due to fusobacterium necrophorum. This syndrome is also known as human necrobacillosis or post-anginal septicaemia. Besides local symptoms (cervical edema, localized pain, dilated superficial collateral veins, erythrocyanosis, indurated vein), severe systemic complications like septicaemia and septic pulmonary embolism may occur (Vargiami & Zafeiriou, 2010; Gbaguidi et al., 2011).

When evaluating patients for clinical signs of deep arm vein thrombosis, it is important to bear in mind possible alternative diagnoses. These include e.g. superficial thrombophlebitis, paravasates after peripheral infusions, lymphedema, cellulitis, haematoma, venous compression and traumatic injuries (Kommareddy et al., 2002; Bernardi et al., 2006).

6. Diagnostic procedures

As in thrombosis of the lower extremities, there are no reliable clinical symptoms to diagnose deep arm vein thrombosis. Therefore, diagnostic test are necessary to diagnose or rule out upper extremity thrombosis. Contrast venography is the gold standard diagnostic method, allowing an unparalleled overview of all arm veins with high resolution (Fig 2). However, venography is invasive, inconvenient for the patient and suffers from moderate inter-observer agreement rates (between 71 and 83%) in upper extremity deep vein thrombosis (Baarslag et al., 2003). Furthermore, possible complications as contrast agent mediated kidney damage, allergic reactions and even venography-induced thrombosis can occur (Bernardi et al., 2006).

Ultrasound has several advantages compared to invasive methods and has become the diagnostic method of choice in lower extremity deep vein thrombosis (Kearon et al., 1998; Goodacre et al., 2006). The main strengths of ultrasound are its non-invasive nature, general availability, as well as the lack of radiation and contrast material. However, ultrasound suffers generally from some disadvantages, including observer variability and usually lack of standardized documentation. In arm vein thrombosis, an additional obstacle is the portion of the subclavian vein behind the clavicle, impeding compression manoeuvres in this clinically important region. In addition, the brachiocephalic veins and the superior vena

cava cannot be examined directly. In a substantial number of cases it will therefore be necessary to rely on indirect signs, as e.g. lack of Doppler signals (Fig. 3B) or characteristic changes in the Doppler flow distal of the occluded segment (Fig. 4). Nevertheless, several studies have shown high sensitivity and specificity of different ultrasound modalities (continuous wave ultrasound, compression ultrasound, colour Doppler ultrasound) in patients with suspected arm vein thrombosis (Prandoni et al., 1997a; B. O. Mustafa et al., 2002; Di Nisio et al., 2010); see Table 2. Despite these impressive numbers, the clinician should bear in mind that all these studies of arm vein thrombosis have been performed in relatively few patients. Therefore, the reported confidence intervals are wide and the safety of withholding therapy in a patient with negative ultrasound has not been proven prospectively in an adequately powered study (B.O. Mustafa et al. 2002). Even with these limitations, ultrasound is a valuable tool for the diagnosis of deep arm vein thrombosis in the hand of an experienced operator, and should be performed in most cases as the first imaging test. For magnetic resonance imaging, a study with 44 patients comparing time of flight and Gadolinium-enhanced imaging reported a moderate sensitivity and specificity (Baarslag et al., 2004). Computed tomography scanning for the diagnosis of deep arm vein thrombosis has only been described in a small case series (Kim et al., 2003), although this modality is often used to detect thrombi in clinical practice (Fig. 3A).

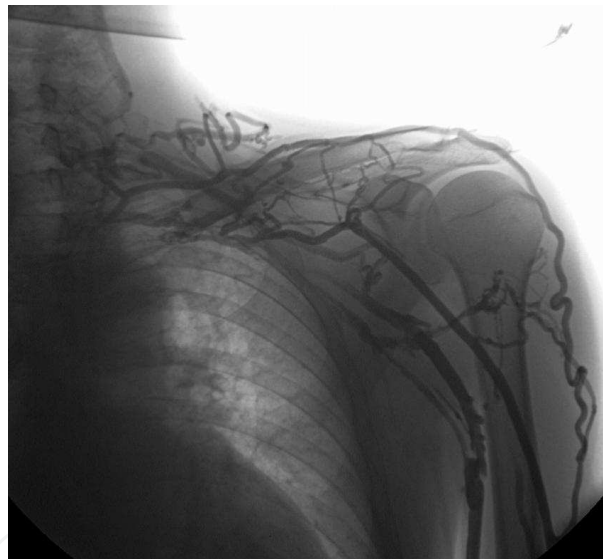


Fig. 2. Venogram of a chronic occlusion of the left subclavian vein with extensive collateralization (Department of Radiology, Innsbruck Medical University).

Since there is no imaging method combining optimal accuracy and minimal burden for the patient, alternative methods have been searched for. An interesting clinical prediction score for arm vein thrombosis, reminiscent of the Wells score for lower extremity thrombosis (Wells et al., 1997), has been published by Constans and coworkers (Constans et al., 2008). This simple score assigns one point each for a central venous catheter or pacemaker lead, localized pain and unilateral edema. One point is subtracted in the case that an alternative diagnosis would seem at least as likely as deep arm vein thrombosis. D-dimer testing has also been evaluated in a cohort of patients with suspected deep arm vein thrombosis (Merminod et al., 2006). Although nearly 100% sensitive, D-dimer suffers from a low specificity.

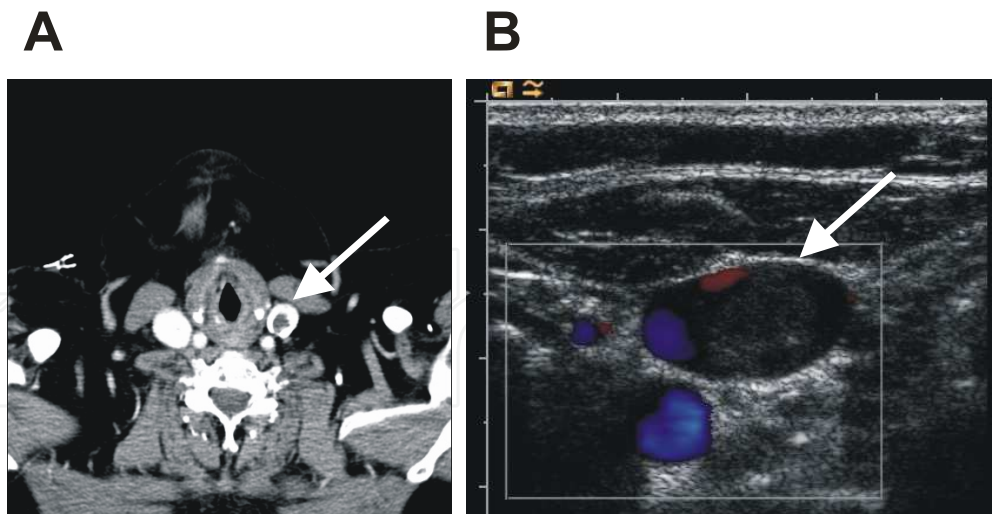


Fig. 3. Computed tomography scan (A, Department of Radiology, Innsbruck Medical University) and colour duplex ultrasound (B) of the same patient showing a floating thrombus in the left internal jugular vein.

Test	Sensitivity	Specificity	Advantage	Disadvantage	Reference
Clinical score	78%	64%	simplicity	performance	Constans et al. 2008
D-Dimer	100%	14%	sensitivity	specficity	Merminod et al. 2006
CUS	96%	94%	noninvasive	operator-dependent	Di Nisio et al. 2010
CUS + CD	100%	93%	noninvasive	operator-dependent	Di Nisio et al. 2010
MRI	71%	89%	overview	cost	Baarslag et al. 2004
Venography	100%	100%	overview	invasive	Baarslag et al. 2003

Table 2. Strengths and weaknesses of diagnostic tests for suspected deep arm vein thrombosis. CUS compression ultrasound. CD colour Doppler ultrasound. MRI magnetic resonance imaging.

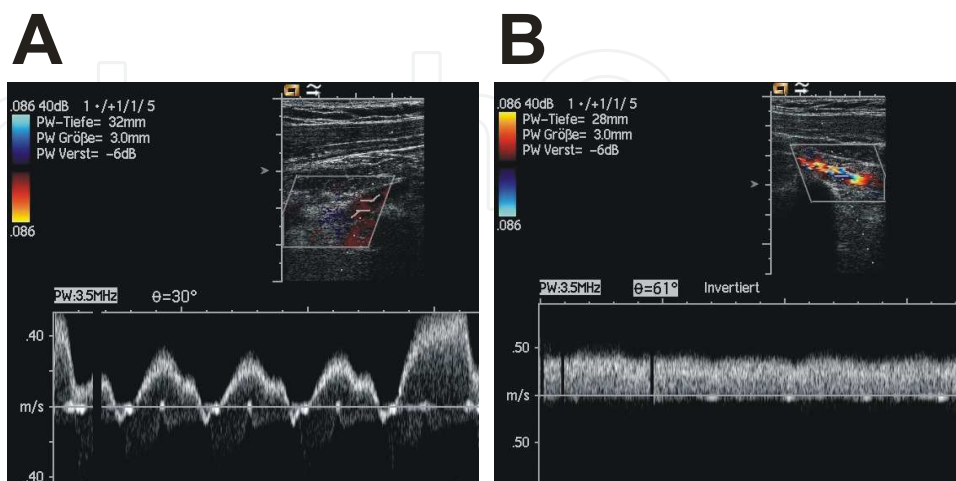


Fig. 4. Indirect sonographic diagnosis of a non-recent thrombosis of the left subclavian vein with partial recanalisation. Normal venous flow with cardiac and respiratory modulation in the right subclavian vein (A) compared to linear flow in the left subclavian vein (B).

7. Natural history and complications

Compared to lower extremity deep vein thrombosis, relatively little is known about the natural history of deep arm vein thrombosis. The follow-up of patients not receiving anticoagulant treatment was reviewed by Thomas & Zierler, who found high rates of post-thrombotic syndrome (74%) and pulmonary embolism (12%) in patients treated only with physical methods (rest, heat, elevation) (Thomas & Zierler, 2005). These findings underscore the importance of a correct and fast diagnosis of upper extremity deep vein thrombosis and challenge the common view of arm vein thrombosis as a relatively harmless disease. However, even patients that are treated according to current guidelines have a significant risk of severe complications (Table 3). Compared to lower extremity deep vein thrombosis, patients with deep arm vein thrombosis present less frequently with concomitant pulmonary embolism (9% versus 30%) (Munoz et al., 2008; Lechner et al., 2008). However, pulmonary embolism caused by deep arm vein thrombosis can even be fatal in rare cases (Monreal et al., 1994). With the exception of patients with malignancies, the recurrence rate tends to be lower than in deep vein thrombosis (Spencer et al., 2007; Munoz et al., 2008). However, the total mortality of patients with upper extremity and lower extremity thrombosis appears to be similar and is mainly related to the underlying disease (Spencer et al., 2007; Munoz et al., 2008). Contrary to common believe, post-thrombotic syndrome is not a rare complication in deep arm vein thrombosis and may lead to functional disability and significant impaired quality of life in these patients (Prandoni et al., 2004; Kahn et al., 2005; Vik et al., 2009). Two modified versions of a validated score system for post-thrombotic syndrome in lower extremity thrombosis (Prandoni et al., 1997b) have been adapted to arm vein thrombosis (Table 4).

Complication	Frequency	References
Recurrence	78 / 1060 (7.4%)	Martinelli et al. 2004, Bernardi et al. 2006, Spencer et al. 2007, Munoz et al. 2008, Isma et al. 2010
Pulmonary embolism	186 / 2094 (8.9 %)	Kommareddy et al 2002, Bernardi et al. 2006, Spencer et al. 2007, Munoz et al. 2008, Lechner et al. 2008
Fatal pulmonary embolism	10 / 1156 (0.87%)	Bernardi et al. 2006, Munoz et al. 2008
Post-thrombotic syndrome	141 / 610 (23%)	Bernardi et al. 2006

Table 3. Common complications of deep arm vein thrombosis.

8. Treatment

Due to the lack of adequately powered, randomized clinical trials the current guidelines for the treatment of arm vein thrombosis are mainly based on small cohort studies, expert opinion or extrapolation of data derived from larger studies performed in patients with lower extremity deep vein thrombosis. Nevertheless, the eight edition of the American college of chest physicians' (ACCP) guidelines cover several important aspects of the treatment of patients with upper extremity deep vein thrombosis (Kearon et al., 2008). For the initial treatment, therapeutic doses of low molecular weight heparin, unfractionated heparin or fondaparinux are recommended. Overlapping with this initial treatment, long-term anticoagulation with a vitamin K antagonist should be started and continued for a minimum of 3 months. No studies are available that have addressed the ideal duration of

anticoagulant therapy in patients with arm vein thrombosis. There is no specific recommendation in the ACCP guidelines on the treatment of cancer patients with upper extremity deep vein thrombosis. In cancer patients with deep arm vein thrombosis, the use of low molecular weight heparins instead of vitamin K antagonist as long-term treatment has been suggested in analogy to lower extremity thrombosis, but there are currently no studies supporting this approach (Shivakumar et al., 2009). Although various degrees of post-thrombotic syndrome have to be expected in the long term follow up of about 1 in 4 patients with upper extremity deep vein thrombosis, the ACCP guidelines do not advocate the routine use of elastic bandages or compression sleeves for the arm, unless patients report severe symptoms like persistent edema and pain.

A number of studies have described case series of deep arm vein thrombosis treated with a variety of invasive therapeutic options, including catheter-guided thrombolysis, percutaneous angioplasty with or without venous stent insertion, surgical thrombectomy and surgical decompression of costoclavicular narrowing to correct thoracic inlet syndrome, e.g. by first rib resection (Zimmermann et al., 1981; Becker et al., 1983; Machleder, 1993; Urschel & Razzuk, 1998). Some investigators recommend such an invasive approach routinely e.g. in patients with effort related thrombosis (Paget von Schroetter's syndrome) (Kommareddy et al., 2002). Here, the ACCP guidelines clearly do not recommend invasive procedures routinely, but only in selected patients and in specially equipped centers. It remains to be determined in adequately designed, randomized clinical trials whether these invasive procedures, which carry a substantial risk of major bleeding and other serious complications, provide a benefit compared to standard anticoagulation with optimal mechanical compression using elastic bandages.

Subjective symptoms	Objective Signs	Subjective symptoms	Objective Signs
Heaviness	Edema	Heaviness	Edema
Pain	Skin induration	Pain	Prominent veins on arm
Pruritus	Discoloration	Pruritus	Prominent veins over shoulder or anterior chest wall
Physical limitation	Venous ectasia	Cramps	Dependent cyanosis
Paraesthesia	Redness	Paraesthesia	Redness
	Pain during compression		Tenderness
Prandoni et al. 2004, Vik et al. 2009		Kahn et al. 2005	

Table 4. Two suggested modifications of the Villalta scale for the assessment of post-thrombotic syndrome in deep arm vein thrombosis. Each sign or symptom is graded as 0 (absent), 1 (mild), 2 (moderate) or 3 (severe). A score of 5 or higher is classified as post-thrombotic syndrome and score of 15 or higher as severe post-thrombotic syndrome.

Another point of debate is the question whether central venous catheters should be removed when a diagnosis of deep vein thrombosis has been confirmed in the respective vessel. Most experts opt against catheter removal, if the catheter is still needed and still functional. In a cohort study of 74 cancer patients with acute upper extremity thrombosis, the catheters were not removed and patients were treated for 3 months with standard anticoagulation without recurrent episodes of venous thromboembolism (Kovacs et al., 2007). If the catheter is removed, the ACCP guidelines recommend not to shorten the anticoagulation period below 3 months (Kearon et al., 2008).

9. Prevention

Patients with central venous catheters carry a high risk of deep arm vein thrombosis, which may exceed 60 % in certain patient groups (ICU patients, oncological and hematological patients) Van Rooden et al., 2005. Therefore, approaches to prevent catheter-related thrombosis by means of pharmacological prophylaxis e.g. in cancer patients, appear attractive. However, despite an early study showing benefit of low dose warfarin in this context (Bern et al., 1990), subsequent studies with warfarin and heparins could not confirm this protective effect. A recent meta-analysis did show a trend, but no significant reduction of symptomatic deep vein thrombosis with any form of thromboprophylaxis (Akl et al., 2008). In accordance with these data, the current guidelines for the prevention of venous thromboembolism do not recommend routine use of thromboprophylaxis in cancer patients with indwelling central venous catheters (Geerts et al., 2008).

The placement of superior vena cava filters has been reported in case reports and small case series. Although effective in preventing pulmonary embolism from thrombi in the upper extremities, these filters may cause severe complications, like cardiac tamponade and aortic perforation (Owens et al., 2010) and do not protect from thrombi in the lower extremities. Therefore, the placement of these filters should be limited to special situations (Kucher, 2011).

10. Conclusions / open questions

About 5% of all thromboses are expected to occur in the deep veins of the upper extremities. Besides effort-related thromboses, most patients with arm vein thrombosis have typical risk factors, like central venous catheters or malignancies. Typical clinical syndromes include edema and localized pain, whereas other patients are asymptomatic or present with complex syndromes. Today, diagnosis will most often be performed by ultrasound; in some cases additional testing (e.g. computed tomography scanning, magnetic resonance imaging) will be necessary. The most important complications are recurrent thrombosis, pulmonary embolism and post-thrombotic syndrome. Treatment should be initiated without delay and consist in most cases of standard anticoagulation treatment with heparins followed by a vitamin K antagonist for at least 3 months. In selected cases, invasive therapeutic regimes including catheter-guided thrombolysis and surgical procedures may be applied. Routine prevention of catheter-related thrombosis or embolic complications by anticoagulants in prophylactic doses or implantation of superior vena cava filters is not recommended. Compared to deep vein thrombosis of the lower extremities, deep vein thrombosis of the arm veins has been studied much less intensely. For example, the optimal duration of anticoagulant therapy and the value of compression therapy are not precisely known for arm vein thromboses. Therefore, many of the current recommendations are in fact extrapolations from data on deep leg vein thrombosis. Specific studies are needed to better understand the pathogenesis of deep vein thrombosis of the arms and to improve diagnostic and therapeutic strategies.

11. References

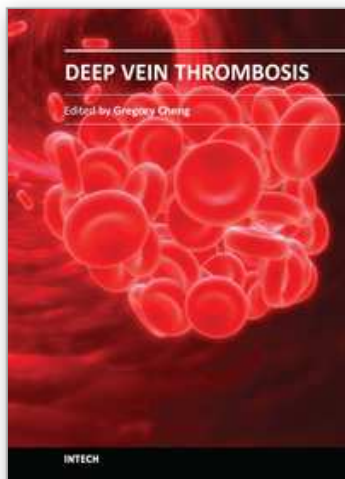
- Akl, E.A.; Kamath, G.; Yosucio, V.; Kim, S.Y.; Barba, M.; Sperati, F.; Cook, D.J. & Schunemann, H.J. (2008) Thromboprophylaxis for patients with cancer and central venous catheters. *Cancer* 112, 2483-2492.
- Baarslag, H.J.; Van Beek, E.J.R.; Tijssen, J.G.P.; van Delden, O.M.; Bakker, A.J. & Reekers, J.A. (2003) Deep vein thrombosis of the upper extremity: intra- and interobserver study of digital subtraction venography. *European Radiology* 13, 251-255.

- Baarslag, H.J.; Van Beek, E.J.R. & Reekers, J.A. (2004) Magnetic resonance venography in consecutive patients with suspected deep vein thrombosis of the upper extremity: Initial experience. *Acta Radiologica* 45, 38-43.
- Bauersachs, R.M.; Manolopoulos, K.; Hoppe, I.; Arin, M.J. & Schleussner, E. (2007) More on: the 'ART' behind the clot: solving the mystery. *Journal of Thrombosis and Haemostasis* 5, 438-439.
- Beathard, G.A. (2001) Catheter thrombosis. *Seminars in Dialysis* 14, 441-445.
- Becker, G.J.; Holden, R.W.; Rabe, F.E.; Castanedazuniga, W.R.; Sears, N.; Dilley, R.S. & Glover, J.L. (1983) Local thrombolytic therapy for subclavian and axillary vein-thrombosis - treatment of the thoracic inlet syndrome. *Radiology* 149, 419-423.
- Bern, M.M.; Lokich, J.J.; Wallach, S.R.; Bothe, A.; Benotti, P.N.; Arkin, C.F.; Greco, F.A.; Huberman, M. & Moore, C. (1990) Very low-doses of warfarin can prevent thrombosis in central venous catheters - a randomized prospective trial. *Annals of Internal Medicine* 112, 423-428.
- Bernardi, E.; Pesavento, R. & Prandoni, P. (2006) Upper extremity deep venous thrombosis. *Semin.Thromb.Hemost.* 32, 729-736.
- Blom, J.W.; Doggen, C.J.; Osanto, S. & Rosendaal, F.R. (2005) Old and new risk factors for upper extremity deep venous thrombosis. *J.Thromb.Haemost.* 3, 2471-2478.
- Brismar, B; Hardstedt, C & Jacobson, S. (1981). Diagnosis of thrombosis by catheter phlebography after prolonged central venous catheterization. *Annals of Surgery* 194,779-783.
- Chen, S.C.; Chang, J.M.; Wang, C.S.; Wu, H.C. & Chen, H.C. (2009) Upper limb deep vein thrombosis following calcium gluconate injection. *Nephrology* 14, 621.
- Constans, J.; Salmi, L.R.; Sevestre-Pietri, M.A.; Perusat, S.; Nguon, M.; Degeilh, M.; Labarere, J.; Gattolliat, O.; Boulon, C.; Laroche, J.P.; Le Roux, P.; Pichot, O.; Quere, I.; Conri, C. & Bosson, J.L. (2008) A clinical prediction score for upper extremity deep venous thrombosis. *Thromb.Haemost.* 99, 202-207.
- Czihal, M. & Hoffmann, U. (2011) Upper extremity deep venous thrombosis. *Vascular Medicine* 16, 191-202.
- Di Nisio, M.; van Sluis, G.L.; Bossuyt, P.M.M.; Buller, H.R.; Porreca, E. & Rutjes, A.W.S. (2010) Accuracy of diagnostic tests for clinically suspected upper extremity deep vein thrombosis: a systematic review. *Journal of Thrombosis and Haemostasis* 8, 684-692.
- Gbaguidi, X.; Janvresse, A.; Benichou, J.; Cailleux, N.; Levesque, H. & Marie, I. (2011) Internal jugular vein thrombosis: outcome and risk factors. *Qjm-An International Journal of Medicine* 104, 209-219.
- Geerts, W.H.; Bergqvist, D.; Pineo, G.F.; Heit, J.A.; Samama, C.M.; Lassen, M.R. & Colwell, C.W. (2008) Prevention of venous thromboembolism. *Chest* 133, 381S-453S.
- Goltz, J.P.; Scholl, A.; Ritter, C.O.; Wittenberg, G.; Hahn, D. & Kickuth, R. (2010) Peripherally placed totally implantable venous-access port systems of the forearm: clinical experience in 763 consecutive patients. *Cardiovascular and Interventional Radiology* 33, 1159-1167.
- Goodacre, S.; Sampson, F.; Stevenson, M.; Wailoo, A.; Sutton, A.; Thomas, S.; Locker, T. & Ryan, A. (2006) Measurement of the clinical and cost-effectiveness of non-invasive diagnostic testing strategies for deep vein thrombosis. *Health Technology Assessment* 10, 1-168.
- Hernandez, D.; Diaz, F.; Rufino, M.; Lorenzo, V.; Perez, T.; Rodriguez, A.; De Bonis, E.; Losada, M.; Gonzalez-Posada, J.M. & Torres, A. (1998) Subclavian vascular access stenosis in dialysis patients: Natural history and risk factors. *Journal of the American Society of Nephrology* 9, 1507-1510.

- Hill, S.L. & Berry, R.E. (1990) Subclavian vein thrombosis: a continuing challenge. *Surgery* 108, 1-9.
- Illig, K.A. & Doyle, A.J. (2010) A comprehensive review of Paget-Schroetter syndrome. *Journal of Vascular Surgery* 51, 1538-1547.
- Isma, N.; Svensson, P.J.; Gottsater, A. & Lindblad, B. (2010) Upper extremity deep venous thrombosis in the population-based Malmo thrombophilia study (MATS). Epidemiology, risk factors, recurrence risk, and mortality. *Thrombosis Research* 125, E335-E338.
- Joffe, H.V.; Kucher, N.; Tapson, V.F. & Goldhaber, S.Z. (2004) Upper-extremity deep vein thrombosis: a prospective registry of 592 patients. *Circulation* 110, 1605-1611.
- Kahn, S.R.; Elman, E.; Bornais, C.; Blostein, M. & Wells, P.S. (2005) Post-thrombotic syndrome, functional disability and quality of life after upper extremity deep venous thrombosis in adults. *Thrombosis and Haemostasis* 93, 499-502.
- Kaufman, B.R.; Zoldos, J.; Bentz, M. & Nystrom, N.A. (1998) Venous gangrene of the upper extremity. *Annals of Plastic Surgery* 40, 370-377.
- Kearon, C.; Ginsberg, J.S. & Hirsh, J. (1998) The role of venous ultrasonography in the diagnosis of suspected deep venous thrombosis and pulmonary embolism. *Annals of Internal Medicine* 129, 1044-1049.
- Kearon, C.; Kahn, S.R.; Agnelli, G.; Goldhaber, S.; Raskob, G.E. & Comerota, A.J. (2008) Antithrombotic therapy for venous thromboembolic disease: American College of Chest Physicians Evidence-Based Clinical Practice Guidelines (8th Edition). *Chest* 133, 454S-545S.
- Kim, H.C.; Chung, J.W.; Park, J.H.; Yin, Y.H.; Park, S.H.; Yoon, C.J. & Choi, Y.H. (2003) Role of CT venography in the diagnosis and treatment of benign thoracic central venous obstruction. *Korean Journal of Radiology* 4, 146-152.
- Koksoy, C.; Kuzu, A.; Erden, I. & Akkaya, A. (1995) The risk-factors in central venous catheter-related thrombosis. *Australian and New Zealand Journal of Surgery* 65, 796-798.
- Kommareddy, A.; Zaroukian, M.H. & Hassouna, H.I. (2002) Upper extremity deep venous thrombosis. *Semin.Thromb.Hemost.* 28, 89-99.
- Kovacs, M.J.; Kahn, S.R.; Rodger, M.; Anderson, D.R.; Andreou, R.; Mangel, J.E.; Morrow, B.; Clement, A.M. & Wells, P.S. (2007). A pilot study of central venous catheter survival in cancer patients using low-molecular-weight heparin (dalteparin) and warfarin without catheter removal for the treatment of upper extremity deep vein thrombosis (the catheter study). *Journal of Thrombosis and Haemostasis* 5:1650-1653
- Kucher, N. (2011) Deep-vein thrombosis of the upper extremities. *New England Journal of Medicine* 364, 861-869.
- Lechner, D.; Wiener, C.; Weltermann, A.; Eischer, L.; Eichinger, S. & Kyrle, P.A. (2008) Comparison between idiopathic deep vein thrombosis of the upper and lower extremity regarding risk factors and recurrence. *Journal of Thrombosis and Haemostasis* 6, 1269-1274.
- Lepper, P.M.; Ott, S.R.; Hoppe, H.; Schumann, C.; Stammberger, U.; Bugalho, A.; Frese, S.; Schmucking, M.; Blumstein, N.M.; Diehm, N.; Bals, R. & Hamacher, J. (2011) Superior vena cava syndrome in thoracic malignancies. *Respiratory Care* 56, 653-666.
- Luciani, A.; Clement, O.; Halimi, P.; Goudot, D.; Portier, F.; Bassot, N.; Luciani, J.A.; Avan, P.; Frija, G. & Bonfils, P. (2001) Catheter-related upper extremity deep venous thrombosis in cancer patients: A prospective study based on Doppler US. *Radiology* 220, 655-660.

- Machleder, H.I. (1993) Evaluation of a new treatment strategy for Paget-Schroetter syndrome - spontaneous thrombosis of the axillary-subclavian vein. *Journal of Vascular Surgery* 17, 305-317.
- Mai, C. & Hunt, D. (2011) Upper extremity deep venous thrombosis: a review. *American Journal of Medicine* 124, 402-407.
- Marschang, P.; Niederwanger, A.; Gasser, R.W.; Daniaux, M. & Sturm, W. (2008) Symptomatic upper extremity deep vein thrombosis as a complication of ambulatory blood pressure monitoring. *Thromb.Haemost.* 100, 711-712.
- Martin, C.; Viviani, X.; Saux, P. & Gouin, F. (1999) Upper-extremity deep vein thrombosis after central venous catheterization via the axillary vein. *Critical Care Medicine* 27, 2626-2629.
- Martinelli, I.; Battaglioli, T.; Bucciarelli, P.; Passamonti, S.M. & Mannucci, P.M. (2004) Risk factors and recurrence rate of primary deep vein thrombosis of the upper extremities. *Circulation* 110, 566-570.
- Martinelli, I.; Bucciarelli, P. & Mannucci, P.M. (2010) Thrombotic risk factors: Basic pathophysiology. *Critical Care Medicine* 38, S3-S9.
- Merminod, T.; Pellicciotta, S. & Bounameaux, H. (2006) Limited usefulness of D-dimer in suspected deep vein thrombosis of the upper extremities. *Blood Coagulation & Fibrinolysis* 17, 225-226.
- Monreal, M.; Raventos, A.; Lerma, R.; Ruiz, J.; Lafoz, E.; Alastrue, A. & Llamazares, J.F. (1994) Pulmonary embolism in patients with upper extremity DVT associated to venous central lines - a prospective-study. *Thrombosis and Haemostasis* 72, 548-550.
- Munoz, F.J.; Mismetti, P.; Poggio, R.; Valle, R.; Barron, M.; Guil, M. & Monreal, M. (2008) Clinical outcome of patients with upper-extremity deep vein thrombosis - Results from the RIETE registry. *Chest* 133, 143-148.
- Mustafa, B.O.; Rathbun, S.W.; Whitsett, T.L. & Raskob, G.E. (2002) Sensitivity and specificity of ultrasonography in the diagnosis of upper extremity deep vein thrombosis - A systematic review. *Archives of Internal Medicine* 162, 401-404.
- Mustafa, S.; Stein, P.D.; Patel, K.C.; Otten, T.R.; Holmes, R. & Silbergleit, A. (2003) Upper extremity deep venous thrombosis. *Chest* 123, 1953-1956.
- Owens, C.A.; Bui, J.T.; Knuttinen, M.G.; Gaba, R.C. & Carrillo, T.C. (2010) Pulmonary embolism from upper extremity deep vein thrombosis and the role of superior vena cava filters: A review of the literature. *Journal of Vascular and Interventional Radiology* 21, 779-787.
- Palamari, B.; Breen, J.F. & Wysokinski, W.E. (2010) Lipoma causing upper extremity deep vein thrombosis: A case report. *Journal of Thrombosis and Thrombolysis* 30, 109-111.
- Phipps, C. & Joo, H. (2008) Upper limb deep vein thrombosis and portable computer games. *American Journal of Medicine* 121, E3.
- Prandoni, P.; Polistena, P.; Bernardi, E.; Cogo, A.; Casara, D.; Verlato, F.; Angelini, F.; Simioni, P.; Signorini, G.P.; Benedetti, L. & Girolami, A. (1997a.) Upper-extremity deep vein thrombosis - Risk factors, diagnosis, and complication. *Archives of Internal Medicine* 157, 57-62.
- Prandoni, P.; Villalta, S.; Bagatella, P.; Rossi, L.; Marchiori, A.; Piccioli, A.; Bernardi, E.; Girolami, B.; Simioni, P. & Girolami, A. (1997b.) The clinical course of deep-vein thrombosis. Prospective long-term follow-up of 528 symptomatic patients. *Haematologica* 82, 423-428.
- Prandoni, P.; Bernardi, E.; Marchiori, A.; Lensing, A.W.; Prins, M.H.; Villalta, S.; Bagatella, P.; Sartor, D.; Piccioli, A.; Simioni, P.; Pagnan, A. & Girolami, A. (2004) The long term

- clinical course of acute deep vein thrombosis of the arm: prospective cohort study. *BMJ* 329, 484-485.
- Schoen N.; Netzsich, C. & Kröger K. (2007) Subclavian vein thrombosis and backpacking. *Clinical Research in Cardiology* 96, 42-44.
- Sheeran, S.R.; Hallisey, M.J.; Murphy, T.P.; Faberman, R.S. & Sherman, S. (1997) Local thrombolytic therapy as part of a multidisciplinary approach to acute axillosubclavian vein thrombosis (Paget-Schroetter syndrome). *Journal of Vascular and Interventional Radiology* 8, 253-260.
- Sheikh, M.A.; Topoulos, A.P. & Deitcher, S.R. (2002) Isolated internal jugular vein thrombosis: risk factors and natural history. *Vascular Medicine* 7, 177-179.
- Shivakumar, S.P.; Anderson, D.R. & Couban, S. (2009) Catheter-associated thrombosis in patients with malignancy. *Journal of Clinical Oncology* 27, 4858-4864.
- Sood, S.L. (2009) Cancer-associated thrombosis. *Current Opinion in Hematology* 16, 378-385.
- Spencer, F.A.; Emery, C.; Lessard, D. & Goldberg, R.J. (2007) Upper extremity deep vein thrombosis: A community-based perspective. *American Journal of Medicine* 120, 678-684.
- Thomas, I.H. & Zierler B.K. (2005) An integrative review of outcomes in patients with acute primary upper extremity deep venous thrombosis following no treatment or treatment with anticoagulation, thrombolysis, or surgical algorithms. *Vascular and Endovascular Surgery* 39, 163-174.
- Timsit, J.F.; Farkas, J.C.; Boyer, J.M.; Martin, J.B.; Misset, B.; Renaud, B. & Carlet, J. (1998) Central vein catheter-related thrombosis in intensive care patients - Incidence, risks factors, and relationship with catheter-related sepsis. *Chest* 114, 207-213.
- Urschel, H.C. & Razzuk, M.A. (1998) Neurovascular compression in the thoracic outlet - Changing management over 50 years. *Annals of Surgery* 228, 609-615.
- Van Rooden, C.J.; Molhoek, S.G.; Rosendaal, F.R.; Schaliij, M.J.; Meinders, A.E. & Huisman, M.V. (2004) Incidence and risk factors of early venous thrombosis associated with permanent pacemaker leads. *Journal of Cardiovascular Electrophysiology* 15, 1258-1262.
- Van Rooden, C.J.; Tesselaar, M.E.T.; Osanto, S.; Rosendaal, F.R. & Huisman, M.V. (2005) Deep vein thrombosis associated with central venous catheters - a review. *Journal of Thrombosis and Haemostasis* 3, 2409-2419.
- Van Stralen, K.J.; Blom, J.W.; Doggen, C.J.M. & Rosendaal, F.R. (2005) Strenuous sport activities involving the upper extremities increase the risk of venous thrombosis of the arm. *Journal of Thrombosis and Haemostasis* 3, 2110-2111.
- Vargiami, E.G. & Zafeiriou, D.I. (2010) Eponym The Lemierre syndrome. *European Journal of Pediatrics* 169, 411-414.
- Verso, M.; Agnelli, G.; Kamphuisen, P.W.; Ageno, W.; Bazzan, M.; Lazzaro, A.; Paoletti, F.; Paciaroni, M.; Mosca, S. & Bertoglio, S. (2008) Risk factors for upper limb deep vein thrombosis associated with the use of central vein catheter in cancer patients. *Internal and Emergency Medicine* 3, 117-122.
- Vik, A.; Holme, P.A.; Singh, K.; Dorenberg, E.; Nordhus, K.C.; Kumar, S. & Hansen, J.B. (2009) Catheter-directed thrombolysis for treatment of deep venous thrombosis in the upper extremities. *Cardiovascular and Interventional Radiology* 32, 980-987.
- Wells, P.S.; Anderson, D.R.; Bormanis, J.; Guy, F.; Mitchell, M.; Gray, L.; Clement, C.; Robinson, K.S. & Lewandowski, B. (1997) Value of assessment of pretest probability of deep-vein thrombosis in clinical management. *Lancet* 350, 1795-1798.
- Zimmermann, R.; Morl, H.; Harenberg, J.; Gerhardt, P.; Kuhn, H.M. & Wahl, P. (1981) urokinase therapy of subclavian-axillary vein-thrombosis. *Klinische Wochenschrift* 59, 851-856. Supported by grant P 20825-B05 of the Austrian Science Funds (FWF).



Deep Vein Thrombosis

Edited by Dr. Gregory Cheng

ISBN 978-953-51-0225-0

Hard cover, 184 pages

Publisher InTech

Published online 07, March, 2012

Published in print edition March, 2012

This book provides a comprehensive review of deep vein thrombosis. There are chapters on risk factors for DVT, post thrombotic syndrome and its management, vena cava malformation as a new etiological factor and thrombosis in the upper limbs. DVT is usually seen in patients undergoing major surgeries. The guidelines for thrombo-prophylaxis in orthopaedic patients, radical pelvic surgeries, laparoscopic operations and risks versus benefits in regions with a low prevalence of DVT are thoroughly addressed. Cancer and its treatment are recognized risk factors for VTE and extended prophylaxis in ambulatory cancer patients is reviewed. The role of imaging and endovascular therapies in acute DVT, hypercoagulability in liver diseases and the challenges in developing countries are discussed.

How to reference

In order to correctly reference this scholarly work, feel free to copy and paste the following:

Peter Marschang (2012). Deep Vein Thrombosis of the Arms, Deep Vein Thrombosis, Dr. Gregory Cheng (Ed.), ISBN: 978-953-51-0225-0, InTech, Available from: <http://www.intechopen.com/books/deep-vein-thrombosis/deep-vein-thrombosis-of-the-arms->

INTECH
open science | open minds

InTech Europe

University Campus STeP Ri
Slavka Krautzeka 83/A
51000 Rijeka, Croatia
Phone: +385 (51) 770 447
Fax: +385 (51) 686 166
www.intechopen.com

InTech China

Unit 405, Office Block, Hotel Equatorial Shanghai
No.65, Yan An Road (West), Shanghai, 200040, China
中国上海市延安西路65号上海国际贵都大饭店办公楼405单元
Phone: +86-21-62489820
Fax: +86-21-62489821

© 2012 The Author(s). Licensee IntechOpen. This is an open access article distributed under the terms of the [Creative Commons Attribution 3.0 License](#), which permits unrestricted use, distribution, and reproduction in any medium, provided the original work is properly cited.

IntechOpen

IntechOpen