

We are IntechOpen, the world's leading publisher of Open Access books Built by scientists, for scientists

4,800

Open access books available

122,000

International authors and editors

135M

Downloads

Our authors are among the

154

Countries delivered to

TOP 1%

most cited scientists

12.2%

Contributors from top 500 universities



WEB OF SCIENCE™

Selection of our books indexed in the Book Citation Index
in Web of Science™ Core Collection (BKCI)

Interested in publishing with us?
Contact book.department@intechopen.com

Numbers displayed above are based on latest data collected.

For more information visit www.intechopen.com



Nifedipine Gel with Lidocaine in the Treatment of Anal Fissure in Children: A Pilot Study and Review of the Literature

Baruch Klin¹, Ibrahim Abu-Kishk²,
Yigal Efrati¹ and Gad Lotan¹

¹Department of Pediatric Surgery &
²Pediatric Intensive Care Unit, Assaf Harofeh Medical Center,
Zerifin, Affiliated to the Sackler School of Medicine,
Tel-Aviv University, Tel-Aviv,
Israel

1. Introduction

Anal fissures are common in infancy and represent the most common cause of bright rectal bleeding at any age. Delayed diagnosis and treatment can lead to a disturbing cycle of constipation, repeat rectal bleeding, and crying, due to increasing pain during and after defecation. In spite of its high frequency, the problem remains underrated by most clinicians, with only a paucity of data on the management of anal fissures in children being found in the literature. The objective of this work is to bring this common and distressing problem into a more positive light, based on our good results achieved by the nifedipine gel with lidocaine treatment.

2. History

The first description of anal sphincterotomy in the world literature is found in Alexis Boyer's 11-volume *Traite des Maladies Chirurgicales* published between 1818 and 1826 (DeMoulin, 1977). His descriptions of the condition are dramatic, detailing the severe suffering patients endured. Louis Lemmonier, in 1869, gave the world the first anatomic description of an anal fissure. Boyer established the relationship between anal sphincter spasm and no healing of anal fissures, as well as the association between constipation and anal fissure. He was the first to divide the sphincter to cure the problem. This procedure, routine and quite safe today, caused deaths and pelvic abscesses in four patients, as reported by Velpeau in 1832. During the 1950s, fissure excision, anal sphincter stretching, injection therapy (local anesthetic and sclerotherapy) and sphincterotomy were performed for chronic anal fissures. Later, in the late 1960s and early 1970s, cutaneous island advancement flaps were added to this group (Ruiz-Moreno, 1968; Samson & Stewart, 1970). The modern reintroduction of sphincterotomy for anal fissure can be attributed to Eisenhammer (1951). In 1953, Inburg published his technique of partial internal sphincterotomy, cutting the sphincter through the bed of the fissure. It was not until the mid to late 1970s that lateral internal sphincterotomy became accepted as the standard of care to treat anal fissures surgically (J. Nelson, 2006).

3. Definition

An anal fissure is a linear, longitudinal split in the lining of the distal anal canal, extending from below the dentate line to the anal verge. They are usually very painful because of their somatic innervations, the pain resulting from spasm of the anal sphincter in response to stretching and tearing during passage of stool. A well developed anal fissure rests directly over the internal sphincter and the circular fibers of this sphincter are visible on the floor of the fissure on naked eye inspection.

4. Anatomy

ANAL FISSURE - ANATOMY

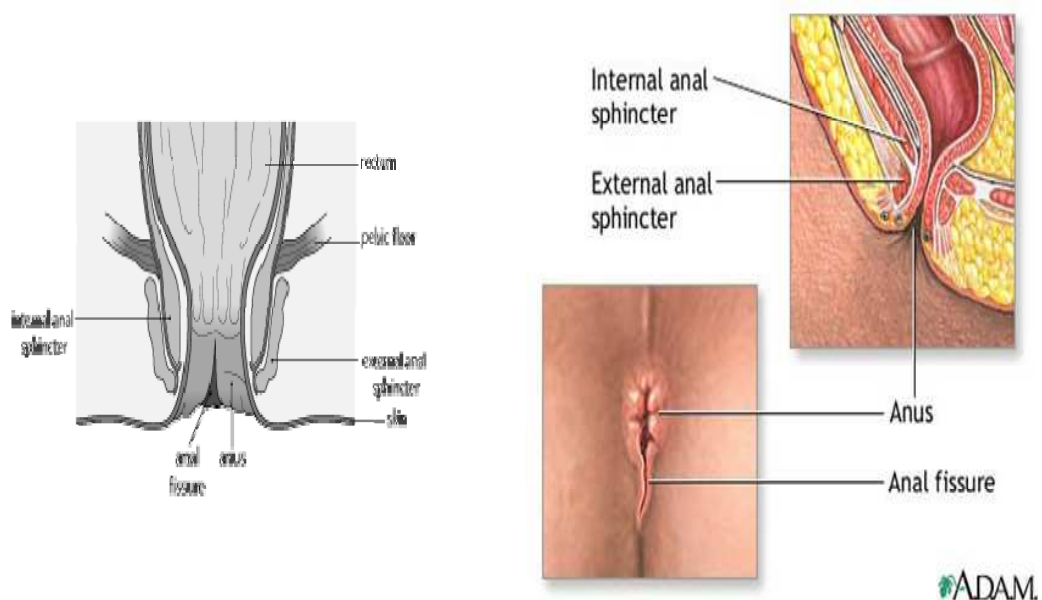


Fig. 1. Anal fissure anatomy.

5. Incidence and etiology

Anal fissures presents mostly in children aged 6-24 months. The overall incidence in children is not well described. Anal fissures are located in the posterior midline in 90% of the cases, although 10-20% in women and 1-10% in men are located in the anterior midline (Notaras, 1988). The posterior commissure of the anoderm is less well perfused than other anodermal regions (Schouten et al., 1994). Pressure over the branches of the inferior rectal artery (increased tone at the internal sphincter and high canal pressures) causes relative ischemia (Klosterhalfen et al., 1989). First described as a disease entity in 1934, the cause of

anal fissures is still unknown. Constipation and passage of hard stool were traditionally blamed and believed to be the causative factor of anal fissure, but a history of constipation is elicited in only approximately 20% of the patients (McCallion & Gardiner, 2001). Trauma, usually because of passage of a large or hard stool, is believed to be a common initiating factor. Ball suggested that passage of hard stool tore down the anal valve, leaving the coiled-up skin at the anal verge as the "sentinel pile" (Lund & Scholefield, 1996). The remaining fissures are associated with chronic diarrhea, food allergy, Crohn's disease, syphilis, human immunodeficiency virus (HIV), or tuberculosis.

6. Pathophysiology

The pathophysiology is fairly complex and multifactorial, with anodermal ischemia, infection, chronic constipation, hypertonicity of the smooth muscle of the internal anal sphincter (IAS) and elevated maximal anal resting pressure (MARP) being involved (Gillet & Padias, 2006; Schouten et al., 1996). The exact mechanism surrounding the pathophysiology of anal fissures has not been clearly established, but current theories involve the tonicity of the anal sphincter and anal blood flow. A relative lack of nitrate oxide synthase, as found in other spasmodic states of the gastrointestinal tract, has been suggested as a possible mechanism for IAS hypertonia (Lund, 2006). As fissures are most commonly seen in the posterior midline, inadequate blood flow to this region has been hypothesized to play a role in the development of fissures. End arterioles from the inferior rectal artery pierce both sphincters to reach the submucosa of the anal canal and travel cephalad in this plane. Klosterhalfen et al. (1989) suggested that hypertonic sphincter decreases blood flow in these terminal vessels as they pass through the IAS fibers. Recognized features common to most chronic anal fissures are a high resting anal canal pressure due to hypertonicity of the internal anal sphincter, reduced vascular perfusion index at the site of the fissure, and the presence of "ultraslow" pressure wave activity in the internal anal sphincter (Hancock, 1977, Schouten & Blankensteijn, 1992).

7. Classification

Anal fissures may be classified as acute or chronic and typical or atypical. Acute fissures cause bright red bleeding with bowel movements and anal pain or spasm that can last for hours after the bowel movement. They have the appearance of a simple tear, superficial or deep in the anoderm. Chronic anal fissures present with induration at the edges, a sentinel pile, visible fibers of the internal anal sphincter, chronic granulation tissue in the base of the fissure and a hypertrophied anal papilla. They are acute fissures that fail to heal following 6 to 8 weeks of intensive treatment. Typical fissures are usually in the posterior or anterior midline, and are not associated with other diseases. Atypical fissures can occur anywhere in the anal canal, and tend to be associated with other diseases.

8. Differential diagnosis

Pruritus ani, inflammatory bowel disease (mostly Crohn's disease), tuberculosis, immune system diseases, acquired immunodeficiency syndrome (AIDS), Chlamydia, venereal diseases, neoplasm, and sexual abuse.

9. Innervation and pharmacology of the internal sphincter

The enteric nervous system consists of two major plexuses of interconnecting ganglia, the myenteric (Auerbach's) plexus and the submucous (Meissner's) plexus. The enteric nervous system contains entire reflex pathways that permit peristaltic contractions independent of extrinsic innervations. The internal anal sphincter receives its sympathetic innervations from the hypogastric pelvic plexuses. Parasympathetic innervation is from the first, second, and third sacral segments via the pelvic plexus. Internal anal smooth muscle relaxation can be inhibited by stimulation of nonadrenergic noncholinergic enteric neurons, parasympathetic muscarinic receptors, or sympathetic beta adrenoceptors, and by inhibition of calcium entry into the cell. Sphincter contraction depends on an increase in cytoplasmic calcium and is enhanced by sympathetic alpha adrenergic stimulation (Bhardwaj et al., 2000). A number of putative nonadrenergic transmitters have been suggested, the work being concentrated on the function of adenosine triphosphate (ATP), vasoactive intestinal peptide (VIP), and nitric oxide (NO) and their role in mediating the rectoanal inhibitory reflex (RAIR), as they are known to act together in mediating enteric inhibitory cotransmission in other areas of the gut. NO activates soluble guanylate monophosphate (cGMP) and relaxation of smooth muscle. NO has been widely demonstrated to be the main chemical neurotransmitting agent in the nonadrenergic neurons mediating relaxation of the internal anal sphincter. Working on the opossum internal anal sphincter, Rattan and Chakder suggested that NO was a nonadrenergic noncholinergic inhibitory neurotransmitter (Rattan & Chakder, 1992). NO caused tetrodotoxin-resistant relaxations of internal anal sphincter strips. The internal anal sphincter generates a high degree of tone in the resting state and is responsible for 50-85% of overall resting anal tone. This is due to both intrinsic myogenic activity and extrinsic adrenergic innervations. The effects of adrenergic agonists are well documented. Parks et al demonstrated that internal anal sphincter strips contracted to noradrenaline, had a variable response to adrenaline and relaxed in response to isoprenaline (Parks et al., 1969). Analysis of these responses using appropriate adrenoceptor antagonists has shown that contractions were mediated via alpha-receptors and relaxations via beta-receptors. Contractions to noradrenaline and adrenaline can be converted to relaxations by the addition of an alpha-receptor antagonist. Burleigh et al. (1979) have shown that acetylcholine has a predominantly inhibitory effect on internal anal sphincter smooth muscle acting through muscarinic receptors. Furthermore, electrical field stimulation of internal anal sphincter strips resulted in relaxation of the smooth muscle. These relaxations are abolished by tetrodotoxin, indicating that they are nerve mediated. Transient internal anal sphincter relaxation in response to rectal distension was first described by Gowers in 1877. O'Kelly et al. (1994) suggested that NO might be important in mediating the rectoanal inhibitory reflex. A review on the pharmacology of the internal anal sphincter was reported by Cook et al. (2001).

10. Clinical picture

The clinical picture involves a history of constipation in 20% of the cases, intense crying with bowel movements, streaks of bright red blood on the surface of hard stool, on the diaper, or on the toilet paper, following bowel movements, discharge and pruritus. The clinical hallmark of anal fissure is pain during, and especially some time after defecation. Inspection of the anal region reveals a posterior midline laceration, a sentinel skin tag, and signs of inflammation.

11. Medical treatment

Acute fissures often resolve within 10-14 days of conservative management. However, as long as 6-8 weeks may be necessary for the fissure to heal. Recurrence after conservative management can be observed in 27% of the cases. Dietary modification (increased fluid and fiber intake), stool softeners (lactulose) and warm baths are all part of the conservative treatment (Shafik, 1993). Conservative treatment is safe, has few side effects, and should usually be the first step in therapy. Shub et al. (1978) reported that 44% of fissure patients healed with sitz baths, a psyllium fiber supplement, and emollient suppositories. In 27% of these "healed" patients, the fissures recurred over a 5-year follow-up period.

The optimal treatment for an anal fissure is to induce a temporary reduction of anal canal resting pressure to allow healing of the fissure without permanently disrupting normal sphincter function. Internal anal smooth muscle relaxation can be inhibited by stimulation of non-adrenergic non-cholinergic enteric neurons, parasympathetic muscarinic receptors, or sympathetic beta adrenoceptors, and by inhibition of calcium entry into the cell.

11.1 Glyceryl trinitrate

Glyceryl trinitrate (GTN) is a vasodilator and causes relaxation of smooth muscle. Relaxation of the internal sphincter tone is achieved by the reduction of intracellular calcium in the smooth muscle cells by nitric oxide donation. Topical GTN heals anal fissures better than a placebo, irrespective of dose, but is associated with headache in around 25% of the patients. During the late 90's, GTN ointment was the best one could offer for a child with anal fissure. Exogenous nitrates release nitric oxide in vivo and have been used clinically as nitric oxide donors. Loder et al. (1994) demonstrated that topical application of 0.2% GTN led to decreased resting anal pressure. Chemical sphincterotomy using GTN with adjunctive stool softeners has been demonstrated to be quite effective at relieving symptoms and promoting healing. They significantly decrease pain during the therapy period. A study of 80 patients reported in the *Lancet* in 1997 showed healing in 26/38 (68%) after GTN, compared with 3/30 (8%) after placebo (Lund & Scholefield, 1997). Another study comparing GTN, lidocaine and placebo, was reported in the *Journal of Pediatric Surgery* in 1999. Complete healing was observed in 26/31 (83.9%) after GTN, 7/14 (50%) after lidocaine, and 6/11 (35.3%) after placebo (Tander et al., 1999). Kenny et al. (2001) questioned the healing power of GTN, reporting 31 children with an overall fissure healing rate of 84%, but with no differences being observed between GTN and placebo. Bacher et al. (1997) conducted a randomized trial of 0.2% GTN vs. 2% lidocaine gel, each applied 3 times daily, in a mixed group of acute and chronic fissure patients. After 1 month, healing rates were higher with GTN in both the acute (91.6%, GTN vs. 50%, lidocaine) and chronic (62.5%, GTN vs. 20%, lidocaine) fissure groups. A randomized, placebo-controlled treatment of anal fissure by lidocaine, EMLA, and GTN in 102 children, showed faster response rates by GTN application, and similar and high success rates by 8 weeks of EMLA treatment (Sönmez et al., 2002). The average age of patients was 3 years (range, 2.5 months to 15 years). Symptoms at admission consisted of hard stools in 90% of patients, pain or crying during defecation in 87%, bleeding in 84%, excessive straining at defecation in 35%, and mucosal prolapse in 9%. Despite the encouraging results reported with topical nitrates, severe headaches and noted relapse rates are major drawbacks. Dorfman et al. (1999) reported a 27% symptomatic relapse rate (median follow-up, 6 months). Associated side-effects were observed in 78% of

patients, including headaches in 63% and light-headedness in 52%. Carapeti et al. (1999) noted relapse rates of 33% with 0.2% GNT and 25% with escalating-dose GTN (mean follow-up, 9 months). Headaches were observed in 72% of the patients. More recent studies have shown lower healing rates with GTN than were initially reported. Patient non-compliance and tachyphylaxis are also major drawbacks to this treatment. Local application of another precursor of nitric oxide, L-arginine, has been reported as effective in promoting fissure healing without headache as a side effect (Gosselink et al., 2005).

11.2 Calcium channel blockers

They improve fissure healing by inhibiting calcium ion entry through voltage-sensitive areas of vascular smooth muscle, causing muscle relaxation and vascular dilatation. Topical diltiazem (Cardizem) has similar efficacy to GNT, with fewer side effects, but the experience with children is small.

11.3 Nifedipine

NIFEDIPINE CHEMICAL STRUCTURE

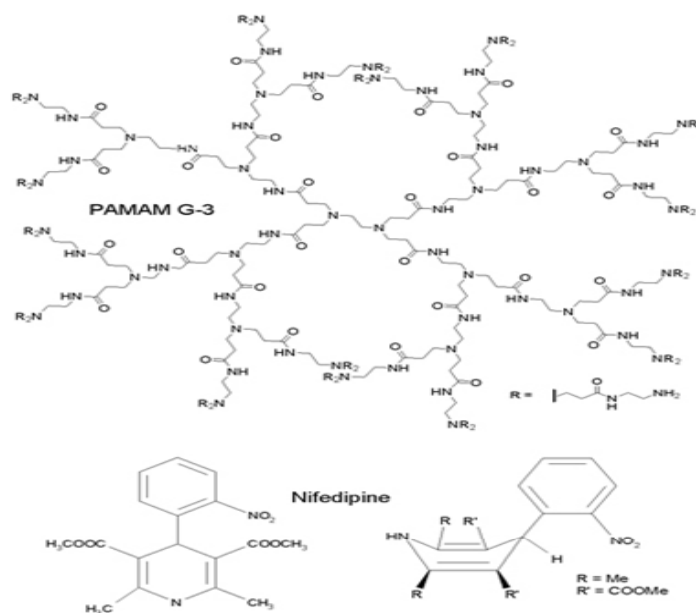


Fig. 2. Nifedipine chemical structure.

Nifedipine (Adalat) has a modulating effect on the microcirculation (Oshiro et al., 1995). The advent of this calcium channel blocker as nifedipine gel was a turning point and a major contribution to the healing of posterior anal fissures. Used to treat hypertension, angina pectoris, Raynaud's syndrome, congestive heart failure, and cardiomyopathies, it may cause side effects like headache, upset stomach, dizziness, tiredness, flushing, heartburn, tachycardia, muscle cramps, enlargement of gum tissue around teeth, constipation, nasal congestion, and cough. The first clinical study on the effects of calcium antagonists on resting

anal pressure showed that pressures were reduced with sublingual nifedipine in both healthy volunteers and patients with hypertonic sphincters (Chrysos et al., 1996). A medline database literature search concerning the non-surgical treatment of chronic anal fissures, including 282 patients, called the attention to nifedipine gel. The study compared nifedipine with lidocaine with hydrocortisone acetate, showing 98% complete healing after nifedipine and 61% complete healing in the control group. Nifedipine reduced MRAP by 30% and maximum squeeze pressure by 16.8% (McCallion & Gardiner, 2001). Another large study by Perroti et al. (2002) comparing nifedipine and lidocaine with hydrocortisone and lidocaine, showed complete healing in 94.5% of the nifedipine treated patients and only 16.4% of the control patients.

Preliminary results of a multicenter study on nifedipine for local use in conservative treatment of anal fissures was reported by Antropoli in 1999. Total remission from acute anal fissure was achieved after 21 days of therapy in 95% of the nifedipine-treated patients, with a mean reduction of 30% in maximum resting anal pressures. A randomized controlled double-blind trial comparing nifedipine gel plus lidocaine, topical lidocaine alone and hydrocortisone acetate ointment, showed topical nifedipine plus lidocaine gel to be effective and well tolerated in the treatment of chronic anal fissures (Perroti et al., 2002). In other studies reported by Merenstein & Rosenbaum (2003) and Slawson (2003), remarkable improvement in healing was observed when 1.5% lidocaine and 0.3% nifedipine were applied twice daily for 6 weeks. Ezra & Susmalliam (2003) showed a better healing rate with topical nifedipine than with GTN. Katsinelos et al. (2006) reported that aggressive treatment of acute anal fissure with 0.5% nifedipine gel ointment prevents its evolution to chronicity. Twenty-seven of their 31 patients achieved complete remission and healing of the anal fissure following an 8-week treatment course (85.2%). Recurrence was observed in 16% of their patients. A systematic review of medical therapy for anal fissure including 31 trials from 1966 to 2002 returned the black shadow of pessimism to most physicians' minds. Nine agents were studied: GTN, isosorbide dinitrate, botulinum toxin, diltiazem, nifedipine, hydrocortisone, lidocaine, bran, and placebo. The results were only marginally better than placebo (R. Nelson, 2004)! A Cochrane Collaboration Review from 2009, by the same author, showed no better results. GNT was found to be marginally, but significantly, better than placebo in healing anal fissure (48.6% vs. 37%, $p < 0.004$), but late recurrence of the fissure was common, in the range of 50% of those initially cured! Botox and calcium channel blockers were equivalent to GNT in efficacy, with fewer adverse effects. No medical therapy was found to come close to the efficacy of surgical sphincterotomy (R.L. Nelson, 2006). Combined treatments have also been reported. The combination of nifedipine and botulinum toxin was superior to nitroglycerin and pneumatic dilatation with respect to both healing (94% v. 71%) and recurrence rate (2% v. 27%) (Tranqui et al., 2006). Headache is the most common complication of administering topical nifedipine in adults, but not in children. Nifedipine gel in the treatment of anal fissure has now been accepted even in China, with good results (Hong-yu et al., 2004). Reversible chemical sphincterotomy with nifedipine gel looks now as the most promising development in the treatment of anal fissures in children. The outcome is extremely good and side effects almost nonexistent.

11.4 Botulinum toxin (Botox)

Botulinum neurotoxin is a lethal biological substance produced by the anaerobic bacterium *Clostridium botulinum*. Serotype A is commercially available and has proven to be of therapeutic value in a variety of clinical conditions such as strabismus, torticollis,

hyperhidrosis, achalasia and chronic anal fissure (Jankovic & Brin, 1991). Botulinum toxin (Botox) is associated with a similar rate of healing of anal fissure as GTN, but is more expensive. The technique, dose and site of injection do not affect the rate of healing. The experience in children is very small. Jost & Schimrig (1993) first reported the use of botulinum toxin (BT) for anal fissure in 1933. The commercially available agent prevents neural transmission by preventing acetylcholine release from presynaptic nerve terminals. BT exerts its effects on the acetylcholine releasing parasympathetic peripheral nerve endings as well as the ganglionic nerve endings, leading to flaccid paralysis of the internal anal sphincter (IAS). This effect stays for about 3 months, a period sufficient for most non-complicated anal fissures to heal. Jost (1997) subsequently reported on a series of 100 patients treated with BT injection. In all, 78 patients became pain-free within 3 days, and healing rates at 3 and 6 months were 82% and 79%. BT injection was compared with topical GTN (0.2% twice daily) in a randomized trial of 50 chronic anal fissure patients (Brisinda et al., 1999). Resting anal pressure decreased in both groups, but did so to a greater extent in the BT group (29% with BT vs. 14% with GTN at 2 months). Healing rates were 96% in the BT group and 60% in the GTN group. No adverse effects were seen in the BT group.

11.5 Hyperbaric oxygen

Hyperbaric oxygen therapy provides a significant increase in tissue oxygenation in hypoperfused wounds. This increase in oxygen tension induces positive changes in the wound repair process by enhancing fibroblast replication, collagen synthesis and neovascularization. Cundall et al. (2003) reported a small series of adult patients with chronic anal fissure treated by hyperbaric oxygen. They found the procedure safe and appropriate in patients who have failed medical treatment, in those at risk of fecal incontinence, and in patients who are unfit for operation or in whom surgery has failed (Cundall et al., 2003).

11.6 Naturopathic treatment

Homeopathic medicines are excellent to alleviate the pain and spasm. Some of the more often indicated medicines are Chamomilla, Graphites, Nitric acid, Ratanhia, Sepia, Silicea and Thuja. Aesculus and Paeonia may be indicated if keynote symptoms are present. Homeopathic medicines often work faster and provide greater pain relief than analgesics and narcotics. In order to facilitate healing of the fissure, a topical cream consisting of Vitamins A and E, panthenol, calendula, goldenseal and Emu oil, can be used (Kruzel, 2006).

11.7 Iontophoresis

Iontophoresis using a zinc or copper electrode and applying a positive current will help to facilitate healing by hardening the underlying fissure, decreasing bleeding and affording pain relief.

11.8 Nd:YAG or CO2 laser

Contact Nd:YAG laser therapy appears to be efficient and safe in the treatment of anorectal lesions, including anal fissures (Sankar & Joffe, 1988; Walfisch et al., 1994). With the advent of the CO2 laser, a laser sphincterotomy and fissurectomy have proved to be very effective, with good results, prompt rehabilitation, reduced amount of complications and fewer

recurrences (Ali, 1988; Skobelkin et al., 1989). It involves laser vaporization of the fissure locally. Patient acceptance is remarkable, and the treatment can be carried out at a fraction of the cost of hospital surgical treatment. There are no reports of laser treatment for anal fissures in children.

11.9 Wonder remedies



Fig. 3a. Anal Fissures DX: a unique formula with anti-inflammatory properties, providing immediate soothing relief.



Fig. 3b. H-Fissures: healing natural oil with anti-inflammatory properties, specially formulated to provide instant relief from the pain and discomfort of fissures, reducing the swelling without skin irritation.



Fig. 3c. Fissure Control: a breakthrough topical homeopathic treatment made of a blend of herbs (Chamomile, Lavandula Angustifolia, Helichrysum, and Hamamelis Virginiana).



Fig. 3d. Paeonia-Heel: a homeopathic medicine containing *Paeonia officinalis* (Peony), Graphites (graphite), *Nux vomica* (vomit nut), Sulfur (sulphur), *Acidum nitricum* (nitric acid), and *Hamamelis* (witch-hazel).



Fig. 3e. Dr Wheatgrass's cream: enriched with highly bioactive wheatgrass-derived antioxidants, containing vitamins A,C and E, phytosterols, aminoacids and minerals. The Figure shows Dr Wheatgrass's antioxidant skin recovery cream.



Fig. 3f. Nature's Wonderland Stone Root Herbal Supplement: *Collinsonia Canadensis*, sour and spicy in taste, and warming in action. It relaxes constriction and clears venous congestion and inflammation. The Figure shows the *Collinsonia Canadensis* flowers.

12. Surgical treatment

Surgical treatment is rarely needed for infants and children. Open or closed lateral internal sphincterotomy (healing rates of 93% to 100%, recurrence rates of 0% to 25%), internal sphincterotomy (for chronic anal fissures), and posterior midline sphincterotomy are all part of the surgical arsenal. The open lateral sphincterotomy is the procedure of choice for children. Relative contraindications to operative treatment include inflammatory bowel disease and profound immunosuppression.

12.1 Anal dilatation

First described in 1829 by Recamier and popularized by Lord in the treatment of hemorrhoids, anal stretching has been used in the past based on the concept of loosening the sphincter muscle and increasing the blood flow to the anoderm. Anal dilatation was reintroduced for anal fissure therapy in 1964, with success rates of 87% to 100% (Watts et al., 1964), but are not recommended in children because of the very high rate of recurrence (10% - 30%), risk of sphincter damage and incontinence after excessive stretching.

12.2 Fissurectomy

Fissurectomy as a treatment for anal fissures in children was found successful only when combined with postoperative laxative therapy (Lambe et al., 2000a). An important part of their technique was the use of stay sutures to avoid the need for an anal retractor, thereby preventing stretching of the internal anal sphincter. A triangular part of the anoderm is excised along with the fissure itself. A good and reliable operation, but leaves behind a large and uncomfortable external wound, which takes a long time to heal. Application of a split thickness graft to the wound has been advocated, in order to improve healing.

12.3 Internal anal sphincterotomy

Internal anal sphincterotomy (IAS) was popularized for the treatment of anal fissure during the 1950s by Eisenhammer (1951). Lateral internal sphincterotomy (LIS) has been found to be the preferred operation. LIS can be performed using either the open or closed technique, the method of Notaras, dividing the IAS via a small stab wound (Notaras, 1971). Equal success has been reported with open or closed lateral sphincterotomy for acute and chronic anal fissures in children. A systematic review on the treatment of anal fissure was published by Steele & Madoff in 2006. Current concepts in anal fissures were reported by Ayantude et al. (2006) in the same year, involving a literature search from 1970 to 2004.

Chronic anal fissures tend to be refractory and are usually reluctant to heal with conservative treatment. Chronicity is defined by chronology (6-8 weeks) and morphologic features (visible transverse internal anal sphincter fibers, chronic granulation tissue, indurated edge, a sentinel pile, and a hypertrophic anal papilla). A very large series of adult patients was published by Lysy et al. in 2006. Prolonged periods of treatment were necessary and 384 patients were healed (84.4%) by the end of four months. Older age and longer time interval between symptom appearance and treatment negatively affected fissure healing. The explanation for the latter was that longer time exposure of the fissure area to

inflammation and ischemia and subsequent fibrosis may compromise the healing process. After recurrence, patient education for self and prompt retreatment was found to improve outcome. Chronic anal fissures are caused by internal sphincter hypertonia, which leads to reduced blood flow and tissue hypoxia, with consequent healing failure. A cautious surgical approach is required to treat those who do not respond to medical treatment, and should include excision of the fissure along with its sentinel tag and internal sphincterotomy at the base of the ulcer (Cohen & Dehn, 1995; Lambe et al., 2000b). The wound is left open and should heal in 7-14 days without scarring. Local reconstruction with advancement flaps is a relatively new and effective adjunct to chronic fissure excision. Practice parameters for the management of anal fissures from the American Society of Colon and Rectal Surgeons were reported by Orsay et al. (2004) and a very extensive review on the diagnosis and care of patients with anal fissure was reported by the American Gastroenterological Association (Madoff & Fleshman, 2003).

13. Our experience: Nifedipine gel 0.2% with lidocaine

13.1 Subjects

Seventy children suffering from acute and chronic anal fissures treated by us between 2004 and 2010 comprised the study population. They were all treated topically with nifedipine gel 0.2% with lidocaine for 4 weeks and followed up for as long as possible in our outpatient clinic (a maximum of 5 years).

13.2 Methods

Because anal fissure has such a distinctive appearance, its healing is the most objective measure of treatment efficacy available that can be standardized. Combining all analyses in which a placebo was used as the comparison group, the healing rate in the placebo group is 35.5 percent, a level of response that is fairly uniform across studies (standard deviation, 11.8 percent). For these reasons we did not find necessary to use a control group in the present pilot study.

13.3 Results

There were 28 males and 42 females. Their clinical presentation consisted of constipation, rectal bleeding, anal and abdominal pain, perianal itching and rectal prolapse (58, 50, 33, 6, 4, and 1 cases, respectively). Posterior, anterior, multiple, both posterior and anterior, and both posterior and lateral fissures were the main physical findings (44, 16, 5, 4, and 1 cases, respectively). Fifty eight patients completed the 4-week treatment course, with another 7 patients requiring a second 4-week treatment course in order to achieve complete remission, indicated by resolution of symptoms and complete healing of the fissure (65 patients altogether). The remaining 5 patients had recurrence of symptoms in 2, 4, 11, 18 and 19 months, respectively, treated successfully by an additional 4-week course of nifedipine. The recurrence rate observed was very low (7.14%). All the 70 patients had a mean follow-up of 1.88 years, ranging from 6 months to 5.2 years. Problems with compliance were not observed, one of the main reasons for treatment failure in adults. No side effects of nifedipine were observed.

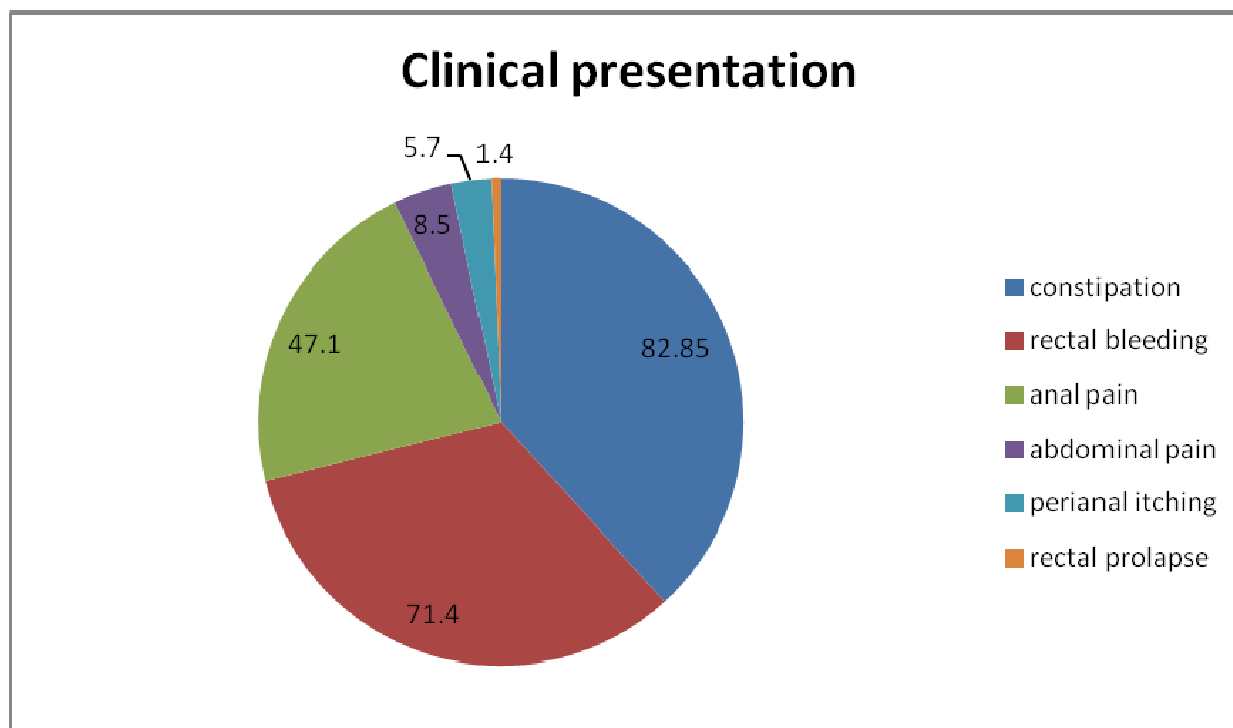


Fig. 4. Clinical presentation (percentage)

14. Special situations

1. Crohn's disease: Platell et al. (1996) noted symptomatic anal pathology in 42.4% of Crohn's disease patients, 27.6% of them presenting anal fissures. Frequently, they are multiple or off the midline, and often coexist with other pathology (Sangwan et al., 1996). They can be locally aggressive, progressing to form deep ulcers with granulating bases and overlapping skin edges.
2. HIV/AIDS: Anal fissures maintain their typical appearance, but have poor wound healing (Lord, 1997). Barrett et al. (1998) reported their experience with perianal disease in 260 HIV-positive patients, 32% of them with anal fissures (Barrett et al., 1998). Eighteen patients underwent sphincterotomies. Viamonte et al. (1993) reviewed the treatment of 33 HIV-positive fissure patients. Thirteen underwent LIS, with excellent results (12 improved).

15. Conclusions

Topical 0.2% nifedipine with lidocaine appears today as the most efficient mode of treatment for anal fissures in children, with a significant healing rate and no side effects. It is safe and effective, prevents the evolution of acute anal fissures in children to chronicity, avoids surgical procedures in the great majority of cases, avoids complications and does not require hospitalization.

Efficacy of medical treatment (number of patients)

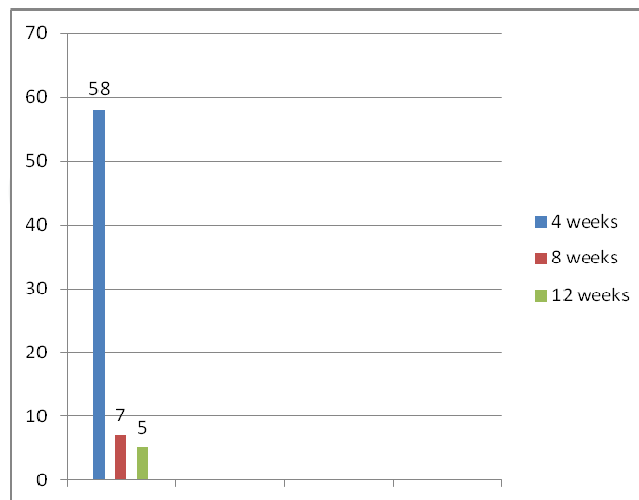


Fig. 5. Efficacy of medical treatment.

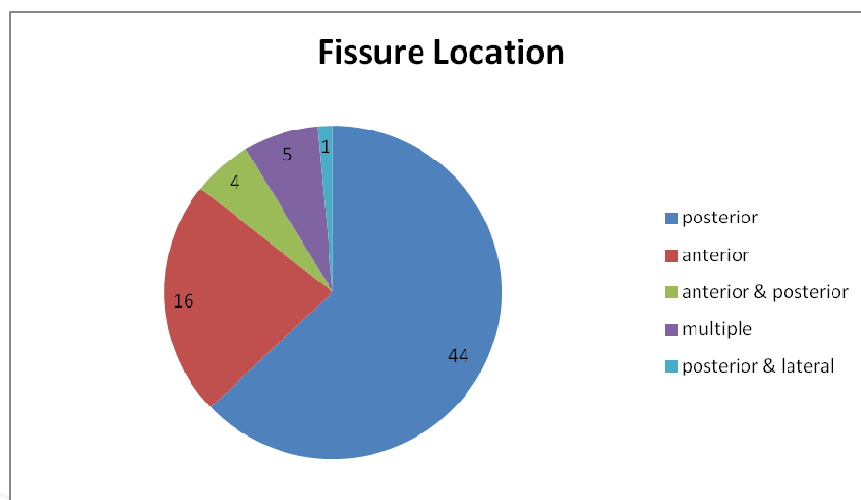


Fig. 6. Fissure location

16. Acknowledgment

The authors wish to express their gratitude to Mrs. Fredrica Gendler for her continuous help, highly professional and invaluable assistance.

17. References


- Ali, M.M. (1988). Treatment of chronic anal fissure utilizing CO2 Laser. *Laser Medicine and Surgery News and Advances*, Vol.6, No.1, (February 1988), pp. 39-40
- Antropoli, C., Perrotti, P., Rubino, M., Martino, A., De Stefano, G., Migliore, G., Antropoli, M., & Piazza, P. (1999). Nifedipine for local use in conservative treatment of anal

- fissures: preliminary results of a multicenter study. *Diseases of the Colon and Rectum*, Vol.42, No.8, (August 1999), pp. 1011-1015
- Ayantude, A.A., & Debrah, S.A. (2006). Current concepts in anal fissures. *World Journal of Surgery*, Vol.30, No.12, (December 2006), pp. 2246-2260
- Bacher, H., Mischinger, H.J., Werkgartner, G., Cerwenka, H., El-Shabrawi, A., Pfeifer, J., & Schweiger, W. (1997). Local nitroglycerin for treatment of anal fissures: an alternative to lateral sphincterotomy? *Diseases of the Colon & Rectum*, Vol.40, No.7, (July 1997), pp. 840-845
- Barrett, W.L., Callahan, T.D., & Orkin, B.A. (1998). Perianal manifestations of human immunodeficiency virus infection: experience with 260 patients. *Diseases of the Colon and Rectum*, Vol.41, No.5, (May 1998), pp. 606-611
- Bhardwaj, R., Vaizey, C.J., Boulos, P.B., & Hoyle C.H. (2000). Neuromyogenic properties of the internal anal sphincter: therapeutic rationale for anal fissures. *Gut*, Vol.46, No.6, (June 2000), pp. 861-868
- Brisinda, G., Maria, G., Bentivoglio, A.R., Cassetta, E., Gui, D., & Albanese, A. (1999). A comparison of injections of botulinum toxin and topical nitroglycerin ointment for the treatment of chronic anal fissure. *The New England Journal of Medicine*, Vol.341, No.2, (July 1999), pp. 65-69
- Burleigh, D. E., D'Mello, A., & Parks, A. G. (1979). Responses of isolated human internal anal sphincter to drugs and electrical field stimulation. *Gastroenterology*, Vol.77, No.3, (September 1979), pp. 484-490
- Carapeti, E.A., Kamm, M.A., McDonald, P.J., Chadwick, S.J., Melville, D., & Phillips, R.K. (1999). Randomised controlled trial shows that glyceryl trinitrate heals anal fissures, higher doses are not more effective, and there is a high recurrence rate. *Gut*, Vol.44, No.5, (May 1999), pp. 727-730
- Chrysos, E., Xynos, E., Tzovaras, G., Zoras, O.J., Tsiaoussis, J., & Vassilakis, S.J. (1996). Effect of nifedipine on rectoanal motility. *Diseases of the Colon and Rectum*, Vol.39, No.2, (February 1996), pp. 212-216
- Cohen, A., & Dehn, T.C. (1995). Lateral subcutaneous sphincterotomy for treatment of anal fissure in children. *The British Journal of Surgery*, Vol.82, No.10, (October 1995), pp. 1341-1342
- Cook, T.A., Brading, A.F., & Mortensen, N.J. (2001). The pharmacology of the internal anal sphincter and new treatments of ano-rectal disorders. *Alimentary Pharmacology & Therapeutics*, Vol.15, No.7, (July 2001), pp. 887-898
- Cundall, J.D., Gardiner, A., Laden, G., Grout, P., & Duthie, G.S. (2003). Use of hyperbaric oxygen to treat chronic anal fissure. *The British Journal of Surgery*, Vol.90, No. 4, pp. 452-453
- DeMoulin, D. (1977). A fundamental affair - a short history of anal fissure. *Archivum Chirurgicum Neerlandicum*, Vol.29, No.3, (1977), pp. 163-166
- Dorfman, G., Levitt, M., & Platell, C. (1999). Treatment of chronic anal fissure with topical glyceryl trinitrate. *Diseases of the Colon and Rectum*, Vol.42, No.8, (August 1999), pp. 1007-1010
- Eisenhammer, S. (1951). The surgical correction of chronic internal anal sphincteric contracture. *South African Medical Journal*, Vol.25, No.28, (July 1951), pp. 486-489
- Ezri, T., & Susmallian, S. (2003). Topical nifedipine vs. topical glyceril trinitrate on chronic anal fissure. *Diseases of the Colon and Rectum*, Vol.46, No.6, (June 2003), pp. 805-808
- Gillett, B.P., & Paidas, C.N. (2006). Anal fissure, In: *eMedicine*, Accessed 4th August, 2011, Available from: www.emedicine.medscape.com/article/934952-print
- Gosselink, M.P., Darby, M., Zimmerman, D.E., Gruss, H.J., & Schouten, W.R. (2005). Treatment of chronic anal fissure by application of L-arginine gel : a phase II study in 15 patients. *Diseases of the Colon and Rectum*, Vol.48, No.4, (April 2005), pp. 832-837

- Gowers, W.R. (1877). The automatic action of the sphincter ani. *Proceedings of the Royal Society of London*, Vol.26, pp. 77–84
- Hancock, B.D. (1977). The internal sphincter and anal fissure. *The British Journal of Surgery*, Vol.64, No.2, (February 1977), pp. 92–95
- Hong-yu, T., Jia-he, X.U., Mei-fu, S., & Yu-miao, H. (2004). Nifedipine gel in the treatment of anal fissure. *Chinese Journal of New Drugs and Clinical Remedies*, Vol.01, ISSN 1007–7669
- Jankovic, J., Brin, M.F. (1991). Therapeutic uses of botulinum toxin. *The New England Journal of Medicine*, Vol.324, No.17, (April 25), pp. 1186–1194
- Jost, W.H., & Schimrig, K. (1993). Use of botulinum toxin in anal fissure. *Diseases of the Colon and Rectum*, Vol.36, No.10, (October 1993), pp. 974
- Jost, W.H. (1997). One hundred cases of anal fissure treated with botulin toxin: early and long-term results. *Diseases of the Colon and Rectum*, Vol.40, No.9, (September 1997), pp. 1029–1032
- Inburg, K.R. (1953). Partial internal sphincterotomy compared with some other methods in the treatment of anal fissure. *Acta Chirurgica Scandinavica*, Vol.183, pp. 1–40
- Katsinelos, P., Kountouras, J., Paroutoglou, G., Beltsis, A., Chatzimavroudis, G., Zavos, C., Katsinelos, T., & Papaziogas, B. (2006). Aggressive treatment of acute anal fissure with 0.5% nifedipine ointment prevents its evolution to chronicity. *World Journal of Gastroenterology*, Vol.12, No.38, (October 2006), pp. 6203–6206
- Kenny, S.E., Irvine, T., Driver, C.P., Nunn, A.T., Losty, P.D., Jones, M.O., Turnock, R.R., Lamont, G.L., & Lloyd, D.A. (2001). Double blind randomised controlled trial of topical glyceryl nitrate in anal fissure. *Archives of Disease in Childhood*, Vol.85, No.5, (November 2001), pp. 404–407
- Klosterhalfen, B., Vogel, P., Rixen, H., & Mittermayer, C. (1989). Topography of the inferior rectal artery: a possible cause of chronic, primary anal fissure. *Diseases of the Colon & Rectum*, Vol.32, No.1, (January 1989), pp. 43–45
- Kruzel, T.A. (2006). Naturopathic treatment of anal fissure. *Naturopathic Doctor News & Review*, (March 2006).
- Lambe, G.F., Driver, C.P., Morton, S., & Turnock, R.R. (2000a). Fissurectomy as a treatment for anal fissures in children. *Annals of the Royal College of Surgeons of England*, Vol.82, No.4, (July 2000), pp. 254–257
- Lambe, G.F., Driver, C.P., Morton, S., & Turnock, R.R. (2000b). Fissurectomy as a treatment for anal fissures in children. *Annals of the Royal College of Surgeons of England*, Vol.82, No. 4, (July 2000), pp. 254–257
- Loder, P.B., Kamm, M.A., Nicholls, R.J., & Phillips, R.K. (1994). Reversible chemical sphincterotomy by local application of glyceryl trinitrate. *The British Journal of Surgery*, Vol.81, No.9, (September 1994), 1386–1389
- Lord, R.V. (1997). Anorectal surgery in patients infected with human immunodeficiency virus: factors associated with delayed wound healing. *Annals of Surgery*, Vol.226, No.1, (July 1997), pp. 92–99
- Lund, J.N., Scholefield, J.H. (1996). Aetiology and treatment of anal fissure. *The British Journal of Surgery*, Vol.83, No.10, (October 1996), pp. 1335–1344
- Lund, J.N., & Scholefield, J.H. (1997). A randomized, prospective, double-blind, placebo-controlled trial of glyceryl trinitrate ointment in treatment of anal fissure. *Lancet*, Vol.9044, No.349, (January 1997), pp. 11–14
- Lund, J.N. (2006). Nitric oxide deficiency in the internal anal sphincter of patients with chronic anal fissure. *International Journal of Colorectal Disease*, Vol.21, pp. No 7, (October 21), pp. 673–675

- Lysy, J., Israeli, E., Levy, S., Rozentzweig, G., Strauss-Liviatan, N., & Goldin, E. (2006). Long-term results of "chemical sphincterotomy" for chronic anal fissure: a prospective study. *Diseases of the Colon and Rectum*, Vol.49, No.6, (June 2006), pp. 858-864
- Madoff, R.D., & Fleshman, J.W. (2003). AGA technical review on the diagnosis and care of patients with anal fissure. *Gastroenterology*, Vol.124, No.1, (January 2003), pp. 235-245
- McCallion, K., & Gardiner, K.R. (2001). Progress in the understanding and treatment of chronic anal fissure. *Postgraduate Medical Journal*, Vol.77, No.914, (December 2001), pp. 753-758
- Merenstein, D., & Rosenbaum, D. (2003). Is topical nifedipine effective for chronic anal fissures? *The Journal of Family Practice*, Vol.52, No.3, (March 2003), pp. 190-192
- Nelson, J. (2006). History of anal fissure treatment. *Seminars in Colon & Rectal Surgery*, Vol.17, No.3, (March 2006), pp. 104-105
- Nelson, R. (2004). A systematic review of medical therapy for anal fissure. *Diseases of the Colon and Rectum*, Vol.47, No.4, (April 2004), pp. 422-431
- Nelson, R.L. Non surgical therapy for anal fissure. (2006). *Cochrane Database of Systematic Reviews*, Issue 4, Art. No.CD003431, DOI: 10.1002/14651858.CD003431.pub2
- Notaras, M.J. (1988). Anal fissure and stenosis. *The Surgical Clinics of North America*, Vol.68, No.6, (December 1988), pp. 1427-1440
- Notaras, M.J. (1971). The treatment of anal fissure by lateral subcutaneous internal sphincterotomy - a technique and results. *The British Journal of Surgery*, Vol.58, No.2, (February 1971), pp. 96-100
- O'Kelly, T.J., Davies, J.R., Brading, A.F., & Mortensen, N.J. (1994). Distribution of nitric oxide synthase containing neurons in the rectal myenteric plexus and anal canal. Morphologic evidence that nitric oxide mediates the rectonal inhibitory reflex. *Diseases of the Colon and Rectum*, Vol.37, No.4, (April 1994), pp. 350-357
- Orsay, C., Rakinic, J., Perry, W.B., Hyman, N., Buie, D., Cataldo, P., et al. (2004). Practice parameters for the management of anal fissures (revised). *Diseases of the Colon and Rectum*, Vol.47, No.12, (December 2004), pp. 2003-2007
- Oshiro, H., Kobayashi, I., Kim, D., Takenaka, H., Hobson, R.W. 2nd, & Durán, W.N. (1995). L-type calcium channel block the microvascular hyperpermeability induced by platelet-activating factor in vivo. *Journal of Vascular Surgery*, Vol.22, No.6, (December 1995), pp. 732-739; discussion 739-741
- Parks, A.G., Fishlock, D.J., Cameron, J.D., & May, H. (1969). Preliminary investigation of the pharmacology of the human internal anal sphincter. *Gut*, Vol.10, No.8, (August 1969), pp. 674-677
- Perrotti, P., Bove, A., Antropoli, C., Molino, D., Antropoli, M., Balzano, A., De Stefano, G., & Attena, F. (2002). Topical nifedipine with lidocaine ointment vs. active control for treatment of chronic anal fissure: results of a prospective, randomized, double-blind study. *Diseases of the Colon and Rectum*, Vol.45, No.11, (November 2002), pp. 1468-1475
- Platell, C., Mackay, J., Collopy, B., Fink, R., Ryan, P., & Woods, R. (1996). Anal pathology in patients with Crohn's disease. *The Australian and New Zealand Journal of Surgery*, Vol.66, No.1, (January 1996), pp. 5-9
- Rattan, S., & Chakder, S. (1992). Role of nitric oxide as a mediator of internal anal sphincter relaxation. *The American Journal of Physiology*, Vol.262, No.1 Pt 1, (January 1992), pp. G107-G112
- Ruiz-Moreno, F. (1968). Sliding mucocutaneous flap for the treatment of anal ulcer. *Diseases of the Colon & Rectum*, Vol.11, No.4, (July-August 1968), pp. 285-288
- Samson, R., & Stewart, W. (1970). Sliding skin grafts in the treatment of anal fissures. *Diseases of the Colon & Rectum*, Vol.13, No.5, (September-October 1970), pp. 372-375

- Sangwan, Y.P., Schoetz, D.J. Jr., Murray, J.J., Roberts, P.L., & Collier, J.A. (1996). Perianal Crohn's disease. Results of local surgical treatment. *Diseases of the Colon and Rectum*, Vol.39, No.5, pp. 529-535
- Sankar, M.Y., & Joffe, S.N. (1988). Laser surgery in colonic and anorectal lesions. *The Surgical Clinics of North America*, Vol.68, No.6, (December 1988), pp. 1447-1469
- Schouten, W.R., & Blankensteijn, J.D. (1992). Ultra slow wave pressure variations in the anal canal before and after lateral internal sphincterotomy. *International Journal of Colorectal Disease*, Vol.7, No.3, (September 1992), pp. 115-118
- Schouten, W.R., Briel, J.W., & Auwerda, J.J. (1994). Relationship between anal pressure and anodermal blood flow. The vascular pathogenesis of anal fissures. *Diseases of the Colon & Rectum*, Vol.37, No.7, (July 1994), pp. 664-669
- Schouten, W.R., Briel, J.W., Aurwerda, J.J., & Boerma, M.O. (1996). Anal fissure: new concepts in pathogenesis and treatment. *Scandinavian Journal of Gastroenterology. Supplement*, Vol.218, pp. 78-81
- Shafik, A. (1993). Role of warm-water bath in anorectal conditions: The "thermosphincteric reflex". *Journal of Clinical Gastroenterology*, Vol.16, No.4, (June 1993), pp. 304-308
- Shub, H.A., Salvati, E.P., & Rubin, R.J. (1978). Conservative treatment of anal fissure: an unselected, retrospective and continuous study. *Diseases of the Colon and Rectum*, Vol.21, No.8, (December 1978), pp. 582-583
- Skobelkin, O.K., Tolstykh, P.I., Derbenev, V.A., Ste'enko, V.G., & Kochurkov, N.V. (1989). [Carbon dioxide laser in the surgical treatment of proctologic diseases]. *Vestnik Khirurgii Imeni I. I. Grekova*, Vol.143, No.9, (September 1989), pp. 3-5 [Article in Russian]
- Slawson, D. (2003). Topical nifedipine plus lidocaine gel effective for anal fissures. *American Family Physician*, Vol.67, No.8, (April 2003) pp. 1781
- Sönmez, K., Demiroğullari, B., Ekingen, G., Türkyilmaz, Z., Karabulut, R., Başaklar, A.C., & Kale, N. (2002). Randomized, placebo-controlled treatment of anal fissure by lidocaine, EMLA, and GNT in children. *Journal of Pediatric Surgery*, Vol.37, No.9, (September 2002), pp. 1313-1316
- Steele, S.R., & Madoff, R.D. (2006). Systematic review: the treatment of anal fissure. *Alimentary Pharmacology & Therapeutics*, Vol.24, No.2, (July 2006), pp. 247-257
- Tander, B., Güven, A., Demirbağ, S., Ozkan, Y., Oztürk, H., & Cetinkurşun, S. (1999). A prospective, randomized, double-blind, placebo-controlled trial of glyceryl nitrate ointment in the treatment of children with anal fissure. *Journal of Pediatric Surgery*, Vol.34, No.12, (December 1999), pp. 1810-1812
- Tranqui, P., Trottier, D.C., Victor, C., & Freeman J.B. (2006). Nonsurgical treatment of chronic anal fissure: nitroglycerin and dilatation versus nifedipine and botulinum toxin. *Canadian Journal of Surgery*, Vol.49, No.1, (February 2006), pp. 41-45
- Viamonte, M., Dailey, T.H., & Gottesman, L. (1993). Ulcerative disease of the anorectum in the HIV+ patient. *Diseases of the Colon and Rectum*, Vol.36, No.9, (September 1993), pp. 801-805
- Walfisch, S., Ohana, N., & Charuzi, E. (1994). Nd:YAG laser for anorectal surgery: initial experience in Israel. *Harefuah*, Vol.126, No.1, (January 1994), pp. 1-4, 56 [Article in Hebrew]
- Watts, J.M., Bennett, R.C., & Goligher, J.C. (1964). Stretching of anal sphincters in treatment of fissure-in-ano. *British Medical Journal*, Vol.8, No.2, (August 1964), pp 342-343



Complementary Pediatrics

Edited by Dr. Öner Özdemir

ISBN 978-953-51-0155-0

Hard cover, 354 pages

Publisher InTech

Published online 16, March, 2012

Published in print edition March, 2012

Complementary Pediatrics covers complementary issues of pediatric subspecialties consisting of ophthalmologic, surgical, psychosocial and administrative issues of frequently used medications. This book volume with its 16 chapters will help get us and patients enlightened with the new developments on these subspecialties' area.

How to reference

In order to correctly reference this scholarly work, feel free to copy and paste the following:

Baruch Klin, Ibrahim Abu-Kishk, Yigal Efrati and Gad Lotan (2012). Nifedipine Gel with Lidocaine in the Treatment of Anal Fissure in Children: A Pilot Study and Review of the Literature, Complementary Pediatrics, Dr. Öner Özdemir (Ed.), ISBN: 978-953-51-0155-0, InTech, Available from:
<http://www.intechopen.com/books/complementary-pediatrics/nifedipine-gel-with-lidocaine-in-the-treatment-of-anal-fissure-in-children-a-pilot-study>

INTECH
open science | open minds

InTech Europe

University Campus STeP Ri
Slavka Krautzeka 83/A
51000 Rijeka, Croatia
Phone: +385 (51) 770 447
Fax: +385 (51) 686 166
www.intechopen.com

InTech China

Unit 405, Office Block, Hotel Equatorial Shanghai
No.65, Yan An Road (West), Shanghai, 200040, China
中国上海市延安西路65号上海国际贵都大饭店办公楼405单元
Phone: +86-21-62489820
Fax: +86-21-62489821

© 2012 The Author(s). Licensee IntechOpen. This is an open access article distributed under the terms of the [Creative Commons Attribution 3.0 License](#), which permits unrestricted use, distribution, and reproduction in any medium, provided the original work is properly cited.

IntechOpen

IntechOpen