

We are IntechOpen, the world's leading publisher of Open Access books Built by scientists, for scientists

4,800

Open access books available

122,000

International authors and editors

135M

Downloads

Our authors are among the

154

Countries delivered to

TOP 1%

most cited scientists

12.2%

Contributors from top 500 universities



WEB OF SCIENCE™

Selection of our books indexed in the Book Citation Index
in Web of Science™ Core Collection (BKCI)

Interested in publishing with us?
Contact book.department@intechopen.com

Numbers displayed above are based on latest data collected.

For more information visit www.intechopen.com



Microinvasive Carcinoma of the Cervix

Fernando Anschau, Chrystiane da Silva Marc,
 Maria Carolina Torrens and Manoel Afonso Guimarães Gonçalves
*Pontifícia Universidade Católica do Rio Grande do Sul,
 Fundação Universitária de Cardiologia – Instituto de Cardiologia de Porto Alegre,
 Faculdade Nossa Senhora de Fátima – Caxias do Sul
 Brazil*

1. Introduction

There is a minimally invasive nosological entity among cervical precursor lesions and frank invasive cancer. Initially described by Mestwerdt in 1947, cases of microinvasive carcinoma of the uterine cervix represent a group of patients with better prognosis with the possibility of needing less radical treatment.¹ Despite that microinvasion has been defined since the 1940s, the depth of invasion, as well as the lateral extension, are subjects of various classifications and certain controversy.

2. Definition

There is a continuum of knowledge about microinvasive cervical cancer from its initial landmark in 1947, which must be understood so that we can reflect on the information and approaches recommended by different authors.

The first conception of microinvasive squamous cell carcinoma of the cervix was presented by Mestwerdt in 1947, who strived to develop an early diagnosis of cervical carcinoma. In this first work, Mestwerdt cited that the discovery of 43 cases of microcarcinoma was possible with the combination of colposcopy and the iodine test with the standard histologic examination over a period of 9 ½ years. This author considered the attributes of microcarcinoma of cervix to be the following:

- Size still at the microscopic level.
- All originate from the squamous epithelium of the cervix to cervical canal up to its limit, but is still not associated with the surface.
- They show all the phases of atypia.
- Besides the complete structure of changes in all layers of the surface epithelium, where its construction is in the longer recognizable, there is simultaneous rupture of the basal membrane by glandular budding in the connective tissue.
- Also observed on the surface is invasion of lymphatic spaces and blood vessels.

The measurement of stromal invasion, always defined microscopically, should be done from the basement membrane. ¹ In 1961, the International Federation of Gynecology and Obstetrics (FIGO) on proposing the classification cervical cancer, recommended the

subdivision of stage I into IA and IB. Stage IA would be defined as early stromal invasion. In 1965, two groups published the problematization with respect to depth of invasion. Margulis and coworkers believed that the definition should include invasion of 5.0 mm of the stroma, while Ullery and coworkers considered invasion beyond the basement membrane of 3.0 mm.

Temporarily, we can refer to 1971 when FIGO introduced the term “occult cancer of the cervix” for stage IA. In 1973, Burghardt proposed the study of the volume of the lesion, believing that 500 mm³ would be a better option for the definition in question.

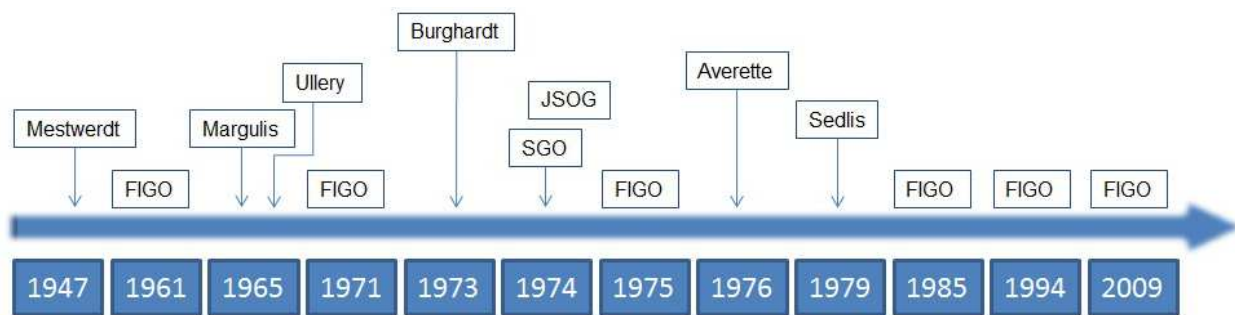
Despite the above mentioned proposal by FIGO, there was still no clear criteria for minimal stromal invasion. In 1974, the Society of Gynecologic Oncologists (SGO) proposed a definition for microinvasion as a lesion that invaded below the basement membrane to a depth of 3 mm or less, with no evidence of invasion of the lymphovascular space. SGO believed that the horizontal dimension would not enter into the classification of microinvasion. Despite new classifications in 1971 and 1975, with the introduction of the term occult carcinoma, FIGO would return in the 1980s with a definition that considered the measurement of the depth of invasion in cervical cancer in stage I. The preoccupation with the depth and extension of the lesion can also be observed in the study of Averette and coworkers, which in 1976 led to expectations regarding lesions of up to 1 mm, and in the study of Sedlis and colleagues, who determined a maximal extension of 4 mm for the definition of microinvasive cancer. The new definition from FIGO in 1985 brought criteria for carcinomas referred to as pre-clinical, dividing them into two groups: IA1 with minimal stromal invasion and IA2 with invasion up to 5 mm and not exceeding 7 mm. Again, in referring to the FIGO classification, we observe the reiteration of not considering the influence of the invasion of the lymphatic space in the stage.

In 1994, FIGO presented the classification of cervical cancer that put together clear measurements for the invasion of the stroma in stages IA1 and IA2. This classification was revised in 2009, and the term microscopic cancer was proposed for stage IA. Therefore, all gross lesions, even if superficial, were considered stage IB. The invasion was limited to 5 mm in depth and 7 mm of extension. The involvement of the lymphovascular space continued to have no effect on staging, but did influence the treatment. The invasion of the stroma up to 3 mm in depth and 7 mm of extension characterized stage IA1, and invasion of the stroma between 3 mm and 5 mm in depth and 7 mm of extension, stage IA2.^{2,3}

Certainly one of the main factors involved in the definition of the depth of invasion and in the classification of microinvasion was the involvement of the lymphovascular space and consequently the possibility of lymph node metastasis in the pelvis and vaginal recurrence. The role of lymphovascular invasion and the possibility of lymph node metastasis are also the subject of many speculations about the treatment of microinvasive cervical carcinoma.

3. Diagnosis

Over the last years this early invasive carcinoma has become an increasingly important part of the problem of cervical cancer. The mounting frequency with which these diagnoses are made is directly related to the increased use of the Papanicolaou smear technique and use of large loop excision of the transformation zone.



FIGO: International Federation of Gynecology and Obstetrics;
 SOG: Society of Gynecologic Oncologists (USA);
 JSOG: Japanese Society of Obstetrics & Gynecology;

Fig. 1. Evolution of the definition of microinvasive carcinoma of the cervix

Although definitive diagnosis of microinvasion must be done by histological evaluation of specimens obtained by conization or hysterectomy, some colposcopy signs could identify this situation. Reid pointed out some colposcopic and clinical warning signs of invasion:

- Friable areas, with easy bleeding upon touch
- Defined areas as colposcopically significant - with Reid index ≥ 5 - showing irregular surface
- Superficial ulcers with white epithelium at edges
- Atypical vessels
- Mosaic or rough dotted area at extreme, particularly when showing large and irregular intercapillary distance
- Groups of lesions with large extension and with characteristics of colposcopic lesion of high grade
- Colposcopic lesions of high grade type penetrating more than 5 mm in the endocervical canal
- Intra-epithelial cervical lesions of high grade on histology by biopsy in which the basement membrane cannot be clearly defined
- Cytological evidence of squamous cell carcinoma or of adenocarcinoma *in situ*

Despite the efforts for colposcopic detection of microinvasive alterations, this diagnostic modality does not show a good predictive indicator of the severity of the cervical lesion and tends to underestimate microinvasive carcinoma. The colposcopic images, besides not being characteristic, are difficult to interpret and microinvasive lesions are often endocervical. Colposcopic signs are even more inconsistent when the focus of invasion is small and superficial.^{4, 5, 6} There are no specific colposcopic findings of microinvasive carcinoma. The findings resemble cases of *in situ* and invasive carcinoma. Colposcopy is better at identifying pre-malignant or frank invasive disease than microinvasive lesions.

The determination of microinvasion should always be done by systematic histologic evaluation of a consistent sample of cervix, using serial sections in order to determine with precision the depth and extension of the invasion, besides the penetration of the lymphovascular space. Even with colposcopic lesion with guided biopsy of the cervix, sometimes there is no guarantee that the biopsied material is sufficient for defining the diagnosis. In the localization of the microinvasion, with the analysis of the conization

specimens of the cervix, the focus of the microinvasion from the basement membrane of the epithelium is found at the following sites: the ectocervix besides the last gland in 11% of cases, inside the transformation zone in 71% of cases (22% on the surface of the epithelium and 49% in the depth or glandular crypts) and in the endocervical canal in 18% of cases.⁷

The whole extension of cervical cancer screening programs have led to an increase in the detection of microinvasion, as well as the dissemination of the utilization of a diathermy loop for excision of altered areas and resection of the transformation zone in the investigation of suspect cases.

The evaluation of the biopsy by an experienced pathologist is essential for the correct identification of microinvasion with its respective measurement and characterization of the presence or not of invasion of the lymphovascular space. Also, it is of great importance that the pathologist can determine the presence of compromise of the margins and the grade of these lesions. Therefore, for young patients with the intention of preserving fertility, the identification of these parameters can translate to conservative treatment.

4. Treatment

Based on the premise that the neoplastic cell with malignant differentiation has the potential to metastasize through the lymphatic and vascular systems, it should be taken into consideration that this could occur even at initial stages of invasion of the basement membrane. Meanwhile, various lines of epidemiological evidence indicate stage IA1 as having a low potential for lymph node metastasis and good disease-free survival rates. Lee and et al. found that the lymphovascular space was compromised in 0.9% of cases when invasion was less than 1 mm and in 10.2 % when invasion was between 1 and 3 mm deep.⁸ Ostor et al. demonstrated compromise of the space lymphovascular in 3% and 15% when invasion was up to 1 mm and between 1 and 3 mm, respectively.⁹

The requirements in relation to the involvement of the lymphovascular space with tumor cells are still points to ponder; therefore, understanding that doubt is part of the thought process, we propose the following reflections: (1) Why ignore the involvement of the lymphovascular space? (2) Why value the involvement of the lymphovascular space?

Why ignore the involvement of the lymphovascular space?

- Conflicting evidence
- Studies not associating the involvement of the lymphovascular space with lymph node metastasis
- Interpretation of invasion of the lymphovascular space is subjective
- Inflammation and retraction artifacts can cause confusion

Why value the involvement of the lymphovascular space?

- Think of invasive tumor
- Associated with greater probability of lymph node metastasis
- Associated with worse prognosis - more radical treatment
- Increased identification with increased serial sections

The initial idea of Mestwerdt of performing serial histologic sections with detailed examination of the sections is still an interesting prerogative in this aspect. In 1975, a study

with serial sections of 30 microinvasive carcinomas of the cervix (invasion between 2 and 5 mm) demonstrated that 30% had compromise of the lymphovascular space – based on the first of the blocks; but this percentage increased to 57% with serial sections. No patient showed lymph node metastasis.¹⁰

5. Lymph nodes

Although FIGO does not include the lymph node status in its staging system for cervical carcinoma, it is known that for patients treated surgically in initial stages, the presence of ganglion metastasis is the most important risk factor for recurrence and mortality.¹¹ In addition, an adequate knowledge of lymph node compromise is essential for the indication of adjuvant treatment.

Traditionally, for lymph node evaluation, the technique proposed is bilateral retroperitoneal lymphadenectomy. However, this practice, associated with high rates of short- and long-term morbidity, has been questioned in initial stages, since a small portion of patients show lymphatic compromise. Studies with patients in stages IA1 and IA2 demonstrated an incidence of lymph node metastasis in 7.3% (0%-13.8%) of cases.^{12, 13} In the work of Sevin et al.¹⁴, no cases of lymph node invasion were found when analyzing 110 cases of microinvasive carcinoma with stromal invasion less than or equal to 5 mm. What we can reflect on the positivity of the lymph nodes is that as the depth of stromal invasion increases, there is an increase in the percent of lymph nodes compromised with metastatic cells. Thus, some studies demonstrate the following relation between depth of invasion and lymph node metastasis: invasion up to 1 mm, presence of <1 to 1.5% of lymph nodes compromised; between 1 and 3 mm, <1 to 4.2%; between 3 and 5 mm, between 2 and 3.7%.^{8,9}

Aimed at reducing the rate of complications of lymphadenectomy, the technique of sentinel lymph node biopsy (SLB), introduced by Cabañas,¹⁵ has been studied in cases of cervical carcinoma. Studies evaluating the accuracy and applicability of sentinel lymph node biopsy in cervical carcinoma have shown promising results (high rates of detection and low false-positive rates), mainly when analyzing cases of lesions less than 2 cm.¹⁶ Other authors have demonstrated a 94% rate of detection of sentinel lymph nodes associated with sensitivity and negative predictive value of 100%, for tumors less than 2 cm.¹⁷ The recent study SENTICOL¹⁸, in which SLB was carried out in a uniform manner by experienced surgeons, combining techniques that utilize blue dye and lymphoscintigraphy with technetium (Tc99), demonstrated a sensitivity of 92% and obtained ideal mapping in 75% of patients. These authors concluded that when utilizing the two techniques combined, a negative result in the sentinel lymph nodes on both sides indicates the absence of metastatic disease, with a negative predictive value of 98.2%.

In accordance with studies in 2011, the use of laparoscopy in the detection and removal of sentinel lymph nodes (SL) is evidence-based and safe with either the use of blue dye or Tc99 lymphoscintigraphy. When these two detection techniques were compared, Tc99 showed a significantly higher rate of identification of sentinel lymph nodes.¹⁹ The identification of LS by SPECT-CT has also been the target of studies. The results to date suggest that this examination can increase the detection and improve the preoperative anatomic localization of LS, when compared to lymphoscintigraphy with Tc99.^{20, 21}

In relation to microinvasive disease, there are no studies only with this population, the focus of interest of the present chapter. A significant part of the works with initial cases includes patients between FIGO stages IA1 and IB1. Although current studies have shown encouraging results, SLB cannot yet be considered standard treatment for initial cases of cervical carcinoma. Its clinical impact must be demonstrated in randomized studies that compare outcomes such as disease-free survival and global survival between patients submitted to traditional pelvic lymphadenectomy and to the sentinel lymph node technique.

Certainly, one important question in the context of microinvasive carcinoma is the search for more conservative therapies with the establishment of a certain balance between uterine preservation and disease-free surgical margins. On demonstrating a lower lymph node compromise in microinvasive carcinoma, especially when there is no involvement of the lymphovascular space, this balance becomes more appropriate.

The primary treatment of cancer of the cervix and thereby of the microcarcinoma of the cervix is surgery, save exceptions of cases with clinical contraindications to surgery, where radiotherapy combined with chemotherapy and the possibility of brachytherapy are valid options. Extended radical hysterectomy with lymphadenectomy is the standard treatment for those women who do not want more children, certainly observing the considerations previously indicated, which authorize a more conservative approach. This standard treatment –radical hysterectomy– can be executed by the vaginal route, Schauta-Amreich or Schauta-Stoeckel surgery with videolaparoscopic radical pelvic lymphadenectomy, or by the abdominal route, Wertheim-Meigs surgery.

Dargent surgery, radical trachelectomy with videolaparoscopic pelvic lymphadenectomy, is indicated in young patients who wish to preserve fertility, constituting a more radical alternative than conization.²²

When the discussion of the treatment of cancer of the cervix includes specificities such as the case of microinvasion, it is also necessary to consider other specificities. In this point, we must focus on the characteristics of the disease, with the peculiarities of the stage (IA1 or IA2), of the histologic type and of the presence of invasion of the lymphovascular spaces, as well as on the characteristics of the patient, with possible clinical restrictions, with questions of preservation of fertility and with the consent of treatment options.

For the cases with stage IA1 where we did not find any evidence of involvement of the lymphovascular space, conservative treatment – by conization of the cervix –can be an acceptable option, especially for those patients who wish to preserve fertility.^{23, 24} The participation of the patient in agreement with the approach should always be pointed out; at this moment, concordance with a more radical treatment can be an option – with the choice of simple hysterectomy, for example. Current recommendations from the World Health Organization, without specification of histopathologic type, are simple hysterectomy for women with microinvasive cancer stage IA1.²⁵ Risk for recurrence after this treatment is 1% and overall 5-year survival is 99%.²⁷ When faced with compromise by tumor cells in the lymphovascular space, the indication should be major radical treatment – consisting of total hysterectomy with parametrectomy, resection of the upper third of the vagina and pelvic lymphadenectomy.

Those patients with stage IA2 have a greater potential of lymph node metastasis at this stage, which could also involve a more radical treatment. The cases where no invasion of the

lymphovascular space is observed, the complete excision of the lesion by extrafascial hysterectomy or, in selected cases and when there is desire for preservation of fertility, by conization with free margins can be an option. When fertility is not an issue, the treatment proposed here should also be considered, with an indication of hysterectomy. Alternatively, trachelectomy or radical hysterectomy can also be applied, without the need for pelvic lymphadenectomy.²⁶

As in the previously mentioned cases of involvement of the lymphovascular space, also in the cases of stage IA2, there is an indication of radical hysterectomy with pelvic lymphadenectomy. When the preservation of fertility is desired, vaginal radical trachelectomy with extra-peritoneal or laparoscopic pelvic lymphadenectomy is the option. Risk of recurrence of IA2 tumors treated with radical hysterectomy and bilateral pelvic lymphadenectomy is 3-5% and overall 5-year survival is 96%.²⁷

6. Follow-up

After treatment, the patients should have a regular periodic follow-up with clinical gynecologic examinations, oncotic colposcopy and colposcopy. Follow-up protocols after the conclusion of the initial treatment are variable, using a number of tests in a variety of intervals with debatable results. The components that should be considered for an ideal follow-up program are: (i) optimal interval for the follow-up; (ii) available tests for follow-up; (iii) modifications in the course of the follow-up in accordance with the risk of recurrence identified in the primary treatment.


The tests available for the follow-up are the following: anamnesis, physical examination, cervical cytology, ultrasonography, magnetic resonance, computed tomography, positron emission tomography (PET) and tumor markers. Physical examination and vaginal cytology are the most commonly used methods in the follow-up. The physical examination, especially, has led to a considerable number of detections in patients in which cyto-detection was low. To date, there is little definitive evidence of the most suitable strategy for follow-up (for patients clinically free of disease after primary treatment). Therefore, it is important that the patient have some understanding to facilitate the follow-up. Among these, general symptoms such as weight loss, loss of appetite, fatigue, pain, cough, dyspnea, confusion, and edema of legs (mainly unilateral), beside local symptoms such as bleeding and vaginal, vesical or anal secretion, distension or abdominal pain.²⁸

The periodicity recommended for the doctor visits is as follows: 3 to 4 months in the first 2 years; every 6 months for the next 3 years; and annually after this period, maintaining a follow-up for 10 years.

7. References

- [1] Mestwerdt G. Zentralbl Gynakol 1947; 69:198-202
- [2] Creasman W. New gynecologic cancer staging. Gynecol Oncol 1995;58:157-8
- [3] FIGO. Int J Gynecol Oncol 2009; 105:103-4.
- [4] Choo YC, et al. Br J Obstet Gynecol 1984; 91:1156-60
- [5] Figueiredo PG, et al. RBGO 2003; 24:37-43
- [6] Hopman EH, et al. Aus N Z J Obstet Gynaecol 1998, 53:97-106

- [7] Reich O, Pickel H, Tamussino K, Winter R. Microinvasive carcinoma of the cervix: site of the first focus invasion. *Obstet Gynecol* 2001; 97:890-2.
- [8] Lee KBM, et al. *Int J Gynecol Cancer* 2006, 16:1184-1187
- [9] Ostor AG: Pandora's box or Ariadne's thread? Definition and prognostic significance of microinvasion in the uterine cervix: squamous lesions. *Pathology Annual* 1995; 103-136
- [10] Roche WD & Norris HJ. 1975
- [11] Biewenga P, Van der Velden J, Mol BW, et al. Prognostic model for survival in patients with early stage cervical cancer. *Cancer* 2011;117:768-76.
- [12] Matsuura Y, Kawagoe T, Toki N, Tanaka M, Kashimura M. Long-standing complications after treatment for cancer of the uterine cervix—clinical significance of medical examination at 5 years after treatment. *Int J Gynecol Cancer* 2006;16:294-7.
- [13] Rogers, Linda J. MMed, FCOG; Luesley, David M. MA, MD, FRCOG. Stage IA2 Cervical Carcinoma: How Much Treatment Is Enough?. *International Journal of Gynecological Cancer*. 19(9):1620-1624, December 2009.
- [14] Sevin BU, Nadji M, Averette HE, Hilsenbeck S, Smith D, Lampe A. Microinvasive carcinoma of the cervix. *Cancer* 1992 ;70:2121-8.
- [15] Cabanas RM: An approach for the treatment of penile carcinoma. *Cancer* 39:456-466, 1977
- [16] Robison K, Holman LL, Moore RG. Update on sentinel lymph node evaluation in gynecologic malignancies. *Curr Opin Obstet Gynecol*. 2011 Feb;23(1):8-12.
- [17] Darlin L, Persson J, Bossmar T, et al. The sentinel node concept in early cervical cancer performs well in tumors smaller than 2 cm. *Gynecol Oncol* 2010; 117:266-269
- [18] LeCuru F, Mathevet P, Querleu D, et al. Bilateral negative sentinel nodes accurately predict absence of lymph node metastasis in early cervical cancer: results of the SENTICOL study. *J Clin Oncol* 2011;29:1686-91
- [19] Roy M, et al, Value of sentinel node mapping in cancer of the cervix, *Gynecol Oncol* (2011), doi:10.1016; 2011.04.002
- [20] Martinez A, Zerdoud S, Mery E, Bouissou E, Ferro G, Querleu D. Hybrid imaging by SPECT/CT for sentinel lymph node detection in patients with cancer of the uterine cervix. *Gynecol Oncol*. 2010;119(3):431-5.
- [21] Pandit-Taskar N, Gemignani ML, Lyaal A, Larson SM, Barakat RR, Abu Rustum NR. Single photon emission computed tomography SPECT-CT improves sentinel node detection and localization in cervical and uterine malignancy. *Gynecol Oncol*. 2010 Apr;117(1):59-64.
- [22] Querleu D, Childers JM, Dargent D. *Laparoscopic Surgery in Gynecological Oncology*. Oxford: Blackwell Science, 1999.
- [23] Stehman FB, Rose PG, Greer BE, Roy M, Plante M, Penalver M et al. Innovations in the treatment of invasive cervical cancer. *Cancer* 2003;98(9 Suppl):2052-63.
- [24] Kesic V. Management of cervical cancer. *Eur J Surg Oncol* 2006;32(8):832-7.
- [25] *Comprehensive cervical cancer control: a guide to essential practice*. WHO Press. Geneva, Switzerland. 2006. pp179-181.
- [26] Creasman WT, Zaino RJ, Major FJ, DiSaia PJ, Hatch KD, Homesley HD. Early invasive carcinoma of the cervix (3 to 5 mm invasion): risk factors and prognosis. A Gynecologic Oncology Group study. *Am J Obstet Gynecol* 1998;178:62-5.
- [27] Benedet JL, Odicino F, Maisonneuve P, et al. Carcinoma of the cervix uteri. *Int J Gynaecol Obstst* 2003;83(Suppl 1):41-78.
- [28] Elit L, Fyles AW, Devries MC, Oliver TK, Fung-Kee-Fung M; Gynecology Cancer Disease Site Group. Follow-up for women after treatment for cervical cancer: a systematic review. *Gynecol Oncol*. 2009 Sep;114(3):528-35. Epub 2009 Jun 26.



Topics on Cervical Cancer With an Advocacy for Prevention

Edited by Dr. R. Rajamanickam

ISBN 978-953-51-0183-3

Hard cover, 284 pages

Publisher InTech

Published online 02, March, 2012

Published in print edition March, 2012

Cervical Cancer is one of the leading cancers among women, especially in developing countries. Prevention and control are the most important public health strategies. Empowerment of women, education, "earlier" screening by affordable technologies like visual inspection, and treatment of precancers by cryotherapy/ LEEP are the most promising interventions to reduce the burden of cervical cancer. Dr Rajamanickam Rajkumar had the privilege of establishing a rural population based cancer registry in South India in 1996, as well as planning and implementing a large scale screening program for cervical cancer in 2000. The program was able to show a reduction in the incidence rate of cervical cancer by 25%, and reduction in mortality rate by 35%. This was the greatest inspiration for him to work on cervical cancer prevention, and he edited this book to inspire others to initiate such programs in developing countries. InTech - Open Access Publisher plays a major role in this crusade against cancer, and the authors have contributed to it very well.

How to reference

In order to correctly reference this scholarly work, feel free to copy and paste the following:

Fernando Anschau, Chrystiane da Silva Marc, Maria Carolina Torrens and Manoel Afonso Guimarães Gonçalves (2012). Microinvasive Carcinoma of the Cervix, Topics on Cervical Cancer With an Advocacy for Prevention, Dr. R. Rajamanickam (Ed.), ISBN: 978-953-51-0183-3, InTech, Available from: <http://www.intechopen.com/books/topics-on-cervical-cancer-with-an-advocacy-for-prevention/microinvasive-carcinoma-of-the-cervix>

INTECH
open science | open minds

InTech Europe

University Campus STeP Ri
Slavka Krautzeka 83/A
51000 Rijeka, Croatia
Phone: +385 (51) 770 447
Fax: +385 (51) 686 166
www.intechopen.com

InTech China

Unit 405, Office Block, Hotel Equatorial Shanghai
No.65, Yan An Road (West), Shanghai, 200040, China
中国上海市延安西路65号上海国际贵都大饭店办公楼405单元
Phone: +86-21-62489820
Fax: +86-21-62489821

© 2012 The Author(s). Licensee IntechOpen. This is an open access article distributed under the terms of the [Creative Commons Attribution 3.0 License](#), which permits unrestricted use, distribution, and reproduction in any medium, provided the original work is properly cited.

IntechOpen

IntechOpen