

We are IntechOpen, the world's leading publisher of Open Access books Built by scientists, for scientists

4,800

Open access books available

122,000

International authors and editors

135M

Downloads

Our authors are among the

154

Countries delivered to

TOP 1%

most cited scientists

12.2%

Contributors from top 500 universities



WEB OF SCIENCE™

Selection of our books indexed in the Book Citation Index
in Web of Science™ Core Collection (BKCI)

Interested in publishing with us?
Contact book.department@intechopen.com

Numbers displayed above are based on latest data collected.
For more information visit www.intechopen.com



Ultrasound Guided Hip Injection Techniques

Micu Mihaela Cosmina
*Rehabilitation Clinical Hospital Cluj, Rehabilitation Department II,
Rheumatology Division
Romania*

1. Introduction

Current development of medical practice has shown that imaging-guided interventional invasive techniques are superior to blind manoeuvres. Moreover, a safe nonradiant and cheap imaging guidance method is always preferred (Aliabadi P et al., 1988; Ozonoff MB, 1973; Sofka CM et al., 2005; Picano & Matucci Cerinic, 2010). In addition to its primary use as a very useful diagnostic tool and natural extension of the clinical examination, musculoskeletal ultrasound is now frequently used in clinical rheumatological practice for guiding interventional manoeuvres.

Interventional musculoskeletal ultrasound guided manoeuvres refer to a variety of invasive procedures performed percutaneously covering diagnostic as well as therapeutic injection of joints, tendon sheaths or other peri-articular structures up to more complex manoeuvres like biopsies, removal of foreign bodies and intratumoral therapeutic injections.

Ultrasonography has a very important advantage over other imaging methods because it allows the concomitant visualization of the target structure, the needle penetration and tip positioning as well as the drug deposition (Bradley MJ, 2001). Indeed, musculoskeletal ultrasound evaluation is an accurate and reliable method in depicting articular and periarticular lesions, has no radiation, is cheap and quick to perform and allows repeated examinations at baseline and during follow up (Bierma-Zeinstra et al., 2001; Koski JM et al., 1989; Iagnocco A et al., 2006; Qvistgaard E et al., 2001). Moreover, a modular flexible training strategy to achieve competence in diagnostic as well as in interventional musculoskeletal ultrasound showed a fast learning curve among rheumatologists, thus encouraging its employment in daily practice (Atchia I et al., 2007).

Hip joint pathology is very frequently encountered in clinical practice. Hip joint pain is the main symptom generated by several pathological conditions including primary osteoarthritis (OA), inflammatory diseases like rheumatoid arthritis, spondylarthropaties, crystal deposition diseases as well as congenital and traumatic disorders with potential evolution to secondary OA.

Recently, several studies have shown an increase in the general population of hip OA incidence in parallel with an increase of obesity incidence and higher life expectancy worldwide. Chronic hip pain on walking is the most important factor impacting on patient quality of life and is complicated by functional disability due to structural damage. The management of hip pain is therefore burdened by long term high treatment costs. In fact, the increasing number of total hip replacements with elevated surgery costs and prolonged

rehabilitation procedures are challenging the health care systems all over the world (Birrell F et al., 2003; Brooks PM, 2006). For this reason, various diagnostic and treatment strategies are continuously tested in order to obtain maximum efficacy and minimize the total management costs .

In the outpatient rheumatological setting, diagnostic aspiration and therapeutic intra-articular hip joint injections are frequently required. In fact, the guided aspiration of the fluid from the coxofemoral joint is of paramount importance to obtain laboratory analyses (microscopy-culture and Gram stain) that may rapidly differentiate septic arthritis from other inflammatory joint conditions like rheumatoid arthritis, spondylarthropathies and crystal deposition diseases. Other imaging techniques do not differentiate a septic effusion from other kind of effusions because of the non-specific appearance. (Foldes K et al., 1995)

The current Osteoarthritis Research Society International (OARSI) and Assessment of SpondyloArthritis International Society (ASAS) / European League Against Rheumatism (EULAR) therapeutic guidelines include hip corticosteroid injection, which is still a rare therapeutic approach because standardized criteria for patients selection are still missing and because of the small number of performing physicians. These are clear limitation in using the method. (Zhang W et al., 2005, 2008) On the other hand, the use of intraarticular hip viscosupplementation is still under study because of the low number of existing trials, most of them with contradictory results and is still waiting for approval in some countries. (Migliore A et al., 2004; Qvistgaard E et al., 2006; Richette P et al., 2009)

It is well known that deep joints, like the hip, are difficult to reach and inject and therefore require imaging guided needle techniques that are currently preferred to the blind injections guided only by anatomical landmarks. In fact, musculoskeletal ultrasound guided technique allows a correct needle penetration (avoiding neurovascular structures injury), joint aspiration, and a more accurate drug deposition which assures a higher efficacy. (Leopold SS et al., 2001 ; Iagnocco A & Naredo E , 2010; Naredo E et al., 2005)

The first data about the use of musculoskeletal ultrasound guided hip aspiration of synovial fluid were reported by Komppa in 1985. (Komppa GH et al., 1985) Ultrasound guided injections were introduced much later in clinical trials and practice, when it became evident that joint ultrasound facilitates a quick, accurate diagnosis and operative safe local treatment showing extraordinary advantages over the other imaging techniques. Despite several efforts made in many countries to implement the invasive musculoskeletal ultrasound guided techniques as a part of the rheumatology curriculum, this procedure still remains insufficiently exploited among rheumatologists.

The aim of this chapter is to describe the basic techniques of the ultrasound guided hip joint injection and to update the therapeutic standards, indications and contraindications, efficacy and safety of the method.

2. Anatomy of the hip

The hip is a “ball and socket” synovium lined joint between the spherical femoral head covered by hyaline articular cartilage and the cup- shaped acetabulum. The capsule, superficially reinforced in the anterior aspect by the ilio- femoral ligament and covered by synovial tissue, extends around the joint attaching superiorly to the acetabulum and labrum and inferiorly to the intertrochanteric area. The deep synovial layer reflects back from the intertrochanteric area to the head neck junction delineating the anterior joint recess. The ilio- psoas muscle is superficial to the anterior aspect of the capsule.

3. Sonoanatomy, patient position and scanning technique

To perform an ultrasound guided procedure, the patient should be supine with the heels together and slightly (10-20 °degrees) externally rotated legs. The examination is performed with a low frequency 3.5- 7.5 MHz linear array probe or a convex one (2.5-5 MHz) for obese or muscular patients, following EULAR ultrasound evaluation guidelines with multiplanar structure scanning, in grey scale and Doppler mode. (Iagnocco A & Naredo E, 2010; Leopold SS et al., 2001; Naredo E et al., 2005; Qvistgaard E et al., 2006) The anterior longitudinal view as well as the transversal one are fundamental.

The anterior (superior collicular recess) and the supero- anterior recesses are the most important in musculoskeletal ultrasound assessment because of the sensitivity in depicting synovitis. (Backhaus M et al., 2001; Iagnocco A et al., 2006; Qvistgaard E et al., 2001) Femoral neuro- vascular structures are located medial to the joint and easily depicted in transversal view. (Figures 1, 2)

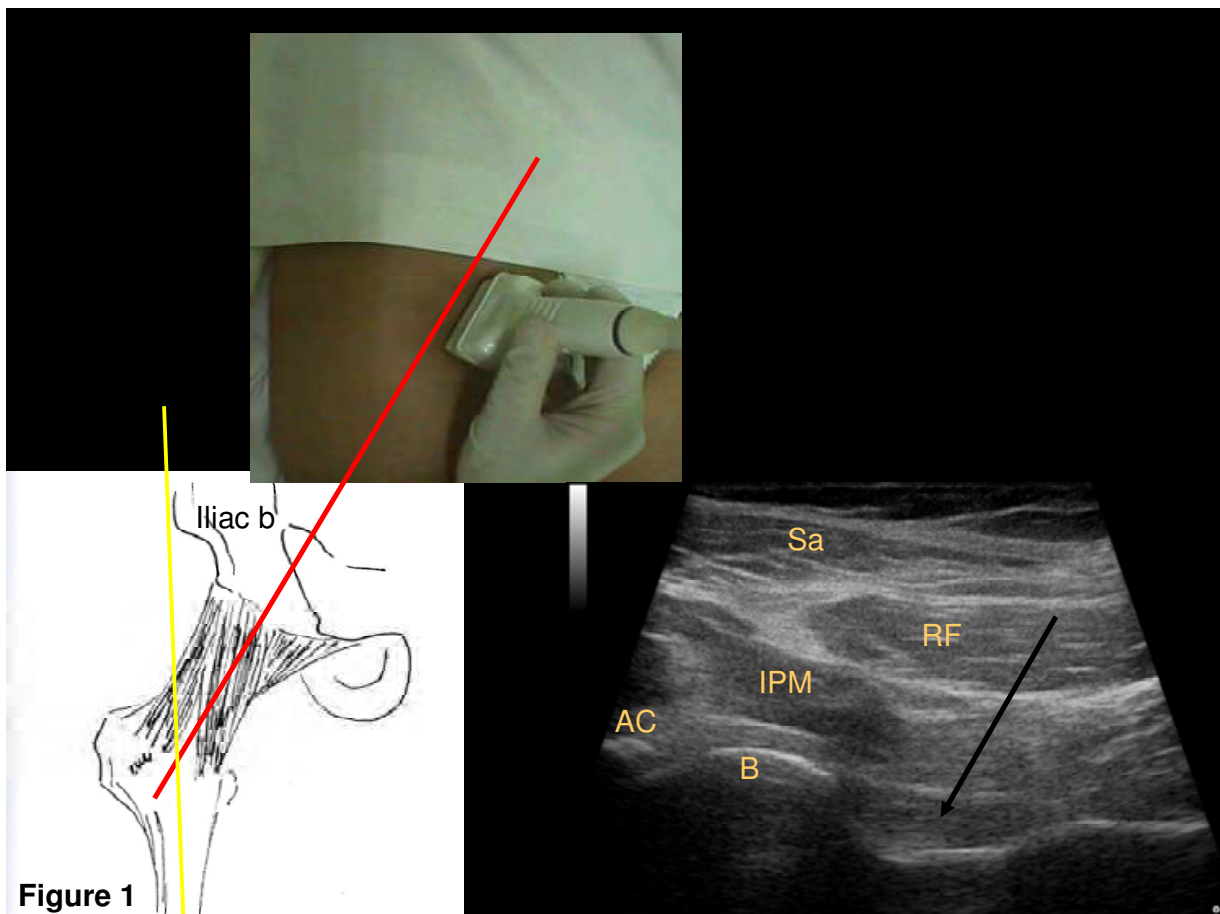


Figure 1. Anterior longitudinal scanning and view of the hip. Patient photo in scanning position and correct position of the probe; drawing of the hip region showing the probe position parallel to the femoral neck (red line); sonoanatomy of the hip in trapezoidal view- anterior joint recess (black arrow). Legend: B- bone (femoral head), AC- acetabulum, RF- rectus femoris muscle, IPM- ilio-psoas muscle, Sa- sartorius muscle, Iliac b- iliac bone.

4. Ultrasound guided hip injection

Generally, two types of US joint injection techniques may be performed: an indirect method (half blind) and a real time procedure which may be further divided in a “hand free” technique and a device guided one.

4.1 Indirect method

The indirect method uses ultrasound for establishing the puncture site, the depth of the target structure but without following the needle penetration. After performing two perpendicular scans, the site of the needle insertion is marked with a skin marking pen and the dept of the target is measured with the ultrasound machine callipers. After the probe removal and proper skin disinfection, the needle is perpendicularly inserted progressing blindly up to the depth previously measured, followed by aspiration and/or drug injection. The blind injection, despite previous imaging location of the target structure, may expose to inaccurate needle positioning. (Cantini F et al., 2005)

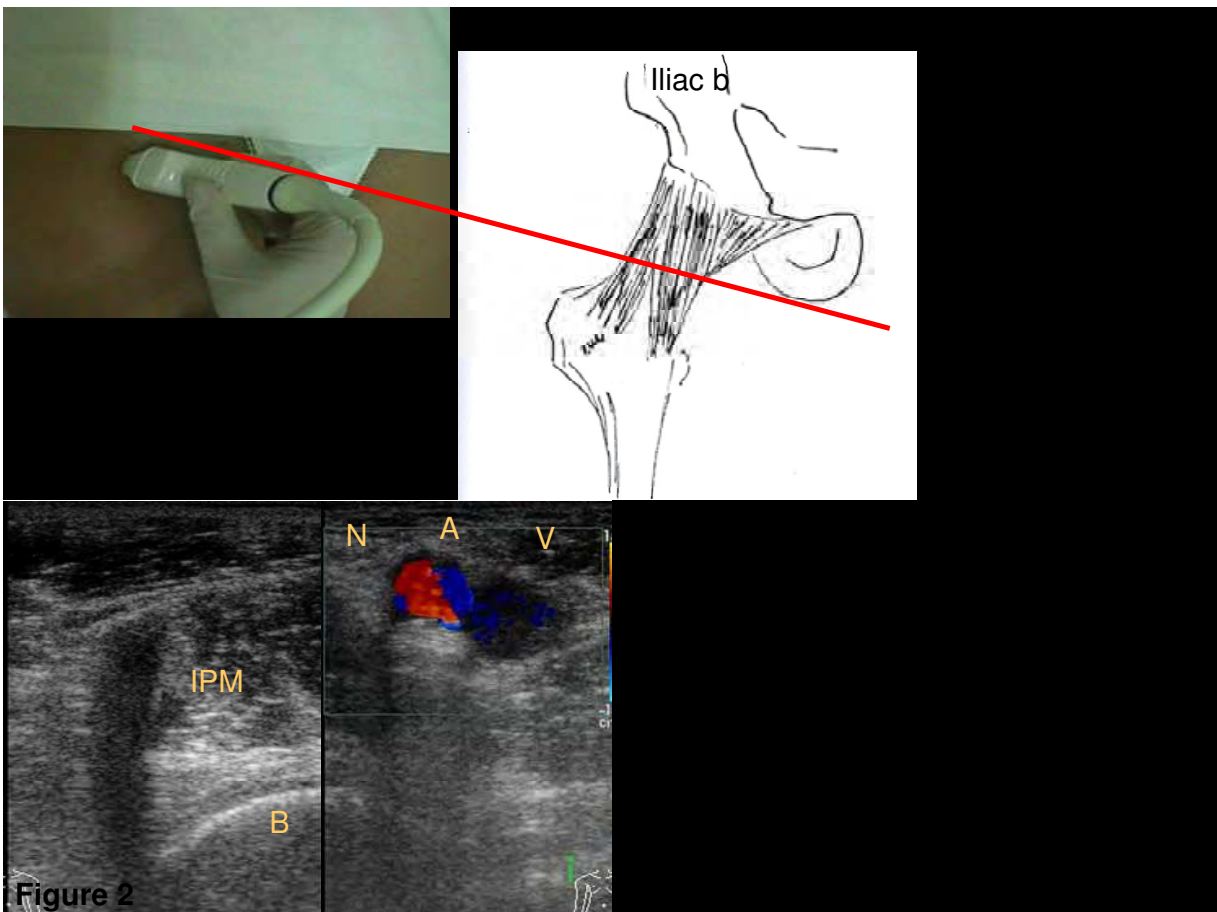


Fig. 2. Anterior transversal scanning and view of the hip. Patient photo and correct position of the probe perpendicular to the femoral neck (red line); drawing of the hip region and sonoanatomy of the hip. Medial to the joint (right side of the ultrasound image), the neurovascular structures can be recognized. Legend: B- bone, IPM- ilio-psoas muscle, N- femoral nerve, A- femoral artery, V- femoral vein, iliac b- iliac bone.

4.2 Real time method

With the real time injection methods, the probe is placed in close proximity of the puncture site and the progression of the needle is followed having direct ultrasound control of the position and depth.

4.2.1 Device guided technique

The device guided technique is used less frequently in clinical practice because of the supplementary cost of the biopsy device and further sterile preparation before each puncture manoeuvre. Instead, the penetration of the needle is more precisely and easier to use even for beginners in the field of invasive guided manoeuvres, the insertion of the needle is made always from the lateral side of the probe, in older models. Attachable guiding kits are easier to use and became more popular in the last years. The procedure can be easily performed by a single person, but the method has a certain limitation due to the fixed angle relative to the transducer.

4.2.2 Hand free technique

The "hand free" technique requires more experienced practitioners but is more flexible, allows multiple angle repositioning of the probe and may allow, if necessary, to redirect the needle during the manoeuvre. The site of needle insertion can be placed in fact anywhere in relation with the probe and allows the choice of the most convenient position for the performing doctor. The method is performed usually by two or, more rarely, by a single physician but is burdened by higher learning costs.

5. Approach to the hip joint

Nowadays, two real time musculoskeletal ultrasound guided hip injection approaches are used (Migliore A et al., 2001, 2004). The *longitudinal antero-inferior* approach, suggested mostly for aspiration of synovial fluid and corticosteroid deposition and the *longitudinal antero-superior* approach having the femoral head as target, proposed for viscosupplementation drug deposition.

As a rule, before starting the interventional procedure, an ultrasound evaluation of the hip joint must be repeated in order to reconfirm the diagnostic selection criteria for the invasive manoeuvre and to choose the most appropriate approach. An adequate but also comfortable scanning position is required for the patient as well as for the doctor.

6. Written consent of the patient

The patient must be informed about the injection indication, about potential side effects or complications and must sign a written consent.

7. Antiseptic rules

All puncture techniques must fulfil the antiseptic rules. After wearing of sterile gloves, the preparation of the skin above the hip with iodine or chlorhexidine gluconate is made. In addition to these requests, a large variation in using supplementary antiseptic methods is present among doctors. Some use a sterile condom to isolate the transducer followed by application of sterile gel on the scanning area. The needle insertion is possible

through it. Other practitioners prefer nonsterile gel commonly used for musculoskeletal ultrasound evaluations, with application strictly under the probe footprint and needle insertion at a distance of 1-2 cm from the transducer margin through previous disinfected skin surface.

8. Visualisation of the needle

The progression of the needle through different tissue layers (fat tissue, rectus femoris and ilio- psoas muscle, capsule) can be followed if it is kept inside the ultrasound beam, with maximum accuracy if the penetration direction is perpendicular to the ultrasound beam. When linear array probes are used in standard view, the horizontal position of the needle allows a better visualisation of the progression in the tissues but in deep structures, like the hip joint, it is impossible to position the needle horizontal. The use of very long needles has a breaking risk during tissue penetration. Today, new developed steering based imaging techniques obtained by activating consecutive elements in the linear array are now able to generate oblique lines of sights along the dept axis creating the trapezoid shaped image display. In this case, due to the characteristics of the ultrasound beam or by using curvilinear probes, the 45° up to 60° degree angulation of the needle obtains good visualisation of the needle position. In clinical practice, it is proven that the visualisation of the relationship between the needle tip and target structure is more important in comparison to the visualisation of the entire needle body.

For aspiration, spinal-needle gauge 18-20 are used, while for injection only, a 22 gauge needle is sufficient. For better visualisation due to increased reflectivity, some performing physicians scratch the needle surface with a sterile scalpel and keep the mandrin inside while inserting the needle. (Sofka CM et al., 2005)

9. Artifacts

Some artefacts, like anisotropy can occur, creating difficulties in needle visualisation. This artefact may appear when the needle is not strictly perpendicular to the ultrasound beam: in this case, the needle is not visualised as a shiny hyperechoic line but it appears as a hypo-anechoic line. Also the comet tail artefact characteristic for the needle insertion in a fluid collection can be very much attenuated while penetrating a solid structure. Some practitioners activate the Doppler mode while penetrating the skin and underlying layers to follow the needle tip up to the bony cortex. (Hamper UM et al., 1991)

10. Hip injection techniques

10.1 Antero- inferior longitudinal approach

The *antero- inferior longitudinal* approach is designed for hip aspiration of the anterior recess content in inflammatory or septic conditions as well as for corticosteroid injections in cases of synovitis refractory to traditional treatment. (Iagnocco A et al., 2006; Micu MC et al., 2010; Zhang W et al., 2005, 2008)

In our daily practice, the “free hand” technique is used with the following steps: the patient lays in supine position and legs slightly external rotated , the image of the hip is obtained in longitudinal view (probe placed parallel to the femoral neck and lateral to the femoral neuro- vascular structures) and transversal view for the last check. After proper disinfection

of the area, the image is obtained in longitudinal view by placing nonsterile gel exactly under the probe footprint, the needle is inserted 2 cm from the distal part of the probe with an angle of 45° degrees to the horizontal skin plane having as target the head neck junction. The needle insertion can be traced from the moment it enters in the ultrasound beam, approximately 1 cm below the skin, through the fat tissue, rectus femoris and ilio-psoas muscle, capsule up to the bone. (Figure 3, 4)

IntechOpen

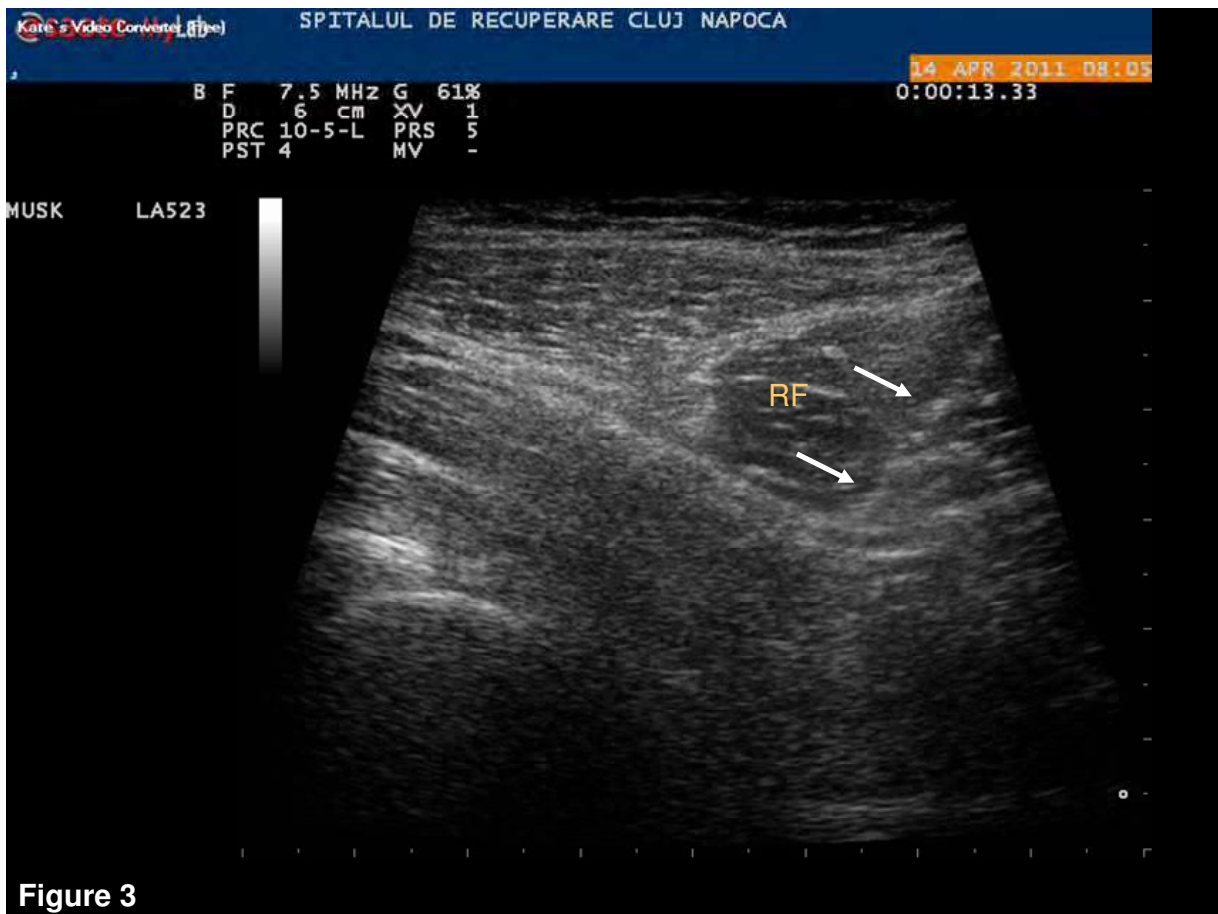

Figure 3. Anterior longitudinal view of the hip; visualisation of the needle as a hyperechoic line penetrating the rectus femoris muscle (white arrows)

IntechOpen

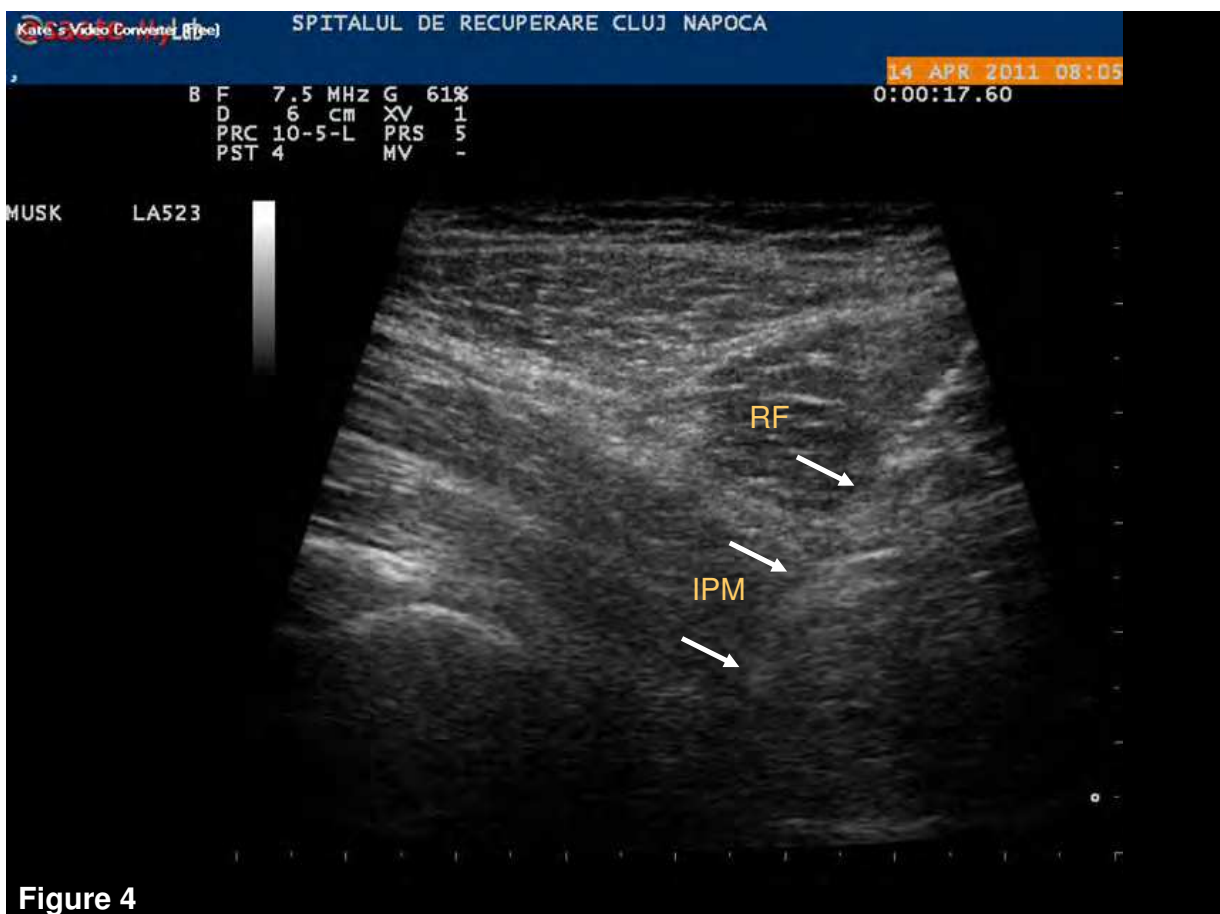


Fig. 4. Anterior longitudinal view of the hip; visualisation of the needle as a hyperechoic line penetrating the rectus femoris and ilio-psoas muscle (white arrows)

After bony cortex contact, the needle is retracted 3-4 mm in order to avoid engaging the tip in the posterior synovial layer and facilitate the tip placement inside the anterior joint recess. In this position, the effusion can be aspirated and/ or corticosteroids can be injected. (Micu MC et al., 2010) (Figures 5, 6, 7)

IntechOpen

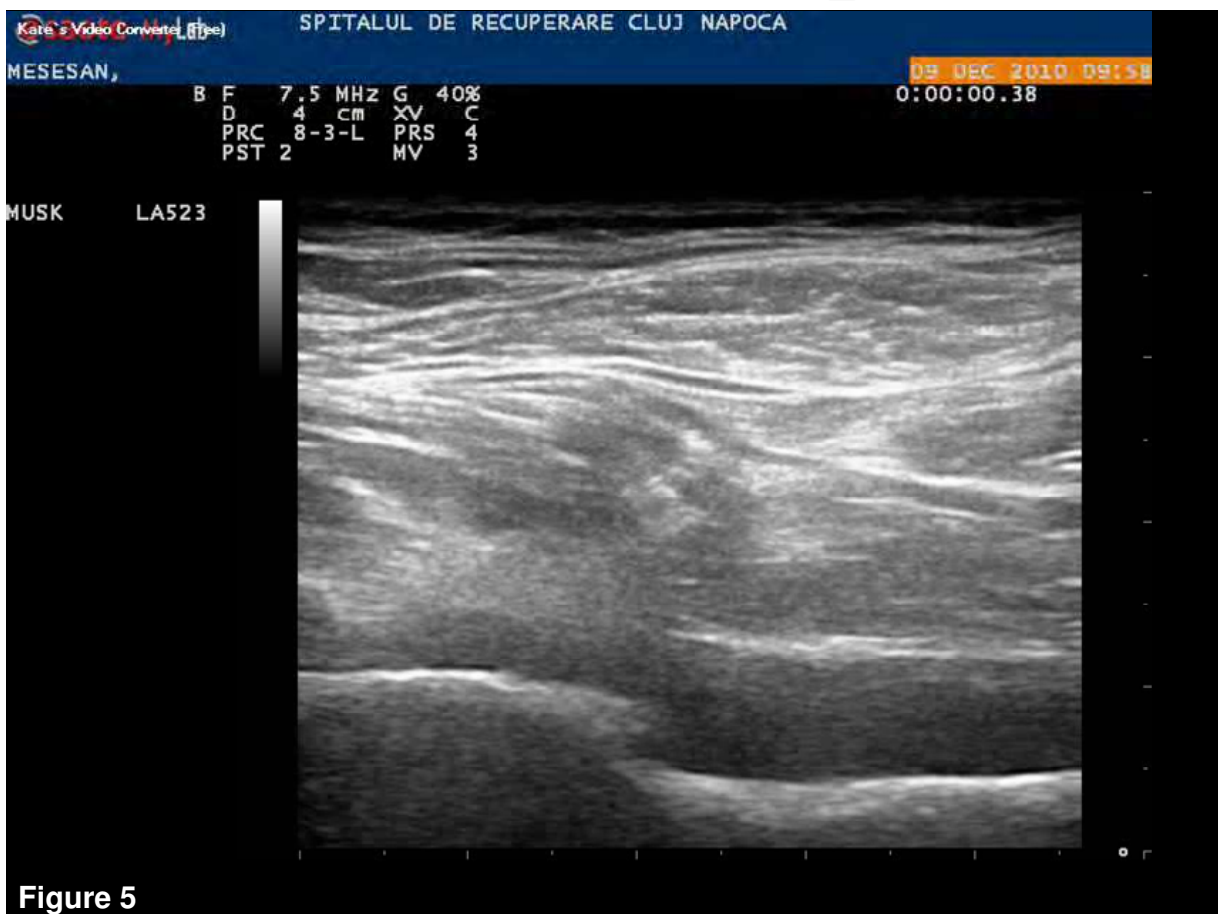


Figure 5

Fig. 5. Anterior longitudinal view of the hip; irregularities of the bony cortex and synovitis with capsule distension can be seen.

IntechOpen

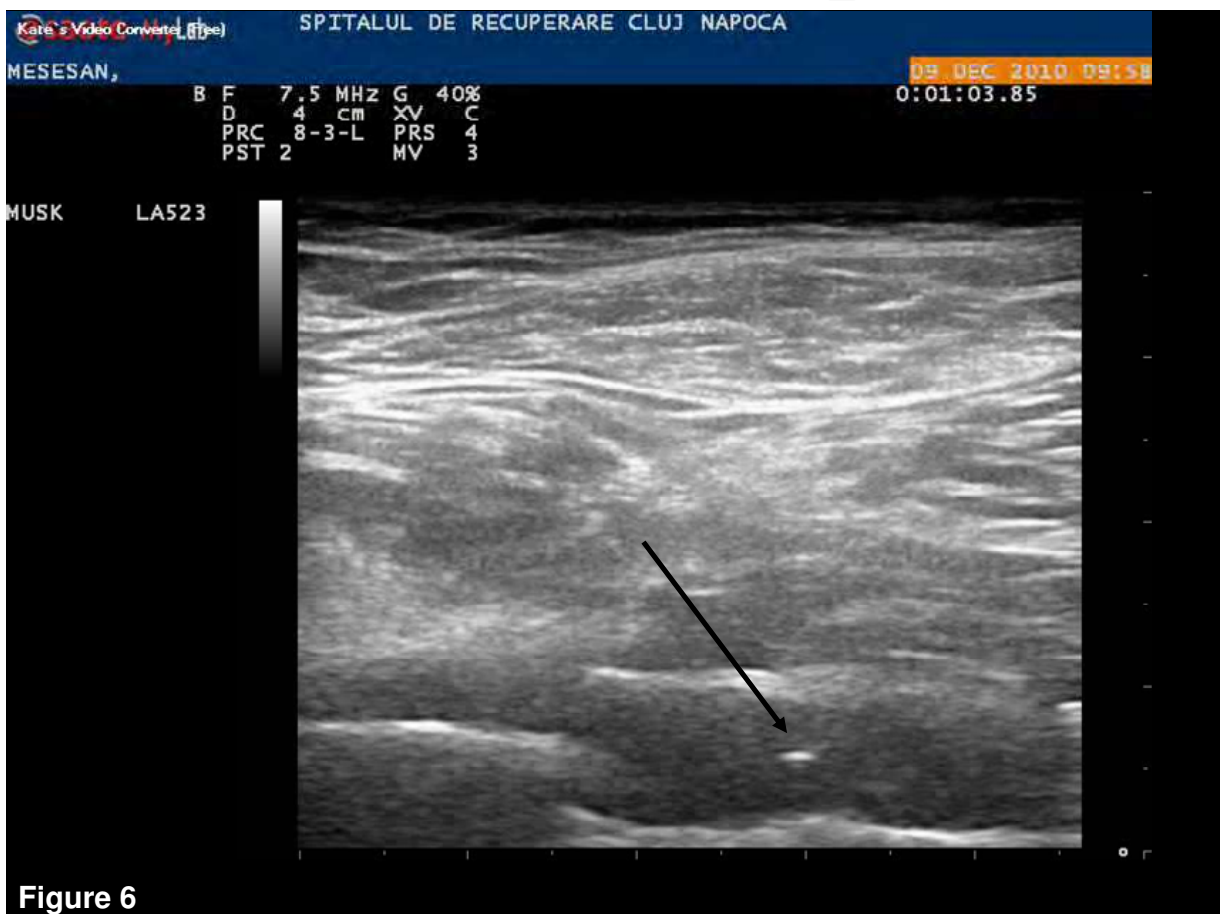

Figure 6. Anterior longitudinal view of the hip; the needle tip can be identified as a hyperechoic dot inside the anterior recess (black arrow).

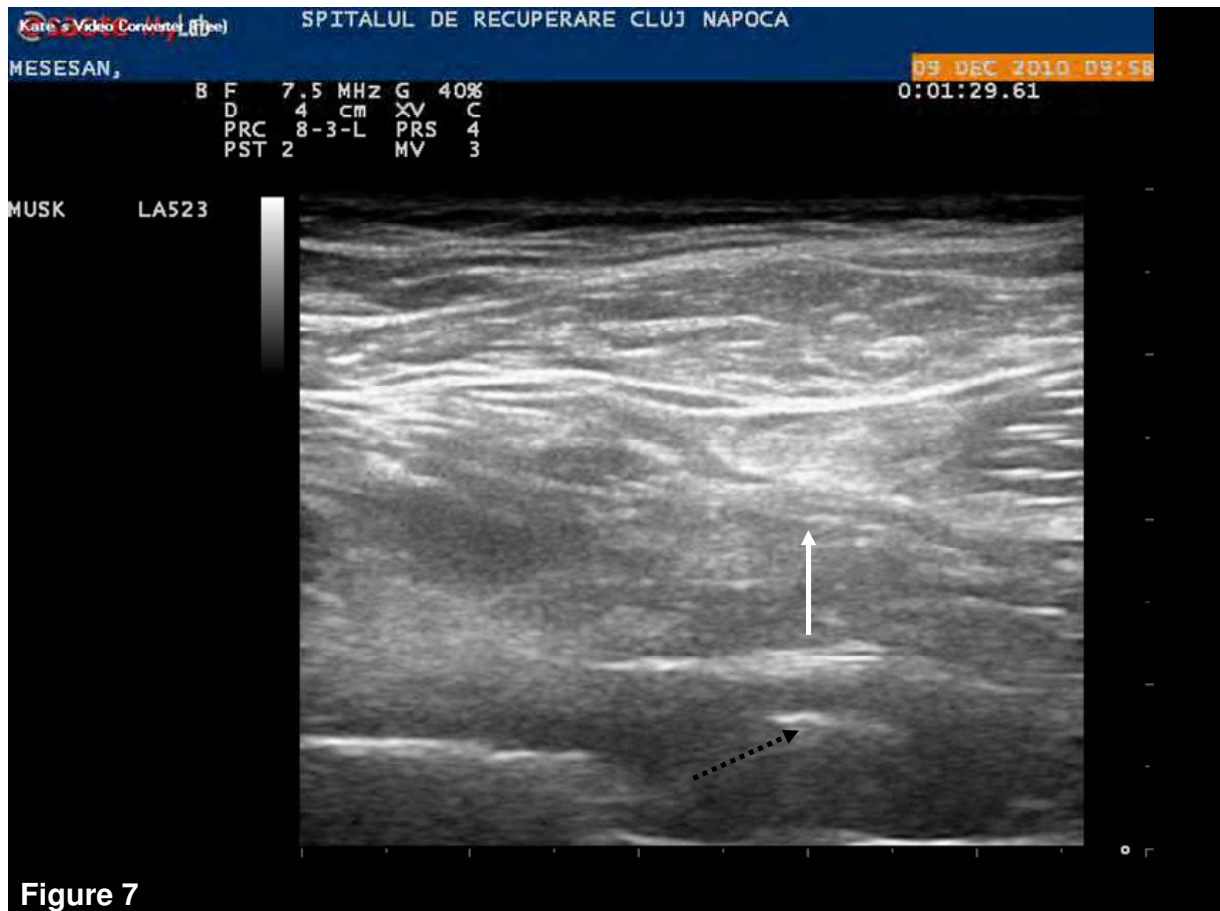

Figure 7. Anterior longitudinal view of the hip; visualisation of the corticosteroid drug as a hyperechoic mass while being injected (black punctured arrow); distension of the capsule after corticosteroid deposition in direction of the white arrow.

It is extremely important to visualize the progression of the needle through the capsule because sometimes this structure can become very thick after repeated inflammatory episodes, giving the sensation of bony contact inducing subsequent extracapsular drug deposition. A potential advantage of the *antero- inferior longitudinal* approach is the anatomical position of the ilio- femoral ligament with an inverted “Y” shape so that the needle can be inserted between the two ligament branches, in a thinner part of the capsule. This allows a less traumatic perforation.

The aspiration of hip effusions is possible only in some cases, partly explicable due to its gravitational movement inside the recess while laying supine (Iagnocco A et al., 2006; Micu MC et al., 2010). The injection of different corticosteroid products alone or with Lidocaine, with or without a small amount of air, is visualized in real time as a growing hyperechoic mass generated by the injected drug crystals and air bubbles creating the reverberation and ring down artifacts. The detection of the antigravitational movement of the drugs in the supero- anterior recess is also possible. (Figures 8, 9)

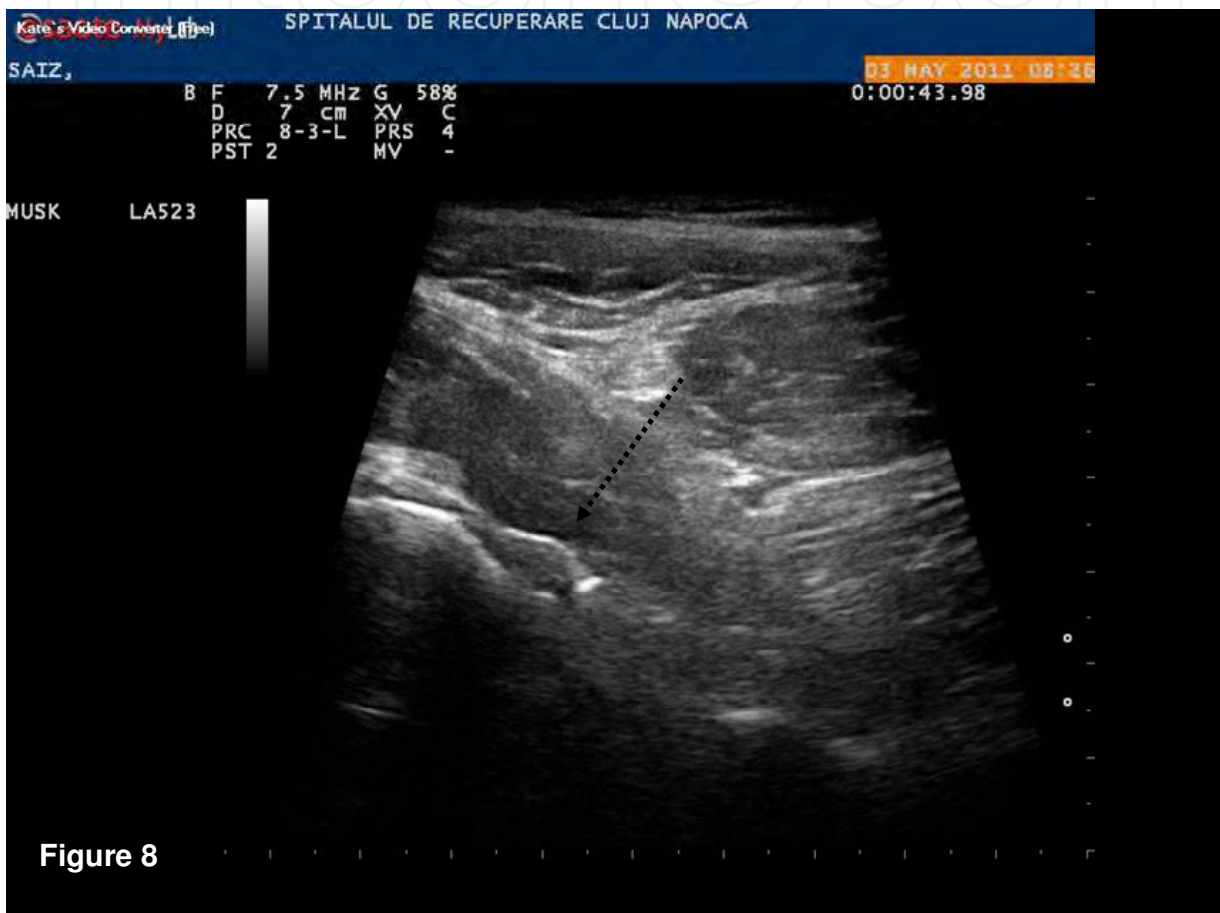

Fig. 8. Anterior longitudinal view of the hip- trapezoidal view; progressive antigravitational movement of the corticosteroid drug after intraarticular deposition (black punctured arrows) at the beginning of the injecting manoeuvre.

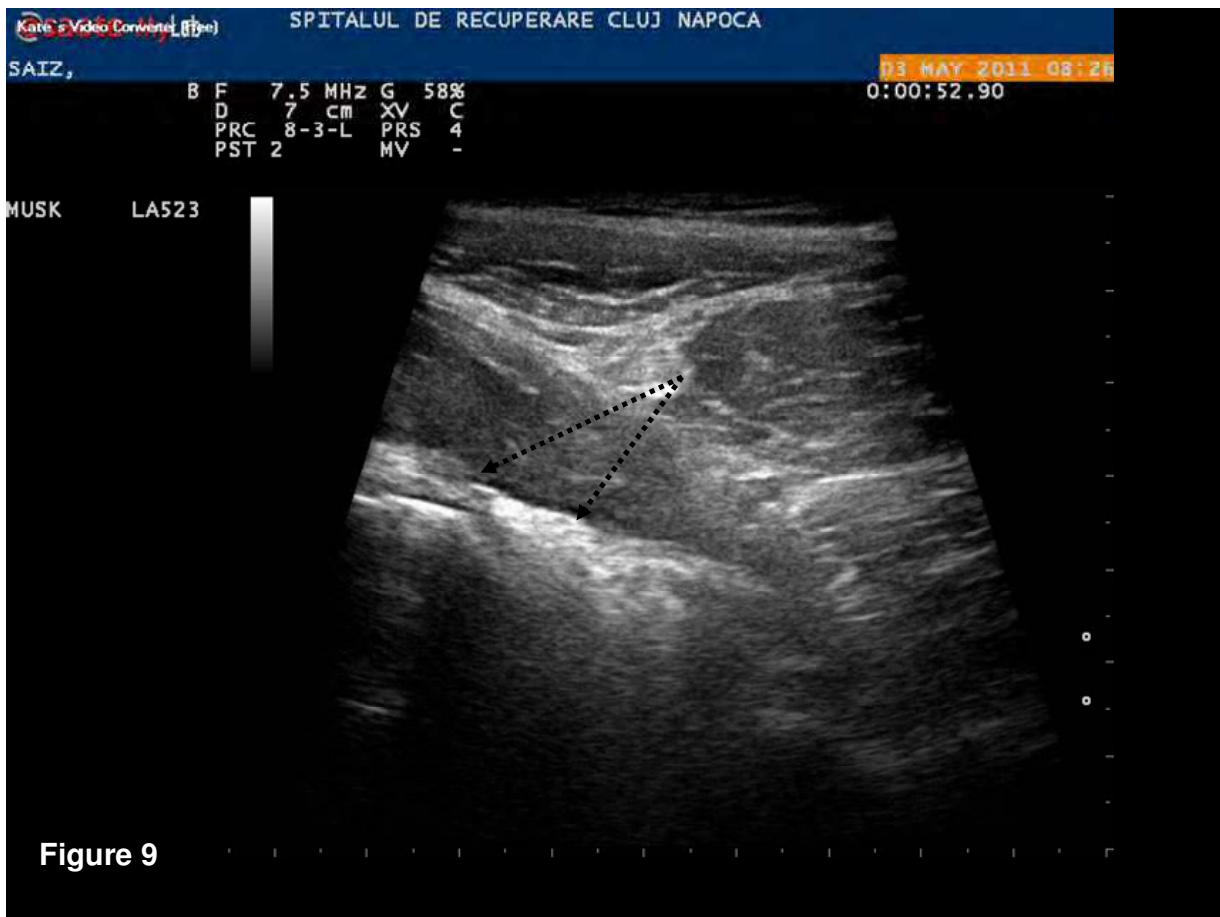

Figure 9

Fig. 9. Anterior longitudinal view of the hip- trapezoidal view; progressive antigravitational movement of the corticosteroid drug after intraarticular deposition generating comet tail artefact and partially blocking the ultrasound beam penetration (black punctured arrows), at the end of the injecting manoeuvre.

Sometimes, hyperechoic traces of CS can be visualized while retracting the needle, indicating the direction of previous needle penetration. Some authors suggest to flush the syringe and needle with lidocaine or saline solution at the end of the injection avoiding the reflux of corticosteroids into the shaft during the retraction of the needle (Bianchi , 2007).

10.2 Antero- superior longitudinal approach

The *antero- superior longitudinal* approach is used mainly for viscosupplementation products injection and allows deposition of the drug as close as possible to the femoral cartilage (Migliore A et al., 2004). It is not known if there is a real benefit of this kind of drug deposition and if the drug remains in the cartilage proximity after the patients regain vertical position. Other authors use also the antero- inferior approach for viscosupplementation drug deposition. (Qvistgaard E et al., 2006) The position of the patient, the scanning technique, and skin preparation procedure follow the same steps as described before and a spinal puncture needle of 22 gauge is inserted usually using a biopsy guiding device. The needle is introduced inside the anterior capsular recess at the level of the femoral head and after femoral head contact, retraction of the needle tip of 1 mm is requested and drug is injected under direct visualisation of the drug in grey scale or Doppler.

11. Patients selection criteria

The physician must be aware of the current selection criteria for diagnostic and therapeutic hip injection. For diagnostic purposes, aspiration of hip synovial fluid is important for differentiating septic arthritis from other inflammatory joint involvement, especially in monoarthritis. Aspiration can be of benefit also due to mechanical decompression and cleaning of the joint recess by pathologic fluid removal.

11.1 Corticosteroid intraarticular hip injection

The selection for corticosteroid hip intraarticular injection is made for patients with symptomatic hip OA, refractory to conventional pain killers, with synovitis and sometimes also for patients with advanced OA with contraindication for total hip replacement. (Kruse DW, 2008)

11.2 Intraarticular hip viscosupplementation

Hip intraarticular viscosupplementation is recommended in patients refractory to other non-invasive-nonsurgical treatment options, not yet candidates for hip replacement, with contraindication for NSAIDs, and refractory to corticosteroids (Migliore A et al., 2010).

11.3 Exclusion criteria

There are important exclusion criteria for hip injection techniques to be considered. Most of the contraindications are temporary and relative, such as suspected or known hip joint infection, joint fracture, anticoagulant therapy to avoid intra/ peri- capsular bleeding, extensive skin pathology in the area of injection, presence of joint prosthesis, uncontrolled high blood pressure and diabetes mellitus, glaucoma, severe congestive heart failure, some severe liver or bone marrow diseases with negative impact on coagulation. Drug(s) allergy may represent an absolute contraindication. Severe hip OA with total absence of radiological joint space contraindicates the use of intraarticular viscosupplementation drugs (Kruse DW, 2008; Migliore A et al., 2010).

12. Efficacy of intraarticular guided injections

Recent trials have demonstrated clear clinical benefit of intraarticular hip injection with corticosteroids and viscosupplementation in hip OA treatment. The imaging techniques currently used for guiding needle insertion are musculoskeletal ultrasound and fluoroscopy, in different protocols, preparates and dosage (Atchia I et al., 2011; Flanagan J et al., 1988; Kullenberg B et al., 2004; 2005; Lambert RGW et al., 2001; Leopold SS et al., 2005; Margules KR , 2001; Migliore A et al., 2004, 2010; Micu MC et al., 2010; Qvistgaard E et al., 2006; Robinson P et al., 2007; Sofka CM et al., 2005).

13. Side effects

As with any other joint injections, various and well known side effects may occur with hip intraarticular joint injection. There are three major concerns for the hip- septic arthritis, osteonecrosis and risk of joint infection after total hip replacement following pre-operative intraarticular corticosteroid injection in a close interval up to the surgical event. In fact, there are just a few cases published in the medical literature reporting the occurrence of local side

effects. Intraarticular viscosupplementation drug deposition is well tolerated and without significant systemic side effects. There are by now eight reported cases of intraarticular granulomatous inflammation developed after a series of three hyaluronic acid injection (Hyalgan GF 20). Intraarticular corticosteroid deposition may have mild systemic effects like transient facial rash, increase of blood pressure or hyperglycemia and local secondary crystalline synovitis which leads to rapid postprocedural local pain. In the literature, there are only two case reports mentioning septic hip involvement following intraarticular corticosteroid injection (Kruse DW, 2008) and four cases of hip aseptic osteonecrosis, but in three of them, corticosteroid deposition was made in another joint. (Kruse DW, 2008; Migliore A et al., 2010) Significant increase in arthroplasty revision secondary to infection in patients who received intraarticular corticosteroid injection prior to surgery is reported in a study performed in 2005 (Kaspar S & de V de Beer j, 2005), but other studies did not confirm any relationship between intraarticular corticosteroid injection prior to total hip arthroplasty. (Chitre AR et al., 2007) As caution, a gap of two months prior to the surgical event is recommended.

14. Post- procedural monitoring

Regardless of the procedure type, aspiration and/ or drug intraarticular injection, the patient must inform the performing physician if any local disturbance or fever occurs within the first 48-72 hours suggesting postprocedural infection. Musculoskeletal ultrasound evaluation for hip joint and periarticular structures can be repeated anytime during follow up without restriction.

15. Conclusions

Ultrasound guided hip injections is ideal for clinical practice because it is rapid, safe and cheap. The method allows precise aspiration even of small amounts of intraarticular fluid and accurate deposition of corticosteroids and viscosupplementation drugs increasing the treatment efficacy. The increasing evidence that musculoskeletal ultrasound is of paramount importance in the rheumatological practice is a further support for its use in guiding the intrarticular injections in order to avoid damage of the structures, misplacing of drugs and help fluid aspiration for diagnostic purposes.

16. References

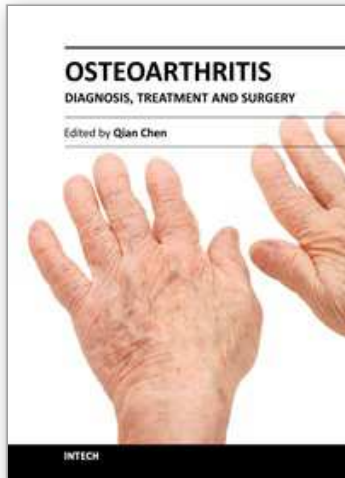
- Aliabadi P, Baker ND & Jaramillo D (1988). Hip arthrography, aspiration, block and bursography. *Radiol Clin North Am* ,Vol. 36, No. 4, (July 1988), pp. 673-690, ISSN 0033-8389
- Atchia I, Birrell F, and Kane D(2007). A modular, flexible training strategy to achieve competence in diagnostic and interventional musculoskeletal ultrasound in patients with hip osteoarthritis. *Rheumatology* , Vol.46, No. 10, (October 2007), pp. 1583- 6, ISSN 1462-0332
- Atchia I, Kane D, Reed M, Isaacs JD, Birrell FN et al (2011). Efficacy of a single ultrasound guided injection for the Treatment of Hip Osteoarthritis. *Ann Rheum Dis* , Vol. 70, No. 1, (January 2011), pp.110-116, ISSN 1468-2060

- Backhaus M, Burmester G, Gerber T, Grassi W, Machold K, Swen W, Wakefield R, Manger B (2001). Guidelines for musculoskeletal ultrasound in rheumatology. *Ann Rheum Dis*, Vol. 60, No. 7, (July 2001), pp. 641–649, ISSN 1468-2060
- Bianchi , BS. (2007). *Ultrasound of the Musculoskeletal System*, Springer - Verlag Berlin Heidelberg, ISBN 978-3-540-42267-9, Germany
- Bierma-Zeinstra SM, Bohnen AM, Verhaar JA, et al (2000). Sonography for hip joint effusion in adults with hip pain. *Ann Rheum Dis*, Vol.59, No. 3, (March 2000), pp.178–82, ISSN 1468-2060
- Birrell F, Afzal C, Nahit E, et al (2003). Predictors of hip joint replacement in new attenders in primary care with hip pain. *Br J Gen Pract*, Vol. 53, No. 486, (January 2003), pp.26-30, ISSN 0960-1643
- Bradley MJ (2001). An in-vitro study to understand successful free-hand ultrasound guided intervention. *Clin Radiol*, Vol. 56, No.6, (June 2001), pp. 495-498, ISSN 0009 -9260
- Brooks PM (2006). The burden of musculoskeletal disease- a global perspective. *Clin Rheumatol*, Vol. 25, No. 6, (November 2006), pp.778-81, ISSN 1434-9949
- Cantini F, Niccoli L, Nannini C et al. Inflammatory changes of hip synovial structures in polymyalgia rheumatica (2005). *Clin Exp Rheumatol*, Vol. 23, No. 4, (July- August 2005), pp. 462-8, ISSN 0392-856X
- Chitre AR, Fehily MJ, Bamford DJ (2007). Total hip replacement after intra-articular injection of local anaesthetic and steroid. *J Bone Joint Surg Br*, Vol.89-B, No.2, (February 2007), pp.166-8, ISSN 0301-620X
- Flanagan J, Casale FF, Thomas TL, Desai KN (1988). Intra-articular injection for pain relief in patients awaiting hip replacement. *Ann R Coll Surg Engl*, Vol.70, No. 3, (May 1988), pp.156-7, ISSN 0035-8843
- Foldes K, Balint P, Balint G, Buchanan WW (1995). Ultrasound guided aspiration in suspect sepsis of resection arthroplasty of the hip joint. *Clin Rheumatol*, Vol.14, No. 3, (May 1995), pp.327-9, ISSN 1434-9949
- Hamper UM, Savader BL, Sheth S (1991). Improved needle-tip visualisation by color Doppler sonography. *Am J Roentgenol*, Vol. 156, No. 2, (February 1991), pp. 401-402, ISSN:1546-3141
- Iagnocco A, Filippucci E, Meenagh G, et al (2006). Ultrasound imaging for the rheumatologist III. Ultrasonography of the hip. *Clin Exp Rheumatol*, Vol. 24, No. 3, (May- June 2006), pp.229–32, ISSN 0392-856X
- Iagnocco A and Naredo E (2010).Ultrasound- guided corticosteroid injection in rheumatology: accuracy or efficacy? *Rheumatology*, Vol. 49, No.8, (March 2010), pp. 1427-28, ISSN 1462-0332
- Kaspar S, de V de Beer j (2005). Infection of hip arthroplasty in previous injection of steroid. *J Bone Joint Surg Br*, Vol. 87-B, No.4, (Apryl 2005), pp. 454-7, ISSN 0301-620X
- Komppa GH, Northern JR Sr, Haas DK, Lisecki E, Ghaed N (1985). Ultrasound guidance for needle aspiration of the hip in patients with painful hip prosthesis. *J Clin Ultrasound*, Vol. 13, No. 6, (July- August 1985), pp.433-4, ISSN 1097-0096
- Koski JM, Anttila PJ, Isomaki HA (1989). Ultrasonography of the adult hip joint. *Scand J Rheumatol*, Vol. 18, No.2, (February 1989), pp.113–7, ISSN 0300-9742
- Kruse DW (2008). Intraarticular cortisone injection for osteoarthritis of the hip. Is it effective? Is it safe? *Curr Rev Musculoskeletal Med*, Vol.1, No.12, (December 2008), pp. 227-233, ISSN 1935-973X

- Kullenberg B, Runesson R, Tuvhag R, Olsson C, Resch S (2004). Intraarticular corticosteroid injection: pain relief in osteoarthritis of the hip? *J Rheumatol* , Vol.31, No. 11, (November 2004), pp.2265-8, ISSN 0263-7103
- Lambert RGW, Hutchings EJ, Grace MGA, Jhangri GS (2007). Conner Spady B, Maksymowich WP. Steroid Injection for osteoarthritis of the hip: a randomized, double-blind, placebo-controlled trial. *Arthritis Rheum* , Vol. 56, No. 7, (July 2007), pp.2278-87, ISSN 1529-0131
- Leopold SS, Battista V, Oliverio JA (2001). Safety and efficacy of intraarticular hip injection using anatomical landmarks. *Clin Orthop* ; 391: 192-7, ISSN 0009-921X
- Margules KR (2001). Fluoroscopically directed steroid instillation in the treatment of hip osteoarthritis: safety and efficacy in 510 cases. *Arthritis Rheum* , Vol.44, No. 10, (October 2001), pp.2449-50, ISSN 1529-0131
- Micu MC, Bogdan G, Fodor D (2010). Steroid injection for hip osteoarthritis: efficacy under ultrasound guidance. *Rheumatology*, Vol. 49, No. 8, (March 2010), pp. 1940-4, ISSN:1462-0332
- Migliore A, Kristoffersen H, Terslev L, Danneskiold-Samsøe B, Torp-Pedersen S, Bliddal H (2001). Guidance by ultrasound of intra-articular injections in the knee and hip joints. *Osteoarthr Cartil* , Vol.9, No. 4, (Apryl 2001), pp.512-7, ISSN 1063-4584
- Migliore A, Tormenta S, Martin Martin LS, et al (2004). Safety profile of 185 ultrasound guided intra- articular injections for treatment of rheumatic diseases in the hip. *Reumatismo* , Vol. 56, No. 4, (Apryl- June, 2004), pp. 104-109, ISSN 0048-7449
- Migliore A, Giovannangeli F, Granata M and Lagana B (2010). Hyalgan G-F 20: Review of its Safety and Efficacy in the Management of Joint Pain in Osteoarthritis. *Clinical Medical Insights: Arthritis and Musculoskeletal Disorders* , Vol.3, No. 12, (December 2010), pp. 55-68, ISSN: 1179-5441
- Naredo E, Cabero F, Cruz A, et al (2005). Ultrasound guided musculoskeletal injections. *Ann Rheum Dis* , Vol.64, No. 2, (February 2005), pp.341-344, ISSN 1468-2060
- Ozonoff MB (1973). Controlled arthrography of the hip: A technique of fluoroscopic monitoring and recording. *Clin Ortop Relat res* , Vol.93, (1973), pp.260-264, ISSN 1413-7852
- Picano E, Matucci-Cerinic M (2010). Unnecessary radiation exposure from medical imaging in the rheumatology patient. *Rheumatology*, on line 22 Dec, doi:10.1093/rheumatology/keq412, ISSN 1462-0332
- Qvistgaard E, Christensen R, Torp- Pedersen S, et al (2006). Intra- articular treatment of hip osteoarthritis : a randomized trial of hyaluronic acid, corticosteroid and isotonic saline. *Osteoarthr Cartilage* , Vol.14, No. 2, (February 2006), pp. 163-70, ISSN 1063-4584
- Qvistgaard E, Kristoffersen H, Terslev L, Danneskiold-Samsøe B, Torp-Pedersen S, Bliddal H (2001). Guidance by ultrasound of intra-articular injections in the knee and hip joints. *Osteoarthr Cartilage*, Vol.9, No. 6, (August 2001), pp.512-7, ISSN 1063-4584.
- Richette P, Ravaud P, Conrozier T, et al (2009). Effect of hyaluronic acid in symptomatic hip osteoarthritis : a multicenter, randomized, placebo- controlled trial. *Arthritis Rheum* , Vol. 60, No 3, (March 2009), pp. 824-30, ISSN 1529-0131
- Robinson P, Keenan AM, Conaghan G (2007). Clinical effectiveness and dose response of image-guided intra-articular corticosteroid injection for hip osteoarthritis. *Rheumatology* , Vol. 46, No. 2, (February 2007), pp.285-91, ISSN 1462-0332

- Sofka CM, Saboeiro G & Adler RS (2005). Ultrasound-guided adult hip injections. *J Vasc Interv Radiol*, Vol. 16, No 8, (August 2005), pp. 1121-3, ISSN 1051-0443
- Wakefield RJ, Balint PV, Szkudlarek M, et al (2005). OMERACT 7 Special Interest Group. Musculoskeletal ultrasound including definitions for ultrasonographic pathology. *J Rheumatol*, Vol. 32, No. 12, (December 2005), pp.2485-7, ISSN: 0263-7103
- Zhang W, Doherty M, Arden N, et al (2005). EULAR evidence based recommendations for the management of hip osteoarthritis: report of a task force of EULAR standing committee for International Clinical Studies Including Therapeutics (ESCISTS). *Ann Rheum Dis*, Vol. 64, No.5, (May 2005), pp. 669-681, ISSN 1468-2060
- Zhang W, Moskowitz RRW, Nuki G, et al (2008). OARSI recommendations for the management of hip and knee osteoarthritis. Part II: OARSI evidence - based, expert consensus guidelines. *Osteoarthr Cartilage*, Vol..16,No.12, (December 2008), pp.137-62, ISSN 1063-4584

IntechOpen



Osteoarthritis - Diagnosis, Treatment and Surgery

Edited by Prof. Qian Chen

ISBN 978-953-51-0168-0

Hard cover, 404 pages

Publisher InTech

Published online 02, March, 2012

Published in print edition March, 2012

Osteoarthritis is one of the most debilitating diseases affecting millions of people worldwide. However, there is no FDA approved disease modifying drug specifically for OA. Surgery remains an effective last resort to restore the function of the joints. As the aging populations increase worldwide, the number of OA patients increases dramatically in recent years and is expected to increase in many years to come. This is a book that summarizes recent advance in OA diagnosis, treatment, and surgery. It includes wide ranging topics from the cutting edge gene therapy to alternative medicine. Such multifaceted approaches are necessary to develop novel and effective therapy to cure OA in the future. In this book, different surgical methods are described to restore the function of the joints. In addition, various treatment options are presented, mainly to reduce the pain and enhance the life quality of the OA patients.

How to reference

In order to correctly reference this scholarly work, feel free to copy and paste the following:

Micu Mihaela Cosmina (2012). Ultrasound Guided Hip Injection Techniques, Osteoarthritis - Diagnosis, Treatment and Surgery, Prof. Qian Chen (Ed.), ISBN: 978-953-51-0168-0, InTech, Available from: <http://www.intechopen.com/books/osteoarthritis-diagnosis-treatment-and-surgery/ultrasound-guided-hip-injection-in-osteoarthritis>

INTECH
open science | open minds

InTech Europe

University Campus STeP Ri
Slavka Krautzeka 83/A
51000 Rijeka, Croatia
Phone: +385 (51) 770 447
Fax: +385 (51) 686 166
www.intechopen.com

InTech China

Unit 405, Office Block, Hotel Equatorial Shanghai
No.65, Yan An Road (West), Shanghai, 200040, China
中国上海市延安西路65号上海国际贵都大饭店办公楼405单元
Phone: +86-21-62489820
Fax: +86-21-62489821

© 2012 The Author(s). Licensee IntechOpen. This is an open access article distributed under the terms of the [Creative Commons Attribution 3.0 License](#), which permits unrestricted use, distribution, and reproduction in any medium, provided the original work is properly cited.

IntechOpen

IntechOpen