

We are IntechOpen, the world's leading publisher of Open Access books Built by scientists, for scientists

4,800

Open access books available

122,000

International authors and editors

135M

Downloads

Our authors are among the

154

Countries delivered to

TOP 1%

most cited scientists

12.2%

Contributors from top 500 universities



WEB OF SCIENCE™

Selection of our books indexed in the Book Citation Index
in Web of Science™ Core Collection (BKCI)

Interested in publishing with us?
Contact book.department@intechopen.com

Numbers displayed above are based on latest data collected.

For more information visit www.intechopen.com



Osteoarthritis of the Wrist

Nimit Patel, Glenn Russo and Craig Rodner
*University of Connecticut
United States of America*

1. Introduction

Our hands are a uniquely human characteristic. They have helped us throughout our evolution and even today they help us to live, work, and play. While osteoarthritis can cause great pain wherever it presents, it is a particularly crippling disease when it affects the wrist and the hands. Unfortunately, osteoarthritis of the wrist can result from a multitude of causes. One can divide these causes into two major categories: traumatic and non-traumatic. Trauma leading to osteoarthritis often occurs because of ligament and bone injury that causes instability, dyskinesia, and altered loading forces that can lead to joint degeneration. Intra- or extra-articular fractures can also produce abnormal joint loading and arthritis. For example, some prototypical patterns of injury include the common scapholunate advanced collapse (SLAC) and the closely related scaphoid fracture and non-union (SNAC). When conducting a general exam on a patient with suspected wrist osteoarthritis, it is essential to begin with a broad differential diagnosis to avoid falling into the trap of premature closure. Congenital, inflammatory, vascular, post-traumatic and idiopathic etiologies have all been known to cause wrist pain. The goal of the history and physical (H&P), therefore, is to articulate the precise cause of this pain in order to design the best treatment plan. The patient's age, hand dominance, aggravating and alleviating pain factors, prior trauma, family history, occupation, hobbies and limb functionality are all essential parts of a good history. The physical exam, given the close proximity and complexity of the intercarpal joints, is particularly important in isolating the exact source of pain. A general inspection should note any swelling, erythema or atrophy. Passive and active range of motion should be assessed with full flexion, extension, pronation and supination as well as radial and ulnar deviation. Physical examination should also comment on any tenderness in the joint in addition to the patient's vascular and neurologic status. Additionally, other joints like the elbow, shoulder and neck should be inspected for injury or symptomatology. All tests should be bilateral. Functional measures like the Disabilities of the Arm, Shoulder and Hand, the Patient Evaluation Measure and the Michigan Hand Outcome Questionnaire have also been used to establish one's functional status (Dias, Rajan et al. 2008). Joint palpation is the most useful technique in localizing articulations that produce pain. In addition to general palpation, there is an array of pain-producing maneuvers that can be used to isolate particular joints. The thumb grind can be used to show thumb carpometacarpal (CMC) arthritis. The scaphoid shift test will point towards a scapholunate instability (Watson, Ashmead et al. 1988). The shear or ballotment test indicates lunotriquetral instability (Reagan, Linscheid et al. 1984). The catch-up-clunk test identifies midcarpal joint instability

(Lichtman, Schneider et al. 1981). Pisiform tracking can be used to isolate pisotriquetral osteoarthritis. (Nagle 2000) (Friedman and Palmer 1991). Pain on pronosupination during elbow flexion will help isolate a distal radioulnar joint arthritis. Pre- and post-operative pain scales, like the Nagy and Buchler system can also be used (Nagy and Buchler 1997).

Strength should be evaluated and is most useful when objectively quantified with a goniometer. Abnormalities in grip strength can indicate pathology and its testing is most accurate when used with the rapid exchange grip strength technique which is best at determining submaximal effort (Hildreth, Breidenbach et al. 1989). In addition to the initial patient visit, this is a useful measure for pre-operative and post-operative comparison.

A patient's laboratory evaluation should include, when appropriate, plasma ESR, CRP, white blood cell count, uric acid, ANA and rheumatoid factor to rule out any infections or likely rheumatologic conditions.

Imaging studies are another valuable tool at the physician's disposal that allows him or her to better determine which joints are affected by the degenerative processes. The standard x-ray series should include a posteroanterior (PA), oblique, and lateral view.. A wrist with normal anatomic relationships will show that the radial shaft, capitate, and third metacarpal will line up along the same vertical axis in the PA wrist x-ray. The physician's initial evaluation should focus on the radioscaphoid, radiolunate and capitolunate joints. A secondary evaluation should include assessment of the Carpometacarpal, scapho-trapezium-trapezoid (STT), ulnocarpal and distal radioulnar joint (Weiss and Rodner 2007). The articular surface of the radiocarpal joints can sometimes be better seen with a tangeiental view. Radioscaphoid and STT joints can be seen best with radial and ulnar deviation views. Carpal tunnel and oblique supination views are excellent for the evaluation of the pisotriquetral joint (Peterson and Szabo 2006). As always, to control for normal anatomic variation, all findings should be compared with the contralateral wrist.

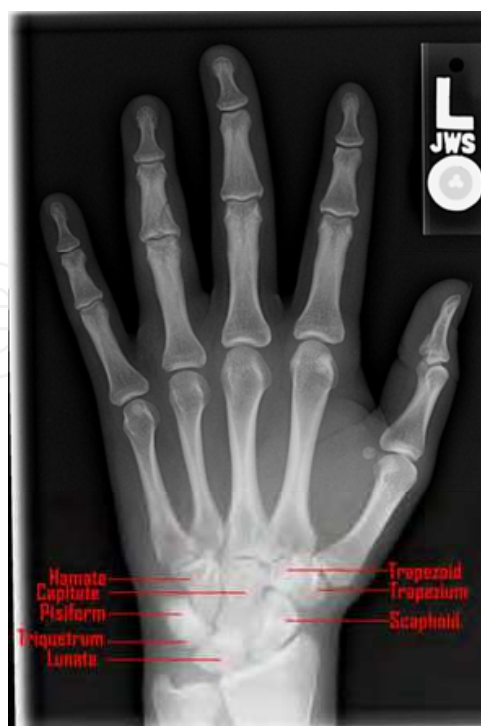

Fig. 1. PA Radiograph of Normal Wrist

Sonographic imaging can be a useful tool when used by a radiologist with sufficient training in its application to hand anatomy. A CT scan may be useful for the evaluation of the smaller intra-carpal articulations as well as the pisotriquetral joint. Less obvious distal radioulnar joint malalignment can also be picked up with CT views in neutral, supination, and pronation positions. However, the CT scan is inferior when compared to the MRI for the evaluation of soft tissue defects (Mutimer, Green et al. 2008). An MRI is therefore better than a CT to evaluate for cartilage injury. Bone scintigraphy is a nonspecific scan that is best used to supplement inconclusive findings. A three-phase scan can be useful in determining the chronicity of a pathological condition; a chronic condition is indicated when technetium uptake is only seen in delayed images. Finally, a diagnostic injection with corticosteroid or anesthetic can be used to confirm the pain-generating joint in the hand. If injection of the suspected joint alleviates the patient's pain, then it is highly likely that you have isolated the source of the problem. This technique is particularly useful in differentiating radiocarpal, midcarpal, and DRUJ insults. It can also confirm pisotriquetral, STT or basilar thumb arthritis. Injection can also distinguish an extra- versus intra-articular pain source.

Treatment is only effective when correctly paired to an accurate diagnosis. Given the wide array of wrist pathologies, the exam and work up of a patient with wrist pain is crucial. All other causes of wrist pain must be ruled out before a diagnosis of osteoarthritis is reached. Moreover, the surgical treatments discussed below are only to be considered after a patient has failed other forms of non-pharmacologic and medical therapies. Some of the more common causes of wrist osteoarthritis, their pathogenesis, diagnostic workup and treatment are discussed below.

2. Osteoarthritis of the radioscaphoid joint

2.1 Scapholunate advanced collapse

Scapholunate advanced collapse (SLAC) represents the most common pattern of degenerative wrist arthritis and accounts for 72% of the cases of wrist arthritis seen today (Watson and Weinzweig 1999). This pattern was first described by Watson and Ballet who reviewed four thousand wrist x-ray films for sequential degenerative changes and determined that arthritis between the scaphoid, lunate, and radius represented 57% of cases surveyed (Watson and Ballet 1984).

In this disease process, the initial insult is a trauma to the scapholunate (SL) ligament which allows for a rotary subluxation of the distal scaphoid, resulting in progressive intercarpal instability and joint degeneration. Degenerative changes first affect the radial styloid and distal pole of the scaphoid (stage I). Arthritic changes then occur in the radioscaphoid joint (stage II), further progress to the capitulate articulation (stage III), and can culminate with pancarpal involvement (Weiss and Rodner 2007).

In addition to SL ligament trauma, calcium pyrophosphate dehydrate (CPPD) crystal deposition can also produce a SLAC wrist pattern of arthritic change (Chen, Chandnani et al. 1990). Also, a recent study suggested that SLAC wrist could result independently of trauma or CPPD. Studies suggest that congenital SL laxity may predispose certain individuals to develop SLAC wrist. (Pollock, Giachino et al. 2010). Other conditions like avascular necrosis of the scaphoid (Kienbock disease), Preiser's disease, intra-articular fractures affecting the radioscaphoid or capitulate joints, perilunate dislocation, malunion of a distal radius fracture and carpal instability can also produce a SLAC pattern of degeneration in the wrist (Vender, Watson et al. 1987).

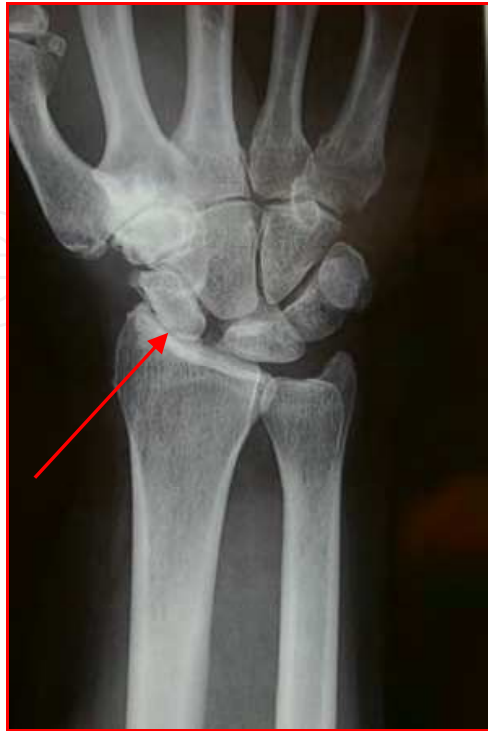

Fig. 2. PA Radiograph SLAC Wrist

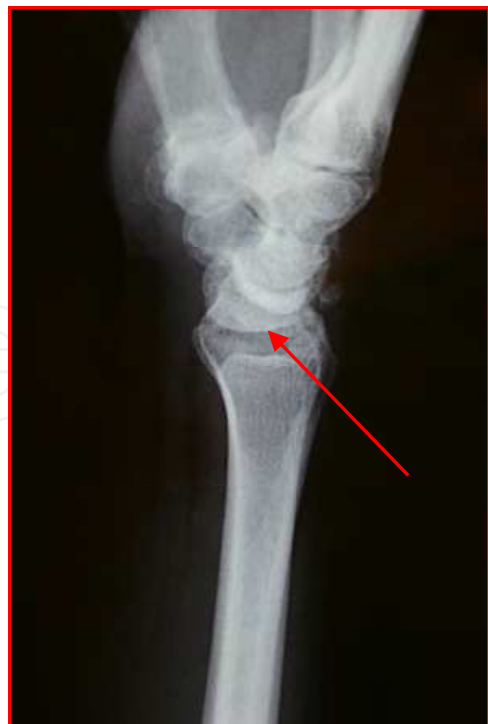

Fig. 3. Lateral Radiograph of SLAC Wrist

As with much of orthopaedics, the anatomy of this system is implicit to its pathology. The proximal pole of the scaphoid is elliptical in shape and it articulates in a corresponding elliptical surface in the distal radius. With scaphoid instability due to SL ligament injury, the scaphoid will rotate causing it to sublux and articulate only on the edges of its joint diathesis. As a result, unequal loading forces can cause degenerative change and joint destruction. Imagine two nested spoons; if one were to rotate by 90 degrees, they would articulate on smaller contact points instead of their entire surface (Mastella, Ashmead et al. 2009). This subluxation and rotation results in the radioscapoid pain that designates stage II of SLAC. Conversely, the radiolunate joint is spherical, so that rotation of the lunate will not cause a change in the force distribution across the joint. It is for this reason that the radiolunate joint is preserved in a SLAC wrist pattern of degeneration. This concept is important because it serves as the basis for surgical intervention.

The presentation of the SLAC wrist typically involves dorsal wrist swelling and tenderness in a periscaphoid distribution. The patient may complain of restricted mobility of their wrist. Patients will demonstrate a positive "shift test" which has been described as the definitive test for scaphoid instability. Pain while applying pressure to the scaphoid during radial deviation of the wrist is a positive test result. (Watson, Ashmead et al. 1988). Wrist ganglia have also been known to develop in the presence of carpal instability. However, in the case of a SLAC wrist, as the disease becomes more advanced the structures needed to form ganglia are abolished. Therefore, this complication may be appreciated early on in the disease process, but is less apparent with advanced pathology. As always, these clinical symptoms should be evaluated in comparison to the contralateral wrist. Also, there have been reports of SLAC wrist that are not associated with pain. These are typically isolated to older, low-demand patients who's arthritic disease is discovered during investigation of another complaint (Fassler, Stern et al. 1993). Other diagnoses to rule out include thumb CMC arthritis, carpal tunnel syndrome, and trigger finger. The diagnosis of SLAC wrist is confirmed with bilateral plain x-rays with evidence of degeneration in the affected hand.

Nonsurgical management of a SLAC wrist or its related conditions currently lacks long term data. This therapy consists of non-steroidal anti-inflammatory drugs (NSAIDS), splints, and injections for symptomatic treatment. By decreasing inflammation with NSAIDS and corticosteroids, and decreasing mobility with splinting we are able to provide some pain relief. Anti-inflammatory medications may need to be tailored to each individual patient as some respond better to some medications than others. Corticosteroid injections can be particularly beneficial in patients who show swelling and synovitis. Moreover, intermittent injections can have less side effects than those associated with chronic anti-inflammatory use. Splints are to be worn intermittently throughout the day and during the night. One study determined that if pain is not limiting and grip strength is greater than or equal to 80%, managing these symptoms non-surgically is a reasonable option (Pilny, Kubes et al. 2006).

Surgical contraindications are due to any pathology that affects the radiolunate joint. A SLAC wrist pattern represents a final common pathway in a variety of disease processes but a defining feature remains to be the preservation of the radiolunate joint. This joint's integrity is critical because it serves as the main point of force translation through the wrist after several of the surgical options. Therefore, any significant degeneration of the radiolunate joint would qualify as a contraindication for surgery. Similarly, any ulnar translation of the carpus on the radius will alter the radiolunate relationship and also serve as a contraindication for surgery (Pellegrini, Parentis et al. 1996).

Surgical therapy can be accomplished through a variety of approaches. Historically, this consisted of scaphoid excision and replacement with a silicone arthroplasty along with fusion of the capitate, lunate, hamate and triquetrum by using Kirschner-wires (K-wires). Use of the silicone scaphoid replacement has fallen out of favor due to the fact that silicone wear resulted in particulate formation, synovitis, and joint collapse (Ashmead, Watson et al. 1994). Despite the failure of the silicone scaphoid replacement, the technique of fusing the four aforementioned carpal bones along with scaphoid excision remains to be a popular surgical option for patients suffering from a SLAC wrist; this procedure is referred to as a scaphoid excision with a four-corner arthrodesis. This is a reliable and effective procedure that provides a stable column for force transfer through the radiolunate joint. Dacho has shown encouraging results with this technique on long-term follow-up in the treatment of both SLAC and SNAC wrist injury (Dacho, Grundel et al. 2006). Mid-term results using K-wires specifically have also enjoyed similar success (Winkler, Borisch et al. 2010).

Alternatively, a proximal row carpectomy (PRC) can be used in lieu of a four-corner arthrodesis. This technique calls for the removal of the proximal row of carpal bones and allows the distal row to collapse proximally. In this scenario, the capitate articulates with the lunate facet of the radius. This surgery preserves a fair amount of wrist mobility and requires no arthrodesis. PRC is a viable alternative to four-corner arthrodesis as it has shown success in long-term follow-up (Liu, Zhou et al. 2009).

Controversy exists in determining which procedure is superior; four-corner arthrodesis with scaphoid excision or PRC. Studies suggest no difference in outcomes when comparing these two procedures. However, some patients may prefer the PRC procedure as it allows for greater wrist mobility. In a high demand wrist the loss of stability could become problematic and the four-corner arthrodesis may be the preferred technique in this patient. (Mulford, Ceulemans et al. 2009) (Cohen and Kozin 2001; Dacho, Baumeister et al. 2008; Bisneto, Freitas et al. 2011).

Other surgical techniques include denervation, total wrist fusion, wrist arthroplasty and variations of intercarpal arthrodeses. Denervation can be accomplished through transection of all articular nerve branches or it can be limited to the anterior or posterior interosseous nerves proximal to the carpus. One study showed long-term data supporting the use of denervation as a treatment for SLAC/SNAC wrist injury (Rothe, Rudolf et al. 2006).

Any symptoms of complex regional pain syndrome (intense burning pain that gets worse over time and spreads to adjacent or contralateral limbs) should be treated with a stress loading program (active exercise with minimal joint motion). Also, the patient should be monitored for triquetral impingement ligament tear syndrome (TILT). This syndrome occurs secondary to ulnar translation of the carpus due to the increased laxity of the radiocarpal ligaments (Watson and Weinzweig 1999). TILT will manifest as pain and tenderness on the ulnar aspect of the wrist. When occurring after a reconstructive surgery, TILT will often resolve spontaneously, however, if it persists it can be corrected by resecting the impinging portion of the ulnar sling. Radiolunate degeneration is a rare complication of reconstruction and is always seen in the context of ulnar translation of the carpus. When this occurs, it can be successfully repaired with total wrist arthrodesis.

Overall, the treatment of SLAC wrist enjoys encouraging outcomes. Post operative follow up shows that patients generally have improved pain levels while maintaining ROM and grip strength. (Malerich, Clifford et al. 1999) Although controversy remains with regard to

the “best” procedure with which to treat a SLAC wrist, we are able to take solace in the fact that regardless of operative technique, patient satisfaction remains very high.

2.2 Scaphoid nonunion advanced collapse

It has become clear that scaphoid nonunion advanced collapse (SNAC) is a clinical entity similar to SLAC wrist in that it is identified by a series of predictable degenerative changes. In a SNAC wrist, however, the initial injury is a fracture and nonunion of the scaphoid rather than an SL ligament injury. A scaphoid malunion can also cause a SNAC injury. Interestingly, in a SNAC injury, because the SL ligament is preserved, the proximal scaphoid fragment is not involved in the degenerative changes and it is the scaphocapitate that tends to be affected (Vender, Watson et al. 1987).

Because of its close similarity to the SLAC wrist, a SNAC injury shares a similar disease progression with comparable stages of joint degeneration. Stage I is associated with arthritis localized to the distal scaphoid and radial styloid. Stage II shows radioscaphoid and scaphocapitate arthritis with a preserved lunocapitate joint. Once the lunocapitate joint becomes involved, a stage III designation is warranted.

Much like the presentation and evaluation of SLAC wrist, a patient with a SNAC wrist injury will present with wrist pain at the radioscaphoid joint and dorsal swelling. Diagnosis will be based on the history and physical but confirmed with an x-ray and its comparison to the contralateral wrist. Treatments for SNAC wrist also overlap with the SLAC wrist and are comprised of nonsurgical management with splinting and injections, as well as surgical options like arthrodesis, proximal row carpectomy, denervation, and radial styloidectomy. One notable difference in between the treatment plans for SLAC and SNAC wrists is that the SNAC wrist can be treated with the excision of the distal scaphoid fragment. One study noted that 13 out of 19 patients showed significant pain relief as well as improved ROM and grip strength with this procedure (Malerich, Clifford et al. 1999).

In summary, a SNAC wrist injury shares a great deal with a SLAC wrist and is discerned through a careful history, physical, and radiographic evaluation. Treatment options are almost identical for the two pathologies with a notable distinction that a SNAC wrist can be treated with a distal scaphoid excision.

3. Osteoarthritis of the distal radioulnar joint

The distal radioulnar joint (DRUJ) is essential to painless pronation and supination of the wrist. A DRUJ that is plagued by osteoarthritis will show restriction and pain with these motions as well as a significantly decreased grip strength. Arthritis in this joint, therefore, severely limits the function of one’s entire hand. Injury can occur secondary to intra-articular fractures involving the DRUJ or malunion of forearm fractures which result in altered biomechanics. The Colles’ fractures in particular can create carpal instability and subsequent arthritis (Cooney, Dobyns et al. 1980).

The radius and ulna are connected by both a proximal and distal radioulnar joint which allow for forearm pronation and supination. Stability of the joints is conferred by a series of ligamentous supports. The DRUJ specifically is supported by the triangular fibrocartilage complex (TFCC). The TFCC is composed of the articular disc, the dorsal and volar radioulnar ligaments, the meniscus homologue, the ulnar collateral ligament, and the sheath of the extensor carpi ulnaris (Palmer and Werner 1981). The articular disc is largely an avascular structure. The main stabilizers of the DRUJ are dorsal and palmar radioulnar

ligaments (af Ekenstam, Palmer et al. 1984). The blood supply is provided by the anterior interosseous artery, the ulnar artery, and the medullary interosseous arteries. Understandably, those structures with ample blood supply, like the TFCC, are able to heal readily while the avascular structures, like the articular disc, are less able to do so. The annular ligament supports the proximal radioulnar joint and the interosseous membrane serves as a connection between the diaphysis of the radius and ulna.

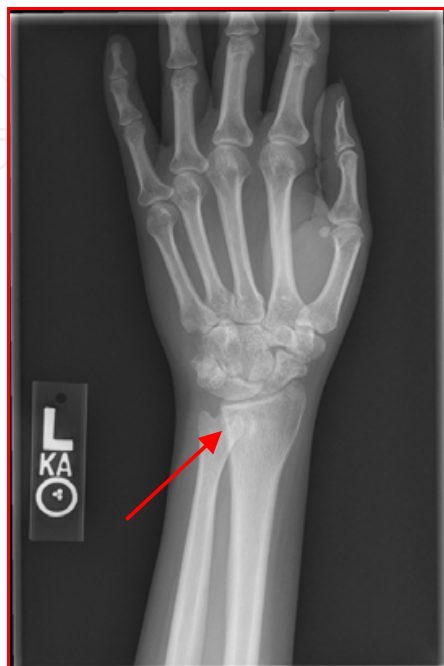

Fig. 4. PA Radiograph of Osteoarthritis of the DRUJ

The natural history of DRUJ arthritis begins with a pre-arthritis condition, usually a radial fracture malunion or instability of the DRUJ, which can develop into a degenerative arthritis over time. DRUJ instability is defined as the inability of the DRUJ to maintain its normal anatomic relationship under physiologic loading. Instability can be classified as either acute or chronic. In a case of acute DRUJ instability, the cause is often a fall on an outstretched hand resulting in an acute dislocation, fracture of the radial head or either bones of the forearm (Edwards and Jupiter 1988). This may result in injury to the joint surface, its supporting ligaments, or both (Bruckner, Alexander et al. 1996). In this scenario, ulna volar dislocation occurs secondary to hypersupination while ulna dorsal dislocations occur secondary to hyperpronation. Dislocations can be classified as either simple (reduced spontaneously or with minimal effort) or complex (irreducible or easily dislocated), the latter of which is usually due to a tear in the TFCC (Bruckner, Alexander et al. 1996). Chronic DRUJ instability can also be the result of a particular injury or it can result from a fracture of the radius and/or ulna, malunion or ligament injury. If left untreated, acute or chronic instability can progress into an arthritic degeneration of the DRUJ and can be associated with ulnar impaction (Kakar, Carlsen et al. 2010).

Most patients will present with painful wrist motions and restricted mobility. If there is a grossly apparent acute fracture, complete radiologic evaluation is warranted (Braun 1992). However, with an injury of a more insidious onset (like subluxation or dislocation) then swelling may be the only physical finding. A volar dislocation of the DRUJ will not allow pronation while a dorsal dislocation will not allow supination (Hauck, Skahen et al. 1996).

The differential diagnosis includes piso-triquetral and triquetro-hamate arthritis. The presence of a piano-key sign should be assessed in patients complaining of DRUJ pain (Scheker, 2009). The patient places their palms down on the examination table and pushes. The sign is present if the head of the ulna can be seen moving up and down. Such a finding is indicative of damage to the triangular fibrocartilage and is more common in rheumatoid arthritis as opposed to osteoarthritis. A second maneuver begins with the patient placing their elbows on the examination table with their forearms positioned perpendicular to the table's surface. Shear force is applied to the DRUJ. Any pain or displacement between the radius and ulna will indicate DRUJ instability. A third maneuver to be performed would be to apply shear force by pushing down on the patient's forearms while the patient pronates and supinates. Pain may be indicative of DRUJ incongruity and/or arthritis.

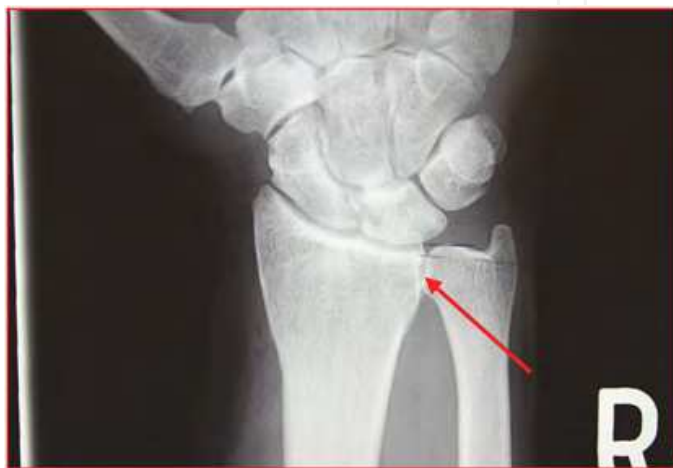

Fig. 5. PA Radiograph of Ulnar Impaction with an Ulnar -sided Lunate Cyst in Setting of DRUJ Arthritis

Radiographic assessment of the DRUJ is important in diagnosis and treatment planning. Typically, plain radiographs are used to survey the joint for any deterioration. A PA x-rays should be taken with the shoulder abducted to 90 degrees, with the elbow flexed at 90 degrees and the wrist in neutral position. The PA view is important in evaluating DRUJ congruency. Typically, the sigmoid notch slants towards the ulnar styloid with a 20 degree angle (af Ekenstam and Hagert 1985). However, evaluation of this angle is important because it has significant implications in ulnar shortening osteotomy as well as some of the other surgical treatment modalities. The lateral x-ray is also essential in determining DRUJ congruency. One can confirm that their scan is a true lateral view when the pisiform is in line with the distal third of the scaphoid. A true lateral view of the carpus will be required to evaluate for DRUJ subluxation. The pisotriquetral joint and hook of hamate can be evaluated from an oblique view with the wrist in a semipronated and semisupinated position. All radiography should be compared with the contralateral side. CT scans can be useful when x-ray findings are unequivocal and may identify joint surface defects and subluxation. (Staron, Feldman et al. 1994). (Pirela-Cruz, Goll et al. 1991). An MRI is more useful if there is clinical suspicion of a triangular fibrocartilage tear or other cartilage defects (Golimbu, Firooznia et al. 1989). A bone scan is warranted in patients with a high clinical suspicion of DRUJ pathology who have a negative plain radiograph (Shewring, Savage et al. 1994). While this is a very sensitive technique, unfortunately, it lacks in specificity. Infection, bruising, and inflammation can be readily detected with scintigraphy.

Treatment will obviously vary greatly depending on the presentation of either a pre-arthritis or arthritic joint. In the case of a simple subluxation or dislocation, treatment consists of immobilization in a reduced position with an above-elbow cast for 6 weeks. A closed reduction, if needed, should be performed under regional anesthesia. If the DRUJ remains unstable after reduction, surgery may be necessary to repair the torn TFCC. Open reduction is only indicated when a closed reduction is impossible or unsatisfactory. Fractures are to be evaluated individually as there are many unique patterns with an ever changing array of plates and screws available for repair. With regard to more chronic DRUJ instability, soft tissue reconstruction is usually satisfactory. Ligamentous injuries can be repaired by either extra-articular or intra-articular approaches. The extra-articular approach is technically an easier surgery and is achieved by a direct radioulnar tether (Fulkerson and Watson 1978) or an indirect radioulnar link (with the use of a ulnocarpal sling or tenodesis) (Breen and Jupiter 1989). An intra-articular repair, though a more demanding procedure, can reconstitute the original ligamentous anatomy and can yield very satisfactory results (Scheker, Belliappa et al. 1994).

In patients with evidence of joint misalignment without the presence of arthritis, treatment can be centered on realignment procedures through a variety of approaches, osteotomy or ulnar shortening osteotomy. An ulnar shortening procedure is another technique that can be used to re-establish stability in an otherwise lax TFCC (Nishiwaki, Nakamura et al. 2005). With this technique, more extensive surgery is avoided and early pre-arthritis conditions can be corrected before they progress further. However, it should be noted that Jupiter and his group determined that shortening by 6mm was enough to produce painful symptoms in the DRUJ (Jupiter and Masem 1988). This evidence of altered kinematics in a cadaver model corroborate this finding (Adams 1993). It was determined that a possible remedy for this cause of DRUJ arthritis is dependent on the status of the articular cartilage of the sigmoid notch and the ulnar seat (Hunt, Hastings et al. 1998). This study also concluded that for less advanced disease, where the DRUJ showed only mild arthrosis, the joint stability could be regained with ulnar shortening osteotomy (Hunt, Hastings et al. 1998).

Once arthritis has developed in the DRUJ, a different armamentarium is available for use. The Darrach resection is the oldest of these procedures and it refers to the resection of the distal end of the ulna; effectively eliminating the pain-generating grinding that would otherwise occur at the DRUJ (Darrach 1992). However, this particular technique is not without post-operative complications which are related to the de-stabilizing nature of the procedure (snapping the ulnar stump and ulnar translocation with tendon rupture). When compared to the Sauve-Kapandji and hemiresection-interposition arthroplastic procedures, the Darrach procedure is less favorable and was only preferred in elderly patients with severe osteoarthritic changes (Minami, Iwasaki et al. 2005). The Sauve-Kapandji technique involves the fusion of the head of the ulna to the radius. In such a surgery, the TFCC will be preserved and the ulnar carpus will remain adequately supported. A recent study suggest that for moderate, but not more complex disease, the Sauve-Kapandji procedure showed good improvement in forearm rotation, grip strength, and pain reduction (Czermak, Wittemann et al. 2007).

While the aforementioned techniques are all useful in relieving pain by removing the grinding contact forces responsible for that pain, they also inherently result in some destabilization. This may be acceptable in a patient with a low-demand lifestyle but it can also be problematic in someone in need of a more durable solution. Recently, prosthetic replacements have been developed and have outcomes as varied as their designs. Advantages and disadvantages of each particular device is best managed by the operating

surgeon. Arthrodesis of the wrist remains a viable final alternative and is usually reserved for malunited fractures of the carpal scaphoid and other complex pathology. However, the fact remains that a thorough H&P and early intervention with a skilled physician will allow a patient the greatest chance of a successful outcome by preventing more advanced disease.

4. Osteoarthritis of the carpometacarpal joint

Though the thumb carpometacarpal (CMC) joint is technically located in the hand, its close proximity to the carpal bone often implicates it as a pain generator when differentiating different causes of chronic wrist pain. Osteoarthritis(OA) of the thumb carpometacarpal (CMC) joint can cause debilitating pain and decreased strength and range of motion, making it difficult to do even the most common household tasks such as turning door-knobs or opening jars. CMC arthritis is the 2nd most common arthritic condition of the hand and in incidence, is the second only to arthritis of the distal interphalangeal joint (DIP).(Wilder, Barrett et al. 2006) Furthermore, it is the most common upper extremity arthritis requiring surgical intervention. It commonly affects women in their 5th to 6th decade of life. Epidemiologic studies have shown that post menopausal women are more likely to develop this condition; radiographic CMC arthritis is present in 25% of men and 40% of women over the age of 75. (Van Heest and Kallemeier 2008)

The thumb CMC is a biconcave-convex "saddle" joint that consists of the articular surfaces of the distal trapezium and the proximal thumb metacarpal. The unique nature of the joint allows for flexion, extension, abduction, adduction, and oppositional movements. Stability of the joint is provided primarily by the bony structures and several key ligaments: anterior oblique, posterior oblique, dorsoradial, palmar oblique, ulnar collateral, and intermetacarpal ligaments. The dorsoradial ligament, one of the thickest CMC ligaments, prevents excessive dorsoradial translation while the intermetacarpal prevents radial translation. Excess pronation, abduction, and extension of the thumb are prevented by the palmar oblique or "beak" ligament which has been regarded as the most important stabilizing structure.(Sung and Akelman 2009) Interestingly, this unique ability and movement of the thumb has been implicated in the pathophysiology of thumb CMC osteoarthritis.

However, the specific etiology of CMC arthritis has yet to be published. Currently, experts believe that the pathogenesis is multifactorial. Genetic and environmental factors, hypermobility of the joint, ligament laxity, anatomic variations, and extrinsic trauma have all been implicated. It has been suggested that genetic influences play a role in the development of CMC arthritis, but its exact pathway has yet to be determined.(MacGregor, Li et al. 2009) Increased joint laxity has been associated as studies have shown that radial subluxation of the base of the thumb CMC joint from the trapezium predisposes patients to developing osteoarthritis of the joint.(Hunter, Zhang et al. 2005) Women have higher incidence of thumb CMC osteoarthritis, possibly suggesting hormonal influences (prolactin, relaxin, and estrogen) as mechanisms for hypermobility and increased joint laxity. (Sung and Akelman 2009). In addition to this, cadaveric studies have shown that women also have a smaller, less congruous trapezium that along with hypermobility and joint laxity contribute to increased stress on the joint.(North and Rutledge 1983; Ateshian, Rosenwasser et al. 1992) It is this increased focal and loading stress on joint cartilage which is believed to be the instigating event. Furthermore, pinching and gripping generate large loads across the CMC joint and may explain why people who actively sew and knit develop arthritis at a higher rate. (Cooney and Chao 1977) Increased body mass index (BMI) has also been

associated with higher rates of CMC arthritis as it is believed increased BMI generates a higher biomechanical load.(Haara, Heliovaara et al. 2004) Finally, prior extrinsic trauma such as a Bennett fracture can predispose an individual to developing OA of the CMC joint and contribute to increased joint laxity and altered biomechanics.(Sung and Akelman 2009) Overall, it is difficult to ascertain one specific cause or risk factor for developing osteoarthritis of the CMC joint; rather, it is important to view the pathophysiology as multifactorial as ongoing research continues to develop and clarify the picture.

Symptomatic patients typically present with diffuse pain around the thenar eminence and perhaps on the dorsum of the thumb base which is exacerbated by pinching and grasping activities. Including the previously mentioned examples, turning the key or holding onto a large jar are often activities that illicit pain. Early in the disease, stiffness and loss of motion are not the primary complaints. As the disease progresses, both symptoms can occur as osteophytes limit motion resulting in a subluxed joint that is adducted, dorsally fixed, and has limited palmar abduction. Chronic stiffness can lead to changes in the metacarpophalangeal (MCP) joint resulting in hyperextension to compensate for the proximal loss of motion and loss of the thumb index web space.(Sung and Akelman 2009) Advanced disease may have dorsoradial subluxation of the first metacarpal on the trapezium termed the “shoulder sign”.

Physical examination demonstrates tenderness to palpation over the dorsal or dorsoradial aspect of the thumb. Erythema, edema, and calor may be present but is not a prerequisite for diagnosis. The “grind test” is performed by rotation the thumb metacarpal while applying axial compression. It is considered positive if there pain with or without crepitus. The test has a high specificity (80-93%) and moderate sensitivity (42-53%) making it useful in confirming the diagnosis of CMC osteoarthritis.(Merritt, Roddey et al. 2010)

Radiographic imaging is the most useful initial study to evaluate and stage CMC osteoarthritis. In the majority of cases posterioranterior, lateral, and oblique views are all that are necessary. A stress view of both thumb CMC joints taken together as the patient pushes their thumb tips together can help assess the degree of joint space loss, but is not required.(Eaton and Littler 1973) The contralateral hand should also be imaged for comparative purposes. There are two major classification systems used for staging. The Eaton staging system is the most widely used and is based on degenerative changes noted on the radiographs. Stage 1 has normal articular cartilage with possible mild narrowing of the joint space secondary to joint effusion or ligament laxity. Stage 2 disease has narrowing of the joint space associated with subchondral sclerotic changes and the possibility of osteophyte formation <2 mm. Mild to moderate subluxation of the thumb on the trapezium radially and dorsally may also be present. Stage 3 involves significant joint space narrowing with cystic and sclerotic changes with osteophytes larger than 2 mm. Stage 4 represents advanced degenerative changes of the CMC joint along with clear evidence scapho-trapezio-trapizoidal (STT) joint destruction. It has also been shown that pain and stiffness do not exactly correlate with radiographic findings.(Eaton and Glickel 1987) The Burton system uses clinical signs, symptoms, and radiographic evidence of disease and can also be used.

The differential diagnosis for pain around the base of the thumb also includes de Quervain tenosynovitis, flexor carpi radialis (FCR) tendonitis, radioscapoid pathology, and carpal tunnel syndrome. Patients with de Quervain tenosynovitis will have tenderness at the tip of the radial styloid and 1st extensor compartment and may have a positive Finkelstein’s test. FCR tendonitis would elicit pain with flexion of the wrist and tend to be more ulnar compared to CMC osteoarthritis. Fracture or arthritis of the scaphoid bone can present similarly and a detailed history and physical investigating for recent trauma is essential in

differentiating the diagnosis. Finally, close to 40% of patients with CMC arthritis had concomitant carpal tunnel syndrome, making it important to diagnose to eliminate additional operations as both conditions can be repaired simultaneously.(Florack, Miller et al. 1992) Likewise, this condition is associated with concomitant arthritis of other carpal joints in the hand such as STT joint. Many times, corticosteroid intra-articular injections can help differentiate between different potential conditions based on subsequent pain relief.

Initial treatment should focus on behavior modification, NSAIDS, and rest. Also, all patients should undergo a trial of conservative management including occupational therapy, splinting, and steroid injections. Occupational therapy should focus on strengthening the surrounding muscles to support the joint while stretching to maximize range of motion. Splinting can reduce the focal and load stress on the joint. The effectiveness of corticosteroid injections is widely debated with several studies demonstrating conflicting conclusions.(Day, Gelberman et al. 2004; Meenagh, Patton et al. 2004; Khan, Waseem et al. 2009; Swindells, Logan et al. 2010) A combination of these two treatments has shown to be effective in stage I and stage II disease.(Swigart, Eaton et al. 1999) As the disease progresses and the joint undergoes further degenerative changes the results of this treatment modality becomes less predictable. A recent study in 2009 also demonstrated hylan injections as an alternative to corticosteroid with equal efficacy.(Heyworth, Lee et al. 2008)

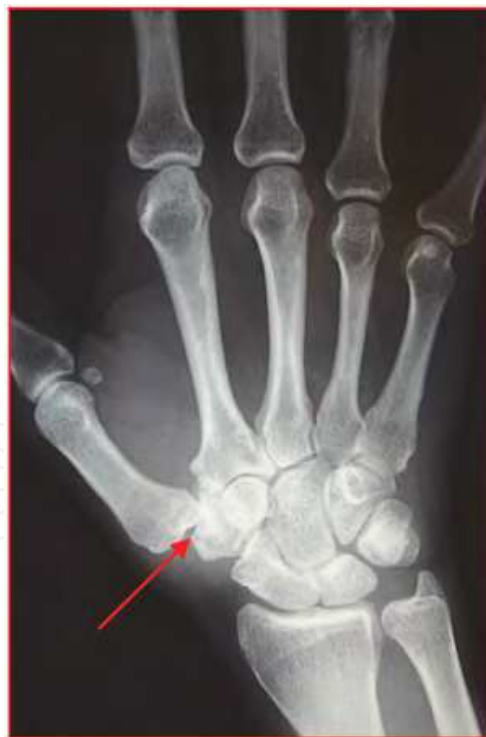

Fig. 6. PA Radiograph of Thumb CMC Arthritis

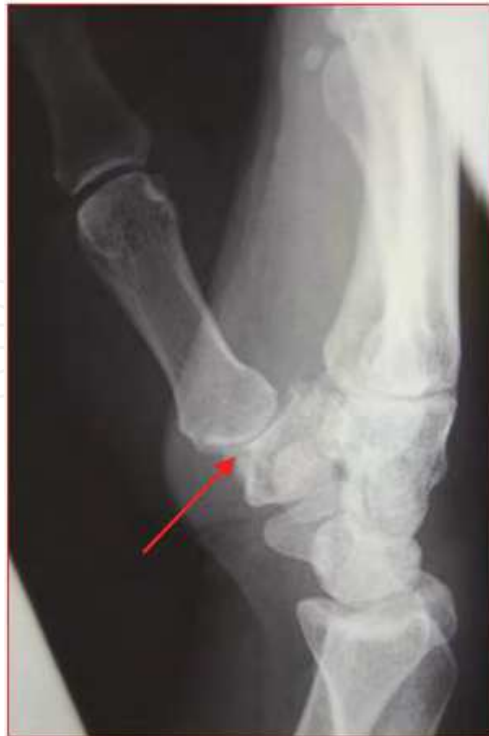

Fig. 7. Lateral Radiograph of Thumb CMC Arthritis

Surgical treatment should be considered when conservative measures have failed to relieve pain and improve day to day thumb function. Various options exist and it is therefore essential to engage the patient in an informed two-way discussion regarding the relative merits and drawbacks of each alternative. Patients with stage 1 or 2 disease have shown good outcomes with arthroscopy, metacarpal extension osteotomy, and volar ligament reconstruction. Arthroscopy is minimally invasive and allows for direct visualization of the articular surface and has been shown to be effective for the treatment of early osteoarthritis of the thumb CMC (Badia and Khanchandani 2007). Likewise, metacarpal extension osteotomy can correct the alignment of the thumb and transfer the load from the diseased palmar compartment to the normal dorsal compartment of the trapezium. (Pellegrini, Parentis et al. 1996) Eaton and Littler have well described a volar ligament reconstruction using part of the FCR tendon and have shown excellent results in 100% of patients with stage 1 and 82%-91% of patients with stage 2 disease. (Eaton, Lane et al. 1984; Freedman, Eaton et al. 2000).

For advanced disease, many surgical options exist: arthrodesis, implant arthroplasty, or resection arthroplasty with or without ligament reconstruction and tendon interposition. Arthrodesis of the thumb CMC joint provides pain relief and a strong and stable thumb for pinch and grasp activities. Disadvantages of the procedure include the risk of nonunion and altered biomechanics (Carroll and Hill 1973) Historically, surgeons have recommended this procedure to younger patients with high demanding jobs post traumatic injury; however, due to the recent success of arthroplasty this procedure may be falling out of favor. All the arthroplasty procedures involve either a full or partial trapeziectomy. Implant arthroplasty have used materials such as silicone, zircon, cerium, and titanium. All have their respective disadvantages from efficacy to side effects. (Sung and Akelman 2009) Total prosthetic joint arthroplasty is a promising field and further research need to assess reproducibility and long term risks and benefits. (Ulrich-Vinther,

Puggaard et al. 2008) Currently, the gold standard is resection arthroplasty with or without ligament reconstruction and tendon interposition. This procedure requires a complete trapeziectomy.(Tomaino 2006; Mathoulin, Moreel et al. 2008; Sammer and Amadio 2010) On the other hand, there are studies that show that ligament recreation provides no further benefit and that trapeziectomy alone is the best and safest operation. (Wajon, Ada et al. 2005; Field and Buchanan 2007) Further studies need to be conducted to clarify this promising therapeutic modality.

In addition to the thumb CMC joint, osteoarthritis of the second or third CMC joint can also cause significant wrist pain. Osteoarthritis of these joints is less common than thumb CMC arthritis. Typically, patients present with dorsal wrist pain and a bony prominence over the CMC joint that is often misdiagnosed as an isolated dorsal ganglion. Generally, repeated subacute trauma from extensive radial or ulnar deviation causes degenerative changes and carpal bossing of the CMC joint. Nonsurgical options consist of rest, NSAIDs, splinting, and intra-articular corticosteroid injections. Surgical options include boss excision and arthrodesis.

Thumb carpometocarpal osteoarthritis is one of the most common orthopaedic conditions a hand surgeon will face. The Eaton classification aids in stratifying the treatment regimen. Patients with early degenerative disease may benefit greatly from a regimen combining intra-articular corticosteroid injections and splinting. Several procedures exist for advanced disease and currently no one particular procedure has shown to be efficacious compared to another.(Wajon, Carr et al. 2009)

5. Osteoarthritis of the scaphotrapeziotrapezoid joint

Scaphotrapeziotrapezoid (STT) arthritis is the second most common degenerative disease of the wrist and often is linked with thumb CMC arthritis due to its close anatomical location. Isolated STT arthritis can also exist and it has been reported in 15% of wrist radiographs and 21% of cadaveric wrists.(Watson and Ballet 1984; Viegas, Patterson et al. 1993). Higher incidence rates have also been published and it is believed that the age of the cadavers may explain the differences in values. (Bhatia, Pisoh et al. 1996; Wollstein and Carlson 2009) Therefore, due to differences between radiographic findings and clinical symptoms, the exact incidence of isolated STT arthritis is unknown. There appears to be a gender bias as it commonly affects postmenopausal women after the age of 50.(Moritomo, Viegas et al. 2000; Kapoutsis, Dardas et al. 2011)

The scaphoid is the largest bone in the proximal carpal row and is an important link between the proximal and distal wrist. It articulates with the distal radius, the lunate, the capitate, the trapezium, and the trapezoid. The trapezium articulates with the scaphoid and first metacarpal via the CMC joint. The trapezoid articulates with the trapezium, scaphoid, capitate, and second metacarpal. Moritomo et al. described the ligaments and biomechanics of the STT joint.(Moritomo, Viegas et al. 2000). The capitate-trapezium ligament originates from the trapezium and inserts into the volar waist of the capitates and deepens the socket of the STT joint acting as a labrum for the distal pole of the scaphoid while reinforcing the volar aspect of the joint capsule as well. The scaphotrapezial and trapeziotrapezoid ligament are two other volar ligaments that stabilize the joint. Dorsally, the dorsolateral STT ligament stabilizes and links the joint to the rest of the midcarpus. The function of the joint is to allow transfer of load from the thumb and radial hand to the scaphoid, capitate, and other carpal bones.

The exact etiology of STT arthritis is unknown; however, there are numerous studies investigating the biomechanics and bony morphology as the underlying mechanism for degenerative change. Moritomo et al. demonstrated that underdevelopment of the capitate-trapezium ligament has been associated with increased prevalence of STT arthritis. The trapezium trapezoid (TT) inclination measures the degree of bone coverage by the facets of each bone over the distal pole of the scaphoid. Degenerative changes of the STT joint were associated with a higher TT inclination suggesting that the trapezium and trapezoid are more palmar relative to the scaphoid in patients with STT arthritis. (Moritomo, Viegas et al. 2000) Interestingly, the morphology of other carpal bones, specifically the lunate, and its effects on wrist kinematics has also been associated with STT arthritis. Type I lunate morphology consist of lunates with a single distal articulation for the capitates, no articulation for the hamate, and a capitates to triquetrum (CT) distance of <2mm. Type II lunates had radial articulation for the capitates and a ulnar articulation for the hamate with a CT distance of ≥ 4 mm. McLean et al. demonstrated that patients with type II lunate morphology had significantly higher incidences of STT arthritis compared to type I lunates and hypothesized that the difference in morphology make type II lunates have comparatively restricted range of motion creating an environment for degenerative change. (McLean, Turner et al. 2009) Carpal instability such as dorsal intercalated segment instability (DISI) has also been associated with increased prevalence of STT arthritis. (Tay, Moran et al. 2007) Finally, STT arthritis has been associated with prior trauma to the joint and surrounding structures.

The patient typically presents with diffuse pain around the base of the thumb and thenar eminence. Generally, isolated STT arthritic pain tends to be more midline (ulnar) compared to CMC arthritis and has been reported as a deep aching pain that may not be associated with thumb motion. (Cannon, Pincus et al. 2008) The pain can be exacerbated by radial extension and flexion of the wrist.

Physical examination generally demonstrates tenderness to palpation of the STT joint. Erythema, edema, and calor rarely are present unless there is significant disease of the thumb CMC joint as well. There is often difficulty differentiating the two clinically even with the use of the grind test. (Tomaino, Vogt et al. 1999) Due to the difficulty in accurate assessment from the history and physical exam, radiography is essential in making the proper diagnosis.

Bilateral PA, lateral, and oblique views should be routinely obtained. Due to the plane of the STT joint, the oblique view appears to be the best study to evaluate the STT joint. Degenerative changes such as narrowing of the joint space between any of the scaphoid, trapezium, and trapezoid or presence of osteophytes signifies STT arthritis. Stress views of the thumb described earlier may also be beneficial. There have been several views that have been developed to specifically target the STT joint but have been difficult to readily obtain in practice. (Wollstein, Wandzy et al. 2005) Comparison should be made to the contra-lateral wrist. There have been some thoughts of using CT or MRI scan for evaluation of the STT joint, but there are no published studies or guidelines regarding their utility. Currently, there is no universal staging system. However, one such system has been proposed that describes the progression of the disease based on radiographic findings. In this categorization, stage I disease has joint space narrowing as compared to other intercarpal joints in the same hand with or without periarticular sclerosis. Stage II disease has the defining characteristics of stage I disease along with the presence of cysts and/or osteophytes. Finally, stage III disease demonstrates complete collapse of the joint. (Wollstein and Carlson 2009)

As previously mentioned, the differential diagnosis must include thumb CMC arthritis. In a cadaveric study, 46 % of patients with STT arthritis had concomitant thumb CMC arthritis. (North and Rutledge 1983) Many hand surgeons term concomitant STT and thumb CMC arthritis as pantrapezial arthritis. As result of its shared prevalence and clinical presentation, it is important to combine clinical exam with radiographic findings for the definitive diagnosis. De Quervain tenosynovitis can present similarly, but the tenderness would be at the tip of the radial styloid and along the 1st extensor compartment with a positive Finkelstein's test. Direct trauma to the STT joint as the primary pain generator should be investigated with a thorough and detailed history. Arthroscopy of the STT joint can be performed as a diagnostic procedure and palmar portal has been described as safe and efficacious. (Bare, Graham et al. 2003)

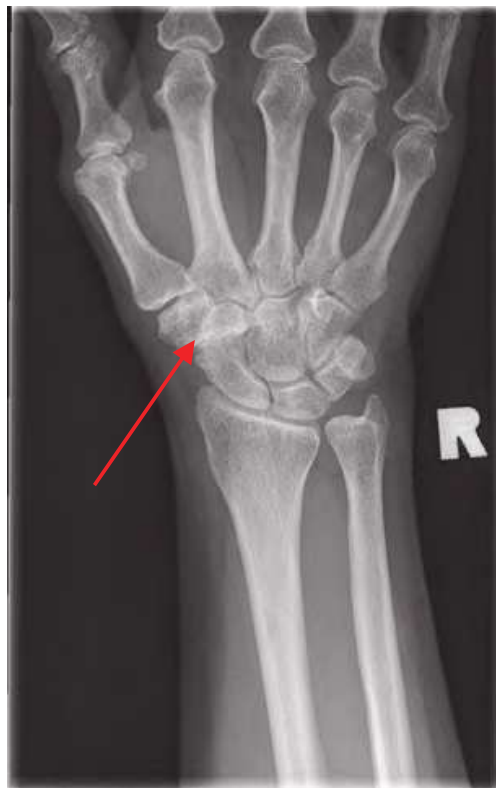

Fig. 8. PA Radiograph of STT Arthritis

Treatment of STT osteoarthritis should begin with nonoperative therapy. Behavior modification, NSAIDs, and rest are mainstay primary therapies. Splinting can especially be effective if there is concomitant thumb CMC arthritis. Intra-articular corticosteroids have been shown to be effective along with splinting for thumb CMC arthritis but there is paucity of data regarding its utility specifically for isolated STT arthritis.

Several operative techniques for management of STT arthritis exist including arthrodesis, resurfacing, and arthroplasty with or without implant. Historically, fusion of the STT joint has been the most common progression of treatment after failed conservative management. STT arthrodesis has been indicated for the treatment of isolated STT arthritis, scapholunate instability, and Kienbock disease. Nonunion complications are generally a concern with arthrodesis and Watson et al reported overall nonunion rate of 4% for STT arthrodesis and specifically 2% for patients whose primary indication was STT arthritis. They also report

good functionality in terms of wrist mobility, grip, key, and tip pinch strength compared to the unaffected side.(Wollstein and Watson 2005) Several technical aspects of the procedure have been shown to be associated with optimal results. The surgeon must thoroughly denude the articular surfaces of cartilage. As the joint is decorticated, the original joint height must be maintained and packed with bone graft from iliac crest or distal radius. The fusing of the scaphoid should be at an angle of 55 to 60 degrees of palmar flexion relative to the long axis of the radius as seen in a lateral radiograph. A radial styloidectomy is necessary and the postoperative protocol consists of long arm cast for 3 weeks followed by a short arm thumb spica cast for an additional 3 weeks. In addition to nonunion other reported complications include reflex sympathetic dystrophy and radial styloid impingment.(Wolf 2008)

Resection arthroplasty refers to excision of 3 to 4 mm of the distal articulation of the scaphoid with or without interposition via the flexor carpi radialis (FCR) tendon. (Garcia-Elias, Lluch et al. 1999) This procedure is an alternative to STT arthrodesis and allows for pain control, improvement of symptoms, and requires less postoperative immobilization.(Weiss and Rodner 2007) The concern with this surgical procedure is the risk of creating carpal instability that can lead to arthritis of other joints in the hand and wrist. Arthroscopic techniques have also been described.(Bare, Graham et al. 2003)

Implant arthroplasty is another option for surgical treatment of the STT joint. Silicone implants have been used in the past and shown to be effective, especially for the treatment of the PIP joint. It is believed that silicone cannot withstand the same amount of compressive forces as bone and therefore prone to fragmentation and development of silicone synovitis.(Swindells, Logan et al. 2010) As a result, different implants such as pyrocarbon and degradable polyurethane spacers have been used. Pyrocarbon implants have elastic properties similar to cortical bone and therefore may allow for better transfer of stress load.(Cook, Klawitter et al. 1981) Preliminary studies have shown significant promise for the use of pyrocarbon implants for the treatment of STT arthritis; however, these studies have been limited for sample size and length of follow up.(Pequignot, D'Asnieres de Veigy et al. 2005; Low and Edmunds 2007). Studies for arthroplasty with a polyurethane spacer (Artelon) are undergoing and perhaps a promising avenue for future treatment.

STT arthritis is the second most common degenerative disease of the wrist and often coexists with thumb CMC arthritis. Patients present with deep pain along the base of the thumb and medial wrist that is exacerbated by flexion and extension. Radiographic imaging is essential in determining the diagnosis. Conservative management should be with activity modification, NSAIDs, and rest. Splinting and intra-articular corticosteroid injections may also be of benefit to some patients. Surgical management includes arthrodesis, resection arthroplasty, and implant arthroplasty with or without interposition.

6. Osteoarthritis of the radiolunate and radioscapoid joint

Arthritis at the radiolunate and radioscapoid joints is a rare phenomenon; however, three common causes are avascular necrosis (including Kienbock and Preiser's disease), post traumatic, and inflammatory. Inflammatory arthritis of the radiolunate and radioscapoid joint can occur; however, this discussion focuses on degenerative osteoarthritis of the wrist.

6.1 Kienbock disease

Kienbock disease, also known as avascular necrosis of the lunate, is another rare cause of osteoarthritis of the wrist. The classical disorder was first described in 1910 by the radiologist Robert Kienbock who, after a series of clinical and radiographic studies, defined a distinct symptomatology of volar wrist pain with isolated degeneration of the lunate that he termed lunatomalacia. (Kienbock 1910) Despite a century of research, the exact etiology and pathophysiology of this disease is unknown.

Currently, there are many factors implicated in the pathophysiology of Kienbock disease and it is likely a combination of these factors that lead to its progression. Primary causes are generally divided into mechanical and vascular factors. Mechanical factors may be due to the local anatomy of the lunate and wrist and uneven distribution of stress and loading forces. Vascular factors imply that a primary disruption in circulation leads to secondary bony pathology.

Historically, negative ulnar variance has been implicated as a mechanical cause of Kienbock disease. Negative ulnar variance refers to the presence of a shortened ulna compared to the radius in terms of distal articular surface. It is believed that a short ulna cannot share axial loads with the radius and therefore increases the amount of stress across the lunate. (Hulten 1928) However, there are studies that also report no association between negative ulnar variance and Kienbock disease. (Gelberman, Bauman et al. 1980; Chen and Shih 1990; D'Hoore, De Smet et al. 1994) A meta-analysis in 2001 demonstrated that many of these previous studies were under powered and had flawed study designs. They concluded that patients with negative ulnar variance were 3.1 times more likely to develop Kienbock disease; however there was no statistical significance. Other mechanical factors associated with the development of Kienbock disease include: the size and shape of the lunate, "radiolunate coverage index", and persistent trauma. Smaller sized lunates and type II shaped lunates are associated with the disease. Patients with a smaller contact area between the radius and lunate have a smaller "radiolunate coverage index" and a higher association with Kienbock disease. Finally, patients with repeated trauma or fracture to the joint may have a higher association to the disease, possibly due to compromise of the vasculature. (Tsuge and Nakamura 1993; Irisarri 2004; Lluch and Garcia-Elias 2011)

Vascular impairment can be either at the external vascular net that supplies the lunate or at the small vessels that penetrate the subchondral bone. Studies have shown that lunates typically have two nutrient supplying vessels. It has been postulated that patients with Kienbock disease have either 1 supplying vessel or a decreased amount of penetrating interosseous branches. (Lluch and Garcia-Elias 2011) The mechanism of injury to these vessels is not known. Lack of blood supply causes necrosis of the bone with subsequent remodeling by osteoclasts and osteoblasts. This remodeling can cause degenerative change and ultimately collapse of the lunate. (Lluch and Garcia-Elias 2011) Other potential causes associated with Kienbock disease include coagulation disorders such as sickle cell disease, long term steroid use, and venous congestion. (Nagasawa, Ishii et al. 1989; Glueck, Freiberg et al. 2008; Lluch and Garcia-Elias 2011)

Patient will typically present with dorsal wrist pain, decreased flexion-extension range of motion, and poor grip strength. Local swelling and tenderness of the lunate may be present, especially as the disease progresses. Radiographic imaging is necessary for the definitive diagnosis. MRI has shown to be more useful in diagnosis and the monitoring of treatment while plain radiographs are best used for staging.

Stage I disease demonstrates mild pain, normal radiographs, and early degenerative changes on MRI. Stage II disease presents with increased pain, edema, and radiographs show increased lunate density. Stage III is divided into IIIA and IIIB. In stage IIIA radiographs show lunate collapse without scapholunate instability while stage IIIB disease shows lunate collapse with scapholunate instability. Stage IV is characteristic of pancarpal arthrosis. (Saunders and Lichtman 2011)

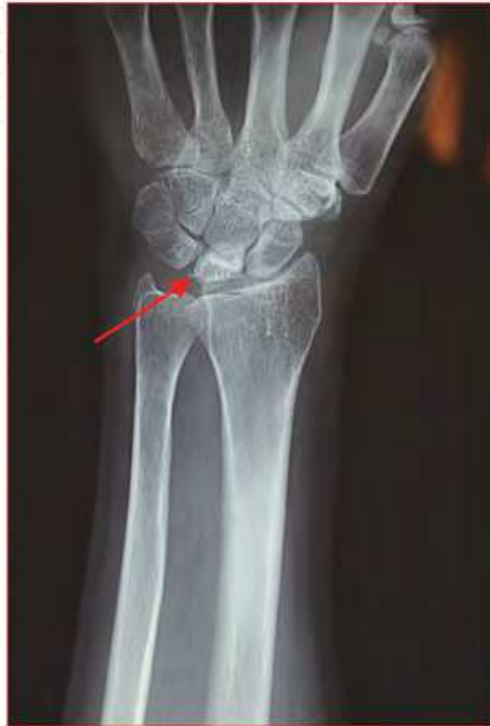

Fig. 9. PA Radiograph of Kienbock Disease

Current treatment recommendations are based on the classification system. Stage I disease is treated with rest, NSAIDs, and possible 3-6 month periods of immobilization. Stage II can be managed conservatively or surgically via radial and capitate osteotomies and lunate revascularization procedures. Radial and capitate osteotomies can change loading forces across the joint and lunate revascularization by transferring a vascularized pedicle with bone from the pisiform or distal radius has shown to be effective. (Shin and Bishop 2002) Stage IIIA is managed with osteotomies and revascularization procedures similar to surgical options for stage II disease. Stage IIIB disease requires procedures that result in increased stability of the joint and therefore scaphocapitate and STT fusion techniques are preferred. Stage IV disease requires salvage procedures such as total wrist arthrodesis, arthroplasty, or proximal row carpectomy. (Saunders and Lichtman 2011) Patients with negative ulnar variance can undergo radial shortening and ulnar lengthening procedures. Currently, no single surgical procedure has shown to be superior. (Delaere, Dury et al. 1998)

Early diagnosis of Kienbock disease may help prevent progression as we continue to investigate the utility of bisphosphonates, stem cells, and prophylactic surgical intervention. The use of gadolinium infused MRI and "lunate stress tests" are techniques that may allow diagnosis at "stage 0" similar to that of osteonecrosis of the femoral head. (Saunders and

Lichtman 2011) Kienbock disease remains a partial enigma to physicians despite being known for over a century. However, as researchers continue to investigate its etiology and develop treatment modalities, the future looks promising.

6.2 Preiser's disease

Similar to Kienbock disease, avascular necrosis of the scaphoid is termed Preiser's disease. The exact epidemiology of Preiser's disease is unknown, but it is considered even rarer than Kienbock disease. Furthermore, the exact etiology is unknown; however, physicians often imply a shared pathophysiology similar to Kienbock disease. Patients generally present with dorsoradial wrist pain, limited range of motion, and possible joint swelling and erythema. Patients may have tenderness to palpation along the anatomic "snuff" box. Diagnosis is confirmed with radiographs or MRI. Currently, a classification does not exist, perhaps due to the low incidence of the disease. Treatment options are similar to Kienbock disease and begins with conservative therapy of immobilization, NSAIDs, splinting, and intra articular injections. Surgical options include revascularization procedures, proximal row carpectomy, and four corner's fusion with scaphoid resection(Amillo-Garayoa, Romero-Munoz et al. 2011).

6.3 Post distal radius fracture

Fracture of the distal radius is one of the most common fractures in orthopaedics and can often cause joint instability and subsequent osteoarthritis. There are various surgical and nonsurgical options for the treatment of a distal radius fracture. Complications may arise from the traumatic injury and/or method of treatment, leading to osteoarthritis of the radiolunate and radioscapoid joint.

Osteoarthritis generally develops due to incongruity between joint surfaces. Furthermore, there is a potential for abnormal loading forces across a misaligned and unstable joint causing joint step off. Over time, this wear and tear can cause degenerative changes and osteophyte formation. Post traumatic chondromalacia has also been implicated as a potential cause of osteoarthritis status post distal radius fracture due to compression of the articular cartilage.

Patients typical with pain and tenderness near the radioscapoid and radioulnar joint. Previous history of distal radial fracture, clinical presentation, and radiographs help confirm the diagnosis. Pathology of the radiolunate joint differentiates this disorder from a SLAC/SNAC wrist where the radiolunate joint is preserved. Treatment options include conservative management with NSAIDs, splinting, physical therapy, and intra articular injections. Surgical options include denervation, total wrist fusion, wrist arthroplasty and variations of intercarpal arthrodesis. (Nagy 2005; Handoll, Huntley et al. 2008)

7. Osteoarthritis of the pisotriquetral joint

Pisotriquetral (PT) arthritis is a relatively uncommon diagnosis. It is thought to be the result of PT joint instability which can occur after injury to the pisiform ligament complex (PLC) which serves to stabilize the PT joint. Injury to these PT joint stabilizers are what could predispose a patient to degenerative joint disease (Rayan, Jameson et al. 2005). Such a ligament injury is either found in the acute setting after a fall onto an outstretched hand, or is associated with a more chronic repetitive motion-type injury.

The pisiform is a sesamoid bone, nearly spherical in shape, which can be found within the fibers of the flexor carpi ulnaris tendon and articulates with the triquetrum. The pisiform forms the medial wall to Guyon's canal and is itself bordered medially by the dorsal retinaculum. The pisiform ligament complex is composed of those ligaments that stabilize the pisiform, namely the pisometacarpal, pisohamate, radial pisotriquetral, ulnar pisotriquetral and transverse carpal ligaments (Rayan, Jameson et al. 2005). Its blood supply is obtained via the proximal and distal poles which contain branches from the ulnar artery. The ulnar nerve lies just radially to the pisiform in most instances. The PT joint is ensheathed by a joint capsule that sometimes communicates with the proximal wrist joint (Viegas, Patterson et al. 1993).

The pathogenesis of PT joint pain can originate from several sources. In a study by Paley et al, it was noted that out of 216 cases of PT pain, primary osteoarthritis only contributed to a minority of the findings (2.3%) while secondary osteoarthritis and flexor carpi ulnaris enthesopathy contributed 48.4% and 44.6% respectively (other arthritides comprised the remaining 4.7%) (Paley, McMurtry et al. 1987). Fractures, tumors, ganglions and congenital malformations have also been noted to contribute to ulnar volar pain (Kernohan, Beacon et al. 1985) (Chen, Barnwell et al. 2011) (El-Morshidy, Rabia et al. 2000). Loose bodies as well as PT arthrosis secondary to a triquetral fracture malunion have also been documented (Steinmann and Linscheid 1997) (Aiki, Wada et al. 2006). Finally, a recent case series has also made the suggestion that PT arthritis can develop after an intercarpal arthodesis (Gaston, Lourie et al. 2007). These clinical entities should be considered in a patient's work-up because they each require a distinct treatment plan to alleviate pain.

It has been hypothesized that injury to the PLC results in PT joint instability and a subsequent arthritis (Rayan, Jameson et al. 2005). Trauma is a likely cause of injury and there are multiple studies that describe a carpal injury that specifically resulted in the dislocation of the pisiform (Goriainov, Bayne et al. 2010) (Matsumoto, Tsunoda et al. 2005). Direct force to the volar hand is the most likely culprit resulting in ligament injury and pisiform subluxation. The insult can be an acute fall on an outstretched hand or it can be the result of a chronic occupational exposure or racket-sport activity. Regardless of the cause, instability begets incongruity and abnormal wearing of the PT joint takes place and causes arthritis.

Presentation of a patient with PT joint pathology typically takes the form of either a chondromalacia, osteoarthritis or flexor carpi ulnaris tendinopathy. Patients will present with a palmar ulnar wrist pain. Exam findings of tenderness in the soft tissues distal and radial to the pisiform as well as an ulnar volar pain that is provoked by passive wrist extension are all consistent with a diagnosis of PT instability. The pisiform tracking test is a useful to elicit PT instability: with the wrist in a fully flexed position, the examiner applies pressure to the pisiform in both a radial and ulnar direction (Hoepfner 2009). Crepitance and pain during this maneuver indicate PT pathology. Also, flexor carpi ulnaris tendinopathy (indicated by tenderness to palpation along the FCU tendon) may or may not coexist with PT dysfunction. In fact, there have been documented cases of FCU rupture in the setting of PT osteoarthritis (Corten, van den Broecke et al. 2004). It is thought that the PT arthritis resulted in impingement and attenuation of the FCU, causing its rupture.

Radiographic analysis can be useful to supplement the physical exam findings. Several semilateral wrist views including (1) full wrist extension and forearm supination of 30 degrees, (2) neutral wrist position with 30 degrees of forearm supination, (3) active and (4)

passive full wrist flexion, and (5) a 45 degree of forearm supination with thumb fully abducted will all be needed to isolate this joint (Jameson, Rayan et al. 2002). Dynamic fluoroscopy can also be a useful tool to isolate the PT joint radiographically and determine its “normal” position. A diagnosis of PT pathology may be confirmed with PT joint injection. Other diagnoses to consider should include triangular fibrocartilage complex tears, ulnar impingement, lunotriquetral dysfunction, distal radioulnar joint subluxation, fracture/nonunion of the hook of hamate and ulnar artery thrombosis.

Like many of the arthritic joint conditions, PT pathology can be treated medically with wrist splints that maintain a neutral position, NSAIDs, and intra-articular steroid injections. Only when a patient’s pain is refractory to these therapies, should surgery be considered. Although PT instability is what leads to the joint degeneration, clinically, we do not attempt to stabilize the pisiform by repairing the ligaments of the PLC. Instead, excision of the pisiform has been used to treat this condition for many years (Carroll and Coyle 1985) (Gomez, Renart et al. 2005) and has consistently provided pain relief without any functional limitations. There have been case reports, however, that promote the use of PT arthrodesis in patients who have more high demand wrists (Abrams and Tontz 2006) (Singer, Eberl et al. 2011). Although this does not represent the current trend in treating PT pathology, with further study, it could serve as a promising alternative to pisiform excision.

In short, PT arthritis may not be a very common cause of ulnar-sided wrist pain, but it can be a very debilitating condition when present. It likely results from an instability due to an imbalance in the complex ligamentous attachments that keep the pisiform suspended in its proper orientation. When evaluating a patient for PT arthritis, the astute physician will keep a high clinical suspicion for the array of conditions that could mimic this type of wrist pain. Pisiform excision remains a very successful surgery for those patients who fail splinting, anti-inflammatories, and injection treatments.

8. Summary

Osteoarthritis of the wrist and hand can be a painful and debilitating disease. This chapter focused on the various causes, clinical presentations, and treatment options of wrist osteoarthritis. Many times evaluation of a patient with wrist pain reveals an extensive differential diagnosis. While obtaining the history, special attention should be focused on the patient’s age, hand dominance, location and quality of the pain, aggravating and relieving factors, prior trauma history, occupation, hobbies, and limb function. Physical exam and palpation of the carpus and hand is essential to identify and localize the pain source. Special maneuvers such as the grind and shift test can help navigate the differential diagnosis and identify the pathologic joint. Ultimately, radiographic imaging can be used for definitive diagnosis and staging the progression of the disease.

SLAC and SNAC wrists are common degenerative patterns seen in osteoarthritis of the wrist and typically present with dorsal wrist swelling and periscaphoid tenderness. Pain and decreased range of motion with pronation and supination is typically indicative of arthritis of the DRUJ joint. Patients with arthritis of the thumb CMC and STT joint present with pain over the thenar eminence that is exacerbated by pinching and grasping activities. Kienbock disease can also present with dorsal wrist pain similar to SLAC wrist; however, the swelling and tenderness is along the lunate. In our discussion of wrist arthritis, degenerative change of the PT joint is the final cause of wrist pain and patients typically present with palmar ulnar pain.

Conservative management should be tried on all patients with wrist pain, especially if the disease is identified early in its progression. Rest, NSAIDs, behavior modification, occupational therapy, splinting, and intra-articular corticosteroid injections are all options that have shown different degrees of efficacy. Furthermore, intra-articular injections can be used as a final tool in differentiating the diagnosis.

Many different surgical options exist for the treatment of advanced degenerative disease. The common goal of surgical treatment is to remove the pain source when possible and stabilize the joint and its surrounding structures. Osteotomies, revascularization techniques, arthroscopy, resection arthroplasty, implant arthroplasty, and arthrodesis are some of the more common procedures used to treat the various arthropathies of the wrist. Physicians and patients must have an interactive discussion regarding the individual merits and drawbacks of each alternative to determine which procedures maximize recovery potential. Surgeons continue to refine and develop new techniques as arthroscopy and total joint arthroplasty of the small joints in the hand and wrist become more common. As long term data regarding the efficacy of each procedure becomes more available, the "best" procedure for each disease may be determined. Research in the 21st century is currently focused on novel treatment methods including gene therapy, cartilage regeneration, and identification of specific etiologic factors that cause osteoarthritis of the wrist. With time, this may allow the physician to prevent the development and progression of the disease altogether.

9. References

- Abrams, R. and W. Tontz (2006). "Pisotriquetral arthrodesis as an alternative to excision for pisotriquetral instability in high-demand patients: a case report in a gymnast." *The Journal of hand surgery* 31(4): 611-614.
- Adams, B. D. (1993). "Effects of radial deformity on distal radioulnar joint mechanics." *The Journal of hand surgery* 18(3): 492-498.
- af Ekenstam, F. and C. G. Hagert (1985). "Anatomical studies on the geometry and stability of the distal radio ulnar joint." *Scandinavian journal of plastic and reconstructive surgery* 19(1): 17-25.
- af Ekenstam, F. W., A. K. Palmer, et al. (1984). "The load on the radius and ulna in different positions of the wrist and forearm. A cadaver study." *Acta orthopaedica Scandinavica* 55(3): 363-365.
- Aiki, H., T. Wada, et al. (2006). "Pisotriquetral arthrosis after triquetral malunion: a case report." *The Journal of hand surgery* 31(7): 1157-1159.
- Amillo-Garayoa, S., L. M. Romero-Munoz, et al. (2011). "Bilateral Preiser's disease: a case report and review of the literature." *Musculoskeletal surgery*.
- Ashmead, D. t., H. K. Watson, et al. (1994). "Scapholunate advanced collapse wrist salvage." *The Journal of hand surgery* 19(5): 741-750.
- Ateshian, G. A., M. P. Rosenwasser, et al. (1992). "Curvature characteristics and congruence of the thumb carpometacarpal joint: differences between female and male joints." *Journal of biomechanics* 25(6): 591-607.
- Badia, A. and P. Khanchandani (2007). "Treatment of early basal joint arthritis using a combined arthroscopic debridement and metacarpal osteotomy." *Techniques in hand & upper extremity surgery* 11(2): 168-173.

- Bare, J., A. J. Graham, et al. (2003). "Scaphotrapezial joint arthroscopy: a palmar portal." *The Journal of hand surgery* 28(4): 605-609.
- Bhatia, A., T. Pisoh, et al. (1996). "Incidence and distribution of scaphotrapezotrapezoidal arthritis in 73 fresh cadaveric wrists." *Annales de chirurgie de la main et du membre superieur : organe officiel des societes de chirurgie de la main = Annals of hand and upper limb surgery* 15(4): 220-225.
- Bisneto, E. N., M. C. Freitas, et al. (2011). "Comparison between proximal row carpectomy and four-corner fusion for treating osteoarthrosis following carpal trauma: a prospective randomized study." *Clinics* 66(1): 51-55.
- Braun, R. M. (1992). "The distal joint of the radius and ulna. Diagnostic studies and treatment rationale." *Clinical orthopaedics and related research*(275): 74-78.
- Breen, T. F. and J. B. Jupiter (1989). "Extensor carpi ulnaris and flexor carpi ulnaris tenodesis of the unstable distal ulna." *The Journal of hand surgery* 14(4): 612-617.
- Bruckner, J. D., A. H. Alexander, et al. (1996). "Acute dislocations of the distal radioulnar joint." *Instructional course lectures* 45: 27-36.
- Cannon, G. W., S. H. Pincus, et al. (2008). "Double-blind trial of recombinant gamma-interferon versus placebo in the treatment of rheumatoid arthritis. 1989." *Arthritis and Rheumatism* 58(2 Suppl): S79-88.
- Carroll, R. E. and M. P. Coyle, Jr. (1985). "Dysfunction of the pisotriquetral joint: treatment by excision of the pisiform." *The Journal of hand surgery* 10(5): 703-707.
- Carroll, R. E. and N. A. Hill (1973). "Arthrodesis of the carpo-metacarpal joint of the thumb." *The Journal of bone and joint surgery. British volume* 55(2): 292-294.
- Chen, C., V. P. Chandnani, et al. (1990). "Scapholunate advanced collapse: a common wrist abnormality in calcium pyrophosphate dihydrate crystal deposition disease." *Radiology* 177(2): 459-461.
- Chen, W. A., J. C. Barnwell, et al. (2011). "An ulnar intraneural ganglion arising from the pisotriquetral joint: case report." *The Journal of hand surgery* 36(1): 65-67.
- Chen, W. S. and C. H. Shih (1990). "Ulnar variance and Kienbock's disease. An investigation in Taiwan." *Clinical orthopaedics and related research*(255): 124-127.
- Cohen, M. S. and S. H. Kozin (2001). "Degenerative arthritis of the wrist: proximal row carpectomy versus scaphoid excision and four-corner arthrodesis." *The Journal of hand surgery* 26(1): 94-104.
- Cook, S. D., J. J. Klawitter, et al. (1981). "The influence of implant elastic modulus on the stress distribution around LTI carbon and aluminum oxide dental implants." *Journal of biomedical materials research* 15(6): 879-887.
- Cooney, W. P., 3rd and E. Y. Chao (1977). "Biomechanical analysis of static forces in the thumb during hand function." *The Journal of bone and joint surgery. American volume* 59(1): 27-36.
- Cooney, W. P., 3rd, J. H. Dobyns, et al. (1980). "Complications of Colles' fractures." *The Journal of bone and joint surgery. American volume* 62(4): 613-619.
- Corten, E. M., D. G. van den Broecke, et al. (2004). "Pisotriquetral instability causing an unusual flexor tendon rupture." *The Journal of hand surgery* 29(2): 236-239.
- Czermak, C., M. Wittemann, et al. (2007). "[Functional results after the Kapandji-Sauve operation for salvage of the distal radioulnar joint]." *Handchirurgie, Mikrochirurgie, plastische Chirurgie : Organ der Deutschsprachigen*

- Arbeitsgemeinschaft für Handchirurgie : Organ der Deutschsprachigen Arbeitsgemeinschaft für Mikrochirurgie der Peripheren Nerven und Gefäße : Organ der Vereinigung der Deutschen Plastischen Chirurgen 39(6): 403-408.
- D'Hoore, K., L. De Smet, et al. (1994). "Negative ulnar variance is not a risk factor for Kienbock's disease." *The Journal of hand surgery* 19(2): 229-231.
- Dacho, A., J. Grundel, et al. (2006). "Long-term results of midcarpal arthrodesis in the treatment of scaphoid nonunion advanced collapse (SNAC-Wrist) and scapholunate advanced collapse (SLAC-Wrist)." *Annals of plastic surgery* 56(2): 139-144.
- Dacho, A. K., S. Baumeister, et al. (2008). "Comparison of proximal row carpectomy and midcarpal arthrodesis for the treatment of scaphoid nonunion advanced collapse (SNAC-wrist) and scapholunate advanced collapse (SLAC-wrist) in stage II." *Journal of plastic, reconstructive & aesthetic surgery : JPRAS* 61(10): 1210-1218.
- Darrach, W. (1992). "Partial excision of lower shaft of ulna for deformity following Colles's fracture. 1913." *Clinical orthopaedics and related research*(275): 3-4.
- Day, C. S., R. Gelberman, et al. (2004). "Basal joint osteoarthritis of the thumb: a prospective trial of steroid injection and splinting." *The Journal of hand surgery* 29(2): 247-251.
- Delaere, O., M. Dury, et al. (1998). "Conservative versus operative treatment for Kienbock's disease. A retrospective study." *Journal of hand surgery* 23(1): 33-36.
- Dias, J. J., R. A. Rajan, et al. (2008). "Which questionnaire is best? The reliability, validity and ease of use of the Patient Evaluation Measure, the Disabilities of the Arm, Shoulder and Hand and the Michigan Hand Outcome Measure." *The Journal of hand surgery, European volume* 33(1): 9-17.
- Eaton, R. G. and S. Z. Glickel (1987). "Trapeziometacarpal osteoarthritis. Staging as a rationale for treatment." *Hand clinics* 3(4): 455-471.
- Eaton, R. G., L. B. Lane, et al. (1984). "Ligament reconstruction for the painful thumb carpometacarpal joint: a long-term assessment." *The Journal of hand surgery* 9(5): 692-699.
- Eaton, R. G. and J. W. Littler (1973). "Ligament reconstruction for the painful thumb carpometacarpal joint." *The Journal of bone and joint surgery. American volume* 55(8): 1655-1666.
- Edwards, G. S., Jr. and J. B. Jupiter (1988). "Radial head fractures with acute distal radioulnar dislocation. Essex-Lopresti revisited." *Clinical orthopaedics and related research*(234): 61-69.
- El-Morshidy, A. F., F. Rabia, et al. (2000). "Bilateral asymptomatic pisiform and hamate coalition--a case report." *Hand surgery : an international journal devoted to hand and upper limb surgery and related research : journal of the Asia-Pacific Federation of Societies for Surgery of the Hand* 5(1): 57-60.
- Fassler, P. R., P. J. Stern, et al. (1993). "Asymptomatic SLAC wrist: does it exist?" *The Journal of hand surgery* 18(4): 682-686.
- Field, J. and D. Buchanan (2007). "To suspend or not to suspend: a randomised single blind trial of simple trapeziectomy versus trapeziectomy and flexor carpi radialis suspension." *The Journal of hand surgery, European volume* 32(4): 462-466.

- Florack, T. M., R. J. Miller, et al. (1992). "The prevalence of carpal tunnel syndrome in patients with basal joint arthritis of the thumb." *The Journal of hand surgery* 17(4): 624-630.
- Freedman, D. M., R. G. Eaton, et al. (2000). "Long-term results of volar ligament reconstruction for symptomatic basal joint laxity." *The Journal of hand surgery* 25(2): 297-304.
- Friedman, S. L. and A. K. Palmer (1991). "The ulnar impaction syndrome." *Hand clinics* 7(2): 295-310.
- Fulkerson, J. P. and H. K. Watson (1978). "Congenital anterior subluxation of the distal ulna. A case report." *Clinical orthopaedics and related research*(131): 179-182.
- Garcia-Elias, M., A. L. Lluch, et al. (1999). "Resection of the distal scaphoid for scaphotrapeziotrapezoid osteoarthritis." *Journal of hand surgery* 24(4): 448-452.
- Gaston, R. G., G. M. Lourie, et al. (2007). "Pisotriquetral dysfunction following limited and total wrist arthrodesis." *The Journal of hand surgery* 32(9): 1348-1355.
- Gelberman, R. H., T. D. Bauman, et al. (1980). "The vascularity of the lunate bone and Kienbock's disease." *The Journal of hand surgery* 5(3): 272-278.
- Glueck, C. J., R. A. Freiberg, et al. (2008). "Heritable thrombophilia-hypofibrinolysis and osteonecrosis of the femoral head." *Clinical orthopaedics and related research* 466(5): 1034-1040.
- Golimbu, C. N., H. Firooznia, et al. (1989). "Tears of the triangular fibrocartilage of the wrist: MR imaging." *Radiology* 173(3): 731-733.
- Gomez, C. L., I. P. Renart, et al. (2005). "Dysfunction of the pisotriquetral joint: degenerative arthritis treated by excision of the pisiform." *Orthopedics* 28(4): 405-408.
- Goriainov, V., G. Bayne, et al. (2010). "Traumatic dislocation of the pisiform: a case report." *Journal of orthopaedic surgery* 18(3): 389-390.
- Haara, M. M., M. Heliövaara, et al. (2004). "Osteoarthritis in the carpometacarpal joint of the thumb. Prevalence and associations with disability and mortality." *The Journal of bone and joint surgery. American volume* 86-A(7): 1452-1457.
- Handoll, H. H., J. S. Huntley, et al. (2008). "Different methods of external fixation for treating distal radial fractures in adults." *Cochrane Database Syst Rev*(1): CD006522.
- Hauck, R. M., J. Skahan, 3rd, et al. (1996). "Classification and treatment of ulnar styloid nonunion." *The Journal of hand surgery* 21(3): 418-422.
- Heyworth, B. E., J. H. Lee, et al. (2008). "Hylan versus corticosteroid versus placebo for treatment of basal joint arthritis: a prospective, randomized, double-blinded clinical trial." *The Journal of hand surgery* 33(1): 40-48.
- Hildreth, D. H., W. C. Breidenbach, et al. (1989). "Detection of submaximal effort by use of the rapid exchange grip." *The Journal of hand surgery* 14(4): 742-745.
- Hulten, O. (1928). "Concerning anatomical variations of the carpal bones." *Acta Radiologica* 9: 155-168.
- Hunt, T. R., H. Hastings, 2nd, et al. (1998). "A systematic approach to handling the distal radio-ulnar joint in cases of malunited distal radius fractures." *Hand clinics* 14(2): 239-249.
- Hunter, D. J., Y. Zhang, et al. (2005). "Trapeziometacarpal subluxation predisposes to incident trapeziometacarpal osteoarthritis (OA): the Framingham Study."

- Osteoarthritis and cartilage / OARS, Osteoarthritis Research Society 13(11): 953-957.
- Irisarri, C. (2004). "Aetiology of Kienbock's disease." *Journal of hand surgery* 29(3): 281-287.
- Jameson, B. H., G. M. Rayan, et al. (2002). "Radiographic analysis of pisotriquetral joint and pisiform motion." *The Journal of hand surgery* 27(5): 863-869.
- Jupiter, J. B. and M. Masem (1988). "Reconstruction of post-traumatic deformity of the distal radius and ulna." *Hand clinics* 4(3): 377-390.
- Kakar, S., B. T. Carlsen, et al. (2010). "The management of chronic distal radioulnar instability." *Hand clinics* 26(4): 517-528.
- Kapoutsis, D. V., A. Dardas, et al. (2011). "Carpometacarpal and scaphotrapeziotrapezoid arthritis: arthroscopy, arthroplasty, and arthrodesis." *The Journal of hand surgery* 36(2): 354-366.
- Kernohan, J., J. P. Beacon, et al. (1985). "Osteoid osteoma of the pisiform." *Journal of hand surgery* 10(3): 411-414.
- Khan, M., M. Waseem, et al. (2009). "Quantitative Assessment of Improvement with Single Corticosteroid Injection in Thumb CMC Joint Osteoarthritis?" *The open orthopaedics journal* 3: 48-51.
- Kienbock, R. (1910). "Concerning traumatic malacia of the lunate and its consequences: joint degeneration and compression." *Fortsch Geb Roentgen* 16: 77-103.
- Lichtman, D. M., J. R. Schneider, et al. (1981). "Ulnar midcarpal instability-clinical and laboratory analysis." *The Journal of hand surgery* 6(5): 515-523.
- Liu, M., H. Zhou, et al. (2009). "Clinical evaluation of proximal row carpectomy revealed by follow-up for 10-29 years." *International orthopaedics* 33(5): 1315-1321.
- Lluch, A. and M. Garcia-Elias (2011). "Etiology of Kienbock disease." *Techniques in hand & upper extremity surgery* 15(1): 33-37.
- Low, A. K. and I. A. Edmunds (2007). "Isolated scaphotrapeziotrapezoid osteoarthritis: preliminary results of treatment using a pyrocarbon implant." *Hand surgery : an international journal devoted to hand and upper limb surgery and related research : journal of the Asia-Pacific Federation of Societies for Surgery of the Hand* 12(2): 73-77.
- MacGregor, A. J., Q. Li, et al. (2009). "The genetic influence on radiographic osteoarthritis is site specific at the hand, hip and knee." *Rheumatology* 48(3): 277-280.
- Malerich, M. M., J. Clifford, et al. (1999). "Distal scaphoid resection arthroplasty for the treatment of degenerative arthritis secondary to scaphoid nonunion." *The Journal of hand surgery* 24(6): 1196-1205.
- Mathoulin, C., P. Moreel, et al. (2008). "Abductor pollicis longus "hammock" ligamentoplasty for treatment of first carpometacarpal arthritis." *The Journal of hand surgery, European volume* 33(3): 292-297.
- Matsumoto, T., M. Tsunoda, et al. (2005). "Traumatic dislocation of the hamate and pisiform: a case report and review of the literature." *Journal of orthopaedic trauma* 19(4): 282-285.
- McLean, J. M., P. C. Turner, et al. (2009). "An association between lunate morphology and scaphoid-trapezium-trapezoid arthritis." *The Journal of hand surgery, European volume* 34(6): 778-782.

- Meenagh, G. K., J. Patton, et al. (2004). "A randomised controlled trial of intra-articular corticosteroid injection of the carpometacarpal joint of the thumb in osteoarthritis." *Annals of the rheumatic diseases* 63(10): 1260-1263.
- Merritt, M. M., T. S. Roddey, et al. (2010). "Diagnostic value of clinical grind test for carpometacarpal osteoarthritis of the thumb." *Journal of hand therapy : official journal of the American Society of Hand Therapists* 23(3): 261-267; quiz 268.
- Minami, A., N. Iwasaki, et al. (2005). "Treatments of osteoarthritis of the distal radioulnar joint: long-term results of three procedures." *Hand surgery : an international journal devoted to hand and upper limb surgery and related research : journal of the Asia-Pacific Federation of Societies for Surgery of the Hand* 10(2-3): 243-248.
- Moritomo, H., S. F. Viegas, et al. (2000). "The scaphotrapezio-trapezoidal joint. Part 2: A kinematic study." *The Journal of hand surgery* 25(5): 911-920.
- Moritomo, H., S. F. Viegas, et al. (2000). "The scaphotrapezio-trapezoidal joint. Part 1: An anatomic and radiographic study." *The Journal of hand surgery* 25(5): 899-910.
- Mulford, J. S., L. J. Ceulemans, et al. (2009). "Proximal row carpectomy vs four corner fusion for scapholunate (Slac) or scaphoid nonunion advanced collapse (Snac) wrists: a systematic review of outcomes." *The Journal of hand surgery, European volume* 34(2): 256-263.
- Mutimer, J., J. Green, et al. (2008). "Comparison of MRI and wrist arthroscopy for assessment of wrist cartilage." *The Journal of hand surgery, European volume* 33(3): 380-382.
- Nagasawa, K., Y. Ishii, et al. (1989). "Avascular necrosis of bone in systemic lupus erythematosus: possible role of haemostatic abnormalities." *Annals of the rheumatic diseases* 48(8): 672-676.
- Nagy, L. (2005). "Salvage of post-traumatic arthritis following distal radius fracture." *Hand Clin* 21(3): 489-498.
- Nagy, L. and U. Buchler (1997). "Long-term results of radioscapulohumeral fusion following fractures of the distal radius." *Journal of hand surgery* 22(6): 705-710.
- Nishiwaki, M., T. Nakamura, et al. (2005). "Ulnar shortening effect on distal radioulnar joint stability: a biomechanical study." *The Journal of hand surgery* 30(4): 719-726.
- North, E. R. and W. M. Rutledge (1983). "The trapezium-thumb metacarpal joint: the relationship of joint shape and degenerative joint disease." *The Hand* 15(2): 201-206.
- Paley, D., R. Y. McMurtry, et al. (1987). "Pathologic conditions of the pisiform and pisotriquetral joint." *The Journal of hand surgery* 12(1): 110-119.
- Palmer, A. K. and F. W. Werner (1981). "The triangular fibrocartilage complex of the wrist--anatomy and function." *The Journal of hand surgery* 6(2): 153-162.
- Pellegrini, V. D., Jr., M. Parentis, et al. (1996). "Extension metacarpal osteotomy in the treatment of trapeziometacarpal osteoarthritis: a biomechanical study." *The Journal of hand surgery* 21(1): 16-23.
- Pequignot, J. P., L. D'Asnieres de Veigy, et al. (2005). "[Arthroplasty for scaphotrapeziotrapezoidal arthrosis using a pyrolytic carbon implant. Preliminary results]." *Chirurgie de la main* 24(3-4): 148-152.
- Peterson, B. and R. M. Szabo (2006). "Carpal osteoarthrosis." *Hand clinics* 22(4): 517-528; abstract vii.

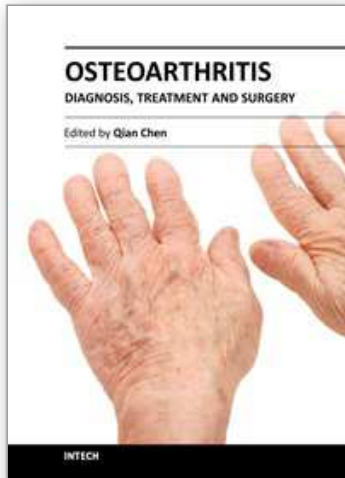
- Pilny, J., J. Kubes, et al. (2006). "[Consequencc of nontreatment scapholunate instability of the wrist]." *Rozhledy v chirurgii : mesicnik Ceskoslovenske chirurgicke spolecnosti* 85(12): 637-640.
- Pirela-Cruz, M. A., S. R. Goll, et al. (1991). "Stress computed tomography analysis of the distal radioulnar joint: a diagnostic tool for determining translational motion." *The Journal of hand surgery* 16(1): 75-82.
- Pollock, J., A. A. Giachino, et al. (2010). "SLAC wrist in the absence of recognised trauma and CPPD." *Hand surgery : an international journal devoted to hand and upper limb surgery and related research : journal of the Asia-Pacific Federation of Societies for Surgery of the Hand* 15(3): 193-201.
- Rayan, G. M., B. H. Jameson, et al. (2005). "The pisotriquetral joint: anatomic, biomechanical, and radiographic analysis." *The Journal of hand surgery* 30(3): 596-602.
- Reagan, D. S., R. L. Linscheid, et al. (1984). "Lunotriquetral sprains." *The Journal of hand surgery* 9(4): 502-514.
- Rothe, M., K. D. Rudolf, et al. (2006). "[Long-term results following denervation of the wrist in patients with stages II and III SLAC-/SNAC-wrist]." *Handchirurgie, Mikrochirurgie, plastische Chirurgie: Organ der Deutschsprachigen Arbeitsgemeinschaft fur Handchirurgie: Organ der Deutschsprachigen Arbeitsgemeinschaft fur Mikrochirurgie der Peripheren Nerven und Gefasse : Organ der Vereinigung der Deutschen Plastischen Chirurgen* 38(4): 261-266.
- Sammer, D. M. and P. C. Amadio (2010). "Description and outcomes of a new technique for thumb Basal joint arthroplasty." *The Journal of hand surgery* 35(7): 1198-1205.
- Saunders, B. M. and D. Lichtman (2011). "A classification-based treatment algorithm for Kienbock disease: current and future considerations." *Techniques in hand & upper extremity surgery* 15(1): 38-40.
- Scheker, L. R., P. P. Belliappa, et al. (1994). "Reconstruction of the dorsal ligament of the triangular fibrocartilage complex." *Journal of hand surgery* 19(3): 310-318.
- Shewring, D. J., R. Savage, et al. (1994). "Experience of the early use of technetium 99 bone scintigraphy in wrist injury." *Journal of hand surgery* 19(1): 114-117.
- Shin, A. Y. and A. T. Bishop (2002). "Pedicled vascularized bone grafts for disorders of the carpus: scaphoid nonunion and Kienbock's disease." *The Journal of the American Academy of Orthopaedic Surgeons* 10(3): 210-216.
- Singer, G., R. Eberl, et al. (2011). "Pisotriquetral arthrodesis for pisotriquetral instability: case report." *The Journal of hand surgery* 36(2): 299-303.
- Staron, R. B., F. Feldman, et al. (1994). "Abnormal geometry of the distal radioulnar joint: MR findings." *Skeletal radiology* 23(5): 369-372.
- Steinmann, S. P. and R. L. Linscheid (1997). "Pisotriquetral loose bodies." *The Journal of hand surgery* 22(5): 918-921.
- Sung, J. K. and E. Akelman (2009). "Thumb Carpometacarpal Arthritis." *Techniques in Orthopaedics* 24(1): 23-26.
- Swigart, C. R., R. G. Eaton, et al. (1999). "Splinting in the treatment of arthritis of the first carpometacarpal joint." *The Journal of hand surgery* 24(1): 86-91.

- Swindells, M. G., A. J. Logan, et al. (2010). "The benefit of radiologically-guided steroid injections for trapeziometacarpal osteoarthritis." *Annals of the Royal College of Surgeons of England* 92(8): 680-684.
- Tay, S. C., S. L. Moran, et al. (2007). "The clinical implications of scaphotrapezium-trapezoidal arthritis with associated carpal instability." *The Journal of hand surgery* 32(1): 47-54.
- Tomaino, M. M. (2006). "Suspensionplasty for basal joint arthritis: why and how." *Hand clinics* 22(2): 171-175.
- Tomaino, M. M., M. Vogt, et al. (1999). "Scaphotrapezoid arthritis: prevalence in thumbs undergoing trapezium excision arthroplasty and efficacy of proximal trapezoid excision." *The Journal of hand surgery* 24(6): 1220-1224.
- Tsuge, S. and R. Nakamura (1993). "Anatomical risk factors for Kienbock's disease." *Journal of hand surgery* 18(1): 70-75.
- Ulrich-Vinther, M., H. Puggaard, et al. (2008). "Prospective 1-year follow-up study comparing joint prosthesis with tendon interposition arthroplasty in treatment of trapeziometacarpal osteoarthritis." *The Journal of hand surgery* 33(8): 1369-1377.
- Van Heest, A. E. and P. Kallemeier (2008). "Thumb carpal metacarpal arthritis." *The Journal of the American Academy of Orthopaedic Surgeons* 16(3): 140-151.
- Vender, M. I., H. K. Watson, et al. (1987). "Degenerative change in symptomatic scaphoid nonunion." *The Journal of hand surgery* 12(4): 514-519.
- Viegas, S. F., R. M. Patterson, et al. (1993). "Wrist anatomy: incidence, distribution, and correlation of anatomic variations, tears, and arthrosis." *The Journal of hand surgery* 18(3): 463-475.
- Wajon, A., L. Ada, et al. (2005). "Surgery for thumb (trapeziometacarpal joint) osteoarthritis." *Cochrane database of systematic reviews*(4): CD004631.
- Wajon, A., E. Carr, et al. (2009). "Surgery for thumb (trapeziometacarpal joint) osteoarthritis." *Cochrane database of systematic reviews*(4): CD004631.
- Watson, H. K., D. t. Ashmead, et al. (1988). "Examination of the scaphoid." *The Journal of hand surgery* 13(5): 657-660.
- Watson, H. K. and F. L. Ballet (1984). "The SLAC wrist: scapholunate advanced collapse pattern of degenerative arthritis." *The Journal of hand surgery* 9(3): 358-365.
- Watson, H. K. and J. Weinzweig (1999). "Triquetral impingement ligament tear (tilt)." *Journal of hand surgery* 24(3): 321-324.
- Weiss, K. E. and C. M. Rodner (2007). "Osteoarthritis of the wrist." *The Journal of hand surgery* 32(5): 725-746.
- Wilder, F. V., J. P. Barrett, et al. (2006). "Joint-specific prevalence of osteoarthritis of the hand." *Osteoarthritis and cartilage / OARS, Osteoarthritis Research Society* 14(9): 953-957.
- Winkler, F. J., N. Borisch, et al. (2010). "[Mid-term results after scaphoid excision and four-corner wrist arthrodesis using K-wires for advanced carpal collapse]." *Zeitschrift fur Orthopadie und Unfallchirurgie* 148(3): 332-337.
- Wolf, J. M. (2008). "Treatment of scaphotrapezio-trapezoid arthritis." *Hand clinics* 24(3): 301-306, vii.

- Wollstein, R. and L. Carlson (2009). "STT (Scapho-Trapezium-Trapezoid) Arthritis." *Techniques in Orthopaedics* 24(1): 19-21.
- Wollstein, R., N. Wandzy, et al. (2005). "A radiographic view of the scaphotrapezium-trapezoid joint." *The Journal of hand surgery* 30(6): 1161-1163.
- Wollstein, R. and H. K. Watson (2005). "Scaphotrapeziotrapezoid arthrodesis for arthritis." *Hand clinics* 21(4): 539-543, vi.

IntechOpen

IntechOpen



Osteoarthritis - Diagnosis, Treatment and Surgery

Edited by Prof. Qian Chen

ISBN 978-953-51-0168-0

Hard cover, 404 pages

Publisher InTech

Published online 02, March, 2012

Published in print edition March, 2012

Osteoarthritis is one of the most debilitating diseases affecting millions of people worldwide. However, there is no FDA approved disease modifying drug specifically for OA. Surgery remains an effective last resort to restore the function of the joints. As the aging populations increase worldwide, the number of OA patients increases dramatically in recent years and is expected to increase in many years to come. This is a book that summarizes recent advance in OA diagnosis, treatment, and surgery. It includes wide ranging topics from the cutting edge gene therapy to alternative medicine. Such multifaceted approaches are necessary to develop novel and effective therapy to cure OA in the future. In this book, different surgical methods are described to restore the function of the joints. In addition, various treatment options are presented, mainly to reduce the pain and enhance the life quality of the OA patients.

How to reference

In order to correctly reference this scholarly work, feel free to copy and paste the following:

Nimit Patel, Glenn Russo and Craig Rodner (2012). Osteoarthritis of the Wrist, Osteoarthritis - Diagnosis, Treatment and Surgery, Prof. Qian Chen (Ed.), ISBN: 978-953-51-0168-0, InTech, Available from: <http://www.intechopen.com/books/osteoarthritis-diagnosis-treatment-and-surgery/wrist-osteoarthritis>

INTECH
open science | open minds

InTech Europe

University Campus STeP Ri
Slavka Krautzeka 83/A
51000 Rijeka, Croatia
Phone: +385 (51) 770 447
Fax: +385 (51) 686 166
www.intechopen.com

InTech China

Unit 405, Office Block, Hotel Equatorial Shanghai
No.65, Yan An Road (West), Shanghai, 200040, China
中国上海市延安西路65号上海国际贵都大饭店办公楼405单元
Phone: +86-21-62489820
Fax: +86-21-62489821

© 2012 The Author(s). Licensee IntechOpen. This is an open access article distributed under the terms of the [Creative Commons Attribution 3.0 License](#), which permits unrestricted use, distribution, and reproduction in any medium, provided the original work is properly cited.

IntechOpen

IntechOpen