

We are IntechOpen, the world's leading publisher of Open Access books Built by scientists, for scientists

4,800

Open access books available

122,000

International authors and editors

135M

Downloads

Our authors are among the

154

Countries delivered to

TOP 1%

most cited scientists

12.2%

Contributors from top 500 universities



WEB OF SCIENCE™

Selection of our books indexed in the Book Citation Index
in Web of Science™ Core Collection (BKCI)

Interested in publishing with us?
Contact book.department@intechopen.com

Numbers displayed above are based on latest data collected.

For more information visit www.intechopen.com



Hyaluronic Acid in the Treatment of Osteoarthritis: What is New

Michele Abate and Vincenzo Salini
*University "G. d' Annunzio" Chieti - Pescara
Italy*

1. Introduction

Osteoarthritis is a very common disease, and its prevalence increases with age. According to the American College of Rheumatology, nearly 70 % of people over age 70 have X - ray evidence of osteoarthritis, although only half ever develop symptoms (Altman et al., 1991). Notwithstanding, due to the huge amount of persons affected, osteoarthritis is a frequent cause of disability (Lawrence et al., 1998).

Several pharmaceutical approaches, such as analgesics, non steroidal anti - inflammatory drugs, COX - 2 inhibitors and steroids (Hochberg et al., 1995), have been proposed, with the aim of reducing pain and maintaining and / or improving joint function. However, none of these options has shown to delay the progression of osteoarthritis or reverse joint damage.

In addition, the incidence of adverse reactions to these drugs increases with age. Data from epidemiological studies consistently show that the risk of gastro - intestinal complications is very high and largely dose - dependent (Griffin MR et al., 1991 ; Smalley & Griffin, 1996). It is well known that non steroidal anti - inflammatory drugs, as well as selective COX - 2 inhibitors, may cause renal failure, hypertension and water retention and have a thrombotic potential, especially for high doses and long term treatments (Roughead et al., 2008; Savage, 2005). Corticosteroids are burdened with relevant adverse reactions, when given systemically, and therefore are usually administered by intra - articular injection in patients who fail to respond to other conservative measures; in particular, patients with joint effusions and local tenderness may have greater benefit from this option (Flanagan et al., 1988).

Although it has been established that corticosteroid injections are relatively safe, there are concerns regarding their possible adverse effects, following repeated injections. These effects include local tissue atrophy, particularly when small joints are injected, long - term joint damage, due to reduced bone formation, and risk of infection, due to suppression of adrenocortical function (Mader et al., 2005; Weitoft et al., 2005).

Considering the limits of therapies at present available, drugs with minimal side effects are therefore warranted.

Viscosupplementation by intra - articular injections of hyaluronic acid has been proposed as useful therapeutic option in the treatment of osteoarthritis in different joints (Migliore et al., 2010).

Aim of the chapter is to summarize the more significant results of this therapeutic approach, reporting the recently published data and focusing attention on issues yet unsolved.

2. Synovial fluid

Synovial fluid is essential for the normal joint functioning : it acts both as a lubricant during slow movement (e.g. in walking), and as an elastic shock absorber during rapid movement (e.g. in running). It also serves as a medium for delivering nutrition, and transmitting cellular signals to articular cartilage.

Hyaluronic acid, produced by synoviocytes, fibroblasts and chondrocytes, is the major chemical component of synovial fluid. The native hyaluronic acid has a molecular weight of 4 - 10 millions Daltons, and is present in articular fluid in concentration about 0.35 gr / 100 ml (Weiss & Band, 1995). It is essential for the viscoelastic properties of the fluid because of high viscosity, and has a protective effect on articular cartilage and soft tissue surfaces of joints (O' Regan et al., 1994; Van den Bekerom et al., 2008).

In pathological conditions, the concentration and molecular weight of hyaluronic acid are reduced, resulting in synovial fluid of lower elasticity and viscosity : the factors which contribute to the low concentrations of hyaluronic acid are diluitional effects, reduced hyaluronan synthesis and free radical degradation (Van den Bekerom et al., 2006). When viscoelasticity of synovial fluid is reduced, the transmission of mechanical force to cartilage may increase its susceptibility to damage.

Therefore, the restoration of the normal articular homeostasis is the rationale for hyaluronic acid administration into osteoarthritic joints. Moreover, being hyaluronic acid a physiological component, it is very likely that it may be deprived of adverse reactions, also after repeated administrations.

3. Therapeutic activities of hyaluronic acid

The direct injection of hyaluronic acid in the joint space allows to reach a proper concentration with low doses, favouring a longer permanence in the joint, and therefore the therapeutic response.

Hyaluronic acid preparations have a short half - life; therefore, the long term effects cannot solely be attributed to the substitution of molecule itself. The term viscosupplementation means restoration of visco - elastic properties, such as cushioning, lubrication, elasticity (Kikuchi et al., 2001), while the term biosupplementation is used to indicate the restoration of joint rheology, anti - inflammatory and anti - nociceptive effects, normalization of endogenous hyaluronic acid synthesis, and chondroprotection. These activities explain why the clinical efficacy is maintained for several months (Gigante & Callegari, 2010 ; Hiraoka et al., 2011; Julovi et al., 2011; Kumahashi et al., 2011).

In Table 1, the main beneficial effects of hyaluronic acid in osteoarthritis are summarized.

4. Hyaluronic acid preparations

At present, preparations with different molecular weight are available (Low and High Molecular Weight), which display distinct pharmaceutical effects (Ghosh & Guidolin, 2002).

The enhanced penetration of low molecular weight preparations (0.5 - 1.5 millions Dalton) through the extracellular matrix of the synovium is thought to maximize the concentration and to facilitate the interaction with target synovial cells, so reducing the synovial inflammation (Bagga H et al., 2006).

ACTION	TARGET	RESULTS
Inhibition	Lymphocyte transformation Phagocytic activity of macrophages and leukocytes Adenosine triphosphate levels	SLOW DOWN THE PROGRESSION OF JOINT DAMAGE
Promotion	Matrix Metalloproteinase (MMP) Release of prostaglandins Normalization of native hyaluronan synthesis Production of tissue inhibitor of MMP - 1	ANTI - INFLAMMATORY ACTIVITY ANTI - NOCICEPTIVE EFFECTS
Protective	Scavenging of free radicals Proteoglycans synthesis by chondrocytes Effects on chondrocytes or cartilage explants from degradation by enzymes, Interleukin - 1, and oxygen - derived free radicals	MODIFIED STRUCTURAL ORGANIZATION TOWARDS NORMAL APPEARANCE

Table 1. Beneficial effects of hyaluronic acid (modified from Carpenter & Motley (2008))

However, because of the low elastoviscosity of these hyaluronan compounds, compared to native hyaluronan in the synovial fluid, interests were shifted to a viscosupplementation fluid similar to the native hyaluronic acid.

Recently, an hyaluronic acid cross - linked preparation (Hylan G - F 20), with high molecular weight (6 - 7 millions Dalton), has been developed (Migliore et al., 2010).

This formulation, by means of its hydrophilic properties, retains higher amounts of fluid in articular space; it is also provided by a greater anti - inflammatory activity, as shown by studies on migration of inflammatory cells in the joint and on reduced Prostaglandin E 2 and bradykinin concentration (Goto et al., 1999; Takahashi et al., 1999). Moreover, high molecular weight hyaluronic acid is considered more effective in relieving pain, compared to low molecular weight hyaluronic acid.

A novel hyaluronic acid preparation, non - animal stabilised hyaluronic acid (NASHA) (Berg & Olsson, 2004) has been manufactured by a two stage procedure : biosynthesis of hyaluronic acid by cultured bacteria, followed by a mild stabilization process. Stabilisation does not change the biochemical properties of hyaluronic acid, but creates bio - compatible gel with improved viscoelastic properties and a longer residence time in joint, compared with non - stabilised hyaluronic acid preparation.

Currently, with aim of favouring a longer presence of hyaluronic acid in the joint, long acting preparations are under study (Abate et al, 2010). Hopefully, these compounds, with better rheological and biological properties, could influence positively the natural history of osteoarthritic disease.

5. Indications to treatment

Viscosupplementation can be considered when the patient has not found pain relief from exercise, physical therapy, weight loss, use of orthotics and analgesics or non steroidal anti -

inflammatory drugs. Other indications may be the intolerance to drugs or the use of multiple systemic medications, as frequently happens in the elderly (Waddell, 2007).

The treatment, in general, is offered to patients with intermediate Kellgren – Lawrence score (mild osteoarthritis) (Kellgren & Lawrence, 1957), who report better results in term of function and pain reduction (Brzusek & Petron, 2005).

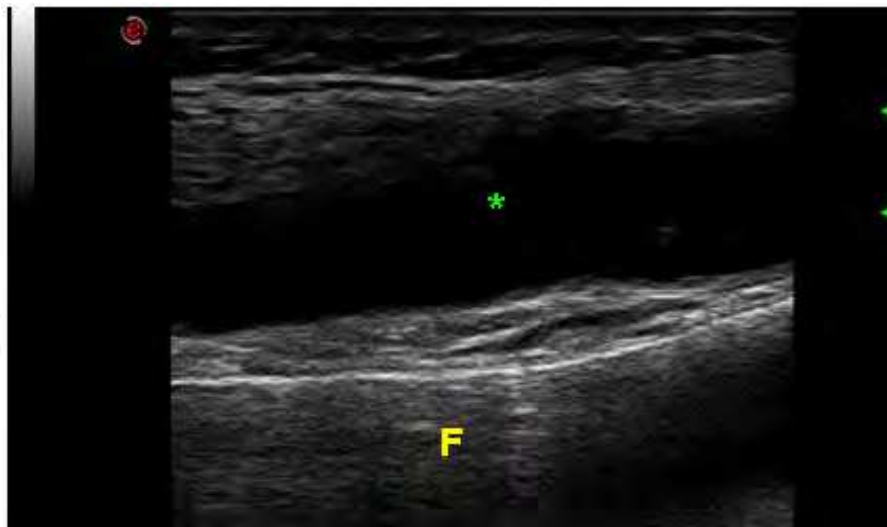The administration of hyaluronic acid is contraindicated only in patients with known hypersensitivity to preparations components; patients with severe osteoarthritis (Kellgren – Lawrence score IV) or affected by inflammatory musculoskeletal diseases (rheumatoid arthritis, chondrocalcinosis, psoriasis, gout), may have limited benefit (Waddell, 2007).

6. Infiltration techniques

Intra – articular injection of hyaluronic acid must be performed in sterile conditions, to minimize the risk of inflammatory complications (i.e. septic arthritis).

Moreover, the use of “image – guided” infiltration techniques is mandatory; indeed, when joint infiltration is performed blindly, the failure rate is high, and the drug may be administered in the para – articular space. In this case, treatment loses its efficacy and side effects, mainly pain, frequently occur (Pourbagher et al., 2005; Zwar et al., 2004).

The ultrasound – guided injection, compared with fluoroscopy, has several advantages : it is simple, fast, economic and safe; it does not require the use of contrast media, allowing the infiltration in patients intolerant to iodized contrasts. It can be repeated without limits, allows an easy visualization of fluid in the articular recess (which may be aspirated) (Figure 1), and shows how narrow is the articular space.

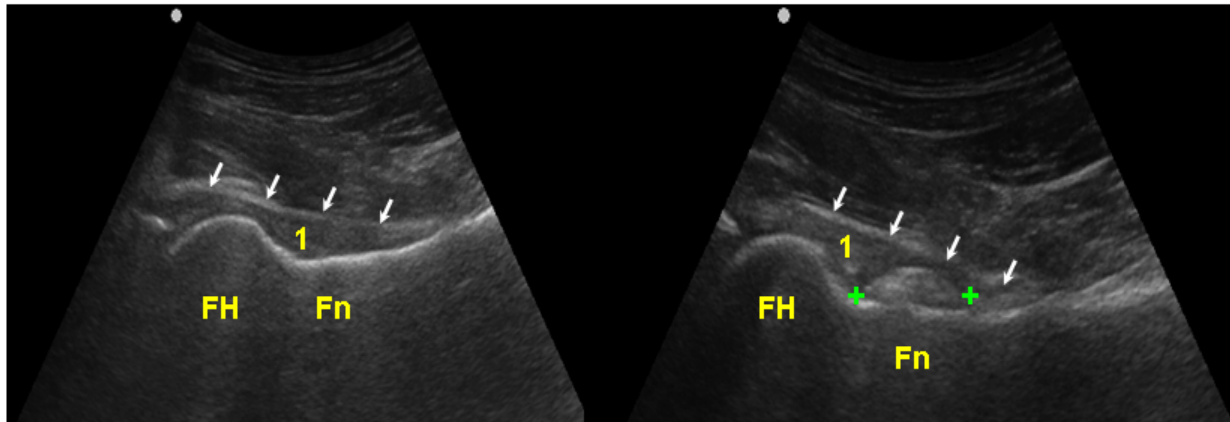


F = Femur

Fig. 1. Ultrasound imaging (longitudinal scan). An effusion (*) is present inside the articular space of knee joint.

Moreover, it is able to show the position of the needle, and, by means of continuous Color Doppler monitoring, to evaluate its distance from vessels. Finally, ultrasound technique allows the visualization of the viscous fluid injected inside the joint (Migliore et al., 2004).

In figure 2, an example of intra – articular injections of hip joint is presented.



FH = Femoral head; Fn = Femoral neck; 1 = articular space; Arrows = articular capsule

Fig. 2. Ultrasound guided injection of hip joint (longitudinal scan). Before the injection, hip joint is evaluated (left panel). After the injection (right panel), the correct placement of hyaluronic acid (calipers) is confirmed by the presence of hyperechoic material inside the articular space.

7. Clinical results

In this section we report the main results obtained with hyaluronic acid in the treatment of osteoarthritis in different joints.

7.1 Knee osteoarthritis

Viscosupplementation with hyaluronic acid in knee osteoarthritis has been approved by Food and Drugs Administration (Hunter & Lo, 2008).

Recent guidelines are based on a meta - analysis, including 5257 participants to 40 Randomized Controlled Trials (Curran, 2010; National Collaborating Center for Chronic Conditions at the Royal College of Physicians, 2008). These studies were performed, single or double - blind, with different types of hyaluronic acid (low and high molecular weight) against placebo. The number of injections ranged from 3 to 5 weekly, with a maximum of 11 in 23 weeks, the doses from 15 to 60 mg and the trials length from 4 weeks to 18 months.

Pain was evaluated by means of Visual Analogic Scale and Western Ontario and McMaster Universities Osteoarthritis Index, at rest and under different load conditions. A minor number of studies evaluated the functional outcomes (Western Ontario and McMaster Universities Osteoarthritis Index [physical function], Lequesne Index, Range of motion), the subjective global assessment and the quality of life of the patients. The results of the majority of studies are in favour of hyaluronic acid, although in several randomized controlled trials no significant differences have been found in comparison with intra - articular placebo. The percentages of improvement from baseline, in all the outcomes measures, were 28 % to 54 % for pain, and 9 % to 32 % for function, and were similar in the trials where low molecular weight or high molecular weight hyaluronic acid were used (Aggarwal & Sempowski, 2004; Divine et al., 2007; Waddel 2007). However, the number of injection needed was in general lower for high molecular weight preparation and this is not a negligible advantage for the patients.

A recent systematic review has compared the post - intervention time course of the effects of hyaluronic acid and corticosteroid (the "therapeutic trajectory") (Bannuru et al., 2009).

This meta analysis highlights the therapeutic trajectory of hyaluronic acid for knee osteoarthritis pain over six months following the intervention. From baseline to week 4, intra-articular corticosteroid appear to be relatively more effective than hyaluronic acid. By week 4 the two approaches have equal efficacy, but beyond week 8 hyaluronic acid has greater efficacy.

It should be observed that the benefit is not equally distributed among patients, some of them being non-responders to therapy. The characteristics of responders, at present, have not been clearly identified, but some authors claim that a greater benefit may be obtained in patients with low grade osteoarthritis (Dagenais et al., 2006). On the contrary, age does not influence the therapeutic response (Abate et al., 2008).

7.2 Hip osteoarthritis

The number of studies about viscosupplementation of hip osteoarthritis is limited, when compared with studies in knee osteoarthritis. The reasons can be the deeper localization of this joint, and the proximity of femoral vessels and nerves.

Moreover, the level of evidence for most of these studies is low, because they are cohort studies and lack of a reference group (Abate et al., 2010), a score I (i.e. the highest level of evidence), according to the Center for Evidence Based Medicine criteria (Fletcher & Sackett, 1979), having been assigned only to Tikiz's (Tikiz et al., 2005) and Qvistgaard's (Qvistgaard et al., 2006) studies.

A new randomized controlled three-arm study, comparing intra-articular injection of hyaluronic acid, corticosteroid and bupivacaine, is in progress; this trial will hopefully provide robust information on the advantages of drugs towards the simple anaesthetic treatment (Colen et al., 2010).

In the published studies, several hyaluronic acid compounds were used. The number of injections ranged from 1 to 3 for each patients, and only in few cases 4 or 5 injections were performed. In general, the injections number was lower for high molecular weight preparations. The length of treatments and the outcome measures were similar to those used in knee randomized controlled trials.

All the trials have shown a reduction of pain, which, in general, becomes evident within 3 months and persists in the following months. Only few studies report a precocious reduction of the pain: within a week, according to Brocq (Brocq et al., 2002) (- 27 %), and within the first 2 - 4 weeks according to Qvistgaard (Qvistgaard et al., 2001) (- 14 % and - 32 %, respectively). The positive effects on pain after 1 - 3 months range from - 16.1 % to - 52.2 % (mean - 37.2 %), whereas, overall, the mean Visual Analogic Scale score decreases about 49 % after 3 - 6 months (range 31 - 80 %) (Abate et al., 2008).

Therefore, it seems that the benefit increases in the long term. However, it must be underlined that only few studies report longer follow-up periods: at 12 (Migliore et al., 2005) and at 18 months (Migliore et al., 2006a), with persistent benefit on the pain (VAS - 36.4 %). Besides the reduction of pain, also the articular function is improved. These positive effects have been observed using different evaluation scales: + 11 % in the Harris Hip Score, + 32 - 45 % in Western Ontario and McMaster Universities Osteoarthritis Index score, + 45 % in Lequesne Index, and + 95 % in American Academy of Orthopaedic Association Lower Limb Core Scale (Abate et al., 2008). A further observation, which confirms the previous data, is the reduction of non steroidal anti-inflammatory drugs consumption (Migliore et al., 2011).

7.3 Ankle osteoarthritis

Only few studies have been performed in ankle osteoarthritis and, among these, four were randomized / controlled trials (level of evidence 1) (Carpenter & Motley, 2008; Cohen et al., 2008; Karatosun et al., 2008; Salk et al., 2005, 2006), while seven studies (Hanson et al., 1999; Luciani et al., 2008; Mei - Dan et al., 2010; Sun et al., 2006; Valiveti et al., 2006; Witteveen et al., 2008, 2010) were case series (level of evidence 4).

In all these studies, patients suffering from post - traumatic Kellgren - Lawrence grade II - IV ankle osteoarthritis were enrolled. Different hyaluronic acid preparations were used, and patients received 1 up to 5 injections. Only in one study, the injections were performed by means of image guidance (fluoroscopy) (Cohen et al., 2008). Clinical benefit was evaluated by means of different scales (Visual Analogic Scale, Ankle Osteoarthritis Scale, American Orthopaedic Foot and Ankle Society, Short Form - 12, Short Form - 36, Western Ontario and McMaster Universities Osteoarthritis Index), and the follow - up period varied from 6 to 18 months.

In studies performed without control group (Hanson et al., 1999; Luciani et al., 2008; Mei - Dan et al., 2010; Sun et al., 2006; Valiveti et al., 2006; Witteveen et al., 2008, 2010) (Table 2), an improvement in all the outcome measures was reported, with the effect lasting for 18 months (Luciani et al., 2008). However, it is not clear from reports whether the pain reduction was clinically significant, or could be ascribed only to a placebo effect. In addition, the lack of controls does not allow definitive conclusions on the efficacy of hyaluronic acid.

Authors	Patients	Age	HA	Dose	Follow up	Results
Mei - Dan	15	43	LMW	1x5 wks	7 months	Positive
Sun	75	50	LMW	1x5 wks	6 months	Positive
Luciani	21	45	HMW	1x3 wks	3 months	Positive
Witteveen(2008)	55	41	HMW	1 or 2	6 - 9 months	Positive
Witteveen(2010)	26	43	HMW	1 or 2 or 3	6 months	Positive

HA = Hyaluronic acid; LMW = Low Molecular Weight; HMW = High Molecular Weight

Table 2. Case series studies on ankle osteoarthritis. Valiveti (2006) and Hanson (1999) studies' are not reported due to the small number of cases.

The level 1 evidence studies are more qualified to assess the therapeutic efficacy, but also these trials show several limitations (e.g., no information on the actual number of potential patients, no clear patients randomization, imbalance of baseline characteristics between intervention and control groups, statistical weakness), and therefore have to be considered as low quality studies.

In these studies (Carpenter & Motley, 2008; Cohen et al., 2008; Karatosun et al., 2008; Salk et al., 2005, 2006) (Table 3), the patients treated with hyaluronic acid showed a significant decrease in pain and disability at 6 months (Cohen et al., 2008; Salk et al., 2005, 2006), with the effects lasting 12 - 13 months (Carpenter & Motley, 2008; Karatosun et al., 2008). Besides the reduction of these parameters, an improvement in ankle sagittal range of motions, and gait quality was observed (Karatosun et al., 2008).

Authors	Patients	Age	HA	Dose	Control	Follow up	HA vs Controls
Carpenter	26	55	HMW	1x3 wks	Arthroscopy	13 months	> HA (moderate)
Cohen	30	49	LMW	1x5 wks	Saline	6 months	No difference
Karatosun	30	55	LMW	1x3 wks	Exercise	12 months	No difference
Salk	17	58	LMW	1x5 wks	Saline	6 months	No difference

Table 3. Randomized controlled trials on ankle osteoarthritis. Salk et al. (2006, 2005) presented their results in two different journals.

In any study the authors found difference between hyaluronic acid and controls groups. In particular, in the studies performed by Salk (Salk et al., 2005, 2006) and Cohen (Cohen et al., 2008), the patients, treated with a 1 - 2 ml phosphate - buffered saline solution injection, reported a similar improvement in all parameters evaluated. Analogously, positive results were observed in patients, who followed a 6 weeks exercise therapy (muscle strengthening and ankle range of motion exercises) (Karatosun et al., 2008), and after arthroscopic lavage of osteoarthritic ankle joint (Carpenter & Motley, 2008).

On the basis of these observations, no clear evidence on the efficacy of hyaluronic acid in reducing pain, and improving function, in ankle osteoarthritis, is provided.

Several factors can explain why viscosupplementation has limited efficacy in ankle osteoarthritis.

Ankle joint, anatomically and functionally, is more complex than other joints, which are usually treated with positive results with hyaluronic acid (hip, knee) (Saltzman et al., 2005).

Another possible reason of the limited benefit of hyaluronic acid can be related to its use mostly in post - traumatic osteoarthritis (Zhang & Jordan, 2010), which has a pathogenesis quite different from that of primary degenerative osteoarthritis.

Finally, it must be considered that all studies (Carpenter & Motley, 2008; Hanson et al., 1999; Karatosun et al., 2008; Luciani et al., 2008; Mei - Dan et al., 2010; Salk et al., 2005, 2006; Sun et al., 2006; Valiveti et al., 2006; Witteveen et al., 2008, 2010), but one (Cohen et al., 2008), were performed blindly, with any imaging guidance. This can be a valid explanation of several unsatisfactory results, because there is evidence that about one third of intra - articular injections are not delivered into the intra - articular cavity, when performed without a visual aid (Cunnington et al., 2010).

At this regard, ankle joint presents many technical difficulties of injecting intra - articular, due to its complex anatomy, further complicated from the osteoarthritic joint changes (Woo et al., 2010).

7.4 Gleno – Humeral osteoarthritis

Hyaluronic acid is effective and well tolerated for the treatment of osteoarthritis and persistent shoulder pain refractory to other standard non operative interventions (Andrews, 2005).

Several authors (Blaine et al., 2008; Leardini et al., 1988) report that both 3 and 5 weekly intra - articular injections of low molecular weight hyaluronic acid provide significant improvement in terms of shoulder pain (Visual Analogic Scale score on movement), with the effects lasting 7 - 26 weeks (Blaine et al., 2008).

Similarly, in a 6 months follow - up studies (Merolla et al., 2011; Silverstain et al., 2007), a significant reduction in Visual Analogic Scale pain score was also provided with 3 weekly intra - articular high molecular weight hyaluronic acid (Hylan G - F 20) injections. In addition, most of the patients experienced an improvement in the shoulder function score and in the activities of daily living (Itokazu & Matsunaga, 1995; Merolla et al., 2011).

A recent study comparing Hylan G - F 20 versus 6 methylprednisolone acetate shows that hyaluronic acid is effective in reducing pain for up to 6 months, whereas corticosteroid injections result in improvement at 1 month only (Merolla et al., 2011).

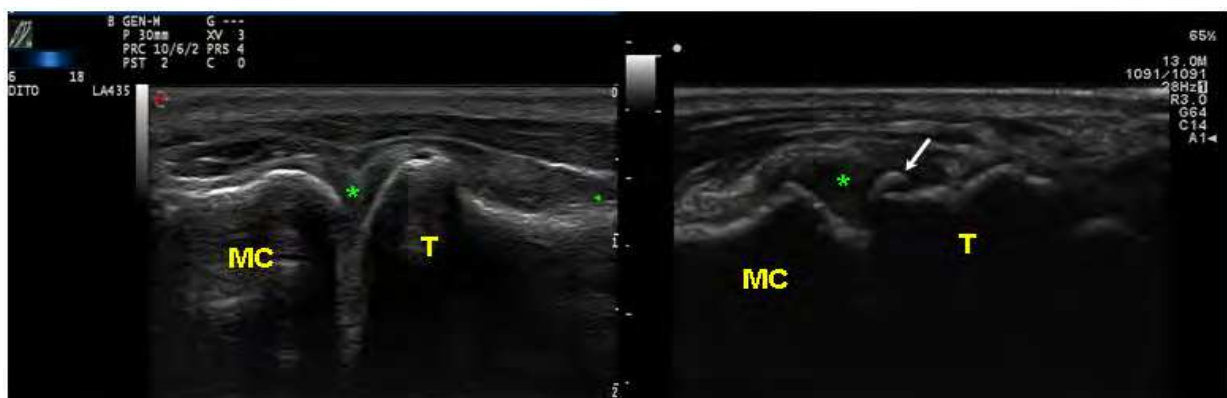
Finally, the efficacy of hyaluronic acid has been demonstrated in the treatment of different shoulder diseases, such as subacromial bursitis, adhesive capsulitis and rotator cuff tear (Blaine et al., 2008; Calis et al., 2006; Fernandez - Palazzi et al., 2002; Rovetta & Monteforte, 1998; Tamai et al., 2004), with positive results on pain, joint mobility and shoulder function.

7.5 Carpo – Metacarpal osteoarthritis

Because carpo - metacarpal joint is essential for the closure of the first web, a loss of function causes an alteration of the thumb - index pinch, and therefore can lead to functional impairment (Spacek et al., 2004).

Several conservative treatments have been proposed (corticosteroids, non steroidal anti - inflammatory drugs, prolotherapy, splinting), but none of these has shown to delay the progression of osteoarthritis or reverse joint damage (Fuchs et al., 2006).

Recent studies have investigated the efficacy of hyaluronic acid in the treatment of carpo - metacarpal osteoarthritis (Figure 3) and positive results have been reported by most of the authors.



MC = Metacarpal bone

Fig. 3. Ultrasound features of carpo - metacarpal osteoarthritis (right panel) : the cortex of the trapezium bone (T) is irregular and an osteophyte is present (arrow); mild articular effusion (*) can be also appreciated. In left panel, normal features are reported.

In particular, an early improvement in Visual Analogic Scale score was observed after 2 weeks post treatment (Heyworth et al., 2008), with the effects lasting until 1 - 3 months (Coaccioli et al., 2006; Roux et al., 2007; Schumacher et al., 2004; Stahl et al., 2005). The long term effects of hyaluronan were demonstrated only in few studies (Fuchs et al., 2006; Heyworth et al., 2008;), in which the pain relief was reported at 6 months (Di Sante et al., 2011).

Beside pain reduction, also grip strength improved significantly in some studies (Migliore et al., 2010), although these effects were achieved slowly, with better results observed at 6 months (Fuchs et al., 2006; Heyworth et al., 2008; Stahl et al., 2005).

In our experience (Table 4), a single ultrasound guided injection of hyaluronic acid is effective in treatment of carpo - metacarpal osteoarthritis (Salini et al., 2009). After therapy the Visual Analogic Scale pain score, both at rest and during common daily activities, decreases, while the hand function and strength are improved. The best improvement is observed in the pulp pinch strength, because the carpo - metacarpal joint is strongly stressed in this movement (Spacek et al., 2004), and therefore a better mobility and a reduction of pain in the joint allow evident increase in performance.

	Baseline	Follow - up	p
VAS rest	1,8 ± 1	0,5 ± 0,6	< 0.001
VAS activities	8 ± 0,9	4,1 ± 1,4	< 0.001
Dreiser Index	18,5 ± 3,3	20,7 ± 2,7	< 0.004
Hand grip (Kg)	19,3 ± 16,5	19,6 ± 16,1	0.13
Lateral grip (Kg)	9,5 ± 4	10 ± 3,3	0.17
Pulp grip (Kg)	4,1 ± 1,4	5,4 ± 1,3	< 0.001
NSAIDs (n. of subjects)	16	7	
NSAIDs (tablets / week)	2,4 ± 1,9	1,1 ± 1,3	< 0.02

NSAID = Non Steroidal Anti - Inflammatory Drug; VAS = Visual Analogic Scale

Table 4. Positive results of hyaluronic acid on pain and hand function

7.6 Temporo-mandibular joint

At present, 19 studies have been published, and only 8 were randomized and controlled trials (Manfredini et al., 2010). All studies reported a decrease in pain levels independently by the patients' disorder and by the adopted injection protocol. Positive outcomes were maintained over the follow - up period, which ranged largely from 15 days to 24 months. The superiority of hyaluronic acid injections was shown only against placebo saline injections, but outcomes were comparable with those achieved with corticosteroid injections.

Interestingly, in an experimental model of arthropatic temporomandibular joint, El - Hakim and Elyamani (El - Hakim & Elyamani 2011) found, after repeated intra - articular injections of hyaluronic acid, an increase in the thickness of the cartilaginous layer, suggesting that hyaluronic acid can inhibit the progression of osteoarthritic changes.

A recent study, aiming to identify predictors for treatment efficacy, has shown that only unilateral temporomandibular joint osteoarthritis predicts better the benefit (Guarda - Nardini et al., 2011), while sex, age, pain duration are not provided of predictive power.

7.7 Other joints

Encouraging results have been reported in the treatment of painful hallux rigidus (Pons et al., 2007), of sacroiliac joint syndrome (Calvillo et al., 2000; Srejjic et al., 1999), and of nerve root adhesion after lumbar intervertebral disco herniation (Wang et al., 2002).

In the treatment of elbow osteoarthritis the results are inconclusive. Positive effects have been observed only in two small studies (Fernandez - Palazzi et al., 2002; Hanson, 1999), while, in a larger study (18 patients), intra - articular hyaluronic acid was not effective in the treatment of post - traumatic osteoarthritis of the elbow (Van Brakel & Eygendaal, 2006).

Controversial results have been observed also in the treatment of spine osteoarthritis. Fuchs et al. (Fuchs et al., 2005) reported significant pain relief and improved quality of life, also in the long term, in patients affected from facet joints osteoarthritis with chronic non radicular pain in the lumbar spine. However, these results are not in agreement with a recent study by Cleary et al. (Cleary et al., 2008), who have not seen any benefit of viscosupplementation in the management of symptomatic lumbar facet osteoarthritis.

8. Side effects

Several factors may contribute to the occurrence of side effects : among them, the characteristics and amount of hyaluronic acid preparation injected, the number of injections, the skill of the operator, the technique used, the local and systemic tissues reactions.

In quite all the clinical trials, no general side effects were observed, and only few patients reported a sensation of heaviness and pain in their joint after injection (Abate M, 2009).

These effects were more frequent in studies performed in blind conditions compared to those performed under imaging guidance. No differences were observed in relation to hyaluronic acid preparation used or to the number of injections (Abate M, 2008).

Side effects usually disappeared after 2 - 7 days without any therapeutic intervention and did not limit basic or instrumental activities of daily living.

Vascular or nervous complications were never reported, neither gout, chondrocalcinosis, sometimes observed after viscosupplementation of the knee (Curran, 2010).

Septic arthritis or aseptic synovial effusion occurred in a very limited number of cases (Brocq et al., 2002; Chazerain et al., 1999).

9. Hyaluronic acid vs corticosteroids

Intra - articular corticosteroids are the alternative choice to hyaluronic acid for treatment of osteoarthritis. Therefore it is important to evaluate the studies, which compared these treatment modalities. The large majority of comparison studies has been performed between different hyaluronic acid preparations and steroids (methylprednisolone, triamcinolone) (Bellamy et al., 2006).

In several studies, better results were observed after hyaluronic acid injection (Cohen et al., 2008; Fuchs et al., 2005, 2006), in other no significant difference was found (Chazerain et al., 1999; Qvistgaard et al., 2006). Steroids however offered the best results on joints with inflammatory effusions (Atchia et al., 2011).

Only one study compared the clinical efficacy of hyaluronic acid versus corticosteroids and placebo in hip osteoarthritis. This very large trial, including 101 patients, did not show significant differences between the treatments in all the outcome measures, after 3 months

(Qvistgaard et al., 2006). However, within this time period, an improvement was found, which resulted clearly evident in the steroid group and moderate in hyaluronic acid group, compared to placebo (Qvistgaard et al., 2006).

A comparison study on the efficacy of Hylan G - F 20 versus 6 - methylprednisolone acetate in shoulder osteoarthritis shows that hyaluronic acid is effective in reducing pain for up to 6 months, whereas corticosteroids injections result in an improvement at 1 month only (Merolla et al., 2011).

Analogously, Bannuru et al. (Bannuru et al., 2009) have shown in the treatment of knee osteoarthritis that intra - articular corticosteroids appear to be relatively more effective for pain than hyaluronic acid in the first four weeks, but in the long term hyaluronic acid has greater efficacy.

In carpo - metacarpal joint osteoarthritis, a rapid pain relief was observed after triamcinolone or methylprednisolone injections (after 2 - 4 weeks), but disappeared soon after (Heyworth et al., 2008). Positive effects were achieved with hyaluronic acid more slowly, but were long - lasting and persisted 6 months after end of treatment period (Fuchs et al., 2006).

Also for the treatment of temporomandibular joint osteoarthritis, the comparison between corticosteroids and hyaluronic acid has shown that both compounds reduce pain and improve articular function (Manfredini et al., 2010).

10. Conclusions

On the basis of the published trials, we may affirm that viscosupplementation therapy with hyaluronic acid is a safe and effective method in the management of osteoarthritis resistant to conventional therapies. This treatment has been approved by Food and Drug Administration for knee osteoarthritis, whereas for the other osteoarthritic joints there are promising results but not conclusive evidence.

The use of hyaluronic acid is mainly recommended when non steroidal anti - inflammatory drugs are contraindicated or badly tolerated, when non steroidal anti - inflammatory drugs or corticosteroid are inefficacious, or in young patients candidate to prosthesis.

Viscosupplementation significantly reduces pain within 3 months and this beneficial effect is maintained in the long term (12 - 18 months). The articular function is improved and, therefore, patients can rapidly come back to work and to social activities.

Only few trials have shown a very early improvement, which has been related to the lubricating effect of hyaluronate in "dry" joints, as reported in studies of viscosupplementation in knee osteoarthritis, and / or to a short term placebo effect (Brocq et al., 2002).

The reduction in non steroidal anti - inflammatory drugs consumption is another important clinical achievement with significant health economic consideration (Sturkenboom et al., 2002). Not only direct costs (non steroidal anti - inflammatory drugs purchasing), but also the indirect costs associated with management of non steroidal anti - inflammatory drugs side effects, are saved. Cost - benefit analysis is difficult in comparison with corticosteroids. Corticosteroids doses are cheaper than hyaluronic acid preparation, but the efficacy of these drugs seems to last less longer than hyaluronic acid preparations, with more relevant side effects, which can offset the initial saving (Qvistgaard et al., 2006).

Patients with mild morphological alterations, and with preserved articular space, are more responsive to treatment (Brocq et al., 2002; Gaston et al., 2007; Van den Bekerom et al., 2006); the results are less encouraging in patients with severe osteoarthritis (Kellgren - Lawrence IV), only few studies reporting a good therapeutic effects (Migliore et al., 2006b).

Articular effusion usually is associated to a reduced therapeutic efficacy due to the "dilution effect" of the drug (Qvistgaard et al., 2006). In this situation, a better therapeutic response is observed with intra - articular corticosteroids, probably linked to their anti - inflammatory activity (Qvistgaard et al., 2006).

The better biological activity, shown by high molecular weight hyaluronic acid preparations *in vitro*, has not been confirmed in clinical trials (Tikiz et al., 2005). In fact, the percentage of improvement in all the outcomes measures is similar with low molecular weight and high molecular weight hyaluronic acid preparations (Caglar - Yagchi et al., 2005). An advantage of high molecular weight hyaluronic acid may be the reduced number of the injections needed to obtain the therapeutic effect.

When the therapy is delivered by appropriately trained doctors, under strict imaging guidance, viscosupplementation is a safe procedure, without any systemic or local side effect, excluding the pain of the injection and a sensation of heaviness for few hours / days after treatment. It is likely that persistent pain and joint swelling or major complications, such as septic arthritis may occur when injection is not properly performed. Even experienced clinicians can miss intra - articular placement of the drug, especially in small joints (Gaffney et al., 1995; Jones et al., 1993). The very high tolerability of the preparation allows the contemporary use of other drugs, which is very important in elderly patients with comorbid conditions and poli - pharmaceutical treated.

Although these promising results, several questions are still opened.

Inclusion and exclusion criteria vary largely in different studies and therefore the characteristics of patients, who are better responsive to treatment, are not clearly defined. The identification of these patients is, therefore, strongly recommended.

No consensus exist about the doses of hyaluronic acid, the interval between doses and the number of injections, which are more effective in the different clinical situations. A 3 - 5 doses regimen is usually recommended, but studies which compare different treatment schedules are lacking (Tikiz et al., 2005).

It is also debated whether high molecular weight hyaluronic acid has to be preferred to low molecular weight hyaluronic acid. The better biological activity, showed by high molecular weight hyaluronic acid preparations *in vitro*, has not been confirmed in clinical trials (Tikiz et al., 2005). Some authors prefer to use high molecular weight hyaluronic acid because these preparations have a longer half - life time, so that the number of the injections needed to obtain the therapeutic effect may be reduced.

Interpretation of result is made difficult by the different degree of severity of osteoarthritis, genetic and biological characteristics of patients enrolled in the studies and by concurrent therapies with other drugs and rehabilitation treatments (Brocq et al., 2002; Conrozier et al., 2003; Migliore et al., 2003; Tikiz et al., 2005; Vad et al., 2003).

Finally, it must be remembered that there is a strong placebo effect from joint injection, which may cause a nearly 30 % reduction in pain relief during the first 2 weeks (Brocq et al., 2002; Egsmose et al., 1984; Kirwan, 2001; Ravaud et al., 1999; Tikiz et al., 2005).

11. References

- Abate, M., Pulcini, D., Di Iorio, A. & Schiavone, C. (2010). Viscosupplementation with intra-articular hyaluronic acid for treatment of osteoarthritis in the elderly. *Curr Pharm Des*, Vol.16, No.6, pp. 631-640
- Abate, M., Pelotti, P., De Amicis, D., Di Iorio, A., Galletti, S. & Salini, V. (2008). Viscosupplementation with hyaluronic acid in hip osteoarthritis (a review). *Ups J Med Sci*, Vol.113, No.3, pp. 261-277
- Aggarwal, A. & Sempowski, IP. (2004). Hyaluronic acid injections for knee osteoarthritis. Systematic review of the literature. *Can Fam Physician*, Vol.50, pp. 249-256
- Altman, R., Alarcon, G., Appelrouth, D., Bloch, D., Borenstein, D., Brandt, K., Brown, C., Cooke, TD., Daniel, W., Feldman, D. & et al. (1991). The American College of Rheumatology criteria for the classification and reporting of osteoarthritis of the hip. *Arthritis Rheum*, Vol.34, No.5, pp. 505-514
- Andrews, JR. (2005). Diagnosis and treatment of chronic painful shoulder: review of nonsurgical interventions. *Arthroscopy*, Vol.21, No.3, pp. 333-347
- Atchia I, Kane D, Reed MR, Isaacs JD, Birrell F. (2011). Efficacy of a single ultrasound-guided injection for the treatment of hip osteoarthritis. *Ann Rheum Dis*, Vol.70, No.1, pp. 110-116
- Bagga, H., Burkhardt, D., Sambrook, P. & March, L. (2006). Longterm effects of intraarticular hyaluronan on synovial fluid in osteoarthritis of the knee. *J Rheumatol*, Vol. 33, No.5, pp. 946-950
- Bannuru, RR., Natov, NS., Obadan, IE., Price, LL., Schmid, CH. & McAlindon, TE. (2009). Therapeutic trajectory of hyaluronic acid versus corticosteroids in the treatment of knee osteoarthritis: a systematic review and meta-analysis. *Arthritis Rheum*, Vol.61, No.12, pp. 1704-1711
- Bellamy, N., Campbell, J., Robinson, V., Gee, T., Bourne, R. & Wells, G. (2006). Viscosupplementation for the treatment of osteoarthritis of the knee. *Cochrane Database of Systematic Reviews*, Vol.19, No.2
- Berg, P. & Olsson, U. (2004). Intra-articular injection of non-animal stabilised hyaluronic acid (NASHA) for osteoarthritis of the hip: a pilot study. *Clin Exp Rheumatol*, Vol.22, No.3, pp. 300-306
- Blaine, T., Moskowitz, R., Udell, J., Skyhar, M., Levin, R., Friedlander, J., Daley, M. & Altman, R. (2008). Treatment of persistent shoulder pain with sodium hyaluronate: a randomized, controlled trial. A multicenter study. *J Bone Joint Surg Am*, Vol.90, No.5, pp. 970-979
- Brocq, O., Tran, .G, Breuil, V., Grisot, C., Flory, P. & Euller-Ziegler, L. (2002). Hip osteoarthritis: short-term efficacy and safety of viscosupplementation by hylan G-F 20. An open-label study in 22 patients. *Joint Bone Spine*, Vol.69, No.4, pp. 388-391
- Brzusek, D. & Petron, D. (2008). Treating knee osteoarthritis with intra-articular hyaluronans. *Curr Med Res Opin*, Vol.24, No.12, pp. 3307-3322
- Caglar-Yagci, H., Unsal, S., Yagci, I., Dulgeroglu, D. & Ozel, S. (2005). Safety and efficacy of ultrasound-guided intra-articular hylan G-F 20 injection in osteoarthritis of the hip: a pilot study. *Rheumatol Int*, Vol.25, No.5, pp. 341-344

- Calis, M., Demir, H., Ulker, S., Kirnap, M., Duygulu, F. & Calis, HT. (2006). Is intraarticular sodium hyaluronate injection an alternative treatment in patients with adhesive capsulitis? *Rheumatol Int*, Vol.26, No.6, pp. 536-540
- Calvillo, O., Skaribas, I. & Turnipseed, J. (2000). Anatomy and pathophysiology of the sacroiliac joint. *Curr Rev Pain*, Vol.4, No.5, pp. 356-361
- Carpenter, B. & Motley, T. (2008). The role of viscosupplementation in the ankle using hylan G - F 20. *Journal of Foot & Ankle Surgery*, Sep-Oct, Vol.47, No.5, pp. 377-384
- Chazerain, P., Rolland, D., Cordonnier, C. & Ziza, JM. (1999). Septic hip arthritis after multiple injections into the joint of hyaluronate and glucocorticoid. *Rev Rhum Engl Ed*, Vol.66, No.7-9, pp. 436
- Cleary, M., Keating, C. & Poynton, AR. (2008). Viscosupplementation in lumbar facet joint arthropathy: a pilot study. *J Spinal Disord Tech*, Vol.21, No.1, pp. 29-32
- Coaccioli, S., Pinoca, F. & Puxeddu, A. (2006). Short term efficacy of intra-articular injection of hyaluronic acid in osteoarthritis of the first carpometacarpal joint in a preliminary open pilot study. *Clin Ter*, Vol.157, No.4, pp. 321-325
- Cohen, MM., Altman, RD., Hollstrom, R., Hollstrom, C., Sun, C. & Gipson, B. (2008). Safety and efficacy of intra - articular sodium hyaluronate (Hyalgan) in a randomized, double - blind study for osteoarthritis of the ankle. *Foot and Ankle International*, Vol.29, No.7, pp. 657-663
- Colen, S., van den Bekerom, MP., Bellemans, J. & Mulier, M. (2010). Comparison of intra-articular injections of hyaluronic acid and corticosteroid in the treatment of osteoarthritis of the hip in comparison with intra-articular injections of bupivacaine. Design of a prospective, randomized, controlled study with blinding of the patients and outcome assessors. *BMC Musculoskelet Disord*, Vol.11, pp. 264
- Conrozier, T., Bertin, P., Mathieu, P., Charlot, J., Bailleul, F., Treves, R., Vignon, E. & Chevalier, X. (2003). Intra-articular injections of hylan G-F 20 in patients with symptomatic hip osteoarthritis: an open-label, multicentre, pilot study. *Clin Exp Rheumatol*, Vol.21, No.5, pp. 605-610
- Cunnington, J., Marshall, N., Hide, G., Bracewell, C., Isaacs, J., Platt, P. & Kane, D. (2010). A randomized, double - blind, controlled study of ultrasound - guided corticosteroid injection into the joint of patients with inflammatory arthritis. *Arthritis Rheum*, Jul, Vol. 62, No.7, pp. 1862-1869
- Curran, MP. (2010). Hyaluronic acid (Supartz®) : a review of its use in osteoarthritis of the knee. *Drugs Aging*, Vol.27, No.11, pp. 925-941
- Dagenais, S. (2006). Intra-articular hyaluronic acid (viscosupplementation) for knee osteoarthritis. *Issues Emerg Health Technol*, Vol.94, pp. 1-4
- Divine, JG., Zazulak, BT. & Hewett, TE. (2007). Viscosupplementation for knee osteoarthritis: a systematic review. *Clin Orthop Relat Res*, Vol.455, pp. 113-122
- Di Sante, L., Cacchio, A., Scettri, P., Paoloni, M., Ioppolo, F. & Santilli, V. (2011). Ultrasound-guided procedure for the treatment of trapeziometacarpal osteoarthritis. *Clin Rheumatol*, Mar 22
- Egsmose, C., Lund, B. & Bach, AR. (1984). Hip joint distension in osteoarthrosis. A triple-blind controlled study comparing the effect of intra-articular indoprofen with placebo. *Scand J Rheumatol*, Vol.13, No.3, pp. 238-242

- El-Hakim, IE. & Elyamani, AO. (2011). Preliminary evaluation of histological changes found in a mechanical arthropatic temporomandibular joint (TMJ) exposed to an intra-articular Hyaluronic acid (HA) injection, in a rat model. *J Craniomaxillofac Surg*, Jan 7
- Fernandez-Palazzi, F., Viso, R., Boadas, A., Ruiz-Saez, A., Caviglia, H. & De Bosch, NB. (2002). Intra-articular hyaluronic acid in the treatment of haemophilic chronic arthropathy. *Haemophilia*, Vol.8, No.3, pp. 375-381
- Flanagan, J., Casale, FF., Thomas, TL. & Desai, KB. (1988). Intra-articular injection for pain relief in patients awaiting hip replacement. *Ann R Coll Surg Engl*, Vol.70, No.3, pp. 156-157
- Fletcher, B. & Sackett, D. (1979). Canadian task force on the periodic health examination: the Periodic Health Examination. *CMAJ*, Vol.121, pp. 1193-1254
- Fuchs, S., Monikes, R., Wohlmeiner, A. & Heyse, T. (2006). Intra-articular hyaluronic acid compared with corticoid injections for the treatment of rhizarthrosis. *Osteoarthritis Cartilage*, Vol.14, No.1, pp. 82-88
- Fuchs, S., Erbe, T., Fischer, HL. & Tibesku, CO. (2005). Intraarticular hyaluronic acid versus glucocorticoid injections for nonradicular pain in the lumbar spine. *J Vasc Interv Radiol*, Vol.16, No.11, pp. 1493-1498
- Gaffney, K., Ledingham, J. & Perry, JD. (1995). Intra-articular triamcinolone hexacetonide in knee osteoarthritis: factors influencing the clinical response. *Ann Rheum Dis*, Vol.54, No.5, pp. 379-381
- Gaston, MS., Tiemessen, CH. & Philips, JE. (2007). Intra-articular hip viscosupplementation with synthetic hyaluronic acid for osteoarthritis: efficacy, safety and relation to pre-injection radiographs. *Arch Orthop Trauma Surg*, Vol.127, No.10, pp. 899-903
- Ghosh, P. & Guidolin, D. (2002). Potential mechanism of action of intra-articular hyaluronan therapy in osteoarthritis: are the effects molecular weight dependent? *Semin Arthritis Rheum*, Vol.32, No.1, pp. 10-37
- Gigante, A. & Callegari, L. (2011). The role of intra-articular hyaluronan (Sinovial) in the treatment of osteoarthritis. *Rheumatol Int*, Vol. 31, No.4, pp. 427-444
- Goto, H., Onodera, T., Hirano, H. & Shimamura, T. (1999). Hyaluronic acid suppresses the reduction of alpha2(VI) collagen gene expression caused by interleukin-1beta in cultured rabbit articular chondrocytes. *Tohoku J Exp Med*, Vol.187, No.1, pp. 1-13
- Griffin, MR., Piper, JM., Daugherty, JR., Snowden, M. & Ray, WA. (1991). Non steroidal anti-inflammatory drug use and increased risk for peptic ulcer disease in elderly persons. *Ann Intern Med*, Vol.114, No.4, pp. 257-263
- Guarda-Nardini, L., Ferronato, G., Favero, L. & Manfredini, D. (2011). Predictive factors of hyaluronic acid injections short-term effectiveness for TMJ degenerative joint disease. *J Oral Rehabil*, Vol.38, No.5, pp. 315-320
- Hanson, EC. (1999). Sodium hyaluronate - application in a community practice. *American Journal of Orthopaedics*, Vol.28, Suppl.11, pp. 11-12
- Heyworth, BE., Lee, JH., Kim, PD., Lipton, CB., Strauch, RJ. & Rosenwasser, MP. (2008). Hylan versus corticosteroid versus placebo for treatment of basal joint arthritis: a prospective, randomized, double-blinded clinical trial. *J Hand Surg [Am]*, Vol.33, No.1, pp. 40-48

- Hiraoka N, Takahashi KA, Arai Y, Sakao K, Mazda O, Kishida T, Honjo K, Tanaka S, Kubo T. (2011). Intra-articular injection of hyaluronan restores the aberrant expression of matrix metalloproteinase-13 in osteoarthritic subchondral bone. *J Orthop Res*, Vol.29, No.3, pp. 354-360
- Hochberg, MC., Altman, RD., Brandt, KD., Clark, BM., Dieppe, PA., Griffin, MR., Moskowitz, RW. % Schnitzer, TJ. (1995). Guidelines for the medical management of osteoarthritis. Part II. Osteoarthritis of the knee. American College of Rheumatology. *Arthritis Rheum*, Vol.38, No.11, pp. 1541-1546
- Hunter, DJ. & Lo, GH. (2008). The management of osteoarthritis: an overview and call to appropriate conservative treatment. *Rheum Dis Clin North Am*, Vol.34, No.3, pp. 689-712
- Itokazu, M. & Matsunaga, T. (1995). Clinical evaluation of high-molecular-weight sodium hyaluronate for the treatment of patients with periartthritis of the shoulder. *Clin Ther*, Vol.17, No.5, pp. 946-955
- Jones, A., Regan, M., Ledingham, J., Pattrick, M., Manhire, A. & Doherty, M. (1993). Importance of placement of intra-articular steroid injections. *BMJ*, Vol.307, No.6915, pp. 1329-1330
- Julovi, SM., Ito, H., Nishitani, K., Jackson, CJ. & Nakamura, T. (2011). Hyaluronan inhibits matrix metalloproteinase-13 in human arthritic chondrocytes via CD44 and P38. *J Orthop Res*, Vol.29, No.2, pp. 258-264
- Karatosun, V., Unver, B., Ozden, A., Ozay, Z. & Gunal, I. (2008). Intra - articular hyaluronic acid compared to exercise therapy in osteoarthritis of the ankle. A prospective randomized trial with long - term follow - up. *Clinical and experimental rheumatology*, Mar-Apr, Vol.26, No.2, pp. 288-294
- Kellgren, JH. & Lawrence, JS. (1957). Radiological assessment of osteo-arthrosis. *Ann Rheum Dis*, Vol.16, No.4, pp. 494-502
- Kikuchi, T., Yamada, H. & Fujikawa, K. (2001). Effects of high molecular weight hyaluronan on the distribution and movement of proteoglycan around chondrocytes cultured in alginate beads. *Osteoarthritis Cartilage*, Vol.9, No.4, pp. 351-356
- Kirwan, J. (2001). Is there a place for intra-articular hyaluronate in osteoarthritis of the knee? *Knee*, Vol.8, No.2, pp. 93-101
- Kumahashi, N., Naitou, K., Nishi, H., Oae, K., Watanabe, Y., Kuwata, S., Ochi, M., Ikeda, M. & Uchio, Y. (2011). Correlation of changes in pain intensity with synovial fluid adenosine triphosphate levels after treatment of patients with osteoarthritis of the knee with high-molecular-weight hyaluronic acid. *Knee*, Vol.18, No.3, pp. 160-164
- Lawrence, RC., Helmick, CG., Arnett, FC., Deyo, RA., Felson, DT., Giannini, EH., Heyse, SP., Hirsch, R., Hochberg, MC., Hunder, GG., Liang, MH., Pillemer, SR., Steen, VD., & Wolfe, F. (1998). Estimates of the prevalence of arthritis and selected musculoskeletal disorders in the United States. *Arthritis Rheum*, Vol.41, No.5, pp. 778-799
- Leardini, G., Perbellini, A., Franceschini, M. & Mattara, L. (1988). Intra-articular injections of hyaluronic acid in the treatment of painful shoulder. *Clin Ther*, Vol.10, No.5, pp. 521-526

- Luciani, D., Cadossi, M., Tesei, F., Chiarello, E. & Giannini, S. (2008). Viscosupplementation for grade II osteoarthritis of the ankle : a prospective study at 18 months' follow - up. *Chir Organi Mov*, Dec, Vol.92, No.3, pp. 155-160
- Mader, R., Lavi, I. & Luboshitzky, R. (2005). Evaluation of the pituitary-adrenal axis function following single intraarticular injection of methylprednisolone. *Arthritis Rheum*, Vol.52, No.3, pp. 924-928
- Manfredini, D., Piccotti, F. & Guarda-Nardini, L. (2010). Hyaluronic acid in the treatment of TMJ disorders: a systematic review of the literature. *Cranio*, Vol.28, No.3, pp. 166-76
- Mei - Dan, O., Kish, B., Shabat, S., Masarawa, S., Shteren, A., Mann, G. & Nyska, M. (2010). Treatment of osteoarthritis of the ankle by intra - articular injections of hyaluronic acid: a prospective study. *J Am Podiatr Med Assoc*, Mar-Apr, Vol.100, No.2, pp. 93-100
- Merolla, G., Sperling, JW., Paladini, P. & Porcellini, G. (2011). Efficacy of Hylan G-F 20 versus 6-methylprednisolone acetate in painful shoulder osteoarthritis: a retrospective controlled trial. *Musculoskelet Surg*, May 13
- Migliore, A., Granata, M., Tormenta, S., Laganà, B., Piscitelli, P., Bizzi, E., Massafra, U., Alimonti, A., Maggi, C., De Chiara, R., Iannesi, F., Sanfilippo, A., Sotera, R., Scapato, P., Carducci, S., Persod, P., Denaro, S., Camminiti, M., Pagano, MG., Bagnato, G. & Iolascon, G. (2011). Hip viscosupplementation under ultra-sound guidance reduces NSAID consumption in symptomatic hip osteoarthritis patients in a long follow-up. Data from Italian registry. *Eur Rev Med Pharmacol Sci*, Vol.15, No.1, pp. 25-34
- Migliore, A., Giovannangeli, F., Granata, M. & Laganà, B. (2010). Hylan g-f 20: review of its safety and efficacy in the management of joint pain in osteoarthritis. *Clin Med Insights Arthritis Musculoskelet Disord*, Vol.20, No.3, pp. 55-68
- Migliore, A., Tormenta, S., Massafra, U., Martin Martin, LS., Carloni, E., Padalino, C., Alimonti, A. & Granata, M. (2006a).[18-month observational study on efficacy of intraarticular hyaluronic acid (Hylan G-F 20) injections under ultrasound guidance in hip osteoarthritis]. *Reumatismo*, Vol.58, No.1, pp. 39-49
- Migliore, A., Tormenta, S., Martin Martin, LS., Iannesi, F., Massafra, U., Carloni, E., Monno, D., Alimonti, A, Granata, M. (2006b). The symptomatic effects of intra-articular administration of hylan G-F 20 on osteoarthritis of the hip: clinical data of 6 months follow-up. *Clin Rheumatol*, Vol.25, No.3, pp. 389-393
- Migliore, A., Tormenta, S., Valente, C., Massafra, U., Martin Martin, LS., Carmenini, E., Bernardini A & Alimonti, A. (2005). [Intra-articular treatment with Hylan G-F 20 under ultrasound guidance in hip osteoarthritis. Clinical results after 12 months follow-up]. *Reumatismo*, Vol.57, No.1, pp. 36-43
- Migliore, A., Tormenta, S., Martin Martin, LS., Valente, C., Massafra, U., Latini, A. & Alimonti, A. (2004). [Safety profile of 185 ultrasound-guided intra-articular injections for treatment of rheumatic diseases of the hip]. *Reumatismo*, Vol.56, No.2, pp. 104-109

- Migliore, A., Martin, LS., Alimonti, A., Valente, C. & Tormenta, S. (2003). Efficacy and safety of viscosupplementation by ultrasound-guided intra-articular injection in osteoarthritis of the hip. *Osteoarthritis Cartilage*, Vol.11, No.4, pp. 305-306
- National Collaborating Centre for Chronic Conditions (UK). (2008). Osteoarthritis: National clinical guideline for care and management in adults. London: Royal College of Physicians (UK)
- O'Regan, M., Martini, I., Crescenzi, F., De Luca, C. & Lansing, M. (1994). Molecular mechanisms and genetics of hyaluronan biosynthesis. *Int J Biol Macromol*, Vol.16, No.6, pp. 283-286
- Pons, M., Alvarez, F., Solana, J., Viladot, R. & Varela, L. (2007). Sodium hyaluronate in the treatment of hallux rigidus. A single-blind, randomized study. *Foot Ankle Int*, Vol.28, No.1, pp. 38-42
- Pourbagher, MA., Ozalay, M. & Pourbagher, A. (2005). Accuracy and outcome of sonographically guided intra-articular sodium hyaluronate injections in patients with osteoarthritis of the hip. *J Ultrasound Med*, Vol.24, No.10, pp. 1391-1395
- Qvistgaard, E., Christensen, R., Torp-Pedersen, S. & Bliddal, H. (2006). Intra-articular treatment of hip osteoarthritis: a randomized trial of hyaluronic acid, corticosteroid, and isotonic saline. *Osteoarthritis Cartilage*, Vol.14, No.2, pp. 163-170
- Qvistgaard, E., Kristoffersen, H., Terslev, L., Danneskiold-Samsoe, B., Torp-Pedersen, S. & Bliddal, H. (2001). Guidance by ultrasound of intra-articular injections in the knee and hip joints. *Osteoarthritis Cartilage*, Vol.9, No.6, pp. 512-517
- Ravaud, P., Moulinier, L., Giraudeau, B., Ayral, X., Guerin, C., Noel, E., Thomas, P., Fautrel, B., Mazieres, B. & Dougados, M. Effects of joint lavage and steroid injection in patients with osteoarthritis of the knee: results of a multicenter, randomized, controlled trial. *Arthritis Rheum*, Vol.42, No.3, pp. 475-482
- Roughead, EE., Ramsay, E., Pratt, N. & Gilbert, AL. (2008). NSAID use in individuals at risk of renal adverse events: an observational study to investigate trends in Australian veterans. *Drug Saf*, Vol.31, No.11, pp. 997-1003
- Roux, C., Fontas, E., Breuil, V., Brocq, O., Albert, C. & Euller-Ziegler, L. (2007). Injection of intra-articular sodium hyaluronidate (Sinovial) into the carpometacarpal joint of the thumb (CMC1) in osteoarthritis. A prospective evaluation of efficacy. *Joint Bone Spine*, Vol.74, No.4, pp. 368-372
- Rovetta, G. & Monteforte, P. (1998). Intraarticular injection of sodium hyaluronate plus steroid versus steroid in adhesive capsulitis of the shoulder. *Int J Tissue React*, Vol.20, No.4, pp. 125-130
- Salini, V., De Amicis, D., Abate, M., Natale, MA., Di Iorio, A. (2009). Ultrasound-guided hyaluronic acid injection in carpometacarpal osteoarthritis: short-term results. *Int J Immunopathol Pharmacol*, Vol.22, No.2, pp. 455-460
- Salk, RS., Chang, TJ., D'Costa, WF., Soomekh, DJ. & Grogan, KA. (2006). Sodium hyaluronate in the treatment of osteoarthritis of the ankle : a controlled, randomized, double - blind pilot study. *J Bone Joint Surg Am*, Feb, Vol.88, No.2, pp. 295-302

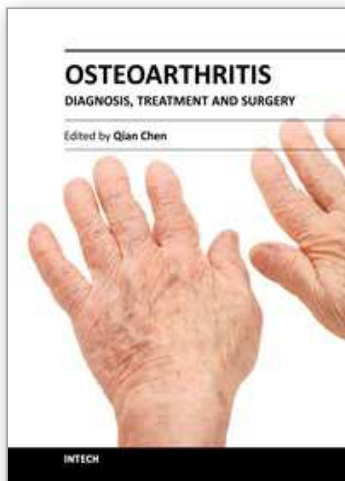
- Salk, R., Chang, T., D'Costa, W., Soomekh, D. & Grogan, K. (2005). Viscosupplementation (hyaluronans) in the treatment of ankle osteoarthritis. *Clin Podiatr Med Surg*, Oct, Vol.22, No.4, pp. 585-597
- Saltzman, CL., Salamon, ML., Blanchard, GM., Huff, T., Hayes, A., Buckwalter, JA. & Amendola, A. (2005). Epidemiology of ankle arthritis : report of a consecutive series of 639 patients from a tertiary orthopaedic center. *Iowa Orthop J*, Vol.25, pp. 44-46
- Savage, R. (2005). Cyclo-oxygenase-2 inhibitors: when should they be used in the elderly? *Drugs ageing*, Vol.22, No.3, pp. 185-200
- Schumacher, HR., Meador, R., Sieck, M. & Mohammed, Y. (2004). Pilot Investigation of Hyaluronate Injections for First Metacarpal-Carpal (MC-C) Osteoarthritis. *J Clin Rheumatol*, Vol.10, No.2, pp. 59-62
- Silverstein, E., Leger, R. & Shea, KP. (2007). The use of intra-articular hylan G-F 20 in the treatment of symptomatic osteoarthritis of the shoulder: a preliminary study. *Am J Sports Med*, Vol.35, No.6, pp. 979-985
- Smalley, WE. & Griffin, MR. (1996). The risks and costs of upper gastrointestinal disease attributable to NSAIDs. *Gastroenterol Clin North Am*, Vol. 25, No.2, pp. 373-396
- Spacek, E., Poiraudou, S., Fayad, F., Lefèvre-Colau, MM., Beaudreuil, J., Rannou, F., Fermanian, J. & Revel, M. (2004). Disability induced by hand osteoarthritis: are patients with more symptoms at digits 2-5 interphalangeal joints different from those with more symptoms at the base of the thumb? *Osteoarthritis Cartilage*, Vol.12, No.5, pp. 366-373
- Srejc, U., Calvillo, O. & Kabakibou, K. (1999). Viscosupplementation: a new concept in the treatment of sacroiliac joint syndrome: a preliminary report of four cases. *Reg Anesth Pain Med*, Vol.24, No.1, pp. 84-88
- Stahl, S., Karsh-Zafir, I., Ratzon, N. & Rosenberg, N. (2005). Comparison of intraarticular injection of depot corticosteroid and hyaluronic acid for treatment of degenerative trapeziometacarpal joints. *J Clin Rheumatol*, Vol.11, No.6, pp. 299-302
- Sturkenboom, MC., Romano, F., Simon, G., Correa-Leite, ML., Villa, M., Nicolosi, A., Borgnolo, G., Bianchi-Porro, G. & Mannino, S. (2002). The iatrogenic costs of NSAID therapy: a population study. *Arthritis Rheum*, Vol.47, No.2, pp. 132-140
- Sun, SF., Chou, YJ., Hsu, CW., Hwang, CW., Hsu, PT., Wang, JL., Hsu, YW. & Chou, MC. (2006). Efficacy of intra - articular hyaluronic acid in patients with osteoarthritis of the ankle : a prospective study. *Osteoarthritis & Cartilage*, Sep, Vol.14, No.9, pp. 867-874
- Takahashi, K., Goomer, RS., Harwood, F., Kubo, T., Hirasawa, Y. & Amiel, D. (1999). The effects of hyaluronan on matrix metalloproteinase-3 (MMP-3), interleukin-1beta(IL-1beta), and tissue inhibitor of metalloproteinase-1 (TIMP-1) gene expression during the development of osteoarthritis. *Osteoarthritis Cartilage*, Vol.7, No.2, pp. 182-190
- Tamai, K., Mashitori, H., Ohno, W., Hamada, J., Sakai, H. & Saotome, K. (2004). Synovial response to intraarticular injections of hyaluronate in frozen shoulder: a

- quantitative assessment with dynamic magnetic resonance imaging. *J Orthop Sci*, Vol.9, No.3, pp. 230-234
- Tikiz, C., Unlu, Z., Sener, A., Efe, M. & Tuzun, C. (2005). Comparison of the efficacy of lower and higher molecular weight viscosupplementation in the treatment of hip osteoarthritis. *Clin Rheumatol*, Vol.24, No.3, pp. 244-250
- Vad, VB., Sakalkale, D., Sculco, TP. & Wickiewicz, TL. (2003). Role of hylan G-F 20 in treatment of osteoarthritis of the hip joint. *Arch Phys Med Rehabil*, Vol.84, No.8, pp. 1224-1226
- Valiveti, M., Reginato, AJ. & Falasca, GF. (2006). Viscosupplementation for degenerative joint disease of shoulder and ankle. *Journal of Clinical Rheumatology*, Vol.12, No.3, pp. 162- 163
- Van Brakel, RW. & Eygendaal, D. (2006). Intra-articular injection of hyaluronic acid is not effective for the treatment of post-traumatic osteoarthritis of the elbow. *Arthroscopy*, Vol.22, No.11, pp. 1199-1203
- Van den Bekerom, MP., Lamme, B., Sermon, A. & Mulier, M. (2008). What is the evidence for viscosupplementation in the treatment of patients with hip osteoarthritis? Systematic review of the literature. *Arch Orthop Trauma Surg*, Vol.128, No.8, pp. 815- 823
- Van den Bekerom, MP., Mylle, G., Rys, B. & Mulier, M. (2006). Viscosupplementation in symptomatic severe hip osteoarthritis: a review of the literature and report on 60 patients. *Acta Orthop Belg*, Vol. 72, No.5, pp. 560-568
- Waddell, DD. (2007). Viscosupplementation with hyaluronans for osteoarthritis of the knee: clinical efficacy and economic implications. *Drugs Aging*, Vol.24, No.8, pp. 629-642
- Wang, W., Li, P., Zhang, YL., Yang, Y., Wang, FL. & Zhang, Y. (2002). [The clinical effects of percutaneous lumbar discectomy combined with sodium hyaluronate in the treatment of lumbar intervertebral disc herniation]. *Zhongguo Xiu Fu Chong Jian Wai Ke Za Zhi*, Vol.16, No.1, pp. 23-25
- Weiss, C. & Band, P. (1995). Musculoskeletal applications of hyaluronan and hylan. Potential uses in the foot and ankle. *Clin Podiatr Med Surg*, Vol.12, No.3, pp. 497-517
- Weitoft, T., Larsson, A., Saxne, T. & Ronnblom, L. (2005). Changes of cartilage and bone markers after intra-articular glucocorticoid treatment with and without postinjection rest in patients with rheumatoid arthritis. *Ann Rheum Dis*, Vol.64, No.12, pp. 1750-1753
- Witteveen, AGH., Sierevelt, IN., Blankevoort, L., Kerkhoffs, GM. & van Dijk, CN. (2010). Intra - articular sodium hyaluronate injections in the osteoarthritic ankle joint : effects, safety and dose dependency. *Foot Ankle Surg*, Dec, Vol.16, No.4, pp. 159-163
- Witteveen, AGH., Giannini, S., Guido, G., Jerosch, J., Lohrer, H., Vannini, F., Donati, L., Schulz, A., Scholl, J., Sierevelt, IN. & van Dijk, CN. (2008). A prospective multi - centre, open study of the safety and efficacy of hylan G-F 20 (Synvisc) in patients with symptomatic ankle (talo - crural) osteoarthritis. *Foot and Ankle Surgery*, Vol.14, No.3, pp. 145-152
- Woo, SB., Wong, TM., Chan, WL., Yen, CH., Wong, WC. & Mak, KL. (2010). Anatomic variations of neurovascular structures of the ankle in relation to arthroscopic portals: a cadaveric study of Chinese subjects. *J Orthop Surg (Hong Kong)*, Apr, Vol.18, No.1, pp. 71-75

- Zhang, Y. & Jordan, JM. (2010). Epidemiology of osteoarthritis. *Clin Geriatr Med*, Aug, Vol.26, No.3, pp. 355-369
- Zwar, RB., Read, JW. & Noakes, JB. (2004). Sonographically guided glenohumeral joint injection. *AJR Am J Roentgenol*, Vol.183, No.1, pp. 48-50

IntechOpen

IntechOpen



Osteoarthritis - Diagnosis, Treatment and Surgery

Edited by Prof. Qian Chen

ISBN 978-953-51-0168-0

Hard cover, 404 pages

Publisher InTech

Published online 02, March, 2012

Published in print edition March, 2012

Osteoarthritis is one of the most debilitating diseases affecting millions of people worldwide. However, there is no FDA approved disease modifying drug specifically for OA. Surgery remains an effective last resort to restore the function of the joints. As the aging populations increase worldwide, the number of OA patients increases dramatically in recent years and is expected to increase in many years to come. This is a book that summarizes recent advance in OA diagnosis, treatment, and surgery. It includes wide ranging topics from the cutting edge gene therapy to alternative medicine. Such multifaceted approaches are necessary to develop novel and effective therapy to cure OA in the future. In this book, different surgical methods are described to restore the function of the joints. In addition, various treatment options are presented, mainly to reduce the pain and enhance the life quality of the OA patients.

How to reference

In order to correctly reference this scholarly work, feel free to copy and paste the following:

Michele Abate and Vincenzo Salini (2012). Hyaluronic Acid in the Treatment of Osteoarthritis: What is New, Osteoarthritis - Diagnosis, Treatment and Surgery, Prof. Qian Chen (Ed.), ISBN: 978-953-51-0168-0, InTech, Available from: <http://www.intechopen.com/books/osteoarthritis-diagnosis-treatment-and-surgery/hyaluronic-acid-in-the-treatment-of-osteoarthritis-what-is-new>

INTECH
open science | open minds

InTech Europe

University Campus STeP Ri
Slavka Krautzeka 83/A
51000 Rijeka, Croatia
Phone: +385 (51) 770 447
Fax: +385 (51) 686 166
www.intechopen.com

InTech China

Unit 405, Office Block, Hotel Equatorial Shanghai
No.65, Yan An Road (West), Shanghai, 200040, China
中国上海市延安西路65号上海国际贵都大饭店办公楼405单元
Phone: +86-21-62489820
Fax: +86-21-62489821

© 2012 The Author(s). Licensee IntechOpen. This is an open access article distributed under the terms of the [Creative Commons Attribution 3.0 License](#), which permits unrestricted use, distribution, and reproduction in any medium, provided the original work is properly cited.

IntechOpen

IntechOpen