

We are IntechOpen, the world's leading publisher of Open Access books Built by scientists, for scientists

4,800

Open access books available

122,000

International authors and editors

135M

Downloads

Our authors are among the

154

Countries delivered to

TOP 1%

most cited scientists

12.2%

Contributors from top 500 universities



WEB OF SCIENCE™

Selection of our books indexed in the Book Citation Index
in Web of Science™ Core Collection (BKCI)

Interested in publishing with us?
Contact book.department@intechopen.com

Numbers displayed above are based on latest data collected.

For more information visit www.intechopen.com



Intra-Articular Injections for the Treatment of Osteoarthritis: Focus on the Clinical Use of Several Regimens

Dong Rak Kwon and Gi Young Park

Departments of Rehabilitation Medicine, Catholic University of Daegu School of Medicine, Daegu, South Korea

1. Introduction

Osteoarthritis is the most common joint disease, and is characterized by progressive loss of articular cartilage, subchondral bone sclerosis, osteophyte formation, synovial membrane changes, and an increase in synovial fluid with decreased viscosity and lubrication properties. Mechanical, biochemical, and genetic factors are all involved in pathogenesis of osteoarthritis (Chevalier, 2002; Wearing et al., 2006).

Given the chronic and non-life-threatening nature of osteoarthritis, a good safety profile is essential. Characteristics of osteoarthritis vary across patients, and several definite clinical patterns have been identified. The choice of a suitable treatment strategy for a patient depends on clinical history, contraindications to specific therapies, and overall tolerability and acceptability of the considered treatment. This is especially true in the elderly, the major targeted people for osteoarthritis therapy, for whom one must consider the risk of upper gastrointestinal or adverse renal effects and the diverse array of concomitantly used medications. Intra-articular injection into osteoarthritic joints may play an important role in the therapeutic plan. Osteoarthritis of weight-bearing joints, such as knee osteoarthritis, is more a local mechanical driven disease than a generalized one. In order to reach a non-vascularized tissue, such as cartilage, local intra-articular administration of drugs should be considered.

Intra-articular injections are one of the clinician's many tools for treatment of osteoarthritis. Injection should be contemplated as an adjunct to the overall treatment plan-never as the sole component of therapy. Injections may be used diagnostically as well as therapeutically and are generally "safe" when used judiciously by a skilled practitioner.

At this time, no targeted treatments for osteoarthritis have been developed. Therefore, preclinical and clinical research studies using other pharmacologic agents that might provide additional benefit are currently underway. A review of these investigational approaches – hyaluronic acid, recombinant human growth hormone, and platelet rich plasma – will be presented here.

1.1 Rationale for intraarticular injection of osteoarthritis

While some patients present with generalized osteoarthritis, which is thought to be strongly influenced by genetic factors, much of osteoarthritis of weight bearing joints can be regarded as a local disease driven by abnormal mechanical stress.

Osteoarthritis, distinct from many other diseases, is amenable to local intraarticular treatment as well as systemic treatment. Though most efforts so far have concentrated on development of systemic treatments, the agents used bear considerable risk of systemic side effects, such as the cardiovascular events and gastrointestinal adverse effects observed in association with most non-steroidal anti-inflammatory drugs and cyclooxygenase-2 inhibitors for treatment of joint pain (Petit-Zeman, 2004; Topol, 2004). The chronic nature of the disease requires development of drugs suitable for chronic systemic treatment with minimal side effects, which is a challenging goal. Local drug application, i.e., injection of drugs directly into the affected joint, is an option for treatment of osteoarthritis which is already frequently used and has the potential to deliver the desired profile.

In summary, progression of knee osteoarthritis results from local factors, which include synovial membrane inflammation, chondrocyte activation, and bone remodeling. Therefore, it appears logical to favor an intra-articular route for treatment of knee (as well as hip) osteoarthritis.

1.2 Advantages and disadvantages of intraarticular administration compared to systemic administration

The main advantage of intraarticular administration is that the drug reaches the cartilage, which includes no blood vessels, and, therefore, is not exposed to circulating drugs (Gerwin et al., 2006). Drugs given by systemic administration may also penetrate the joint fluid from blood via diffusion through the synovium, particularly in cases of active synovitis, as in rheumatoid arthritis. Because the superficial cartilage is altered in osteoarthritis, drugs present in high concentrations in the joint fluid may be able to penetrate within the cartilage by passive diffusion. However, short residence time due to rapid uptake by circulation imposes a major challenge in intra-articular delivery of solutions and correlates with the severity of synovitis (which accelerates drug clearance) (Gerwin et al., 2006). For instance, most hyaluronic acid preparations remain in the joint for only a few hours (half-life, 17 h) (Brandt et al., 2000). This emphasizes the need for development of sustained-release formulas that support continuous release of the drug from a depot in the joint space over a period of several weeks to months.

In the effort to achieve an increase in drug residence time in the synovial cavity, drug delivery systems may be used. Among them, thermally responsive elastin-like polypeptide gels capable of spontaneous aggregation after intraarticular injection represent a simple and innovative way to prolong the intraarticular half-life of a drug. These aggregating elastin-like polypeptides form a drug-depot, resulting in a 25-fold longer half-life than drugs administered with a non-aggregating protein (Betre et al., 2006). Besides the thermo-gelling approach, which is used to increase the retention time of a drug formulation in the joint, pH-sensitive gels are interesting tools. For instance, an intra-articularly injected sustained-release vehicle, such as gelatin hydrogel microspheres, for platelet rich plasma appeared to stimulate cartilage matrix metabolism, suggesting its potential for use in osteoarthritis treatment (Saito et al., 2009).

Aspiration and injection into the knee or other joints is a common technique for both diagnostic and therapeutic purposes, in spite of practical difficulties, such as the lack of accessibility of the joint, and, thus, obstructed needle placement (Jackson et al., 2002). Although rare, complications of intraarticular injections, such as infection, post-injection flare, crystal-induced synovitis, cutaneous atrophy, and steroid arthropathy (Neustadt,

2001), could result in dramatic side effects. The incidence of septic joints related to local steroid injection is about 1 in 10 000 injections, while for post-injection flare, a frequency of around 2% has been reported. Inappropriate injection technique, inexact needle placement, and blockage of synovial outflow by viscous injections have all been suggested as causative factors for development of acute pseudoseptic arthritis (Chen et al., 2002) Therefore, proper needle placement within the intraarticular joint deserves careful attention.

1.3 Technical consideration of intraarticular administration

Although an intra-articular injection of the knee is not a complex procedure, assessment of whether the tip of the needle lies free in the joint or is embedded in synovium or soft tissue before administration of the preparation of medication could be difficult. Some recent studies have called into question the ability of physicians to accurately localize such injections, finding that almost a third of knee injections are inaccurate (Jones & Doherty, 2003). This finding emphasizes the importance of proper needle placement. Needle placement is easily confirmed when an effusion is present. The return of synovial fluid documents intra-articular placement of the needle. In the absence of an effusion, needle placement requires the use of anatomic landmarks and tactile feed-back to help the operator in positioning of the needle. Prior to performance of an injection, all landmarks for entry into the joints were outlined with a marking pen (Fig. 1.).

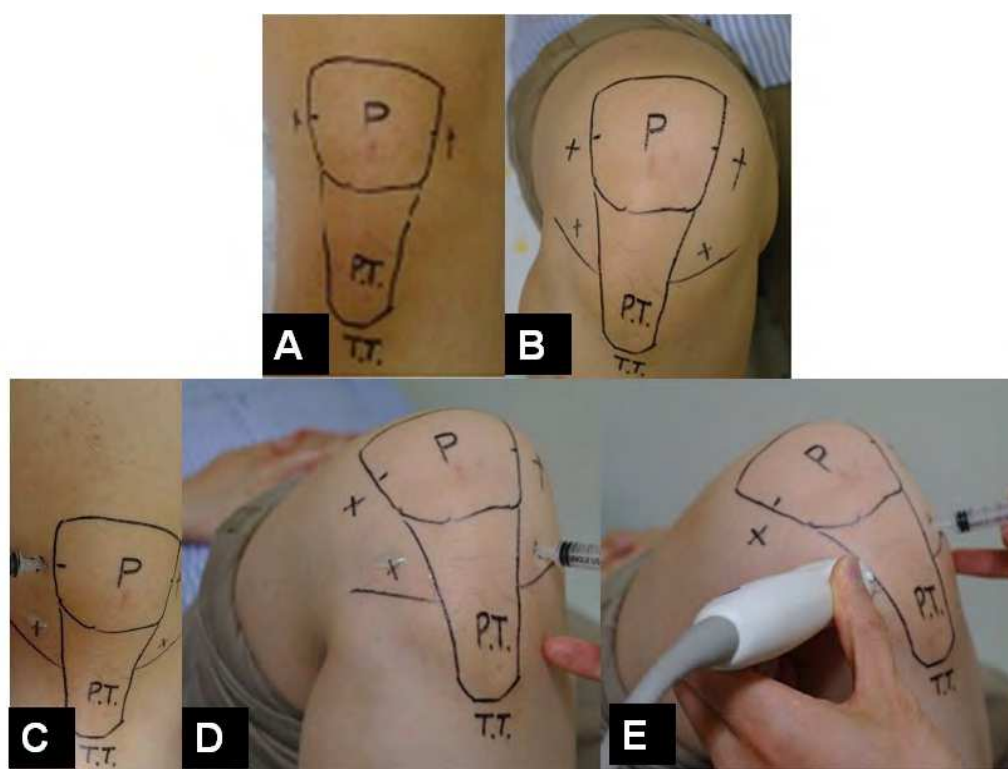


Fig. 1. All landmarks were outlined with a marking pen. A. Landmarks for lateral and medial mid-patellar injections sites. B. Landmarks for anteriomedial and anteriolateral injections sites. C. Lateral mid-patellar injection were performed with the lower limb extended on the examination table. D. Anteriolateral injection were performed with the knee in flexed position. E. Anteriolateral injection via ultrasound guidance were performed with the knee in flexed position.

The operator then stands level with the other knee. With one hand, the patella is pushed up and toward the operator, which causes the lateral/medial edge to become more prominent. Lateral mid-patella and medial mid-patella injections were administered with the lower extremity extended on the examination table. The needle was advanced transversely between the articular surfaces of the patellofemoral joint at the midpoint of the patella. Jackson et al. evaluated the accuracy of needle placement in 80 obese patients undergoing treatment for symptomatic degenerative joint disease (Jackson et al., 2002). They reported difficulty in establishing anatomical landmarks about the knee due to obesity. A large quantity of subcutaneous fat also increases the distance between the skin and the joint space. They used anteromedial, anterolateral, and lateral mid-patella portals. Results of their study demonstrated that injection through the lateral mid-patella approach had an accuracy of 93%. They explained that, when this route is used, the needle passes through a minimal amount of soft tissue in order to reach the intra-articular space; therefore, they recommended use of the lateral mid-patella portal with the knee extended. The extended leg lateral midpatellar approach has been shown to be highly accurate (93%) (Fig. 1.) (Jackson et al., 2002). In patients with severe osteoarthritis, the midpatellar approach may be impractical due to hindrance of the injection pathway by patellofemoral osteophytes (Jackson et al., 2002). To overcome this problem, anteriolateral and anteriomedial injections were performed with the patient's leg hanging over the side of the examination table with the knee flexed to approximately 90 degrees (Fig. 1). On the basis of careful palpation of anatomical landmarks, the injection site was selected inferior to the patella, one finger breadth proximal to the joint surface, and either medial or lateral to the patellar tendon. The needle was directed obliquely toward the intercondylar notch. While accessing the anteriolateral and anteriomedial approach with the patient in the sitting position with the knee bent, these approaches provide only 71-75% accuracy (Neustadt, 2006). Improvement of accuracy has been attempted through use of ultrasound techniques; the operator placed the long axis of the ultrasound transducer over the anteriomedial portion of the knee (Fig. 1.). The modified anteriolateral bent knee approach has been reported to be an effective, accurate, and equivalent alternative to the standard lateral midpatellar approach for intraarticular injection of the knee (Chavez-Chiang et al., 2011). Therefore, any of these approaches might be preferred, depending on the experience of the physician. On the other hand, 100% accuracy could not be obtained through any approach, which should be kept in mind when treating knee problems with intra-articular injections. Injections were administered using a 5 ml syringe, with a 4 cm long needle. Injection and aspiration of the knee is commonly used for both diagnostic and therapeutic purposes. Determination of whether the needle tip lies freely within the joint or is embedded in the synovium or other intra-articular tissues may be difficult. In addition, clinical experience has shown that intra-articular injection is more painful when the tip of the needle is placed in Hoffa's fat pad.

2. Special focus on three intraarticular administration regimens

2.1 Current most available intraarticular injection formulation for treatment of osteoarthritis: Hyaluronic acid

2.1.1 Basic concept of hyaluronic acid

Hyaluronic acid is a very long polysaccharide chain, consisting of repeating disaccharide units of N-acetyl-glucosamine and glucuronic acid. The average molecular weight of synovial fluid hyaluronic acid is 5 to 7×10^6 d, or 12,500 disaccharide units (Balazs &

Denlinger, 1993). Endogenous hyaluronic acid is synthesized by type B synoviocytes and fibroblasts in the synovium and released into the joint space. Hyaluronic acid is a major component of synovial fluid and articular cartilage, and is an important contributor to joint homeostasis (Balazs & Denlinger, 1993). The viscoelasticity and rheology of synovial fluid is due entirely to its hyaluronic acid content.

Hyaluronic acid contributes to the viscous and elastic properties, affording the synovial fluid the peculiar capacity to function differently under distinct loading conditions (Simon, 1999). Viscosity is defined as the ability to dissipate mechanical energy as heat during low shear stress; elasticity is the ability of a molecule to absorb mechanical energy under increased loads. In the presence of low shear forces with slow joint movements, the hyaluronic acid solution exhibits high viscosity with reduced elasticity and acts as a joint lubricant. With increased rates of joint motion (high shear), this is reversed as the synovial fluid becomes more elastic and acts as a shock absorber (Balazs & Denlinger, 1993). The normal adult knee contains approximately 2 mL of synovial fluid, with a hyaluronic acid concentration of 2.5 to 4.0 mg/mL (Watterson & Esdaile, 2000). In patients with osteoarthritis, the concentration and molecular weight of hyaluronic acid in synovial fluid is reduced by a factor of 2 or 3, owing to both degradation and dilution. Furthermore, the molecular weight of the hyaluronate that is present is reduced to as low as 2×10^5 d (Balazs & Denlinger, 1993). These consequences lead to dramatic changes in the viscoelastic properties of the synovial fluid, and, thus, altered joint mechanics. Decreased lubrication leads to increased stress upon the already diseased cartilage, further disrupting the collagen network and the integrity of the chondral surface (Marshall, 2000). Cartilage nutrition and waste removal are also adversely affected. Beyond these mechanical properties, hyaluronic acid has been reported to serve other significant functions within the joint (See Table 1-hyruan injection review). Higher molecular weight hyaluronic acid has been shown to influence a variety of leukocyte functions, including migration, chemotaxis, phagocytosis, adherence, and proliferation. In vitro studies have further demonstrated effects on levels of prostaglandins and cyclic AMP in synovial fluid. In addition to these anti-inflammatory properties, analgesic activity of hyaluronic acid has been demonstrated in both in vitro and animal studies (Ghosh, 1994). This may be mediated both directly via inhibition of nociceptors and indirectly through decrease of synthesis of or binding to bradykinin, substance P, and other hyperalgesic compounds.

Hyaluronic acid may have a chondroprotective effect, inhibiting degradation of cartilage, as well as encouraging its healing and repair. Ghosh (Ghosh, 1994) conducted de novo HA biosynthesis by fibroblasts upon in vitro exposure to exogenous hyaluronic acid. The efficacy of intra-articular injection can be influenced by the concentration and molecular weight of exogenous hyaluronic acid, with molecular weights greater than 5×10^6 being the most effective. Lower molecular weight hyaluronic acid compounds did not elicit a significant biosynthetic response. The author also reported that high molecular weight cross-linked derivatives of hyaluronic acid (hylans) provided a protective effect on chondrocytes exposed to cytokines (IL-1), oxygen-derived free radicals, or leukocyte proteinases. This effect was reversible and viscosity dependant; higher molecular weight hyaluronic acid may yield more superior protection than those with lower molecular weights.

2.1.2 History and development of HA

In the late 1960s, Balazs and coworkers (Balazs & Denlinger, 1993) conducted extensive research into joint fluid rheology and hyaluronic acid, which resulted in definition of the

concept of “viscosupplementation”. Nearly 2 decades would pass before clinical application was achieved. Original source material for study was derived from both human umbilical cord tissue and rooster combs. Subsequently, the noninflammatory fraction of sodium hyaluronan (NIF-NaHA) was developed for therapeutic use in both joint viscosupplementation and ophthalmic viscosurgery. This product (marketed as Healon or Hyartil-Vet) was subsequently used, with some reported success, for treatment of traumatic joint injury in race horses beginning in 1975 (Marshall, 2000). In the late 1980s, 2 NIF-NaHA products, Artz (Seikagaku, Japan) and Hyalgan (Fidia, Italy), were placed on the market overseas for use in human arthritic joints. Because both formulations were lower in molecular weight, clinical recommendations were for 5 weekly injections. Hylans has been reported to improve viscoelastic properties and increase residual time within the joint, as a function of cross-linking. Two forms, a fluid (hylan A) and a gel (hylan B), were produced. Exogenous hylan A has been demonstrated to remain in the knee joint for approximately 1 week after injection; hylan B may be present for as long as 30 days after injection. Hylan G-F 20 (Synvisc) was the first (and remains the only) commercially available cross-linked hyaluronic acid in the United States. Hylan G-F 20 consists of a combination of the fluid and gel forms at a 4:1 ratio (or 20% gel). Its molecular weight is 6×10^6 d, similar to that of hyaluronic acid in a healthy joint. By comparison, the molecular weight of Hyalgan is significantly less (between 5.0 and 7.3×10^5 d). Viscosupplementation with intra-articular hyaluronic acid was first approved by the Food and Drug Administration in 1997. Several different formulations of hyaluronic acid from diverse sources, and with varying composition and molecular weight, are available in the United States for intra-articular injection. By obtaining approval under the category of a “biologic device,” these agents are indicated for treatment of pain in patients with osteoarthritis who have failed to respond to conservative treatment, such as non-pharmacological therapy and simple analgesics. Each of these agents (Table 2) has distinct properties, dosing instructions, cost, and, possibly, clinical outcomes. Viscosupplementation is currently indicated only for treatment of patients with osteoarthritis of the knee. It has been accepted as part of the American College of Rheumatology guidelines for treatment of osteoarthritis and the American Academy of Orthopedic Surgeons guidelines for treatment of osteoarthritis of the knee.

Hyaluronic acid formulations can be obtained by prescription or directly from the clinician’s office, and are dispensed in 2 mL vials or 2 mL prefilled syringes. Currently, the recommended injection schedules are 1 injection weekly for 3 weeks for the cross linked higher molecular weight injection, such as hylan G-F 20. All of these products, except for Euflexxa, are contraindicated in patients with a hypersensitivity to poultry. Any knee effusion should be aspirated before injection in order to prevent dilution of the viscosupplement (Vad et al., 2003). Excessive weight-bearing and activity are limited for 48 to 72 hours after each injection. Repeat courses of viscosupplementation are Food and Drug Administration approved, and have generally led to a 6-month interval period between injections (Raynauld et al., 2005)

2.1.3 Safety profile of hyaluronic acid

The safety profile of intra-articular hyaluronans is very favorable, and, because they are used as a local therapy, there are no known drug interactions—an advantage for patients receiving treatment for comorbid conditions. The total incidence of side effects has been reported to be approximately 1% to 4% per injection (Hammesfahr et al., 2003). The most frequent adverse

effect is local reaction in the injected knee, including mild pain, swelling, warmth, and/or redness at the site of injection. Such reactions are usually temporary, lasting 1 or 2 days, and generally respond well to physiotherapy and non-steroidal anti-inflammatory drugs. In one large, retrospective review of viscosupplementation with hylan G-F 20 (Synvisc), local adverse reactions developed in 28 of 336 patients, with an overall rate of 2.7% per injection. Incidence of adverse events was found to be significantly affected by the injection technique, with a side effects response rate of 5.2% with a medial approach in a flexed knee, versus 1.7% when injected laterally in extension (Hammesfahr et al., 2003). Adverse reactions may be related more to the accuracy of intra-articular injection than the substance itself. As previously mentioned, injection technique is very important. There is growing evidence that hylan G-F 20 in particular may be associated with an adverse event, which has been termed pseudosepsis, or a severe acute inflammatory reaction (Goldberg & Coutts., 2004). This phenomenon has been associated with cross-linked hyaluronic acid. This clinical entity appears to be distinct from previously described minor local inflammatory reactions uncommonly seen with all hyaluronic acid preparations. Pseudosepsis presents as a severe inflammatory process of the joint, with a large effusion, and significant pain occurring within 1 to 3 days of injection. Differential diagnosis is requested from true sepsis or inflammatory arthritis, requiring synovial aspiration and examination. Aspirates of patients with pseudosepsis typically show a moderate cell count with high numbers of mononuclear cells (eosinophils, neutrophils, and macrophages), and the absence of organisms or calcium pyrophosphate crystals.

Pseudosepsis characteristically occurs after previous injection, such as upon receiving the second or third injection in the first course. One report documented a 10-fold increase in the rate of reactions in patients

undergoing a repeat course of hylan G-F 20 viscosupplementation (Leopold et al., 2002). As a result, some authors have supposed an immunologic etiology for this process (Leopold et al., 2002). However, in a recent prospective study comparing aspirates from 16 patients who presented with a severe acute inflammatory reaction after Synvisc treatment with 20 aspirates from control patients with osteoarthritis, analysis was notably more consistent with a type 4 (cell-mediated) hypersensitivity reaction than with an antibody-mediated reaction (Marino et al., 2006). The frequent presence of eosinophils further supports these findings. To date, sodium hyaluronates (Hyalgan, etc) have not been reported to trigger this process, suggesting a link between pseudosepsis and chemical cross-linking modification of the hyaluronic acid molecule in hylan synthesis (Synvisc). Pseudosepsis requires symptomatic treatment, including use of modalities, activity modification, analgesics, and non-steroidal anti-inflammatory drugs. Arthrocentesis is recommended in order to rule out sepsis, and can be helpful in palliation. Once infection has been excluded, intra-articular steroids may be of value (Goldberg & Coutts., 2004).

2.1.4 Preclinical studies

Chondroprotective effects of hyaluronic acid were observed *in vitro*, e.g., that it stimulates production of tissue inhibitors of matrix metalloproteinases by chondrocytes, inhibits neutrophil-mediated cartilage degradation, and attenuates interleukin-1 induced matrix degeneration and chondrocyte cytotoxicity (Brockmeier & Shaffer, 2006). In several studies hyaluronic acid was found to enhance prostaglandin synthesis and to decrease prostaglandin breakdown and release from cartilage matrix (Moreland, 2003). In addition, it was shown to normalize endogenous hyaluronic acid synthesis by synoviocytes (Vuorio et al., 1982).

There has been considerable controversy with regard to whether hyaluronic acid has structure-modifying effects. A number of animal models have been conducted for experimental induction of changes associated with osteoarthritis, such as degradation of collagen and proteoglycans of articular cartilage, and increased inflammation. The most commonly studied models have been total or partial meniscectomy and anterior cruciate ligament transection; it should be noted that these models are quite aggressive in that degenerative changes can occur within a few months after induction. Using these approaches, potential structure-modifying activities of exogenously added hyaluronic acid have been demonstrated in several species. Wiig et al. (Wiig et al., 1990) reported that administration of a single injection of Healon₁ (sodium hyaluronate, MW 1900 - 3900 kDa) (Pharmacia & Upjohn, Uppsala, Sweden) immediately after anterior cruciate ligament transection in rabbits resulted in significantly decreased inflammation, increased collagen synthesis, increased angiogenesis, and enhanced tissue repair, compared with a single injection of saline.

The structure-modifying effects of hyaluronic acid have been investigated using a meniscectomy model in rabbits and sheep. Injection of Artz (Supartz, sodium hyaluronate, MW 620 - 1170 kDa) after partial meniscectomy in rabbits or sheep resulted in significantly inhibited cartilage degeneration (Kikuchi et al., 1996; Armstrong et al., 1994). Five weekly intraarticular injections of sodium hyaluronate, initiated immediately after partial or total meniscectomy, resulted in significantly enhanced collagen remodeling, compared with saline injections (Sonoda et al., 1997, 2000). A course of 5 weekly injections of Artz (Supartz, sodium hyaluronate, MW 620 - 1170 kDa) was found to protect chondrocytes from apoptotic cell death following anterior cruciate ligament transection in a rabbit model (Takahashi et al., 2000).

Following administration to either rabbits or dogs after anterior cruciate ligament transection, Artz (Supartz, sodium hyaluronate, MW 620 - 1170 kDa) was also found to decrease the degree of damage to femoral cartilage and aided in preservation of articular cartilage and integrity of synovial tissue (Yoshioka et al., 1997; Shimizu et al., 1998).

In a study for evaluation of the effects of Synvisc (hylan G-F 20, MW >6000 kDa) (Biomatrix, Montreal, Canada) in a dog anterior cruciate ligament transection model, gross morphological and histological damage within joints that received injections was significantly milder than that seen in control joints (Marshall et al., 2000). Similar results were obtained in rabbits and dogs using Hyalgan (sodium hyaluronate, MW 500 - 730 kDa). A course of 5 weekly Hyalgan injections, starting at 4 or 13 weeks after anterior cruciate ligament transection, resulted in a significantly reduced degree of articular degeneration at evaluations performed 26 weeks after surgery. In this study, rabbits who received 10 injections showed less disease progression than did rabbits treated with five injections, suggesting that a sequential course of Hyalgan therapy may provide long-term benefits for altering the disease course (Amiel et al., 2003). In dogs, initiation of weekly IA injections of sodium hyaluronate starting at 3, 6, or 12 weeks after anterior cruciate ligament transection (the POND-Nuki model of osteoarthritis) resulted in significantly inhibited formation of a fibroblast-like cell layer on the articular cartilage and increased mean chondrocyte density and area in the middle and deep layer of the articular cartilage (Schiavinato et al., 1989). When given starting at 3, 6, or 12 weeks after anterior cruciate ligament transection in dogs, Hyalartz (sodium hyaluronate, MW 500 - 750 kDa) was found to induce a significant reduction in cartilaginous lesions (POND-Nuki model of osteoarthritis) (Wenz et al., 2000).

On the other hand, injection of hyaluronic acid into sheep joints subjected to meniscectomy resulted in significantly more extensive osteophytosis and cartilage fibrillation and reduction in proteoglycan synthesis. A striking reduction in proteoglycan concentration in cartilage was also observed in dogs with anterior cruciate ligament transection who received prophylactic treatment with a series of hyaluronic acid injections. These findings raised concerns that hyaluronic acid treatment could aggravate joint damage in osteoarthritis. Safety and efficacy of intraarticular hyaluronic acid for treatment of pain of osteoarthritis of the knee have been demonstrated; preliminary work supports use of hyaluronic acid for osteoarthritis pain relief in other joints as well. Based on preclinical data, there is evidence to support the notion that all hyaluronic acids approved in the US may have some structure-modifying characteristics. Work in these areas is ongoing.

2.1.5 Clinical studies

The first human clinical trial of intra-articular hyaluronic acid for treatment of arthritis was published by Peyron and Balazs in 1974.

A large number of clinical trials have been conducted with different hyaluronic acid preparations, several of which involve large, multicenter, blinded, randomized, placebo-controlled studies. Early clinical trials attempted to establish the clinical safety of intra-articular hyaluronic acid and its clinical superiority in comparison with placebo (Table 2). Some of these studies have provided evidence that hyaluronic acid preparations are more effective than placebo in reducing pain associated with osteoarthritis (Dixon et al., 1988; Dougados et al., 1993) In contrast, others were unable to demonstrate any significant difference when compared with placebo groups (Henderson et al., 1993; Dahlberg et al., 1994).

Recent attention has focused on comparison of intra-articular viscosupplementation with other osteoarthritis treatment methods (such as oral anti-inflammatories and intra-articular steroid injections). In a multicenter trial in Canada, Adams et al compared the 3 treatment arms: oral non-steroidal anti-inflammatory drugs alone, hylan G-F 20 treatment (3 weekly injections), and combined oral non-steroidal anti-inflammatory drugs and hylan G-F 20 treatment. Patients took their "usual" non-steroidal anti-inflammatory drugs in the appropriate arms. At 12 weeks, all 3 of the groups showed improvement, but no statistical difference was observed between groups. However, at the 26-week time point, both the hylan G-F 20 only and combined non-steroidal anti-inflammatory drugs and hylan G-F 20 groups were statistically superior to the non-steroidal anti-inflammatory drugs only group (Adams et al., 1995). In another large, prospective study, Altman et al compared 5 weekly injections of sodium hyaluronate with a placebo group and with a group of patients treated with oral Naproxen. On the basis of visual analog scores and the Western Ontario and McMaster University Osteoarthritis Index, the hyaluronate group was found to be superior to the placebo group at 26 weeks. The hyaluronic acid group also tended to show improved outcomes, compared with the non-steroidal anti-inflammatory drugs group; however, this finding did not show statistical significance (Altman et al., 1998). Three recent prospective studies have been conducted for comparison of intra-articular hyaluronic acid to intra-articular corticosteroids. In 1 randomized, blinded comparative trial, 63 patients were stratified to receive 5 weekly injections of sodium hyaluronate or 1 injection of triamcinolone followed by 4 placebo injections. Patients were followed for 6 months with VAS assessments of pain with trends suggesting some benefit of viscosupplementation over

intra-articular steroids. However, due to a high drop-out rate, the findings were not statistically significant (Jones et al., 1995). Leopold et al conducted a prospective comparison of 2 cohorts of patients with knee osteoarthritis. Patients in the first group received 3 weekly injections with hylan G-F 20, whereas those in the second group received 1 injection of intra-articular betamethasone, and were able to request 1 additional corticosteroid injection if needed, over the course of the study. Although both groups showed improvement, at 6 months, no significant difference was noted between the 2 cohorts with respect to WOMAC scores, VAS, or the Knee Society Scoring System (Leopold et al., 2003). In a more recent report from the Synvisc 901 study group, Caborn et al used the Western Ontario and McMaster University Osteoarthritis Index and Visual analogue scores pain scores to compare the 2 groups of patients who received either 3 weekly injections of hylan G-F 20 or 1 isolated injection of triamcinolone. This study was not blinded. In their study, maximal benefit was noted at week 2 for the steroid group and at week 12 for the hylan G-F 20 group. From week 12 through week 26, significantly superior outcomes were observed in patients treated with hylan G-F 20 when compared with those treated with intra-articular steroids (Caborn et al., 2004).

In the most recent meta-analysis from the Cochrane database, one research study obtained 76 randomized placebo-controlled trials that fulfilled strict study design and methodology criteria. On the basis of their analysis of the literature, the authors concluded that viscosupplementation is an effective treatment for osteoarthritis of the knee, with favorable effects on pain, function, and patient global assessment, particularly during weeks 5 to 13 after the injection period (Bellamy et al., 2006).

Conservative treatments for osteoarthritis may be characterized as symptom-modifying or disease-modifying drugs. As defined by the Osteoarthritis Research Society, disease-modifying drugs are those that are intended to prevent, retard, stabilize, or reverse development of morphological changes of osteoarthritis (Altman et al., 1996). At present, no pharmacological treatments for osteoarthritis have been approved for the indication of modifying the rate of osteoarthritis disease progression. Intra-articular hyaluronic acid is currently indicated only as a symptom-modifying treatment for osteoarthritis of the knee.

However, evaluation of novel agents and agents with established symptom-modifying activity for disease-modifying effects has become a major focus of research on osteoarthritis. In an effort to obtain evidence for disease-modifying efficacy of hyaluronic acid injections, a large number of clinical trials have been conducted with different hyaluronic acid preparations over the past 25 years. However, there is substantial evidence to suggest that hyaluronic acid in certain patient populations can also have disease modifying activity. This possibility was initially suggested by the finding that the pain-relieving benefit of intraarticular hyaluronic acid generally persists for considerably longer than its half-life within the injected joint, which has been estimated in animal studies to be as short as 18 to 24 h (Sakamoto et al., 1984). For example, clinical efficacy in randomized, controlled trials has been demonstrated to last for at least 26 weeks for Hyalgan®(sodium hyaluronate, average molecular weight 500 -730 kDa) (Altman et al., 1998) and may last as long as a year or more in some patients (Kotz & Kolarz, 1999). Similarly, Synvisc_ (hylan G-F 20, average MW >6000 kDa) (Wobig et al., 1998) (Genzyme Biosurgery, Cambridge, MA), and Supartz® (sodium hyaluronate, average MW 630 - 1120 kDa) (Puhl et al., 1993) (Seikagaku Corporation, Tokyo, Japan) have also demonstrated months of pain relief. Although many of these studies were well designed, the results are difficult to interpret due to a number of

factors. A number of these studies used highly subjective, non-validated rating scales. Different formulations and treatment regimens were often used, limiting study comparisons. Patient treatment groups were often heterogenous, leading to stratified outcomes based on characteristics such as age and disease severity.

The ideal candidate for intra-articular hyaluronic acid has yet to be clearly defined. Despite clinical evaluations, age, symptoms, and disease severity have not proven helpful in identifying patients who may best benefit. One early placebo-controlled trial indicated increased benefit among older patients with more significant osteoarthritis. (Lohmander et al., 1996)

In another study, Dahlberg et al evaluated a group of patients with normal radiographs and early arthritic changes observed at arthroscopy. They reported no significant benefit from 5 weekly injections of sodium hyaluronate (compared with placebo) (Dahlberg et al., 1994). Despite failure to identify the optimal cohort, there is reason to believe that the greatest potential benefit of hyaluronic acid would likely be among younger patients, as some clinical data have suggested that younger patients are more likely to respond. In a meta-analysis by Wang et al, 35 patients older than 65 years of age and those with the most advanced stages of arthritic change (ie, complete loss of joint space) were found to be less likely to show improvement with hyaluronic acid therapy. Jubb et al., in a large, randomized study for evaluation of the disease-modifying effects of sodium hyaluronate in knee osteoarthritis, demonstrated that viscosupplementation, compared with placebo, significantly reduced the radiographic progression of joint space loss in the subset of patients with a higher joint space area at study entry. Currently, intra-articular hyaluronic acid therapy should be considered in patients who have failed standard non-pharmacologic and pharmacologic treatment options, those who have a contraindication to non-steroidal anti-inflammatory drugs, and those who are trying to delay or are poor candidates for surgical treatment. (Jubb et al., 2003)

2.2 Candidate drugs for disease-modifying intraarticular injection regimens

Metabolism of mature articular cartilage is regulated by a number of growth factors that are delivered from cellular production within the cartilage, as well as from the synovial fluid and surrounding tissues. As the mechanisms of action for these growth factors are obtained through well-defined in vitro studies, it is becoming clear that growth factors may eventually serve to augment current cartilage repair techniques.

Chemotactic growth factors may be used to encourage cell migration to an injury site. Cell numbers can be increased and matrix production up-regulated by release of appropriate local growth factors via scaffolds or other methods of intra-articular administration.

Growth factors are a group of biologically active polypeptides produced by the body, which can stimulate cellular division, growth, and differentiation. In articular cartilage, numerous growth factors work in concert to regulate development and homeostasis of articular cartilage throughout life (Goldring et al., 2009). Therefore, growth factors offer promising treatments for enhanced regeneration of cartilage in situations of widespread cartilage loss, such as those that occur in osteoarthritis. When considering an osteoarthritic joint, the effects of any treatment, such as growth factors, on cartilage, synovial lining, ligaments, tendons, meniscus, any exposed subchondral bone, as well as on mesenchymal stem cells that gain access to the articular environment should be collectively considered. Numerous anabolic growth factors stimulate chondrocyte synthesis of proteoglycans, aggrecan, and

type II collagen, induce synoviocyte and mesenchymal stem cell proliferation, drive chondrogenic differentiation of mesenchymal stem cells, and decrease the catabolic effects of cytokines, such as interleukin-1 and matrix metalloproteinases. In addition to being proanabolic and anticatabolic to restoration of cartilage in naturally occurring disease, an ideal growth factor for general cartilage tissue engineering or regeneration in osteoarthritis would be effective regardless of the patient's age or the presence of osteoarthritis and would have no detrimental effects on either cartilage or the synovial lining.

Historically, most growth factors have been evaluated on an independent basis, rather than in combination, in order to assess their effects on cartilage homeostasis *in vitro* or *in vivo*. Given the array and interactions of growth factors necessary for proper cartilage development and homeostasis, it is unlikely that any single growth factor will lead to complete cartilage repair or affect the arthritic milieu, but rather a combination approach will be required.

In the following review, some key players are portrayed comprehensively. Obviously, the collected insights indicate a major potential for regulation of cartilage and chondrocytes in disease and regeneration within the organism and in tissue engineering if the structural properties and dynamics of natural hormone activity are carefully considered. Individual characteristics of growth factors are described.

Transforming Growth Factor- β 1 stimulates chondrocyte synthetic activity and decreases the catabolic activity of interleukin-1 (Blaney et al., 2007). *In vitro*, Transforming Growth Factor- β 1 stimulates chondrogenesis of synovial lining and bone marrow-derived mesenchymal stem cells (Fan et al., 2010; Kurth et al., 2007). In addition, promising studies in rabbits have demonstrated Transforming Growth Factor- β 1-enhanced repair of cartilage defects (Diao et al., 2009). However, in mouse and rabbit animal studies, numerous deleterious side effects of Transforming Growth Factor- β 1 supplementation have been announced, including stimulation of synovial proliferation and fibrosis, attraction of inflammatory leukocytes to the synovial lining, and induction of osteophyte formation (Bakker et al., 2001; Blaney et al., 2007). Given these serious safety concerns, which are not components of other growth factor-based strategies, Transforming Growth Factor- β 1 therapy is not presently a suitable option for use in the articular environment.

Insulin like growth factor is a circulating cytokine that reaches articular cartilage through the synovial fluid. Insulin like growth factor is a single polypeptide with protein sequencing similar to that of insulin. Insulin like growth factor -1 is the main anabolic growth factor for articular cartilage.

It plays a key role in cartilage homeostasis, balancing proteoglycan synthesis and breakdown by chondrocytes. *In vitro* studies have demonstrated that Insulin like growth factor -1 stimulates proteoglycan production in a dose-dependent manner, as evidenced by increased [35 S]-sulfate incorporation (Coutts et al., 1997). Similarly, Insulin like growth factor -1 has been shown to slow proteoglycan catabolism in a dose-dependent fashion (Hickey et al., 2003).

The role of Insulin like growth factor -I in articular cartilage metabolism in both health and disease has been extensively evaluated (Denko et al., 1994; MaQuillan et al., 1986; Middleton et al., 1996; Posever et al., 1995; Wang et al., 1995). When added exogenously to monolayer or explant cultures of normal articular cartilage from a variety of species, Insulin like growth factor-I induces a plethora of anabolic effects and decreases catabolic responses (Sah et al., 2008; Schalkwijk et al., 1989; Tyler 1989). Chondrogenic differentiation of mesenchymal stem

cells is induced by Insulin like growth factor-I, but is enhanced when Insulin like growth factor -I and Transforming Growth Factor-b1 are used in combination (Longobardi et al., 2006; Worster et al., 2001). The premise that Insulin like growth factor-I is required for maintenance of articular cartilage integrity is supported by an in vivo study in rats in which chronic Insulin like growth factor-I deficiency led to development of articular cartilage lesions (Ekenstedt et al., 2006). In animal models, Insulin like growth factor-I has led to enhanced repair of extensive cartilage defects and protection of the synovial membrane from chronic inflammation (Fortier & Miller, 2006; Goodrich et al., 2007). However, studies of human articular cartilage indicate that serum Insulin like growth factor-1 levels and chondrocyte responsiveness to Insulin like growth factor-1 diminish progressively with age (Ashton & Matheson, 1979; Boehm et al., 2007; Fortier & Miller, 2006; Loeser et al., 2002; Loeser et al., 2000; Martin et al., 1997; Trippel, 1995) This finding suggests that a simultaneous decrease in the amount of Insulin like growth factor-1 available and a reduced ability of cells to respond to the remaining Insulin like growth factor may produce cartilage that is less capable of maintaining its structural and functional integrity. Insulin like growth factor non-responsiveness has been further observed to exist in chondrocytes from arthritic cartilage or in the presence of inflammation (Verschure et al., 1996). The cellular response to Insulin like growth factor-1 is receptor mediated and Insulin like growth factor binding proteins in synovial fluid appear to regulate the amount of free Insulin like growth factor-1 available for receptor binding (Trippel, 1995).

Age-related decline in the responsiveness of chondrocytes to Insulin like growth factor-1 appears to be due at least in part to overexpression of Insulin like growth factor binding proteins. Chondrocytes from patients with osteoarthritis have been observed to generate excessive levels of Insulin like growth factor-1 binding proteins (Martin et al., 1997; van den Berg et al., 1999). It has also been suggested that a defect in Insulin like growth factor receptor binding or postreceptor signaling may contribute to Insulin like growth factor non-responsiveness in aged and arthritic cartilage (Verschure et al., 1996; coutts et al., 2003; Hickey et al., 2003).

Evidence suggests an uncoupling of Insulin like growth factor-I responsiveness in osteoarthritis with Insulin like growth factor-I having the ability for robust stimulation of matrix synthesis with an inability to decrease matrix catabolism (Morales, 2008). Despite the diminished ability of Insulin like growth factor-I to decrease catabolism in aged and osteoarthritis cartilage, studies have suggested that a combination of Insulin like growth factor-I and bone morphogenetic protein-7 results in greater potential for repair than either growth factor alone (Chubinskaya et al., 2007; Loeser et al., 2003). These studies demonstrated that, in general, bone morphogenetic protein-7 was more potent than Insulin like growth factor-I in stimulating matrix synthesis in aged and osteoarthritis cells; however, the greatest increase in matrix synthesis was observed after combination treatment with bone morphogenetic protein-7 and Insulin like growth factor-I.

Platelet-derived growth factor is a locally produced and locally acting growth factor. It is synthesized by smooth muscle cells, fibroblasts, endothelial cells, and macrophages and is stored primarily in platelets (Lee, 2000).

Platelet-derived growth factor plays a fundamental role in the wound healing cascade. It is present in high concentrations in platelets and in fluids generated during the early stage of wound healing (Spindler et al., 1995). Platelet-derived growth factor is a potent mitogenic and chemotactic factor for cells of mesenchymal origin, including fibroblasts, osteoblasts,

and chondrocytes, and is thus believed to be capable of enhancing tissue regeneration and repair. Platelet-derived growth factor receptors have been identified on a number of cell types, including chondrocytes, and the number of receptors is up-regulated by the presence of inflammatory cytokines, such as interleukin-1 (Smith et al., 1991).

Indirect evidence for the role of Platelet-derived growth factor and other growth factors active in the wound healing process can be seen from the healing response in cartilage defects treated with microfracture. This procedure involves creation of microperforations in subchondral bone with an arthroscopic awl in and around a chondral lesion (Steadman et al., 2001). The mechanical integrity of the bone is maintained through careful placement of holes. The awl is driven to a depth of 2-4 mm to ensure that the marrow space is accessed and bleeding is observed. A clot forms in the defect, which is anchored to the bone by the increased surface roughness produced by the microperforations. Growth factors such as Platelet-derived growth factor are released into the defect site, exerting chemotactic and mitogenic effects on cells in the surrounding cartilage and infiltrating mesenchymal stem cells. This provides an enriched environment for new tissue formation, which may be augmented by placement of a scaffold seeded with autologous cells (Breinan et al., 2000; Dorotka et al., 2005).

Platelet-derived growth factor exists as a homodimer (Platelet-derived growth factor-AA or Platelet-derived growth factor-BB) or a heterodimer (Platelet-derived growth factor-AB). Evidence to support the use of Platelet-derived growth factor in cartilage repair has been extrapolated from the role of Platelet-derived growth factor in wound healing or stimulation of matrix synthesis in growth plate chondrocytes (Schmidt et al., 2006). In vivo, when injected into the knee of skeletally immature rats, no adverse effects were noted in the cartilage or synovial membrane (Hulth et al., 1996). Presently, the most commonly used form of Platelet-derived growth factor is within the milieu of platelet-rich plasma, as discussed subsequently.

2.2.1 Growth hormone

Growth and homeostasis of cartilage tissue, particularly chondrocytes, during embryogenesis, postnatal development, and adulthood is governed by a significant number of humoral factors. Those factors may also be used during intrinsic or artificial repair and induced regeneration. Unfortunately, many of them also appear to accompany degenerative disease processes, such as osteoarthritis, and the question remains as to what extent they are involved in disease processes or whether they are actually a signature of ongoing endogenous repair pathways (Gaissmaier et al., 2008).

Paracrine components can be delivered through typical nutrient supply mechanisms, ie, fluid flow under compressive loading, which also delivers blood based hormones, such as insulin and cytokines. Alternatively, certain elements are retained in the extracellular matrix, including Insulin-like growth factor Insulin like growth factor-1 and Insulin like growth factor-binding proteins, or ions, like potassium, which is the major counter ion for sulfate residues on glycosaminoglycans, and calcium (which is stored in mineralized cartilage) bound in part to matrix vesicles and chondrocalcin (collagen type II C-propeptide) (Gaissmaier et al., 2008). The insulin-like growth factor signaling axis is involved in maintenance of matrix metabolism in articular cartilage (McQuillan et al., 1986) A demise in metabolic control of cartilage matrix content is the hallmark of degenerative osteoarthritis (Mankin et al., 2000).

Growth hormone is an important regulator of skeletal growth and bone mineral density. It also stimulates cartilage growth, probably through local and systemic Insulin like growth factor-1 production, and possibly by direct stimulation of cartilage cell proliferation. Circulating Growth hormone or one of its mediators may accelerate healing of osteochondral defects through stimulation of osseous and chondral tissue formation (Adam et al., 1995).

Until recently, the effect of exogenous Growth hormone administration in the process of skeletal repair has remained controversial. Bak *et al.* studied 36 rats with closed diaphyseal tibial fractures with intramedullary nailing. In this study, all rats received subcutaneous injections of recombinant human Growth hormone (1 mg) twice per day. Significant improvement in maximal stiffness and ultimate load-bearing were observed during evaluation performed after 40 days of healing (Bak et al., 1990). Kolbeck *et al.* studied 23 dogs with experimentally-induced 3 cm ulnar bone defects and intramedullary fixation. Dogs were injected with recombinant bovine Growth hormone (1 mg), and several of these Growth hormone -treated dogs showed closure of these bone defects, while the remainder demonstrated healing. They reported that administration of homologous Growth hormone stimulates callus formation and ossification in the early phase of bone healing, which consequently results in increased mechanical strength and stiffness (Kolbeck et al., 2003). On the contrary, Growth hormone administration showed no measurable effects on fracture healing in a standardized tibia osteotomy rabbit model (Carpenter et al., 1992).

Morphoangiogenesis was initially identified in the knees of adult rabbits undergoing intra-articular Growth hormone injections for articulo-physeal cartilage regeneration (Dunn, 2002). In this experiment, the regeneration cascade resulted in transformation of central arteries in subchondral osteones into tortuous, thin-walled fenestrated capillary structures containing erythrocytes, histiocytes, stem cells, and chondrocytes. This morphoangiogenesis might promote generative and constructive action in joints. The exact mechanisms of intra-articular growth hormone are unclear; however, synovial fluid growth hormone could enhance proliferation, matrix synthesis, and differentiation of bone and cartilage cells *in vitro* (Goldspink & Goldberg, 1975).

Kim et al. conducted a study of 30 rabbits with collagenase-induced osteoarthritis. After intra-articular collagenase injection, mature New Zealand white rabbits (n=30) were divided into 3 groups. Group 1 (control rabbits) received once-weekly intra-articular saline injections for 4 weeks. Group 2 rabbits received 6 mg hyaluronic acid injections, and group 3 rabbits were injected with 6 mg hyaluronic acid and 3 mg recombinant human growth hormone. These injections were initiated 4 weeks after collagenase injections. Lameness was observed for 9 weeks after collagenase injections. Macroscopic and histopathological knee joint findings were also evaluated at the end of 9 weeks after collagenase injections. Although all animals had lameness after collagenase injections, the duration and severity of lameness were significantly shorter and less severe in group 3 than in groups 1 and 2 ($P<0.01$) (Fig. 2.) Macroscopic scores showed that femoral condyles of group 3 rabbits received significantly less cartilage damage than those of rabbits in groups 1 and 2 ($P<0.01$) (Fig. 2.) Histopathological score was also the lowest in group 3 ($P<0.01$) (Fig. 2.)

They reported that co-injection of intra-articular HA and recombinant human growth hormone may be more effective than hyaluronic acid injections alone in an osteoarthritis model. Novel combined therapy of hyaluronic acid with chondrocyte protective functions and recombinant human growth hormone with generative and constructive actions in

osteoarthritis-affected joints may be a promising treatment option for osteoarthritis (Kim et al., 2011). The recombinant human growth hormone used in this study is a sustained-release formula, which induced continuous serum Insulin like growth factor-1 elevation for 6 days after a single injection. This product also exhibited greater than 95% bioavailability. Sustained release growth hormone was used in this study. Previously-marketed daily injections have provided distinct peaks and troughs of growth hormone concentrations over a period of 24 hours. The pharmacokinetic profile of recombinant Growth hormone differs from that of normal physiologic growth hormone, with distinct bursts (Laursen et al., 1995). Using poly lactic glycolic acid microparticles for the first time, Genentech and Alkermes developed the Nutropin Depot® as a sustained-release human growth hormone formulation. Nutropin Depot® appeared to achieve stable therapeutic Insulin like growth factor-1 target levels for at least 14 days with higher efficacy and without supraphysiological growth hormone concentrations at all times. Nutropin Depot® required the fewest number of injections for achievement of growth hormone levels within the target range, and appealed to patients in its convenience and compliance. However, the poly lactic glycolic acid particle size of microspheres was too large for efficient suspension in an injection medium. Therefore, injections through a 21 to 23 gauge are inevitable. Complexities with a long-acting protein delivery system using poly lactic glycolic acid include inflammation and protein denaturation by hydrophobic interactions and harsh acidic microenvironments. These complexities decrease the bioavailability of Nutropin Depot® (Fu et al., 2000). However, recombinant human growth hormone in medium chain triglycerides can be easily injected through a 26 to 27 gauge needle due to the small particle size and localized lecithin on the microparticle surfaces.

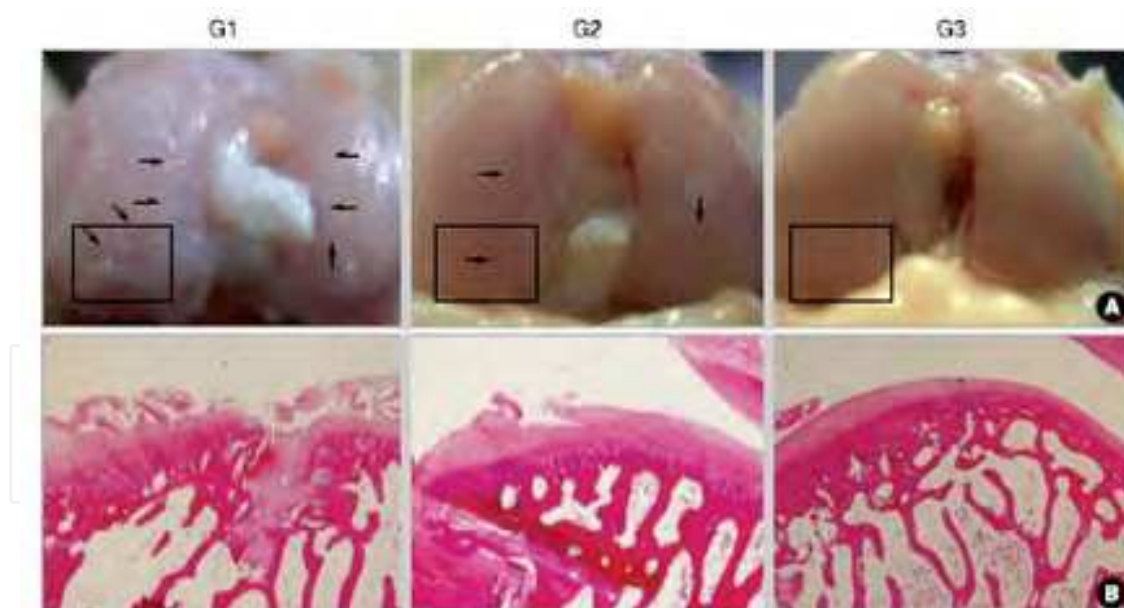


Fig. 2. (A) Gross findings of the femoral condyles in Group 1 (G1), Group 2 (2), and Group 3 (3) rabbits. (B) histologic findings of axial sections obtained at the rectangular areas shown in column A photographs (H&E staining, $\times 40$). The loss of cartilage is seen on the femoral condyle (black arrows). (From Kim SB, Kwon DR, Kwak H, Shin YB, Han HJ, Lee JH, Choi SH. Additive effects of intra-articular injection of growth hormone and hyaluronic acid in rabbit model of collagenase-induced osteoarthritis. *J Korean Med Sci.* 2010 May;25(5):776-780; with permission.)

Lis evaluated diagnostic usefulness of Insulin like growth factor-1 and human growth hormone serum level in osteoarthritis. Twenty five patients with coxarthrosis and 16 healthy persons were enrolled for measurement of Insulin like growth factor-1 and human growth hormone concentration in serum. Insulin like growth factor-1 and human growth hormone serum level were assayed by enzyme-linked immunosorbent assay. No significant correlation was observed between human growth hormone and Insulin like growth factor-1 in serum. Insulin like growth factor-1 concentration in patient serum was found to be significantly lower than that in the control group. They reported that serum concentration of Insulin like growth factor-1 appears to be a useful laboratory marker of osteoarthritis (Lis, 2008).

As previously mentioned, studies of human articular cartilage indicate that serum Insulin like growth factor-1 levels and chondrocyte responsiveness to Insulin like growth factor-1 diminish progressively with age (Ashton & Matheson, 1979; Boehm et al., 2007; Fortier & Miller, 2006; Loeser et al., 2002; Loeser et al., 2000; Martin et al., 1997; Trippel, 1995) This suggests that a simultaneous decrease in the amount of Insulin like growth factor-1 available and a reduced ability for cells to respond to the remaining Insulin like growth factor may cause cartilage to be less capable of maintaining its structural and functional integrity. Insulin like growth factor non-responsiveness has been further observed to exist in chondrocytes from arthritic cartilage or in the presence of inflammation (Verschure et al., 1996). Growth hormone stimulates cartilage growth, probably through production of local and systemic Insulin like growth factor-1.

Recombinant human growth hormone is produced in laboratories. Several well known pharmaceutical companies manufacture recombinant human growth hormone. Recombinant human growth hormone is pure and free of all viruses. Recombinant human growth hormone has been manufactured for several years and is approved by the Food and Drug Administration for several uses, such as inducing growth of short children to a normal size. However, it has not yet been approved by the Food and Drug Administration for injection in joints, which is an "off-label" use. There is interest in the use of growth hormone as a potential osteoarthritis disease-modifying treatment; however, few studies of its effects in humans have been conducted.

2.3 Platelet Rich Plasma (PRP)

2.3.1 Basic science of PRP

Platelets were thought to act solely in the clotting cascade. In addition to local hemostasis at sites of vascular injury, platelets contain an abundance of growth factors and cytokines that are crucial in soft tissue healing and bone mineralization (Anitua et al., 2006). Besides, we know that platelets also discharge many bioactive proteins responsible for attracting macrophages, mesenchymal stem cells, and osteoblasts, which not only promote scavenging of necrotic tissue but also facilitate tissue regeneration and healing (Sampson, 2008). The concept that application of PRP would result in improvement of cartilage repair is based on the physiological role of platelets in wound healing (Nurden et al., 2008). Platelet rich plasma is composed of 3-8 times the concentration of platelets contained in whole blood; therefore, it contains a hyperphysiological content of autologous growth factors. Of note, a universally accepted definition of platelet rich plasma in terms of concentration does not exist. Giusti et al., postulated that the most efficacious concentration of platelets for stimulation of angiogenesis in vitro was 1.5×10^6 platelets/L. In an adult, the normal platelet

count is approximately 150,000-450,000 platelets/L. (Giusti et al., 2009) There are classification schemes that categorize platelet concentrates based on relative concentrations of platelets, leucocytes, and fibrin, and, although it is important to recognize and understand that there are obvious differences between types of platelet concentrates that are being used, the general term/abbreviation, PRP, is used herein (Dohan Ehrenfest et al., 2009). Several centrifuge devices (harvest SmartPRP APC+TM, Huons®sPRP etc) are commercially available for use in physicians' offices. These devices achieve varying concentrations, with whole blood-to-platelet ratios ranging from 1:2 to 1:8. The ratio of white blood cell content also varies with the device. Obviously, the ratio of plasma to platelets in autologous blood is 1:1. Due to a lack of high-quality studies, the ideal ratio of plasma to platelets and the ideal amount of white blood cell concentrate is not well established at this time.

In response to tissue injury, clots rich in platelets and fibrin form a scaffold for subsequent healing. There are over 1500 proteins within platelets, and, among them, are growth factors stored in platelets as granules, which are known to play important roles in the normal healing response, including Platelet-derived growth factor, vascular endothelial growth factor, transforming growth factor- β , fibroblast growth factor, and epidermal growth factor (Qureshi et al., 2009). Through modulation of the inflammatory response, promotion of local angiogenesis, attraction of fibroblasts and local stem cells to the site of injury, and induction of autocrine growth factor production by uninjured adjacent cells, platelets and their products are instrumental in repair and regeneration of normal tissue.

In addition to the growth factors mentioned, there are several others that have been evaluated for their role in chondrogenesis, and it could be concluded that these factors will therefore be important during cartilage regeneration or repair. Clearly, numerous growth factors are needed for proper sequencing of chondrogenesis, and it is likely that more than a single growth factor will be needed for achievement of hyaline cartilage tissue in a reparative procedure. It is becoming increasingly clear that growth factors can work synergistically to enhance cartilage matrix synthesis, as in the case of bone morphogenetic protein-7 and Insulin like growth factor-I (Loeser et al., 2003), and Insulin like growth factor-I, fibroblast growth factor-2, and transforming growth factor- β differentially regulate their own and each other's gene expression and protein production in vitro (Shi et al., 2009). Based on the concept that a combination of bioactive growth factors is likely necessary for cartilage repair, and the increasing application of autogenous biologics for tissue engineering, recent attention has been given to the use of platelet rich plasma in cartilage repair techniques. Another advantage of platelet rich plasma is that on clotting; platelets form three-dimensional scaffolds to fill the cartilage defect and act as a guide for neochondrogenesis in situ. Although these issues are not insurmountable, the agents most likely to succeed in this regard are likely to include the polygrowth factor environment provided by platelet rich plasma products.

2.3.2 History and development of PRP

In the 1930s, Schultz demonstrated an injection technique that successfully induced tightening of loose temporomandibular joints; the solution injected was derived from psyllium seed. In the 1950s, Hackett named this technique prolotherapy to imply proliferation of fibrous tissue. In the early 1990s, his work was updated with articles on proposed mechanisms of action and use of prolotherapy (using other injectants, such as

dextrose and morrhuate sodium) in essentially all joints of the body. More recently, prolotherapy has been defined as the injection of growth factors or growth factor production stimulants to facilitate growth and repair of normal cells and tissue. A proliferant is any solution injected with the intent of growth or repair. Growth factors produced or provided with proliferant injection are those that are increased during the repair phase in soft tissue of various types; thus, connective tissue is the target for treatment. Linetsky et al proposed the term regenerative injection therapy to describe treatments with this goal.

Autologous platelet rich plasma was first used in 1987 by Ferrari et al., following open heart surgery in order to avoid excessive transfusion of homologous blood products. Rationale: reversal of the blood ratio through decrease of red blood cell to 5% and increase of platelets to 94% for stimulation of recovery; defined as a volume of the plasma fraction of autologous blood having a platelet concentration above baseline; clinical efficacy with above 1 million platelets/ul.

In the late 1990s, surgeons began adding platelet rich plasma to fibrin glue, forming a gel for placement in surgical sites. The goal was to improve healing, anchoring of implantable materials, and speed of recovery. In the early part of this century, physicians began injection of platelet rich plasma as a proliferant. The first published, nonsurgical report was a case series published in the podiatry field. Since 2005, the Hackett-Hemwall Foundation and the University of Wisconsin have sponsored an annual research forum focused on regenerative injection treatments. The mode of action of these therapies has been a major focus of discussion. Banks (Banks, 1991) has proposed that the common end point of regenerative therapy is formation of new collagen fibers. Growth factor stimulation by lipids released from cell membrane rupture and microbleeding with release of platelets have been proposed as potential mechanisms for such an effect (Reeves et al., 2008). Rabago et al discussed these proposed mechanisms of action in their review of 4 injection therapies, including dextrose/sodium morrhuate, polidocanol, autologous whole blood, and platelet rich plasma injections. They reported that the common goal of these injections is to stimulate a normal tissue repair cascade resulting in organized collagen fibers, not scars. Regenerative biomedicine is receiving progressive attention in medicine. Advancements in the study of these innovative bioactive therapies, such as the use of platelet rich plasma, mesenchymal stem cells, extracorporeal shock wave therapy, sclerosing agents, nitric oxide, and matrix metalloproteinase etc, have taken place during the past 2 decades.

2.3.3 Preparation and safety of PRP

Platelet rich plasma is prepared by centrifuging autologous, anticoagulated whole blood. The range of ideal concentrations is based primarily on opinion, and most publications differ on the platelet rich plasma concentrations cited. Citrate can be used for inhibition of the clotting cascade by binding ionized calcium. Centrifugation separates the following: (1) plasma (top layer) from (2) platelets and white blood cells (buffy coat, middle layer) and (3) red blood cells (bottom layer) (Fig. 3.) as a result of differences in specific gravity.

In order to further concentrate the preparation, a second centrifugation separates the platelet rich plasma from platelet-poor plasma. Of note, the use of 2 spins versus 1 spin is controversial. Although a second spin will certainly concentrate the platelets further, the question of whether this step is necessary remains a subject of discussion. The platelet rich plasma (middle layer) is then drawn off, and addition of calcium chloride or thrombin activates the platelet rich plasma and results in prompt release of 70% of the growth factors

from the granules within 10 minutes (and nearly all of the contents within an hour). The issue of pre-activation is also controversial, and not all clinicians include this step. Presently, a number of different manufacturers have introduced systems for platelet rich plasma preparation, allowing for both intraoperative and outpatient use of platelet rich plasma for a variety of orthopaedic pathologies (Hall et al., 2009). The volume of platelet rich plasma and concentration of platelets yielded from a volume of whole blood can differ based on the preparation system used (Foster et al., 2009; Mishra et al., 2009; Hall et al., 2009). For example, in our clinic, we use the Huons® sPRP system (Huons®, Gyeonggido, Korea) (Fig. 3.). The procedure utilizes a 50 ml venous blood sample, which is drawn using aseptic technique from the antecubital vein. Use of an 18-19 gauge butterfly needle is advised, in an effort to avoid irritation and trauma to platelets. Blood is then placed in a Korean Food and Drug Administration approved device (Huons®, Gyeonggido, Korea), centrifuged for 3 min at 3,200 rpm, and separated into platelet poor plasma, PRP, and RBC. Platelet poor plasma is extracted through a special port and discarded from the device. Afterward, the platelet rich plasma is withdrawn. Approximately 5.5 or 6.0 cc of platelet rich plasma is available.



Fig. 3. Platelet rich plasma preparation. (1) Platelet poor plasma (top layer) (2) platelets and white blood cells (buffy coat, middle layer) and (3) red blood cells (bottom layer). PPP; platelet poor plasma, PRP; platelet rich plasma, RBC; red blood cell. Photo courtesy of Huons® Technologies, sPRP kit.

Platelet rich plasma is prepared from autologous blood; therefore, any concerns regarding immunogenic reactions or disease transfer are eliminated. Growth factors act on cell membranes, rather than on the cell nucleus, and activate normal gene expression. Growth factors are not mutagenic and act naturally through gene regulation and normal wound healing feed-back control mechanisms.

2.3.4 Preclinical studies

In a rabbit model, osteochondral defects were treated with either autogenous platelet rich plasma in a poly-lacticglycolic acid carrier, poly-lacticglycolic acid alone, or left untreated (Sun et al., 2010). The platelet rich plasma group demonstrated a higher extent of cartilage regeneration as well as increased production of glycosaminoglycans in the extracellular matrix.

Osteoarthritis models have also been used in study of the effects of platelet rich plasma on synovial cell biology. Cells from 10 patients were cultured and exposed to either a platelet-poor or platelet-rich solution. Investigators found that the platelet rich solution in growth

factors enhanced hyaluronic acid secretion; therefore, they concluded that intra-articular injections of platelet-released growth factor may be useful in maintenance of joint homeostasis by contributing to hyaluronic acid restoration (Anitua et al., 2007).

In the animal literature, results of several studies have demonstrated evidence of osteogenesis and formation of cartilaginous tissue with platelet rich plasma combined with chondrocytes or a collagen matrix (Qi et al., 2009). Sustained-release platelet rich plasma intra-articular injections also resulted in increased cartilage matrix metabolism (Saito et al., 2009). Although chondrocytes and platelet rich plasma appeared to stimulate chondrogenesis subcutaneously, demineralized bone matrix and platelet rich plasma did not stimulate osteogenesis intramuscularly (Ranly et al., 2007) which prompts further questions about the substrates with which platelet rich plasma may have synergistic effects and the environment in which the composite is placed. Intra-articularly injected sustained-release vehicles for platelet rich plasma appeared to stimulate cartilage matrix metabolism, which suggests potential uses in osteoarthritis management (Saito et al., 2009). In a canine model, a composite was created when platelet rich plasma was combined with bone marrow stromal cells and demineralized bone matrix, and then subsequently wrapped in a muscle flap containing blood vessels. This combination appeared to enhance osteogenesis and vascularization (Li et al., 2009).

In a study of porcine mandibular bone defects, platelet rich plasma combined with bone marrow was found to stimulate osteogenesis (Lopez-Lopez et al., 2009). In another study, platelet rich plasma was combined with bone graft and stimulated osteogenesis in rabbit calvarium defects (Nagata et al., 2009). Chondrogenesis was demonstrated in rabbit knee cartilage defects when platelet rich plasma was used with a scaffold (Sun et al., 2010). Platelet rich plasma alone also has been found to enhance the healing of diabetic fractures in rats (Gandhi et al., 2006).

2.3.5 Clinical studies

Blood-derived growth factors have already been studied for their potential to aid in cartilage repair and have been documented in the literature in both preclinical and clinical studies (Saito et al., 2009; Wu et al., 2007). In particular, Baltzer et al. (Tamoto et al., 1994) conducted an analysis of the effect of autologous conditioned serum in treatment of patients with knee osteoarthritis. In their prospective, randomized patient- and observer-blinded, placebo-controlled trial, they demonstrated that autologous conditioned serum injections induced considerable improvement of the clinical signs and symptoms of osteoarthritis with results that are even superior to those of hyaluronic acid. Recently, there has been increasing interest in the use of another autologous blood product, platelet rich plasma, which might provide cellular and humoral mediators to promote tissue healing in a variety of applications. The rationale is based on the activity of blood growth factors carried in platelets, many of which have been shown to take part in regulation of articular cartilage (Kobayashi et al., 1994). Platelets contain storage pools of growth factors in their α -granules (Larsen et al., 1977), including Platelet-derived growth factor, Transforming Growth Factor- β , Insulin like growth factor-1, fibroblast growth factor, and many others, as well as cytokines and chemokines (Sanzhez et al., 2009). Platelet rich plasma is derived from centrifugation of autologous whole blood and contains a platelet concentration that is 4 to 5 times higher than that of normal blood, thus offering a high concentration of growth factors in physiological proportions. Some research findings have suggested a possible role for

platelet rich plasma in treatment of cartilage lesions (Saito et al., 2009). In an observational retrospective cohort study using hyaluronan injections as a control, Sanchez et al. (Sanchez et al., 2008) showed interesting preliminary results using intra-articular injections of an autologous preparation rich in growth factors for treatment of knee osteoarthritis. These studies suggest that these potent biological regulators of chondrocytes have an important role in cartilage repair. However, for the time being, evidence for clinical use of platelet rich plasma is still in its infancy, particularly regarding treatment of degenerative knee conditions via multiple platelet rich plasma injections. A study was performed to explore this novel approach for treatment of articular cartilage degenerative lesions. The preliminary results indicated that this procedure was safe and had the potential to relieve pain and improve knee function and quality of life in younger patients with a low degree of articular cartilage degeneration.

A number of studies investigating the use of platelet rich plasma and autologous blood have received attention in the popular press. However, there is still a lack of high-quality, prospective research providing definitive assistance to physicians in the appropriate use of these agents (Nguyen et al., 2011). That being said, early use of these agents for conditions that are often resistant to other treatments has been encouraging (Kazemi et al., 2010). In addition, platelet rich plasma and autologous blood have shown less potential for serious side effects, such as tendon rupture and fat necrosis, than corticosteroids. Autologous blood treatment protocols involve injection of a local anesthetic in the affected region and then performance of venipuncture and re-injection of the patient's blood into the abnormal tissue. To date, no randomized controlled trials have been conducted in this area. We found an observational, retrospective clinical study that used hyaluronan as a control. The investigators used serial intra-articular platelet rich plasma injections, with modest outcomes. Another clinical study was prospective and showed more positive results, but did not include a control group. Investigators found promising results in patients of younger ages, patients with a lower body mass index, males, and cases of milder severity (Filardo et al., 2010). Application of platelet rich plasma in cartilage repair is relatively new; therefore, there have been limited publications investigating its use. Chondrocytes and mesenchymal stem cells exposed to platelet rich plasma have shown both increased cell proliferation and cartilage extracellular matrix synthesis of proteoglycans and collagen type II, compared with controls (Akedo et al., 2006). Synoviocytes from patients with osteoarthritis cultured in platelet rich plasma demonstrated increased hyaluronic acid production and secretion, suggesting that platelet rich plasma could potentially serve as an endogenous source of chondroprotection and joint lubrication after intra-articular application (Anitua et al., 2007). In a cohort of 30 patients for comparison of injections of platelet rich plasma with hyaluronic acid in management of osteoarthritis, the success rate for the pain subscale reached 33.4% for the platelet rich plasma group, compared with 10% for the hyaluronic acid group ($p = 0.004$) (Sanchez et al., 2008). In addition, percent reductions in the physical function subscale and overall Westren Ontario and McMaster Universities (Bellamy et al., 1988) at 5 weeks were also associated solely with treatment modality in favor of platelet rich plasma, with $p = 0.043$ and $p = 0.010$, respectively. Kon et al. reported results of a large, prospective case series using intraarticular platelet rich plasma injection in patients with degenerative chondral lesions of the knee, as seen on magnetic resonance image (Kellgren 0, $n = 58$ knees) or clear osteoarthrosis on radiograph (Kellgren I-III, $n = 33$; Kellgre IV, $n = 24$). Injection of 5 mL PRP (via a lateral approach without guidance) was administered every 21 days for a

total of 3 treatments. Calcium chloride was added for activation of platelets. A substantial improvement in International Knee Documentation Committee (Irrgang et al., 2001) and EuroQol-visual analogue scale scores (EuroQol, 2007) was noted at the end of therapy and at both the 6- and 12-month time points. International Knee Documentation Committee subjective scores as well as the EuroQol-visual analogue scale score also demonstrated major improvements at the end of therapy. The authors concluded that treatment with platelet rich plasma is safe and effective for improvement of pain, function, and quality of life in patients with degenerative articular pathology. No follow-up imaging was reported. The initial hypothesis was that the use of platelet rich plasma might stimulate chondral anabolism and produce a reduction in catabolic processes, thus leading to chondroprotective and chondroregenerative actions, and, therefore, symptomatic improvement. However, the clinical nature of this study makes it difficult to assess the disease-modifying properties of this approach. Moreover, despite the initial considerable improvement in clinical signs and symptoms of knee cartilage degeneration, the marked worsening observed at the 24-month follow-up indicates that improvement due to platelet rich plasma injections is mostly symptomatic, at least with this procedure. Platelet rich plasma probably influences overall joint homeostasis, also through reduction of synovial membrane hyperplasia and modulation of the cytokine level, thus leading to the observed improvement in the clinical outcome, albeit only temporarily, and maybe without affecting cartilage tissue structure or progression of joint degeneration (Saito et al., 2009). Further studies will determine whether or not other application modalities, with different platelet/growth factor concentrations and injection times, may allow for achievement of better and more durable results.

Treatment is most effective in younger male patients, with lower body mass index and lower degrees of chondral degeneration. The interesting results obtained regarding the safety, feasibility, and short-term efficacy of this treatment suggest that it may represent a minimally invasive and safe procedure that may be cyclically repeated in order to improve knee function and quality of life.

Despite early optimism and the positive safety profile of platelet rich plasma and autologous blood, most insurance companies are reluctant to cover the use of these agents due to a lack of high-quality randomized, double-blinded studies.

3. Conclusion

When treating a patient with osteoarthritis, it is best to start with non-interventional approaches, such as physiotherapy, ice, and analgesics. If conservative treatment fails, injectable agents may help. Corticosteroid injections are effective in reducing pain associated with osteoarthritis and in treatment of conditions in which inflammation is present. When corticosteroid treatment is not effective for osteoarthritis, intra-articular injections with hyaluronic acid are another option. Hyaluronic acid injections provide longer-lasting pain relief than corticosteroids for patients with osteoarthritis; however, they are much more expensive. Growth hormone has not yet received Food and Drug Administration approval for injection in joints, which is an "off-label" use. There is interest in the use of growth hormone as a potential osteoarthritis disease-modifying treatment; however, studies of its effects in humans are lacking. Platelet-rich plasma and/or autologous blood injections are safer and may be more effective than corticosteroids for treatment of osteoarthritis.

However, physicians need to understand that high-quality prospective evidence as to the appropriate use of some of these treatments for certain conditions is lacking. Considering the limited data, no clear definition of a standardized platelet rich plasma treatment protocol has been established to date. Further research is needed.

4. Acknowledgment

This book chapter is dedicated to my family; my wife, Mi Sung Kim, my daughter, Hyun Jo Kwon, and my son, Eun Sang Kwon for their love, support and patience through this special effort.

5. References

- Wearing SC, Henning EM, Byrne NM, Steele JR, & Hills AP. (2006). Musculoskeletal disorders associated with obesity: a biomechanical perspective. *Obes Rev.*, 7(3), 239-250, 1467-7881
- Chevalier X. Physiopathogenesis of osteoarthritis. (1998). The arthritis cartilage. *Presse Med.*, 27(2), 81-87, 0755-4982
- Topol EJ. (2004). Failing the public health-rofecoxib, Merck, and the FDA. *N. Engl. J. Med.*, 351(17), 1707-1709, 0028-4793
- Petit-Zeman S. (2004). Characteristics of COX2 inhibitors questioned. *Nat Rev Drug Discov.*, 3(9), 726-727, 1474-1776
- Gerwin N, Hops C, Lucke A. (2006). Intraarticular drug delivery in osteoarthritis. *Adv Drug Deliv Rev.*, 58(2), 226-242, 0169-409X
- Brandt KD, Smith GN Jr, Simon LS. (2000). Intra-articular injection of hyaluronan as treatment for knee osteoarthritis: what is the evidence? *Arthritis Rheum.*, 43(6), 1192-1203, 0004-3591
- Betre H, Liu W, Zalutsky MR, Chilkoti A, Kraus VB, Setton LA. (2006). A thermally responsive biopolymer for intra-articular drug delivery. *J Control Release.*, 115(2), 175-182, 0168-3659
- Saito M, Takahashi KA, Arai Y, Inoue A, Sakao K, Tonomura H, Honjo K, Nakagawa S, Inoue H, Tabata Y, Kubo T. (2009). Intraarticular administration of platelet-rich plasma with biodegradable gelatin hydrogel microspheres prevents osteoarthritis progression in the rabbit knee. *Clin Exp Rheumatol.*, 27(2), 201-207, 0392-856X
- Chen AL, Desai P, Adler EM, Di Cesare PE. (2002). Granulomatous inflammation after Hylan G-F 20 viscosupplementation of the knee : a report of six cases. *J Bone Joint Surg Am.*, 84(7), 1142-1147, 0021-9355
- Jackson DW, Evans NA, Thomas BM. (2002). Accuracy of needle placement into the intra-articular space of the knee. *J Bone Joint Surg Am.*, 84(9), 1522-1527, 0021-9355
- Neustadt DH. (2006). Intra-articular injections for osteoarthritis of the knee. *Cleve Clin J Med.*, 73(10), 897-898, 901-904, 906-911, 0891-1150
- Chavez-Chiang CE, Sibbitt WL Jr, Band PA, Chavez-Chiang NR, Delea SL, Bankhurst AD. (2011). The highly accurate anteriolateral portal for injecting the knee. *Sports Med Arthrosc Rehabil Ther Technol.*, 3(1), 6, 1758-2555

- Jones A, Doherty M. (2003). *Osteoarthritis (2nd edition)*, Oxford University Press, 0198509677, New York
- Ayral X. (2001). Injections in the treatment of osteoarthritis. *Best Pract Res Clin Rheumatol.*, 15(4), 609-626, 1521-6942
- Neustadt DH. (2001). *Osteoarthritis: Diagnosis and Medical/Surgical Management (3rd edition)*, W.B. Saunders Company, 0721684394, Philadelphia
- Balazs EA, Denlinger JL. (1993). Viscosupplementation: a new concept in the treatment of osteoarthritis. *J Rheumatol Suppl.*, 39: 3-9, 0380-0903
- Simon LS. (1999). Viscosupplementation therapy with intra-articular hyaluronic acid. Fact or fantasy?. *Rheum Dis Clin North Am.*, 25(2), 345-358, 0889-857X
- Marshall KW. (2000). Intra-articular hyaluronan therapy. *Curr Opin Rheumatol.*, 12(5), 468-474, 1040-8711
- Ghosh P. (1994). The role of hyaluronic acid in health and disease: interactions with cells, cartilage, and components of synovial fluid. *Clin Exper Rheum.*, 12(1), 75-82, 0392-856X
- Vad VB, Bhat AL, Sculco TP, Wickiewicz TL. (2003). Management of knee osteoarthritis: knee lavage combined with hylan versus hylan alone. *Arch Phys Med Rehabil.*, 84(5), 634-637, 0003-9993
- Raynauld JP, Goldsmith CH, Bellamy N, Torrance GW, Polisson R, Belovich D, Pericak D, Tugwell P. (2005). Effectiveness and safety of repeat courses of hylan G-F 20 in patients with knee osteoarthritis. *Osteoarthritis Cartilage*, 13(2), 111-119, 1063-4584
- Hammesfahr JF, Knopf AB, Stitik T. (2003). Safety of intra-articular hyaluronates for pain associated with osteoarthritis of the knee. *Am J orthop.*, 32(6), 277-283, 1078-4519
- Leopold SS, Warme WJ, Pettis PD, Shott S. (2002). Increased frequency of acute local reaction to intra-articular hylan GF-20 (synvisc) in patients receiving more than one course of treatment. *J Bone Joint Surg Am.*, 84(9), 1619-1623, 0021-9355
- Marino AA, Waddell DD, Kolomytkin OV, Pruett S, Sadasivan KK, Albright JA. (2006). Assessment of immunologic mechanisms for flare reactions to Synvisc. *Clin Orthop Relat Res.*, 442, 187-194, 0009-921X
- Brockmeier SF, Shaffer BS. (2006). Viscosupplementation therapy for osteoarthritis. *Sports Med Arthrosc.*, 14(3), 155-162, 1062-8592
- Moreland LW. (2003). Intra-articular hyaluronan (hyaluronic acid) and hylans for the treatment of osteoarthritis: mechanisms of action. *Arthritis Res. Ther.*, 5(2), 54-67, 1478-6354
- Vuorio E, Einola S, Hakkarainen S, Penttinen R. (1982). Synthesis of underpolymerized hyaluronic acid by fibroblasts cultured from rheumatoid and non-rheumatoid synovitis. *Rheumatol Int.*, 2(3), 97-102, 0172-8172
- Kikuchi T, Yamada H, Shimmei M. (1996). Effect of high molecular weight hyaluronan on cartilage degradation in a rabbit model of osteoarthritis. *Osteoarthritis Cartilage*, 4(2), 99-110, 1063-4584
- Armstrong S, Read R, Ghosh P. (1994). The effects of intraarticular hyaluronan on cartilage and subchondral bone changes in an ovine model of early osteoarthritis. *J Rheumatol.*, 21(4), 680-688, 0315-162X

- Sonoda M, Harwood FL, Wada Y, Moriya H, Amiel D. (1997). The effects of hyaluronan on the meniscus and on the articular cartilage after partial meniscectomy. *Am J Sports Med.*, 25(6), 755-762, 0363-5465
- Sonoda M, Harwood FL, Amiel ME, Moriya H, Temple M, Chang DG, et al. (2000). The effects of hyaluronan on tissue healing after meniscus injury and repair in a rabbit model. *Am J Sports Med.*, 28(1), 90-97, 0363-5465
- Wiig ME, Amiel D, VandeBerg J, Kitabayashi L, Harwood FL, Arfors KE. (1990). The early effect of high molecular weight hyaluronan (hyaluronic acid) on anterior cruciate ligament healing: an experimental study in rabbits. *J Orthop Res.*, 8(3), 425-434, 0736-0266
- Takahashi K, Hashimoto S, Kubo T, Hirasawa Y, Lotz M, Amiel D. (2000). Effect of hyaluronan on chondrocyte apoptosis and nitric oxide production in experimentally induced osteoarthritis. *J Rheumatol.*, 27(7), 1713-1720, 0315-162X
- Schiavinato A, Lini E, Guidolin D, Pezzoli G, Botti P, Martelli M, et al. (1989). Intraarticular sodium hyaluronate injections the Pond-Nuki experimental model of osteoarthritis in dogs. II. Morphological findings. *Clin Orthop.*, 241, 286-299, 0009-921X
- Wenz W, Breusch SJ, Graf J, Stratmann U. (2000). Ultrastructural findings after intraarticular application of hyaluronan in a canine model of arthropathy. *J Orthop Res.*, 18(4), 604-612, 0736-0266
- Yoshioka M, Shimizu C, Harwood FL, Coutts RD, Amiel D. (1997). The effects of hyaluronan during the development of osteoarthritis. *Osteoarthritis Cartilage*, 5(4), 251-260, 1063-4584
- Shimizu C, Yoshioka M, Coutts RD, Harwood FL, Kubo T, Hirasawa Y, et al. (1998). Long-term effects of hyaluronan on experimental osteoarthritis in the rabbit knee. *Osteoarthritis Cartilage*, 6(1), 1-9, 1063-4584
- Marshall KW, Manolopoulos V, Mancer K, Staples J, Damyanovich A. (2000). Amelioration of disease severity by intraarticular hylan therapy in bilateral canine osteoarthritis. *J Orthop Res.*, 18(3), 416-425, 0736-0266
- Amiel D, Toyoguchi T, Kobayashi K, Bowden K, Amiel ME, Healey RM. (2003). Long-term effect of sodium hyaluronate (Hyalgan) on osteoarthritis progression in a rabbit model. *Osteoarthritis Cartilage*, 11(9), 636-643, 1063-4584
- Dixon AS, Jacoby RK, Berry H, Hamilton EB. (1988). Clinical trial of intra-articular injection of sodium hyaluronate in patients with osteoarthritis of the knee. *Curr Med Res Opin.*, 11(4), 205-213, 0300-7995
- Dougados M, Nguyen M, Listrat V, Amor B. (1993). High molecular weight sodium hyaluronate (hyalectin) in osteoarthritis of the knee: a 1 year placebo-controlled trial. *Osteoarthritis Cartilage*, 1(2), 97-103, 1063-4584
- Henderson EB, Smith EC, Pegley F, Blake DR. (1994). Intra-articular injections of 750 kD hyaluronan in the treatment of osteoarthritis: a randomized single centre double-blind placebo-controlled trial of 91 patients demonstrating lack of efficacy. *Ann Rheum Dis.*, 53(8), 529-534, 0003-4967
- Dahlberg L, Lohmander S, Ryd L. (1994). Intraarticular injections of hyaluronan in patients with cartilage abnormalities and knee pain: a one-year double-blind, placebo-controlled study. *Arthritis Rheum.*, 37(4), 521-528, 0004-3591

- Bellamy N, Campbell J, Robinson V, Gee T, Bourne R, Wells G. (2006). Viscosupplementation for the treatment of osteoarthritis of the knee. *Cochrane Database syst Rev.*, 19(2), CD005321, 1469-493X
- Adams ME, Atkinson MH, Lussier AJ, Schulz JL, Siminovitch KA, Wade JP, Zummer M. (1995). The role of viscosupplementation with hylan G-F 20 in the treatment of osteoarthritis of the knee: a Canadian multicenter trial comparing hylan G-F 20 alone, hylan G-F 20 with non-steroidal anti-inflammatory drugs (NSAIDs) and NSAIDs alone. *Osteoarthritis Cartilage*, 3(4), 213-225, 1063-4584
- Altman RD, Moskowitz R. (1998). Intraarticular sodium hyaluronate in the treatment of patients with osteoarthritis of the knee: a randomized clinical trial. *J Rheum.*, 25(11), 2203-2212, 0315-162X
- Jones AC, Patrick M, Doherty S, Doherty M. (1995). Intra-articular hyaluronic acid compared to intra-articular triamcinolone hexacetonide in inflammatory knee osteoarthritis. *Osteoarthritis Cartilage*, 3(4), 269-273, 1063-4584
- Leopold SS, Redd BB, Warme WJ, Wehrle PA, Pettis PD, Shott S. (2003). Corticosteroid compared with hyaluronic acid injections for the treatment of osteoarthritis of the knee: a prospective, randomized trial. *J Bone Joint Surg Am.*, 85(7), 1197-1203, 0021-9355
- Caborn D, Rush J, Lanzer W, Parenti D, Murray C. (2004). A randomized, single-blind comparison of the efficacy and tolerability of hylan G-F 20 and triamcinolone hexacetonide in patients with osteoarthritis of the knee. *J Rheum.*, 31(2), 333-343, 0315-162X
- Altman R, Brandt K, Hochberg M, Moskowitz R. (1996). Design and conduct of clinical trials in patients with osteoarthritis: recommendations from a task force of the Osteoarthritis Research Society. *Osteoarthritis Cartilage*, 4(4), 217-243, 1063-4584
- Goldring MB, Tsuchimochi K, Ijiri K. (2006). The control of chondrogenesis. *J Cell Biochem.*, 97(1), 33-44, 0730-2312
- Blaney Davidson EN, van der Kraan PM, van den Berg WB. (2007). TGF-beta and osteoarthritis. *Osteoarthritis Cartilage*, 15(6), 597-604, 1063-4584
- Fan J, Gong Y, Ren L, Varshney RR, Cai D, Wang DA. (2010). In vitro engineered cartilage using synovium-derived mesenchymal stem cells with injectable gellan hydrogels. *Acta Biomater.*, 6(3), 1178-1185, 1742-7061
- Kurth T, Hedbom E, Shintani N, Sugimoto M, Chen FH, Haspl M, Martinovic S, Hunziker EB. (2007). Chondrogenic potential of human synovial mesenchymal stem cells in alginate. *Osteoarthritis Cartilage*, 15(10), 1178-1189, 1063-4584
- Bakker AC, van de Loo FA, van Beuningen HM, Sime P, van Lent PL, van der Kraan PM, Richards CD, van den Berg WB. (2001). Overexpression of active TGF-beta-1 in the murine knee joint: evidence for synovial-layer-dependent chondro-osteophyte formation. *Osteoarthritis Cartilage*, 9(2), 128-136, 1063-4584
- Diao H, Wang J, Shen C, Xia S, Guo T, Dong L, Zhang C, Chen J, Zhao J, Zhang J. (2009). Improved cartilage regeneration utilizing mesenchymal stem cells in TGF-beta1 gene-activated scaffolds. *Tissue Eng Part A.*, 15(9), 2687-2698, 1937-3341
- Coutts RD, Sah RL, Amiel D. (1997). Effects of growth factors on cartilage repair. *Instr Course Lect.*, 46, 487-494, 0065-6895

- Hickey DG, Frenkel SR, Di Cesare PE. (2003). Clinical applications of growth factors for articular cartilage repair. *AmJ Orthop.*, 32(2), 70-76, 1078-4519
- Ashton IK, Matheson JA. (1979). Change in response with age of human articular cartilage to plasma somatomedin activity. *Calcif Tiss Int.*, 29(2), 89-94, 0171-967X
- Boehm AK, Seth M, Mayr KG, Fortier LA. (2007). Hsp90 mediates insulin-like growth factor 1 and interleukin-1beta signaling in an age-dependent manner in equine articular chondrocytes. *Arthritis Rheum.*, 56(7), 2335-2343, 0004-3591
- Denko CW, Boja B, Moskowitz RW. (1994). Growth promoting peptides in osteoarthritis and diffuse idiopathic skeletal hyperostosis—insulin, insulin-like growth factor-I, growth hormone. *J Rheumatol.*, 21(9), 1725-1730, 0315-162X
- Dore S, Pelletier J, DiBattista JA, Tardif G, Brazeau P, Martel-Pelletier J. (1994). Human osteoarthritic chondrocytes possess an increased number of insulin-like growth factor 1 binding sites but are unresponsive to its stimulation: possible role of IGF-1 binding proteins. *Arthritis Rheum.*, 37(2), 253-263, 0004-3591
- Ekenstedt KJ, Sonntag WE, Loeser RF, Lindgren BR, Carlson CS. (2006). Effects of chronic growth hormone and insulin-like growth factor 1 deficiency on osteoarthritis severity in rat knee joints. *Arthritis Rheum.*, 54(12), 3850-3858, 0004-3591
- Fortier LA, Miller BJ. (2006). Signaling through the small G-protein Cdc42 is involved in insulin-like growth factor-I resistance in aging articular chondrocytes. *J Orthop Res.*, 24(8), 1765-1772, 0736-0266
- Fortier LA, Mohammed HO, Lust G, Nixon AJ. (2002). Insulin-like growth factor-I enhances cell-based repair of articular cartilage. *J Bone Joint Surg Br.*, 84(2), 276-288, 0301-620X
- Goodrich LR, Hidaka C, Robbins PD, Evans CH, Nixon AJ. (2007). Genetic modification of chondrocytes with insulin-like growth factor-1 enhances cartilage healing in an equine model. *J Bone Joint Surg Br.*, 89(5), 672-685, 0301-620X
- Loeser RF, Carlson CS, Del Carlo M, Cole A. (2002). Detection of nitrotyrosine in aging and osteoarthritic cartilage: correlation of oxidative damage with the presence of interleukin-1beta and with chondrocyte resistance to insulin-like growth factor 1. *Arthritis Rheum.*, 46(9), 2349-2357, 0004-3591
- Longobardi L, O'Rear L, Aakula S, Johnstone B, Shimer K, Chytil A, Horton WA, Moses HL, Spagnoli A. (2006). Effect of IGF-I in the chondrogenesis of bone marrow mesenchymal stem cells in the presence or absence of TGF-beta signaling. *J Bone Miner Res.*, 21(4), 626-636, 0884-0431
- Maehara H, Sotome S, Yoshii T, Torigoe I, Kawasaki Y, Sugata Y, Yuasa M, Hirano M, Mochizuki N, Kikuchi M, Shinomiya K, Okawa A. (2010). Repair of large osteochondral defects in rabbits using porous hydroxyapatite/collagen (HAp/Col) and fibroblast growth factor-2 (FGF-2). *J Orthop Res.*, 28(5), 677-686, 0736-0266
- Martin JS, Ellerbrock SM, Buckwalter JA. (1997). Age-related decline in chondrocyte response to insulin-like growth factor-I: the role of growth factor binding proteins. *J Orthop Res.*, 15(4), 491-498, 0736-0266
- McQuillan DJ, Handley CJ, Campbell MA, Bolis S, Milway VE, Herington AC. (1986). Stimulation of proteoglycan biosynthesis by serum and insulin-like growth factor-1 in cultured bovine articular cartilage. *Biochem J.*, 240(2), 423-430, 0264-6021

- Middleton J, Manthey A, Tyler J. (1996). Insulin-like growth factor (IGF) receptor, IGF-I, interleukin-1b (IL-1b), and IL-6 mRNA expression in osteoarthritic and normal human cartilage. *J Histochem Cytochem.*, 44(2), 133-141, 0022-1554
- Morales TI. (2008). The quantitative and functional relation between insulin-like growth factor-I (IGF) and IGF-binding proteins during human osteoarthritis. *J Orthop Res.*, 26(4), 465-474, 0736-0266
- Posever J, Phillips FM, Pottenger LA. (1995). Effects of basic fibroblast growth factor, transforming growth factor-B1, insulin-like growth factor-1, and insulin on human osteoarthritic articular cartilage explants. *J Orthop Res.*, 13(6), 832-837, 0736-0266
- Sah RL, Chen AC, Grodzinsky AJ, Trippel SB. (1994). Differential effects of bFGF and IGF-I on matrix metabolism in calf and adult bovine cartilage explants. *Archives Biochem Biophys.*, 308(1), 137-147, 0003-9861
- Schalkwijk J, Joosten LAB, van den Berg WB, van de Putte LBA. (1989). Chondrocyte nonresponsiveness to insulin-like growth factor 1 in experimental arthritis. *Arthritis Rheum.*, 32(7), 894-900, 0004-3591
- Tyler JA. (1989). Insulin-like growth factor 1 can decrease degradation and promote synthesis of proteoglycan in cartilage exposed to cytokines. *Biochem J.*, 260(2), 543-548, 0264-6021
- Wang E, Wang J, Chin E, Zhou J, Bondy CA. (1995). Cellular patterns of insulin-like growth factor system gene expression in murine chondrogenesis and osteogenesis. *Endocrinology.*, 136(6), 2741-2751, 0013-7227
- Worster AA, Brower-Toland BD, Fortier LA, Bent SJ, Williams J, Nixon AJ. (2001). Chondrocytic differentiation of mesenchymal stem cells sequentially exposed to transforming growth factor-beta1 in monolayer and insulin-like growth factor-I in a three-dimensional matrix. *J Orthop Res.*, 19(4), 738-749, 0736-0266
- Martin JA, Ellerbroek SM, Buckwalter JA. (1997). Age-related decline in chondrocyte response to insulin-like growth factor-I: the role of growth factor binding proteins. *J Orthop Res.*, 15(4), 491-498, 0736-0266
- Verschure PJ, Van Noorden CJ, Van Marle J, Van den Berg WB. (1996). Articular cartilage destruction in experimental inflammatory arthritis: insulin-like growth factor-1 regulation of proteoglycan metabolism in chondrocytes. *Histochem J.*, 28(12), 835-857, 0018-2214
- Trippel SB. (1995). Growth factor actions on articular cartilage. *J Rheumatol Suppl.*, 43, 129-132, 0380-0903
- van den Berg WB, van der Kraan PM, Scharstuhl A, van Beuningen HM. (2001). Growth factors and cartilage repair. *Clin Orthop.*, 391, S244-250, 0009-921X
- Hickey DG, Frenkel SR, Di Cesare PE. (2003). Clinical applications of growth factors for articular cartilage repair. *Am J Orthop.*, 32(2), 70-76, 1078-4519
- Lee SJ. (2000). Cytokine delivery and tissue engineering. *Yonsei Med J.*, 41(6), 704-719, 0513-5796
- Spindler KP, Mayes CE, Miller RR, Imro AK, Davidson JM. (1995). Regional mitogenic response of the meniscus to platelet-derived growth factor (PDGF-AB). *J Orthop Res.*, 13(2), 201-207, 0736-0266

- Smith RJ, Justen JM, Sam LM, Rohloff NA, Ruppel PL, Brunden MN, Chin JE. (1991). Platelet-derived growth factor potentiates cellular responses of articular chondrocytes to interleukin-1. *Arthritis Rheum.*, 34(6), 697-706, 0004-3591
- Steadman JR, Rodkey WG, Rodrigo JJ. (2001). Microfracture: surgical technique and rehabilitation to treat chondral defects. *Clin Orthop.*, 391, S362-369, 0009-921X
- Breinan HA, Martin SD, Hsu HP, Spector M. (2000). Healing of canine articular cartilage defects treated with microfracture, a type-II collagen matrix, or cultured autologous chondrocytes. *J Orthop Res.*, 18(5), 781-789, 0736-0266
- Dorotka R, Windberger U, Macfelda K, Bindreiter U, Toma C, Nehrer S. (2005). Repair of articular cartilage defects treated by microfracture and a three-dimensional collagen matrix. *Biomaterials.*, 26(17), 3617-3629, 0142-9612
- Schmidt MB, Chen EH, Lynch SE. (2006). A review of the effects of insulin-like growth factor and platelet derived growth factor on in vivo cartilage healing and repair. *Osteoarthritis Cartilage.*, 14(5), 403-412, 1063-4584
- Hulth A, Johnell O, Miyazono K, Lindberg L, Heinegard D, Heldin C-H. (1996). Effect of transforming growth factor-B and platelet-derived growth factor-BB on articular cartilage in rats. *J Orthop Res.*, 14(4), 547-553, 0736-0266
- Nemirovskiy O, Zheng YJ, Tung D, Korniski B, Settle S, Skepner A, Yates M, Aggarwal P, Sunyer T, Aguiar DJ. (2010). Pharmacokinetic/pharmacodynamic (PK/PD) differentiation of native and PEGylated recombinant human growth hormone (rhGH and PEG-rhGH) in the rat model of osteoarthritis. *Xenobiotica.*, 40(8), 586-592, 0049-8254
- Lis K. (2008). Insulin-like growth factor 1 (IGF-1) and growth hormone (hGH) as the markers of osteoarthritis. *Chir Narzadow Ruchu Ortop Pol.*, 73(1), 49-52, 0009-479X
- Gaissmaier C, Koh JL, Weise K. (2008). Growth and differentiation factors for cartilage healing and repair. *Int. J. Care Injured.*, 39, S88-S96, 0020-1383
- Adams ME, Atkinson MH, Lussier AJ, Schulz JI, Siminovitch KA, Wade JP, Zumner M. (1995). The role of viscosupplementation with hylan G-F 20 (Synvisc) in the treatment of osteoarthritis of the knee: a Canadian multicenter trial comparing hylan G-F 20 alone, hylan G-F 20 with non-steroidal anti-inflammatory drugs (NSAIDs) and NSAIDs alone. *Osteoarthritis Cartilage.*, 3(4), 213-225, 1063-4584
- Bak B, Jørgensen PH, Andreassen TT. (1990). Increased mechanical strength of healing rat tibial fractures treated with biosynthetic human growth hormone. *Bone.*, 11(4), 233-239, 8756-3282
- Kolbeck S, Bail H, Schmidmaier G, Alquiza M, Raun K, Kappelgard A, Flyvbjerg A, Haas N, Raschke M. (2003). Homologous growth hormone accelerates bone healing-a biomechanical and histological study. *Bone.*, 33(4), 628-637, 8756-3282
- Carpenter JE, Hipp JA, Gerhart TN, Rudman CG, Hayes WC, Trippel SB. (1992). Failure of growth hormone to alter the biomechanics of fracture-healing in a rabbit model. *J Bone Joint Surg Am.*, 74(3), 359-367, 0021-9355
- Dunn AR. (2002). Morphoangiogenesis: a unique action of growth hormone. *Microvasc Res.*, 63(3), 295-303, 0026-2862
- Goldspink DF, Goldberg AL. (1975). Influence of pituitary growth hormone on DNA synthesis in rat tissues. *Am J Physiol.*, 228(1), 302-309, 0002-9513

- Laursen T, Jørgensen JO, Jakobsen G, Hansen BL, Christiansen JS. (1995). Continuous infusion versus daily injections of growth hormone (GH) for 4 weeks in GH-deficient patients. *J Clin Endocrinol Metab.*, 80(8), 2410-2418, 0021-972X
- Fu K, Pack DW, Klibanov AM, Langer R. (2000). Visual evidence of acidic environment within degrading poly (lactic-co-glycolic acid) (PLGA) microspheres. *Pharm Res.*, 17(1), 100-106, 0724-8741
- Anitua E, Sánchez M, Nurden AT, Nurden P, Orive G, Andía I. (2006). New insights into and novel applications for platelet-rich fibrin therapies. *Trends Biotechnol.*, 24(5), 227-234, 0167-7799
- Samposon S, Gerhardt M, Mandelaum B. (2008). Platelet rich plasma injection grafts for musculoskeletal injuries: A review. *Curr Rew Musculoskeletal Med.*, 1(3-4), 165-174, 1935-973X
- Saito M, Takahashi KA, Arai Y, Inoue A, Sakao K, Tonomura H, Honjo K, Nakagawa S, Inoue H, Tabata Y, Kubo T. (2009). Intraarticular administration of platelet-rich plasma with biodegradable gelatin hydrogel microspheres prevents osteoarthritis progression in the rabbit knee. *Clin Exp Rheumatol.*, 27(2), 201-207, 0392-856X
- Wu W, Chen F, Liu Y, Ma Q, Mao T. (2007). Autologous injectable tissue-engineered cartilage by using platelet-rich plasma: experimental study in a rabbit model. *J oral Maxillofac Surg.*, 65(10), 1951-1957, 0278-2391
- Tamoto K, Nochi H, Tada M, Shimada S, Mori Y, Kataoka S, Suzuki Y, Nakamura T. (1994). High-molecular weight hyaluronic acids inhibit chemotaxis and phagocytosis but not lysosomal enzyme release induced by receptor-mediated stimulations in guinea pig phagocytes. *Microbiol Immunol.*, 38(1), 73-80, 0385-5600
- Kobayashi Y, Okamoto A, Nishinari K. (1994). Viscoelasticity of hyaluronic acid with different molecular weights. *Biorheology.*, 31(3), 235-244, 0006-355X
- Larsen A, Dale K, Eek M. (1977). Radiographic evaluation of rheumatoid arthritis and related conditions by standard reference films. *Acta Radiol Diagnosis.*, 18(4), 481-491, 0567-8056
- Nguyen RT, Borg-Stein J, McInnis K. (2011). Applications of platelet-rich plasma in musculoskeletal and sports medicine: an evidence-based approach. *PM R.*, 3(3), 226-250, 1934-1482
- Kazemi M, Azma K, Tavana B, Reziee Moghaddam F, Panahi A. (2010). Autologous blood versus corticosteroid local injection in the short-term treatment of lateral elbow tendinopathy: a randomized clinical trial of efficacy. *Am J Phys Rehabil.*, 89(8), 660-667, 0894-9115
- Wobig M, Dickhut A, Maier R, Vetter G. (1998). Viscosupplementation with hylan G-F 20: a 26-week controlled trial of efficacy and safety in the osteoarthritic knee. *Clin Ther.*, 20(3), 410-423, 0149-2918
- Puhl W, Bernau A, Greiling H, Köpcke W, Pfürringer W, Steck KJ, Zacher J, Scharf HP. (1993). Intra-articular sodium hyaluronate in osteoarthritis of the knee: a multicenter, double-blind study. *Osteoarthritis Cartilage.*, 1(4), 233-241, 1063-4584
- Lohmander LS, Dalén N, Englund G, Hämmäläinen M, Jensen EM, Karlsson K, Odensten M, Ryd L, Sernbo I, Suomalainen O, Tegnander A. (1996). Intra-articular hyaluronan injections in the treatment of osteoarthritis of the knee: a randomised, double blind,

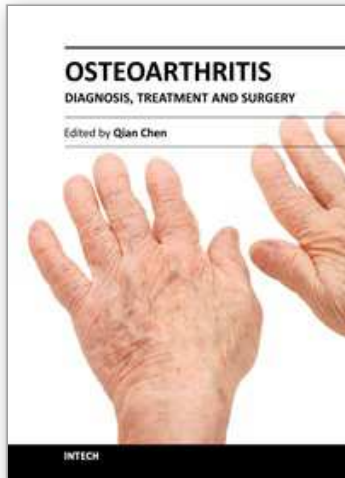
- placebo controlled multicentre trial. Hyaluronan Multicentre Trial Group. *Ann Rheum Dis.*, 55(7), 424-431, 0003-4967
- Jubb RW, Piva S, Beinat L, Dacre J, Gishen P. (2003). A one-year, randomised, placebo (saline) controlled clinical trial of 500-730 kDa sodium hyaluronate (Hyalgan) on the radiological change in osteoarthritis of the knee. *Int J Clin Pract.*, 57(6), 467-474, 1368-5031
- Giusti I, Rughetti A, D'Ascenzo S, Millimaggi D, Pavan A, Dell'Orso L, Dolo V. (2009). Identification of an optimal concentration of platelet gel for promoting angiogenesis in human endothelial cells. *Transfusion.*, 49(4), 771-778, 0041-1132
- Dohan Ehrenfest DM, Rasmusson L, Albrektsson T. (2009). Classification of platelet concentrates: from pure platelet-rich plasma (P-PRP) to leucocyte- and platelet-rich fibrin (L-PRF). *Trends Biotechnol.*, 27(3), 158-167, 0167-7799
- Qureshi AH, Chaoji V, Maignel D, Faridi MH, Barth CJ, Salem SM, Singhal M, Stoub D, Krastins B, Ogihara M, Zaki MJ, Gupta V. (2009). Proteomic and phosphoproteomic profile of human platelets in basal, resting state: insights into integrin signaling. *PLoS One.*, 4(10), e7627, 1932-6203
- Banks A. A rationale for prolotherapy. *J Orthop Med.* 1991; 13: 54-59.
- Reeves D, Fullerton B, Topol G. (2008). The sports medicine resource manual. 1st edition. Saunders Elsevier, 1-4160-3197-9, Philadelphia
- Foster TE, Puskas BL, Mandelbaum BR, Gerhardt MB, Rodeo SA. (2009). Platelet-rich plasma: from basic science to clinical applications. *Am J Sports Med.*, 37(11), 2259-2272, 0363-5465
- Mishra A, Woodall J Jr, Vieira A. (2009). Treatment of tendon and muscle using platelet-rich plasma. *Clin Sports Med.*, 28(1), 113-125, 0278-5919
- Hall MP, Band PA, Meislin RJ, Jazrawi LM, Cardone DA. (2009). Platelet-rich plasma: current concepts and application in sports medicine. *J Am Acad Orthop Surg.*, 17(10), 602-608, 1067-151X
- McQuillan DJ, Handley CJ, Campbell MA, Bolis S, Milway VE, Herington A. (1986). Stimulation of proteoglycan biosynthesis by serum and insulin-like growth factor-I in cultured bovine articular cartilage. *Biochem J.*, 240(2), 423e30, 0264-6021
- Mankin HJ, Mow VC, Buckwalter JA. (2000). Orthopaedic Basic Science. American Academy of Orthopaedic Surgeons, 0892031778 9780892031771 089203176X 9780892031764, Chicago
- Shi S, Mercer S, Eckert GJ, Trippel SB. (2009). Growth factor regulation of growth factors in articular chondrocytes. *J Biol Chem.*, 284(11), 6697-6704, 0021-9258
- Sun Y, Feng Y, Zhang CQ, Chen SB, Cheng XG. (2010). The regenerative effect of platelet-rich plasma on healing in large osteochondral defects. *Int Orthop.*, 34(4), 589-597, 0341-2695
- López-López J, Chimenos-Küstner E, Manzanares-Cespedes C, Muñoz-Sánchez J, Castañeda-Vega P, Jané-Salas E, Alvarez-López JM, Gimeno-Sanding A. (2009). Histomorphological study of the bone regeneration capacity of platelet-rich plasma, bone marrow and tricalcium phosphate: Experimental study on pigs. *Med Oral Patol Oral Cir Bucal.*, 14(12), e620-627, 1698-4447

- Qi YY, Chen X, Jiang YZ, Cai HX, Wang LL, Song XH, Zou XH, Ouyang HW. (2009). Local delivery of autologous platelet in collagen matrix simulated in situ articular cartilage repair. *Cell Transplant.*, 18(10), 1161-1169, 0963-6897
- Ranly DM, Lohmann CH, Andreacchio D, Boyan BD, Schwartz Z. (2007). Platelet-rich plasma inhibits demineralized bone matrix-induced bone formation in nude mice. *J Bone Joint Surg Am.*, 89(1), 139-147, 0021-9355
- Li NY, Yuan RT, Chen T, Chen LQ, Jin XM. (2009). Effect of platelet-rich plasma and latissimus dorsi muscle flap on osteogenesis and vascularization of tissue-engineered bone in dogs. *J Oral Maxillofac Surg.*, 67(9), 1850-1858, 0278-2391
- Nagata MJ, Melo LG, Messori MR, Bomfim SR, Fucini SE, Garcia VG, Bosco AF, Okamoto T. (2009). Effect of platelet-rich plasma on bone healing of autogenous bone grafts in critical-size defects. *J Clin Periodontol.*, 36(9), 775-783, 0303-6979
- Gandhi A, Doumas C, O'Connor JP, Parsons JR, Lin SS. (2006). The effects of local platelet rich plasma delivery on diabetic fracture healing. *Bone.*, 38(4), 540-546, 8756-3282
- Hall MP, Band PA, Meislin RJ, Jazrawi LM, Cardone DA. (2009). Platelet-rich plasma: current concepts and application in sports medicine. *J Am Acad Orthop Surg.*, 17(10), 602-608, 1067-151X
- Anitua E, Sánchez M, Nurden AT, Zalduendo MM, de la Fuente M, Azofra J, Andía I. (2007). Platelet-released growth factors enhance the secretion of hyaluronic acid and induce hepatocyte growth factor production by synovial fibroblasts from arthritic patients. *Rheumatology.*, 46(12), 1769-1772, 1462-0324
- Saito M, Takahashi KA, Arai Y, Inoue A, Sakao K, Tonomura H, Honjo K, Nakagawa S, Inoue H, Tabata Y, Kubo T. (2009). Intraarticular administration of platelet-rich plasma with biodegradable gelatin hydrogel microspheres prevents osteoarthritis progression in the rabbit knee. *Clin Exp Rheumatol.*, 27(2), 201-207, 0392-856X
- Sánchez M, Anitua E, Azofra J, Aguirre JJ, Andia I. (2008). Intraarticular injection of an autologous preparation rich in growth factors for the treatment of knee OA: a retrospective cohort study. *Clin Exp Rheumatol.*, 26(5), 910-913, 0392-856X
- Sánchez M, Anitua E, Orive G, Mujika I, Andia I. (2009). Platelet-rich plasma therapies in the treatment of orthopaedic sport injuries. *Sports Med.*, 39(5), 345-354, 0112-1642
- Bellamy N, Buchanan WW, Goldsmith CH, Campbell J, Stitt LW. (1988). Validation study of WOMAC: a health status instrument for measuring clinically-important-platelet-relevant outcomes following total hip or knee arthroplasty in osteoarthritis. *J Rheumatol.*, 15(12), 1833-1840, 0315-162X
- EuroQol Group. (1990). EuroQol-A New Facility for the Measurement of Health-related Quality of Life. *Health Policy.*, 16(3), 199-208, 0168-8510
- Irrgang JJ, Anderson AF, and Boland AL, Harner CD, Kurosaka M, Neyret P, Richmond JC, Shelborne KD. (2001). Development and validation of the International Knee Documentation Committee subjective knee form. *Am J Sports Med.*, 29(5), 600-613, 0363-5465
- Filardo G, Kon E, Buda R, Timoncini A, Martino AD, Cenacchi A, Fornasari PM, Giannini S, Marcacci M. (2010). Platelet-rich plasma intra-articular knee injections for the treatment of degenerative cartilage lesions and osteoarthritis. *Knee Surg Sports Traumatol Arthrosc.*, 18(4), 472-479, 0942-2056

- Nurden AT, Nurden P, Sanchez M, Andia I, Anitua E. (2008). Platelets and wound healing. *Front Biosci.*, 13, 3532-3548, 1093-9946
- Kim SB, Kwon DR, Kwak H, Shin YB, Han HJ, Lee JH, Choi SH. (2010). Additive effects of intra-articular injection of growth hormone and hyaluronic acid in rabbit model of collagenase-induced osteoarthritis. *J Korean Med Sci.*, 25(5), 776-780, 1011-8934

IntechOpen

IntechOpen



Osteoarthritis - Diagnosis, Treatment and Surgery

Edited by Prof. Qian Chen

ISBN 978-953-51-0168-0

Hard cover, 404 pages

Publisher InTech

Published online 02, March, 2012

Published in print edition March, 2012

Osteoarthritis is one of the most debilitating diseases affecting millions of people worldwide. However, there is no FDA approved disease modifying drug specifically for OA. Surgery remains an effective last resort to restore the function of the joints. As the aging populations increase worldwide, the number of OA patients increases dramatically in recent years and is expected to increase in many years to come. This is a book that summarizes recent advance in OA diagnosis, treatment, and surgery. It includes wide ranging topics from the cutting edge gene therapy to alternative medicine. Such multifaceted approaches are necessary to develop novel and effective therapy to cure OA in the future. In this book, different surgical methods are described to restore the function of the joints. In addition, various treatment options are presented, mainly to reduce the pain and enhance the life quality of the OA patients.

How to reference

In order to correctly reference this scholarly work, feel free to copy and paste the following:

Dong Rak Kwon and Gi Young Park (2012). Intra-Articular Injections for the Treatment of Osteoarthritis: Focus on the Clinical Use of Several Regimens, Osteoarthritis - Diagnosis, Treatment and Surgery, Prof. Qian Chen (Ed.), ISBN: 978-953-51-0168-0, InTech, Available from: <http://www.intechopen.com/books/osteoarthritis-diagnosis-treatment-and-surgery/intra-articular-injections-for-the-treatment-of-osteoarthritis-focus-on-the-clinical-use-of-several->

INTECH
open science | open minds

InTech Europe

University Campus STeP Ri
Slavka Krautzeka 83/A
51000 Rijeka, Croatia
Phone: +385 (51) 770 447
Fax: +385 (51) 686 166
www.intechopen.com

InTech China

Unit 405, Office Block, Hotel Equatorial Shanghai
No.65, Yan An Road (West), Shanghai, 200040, China
中国上海市延安西路65号上海国际贵都大饭店办公楼405单元
Phone: +86-21-62489820
Fax: +86-21-62489821

© 2012 The Author(s). Licensee IntechOpen. This is an open access article distributed under the terms of the [Creative Commons Attribution 3.0 License](#), which permits unrestricted use, distribution, and reproduction in any medium, provided the original work is properly cited.

IntechOpen

IntechOpen