

We are IntechOpen, the world's leading publisher of Open Access books Built by scientists, for scientists

4,800

Open access books available

122,000

International authors and editors

135M

Downloads

Our authors are among the

154

Countries delivered to

TOP 1%

most cited scientists

12.2%

Contributors from top 500 universities



WEB OF SCIENCE™

Selection of our books indexed in the Book Citation Index
in Web of Science™ Core Collection (BKCI)

Interested in publishing with us?
Contact book.department@intechopen.com

Numbers displayed above are based on latest data collected.
For more information visit www.intechopen.com



Dural Reconstruction in Meningioma Surgery

Ciro Parlato¹, Roberto Granata¹, Aldo Moraci¹ and Marina Accardo²

¹Department of Neurosurgery,

²Department of Public Health Section of Pathology,
Second University of Naples

Italy

1. Introduction

After many cranial and spinal neurosurgical removal of meningiomas, reconstruction of the dura mater is needed. The dura has to be meticulously closed following craniotomy (Protasoni et al., 2011), but primary dural closure with sutures alone can be difficult in a loss of native dural tissue (i.e., convexity meningiomas), to enlarge the dural compartment (i.e., inoperable intramedullary tumors) and when the closure is difficult and not sufficiently watertight because dura mater edges have shrunken and they cannot be sutured directly.

In this chapter we review different dural reconstruction techniques and we present our personal experience with TissuDura which is composed of colloidal collagen from equine Achilles' tendon and is inactivated with sodium hydroxide and chloridric acid. Unlike others dural substitutes who have different degrees of porosity, TissuDura has a lamellar structure that makes it waterproof, thus preventing the appearance of cerebrospinal fluid leak and tear. Previous reports have shown an absence of local and systemic toxicity and a low incidence of adherences and inflammation with TissuDura, making it a viable option for dural substitution. We present a series of patients who required dural graft implantation during various cranial and spinal neurosurgical procedures. Unlike previous reports, where a number of patients required sutures for fixation of the collagen matrix, our neurosurgical procedures were performed without the need for sutures, reducing surgery times, and allowing TissuDura to be applied to anatomically difficult locations. On the other hand we review different dural reconstruction techniques include watertight closure and nonwatertight closure of dural defects with and without dural grafts. Watertight closure of dural defects is required, as an inadequate closure of the dura mater at the end of neurosurgical procedures exposes the patient to cerebrospinal fluid leak, infections, hypertensive pneumocephalus, pseudomeningocele, cerebral herniation, and other complications that can lead to a longer period of hospitalization. Over the past decades, various types of material have been evaluated to determine the ideal dural replacement technique, including autografts, allografts, xenografts, and synthetic grafts. Neurosurgeons have used different types of graft to obtain an optimal duroplastic (Warren et al., 2000): egg membrane, rubber laminated leaf, gold foil and other materials. The first duraplasty described in literature was conducted in 1895 by Abbe. At the end of nineteenth century, Beach suggested the use of gold leaf to prevent the formation of meningocerebral adherences. However, many of these products have been associated with postoperative

complications, some of which were serious, such as hemorrhages, development of corticomeningeal adhesions, inflammatory and foreign body reactions. Friction is the major complication of polytetrafluoroethylene duraplasty because of its strong surface tension and poor adaptability. Autologous duraplasties are accompanied by potential donor-site complications and are inappropriate for large defects. Acellular dermal grafts prepared from cadaver human skin do not suffer from these drawbacks; in addition, these matrices have been reported to promote the formation of new dural tissue by providing a scaffold for the growth of local cells while the matrix itself is fully reabsorbed over time (Islam et al., 2004). However, the use of human cadaver skin is associated with the development of atrophy or adhesion with the brain surface. Furthermore, relationships between iatrogenic Creutzfeldt-Jakob disease and implanted human cadaveric dura grafts have recently been reported. Similarly, implanted bovine xenografts carry a risk of transmission of bovine spongiform encephalopathy.

2. Dural substitutes

When primary closure is not possible, the use of dural grafts has been a common neurosurgical practice. This is the case especially in convexity meningioma surgery, where the removal of a large piece of dura along with the tumor to achieve a Simpson grade I or II resection results in a sizable defect that requires grafting. An ideal graft would show no inflammation in the host body and no neurotoxicity and adhesion to the underlying brain. At the same time it would be easily available and inexpensive, as well as durable, flexible, and easily prepared and shaped. Ideally, at the same time it would be rapidly resorbed, allowing the endogenous connective tissue to build up. Additionally, while providing adequate protection for the underlying brain, it should ensure watertight closure.

A common classification of dural substitutes includes: autografts (fascia lata, temporalis fascia), allografts (amniotic and placental membranes, pericardium, fascia, lyophilized dura), xenografts (bovine or porcine pericardium, peritoneum, dermis) and synthetic materials (polytetrafluoroethylene, polyester urethane). However, each materials pose drawbacks that limit their usage and require suturing to the endogenous dura to obtain a watertight closure.

2.1 Autografts

Autograft is a tissue that is taken from one part of a person's body and transplanted to a different part of the same person. There are several autografts, the most important of which are temporalis fascia, pericranium, autologous fat and fascia lata. Autografts do not transmit disease and do not give immuno-mediated responses in the host, but dimensions and qualities of tissues used for transplant are insufficient, especially when there is a considerable loss or retraction of dura mater. Furthermore, autograft requires an additional incision, resulting in an increase in surgical time with a consequent increase in anesthetic time, and a graft's hypoxia potentially causes an inflammatory response of underlying cortex (Islam et al., 2004).

Autologous fat is impervious to water, do not adhere to surrounding tissues and becomes revascularized (Black, 2010, as cited in Mayfield, 1980); it seems to be recommended for repair of dural tear or defects that are inaccessible or unsuitable for standard suture technique. However, autologous fat is not recommended in sovratentorial craniotomies

(except in the evidence of a rhinorrhea after transsphenoidal approaches). Although rare, the most severe complications associated with autologous fat transplant are early fat necrosis and liquefaction (Hwang et al., 1996), fat dissemination in the subarachnoid space (McAllister et al., 1992) and subsequent lipoid meningitis (Ricaurte et al., 2000). Although causes of early fat necrosis are unknown, probably an initial transient ischemia determines early fat necrosis, followed by fat liquefaction. Moreover, liquefaction is more frequent and more serious in presence of a pathogen, in cerebrospinal fluid tear and leakage and after surgical wound's irradiation in postoperative time (Taha et al., 2011). Aseptic lipoid meningitis is the consequence of dissemination of liquefied fat into subarachnoid space, caused by the rupture of tumors or any event which weakens dura mater and creates a communication between epidural and subdural spaces. Differential diagnosis with other chemical meningitis is based on several clinical parameters that make lipoid meningitis easily distinguishable from other variants. In fact, lipoid meningitis occurs at least 1 week after surgery, does not respond to steroids and has a chronic and intermittent clinical course.

Pericranium (the external periosteum that covers the outer surface of the skull) is an autologous graft easy to harvest, does not require an additional skin incision and is more resistant to infection than synthetic grafts, but it is thin, fragile and difficult to handle. These difficulties could be overcome with the use of fibrin sealant; in fact, association of fibrin glue and pericranium seems to make it more easy to handle (Ito et al., 2011).

Despite having a sufficient thickness and being very tough, fascia lata (deep fascia of the thigh) is rarely used in neurosurgery because it is difficult to harvest and requires an additional skin incision, which determines an increased morbidity. On the other hand, temporalis fascia is a strong, fibrous graft used for duraplasty because it does not require an additional skin incision and has all the properties (thickness, strength, flexibility, easy availability) that makes it an optimal dural graft.

2.2 Allografts

Allograft is a transplant from one person to another, but not an identical twin. In past years, neurosurgeons have used several allogenic tissues for duraplasty (amniotic and placental membranes, pericardium, cadaveric lyophilized dura mater), many of which now rejected. Cadaveric lyophilized dura mater is a fragile tissue and creates adherences with surrounding tissues and underlying brain; it can give immunomediated inflammatory reactions and transmit Creutzfeldt - Jacob disease. In fact, it was hypothesized that prions could survive at any type of sterilization; however, it is important to remember that prions can be found in nervous system and have never been shown in dura mater. Moreover, re-operation have demonstrated atrophy of the allograft, even in well-performed surgery, and the transmission of Creutzfeldt - Jacob disease has created doubts about a possible viral transmission.

Dehydrated human pericardium, sterilized by γ -irradiation, is a valuable alternative when autologous material is not available: adherence to the cortex were not observed and dural patch was preserved and appeared as host dura (Caroli et al., 2004). Histologically they demonstrated a vascularization and fibroblastic infiltration of the dural substitute with good incorporation into the surrounding host dura). Moreover, its physical and mechanical properties make it an excellent choice.

Acellular dermal graft, derived from cadaveric human skin, has been used widely for various reconstructive surgery: it is tough, flexible, easy to suture, well tolerated and immunologically inert, does not create adherence with surrounding tissue and underlying brain, and form a watertight barrier that prevent cerebrospinal fluid leak. The internal structure of acellular dermal graft stimulates fibroblast invasion and rapid neovascularization without cell-mediated immune response (Chaplin et al., 1999): these characteristics justify the excellent rate of duralization of acellular dermal graft (Warren et al., 2000). Recently, some Authors have conducted an experimental study using 6 mongrel dogs (weight = 8-12 kg) and they have demonstrated that acellular dermal graft transplant has not been followed by infection, cerebrospinal fluid leak and adherence formation (Islam et al., 2004). Moreover, they histologically have found cellular infiltration of the graft: especially fibroblasts (mostly immature), neutrophils, rare monocytes and lymphocytes. They finally argue that acellular dermal graft may be a reasonable alternative to the available dural graft materials.

2.3 Xenografts

Bovine or porcine pericardium and other xenografts have been used as dural substitutes for many years. Equine Achilles' tendon, bovine or porcine pericardium are a surgical graft or tissue from one species to an unlike species. The prefix xeno- means foreign; it comes from the Greek word xenos, meaning stranger, guest, or host. There are two types of xenografts: 1) processed whole tissues; 2) highly engineered collagen matrix.

Bovine or porcine pericardium are examples of processed whole tissues. They are strong, pliable, easy to handle, economically advantageous, but require watertight suturing. Bovine pericardium is well tolerated, with a low incidence of postoperative complications (2%) (Hida, 2006, as cited in Laun, 1990); however, among the most common complication with this type of graft, there are the onset of foreign body reactions, aseptic meningitis and the transmission of Creutzfeldt – Jacob disease.

On the other hand, collagen matrix has several advantages: it serves as a scaffold and is completely replaced by patient's dura mater in few months (Narotam et al., 1995); moreover, it is an inert, elastic, easily handled adhesive material and does not cause inflammatory reaction or foreign body reaction. It is formed by type I collagen, a very insoluble and only weakly immunogenic material (Narotam, 2009, as cited in Ellingsworth, 1986); in fact, collagen immunogenicity is poor due to absence or scarcity of aromatic aminoacids (Reddy et al., 2002). Requiring no suture and using it as an onlay graft, collagen matrix reduces surgery time and the risk of foreign body giant cell reaction, a frequent complication when neurosurgeon have to suture dura mater (Narotam, 2009, as cited in Macfarlane, 1979). If the overlap between the graft and the dura is appropriate (minimum overlap required = 1 cm), collagen matrix can be used as an onlay graft without an additional fixation; otherwise neurosurgeon needs to use one or multiple additional fixation (for example, fibrin sealant). However, it seems that simultaneous multiple fixation are associated with a higher rate of infection and cerebrospinal fluid leaks (Stendel et al., 2008).

In summary, sutureless dural repair using collagen matrix has several advantages: reducing surgery time, facilitating application of small patches in surgical difficult location, overcoming difficulties related to presence of fragile or ossified dura mater. This advantages

are fundamental in transsphenoidal approach for the narrowness of operative field: a duraplasty is necessary only when neurosurgeons demonstrate a cerebrospinal fluid tear or leak and when there is a communication between suprasellar arachnoid cistern and sellar cavity (Biroli et al., 2008); in these cases surgeon can only use collagen matrix or associate it with a fibrin sealant. Recently, some Authors have demonstrated a lower operating time with the use of collagen matrix as compared with suturable acellular human dermal grafts (Danish et al., 2006).

2.4 Synthetic grafts

Synthetic graft are also widely used in Neurosurgery. In past years several materials have been introduced in surgical practice (polytetrafluoroethylene, polyester urethane). However, these materials present a lot of drawbacks that placed them in the background. Despite their theoretical uniform thickness and no risk of infection transmission, polytetrafluoroethylene and the other synthetic grafts have often a rigid structure, resulting difficult to handle, are often not able to be replaced by dura mater and are burdened by numerous inflammatory and foreign body reactions. These reactions can create an inflammation of surrounding tissues and underlying brain, an excessive fibrin production with graft encapsulation, cerebrospinal fluid bleeding, meningitis, graft rejection, scarring, infections, delayed bleeding, for which a reoperation is often required. Moreover, in watertight closure holes created by suturing graft to dura mater could cause a cerebrospinal fluid leakage. The strength of synthetic absorbable grafts is only guaranteed for the first 2 weeks: these materials are often brittle and they tends to give cerebrospinal fluid leaks, without preserving the guest from serious inflammatory reactions (Yamada et al., 1997). Other drawbacks of polytetrafluoroethylene are represented by its strong surface tension and its lack of adaptability, frequent appearance of friction injury with underlying brain and meninges, which may cause bleeding and inflammation (Islam, 2004, as cited in Yamagata, 1993). On the other hand, some Authors have evaluated advantages and drawbacks of a new synthetic dural graft, designed for use both in traditional watertight dural closure and as a dural underlay graft in non-watertight fashion (Chappell et al., 2009). This dural substitute has two different surfaces: the first one, placed in contact with the brain, is a porous structure (pores diameter $< 1 \mu\text{m}$, so that cellular migration and penetration are prevented); the second one has a porous structure too, but it has larger pores (diameter $\sim 22 \mu\text{m}$), resulting in a rapid cellular infiltration and migration. They finally argue that this synthetic graft may be used as an underlay graft to obtain a non-watertight closure. On the other hand, if used over large voids, watertight closure is also viable.

Moreover, a new transparent artificial dura mater derived from silk fibroin was recently evaluated in craniotomized rats (Kim et al., 2011). This synthetic graft seems to have an excellent biocompatibility, good water vapor and oxygen permeability, blood compatibility, and promotes collagen formation and proliferation of human fibroblast in vitro. The high tensile strength of this material allowed them to suture it easily to the rats' dura mater without demonstrated cerebrospinal fluid tear or leak. Although the Authors cannot establish long term effects of silk fibroin, they argues that its optimal biocompatibility and its ability to inhibit inflammatory reaction make it safe and potentially useful for future neurosurgery.

3. Surgical sealant

Surgical sealants (also called surgical glues or adhesives) are used after a surgery or traumatic injury to bind together external or internal tissue. Surgical glues can be used in conjunction with or as an alternative to sutures and staples; they use a chemical bond to hold tissue together for healing or serve as a barrier to stop the flow of bodily fluids. The four main types of surgical glues are fibrin sealants, cyanoacrylates, glutaraldehyde glues and hydrogels. Cyanoacrylates (stronger than fibrin sealants and sutures, waterproof, flexible) and glutaraldehyde glues (a pungent colorless and potentially neurotoxic oily liquid) are not used in neurosurgery.

3.1 Fibrin sealant

Fibrin sealants are a type of surgical adhesive derived from both human and animal (bovine) blood products. One of these glues is a two component fibrin sealant that consists of human fibrinogen and human thrombin. When combined, thrombin converts fibrinogen to fibrin forming a clot. The mechanism of action of this fibrin glue is expressed by a permanent and rapid adhesion between human tissues and graft, supporting or replacing conventional sutures; moreover, it stimulates haemostasis and dural replacement. These sealants are not neurotoxic: in fact subdural administration in the rabbit was not associated with any adverse reaction (Epstein, 2010). Because adverse reactions are reported voluntarily and the population is of uncertain size, it is not always possible to reliably estimate the frequency of these reactions. Adverse effects are represented by allergic reaction, which may include angioedema, bradycardia, bronchospasm, dyspnea, agitation, tachycardia, headache, hypotension, generalized urticaria, vomiting, but it occur rarely in patients treated with fibrin glue/haemostatic drugs. In isolated cases, these reactions have progressed to severe anaphylaxis. Accidental intravascular administration may cause anaphylactic reaction, thromboembolic complications and disseminated intravascular coagulation. Hypersensitivities to fibrin glues and bovine protein are the only contraindications.

3.2 Hydrogels

Hydrogels are FDA-approved synthetic polyethylene glycol polymers, stronger than fibrin sealants. They are synthetic absorbable sealants (that have to be added to sutured dural repair to obtain a watertight closure), work in the presence of fluid, conform to irregular surface, demonstrate strong adherence and compliance to tissues without interfering with underlying tissue visibility and are reabsorbed in 4-8 weeks without leaving residue. They are also photoactivated, meaning that the sealant sets with exposure to light, which can be a drawback in situations where a patient is hemorrhaging. Hydrogels manufacturer suggests to not apply this sealant to confined bony structures where nerves are present since neural compression may result due to hydrogel swelling (hydrogel may swell up to 50% of its size in any dimension). Other Authors argue the safety and efficacy of a polyethylene glycol hydrogel sealant in patients undergoing elective cranial surgery with documented cerebrospinal fluid leakage after sutured dural repair, when it was used as an adjunct to sutures (Cosgrove et al., 2007). Contraindications include allergy, renal or hepatic dysfunction, head trauma, infection, hydrocephalus, cranial procedure that entails a dural

incision involving penetration of the air sinus or mastoid air cells and in a ventricular or lumbar drain. Moreover, hydrogel should not be used if an active infection is present at the surgical site, in patients with a compromised immune system or autoimmune disease and in combination with other sealants or haemostatic agents. Potential risks and adverse events that could occur from the use of hydrogels include, but are not limited to, wound infection, immediate, delayed and/or persistent cerebrospinal fluid leak, renal compromise, inflammatory reaction, neurological compromise, allergic reaction and/or delayed healing. A type of hydrogel was evaluated in 111 investigational patients in a pivotal clinical study, published in its own package leaflet. Adverse events (cerebral edema, cerebrospinal fluid leak, deep surgical site infection, headache, hydrocephalus, aseptic and bacterial meningitis, cognitive deficits, cranial nerve deficits, motor deficits, neuropsychiatric disorders, speech difficulty, visual disturbance) occur at a rate of 1% or higher in examined patients. Adverse event rates are based on the number of patients having at least one occurrence of a particular adverse event divided by the total number of patients treated. There were two patient deaths (out-of-hospital). In both cases, the deaths were attributed to the patients' prior condition. Recently, Epstein has reviewed literature and has demonstrated in two patients that the use of hydrogel was associated with quadriplegia and a cauda equina syndrome (Epstein, 2010).

4. Watertight closure

Duraplasty, like many surgical techniques and applications, is largely based on the personal experiences of individual surgeons, shaped by training passed down from mentors, and repeated generation after generation. The traditional teaching in neurosurgery has been that the dural reconstruction has to be watertight. This is fundamental (but sometimes very difficult to achieve) in meningioma surgery, especially when an extensive resection of a large convexity meningioma, a skull base meningioma or a posterior fossa meningioma with its dural tail is needed. A fundamental element of the watertight dural reconstruction is the use of suturing. Some Authors developed an *in vitro* model, testing different suturing techniques in providing watertight closure of the dura mater (Megyesi et al., 2004). They compared the efficacy of the interrupted simple, running simple, running locked, and interrupted vertical mattress sutures on primary closure of linear incisions and closure of dural defects using rectangular grafts. The results showed superiority of interrupted simple suture on primary closure of linear incisions over other techniques. In literature, the emphasis on watertight closure has been strong to the point that special techniques have been developed and proposed to reach difficult areas in order to achieve optimal dural reconstruction. However, one potential risk of using primary suture closure would be to create pinholes from the suture needle. In an attempt to achieve watertight closure, holes created on either side of the dura mater or the dural substitute may commonly lead to cerebrospinal fluid leakage. In addition, while implanting synthetic graft materials, dural tearing may be caused by the sutures themselves because of the elastic properties of these grafts which exert traction on the sutures. It is probably because of these factors that studies have shown up to sevenfold more favorable rates of effective dural closure when suture repair is augmented by tissue adhesives. To really understand limits created by the need to suture the dura mater, we make the example of duraplasty to repair a spinal cerebrospinal fluid tear or leak. A dorsal dural tear or leak can be repaired by applying direct sutures. However, lateral

spinal dural tear create a technically difficult problem for placement of sutures because of its inaccessibility. The same problem is present in ventral dural tear or leak: suturing in this area may be a real challenge. However, surgeons can apply a large fat layer on the ventral surface of dural sac, suturing this autologous graft to the outer layer of the dura mater to create a reinforcement of spinal dural suture lines (Black, 2000).

5. Non-watertight dural reconstruction with collagen matrix

Recently, there has been an interest in processing tissues with high connective tissue components such as pericardium and dermis to yield an acellular, antigen-free scaffold for growing endogenous tissue. Other Authors use collagen matrix (DuraGen, Integra Neurosciences, Plainsboro, NJ) for dural reconstruction in the majority of meningiomas where dural enlargement or watertight closure are required. This material is made up of type I collagen and is processed from bovine Achilles' tendon. The collagen matrix provides a low-pressure absorptive surface to diffuse cerebrospinal fluid and attaches to the dural surface via surface tension. It also helps clot formation by the platelets depositing themselves on the collagen, which then disintegrate and release clotting factors, ultimately facilitating fibrin formation. This fibrin has an important role in holding the graft in place until fibroblasts, associated with blood vessels, proliferate into the graft. This fibroblast infiltration starts by day 3–4 and becomes established in 10–14 days. The fibroblasts use the pores on the matrix to lay down endogenous collagen. By 6–8 weeks, the collagen matrix is resorbed and is integrated to the endogenous dura. The non-watertight reconstruction of the dura using the collagen matrix simply consists of the onlay application of the material over the dura. It is easily shaped and has the main advantage of not requiring any suturing. The collagen matrix is incorporated in the endogenous tissue in a relatively short period of time and in 24 weeks becomes barely distinguishable from the endogenous dura, unlike the allogenic cadaveric dura, which shows inadequate fusion with the endogenous dura and in addition becomes encapsulated in a connective tissue layer. This encapsulation has also been described for synthetic materials, which appears not to be an ideal situation with regard to the sealing quality of the material. It has also been shown that the compact structure of the xenogenic materials may limit the fibroblast migration to the edges or to the suture holes. In addition, the collagen, in the form of sponge, can absorb fluid without increasing its volume, and can act as a moistening agent for the brain, allowing penetration of cerebrospinal fluid into the graft. It also forms an effective separation layer and minimizes adhesions between the brain and the overlying tissue. These Authors concluded that non-watertight reconstruction of the dura in meningioma surgery prevented postoperative cerebrospinal fluid leak in 99.6% of patients (Lee, 2008). Graft-related complication was seen in only 2 patients (0.8%). These figures compare favorably to the majority of the reported series in which various techniques of watertight closure is described and the indispensability of watertightness in dural closure is emphasized. In addition to the extremely low rate of graft-related complications and cerebrospinal fluid leak, this technique makes significantly shorter the operative procedure, thereby possibly decreasing the risk of anesthesia-related complications as well, which would be of particular concern in patients with medical comorbidities. It would even help reducing the medical costs related to shortened operating room usage.

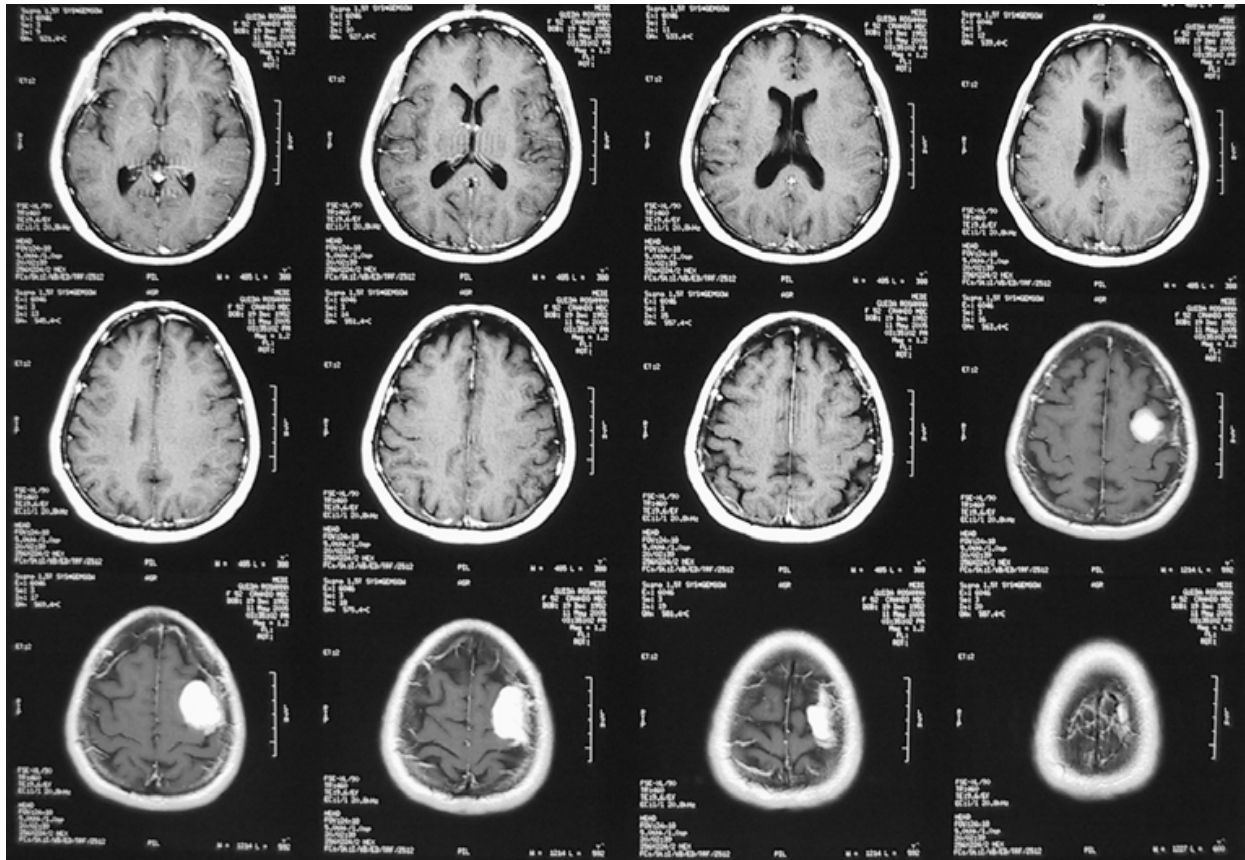


Fig. 1. Preoperative MR with gadolinium of left frontoparietal meningioma.

In our series, we analyzed dural reconstruction in 50 patients affected by meningiomas: 31 in the frontoparietal paramedian region and 19 in the parieto-occipital paramedian region. All cases of dural reconstruction were performed at our department of neurosurgery of the Second University of Naples between 2005 and 2009. TissuDura was rehydrated in physiological saline to obtain a transparent film that could be cut into the desired shape. Patches of the collagen matrix were cut with scissors to the appropriate size for the dural defects with an overlap of 1 cm. The patch was then placed over the dural defect, overlapping at the margins. The patch was fixed using fibrin glue. To avoid postoperative fibrosis, minimal amounts of fibrin glue were used in the repair of the dural defects. Surgical sutures were not used during dural reconstruction. No patient required removal of the graft, and the overlay technique with the use of fibrin glue was simple and fast. The time needed for the neurosurgical procedures was reduced. TissuDura facilitated the application of small patches in anatomically difficult locations. At follow-up, we did not observe any signs of graft rejection or cerebrospinal fluid leaks in any of our patients, and no other complications occurred. We observed the reorganization of dura and normal cerebrospinal fluid circulation. In the two cases of recurrent atypical meningioma, reoperation of the dural reconstruction was performed after 1 year. We observed no adhesions between the brain and neodura. Neodura formation allowing fibroblast ingrowth and collagen formation was observed. In these cases, histopathological and ultra structural findings from the previously implanted TissuDura showed fibroblasts and new normal dural tissue. The collagen matrix was fully degraded and replaced by natural collagen. TissuDura was not recognized as a foreign material and no tissue reactions were observed. We used TissuDura in a wide range

of spinal and cranial neurological procedures. Usually, dural reconstruction during spinal surgery must be meticulously sutured to avoid cerebrospinal fluid leaks because of the increased hydrostatic pressure in the supine or upright position; nevertheless, we performed the reconstructions without sutures and at follow-up we did not observe any cerebrospinal fluid leakages.

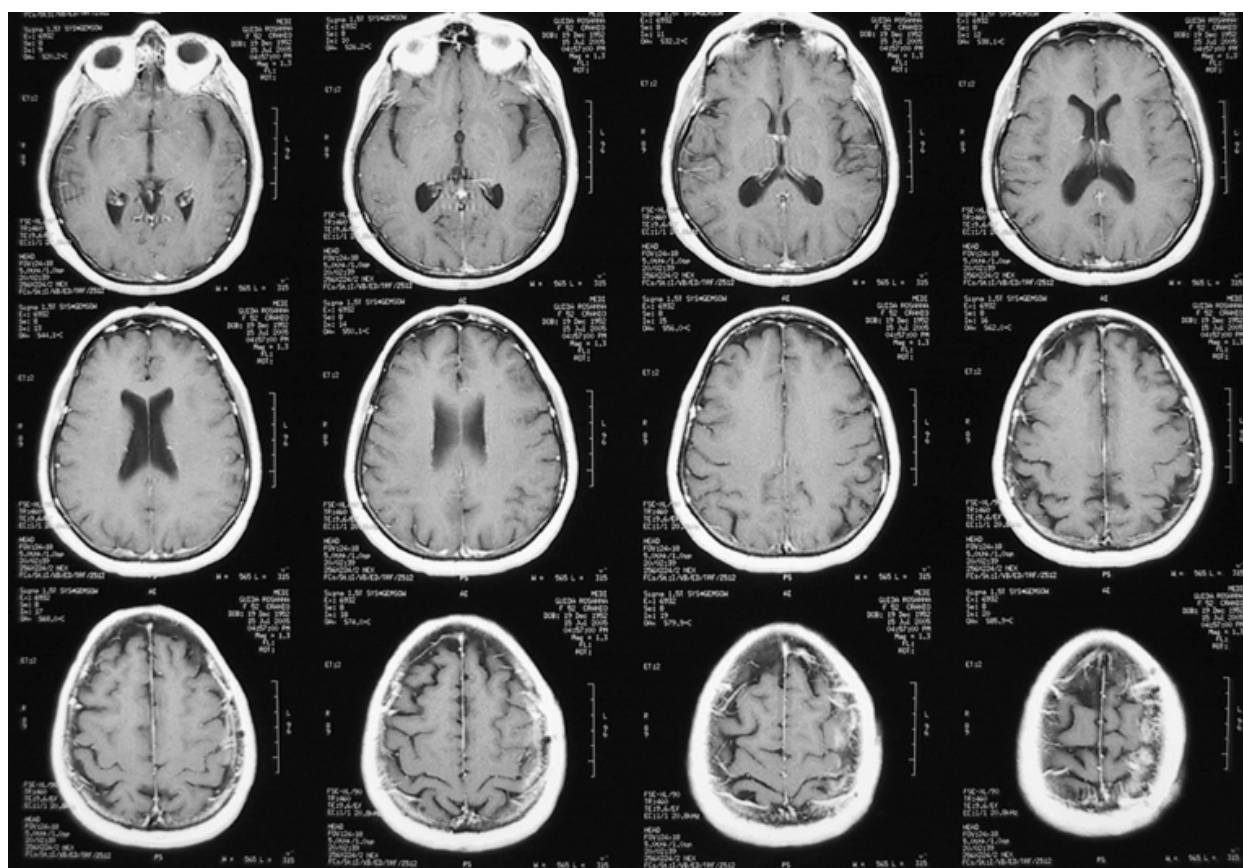


Fig. 2. Dural reconstruction by TissuDura and fibrin glue. Postoperative MR with gadolinium of complete removal of left frontoparietal meningioma.

The use of autologous fat transplants is recommended as a rapid, effective means for repair of dural tears or defects that are inaccessible or unsuitable for standard suture technique. TissuDura may be a viable alternative to these techniques. Some Authors developed a dural substitution technique using bio absorbable fabric and fibrin glue (Hida et al., 2006). In 160 patients who underwent dura repair using this polyglycolic acid–fibrin sheet method, ten (6.3%) experienced subcutaneous cerebrospinal fluid leakage. The Authors concluded that this technique represents a novel alternative to artificial dural substitutes that were available at that time. Recently, other Authors showed that collagen matrix is suitable for use in the posterior fossa where it can be applied as an onlay graft, without the inconvenience and time-consuming process of suturing (Narotam et al., 2007). This represents a more developed collagen-based dural graft compared with a collagen sponge; it was associated with a good safety profile, as well as being effective, easy to use, and time efficient. However, meticulous layered wound closure, the detection and effective control of hydrocephalus, and the use of closed suction wound drainage were required to minimize potential complications related to the use of collagen matrix duraplasty. In our patients, the overlay technique for dural

reconstructions using TissuDura was easy and fast and allowed good results in dural repair during meningiomas surgery without the use of closed suction. To avoid postoperative fibrosis, we used a minimal amount of fibrin glue in the repair of the dural defects. Studies of intracranial implantation in adult sheep showed that implantation of collagen biomatrix did not result in inflammation, cerebrospinal fluid leaks, or impaired wound healing (Knopp et al., 2005). Microscopic assessment of graft incorporation 2 weeks postoperatively showed loosening of the homogeneous structure of the collagen graft with invasion of lymphocytic and monocytic components. After a period of 4 weeks, lymphocytic and monocytic exudates were present and polymorphonuclear giant cells were common with numerous fibroblasts. Eight weeks postoperatively, inflammatory infiltrates had regressed further. After 24 weeks, there was a further regression of inflammatory infiltrates and continuity between the highly collagenous endogenous dura and the newly formed collagen fibers of neodura. In another case report, histological examination of a tissue sample taken 40 days after implantation of a collagen matrix revealed that the graft had been replaced by significant ingrowth of the native dura (Gazzeri et al., 2009). Similarly, in our two patients with recurrent meningiomas who required re-operation, long-term follow-up using histopathological and ultra structural techniques demonstrated re-absorption of the TissuDura and regeneration of dura mater. The first report with documented histopathological and ultra structural imaging showing dura regeneration after TissuDura graft insertion was presented (Parlato et al., 2011). Our ultrastructural observations showed an absence of inflammatory infiltration and migration of fibroblasts, resulting in the neodura regeneration. The collagen matrix was fully degraded and replaced by native collagen neodura after 12 months.

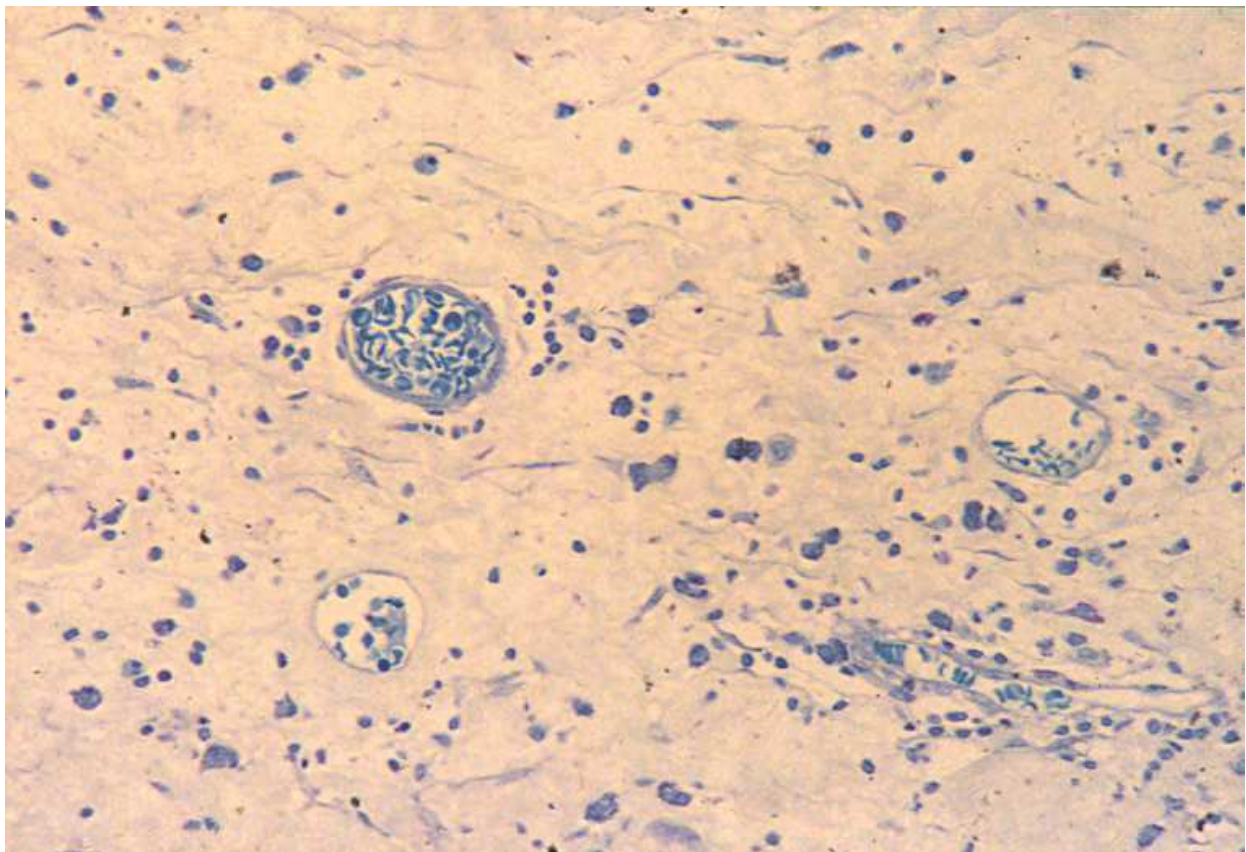


Fig. 3. Neurohistopathological photomicrographs of neodura.

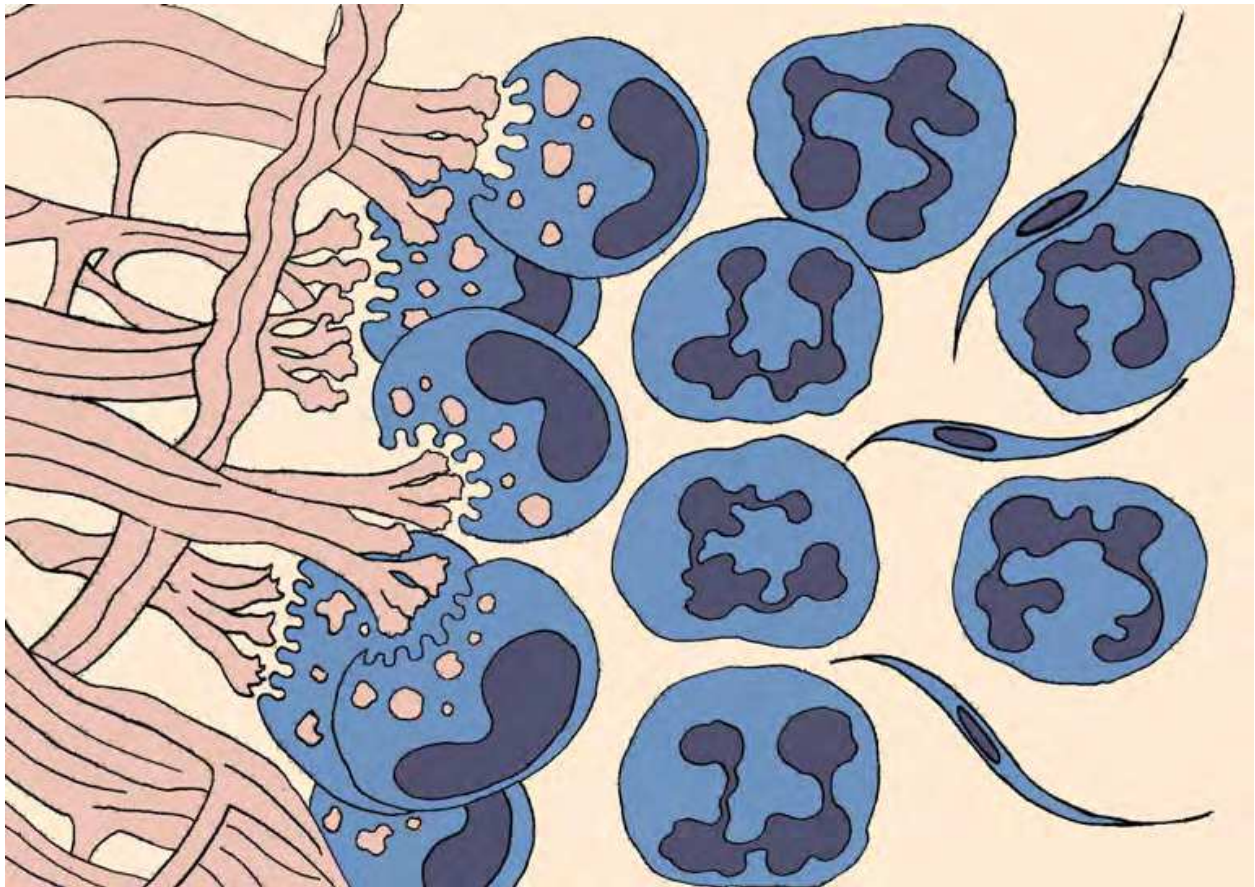


Fig. 4. Illustration of collagen matrix and its interaction with macrophages and neodura.

TissuDura demonstrated all aspects of the ideal dura substitute: elasticity, nonreactivity, good adaptability, and easy and speed of application. Dural reconstructions were performed without surgical sutures, and no incidences of local toxicity or complications such as cerebrospinal fluid leaks, adhesences, or inflammation were observed. Moreover, the overlay technique with the use of fibrin glue was simple and quick to perform. Histopathological and ultra structural images demonstrated dura regeneration after TissuDura graft insertion in patients with recurrent meningioma after 12 months follow-up.

6. Duraplasty after transsphenoidal approach

The transsphenoidal approach is a minimally invasive surgical technique for the removal of several tumors; in this chapter we examined dural reconstruction after surgery of tuberculum sellae, olfactory groove and clival meningiomas. The evolution of the technique has coincided with progress in biotechnology. In the early twentieth century, Hirsh and Cushing have designed and demonstrated benefits of transsphenoidal surgery compared to the classical transcranial approach. Subsequently, Dott, a Cushing's assistant, have ideated several instruments to improve the use of this technique. In 1967, Hardy have used operating microscope for the first time. This progress has been joined by surgeons over the years, making transsphenoidal surgery safer and less invasive. In particular, tuberculum sellae meningiomas are suprasellar meningiomas, frequently arise from the tuberculum sellae, chiasmatic sulcus, Planum sphenoidale, and diaphragma sellae and comprise 5% to

10% of all intracranial meningiomas (Bassiouni et al., 2006). There are several surgical advantages of the endoscopic endonasal transsphenoidal approach for the improvement of visual outcome and the surgical treatment of tuberculum sellae meningiomas (Wang et al., 2010). First, the most important advantage is the avoidance of manipulation of an ischemic, compressed optic system. Second, the extended endoscopic endonasal transsphenoidal approach provides the potential for early and direct visualization of subchiasmatic perforators. Third, complete mobilization and decompression of the optic nerve contribute to its protection. Fourth, this approach obviates brain retraction, provides better cosmetic results in addition to increased patient comfort, and permits working under direct visual control to realize a Simpson grade I removal (Jallo et al., 2002). Recently, advantages and drawbacks of Extended Transtuberculum Transplanum Approach (ETTA) are examined (Frank and Pasquini, 2010). The Authors argue that ETTA allows reaching tuberculum sellae meningiomas through a direct and extracerebral approach, minimizing brain manipulation. Furthermore, it permits a frontal exposure of the anatomic regions that are not easy to visualize through intracranial approaches. However, ETTA has two main limits: 1) reduced versatility, and 2) the risk of cerebrospinal fluid leak. The cerebrospinal fluid leak is extremely variable. To prevent this complication, the Authors suggest the use of a multilayer autologous repair, but they also felt that, independently of the used technique, the range of post-operative cerebrospinal fluid leak can decrease only with an increased experience of surgeon, making the risk of the ETTA acceptable. Recently, advances in transsphenoidal endoscopic surgery have allowed difficult clival and petroclival tumors such as meningiomas causing effacement of the pons and basilar artery to be approached by this technique (Alexander et al., 2010). In past years, these meningiomas could be removed only with a transcranial approach. Now advances in transsphenoidal endoscopic surgery have allowed treatment of these tumors. The most common complications after a transsphenoidal approach are represented by meningitis, tension pneumocephalus and cerebrospinal fluid leak. Meningitis are directly associated with the incidence of untreated post-operative cerebrospinal fluid leak and range from 0,5% to 14%. Tension pneumocephalus has an incidence of less than 0,5%. The last but not the least complication is represented by postoperative cerebrospinal fluid leak, requiring a watertight dural closure, especially when surgeon needs to remove larger meningiomas. There are 4 ways to achieve the same goal: autografts and synthetic grafts; dural suturing with or without dural substitute; vascularized mucoseptal flap method; and the multilayer method. Those methods can be used singly or in combination (Saeki et al., 2010). In past years, lumbar drainage was often used to decrease intracranial pressure, facilitating closure of the dura mater; now the introduction in surgical practice of different types of grafts and sealant has rendered not routinely the use of a lumbar drainage (Kassam et al., 2005). Recently, some Authors have described their opinion about different duraplasties, to establish the better way to prevent post-operative cerebrospinal fluid leak (Liu et al., 2011). Based on their own experience, they place intradurally an autologous fascia lata graft, holding it in place with several pieces of an absorbable haemostatic agent; next they tuck a layer of thick implantable acellular dermal graft at least 1 cm circumferentially between the remaining dural cuff and the edge of the bony defect; then bilateral mucosal flap pedicled on the posterior nasal artery are rotated over the acellular dermal graft to cover cranial base defects. Finally a thin layer of surgical sealant is placed over the multilayer closure (Germani et al., 2007); however, he did not use the flap and showed a postoperative cerebrospinal

fluid leak range of 3%. With innovation made by Liu et al., they demonstrate a decrease in postoperative cerebrospinal fluid leak; moreover, mucosal flap, used as an additional layer, promotes rapid ingrowth of granulation, vascularization and re-epithelialization by sinonasal mucosa and allows surgeon to repair large skull base defects extending anteriorly to the posterior wall of the frontal sinus. On the other hand, some Authors have recently conducted a study on the use of equine collagen foil as dura mater substitute in endoscopic endonasal transsphenoidal surgery (Cappabianca et al., 2006). When an intraoperative cerebrospinal fluid leak is not demonstrated, they put the graft in place by the sole fibrin sealant that seems to be sufficient to prevent a postoperative cerebrospinal fluid leak. On the other hand, large intraoperative cerebrospinal fluid leak needs a multilayer dural reconstruction: the first layer of collagen matrix is put intradurally; the next step is the use of a solid or semisolid buttress to hold the sealing tissue in position and maintain the watertight seal to resist the pulsations of the brain and cerebrospinal fluid; then collagen sponges are put in the sphenoid sinus and, finally, fibrin glue is applied to ensure a watertight closure. Using this technique, Authors have demonstrated a post-operative cerebrospinal fluid leak range of 6,7%.

7. Complications of duraplasties

Cerebral or cerebellar swelling and shrinking margins of the dura mater during prolonged neurosurgery often necessitate a duraplasty to obtain a satisfactory watertight closure. However, despite the use of grafts, duraplasty are sometimes followed in post-operative observation by cerebrospinal fluid leakage, deep wound infection, asymptomatic pseudomeningocele, bleeding and hematomas, adherence formation, cerebral herniation, hypertensive pneumocephalus, epilepsy, chemical or bacterial meningitis, all resulting in a longer hospitalization.

Several complications are demonstrated after posterior fossa surgery. However, a well-performed duraplasty using a collagen matrix is safe and effective in the posterior fossa (Narotam et al., 2009). Authors have compared data derived from their experience with those represented in literature. Previous reports concerning posterior fossa dural repair using watertight seals demonstrate an average cerebrospinal fluid leakage rate of 7,7%, an average infection rate of 7,5%, an average asymptomatic pseudomeningocele, diagnosed with MRI and/or CT scan, rate of 11,8%. Using porous collagen matrix, Authors have found an average infection rate of 1,9% and an average asymptomatic pseudomeningocele rate of 3,8%; no cerebrospinal fluid leaks are described, so they argue that watertight dural closure is not essential in posterior fossa surgery.

Although rarer than posterior fossa surgery, complication are also frequent in sovratentorial approaches. Other Authors demonstrate an average infection rate of 4,5% using porous collagen matrix (Gnanalingham et al., 2002). Collagen matrix is used to obtain a watertight dural closure (Stendel et al., 2008); they report an average infection rate of 2,6%, an average cerebrospinal fluid leakage rate of 5,2% and an average cerebrospinal fluid fistula of 2,6%. Comparing this data with those obtained from literature, they have demonstrated that the use of collagen matrix determines a lower risk of infection and cerebrospinal fluid loss than the use of autograft or synthetic material. Moreover, postoperative infection seems to increase the risk of postoperative cerebrospinal fluid leakage.

Recently, the transmigration of fibrino-purulent and malignant cells into a dural graft was described (El Majdoub et al., 2008); this dural substitute is created with a non-absorbable, finely fibrillary, microporous, non-woven material of high purity aliphatic polyester urethane. Authors argue that local inflammation could create a local immunosuppression; moreover, the graft's implantation itself stimulates IL-10 and/or TGF- β secretion, enhancing immunosuppression and malignant cells infiltration of the graft.

Moreover, other Authors have recently reviewed literature about duraplasty in meningioma surgery and its related complication (Sade et al., 2011). The incidence of cerebrospinal fluid leakage reported in the literature varies, even when surgeons are using similar materials, probably indicating user-dependent variations. Authors demonstrate an average rate of 2 - 2,2% using acellular human dermis, an average rate of 15 % using allogenic cadaveric dura mater, an average rate of 3 % using allogenic and xenogenic pericardium and dura mater, an average rate of 10 % using autologous fascia, an average rate of 7 % using vicryl mesh, an average rate of 3 % using polytetrafluoroethylene and surgical sealant and an average rate of 20,3 % using polytetrafluoroethylene (alone). Other Authors have also published their own data about post-operative cerebrospinal fluid leak in a series of 128 patients who underwent posterior fossa surgery and in whom different types of duraplasty techniques and materials were used (Moskowitz et al., 2009): 25% using suturable bovine collagen, 12% with reformulated bovine collagen, 8% with acellular human dermis; no cerebrospinal fluid leak depending on the type of graft used are been demonstrated using bovine collagen matrix.

Inflammatory reactions can present in a time frame of 1-6 months following surgery; one of these complication is represented by chemical meningitis, that in general are more frequent in posterior fossa craniotomies (Forgacs et al., 2001) but this may not be applicable when it comes to chemical meningitis caused by a dural substitute. The incidence of chemical meningitis is 2,3% (Parizek et al., 1997). A higher incidence of inflammatory reactions was found after posterior fossa surgery (5,2%) compared with supratentorial locations (2%) (Sade et al., 2011); however, Authors emphasize that these data did not reach statistical significance.

The last but not the least problem related with dural reconstruction is represented by bacterial meningitis, a serious postoperative complication that can occur after the implantation of a foreign material. The incidences of postoperative infection differ in various studies, based on the use of various dural grafts (Sade et al., 2011): 1,5 - 2,2% using acellular human dermis, 0,6 % using allogenic and xenogenic fascia latae, pericardium and dura mater, 3,6 - 6,7% using collagen matrix and 9,6 % with polytetrafluoroethylene.

8. Future trends

Several searches of procedures and materials increase the contributions to the current debate on dural reconstruction. There are various schools of thought when it comes to dural reconstruction following meningioma surgery, which are largely based on the personal experience of the individual surgeons. Many schools perform preliminary evaluation of dura mater substitutes in the animals; with continued advances in chemical technology, it is inevitable that newer dural substitutes will be synthesized and they will be even closer to the normal dura, in terms of minimum or no inflammatory response, good handling

characteristic, and biodegradability. Many dural substitutes have been tested in animals but not in humans; others, although used in human, have not been used long enough to assess the long-term results.

Some Authors have described a biodegradable elastic-fibrin material that is being used in humans; preliminary results have indicated that this material seems promising. In an experimental setting, the biodegradable elastin fibrin material produces minimal but histologically detectable inflammatory reaction; it is attenuated if a 0,2 mm thick graft is used rather than a 1 mm thick graft (San-Galli et al., 1996). Other Authors reported the use of biosynthetic cellulose as a dural substitute; they affirmed that the physical properties of biosynthetic cellulose and the low cellular reaction to its implantation qualify this material as an ideal dural substitute; like other materials, the use in humans is pending although experimental results are promising (Mello et al., 1997). Others described the use of hydroxymethylmethacrylate hydrogels as potential dural substitute; experimental studies of this material have been promising, but the use in human is pending (Bathia et al., 1995). Others have developed a composite sheet composed of two layers of L-lactic acid ϵ -caprolactone with polyglycolic acid nonwoven fabric sandwiched between the layers. Clinical trials of this material are pending (Yamada et al., 1997). The vicryl mesh as a suitable dural substitute, with potential advantages, was performed to avoid cerebrospinal fluid leak, following posterior fossa surgery (Verheggen et al., 1997). Many methods to prevent postoperative cerebrospinal fluid leakage are available, but pressure-tight dural closure remains difficult, especially with synthetic surgical membranes. Other Authors assessed the efficacy of a novel dural closure technique, using absorbable polyglactin acid sheet and fibrin glue. They evaluated the results by detecting extradural or subcutaneous cerebrospinal fluid leakage on magnetic resonance imaging. They concluded that the combination of polyglactin acid sheet and fibrin glue can achieve watertight closure after intradural surgery and can minimize the risk of intractable postoperative cerebrospinal fluid leakage. But this simple, economical technique is recommended for dural closure after spinal intradural surgery (Sugawara et al., 2005).

Some Authors compared cranial dural adhesions in a canine model, after duraplasty using nonpenetrating clips or penetrating needles and sutures. They concluded that duraplasties with clips displayed significantly less extensive acute and chronic inflammation, foreign body reaction, and meningoneural adherence than did repairs with needles and sutures (Palm et al., 1999).

Also about BioGlue there are innovative reports; this glue was applied as a reinforcement over collagen sponge as the last layer of the duraplasty. Authors concluded that this glue appears to be an effective adjunct in preventing postoperative cerebrospinal fluid leaks after transsphenoidal surgery. However, careful attention to technical details of the repair is still required to prevent failures, especially when closing large dural and diaphragmatic defects (Dusick et al., 2006). But the adequate repair of intraoperative cerebrospinal fluid leaks during transsphenoidal surgery remains a challenge. Other Authors have described the application of N-butyl 2-cyanoacrylate (cyanoacrylate) tissue glue for repair of cerebrospinal fluid fistulas during transsphenoidal surgery; they concluded that this glue appears to be effective and safe in preventing postoperative cerebrospinal fluid leakage (Cohen-Gadol et al., 2010).

Recently, a new polyethylene glycol dural sealant product was reported as effective at preventing cerebrospinal fluid leak after posterior fossa surgery (Than et al., 2008). Another technique for minor dural gap repair was reported; these Authors performed the duraplasty with a piece of oxidized cellulose, reinforced by fibrin glue, as a sutureless graft with more ease and less technical demand than other techniques. This procedure is a fast and valid alternative to small dural defect closure methods (Gazzeri et al., 2011).

All experimental and clinical studies consider new procedures or new materials, but the newer search field is dural cell culture. Some Authors have analyzed the dural cell culture as a new approach to achieve a duraplasty. Their study succeeded in establishing a cell culture model for duraplasty and indicated cellular migration from the dura borders at the site of the defect during the wound healing process. The cell culture model presented in this report shows that collagen grafts are best suited for duraplasty. In accordance with the immunocytological finding of fibroblast migration from the dura borders, additional application of fibroblast-stimulating growth factors accelerated cellular defect closure (Schick et al., 2003). Other Authors affirmed that fibrin glue is an attractive extracellular matrix for cellular migration from the dura, which is suited to fibroblast culturing in suture nets. Their findings supported the idea of achieving closure of cerebrospinal fluid fistulas by suture application of autologous fibroblasts and fibrin/thrombin preparations as a realistic future goal (Wolf et al., 2005). Also another study have demonstrated that an in vitro model for dural healing was successfully constructed in collagen-coated wells; results implicate cellular migration of fibroblasts from the dural defect margin as an important mechanism of wound healing following duraplasty (Zhou et al., 2006). These evaluations confirm our clinical observations about our cases of duraplasty. On the other hand, there are many searches about mesenchymal stem cells; some Authors have assessed the ability of rat bone marrow derived mesenchymal stem cells, in the presence of a growth factor, (fibroblast growth factor-4 and hydroxyapatite), to act as a scaffold for posterolateral spinal fusion in a rat model (Seo et al., 2009). Recently, human embryonic stem cell-derived mesenchymal cells were described, investigating the efficacy of these cells for cardiac repair after myocardial infarction (Simpson et al., 2011). Finally, the tissue engineering of multilayered constructs that model complex tissues poses a significant challenge for regenerative medicine. Some Authors have reported a three-layered scaffold consisting of an electrospun silk fibroin mat sandwiched between two dense collagen layers, providing an extracellular matrix-like environment for mesenchymal stem cells. They concluded that the ease of multilayered construct fabrication, enhanced biomechanical properties, along with uniformity of cell distribution confirmed the possibility for the incorporation and segregation of different cell types within distinct layers for the regeneration of complex tissues, such as skin, or central nervous system dura mater (Ghezzi et al., 2011). In the foreseeable future, several promising procedures and several synthetically derived dural substitute may be available for human use that contain most of the attributes of an ideal dural substitute.

9. References

- Alexander, H.; Robinson, S.; Wickremesekera, A. & Wormald, P.J. (2010). Endoscopic transsphenoidal resection of a mid-clival meningioma. *Journal of Clinical Neuroscience*, Vol.17, No.3, (March 2010), pp. 374-376.

- Bassiouni, H.; Asgari, S. & Stolke, D. (2006). Tuberculum sellae meningiomas: functional outcome in a consecutive series treated microsurgically. *Surgical Neurology*, Vol.66, No.1, (July 2006), pp. 37–44.
- Bhatia, S.; Bergethon, P.R.; Blease, S.; Kemper, T.; Rosiello, A.; Zimbardi, G.P.; Franzblau, C. & Spatz, E.L. (1995). A synthetic dural prosthesis constructed from hydroxyethylmethacrylate hydrogels. *Journal of Neurosurgery*, Vol.83, No.5, (November 1995), pp. 897-902.
- Biroli, F.; Fusco, M.; Bani, G.G.; Signorelli, A.; Esposito, F.; de Divitiis, O.; Cappabianca, P.; Cavallo, L.M. (2008). Novel equine collagen-only dural substitute. *Neurosurgery*, Vol.62, No.3 Suppl.1, (March 2008), pp. 273–274.
- Black, P. (2000). Cerebrospinal fluid leaks following spinal or posterior fossa surgery: use of fat grafts for prevention and repair. *Neurosurgical Focus*, Vol.9, No.1, (July 2000).
- Cappabianca, P.; Esposito, F.; Cavallo, L.M.; Messina, A.; Solari, D.; di Somma, L.G.M. & de Divitiis, E. (2006). Use of equine collagen foil as dura mater substitute in endoscopic endonasal transsphenoidal surgery. *Surgical Neurology*, Vol.65, No.2, (February 2006), pp. 144–149.
- Caroli, E.; Rocchi, G.; Salvati, M. & Delfini R. (2004). Duraplasty: Our Current Experience. *Surgical Neurology*, Vol.61, No.1, (January 2004), pp. 55–59.
- Chaplin, J.M.; Costantino, P.D.; Wolpoe, M.E.; Bederson, J.B.; Griffey, E. & Zanh, W.X. (1999). Use of Acellular dermal allograft for dural replacement: an experimental study. *Neurosurgery*, Vol.45, No.2, (August 1999), pp. 320–327.
- Chappell, E.T.; Pare, L.; Salehpour, M.; Mathews, M. & Middlehof, C. (2009). GORE PRECLUDE MVP dura substitute applied as a nonwatertight "underlay" graft for craniotomies: product and technique evaluation. *Surgical Neurology*, Vol.71, No.1, (January 2009), pp. 126–129.
- Cohen-Gadol, A.A.; Bellew, M.P.; Akard, W. & Payner, T.D. (2010). The application of n-butyl 2-cyanoacrylate to repair CSF fistulas for 221 patients who underwent transsphenoidal surgery. *Minimally Invasive Neurosurgery*, Vol.53, No.4, (August 2010), pp. 207-209.
- Cosgrove, G.R.; Delashaw, J.B.; Grotenhuis, J.A.; Tew, J.M.; Van Loveren, H.; Spetzler, R.F.; Payner, T.; Rosseau, G.; Shaffrey, M.E.; Hopkins, L.N.; Byrne, R. & Norbash, A. (2007). Safety and efficacy of a novel polyethylene glycol hydrogel sealant for watertight dural repair. *Journal of Neurosurgery*, Vol.106, No.1, (January 2007), pp. 52–58.
- Dusick, J.R.; Mattozo, C.A.; Esposito, F. & Kelly, D.F. (2006). BioGlue for prevention of postoperative cerebrospinal fluid leaks in transsphenoidal surgery: A case series. *Surgical Neurology*, Vol.66, No.4, (October 2006), pp. 371-376.
- El Majdoub, F.; Lohr, M.; Maarouf, M.; Brunn, A.; Stenzel, W. & Ernestus, R.I. (2009). Transmigration of fibrino-purulent inflammation and malignant cells into an artificial dura substitute (Neuro-Patch): report of two cases. *Acta Neurochirurgica*, Vol.151, No.7, (July 2009), pp. 833–835.
- Epstein N.E. (2010). Dural repair with four spinal sealants: focused review of the manufacturers' inserts and the current literature. *The Spine Journal*, Vol.10, No.12, (December 2010), pp. 1065–1068.


- Forgacs, P.; Geyer, C.A. & Freidberg, S.R. (2001). Characterization of chemical meningitis after neurological surgery. *Clinical Infectious Disease*, Vol.32, No.2, (January 2001), pp. 179–185.
- Frank, G. & Pasquini, E. (2010). Tuberculum Sellae Meningioma: The Extended Transsphenoidal Approach - For the Virtuoso Only? *World Neurosurgery*, Vol.73, No.6, (June 2010), pp. 625–626.
- Gazzeri, R.; Neroni, M.; Alfieri, A.; Galarza, M.; Faiola, A.; Esposito, S. & Giordano, M. (2009). Transparent equine collagen biomatrix as dural repair. A prospective clinical study. *Acta Neurochirurgica*, Vol.151, No.5, (May 2009), pp. 537–543.
- Gazzeri, R.; Galarza, M.; Alfieri, A.; Neroni, M. & Roperto R. (2011). Simple intraoperative technique for minor dural gap repair using fibrin glue and oxidized cellulose. *World Neurosurgery*, Vol.76, No.1-2, (July-August 2011), pp. 173-175.
- Germani, R.M.; Vivero, R.; Herzallah, I.R. & Casiano, R.R. (2007). Endoscopic reconstruction of large anterior skull base defects using acellular dermal allograft. *American Journal of Rhinology*, Vol.21, No.5, (September-October 2007), pp. 615–618.
- Ghezzi, C.E.; Marelli, B.; Muja, N.; Hirota, N.; Martin, J.G.; Barralet, J.E.; Alessandrino, A.; Freddi, G. & Nazhat, S.N. (2011). Mesenchymal stem cell-seeded multilayered dense collagen-silk fibroin hybrid for tissue engineering applications. *Biotechnology Journal*, doi: 10.1002/biot.201100127.
- Gnanalingham, K.K.; Lafuente, J.; Thompson, D.; Harkness, W. & Hayward, R. (2002). Surgical procedures for posterior fossa tumors in children: does craniotomy lead to fewer complications than craniectomy? *Journal of Neurosurgery*, Vol.97, No.4, (October 2002), pp. 821–826.
- Hida, K.; Yamaguchi, S.; Seki, T.; Yano, S.; Akino, M.; Terasaka, S.; Uchida, T. & Iwasaki, Y. (2006). Nonsuture dural repair using polyglycolic acid mesh and fibrin glue: clinical application to spinal surgery. *Surgical Neurology*, Vol.65, No.2, (February 2006), pp. 136–142.
- Hwang, P.H. & Jackler R.K. (1996). Lipoid meningitis due to aseptic necrosis of a free fat graft placed during neurotologic surgery. *Laryngoscope*, Vol.106, No.12 Pt.1, (December 1996), pp. 1482–1486.
- Islam, S.; Ogane, K.; Ohkuma, H. & Suzuki, S. (2004). Usefulness of acellular dermal graft as a dural substitute in experimental model. *Surgical Neurology*, Vol.61, No. 3, (March 2004), pp. 297–302.
- Ito, H.; Kimura, T.; Sameshima, T.; Aiyama, H.; Nishimura, K.; Ochiai, C. & Morita, A. (2011). Reinforcement of pericranium as a dural substitute by fibrin sealant. *Acta Neurochirurgica*, Vol.6, (July 2011).
- Jallo, G.I. & Benjamin, V. (2002). Tuberculum sellae meningiomas: microsurgical anatomy and surgical technique. *Neurosurgery*, Vol.51, No.6, (December 2002), pp. 1432–1439.
- Kassam, A.; Carrau, R.L. & Snyderman, C.H. (2005). Evolution of reconstructive techniques following endoscopic expanded endonasal approaches. *Neurosurgical Focus*, Vol.19, No.1, (July 2005).
- Kim, D.W.; Eum, W.S.; Jang, S.H.; Park, J.; Heo, D.H.; Sheen, S.H.; Lee, H.R.; Kweon, H.; Kang, S.W.; Lee, K.G.; Cho, S.Y.; Jin H.J.; Cho, Y.J. & Choi, S.Y. (2011). A transparent artificial dura mater made of silk fibroin as an inhibitor of

- inflammation in craniotomized rats. *Journal of Neurosurgery*, Vol. 114, No.2, (February 2011), pp. 485–490.
- Knopp, U.; Christmann, F.; Reusche, E. & Sepehrnia, A. (2005). A new collagen biomatrix of equine origin versus a cadaveric dura graft for the repair of dural defects—a comparative animal experimental study. *Acta Neurochirurgica*, Vol.147, No.8, (August 2005), pp. 877–887.
- Lee, J.H. (2008). *Meningiomas*, Springer-Verlag, 978-1-84628-526-4, London.
- Liu, J.K.; Christiano, L.D.; Patel, S.K.; Tubbs, S. & Eloy, J.A. (2011). Surgical nuances for removal of olfactory groove meningiomas using the endoscopic endonasal transcribriform approach. *Neurosurgical Focus*, Vol.30, No.5, (May 2011), E3.
- McAllister, J.D.; Scotti, L.N. & Bookwalter, J.W. (1992). Postoperative dissemination of fat particles in the subarachnoid pathways. *American Journal of Neuroradiology*, Vol.13, No.4, (July-August 1992), pp. 1265–1267.
- Megyesi, J.F.; Ranger, A.; MacDonald, W. & Del Maestro, R.F. (2004). Suturing technique and the integrity of dural closures: an in vitro study. *Neurosurgery*, Vol.55, No.4, (October 2004), pp. 950–954.
- Mello, L.R.; Feltrin, L.T.; Fontes Neto, P.T. & Ferraz, F.A. (1997). Duraplasty with biosynthetic cellulose: an experimental study. *Journal of Neurosurgery*, Vol.86, No.1, (January 1997), pp. 143–150.
- Moskowitz, S.I.; Liu, J. & Krishnaney, A.A. (2009). Postoperative complications associated with dural substitutes in suboccipital craniotomies. *Neurosurgery*, Vol.64, No.3 Suppl., (March 2009), pp. 28–34.
- Narotam, P.K.; van Dellen, J.R. & Bhoola, K.D. (1995). A clinicopathological study of collagen sponge as a dural graft in neurosurgery. *Journal of Neurosurgery*, Vol. 82, No.3, (March 1995), pp. 406–412.
- Narotam, P.K.; Reddy, K.; Fewer, D.; Qiao, F. & Nathoo, N. (2007) Collagen matrix duraplasty for cranial and spinal surgery: a clinical and imaging study. *Journal of Neurosurgery*, Vol.106, No.1, (January 2007), pp. 45–51.
- Narotam, P.K.; Qiao, F. & Nathoo, N. (2009). Collagen matrix duraplasty for posterior fossa surgery: evaluation of surgical technique in 52 adult patients. *Journal of Neurosurgery*, Vol.111, No.2, (August 2009), pp. 380–386.
- Palm, S.J.; Kirsch, W.M.; Zhu, Y.H.; Peckham, N.; Kihara, S.; Anton, R.; Anton, T.; Balzer, K. & Eickmann, T. (1999). Dural closure with nonpenetrating clips prevents meningoneural adhesions: an experimental study in dogs. *Neurosurgery*, Vol.45, No.4, (October 1999), pp. 881–882.
- Parizek, J.; Měricka, P.; Husek, Z.; Suba, P.; Spacek, J. & Nomecek, S. (1997). Detailed evaluation of 2959 allogeneic and xenogeneic dense connective tissue grafts (fascia lata, pericardium, and dura mater) used in the course of 20 years for duraplasty in neurosurgery. *Acta Neurochirurgica*, Vol.139, No.9, pp. 827–838.
- Parlato, C.; di Nuzzo, G.; Luongo, M.; Parlato, R.S.; Accardo, M.; Cuccurullo, L.; Moraci, A. (2011). Use of a collagen biomatrix (TissuDura) for dura repair: a long-term neuroradiological and neuropathological evaluation. *Acta Neurochirurgica*, Vol.153, No.1, (January 2011), pp. 142–147.
- Protasoni, M.; Sangiorgi, S.; Cividini, A.; Culuaris, G.T.; Tomei, G.; Dell'Orbo, C.; Raspanti, M.; Balbi, S. & Reguzzoni, M. (2011). The collagenic architecture of human dura mater. *Journal of Neurosurgery*, Vol.114, No.6, (June 2011), pp. 1723–1730.

- Reddy, M.; Schoggl, A.; Reddy, B.; Saringer, W.; Weigel, G. & Matula, C. (2002). A Clinical Study of a Fibrinogen-Based Collagen Fleece for Dural Repair in Neurosurgery. *Acta Neurochirurgica*, Vol.144, No.3, (March 2002), pp. 265-269.
- Ricaurte, J.C.; Murali, R. & Mandell, W. (2000). Uncomplicated postoperative lipoid meningitis secondary to autologous fat graft necrosis. *Clinical Infectious Disease*, Vol.30, No.3, (March 2000), pp. 613-615.
- Sade, B.; Oya, S. & Lee, J.H. (2011). Non-watertight dural reconstruction in meningioma surgery: results in 439 consecutive patients and a review of the literature. *Journal of Neurosurgery*, Vol.114, No.3, (March 2011), pp. 714-718.
- Saeki, N.; Horiguchi, K.; Murai, H.; Hasegawa, Y.; Hanazawa, T. & Okamoto, Y. (2010). Endoscopic endonasal pituitary and skull base surgery. *Neurologia Medico-Chirurgica (Tokyo)*, Vol.50, No.9, pp. 756-764.
- San-Galli, F.; Deminiere, C.; Guerin, J. & Rabaud M. (1996). Use of a biodegradable elastin-fibrin material, Neoplast, as a dural substitute. *Biomaterials*, Vol.17, No.11, (June 1996), pp. 1081-1085.
- Schick, B.; Wolf, G.; Romeike, B.F.; Mestres, P.; Praetorius, M. & Plinkert, P.K. (2003). Dural cell culture. A new approach to study duraplasty. *Cells Tissues Organs*, Vol.173, No.3, pp. 129-137.
- Seo, H.S.; Jung, J.K.; Lim, M.H.; Hyun, D.K.; Oh, N.S. & Yoon, S.H. (2009). Evaluation of Spinal Fusion Using Bone Marrow Derived Mesenchymal Stem Cells with or without Fibroblast Growth Factor-4. *Journal of Korean Neurosurgical Society*, Vol.46, No.4, pp. 397-402.
- Simpson, D.L.; Boyd, N.L.; Kaushal, S.; Stice, S.L. & Dudley, S.C. Jr. (2011). Use of human embryonic stem cell derived-mesenchymal cells for cardiac repair. *Biotechnology and Bioengineering*, doi: 10.1002/bit.23301.
- Stendel, R.; Danne, M.; Fiss, I.; Klein, I.; Schilling, A.; Hammersen, S.; Pietilae, T.; Janisch, W. & Hopfenmuller, W. (2008). Efficacy and safety of a collagen matrix for cranial and spinal dural reconstruction using different fixation techniques. *Journal of Neurosurgery*, Vol.109, No.2, (August 2008), pp. 215-221.
- Sugawara, T.; Itoh, Y.; Hirano, Y.; Higashiyama, N.; Shimada, Y.; Kinouchi, H. & Mizoi, K. (2005). Novel dural closure technique using polyglactin acid sheet prevents cerebrospinal fluid leakage after spinal surgery. *Neurosurgery*, Vol.57, No.4 Suppl, (October 2005), pp. 290-294.
- Taha, A.N.; Almefty, R.; Pravdenkova, S. & Al-Mefty, O. (2011). Sequelae of Autologous Fat Graft Used for Reconstruction in Skull Base Surgery. *World Neurosurgery*, Vol.75, No.5-6, (May-June 2011), pp. 692-695.
- Than, K.D.; Baird, C.J. & Olivi, A. (2008). Polyethylene glycol hydrogel dural sealant may reduce incisional cerebrospinal fluid leak after posterior fossa surgery. *Neurosurgery*, Vol. 63, No.1, (July 2008), pp. 186-187.
- Verheggen, R.; Schulte-Baumann, W.J.; Hahm, G.; Lang, J.; Freudenthaler, S.; Schaake, T. & Markakis, E. (1997). A new technique of dural closure--experience with a vicryl mesh. *Acta Neurochirurgica*, Vol.139, No.11, pp. 1074-1079.
- Wang, Q.; Lu, X.J.; Ji, W.Y.; Yan, Z.C.; Xu, J.; Ding, Y.S. & Zhang, J. (2010). Visual Outcome After Extended Endoscopic Endonasal Transsphenoidal Surgery for Tuberculum Sellae Meningiomas. *World Neurosurgery*, Vol.73, No.6, (June 2010), pp. 694-700.

- Warren, W.L.; Medary, M.B.; Dureza, C.D.; Bellotte, J.B.; Flannagan, P.P.; Oh, M.Y. & Fukushima, T. (2000). Dural repair using acellular human dermis: experience with 200 cases: technique assessment. *Neurosurgery*, Vol.46, No.6, (June 2000), pp. 1391-1396.
- Wolf, G.; Plinkert, P.K. & Schick, B. (2005). Cell transplantation for a CSF-fistula. Experience with fibrin glue and fibroblasts. *HNO*, Vol.53, No.5, pp. 439-445.
- Yamada, K.; Miyamoto, S.; Nagata, I.; Kikuchi, H.; Ikada, Y.; Iwata, H. & Yamamoto, K. (1997). Development of a dural substitute from synthetic bioabsorbable polymers. *Journal of Neurosurgery*, Vol.86, No.6, (June 1997), pp. 1012-1017.
- Zhou, F.; Chen, G.; Zhang, J.M. & Huang, Z.S. (2006). An in vitro culturing model for rabbit dural cells. *Annals of Clinical and Laboratory Science*, Vol.36, No.3, pp. 341-344.

IntechOpen



Meningiomas - Management and Surgery

Edited by Dr. Daniel Monleon

ISBN 978-953-51-0175-8

Hard cover, 136 pages

Publisher InTech

Published online 02, March, 2012

Published in print edition March, 2012

This book is aimed at neurosurgeons with an interest in updating their knowledge on the latest state of meningiomas surgery and management. The book is focused at performing a portrait of that what is state of the art in management of meningiomas. All the chapters have been developed with high quality and including the most modern approaches for the different aspects they deal with. The book concentrates on those problems that, although perhaps less common in the day to day routine of the average neurosurgeon, when present pose a special challenge. This is neither a "how to" book nor a book about meningioma biology. It presents some of the most relevant aspects in the latest developments for meningioma surgery and management in a clear and professional manner.

How to reference

In order to correctly reference this scholarly work, feel free to copy and paste the following:

Ciro Parlato, Roberto Granata, Aldo Moraci and Marina Accardo (2012). Dural Reconstruction in Meningioma Surgery, Meningiomas - Management and Surgery, Dr. Daniel Monleon (Ed.), ISBN: 978-953-51-0175-8, InTech, Available from: <http://www.intechopen.com/books/meningiomas-management-and-surgery/dural-reconstruction-in-meningioma-surgery>

INTECH
open science | open minds

InTech Europe

University Campus STeP Ri
Slavka Krautzeka 83/A
51000 Rijeka, Croatia
Phone: +385 (51) 770 447
Fax: +385 (51) 686 166
www.intechopen.com

InTech China

Unit 405, Office Block, Hotel Equatorial Shanghai
No.65, Yan An Road (West), Shanghai, 200040, China
中国上海市延安西路65号上海国际贵都大饭店办公楼405单元
Phone: +86-21-62489820
Fax: +86-21-62489821

© 2012 The Author(s). Licensee IntechOpen. This is an open access article distributed under the terms of the [Creative Commons Attribution 3.0 License](#), which permits unrestricted use, distribution, and reproduction in any medium, provided the original work is properly cited.

IntechOpen

IntechOpen